EJCRIM
European Journal
of Case Reports
in Internal Medicine

# TO BLEED OR NOT TO BLEED: MANAGING ACUTE PULMONARY EMBOLISM IN HEREDITARY HAEMORRHAGIC TELANGIECTASIA

Isabella Fantoni, Mohammad Jakir Ahmed

Cardiology Department, West Hertfordshire Teaching Hospitals NHS Trust, Watford, United Kingdom

**Corresponding author's e-mail:** jakir.ahmed4@nhs.net

**Received:** 06/10/2026
**Accepted:** 27/10/2026
**Published:** 23/11/2026

**Conflicts of Interests:** The Authors declare no conflict of interest.
**Patient Consent:** Written informed consent was obtained from the patient for the publication of her clinical history and accompanying data. A signed consent form has been retained by the authors and is available to the editor on request.
**Acknowledgments:** The authors are grateful to the haematology, respiratory, and ear, nose and throat teams at West Hertfordshire Teaching Hospitals NHS Trust for their contribution to this patient's care.
**This article is licensed under a CC Attribution-NonCommercial-NoDerivatives 4.0 License**

**How to cite this article:** Fantoni I, Ahmed MJ. To bleed or not to bleed: managing acute pulmonary embolism in hereditary haemorrhagic telangiectasia. EJCRIM 2026;13:doi:10.12890/2026_007589

## ABSTRACT

*Introduction:* Hereditary haemorrhagic telangiectasia is the second most common inherited bleeding disorder yet confers an increased risk of venous thromboembolism. International guidance recommends anticoagulation when indicated but this guidance is built on low-quality evidence.

*Case description:* A 66-year-old woman with severe hereditary haemorrhagic telangiectasia presented with pleuritic chest pain, fever and tachycardia. Her history included recurrent transfusion-dependent epistaxis, pulmonary and hepatic arteriovenous malformations, iron deficiency anaemia and atrial fibrillation, for which anticoagulation had previously been stopped. She was discharged twice with a presumed respiratory infection and admitted on a third attendance with atrial fibrillation and hypotension. On Day 4, D-dimer was 4,387 ng/ml and computed tomography pulmonary angiography confirmed bilateral pulmonary emboli. Therapeutic low-molecular-weight heparin was suspended within 24 hours for epistaxis; warfarin produced gingival bleeding with a slow international normalised ratio response; apixaban was tolerated as an inpatient, but she attended the emergency department three times within seven weeks with prolonged epistaxis and a haemoglobin fall to 86 g/l.

*Discussion:* Bleeding recurred across every anticoagulant class, consistent with cohort data reporting dose reduction or discontinuation in approximately half of treated patients irrespective of agent. Fever contributed to diagnostic anchoring on infection.

*Conclusion:* Guidance directs clinicians to anticoagulate but not how to do so when bleeding recurs. Management depends on individualised, repeatedly revisited risk-benefit assessment and genuine shared decision-making.

## KEYWORDS

Hereditary haemorrhagic telangiectasia (HHT), pulmonary embolism, anticoagulation, apixaban, diagnostic error in hereditary haemorrhagic telangiectasia

EFIM
European Federation of Internal Medicine

Publisher
smc media srl

## LEARNING POINTS

- International guidance strongly recommends that patients with hereditary haemorrhagic telangiectasia receive anticoagulation when there is an indication, since bleeding is not an absolute contraindication; however, this recommendation rests on low-quality evidence and offers no direction on agent, dose or how to proceed when bleeding recurs despite appropriate prescribing.
- Anchoring on a known bleeding diathesis delayed recognition of pulmonary embolism across three attendances. Fever, present throughout, is an underappreciated manifestation of pulmonary embolism that reinforced a misleading infective diagnosis.
- Bleeding recurred across heparin, vitamin K antagonist and direct oral anticoagulant therapy, mirroring cohort data. Antifibrinolytics, the obvious adjunct to improve tolerability, are relatively contraindicated in acute venous thromboembolism, leaving shared decision-making as the principal tool.

## INTRODUCTION

Hereditary haemorrhagic telangiectasia (HHT), or Osler–Weber–Rendu disease, is an autosomal dominant disorder of dysregulated angiogenesis affecting approximately 1 in 5,000 people, making it the second most common inherited bleeding disorder[1]. Mucocutaneous telangiectasia and visceral arteriovenous malformations (AVMs) cause recurrent epistaxis and gastrointestinal haemorrhage, frequently with transfusion-dependent iron deficiency anaemia[1].

Despite this haemorrhagic phenotype, HHT offers no protection against thrombosis and appears to increase it. Factor VIII antigen concentrations are elevated relative to matched controls and rise with age; venous thromboembolism (VTE) affected 6.5% of 309 consecutive patients in one cohort[2]. Low serum iron independently predicts both elevated Factor VIII and VTE, so the chronic anaemia produced by HHT bleeding may itself drive a prothrombotic state[3].

The Second International HHT Guidelines for the Diagnosis and Management of Hereditary Hemorrhagic Telangiectasia (2020) address this tension directly. Recommendation C5 states that patients with HHT should receive anticoagulant or antiplatelet therapy, prophylactic or therapeutic, when there is an indication, with consideration of individualised bleeding risk, and that bleeding in HHT is not an absolute contraindication to these therapies. This is a strong recommendation with 98% panel agreement, but the underlying quality of evidence is graded low. Recommendation C6 advises avoiding dual antiplatelet therapy, or the combination of antiplatelet and anticoagulant therapy, wherever possible[4]. What such guidance cannot supply, given that evidence base, is direction on agent selection, dose intensity or the course to take when bleeding recurs despite appropriate prescribing. The authors describe a patient in whom each of these questions arose in turn.

## CASE DESCRIPTION

A 66-year-old woman with severe HHT presented with a two-week history of pleuritic chest pain, productive cough and intermittent fever. Her history included recurrent epistaxis requiring repeated cauterisation and transfusion, chronic iron deficiency anaemia, hypertension and persistent atrial fibrillation (AF) diagnosed one year earlier. Oral anticoagulation for stroke prevention had been discontinued because of mucosal bleeding from the oral and ocular surfaces. Imaging two years previously had demonstrated two left-sided pulmonary AVMs and a small hepatic AVM. She had self-discontinued bisoprolol over concerns about hypotension.

At first attendance she was hypotensive (93/56 mmHg), tachycardic (90-110 bpm), tachypnoeic (24 breaths/min) and febrile (38°C), with oxygen saturations of 97% on air. She was treated empirically for a lower respiratory tract infection and discharged with oral antibiotics.

She returned one week later with persistent left-sided chest pain and tachycardia to 120 bpm. Lactate was 2.1 mmol/l, and the attendance was complicated by active epistaxis. Acute coronary syndrome was excluded, and she was referred to ambulatory care, where she remained hypotensive (84/55 mmHg) with AF at 119 bpm and a pansystolic murmur. The working diagnosis was symptomatic AF with rapid ventricular response, attributed to beta-blocker cessation and haemodynamic compromise from epistaxis, and she was admitted under cardiology. Haemoglobin was 102 g/l, consistent with an established baseline of 99-105 g/l. Chest radiography showed a left retrocardiac density reported as focal infective change. Echocardiography 16 months earlier had shown preserved left ventricular function, left atrial dilatation and no patent foramen ovale on contrast study.

Digoxin and low-dose bisoprolol were commenced for rate control, digoxin being chosen because it would not lower the patient's blood pressure further. The patient's CHA2DS2-VASc score was 3 (2 excluding female sex). Long-term anticoagulation was considered unsafe given her bleeding history, and the patient was referred for pulmonary vein isolation with left atrial appendage occlusion as a route to reducing stroke risk without indefinite anticoagulation.

On Day 4 of admission, she reported ongoing pleuritic pain

and palpitations. D-dimer was 4,387 ng/ml, and computed tomography pulmonary angiography demonstrated acute emboli at the bifurcation of the right main pulmonary artery extending into the right upper, middle and lower lobe branches, with further emboli in the lingula and left lower lobe. There was a small left pleural effusion without right heart strain.

Therapeutic enoxaparin (1 mg/kg twice daily) was commenced following haematology review, at a haemoglobin of 105 g/l. Within 24 hours she developed significant epistaxis with clot expectoration and it was suspended. Haematology advised resuming treatment dose if tolerated, with intermediate or prophylactic dosing as a fallback, in keeping with recommendation C5[4]; haemoglobin remained stable at 102 g/l four days later. An inferior vena cava filter was judged inappropriate for established pulmonary embolism without proximal deep vein thrombosis, and tertiary centres declined mechanical thrombectomy.

After prolonged multidisciplinary discussion involving cardiology, haematology, respiratory medicine, and ear, nose and throat (ENT), the patient and her family, warfarin with low-molecular-weight heparin bridging was agreed. She declined bridging despite repeated explanation of the risks, which was documented as an informed decision. Warfarin alone produced new spontaneous gingival bleeding with a predictably slow international normalised ratio response and was stopped. Apixaban 5 mg twice daily was commenced and tolerated through 48 hours of inpatient monitoring. ENT review identified bilateral tortuous anastomoses on the nasal septum and floor; she declined cauterisation. She was discharged after 22 days with a haemoglobin of 104 g/l.

She re-attended 18 days later with nasal, ocular and mucosal bleeding lasting six and three hours; haemoglobin had fallen to 86 g/l and her general practitioner had already reduced apixaban to 2.5 mg twice daily. Two further attendances followed, the last with 12 hours of epistaxis and posterior oropharyngeal drainage, managed with compression, silver nitrate cautery and tranexamic acid *(Fig. 1 and Table 1)*.

## DISCUSSION

This case illustrates the distance between a strong guideline recommendation and the bedside decisions it is meant to govern. Recommendation C5 settles the question of whether to anticoagulate: bleeding in HHT is not an absolute contraindication, and withholding therapy from a patient with extensive bilateral pulmonary emboli would have been indefensible[4]. It is silent on what to do when

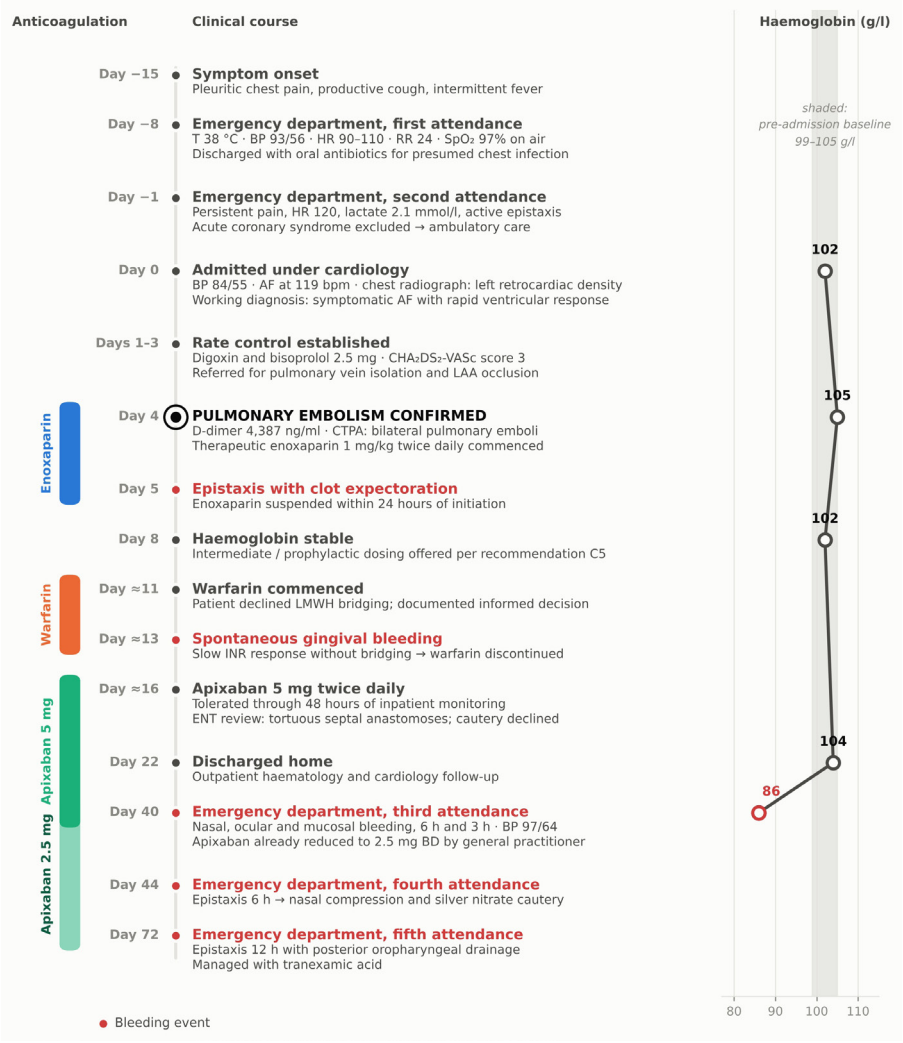


***Figure 1.*** *Clinical timeline from symptom onset to the final emergency department attendance, showing the sequence of anticoagulant agents, bleeding events and haemoglobin trajectory. Day 0 denotes admission under cardiology. Days marked ≈ are approximate.*

*Abbreviations: AF, atrial fibrillation; CTPA, computed tomography pulmonary angiography; ENT, ear, nose and throat; INR, international normalised ratio; LAA, left atrial appendage; LMWH, low-molecular-weight heparin.*

| Agent and dose | Setting | Bleeding outcome | Action taken |
|---|---|---|---|
| Enoxaparin 1 mg/kg twice daily | Inpatient, Day 4 | Significant epistaxis with clot expectoration within 24 hours; Hb 105 to 102 g/l | Suspended; intermediate or prophylactic dosing offered |
| Warfarin, no bridging (patient declined) | Inpatient | New spontaneous gingival bleeding | Discontinued; INR response slow without bridging |
| Apixaban 5 mg twice daily | Inpatient, 48-hour monitoring | No bleeding during admission; Hb 104 g/l at discharge | Continued at discharge |
| Apixaban 2.5 mg twice daily | Community, after discharge | Three emergency attendances in seven weeks; Hb nadir 86 g/l | Dose reduced by general practitioner; compression, cautery, tranexamic acid |

***Table 1.*** *Sequential anticoagulation strategies, bleeding outcomes and actions taken.*
*Abbreviations: Hb, haemoglobin; INR, international normalised ratio.*

the first agent fails, then the second. Our patient bled on heparin, on a vitamin K antagonist and, after discharge, on a direct oral anticoagulant. This is the expected pattern *(Table 2)*. Approximately half of patients in the largest published cohort dose-reduced or discontinued therapy because of worsened bleeding, at similar rates across agent classes, and initiation at reduced dose intensity conferred no advantage[5]. Her better inpatient tolerance of apixaban is consistent with a European audit in which discontinuation was required in 26.7% of apixaban episodes against 50% of rivaroxaban episodes[6]. A 2026 report follows a strikingly similar trajectory: a 58-year-old woman with HHT and acute pulmonary embolism tolerated apixaban initially, was de-escalated to 2.5 mg twice daily, then required three admissions for gastrointestinal bleeding, with a haemoglobin nadir of 44 g/l, before anticoagulation was abandoned at 19 months in favour of an inferior vena cava filter and bevacizumab[7]. The bleeding site differed, gastrointestinal rather than mucosal, but the pattern did not: early tolerance, progressive attrition, eventual abandonment. Throughout, our patient received single-agent therapy, consistent with recommendation C6[4]. The second lesson concerns diagnosis. She attended three times before pulmonary embolism was considered, with clinical attention anchored on a known bleeding diathesis and on presumed infection. Fever was central to this: present at 38°C from the outset, it supported empirical antibiotics and, combined with pleuritic pain and a retrocardiac density, produced a coherent but incorrect picture of pneumonia. Fever is a recognised though underappreciated feature of pulmonary embolism and has been reported as the dominant presenting symptom with no identifiable infective cause[8]. Given the association between HHT, elevated Factor VIII, iron deficiency and

| Study | Design and size | Bleeding outcome | Dose reduction or discontinuation |
|---|---|---|---|
| Virk et al.[5] | Multicentre retrospective cohort; 119 patients, 187 treatment episodes | Haemoglobin 108 g/l in the three months after initiation against 122 g/l before; increased intravenous iron, transfusion and admissions | 50% overall. Warfarin 46%, heparins 48%, direct oral anticoagulants 44% |
| Shovlin et al.[6] | Retrospective audit across eight European HHT centres; 28 patients, 32 episodes | Epistaxis worsened in 24 of 32 episodes (75%) | 34.4% overall. Apixaban 26.7%, rivaroxaban 50% |
| Carfagnini and Kandula[7] | Single case; apixaban over 19 months | Three admissions with gastrointestinal bleeding from angioectasias; haemoglobin nadir 44 g/l, six units transfused | De-escalated at 6 months; discontinued at 19 months, with inferior vena cava filter and bevacizumab |
| The present case | Single case; four treatment episodes | Bleeding on all three anticoagulant classes; haemoglobin nadir 86 g/l | Enoxaparin and warfarin discontinued; apixaban dose-reduced |

***Table 2.*** *Published outcomes of anticoagulant therapy in hereditary haemorrhagic telangiectasia, with this case for comparison.*
*Abbreviations: HHT, hereditary haemorrhagic telangiectasia; VASCERN, European Reference Network for Rare Multisystemic Vascular Diseases.*

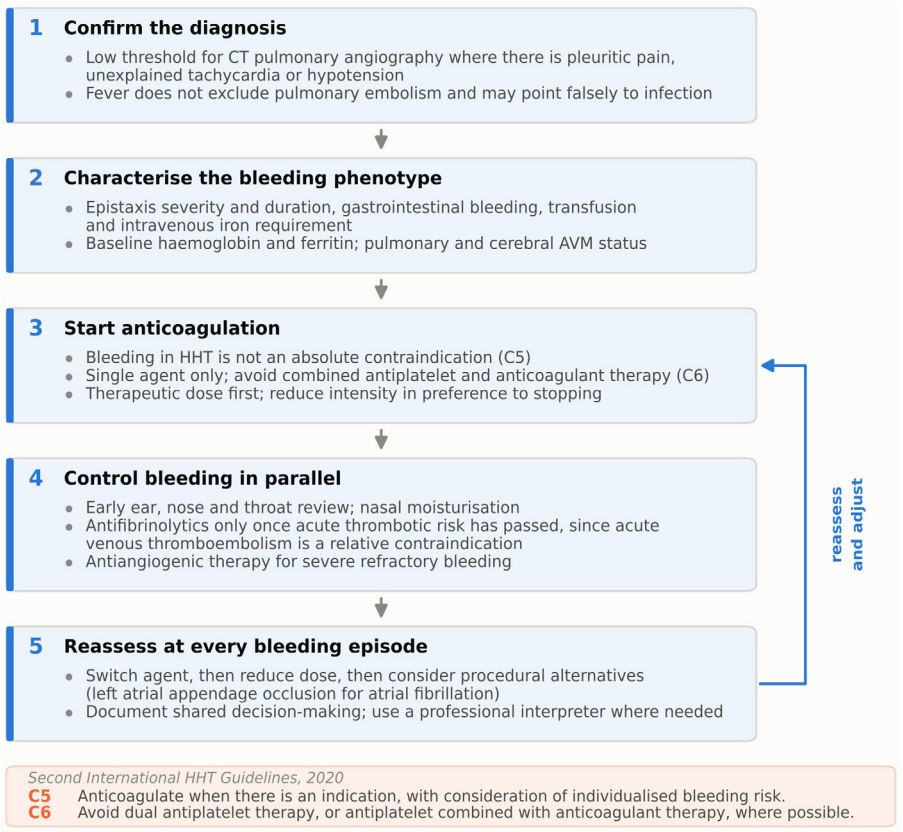


***Figure 2.*** *Suggested approach to acute venous thromboembolism in hereditary haemorrhagic telangiectasia, incorporating recommendations C5 and C6 of the Second International HHT Guidelines.*
*Abbreviations: AVM, arteriovenous malformation; CT, computed tomography; HHT, hereditary haemorrhagic telangiectasia.*

VTE[2,3], a lower threshold for investigating pulmonary embolism is warranted in these patients when pleuritic pain, unexplained tachycardia or hypotension is present, particularly where fever invites an infective explanation.

Adjunctive measures to improve tolerability are constrained in precisely this situation. Antifibrinolytics and systemic antiangiogenic agents have been proposed to enable antithrombotic therapy in HHT[9], but acute VTE is a relative contraindication to antifibrinolytic therapy, so the obvious adjunct is least available when it is most needed. Tranexamic acid was given to our patient only once bleeding had become the dominant acute problem.

What remained was shared decision-making, and this was itself impeded. Depression and post-traumatic stress disorder occur at elevated rates in HHT [10]; for our patient, the prospect of worsened epistaxis was not an abstract risk but a threat to daily function, and it underpinned her refusal of bridging. A language barrier compounded this. Early discussions relied on translation applications or next of kin, by her preference or through limited availability of interpreters; once a professional interpreter service was used, she articulated a markedly clearer understanding of why anticoagulation was being recommended. Informal translation appears inadequate for deliberation of this complexity, and early professional interpretation may improve both the quality of consent and engagement with treatment.

## CONCLUSION

In summary, guidance tells us to anticoagulate patients with HHT when indicated, and it is right to do so. It does not tell us what to do when the patient bleeds on everything. In that situation, repeated reassessment, single-agent therapy, early ENT and haematology involvement, and an honest negotiation with a patient whose experience of bleeding is lifelong may matter more than the choice of molecule. *Figure 2* sets out the approach this case suggests.

## REFERENCES


1. Hermann R, Shovlin CL, Kasthuri RS, Serra M, Eker OF, Bailly S, et al. Hereditary haemorrhagic telangiectasia. Nat Rev Dis Primers. 2025;11:1. doi: 10.1038/s41572-024-00585-z.
2. Shovlin CL, Sulaiman NL, Govani FS, Jackson JE, Begbie ME. Elevated factor VIII in hereditary haemorrhagic telangiectasia (HHT): association with venous thromboembolism. Thromb Haemost. 2007;98 (5):1031-1039. doi: 10.1160/TH07-01-0064.
3. Livesey JA, Manning RA, Meek JH, Jackson JE, Kulinskaya E, Laffan MA, et al. Low serum iron levels are associated with elevated plasma levels of coagulation factor VIII and pulmonary emboli/deep venous thromboses in replicate cohorts of patients with hereditary haemorrhagic telangiectasia. Thorax. 2012;67:328-333. doi: 10.1136/thoraxjnl-2011-201076.
4. Faughnan ME, Mager JJ, Hetts SW, Palda VA, Lang-Robertson K, Buscarini E, et al. Second International Guidelines for the Diagnosis and Management of Hereditary Hemorrhagic Telangiectasia. Ann Intern Med. 2020;173:989–1001. doi: 10.7326/M20-1443.
5. Virk ZM, Zhang E, Rodriguez-Lopez J, Witkin A, Wong AK, Luther J, et al. Safety, tolerability, and effectiveness of anticoagulation and antiplatelet therapy in hereditary hemorrhagic telangiectasia. J Thromb Haemost. 2023;21:26-36. doi: 10.1016/j.jtha.2022.09.003.
6. Shovlin CL, Millar CM, Droege F, Kjeldsen A, Manfredi G, Suppressa P, et al. Safety of direct oral anticoagulants in patients with hereditary hemorrhagic telangiectasia. Orphanet J Rare Dis. 2019;14:210. doi: 10.1186/s13023-019-1179-1.
7. Carfagnini C, Kandula M. Safely treating a pulmonary embolism in a patient with hereditary hemorrhagic telangiectasia: a case report. Clin Case Rep. 2026;14(6):e72750. doi: 10.1002/ccr3.72750.
8. Natour HH, Elgardt I, Rotman-Pikielny P, Natour A, Natour A, Levy Y. Masquerading pulmonary embolism: fever as an overlooked clinical manifestation illustrated by four mini case series and literature review.

Am J Med. 2025;138:1124-1127. doi: 10.1016/j.amjmed.2025.02.026.
9. Al-Samkari H. How I treat bleeding in hereditary hemorrhagic telangiectasia. Blood. 2024;144:940-954. doi: 10.1182/blood.2023021765.
10. Chaturvedi S, Clancy M, Schaefer N, Oluwole O, McCrae KR. Depression and post-traumatic stress disorder in individuals with hereditary hemorrhagic telangiectasia: a cross-sectional survey. Thromb Res. 2017;153:14-18. doi: 10.1016/j.thromres.2017.03.003.