EJCRIM
European Journal
of Case Reports
in Internal Medicine

HOW LONG SHOULD IMMUNE CHECKPOINT INHIBITION THERAPY BE CONTINUED AFTER A COMPLETE RESPONSE IN ADVANCED UROTHELIAL CARCINOMA?

Maria João Oura[1], Rita Pinho[1], Rui Pinto[2], Inês Costa[1], Sara Meireles[1], Isabel Augusto[1]

[1] Medical Oncology Department, ULS São João, Porto, Portugal
[2] Urology Department, ULS São João, Porto, Portugal

Corresponding author's e-mail: mariajoao.oura@gmail.com

Received: 22/09/2026
Accepted: 12/10/2026
Published: 23/11/2026

Conflicts of Interests: The Authors declare no conflict of interest.
Patient Consent: Signed informed consent for publication was obtained from the patients.
This article is licensed under a CC Attribution-NonCommercial-NoDerivatives 4.0 License

How to cite this article: Oura MJ, Pinho R, Pinto R, Costa I, Meireles S, Augusto I. How long should immune checkpoint inhibition therapy be continued after a complete response in advanced urothelial carcinoma? EJCRIM 2026;13:doi:10.12890/2026_007537

ABSTRACT

Introduction: Immune checkpoint inhibitors (ICIs) can induce durable complete responses in advanced urothelial carcinoma (UC), raising an increasingly relevant clinical question: how long should treatment be continued once a sustained complete response has been achieved? The optimal duration of ICI therapy in this setting remains undefined.

Case description: We report two patients with advanced UC and durable complete responses during long-term ICI therapy. A 77-year-old man with recurrent, unresectable disease received carboplatin plus gemcitabine followed by avelumab maintenance from June 2021, achieving complete radiological response in January 2023, sustained for over three years. A 52-year-old man with extensive nodal involvement, considered unsuitable for chemotherapy because of recurrent severe infections, started pembrolizumab in April 2021. Nodal response enabled subsequent radical cystectomy, with complete radiological response documented in June 2022 and sustained for over four years. After a shared decision, both patients remain on ICI therapy more than five years after initiation.

Discussion: These cases highlight the uncertainty surrounding ICI duration in long-term complete responders. Avelumab maintenance is generally continued until progression or unacceptable toxicity, whereas pembrolizumab trials have typically limited treatment to approximately two years. Retrospective evidence suggests that elective discontinuation with subsequent retreatment may be feasible in selected responders, but the optimal timing and criteria for treatment cessation remain undefined.

KEYWORDS

Urothelial carcinoma, immune checkpoint inhibitors, avelumab, pembrolizumab, treatment discontinuation

LEARNING POINTS

- The optimal duration of immune checkpoint inhibition after a sustained complete response remains undefined, with different treatment-duration paradigms for pembrolizumab and avelumab maintenance.
- Available evidence suggests that treatment discontinuation may be feasible in selected responders, particularly after pembrolizumab, although the optimal timing and criteria for stopping treatment remain uncertain.
- In long-term complete responders, decisions regarding treatment discontinuation should consider response durability, treatment-related toxicity, patient preference, treatment burden, and the feasibility of retreatment upon disease progression.

EFIM
European Federation of Internal Medicine

Publisher
smc media srl

INTRODUCTION

Immune checkpoint inhibitors (ICIs) have substantially transformed the treatment of advanced urothelial carcinoma (UC). More recently, enfortumab vedotin plus pembrolizumab have become the preferred first-line treatment for most patients eligible for combination therapy[1]. Platinum-based chemotherapy followed by avelumab maintenance remains an established alternative when enfortumab vedotin is unavailable or inappropriate, while pembrolizumab monotherapy may be considered in selected patients who are ineligible for combination therapy and have PD-L1-positive disease[2,3].

As survival outcomes improve, the optimal duration of ICI therapy has emerged as an increasingly relevant but unresolved clinical question. Pembrolizumab has commonly been administered for a maximum of approximately two years[2], whereas avelumab maintenance is continued until disease progression or unacceptable toxicity[3]. Consequently, patients achieving prolonged complete responses may remain on treatment for several years despite limited evidence defining the additional benefit of continued ICI exposure.

We report two patients with advanced UC who have received continuous ICI therapy for more than five years while maintaining complete radiological responses, highlighting the uncertainty surrounding elective ICI discontinuation in exceptional long-term responders.

CASE DESCRIPTION

CASE 1

A 73-year-old man was diagnosed in 2016 with high-grade UC of the right renal pelvis (pT3N0R0) and concomitant high-grade non-muscle-invasive bladder UC. He underwent right nephroureterectomy with lymphadenectomy, and transurethral resection of the bladder tumour, followed by intravesical bacillus Calmette–Guérin (BCG) for two years, which was subsequently discontinued due to BCGitis.

In late 2020, at the age of 77, imaging revealed a right pelvic mass and iliac lymphadenopathy suspicious for recurrent disease. Surgical exploration in January 2021 demonstrated a pelvic nodal mass invading the terminal ileum and fixed to the pelvic wall. Segmental ileocolic resection was performed, but the residual pelvic disease was considered surgically unresectable. Histopathological examination confirmed invasive UC involving the ileum and metastatic lymph nodes.

The patient received four cycles of carboplatin (AUC 5) plus gemcitabine (1,000 mg/m^2 on days 1 and 8) between February and May 2021, achieving a partial radiological response. Chemotherapy was discontinued following severe mucositis complicated by gastrointestinal bleeding. Maintenance avelumab 800 mg every two weeks was initiated in June 2021. Serial imaging demonstrated progressive regression of the pelvic and retroperitoneal lymphadenopathy, with complete radiological response according to RECIST version 1.1 criteria, first documented in January 2023 *(Fig. 1)*. Subsequent imaging, including ^{18}F-fluorodeoxyglucose-positron emission tomography (FDG-PET)/computed tomography (CT) scan in September 2025 and CT scan of the chest, abdomen and pelvis in May 2026, showed no evidence of disease. Avelumab was generally well tolerated, with grade 1 immune-related thyrotoxicosis that subsequently resolved.

In October 2025, treatment discontinuation was discussed. After shared decision-making, the patient elected to continue avelumab. As of September 2026, he remains on treatment more than five years after initiation.

CASE 2

A 52-year-old man with paraplegia secondary to spinal cord trauma and a 32-pack-year smoking history presented with hematuria in early 2021. An incomplete transurethral resection of an extensive bladder tumor revealed high-grade muscle-invasive UC with squamous differentiation. Staging CT scan demonstrated invasive bladder wall thickening, bilateral hydronephrosis, and multiple pelvic and retroperitoneal lymph nodes suspicious for nodal involvement.

Bilateral nephrostomies were placed, with recovery of renal function. However, recurrent urinary tract infections required repeated hospitalizations and intravenous

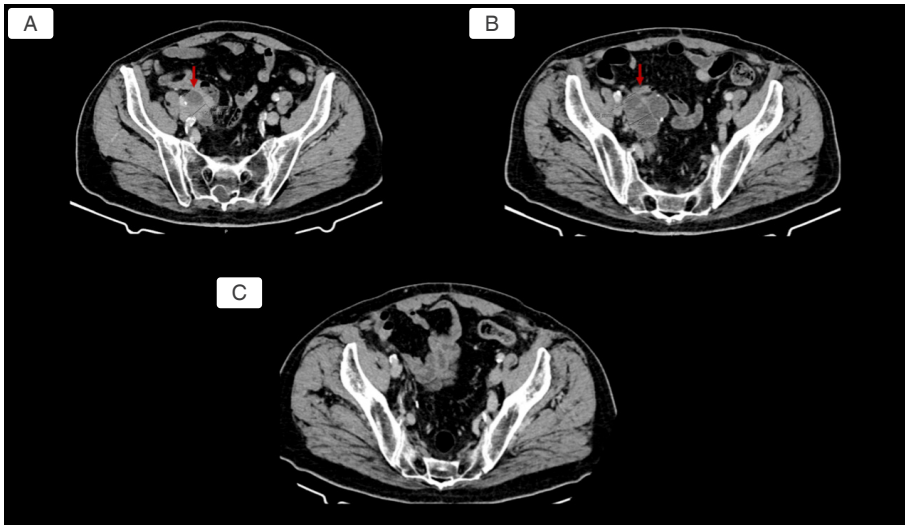

Figure 1. *Radiological evolution of Case 1. A) Computed tomography (CT) scan performed in November 2020 showing disease recurrence in the right hemipelvis. B) CT scan performed in May 2021, after four cycles of chemotherapy, showing the known necrotic adenopathy with increased necrotic component and decreased enhancing viable component, consistent with treatment response. C) CT scan performed in January 2023 showing no evidence of disease.*

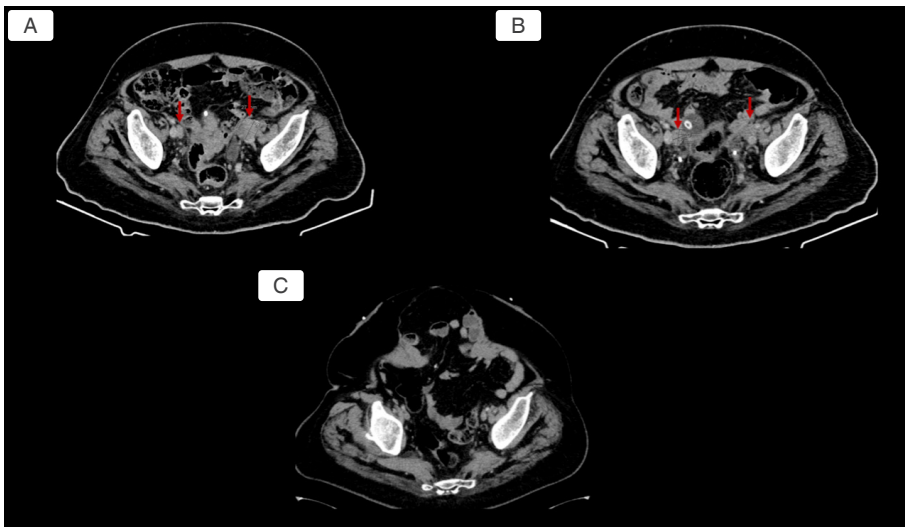

Figure 2. Radiological evolution of Case 2. A) Computed tomography (CT) scan performed in March 2021 showing bilateral external iliac lymphadenopathy, measuring 27 × 27 mm on the left and 19 × 14 mm on the right. B) CT scan performed in June 2021, after four cycles of pembrolizumab, showing a reduction in the size of the previously identified lymphadenopathy, consistent with treatment response. C) CT scan performed in June 2022 showing no evidence of disease.

antibiotics. Although platinum-based chemotherapy was initially considered, recurrent severe infections were considered to confer an unacceptable risk of infectious complications with cytotoxic chemotherapy. Programmed death-ligand 1 (PD-L1) testing showed a combined positive score >10. Given the therapeutic context at that time, recurrent severe infections, and a PD-L1 combined positive score >10, pembrolizumab 200 mg every three weeks was initiated in April 2021[2].

After four cycles, CT scan demonstrated reduction of the previously enlarged lymph nodes. Following multidisciplinary reassessment, salvage surgery with planned lymphadenectomy was undertaken in September 2021. Radical cystoprostatectomy with bilateral cutaneous ureterostomies was performed. However, the planned lymphadenectomy could not be completed because the lymph nodes were densely adherent to the major vessels. Histopathology showed residual high-grade invasive UC (pT3aNxR0). Given the previously documented extensive nodal disease and inability to perform lymphadenectomy, pembrolizumab was continued as systemic therapy.

In February 2022, pembrolizumab was switched to 400 mg every six weeks. Complete radiological response was documented in June 2022 *(Fig. 2)*, and serial imaging has since shown no evidence of disease, including the last CT scan in April 2026. Treatment has been well tolerated without immune-related adverse events.

After shared decision-making, the patient elected to continue pembrolizumab. As of September 2026, he remains on treatment more than five years after initiation, with sustained response and no reported treatment-related toxicity.

The clinical course and treatment timeline of both patients are summarized in *Figure 3*.

DISCUSSION

These cases illustrate an increasingly relevant but unresolved question in advanced UC: once a durable complete response has been achieved with immune checkpoint inhibition, when, if ever, can treatment be safely discontinued? Current evidence does not define an optimal treatment duration in this setting. Importantly, the duration used in clinical practice largely reflects the design of pivotal trials rather than prospective comparisons of fixed-duration versus indefinite treatment. Our two patients have received continuous ICI therapy for more than five years, substantially exceeding the exposure typically reported in pivotal trials.

Treatment-duration paradigms differ between ICIs, largely reflecting the design of pivotal trials. In JAVELIN Bladder 100, avelumab maintenance was continued until progression or unacceptable toxicity, without a predefined maximum duration [3]. Nevertheless, after over two years of follow-up, median treatment duration was 5.8 months and only 19.5% of patients received avelumab for over two years[4]. Late toxicity also remained possible, with immune-related adverse events occurring after 12 months in 22.9% of patients treated for at least one year[4]. Pembrolizumab trials, in contrast, generally limited treatment to approximately two years[2].

Evidence regarding elective discontinuation of avelumab maintenance remains particularly limited. In the JAVEMACS study, only two patients who had achieved complete response to first-line platinum-based chemotherapy discontinued avelumab without receiving subsequent systemic therapy. However, reasons for discontinuation and standardized post-discontinuation disease assessments were not systematically collected[5]. Fujinami et al. reported a patient with metastatic upper tract UC who elected to discontinue avelumab maintenance after 40 administrations while maintaining a partial response and subsequently remained treatment-free without disease progression for more than two years[6]. These limited data suggest that durable disease control after discontinuation may be possible in selected patients but are insufficient to define its safety or optimal timing.

Retrospective data on pembrolizumab provide somewhat more evidence regarding elective discontinuation. In a Japanese nationwide cohort of patients with platinum-refractory metastatic UC who had achieved a complete

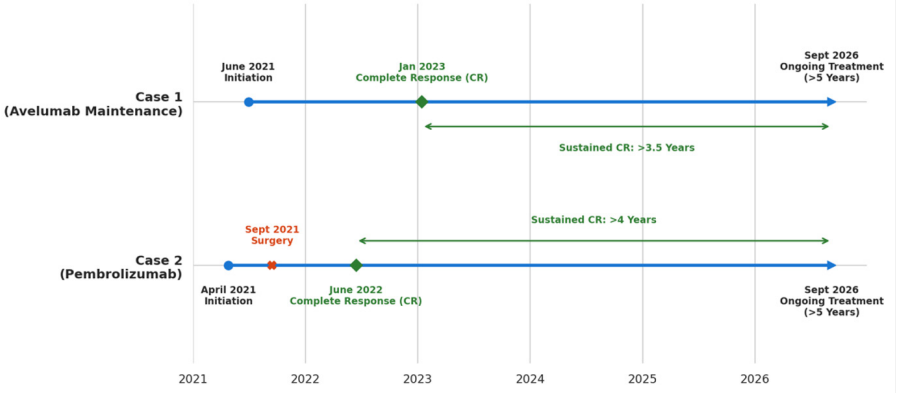

Figure 3. *Clinical course and treatment timeline of Cases 1 and 2. Timeline illustrating treatment initiation, relevant clinical events, achievement of complete response (CR), and duration of sustained response in both patients.*

or partial response to pembrolizumab, 83 patients discontinued treatment before disease progression. Among these patients, the two-year relapse-free, treatment-free, and overall survival rates after discontinuation were 49.0%, 57.4%, and 74.5%, respectively, with complete response associated with more favorable outcomes[7]. These findings suggest that prolonged treatment-free disease control can occur after pembrolizumab discontinuation, particularly among complete responders. For patients who subsequently relapse, the feasibility of ICI retreatment is an important consideration. A pooled analysis of KEYNOTE-045, KEYNOTE-052, and KEYNOTE-361 showed an objective response rate of 41% among 49 patients who were retreated with pembrolizumab after previously achieving complete response or completing approximately two years of therapy[8]. Although these data demonstrate that responses can be recaptured in some patients, retreatment does not guarantee renewed response, and whether the same degree or duration of disease control can be restored remains uncertain. Together, these data suggest that treatment discontinuation and subsequent retreatment may be feasible in selected responders, although neither sustained disease control nor response to retreatment can be guaranteed.

Our cases illustrate the clinical uncertainty surrounding treatment continuation in patients with sustained complete response. In both patients, treatment continuation was chosen after shared decision-making, reflecting minimal ongoing toxicity, patient preference, and uncertainty regarding elective discontinuation. However, sustained complete responses during continued therapy cannot establish that prolonged ICI exposure was necessary to maintain disease control. Based on the available evidence, no specific treatment duration can currently be recommended for patients with advanced UC who achieve a sustained complete response. Decisions, therefore, remain individualized, balancing uncertain relapse risk against treatment burden, potential late toxicity, and healthcare resource utilization.

This question is likely to become increasingly relevant as outcomes improve. Enfortumab vedotin plus pembrolizumab has become the preferred first-line treatment for most eligible patients with advanced UC. Notably, in EV-302, pembrolizumab was administered for a maximum of 35 cycles, whereas enfortumab vedotin could be continued until disease progression or unacceptable toxicity[1]. Identifying patients in whom treatment can be safely discontinued, therefore, remains a key unmet need. Biomarkers may help individualize treatment duration. In the phase III IMvigor011 trial, patients with muscle-invasive UC who had persistently undetectable circulating tumor DNA (ctDNA) after cystectomy and were managed with observation alone had a two-year disease-free survival of 88%[9], suggesting that dynamic ctDNA assessment can identify a population with a low risk of recurrence in the absence of adjuvant systemic therapy. This setting differs from ours in several respects—it is an adjuvant, post-surgical context involving treatment withholding rather than discontinuation after prolonged therapy. Nonetheless, it provides proof of concept for using dynamic biomarkers to guide systemic treatment decisions. Emerging data from advanced melanoma further suggest that sustained ctDNA negativity or clearance during anti-programmed cell death protein 1 therapy may identify patients with durable benefit and could potentially inform individualized treatment discontinuation strategies[10]. Whether ctDNA can similarly guide elective ICI discontinuation in long-term responders with advanced UC warrants prospective investigation.

CONCLUSION

Durable complete responses to ICIs in advanced UC create a therapeutic dilemma for which current evidence provides limited guidance. There is currently no evidence-based treatment duration that can be universally recommended after complete response. Although our cases demonstrate that sustained disease control can coexist with ICI exposure beyond five years, they do not establish whether such prolonged treatment is necessary. Elective discontinuation with subsequent retreatment may be feasible in selected responders, but the optimal timing and criteria remain undefined. Prospective studies incorporating clinical factors and dynamic biomarkers are needed to identify patients in whom ICIs can be safely discontinued.

REFERENCES

1. Powles T, Valderrama BP, Gupta S, Bedke J, Kikuchi E, Hoffman-Censits J, et al. Enfortumab vedotin and pembrolizumab in untreated advanced urothelial cancer. N Engl J Med. 2024;390:875–888. doi: 10.1056/NEJMoa2312117.
2. Vuky J, Balar AV, Castellano D, O'Donnell PH, Grivas P, Bellmunt J, et al. Long-Term Outcomes in KEYNOTE-052: Phase II Study Investigating First-Line Pembrolizumab in Cisplatin-Ineligible Patients With Locally Advanced or Metastatic Urothelial Cancer. J Clin Oncol. 2020;38(23):2658-2666. doi: 10.1200/JCO.19.01213.
3. Powles T, Park SH, Voog E, Caserta C, Valderrama BP, Gurney H, et al. Avelumab Maintenance Therapy for Advanced or Metastatic Urothelial Carcinoma. N Engl J Med. 2020;383(13):1218-1230. doi: 10.1056/NEJMoa2002788.
4. Powles T, Park SH, Caserta C, Valderrama BP, Gurney H, Ullén A, et al. Avelumab First-Line Maintenance for Advanced Urothelial Carcinoma: Results From the JAVELIN Bladder 100 Trial After ≥2 Years of Follow-Up. J Clin Oncol. 2023;41(19):3486-3492. doi: 10.1200/JCO.22.01792.
5. Endo Y, Kitamura H, Shirotake S, Ikeda M, Yonemori K, Kawamura N, et al. Avelumab maintenance therapy for advanced urothelial carcinoma: subgroup analyses by characteristics of first-line platinum-based chemotherapy from a real-world chart review study in Japan (JAVEMACS). BMC Cancer. 2026;26:575. doi: 10.1186/s12885-026-15781-1.
6. Fujinami H, Hata S, Inoue T, Ando T, Shin T. Long-term response to avelumab maintenance therapy and durable remission after cessation in a patient with metastatic urothelial carcinoma of the renal pelvis: a case report. IJU Case Rep. 2026;9(1):e70117. doi: 10.1002/iju5.70117.
7. Ito K, Kita Y, Yokomizo A, Miki J, Yoshio Y, Matsumoto H, et al. Discontinuation of pembrolizumab for advanced urothelial carcinoma without disease progression: nationwide cohort study. Cancer Med. 2023;12:2325–2332. doi: 10.1002/cam4.5057.
8. Koshkin VS, Danchaivijitr P, Bae WK, Semenov A, Ozyilkan O, Su YL, et al. Pembrolizumab retreatment in patients with advanced or metastatic urothelial carcinoma who responded to first-course pembrolizumab-based therapy. Eur Urol. 2025;87:390–395. doi: 10.1016/j.eururo.2024.11.012.
9. Powles T, Kann AG, Castellano D, Gross-Goupil M, Nishiyama H, Bracarda S, et al. ctDNA-guided adjuvant atezolizumab in muscle-invasive bladder cancer. N Engl J Med. 2025;393:2395–2408. doi: 10.1056/NEJMoa2511885.
10. Martínez-Vila C, Teixido C, Martín R, Aya F, Sudhaman S, Budde GL, et al. Personalized circulating tumor DNA assay to assess long-term clinical benefit in patients with advanced melanoma. Cancers (Basel) 2025;17(23):3804. doi: 10.3390/cancers17233804.