EJCRIM
European Journal
of Case Reports
in Internal Medicine

ACUTE HEMOLYSIS AND METHEMOGLOBINEMIA: A G6PD CRISIS PROBABLY TRIGGERED BY PRESERVATIVES IN FROZEN SPINACH

Nabil Belfeki[1], Jean Kaboré[1,2], Abdellah Seghiri[1,3], Khalid Serraj[3], Nouha Ghriss[1], Sonia Kammoun[1]

[1] Department of Internal Medicine and Clinical Immunology, Groupe Hospitalier Sud Île-de-France, Melun, France
[2] Department of Internal Medicine, Ibn Rochd University Hospital, Casablanca, Morocco
[3] Faculty of Medicine and Pharmacy, Oujda, Morocco

Corresponding author's e-mail: jkabore68@yahoo.fr

Received: 31/08/2026
Accepted: 21/09/2026
Published: 23/11/2026

Conflicts of Interests: The Authors declare no conflict of interest.
Patient Consent: Written informed consent for publication of this case report was obtained from the patient.
This article is licensed under a CC Attribution-NonCommercial-NoDerivatives 4.0 License

How to cite this article: Belfeki N, Kaboré J, Seghiri A, Serraj K, Ghriss N, Kammoun S. Acute hemolysis and methemoglobinemia: a G6PD crisis probably triggered by preservatives in frozen spinach. EJCRIM 2026;13:doi:10.12890/2026_007488

ABSTRACT

Introduction: Glucose-6-phosphate dehydrogenase (G6PD) deficiency is a common X-linked enzymopathy that is usually asymptomatic but may cause acute hemolysis following exposure to oxidative stress. The concomitant occurrence of acute hemolysis and methemoglobinemia is uncommonly described.

Case description: A 56-year-old man of central African origin, with no medical history other than arterial hypertension, presented with acute left flank pain and dark urine. Laboratory investigations revealed hemolytic anemia, with a negative direct antiglobulin test and no schistocytes. Numerous hemighost erythrocytes on the peripheral blood smear suggested oxidative hemolysis. G6PD activity was reduced. Methemoglobinemia (8.6%) was also detected in the context of a discrepancy between low pulse oxygen saturation 92% and relatively preserved arterial oxygenation (partial pressure of arterial oxygen 80 mmHg; arterial oxygen saturation 100%). No conventional hemolytic triggers were identified. The patient reported consuming a large quantity of frozen spinach that had been left at room temperature for an extended period during thawing before cooking, subsequently consumed over a 2-day period.

Conclusion: The coexistence of acute hemolysis and methemoglobinemia may indicate a common oxidative exposure in patients with G6PD deficiency. Dietary history should, therefore, include food-storage practices when no conventional precipitating factor is identified. Improperly stored nitrate-rich vegetables like spinach may represent a potential source of nitrite exposure and, consequently, oxidative stress.

KEYWORDS

Glucose-6-phosphate dehydrogenase deficiency, methemoglobinemia, acute hemolysis, oxidative stress, nitrites

LEARNING POINTS

- The coexistence of hemolysis and methemoglobinemia suggests a common oxidative insult.
- A discrepancy between pulse oximetry and arterial oxygenation should raise suspicion for methemoglobinemia.
- Improperly stored nitrate-rich vegetables may be a potential source of nitrite exposure, which oxidizes hemoglobin to methemoglobin and may contribute to oxidative hemolysis in a patient with glucose-6-phosphate dehydrogenase deficiency.

EFIM
European Federation of Internal Medicine

Publisher
smc media srl

INTRODUCTION

Glucose-6-phosphate dehydrogenase (G6PD) deficiency is the most common enzymopathy worldwide, affecting approximately 400 million people[1]. Most affected individuals remain asymptomatic, but acute hemolysis episodes may occur following exposure to oxidative stress, including infections, drugs and food, such as fava beans. Oxidative stress damages intracellular erythrocyte components, including hemoglobin, as well as membrane components. Adequate G6PD activity sustains nicotinamide adenine dinucleotide phosphate (NADPH)-dependent antioxidant defenses and preserves erythrocyte integrity[2]. Herein, we report the case of a 56-year-old patient who developed acute hemolytic anemia associated with methemoglobinemia, leading to the diagnosis of G6PD deficiency.

CASE DESCRIPTION

A 56-year-old man of central African origin, with a history of arterial hypertension treated with nicardipine, presented to the emergency department with sudden-onset left flank pain and dark urine. On physical examination, he was mildly jaundiced, body temperature of 37.0°C, oxygen saturation (SpO_2) of 92% on room air, respiratory rate of 20 breaths per minute, blood pressure of 140/66 mmHg, and a heart rate of 81 beats per minute. Cardiopulmonary auscultation and neurological examination were normal. Abdominal examination revealed tenderness in the left flank, without splenomegaly or hepatomegaly. Urine dipstick testing was positive for blood in the absence of red blood cells on urine microscopy, consistent with hemoglobinuria. Complete blood count showed a hemoglobin level of 9.3 g/dl (normal range 12-14 g/dl) and a reticulocyte count of 158 × 10^9/l (normal range 20-120 × 10^9/l). White blood cell and platelet counts were normal. Lactate dehydrogenase was 2781 IU/l (normal range 135–225 IU/l), and haptoglobin was undetectable at <0.1 g/l (normal range 0.3-2 g/l). Liver tests showed an alanine aminotransferase level at 41 IU/l (normal range 10-50 IU/l), aspartate aminotransferase level 267 IU/l (normal range 10-50 IU/l), total bilirubin level 48 µmol/l (normal range <21 µmol/l), and unconjugated bilirubin level 42 µmol/l (normal range <16 µmol/l). Alkaline phosphatase and gamma-glutamyl transferase levels were normal. Renal function tests, serum electrolytes, and C-reactive protein were normal. The direct antiglobulin test was negative. Peripheral blood smear examination showed anisocytosis and polychromatophilia, along with numerous hemighost erythrocytes. No schistocytes were observed *(Fig. 1)*. A computed tomography scan of the chest, abdomen, and pelvis was normal. Further investigations, including antinuclear antibody testing, blood cultures, peripheral blood flow cytometry, and hemoglobin electrophoresis, were unrevealing. Besides, thick and thin Giemsa-stain smear test was negative for *Plasmodium*. The patient denied any recent drug intake or blood support. He had not consumed fava beans but had eaten frozen spinach that had been left at room temperature for two days, with repeated cycles of refrigeration and reheating. G6PD activity was 5.4 IU/g hemoglobin (normal range 6.6-17.2 IU/g hemoglobin), and the G6PD/pyruvate kinase ratio was 0.1 (normal range 0.49-1.3). The measure of erythrocyte pyruvate kinase activity was normal. The eosin-5′-maleimide-binding test by flow cytometry was normal and ruled out inherited membrane red cell disorder. Arterial blood gas analysis with co-oximetry revealed a methemoglobin level of 8.6%, a partial pressure of arterial oxygen (PaO_2) of 80 mmHg, an arterial oxygen saturation (SaO_2) of 100%, and an oxyhemoglobin fraction of 86%. The final diagnosis of acute hemolysis and methemoglobinemia related to a spinach-trigged G6PD crisis is retained. The patient received oxygen therapy, three units of packed red blood cells transfusion support, folic acid supplementation, and erythropoietin. He was educated about his G6PD deficiency and advised to avoid oxidative triggers. At one-month follow-up, his hemoglobin had recovered to 13.5 g/dl and remains under regular surveillance with no further hemolytic episodes to date.

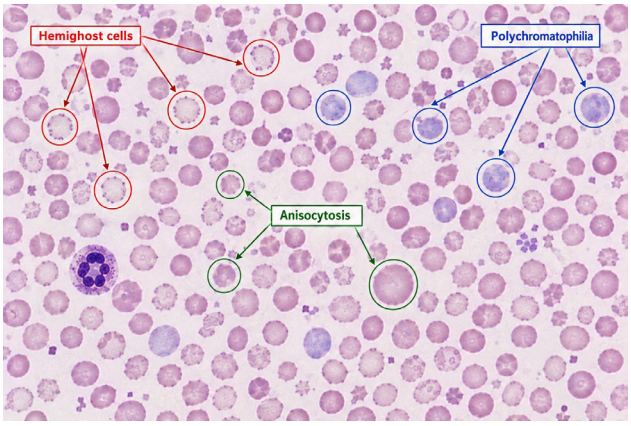

Figure 1. *Illustration of peripheral blood smear examination. AI-generated using GPT-5.6 Luna.*

DISCUSSION

The diagnosis of G6PD deficiency was supported by the combination of acute non-auto-immune haemolysis, hemighost erythrocytes and reduced G6PD activity. Hemighost erythrocytes are a recognized morphological feature of oxidant-induced haemolysis and may be particularly suggestive of G6PD deficiency during an acute hemolytic episode[3]. The association with methemoglobinemia is an unusual feature. Methemoglobin results from oxidation of heme iron from the ferrous (Fe^{2+}) to the ferric (Fe^{3+}) state, impairing normal oxygen transport. In our case, the methemoglobin level was moderate (8.6%) but was accompanied by a characteristic discrepancy between the SpO_2 (92%) and the arterial oxygen measurements (PaO_2 80 mmHg and SaO_2 100%). This “saturation gap” can suggest methemoglobinemia because conventional pulse oximetry is affected by the absorption characteristics of methemoglobin[4]. The simultaneous

occurrence of methemoglobinemia and acute haemolysis suggests exposure to a common oxidant. Although the main intracellular pathway protecting hemoglobin against oxidation relies on reduced nicotinamide adenine dinucleotide (NADH)-dependent mechanisms, NADPH also contributes to the reduction of oxidized hemoglobin[4]. In a patient with G6PD deficiency, an additional oxidative burden may, therefore, facilitate erythrocyte injury. In this case, there was no evidence of infection, oxidant drug intake, or fava beans consumption leading to G6PD-related hemolysis. The patient reported substantial consumption of frozen spinach, which had been left at room temperature for an extended period prior to cooking and subsequently stored for several days. Spinach and other leafy vegetables naturally contain high concentrations of nitrate[5]. Under appropriate storage conditions, nitrite concentrations remain relatively low. However, inadequate storage of nitrate-rich vegetables may favor nitrate-to-nitrite conversion through bacterial contamination and endogenous enzymatic processes[5-7]. Nitrites can oxidize hemoglobin and induce methemoglobinemia. Cases of methemoglobinemia following ingestion of improperly stored nitrate-rich vegetables, including spinach, have been reported[7-9]. The methemoglobinemia observed in our patient provides indirect evidence of exposure to an oxidizing, nitrite-containing substance; however, a causal relationship cannot be definitively established. We hypothesize that prolonged storage and repeated temperature fluctuations may have promoted nitrite accumulation, generating sufficient oxidative stress to induce methemoglobinemia and precipitate hemolysis in the setting of an underlying G6PD deficiency.

CONCLUSION

This case highlights the importance of considering dietary and food-storage exposures in patients with otherwise unexplained oxidative hemolysis. Adult-onset G6PD deficiency was revealed by the concomitant occurrence of acute hemolysis and methemoglobinemia, suggesting a common oxidant trigger. Improperly stored nitrate-rich spinach may have been a source of nitrite exposure and oxidative stress, although a causal relationship could not be established. The combined findings of hemolysis and a saturation gap may provide complementary diagnostic clues to an underlying oxidant exposure. Clinicians should, therefore, enquire about dietary habits and food-storage practices when evaluating unexplained hemolysis in patients with G6PD deficiency.

REFERENCES

1. Yu Z, Xiong Q, Wang Z, Li L, Niu T. Global, regional, and national burden of glucose-6-phosphate dehydrogenase (G6PD) deficiency from 1990 to 2021: a systematic analysis of the global burden of disease study 2021. Front Genet. 2025;16:1593728. doi: 10.3389/fgene.2025.1593728.
2. TeSlaa T, Ralser M, Fan J, Rabinowitz JD. The pentose phosphate pathway in health and disease. Nat Metab. 2023;5(8):1275-1289. doi: 10.1038/s42255-023-00863-2.
3. Chan TK, Chan WC, Weed RI. Erythrocyte hemighosts: a hallmark of severe oxidative injury in vivo. Br J Haematol. 1982;50(4):575-82. doi: 10.1111/j.1365-2141.1982.tb01957.x.
4. Batton R, Villard S, Popoff B. Méthémoglobinémie [Methemoglobinemia]. Rev Med Interne. 2024;45(8):479-487. doi: 10.1016/j.revmed.2024.05.001.
5. Clayton-Cuch D, Niklas AA, Duedahl-Olesen L, Amlund H, Sloth JJ. Nitrite, nitrate and N-nitrosamine occurrence in processed nitrate accumulating vegetables stored under different conditions. Food Chem. 2025;493(Pt 1):145631. doi: 10.1016/j.foodchem.2025.145631.
6. European Food Safety Authority (EFSA). Nitrate in vegetables. Scientific Opinion of the Panel on Contaminants in the Food Chain. EFSA J. 2008;6(6):689. doi:10.2903/j.efsa.2008.689.
7. Chan TY. Vegetable-borne nitrate and nitrite and the risk of methaemoglobinaemia. Toxicol Lett. 2011;200(1-2):107-8. doi: 10.1016/j.toxlet.2010.11.002.
8. EFSA Panel on Contaminants in the Food Chain (CONTAM). Statement on possible public health risks for infants and young children from the presence of nitrates in leafy vegetables. EFSA J. 2010;8(12):1935. doi:10.2903/j.efsa.2010.1935.
9. Sinios A, Wodsak W. Die Spinatvergiftung des Säuglings [Spinach poisoning in infants]. Dtsch Med Wochenschr. 1965;90(42):1856-63. doi: 10.1055/s-0028-1113435.