

A Case of Brucellosis with a Rare Complication: Pericarditis

Gizem Zorlu¹, Seyit Uyar¹, Hakan Ozer¹, Murat Esin², Selin Kir¹, Abdullah Tokuc¹,
Süleyman Dolu¹, Feyzi Bostan¹, Ayhan Hilmi Cekin³

¹Department of Internal Medicine, Antalya Training and Research Hospital, Antalya, Turkey

²Department of Cardiology, Antalya Training and Research Hospital, Antalya, Turkey

³Department of Gastroenterology, Antalya Training and Research Hospital, Antalya, Turkey

Doi: 10.12890/2016_000471- European Journal of Case Reports in Internal Medicine - © EFIM 2016

Received: 25/07/2016

Accepted: 15/10/2016

Published: 28/09/2016

How to cite this article: Zorlu G, Uyar S, Ozer H, Esin M, Kir S, Tokuc A, Dolu S, Bostan F, Cekin AH. A case of brucellosis with a rare complication: pericarditis. *EJCRIM* 2016;3: doi:10.12890/2016_000471.

Conflicts of Interests: The Authors declare that there are no competing interests.

This article is licensed under a [Commons Attribution Non-Commercial 4.0 License](#)

ABSTRACT

Objectives: To describe brucellosis and its possible complications according to clinical, laboratory and radiological findings.

Methods: We describe a case of *Brucella* pericarditis visualized at transthoracic echocardiography with clinical manifestations.

Results: Clinical manifestations, imaging and laboratory findings provided the correct diagnosis of *Brucella* pericarditis. The patient recovered fully following doxycycline and rifampin therapy.

Conclusion: Brucellosis should be considered in the differential diagnosis of disorders that affect the pericardium in endemic areas.

LEARNING POINTS

- *Brucella* pericarditis should be considered in case of disorders that affect the pericardium in endemic areas such as the Mediterranean region.
- When a patient has been diagnosed with brucellosis, oral doxycycline 100 mg twice daily plus oral rifampin 600 mg once daily must be given immediately.

KEYWORDS

Brucellosis, pericarditis; infectious disease.

INTRODUCTION

Brucellosis is a zoonotic disease which is a systemic infection with a broad clinical presentation ranging from asymptomatic to severe disease. *Brucella* infection can affect any organ and system in the human body. The spleen, liver, bone marrow and reticuloendothelial cells are the most frequently affected, with cardiovascular involvement, such as endocarditis, pericarditis and myocarditis, being extremely rare. Here we describe a patient with *Brucella* infection complicated with *Brucella* pericarditis in the absence of concomitant endocarditis, diagnosed as a result of clinical manifestations, imaging, laboratory findings including culture and serology, and the patient's occupation.

CASE REPORT

A 50-year-old man was admitted our hospital with fever, malaise, night sweats and chest pain. He had no medical history and lives in Turkey's Mediterranean region. He works on a farm and consumes his own milk, cheese and yogurt. Physical examination revealed a temperature of 38.7°C, a cardiac murmur and tachypnoea. Laboratory investigations showed a normal complete blood count, high levels of C-reactive protein (40 mg/l) and an erythrocyte sedimentation rate of 57. Electrocardiography was normal, while transthoracic echocardiography showed pericardial effusion (pericardial thickness of 2.3 cm) without cardiac tamponade, normal valves and no signs of endocarditis (Fig. 1). Computed tomography of the thorax also showed pericardial effusion (Fig. 2). Tests for anti-*Brucella* IgG and IgM were strongly positive, as was a standard tube Rose Bengal agglutination test specific for brucellosis (titre >1/640). Also *Brucella* spp. were isolated from blood cultures. Additional laboratory tests were performed to rule out other differential diagnoses such as cardiological or rheumatological disease. Any disease that can cause pericarditis was ruled out. In accordance with these finding, a diagnosis of *Brucella*-related pericarditis in the absence of concomitant endocarditis was made. Oral doxycycline 100 mg twice daily plus oral rifampin 600 mg once daily was started. By 1 month after treatment initiation, the pericardial effusion had regressed to 0.4 cm thickness. The patient's symptoms resolved and transthoracic echocardiography was normal 3 months after treatment.

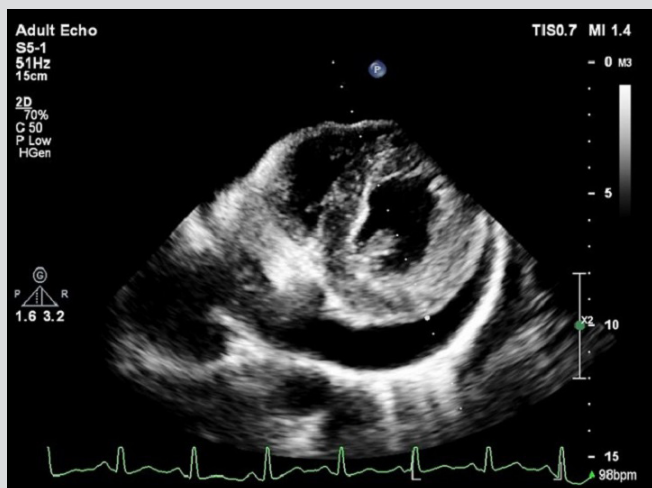


Figure 1. Transthoracic echocardiography image of pericardial effusion

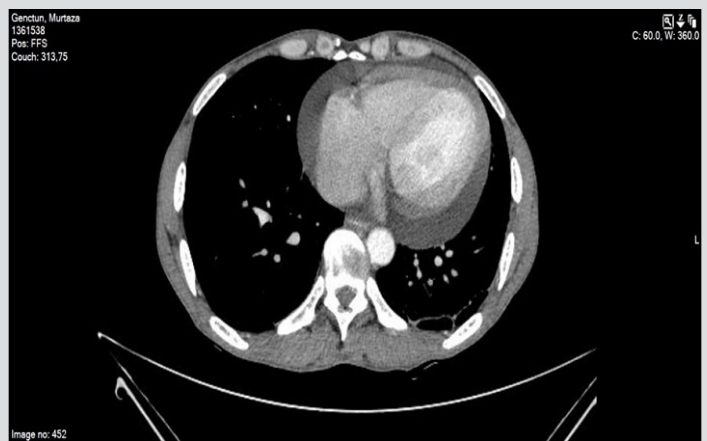

Figure 2. Thoracic computed tomography image of pericardial effusion

DISCUSSION

Brucellosis is zoonotic infection with a high prevalence in the Mediterranean region. *Brucella* spp. can be transmitted to humans from infectious animals and cause disease in humans^[1]. The clinical presentation of brucellosis ranges from asymptomatic to severe disease and includes haematological, gastrointestinal, osteoarticular, neurological and cardiovascular complications^[2]. Cardiovascular problems such as myocarditis, endocarditis and pericarditis are rarely seen. Myocarditis is the most common cardiac complication of brucellosis^[3]. Gür et al. found endocarditis, with concomitant myocarditis and pericarditis, in only two of 283 cases^[4]. In another study from Spain, isolated *Brucella* pericarditis was detected in only one patient out of 530 cases^[5]. This patient worked as a farmer and had a history of fever, night sweats, malaise and chest pain. Transthoracic echocardiography showed pericardial effusion (2.3 cm thickness) without cardiac tamponade. A report by Gatselis et al. described two cases of *Brucella* pericarditis identified by blood culture^[6]. In our case, *Brucella* spp. were isolated from blood cultures and tests for anti-*Brucella* IgG and IgM were strongly positive, as was a standard tube Rose Bengal agglutination test specific for brucellosis (titre >1/640). We conducted additional tests which ruled out other causes of pericardial effusion.

Consequently, a diagnosis of *Brucella* pericarditis was made. We did not perform pericardiocentesis, because in the absence of cardiac tamponade, this procedure is not essential in cases of *Brucella* pericarditis^[2]. In the absence of heart failure or valvular destruction, some

cases have been treated with only antibiotic combinations^[7]. Our patient was put on combined antibiotic therapy (doxycycline and rifampin), his signs and symptoms regressed and regular follow-up was conducted.

CONCLUSION

Brucellosis is highly prevalent in the Mediterranean region. This patient's history of exposure and clinical manifestations suggested *Brucella* infection. Brucellosis should be considered in the differential diagnosis of disorders that affect the pericardium in endemic areas. Clinical suspicion, adequate antibiotic treatment and a multidisciplinary approach result in complete cure in brucellosis where the main cause of death is heart disease.

REFERENCES

1. Marmelo B, Pereiro T, Sousa P, Capelo J, Carragoso A. Brucella non-neutrocytic bacterascites in a patient with chronic liver disease. *EJCRIM* 2015;**2**:doi: 10.12890/2015_000252.
2. Kaya S, Eskazan AE, Elaldi N. Brucellar pericarditis: a report of four cases and review of the literature. *Int J Infect Dis* 2013;**17**:e428–432.
3. Shetty RK, Madken M, Naha K, Vivek G. Successful management of native-valve Brucella endocarditis with medical therapy alone. *BMJ Case Rep* 2013;**2013**. pii: bcr2013200086. doi: 10.1136/bcr-2013-200086.
4. Gür A, Geyik MF, Dikici B, Nas K, Cevik R, Sarac J, et al. Complications of brucellosis in different age groups: a study of 283 cases in southeastern Anatolia of Turkey. *Yonsei Med J* 2003;**44**:33–44.
5. Colmenero JD, Reguera JM, Martos F, Sánchez-De-Mora D, Delgado M, Causse M, et al. Complications associated with Brucella melitensis infection: a study of 530 cases. *Medicine (Baltimore)* 1996;**75**:195–211.
6. Gatselis NK, Makaritsis KP, Gabranis I, Stefos A, Karanikas K, Dalekos GN. Unusual cardiovascular complications of brucellosis presenting in two men: two case reports and a review of the literature. *J Med Case Rep* 2011;**5**:22.
7. Mert A, Kocak F, Ozaras R, et al. The role of antibiotic treatment alone for the management of Brucella endocarditis in adults: a case report and literature review. *Ann Thorac Cardiovasc Surg* 2002;**2013**:381–385.