

# PROLONGED DISEASE CONTROL DESPITE ALK INHIBITOR DISCONTINUATION IN ADVANCED ALK-POSITIVE NSCLC

Syed Ather Hussain<sup>1</sup>, Hafsa Faisal<sup>2</sup>, Grace K. Dy<sup>1</sup>

<sup>1</sup> Department of Thoracic Medicine, Roswell Park Comprehensive Cancer Center, Buffalo, USA

<sup>2</sup> Department of Pulmonary Critical Care Medicine, University at Buffalo, Buffalo, USA

**Corresponding author:** Syed Ather Hussain **e-mail:** drsahussain121@gmail.com

Received: 01/04/2024 Accepted: 02/04/2024 Published: 24/04/2024

**Conflicts of Interests:** SAH and HF have no conflicts of interest to declare. GKD received consulting fees/honoraria from the following within the past three years: Amgen, Astra Zeneca, Bayer, Eli Lilly, Janssen, Mirati, Novartis, Regeneron.

**Patient Consent:** We obtained informed consent from all patients for publishing their clinical history.

**This article is licensed under a Commons Attribution Non-Commercial 4.0 License**

**How to cite this article:** Hussain SA, Faisal H, Dy GK. Prolonged disease control despite ALK inhibitor discontinuation in advanced ALK-positive NSCLC. *EJCRIM* 2024;11:doi:10.12890/2024\_004527

## ABSTRACT

**Introduction:** *EML4-ALK* is an oncogenic driver, seen in around five per cent of advanced non-small-cell lung cancer (NSCLC) patients, which can be targeted with anaplastic lymphoma kinase tyrosine kinase inhibitors with great response rates. Disease flare refers to sudden rapid disease worsening on tyrosine kinase inhibitors (TKI) discontinuation, which is associated with shorter survival and worse outcomes. Here, we review cases previously published in the literature where patients developed disease flares, and contrast this with our patients who had prolonged survival despite TKI discontinuation.

**Case description:** We report three different patients with advanced ALK-positive NSCLC seen at our institute, who had *EML4-ALK* translocation variant 1 oncogenic driver on next-generation sequencing. They received treatment with several different ALK inhibitors before opting to discontinue TKI. They were able to come off TKI safely without developing disease flare and had prolonged survival.

**Discussion:** Shorter time to progression on TKI, presence of symptoms with disease progression or central nervous system/pleural metastasis have been previously linked with development of flare, although this was not seen in our case series. Tumour response at the time of treatment discontinuation, line of therapy, overall disease burden, fusion variant and co-alteration status can affect the prognosis of these patients after ALK TKI cessation. In particular, variant 1 and wild-type TP53 status may be a suitable patient population for dose optimisation strategies. Intermittent TKI dosing strategies may help to avoid acquiring resistance mutations and prevent long-term treatment toxicities.

**Conclusion:** It is important for clinicians to identify patients at risk for developing disease flare on TKI discontinuation to improve outcomes. Intermittent TKI dosing strategies require further investigation.

## KEYWORDS

Advanced non-small cell lung carcinoma; ALK inhibitor; disease flare; targeted therapy

## LEARNING POINTS

- Patients who develop disease flare after cessation have poor survival and worse outcomes.
- Certain phenotypic and molecular characteristics of the tumour may help clinicians identify which patients are likely and which are unlikely to develop disease flare on TKI discontinuation.
- Advanced ALK-positive NSCLC with variant 1 and wild-type TP53 may be a suitable patient population for intermittent TKI dosing investigations.

## INTRODUCTION

Echinoderm microtubule-associated protein-like 4-anaplastic lymphoma kinase (EML4-ALK) gene rearrangement is an oncogenic driver, seen in about five per cent of non-small-cell lung cancer (NSCLC) patients<sup>[1]</sup>. Multiple ALK tyrosine kinase inhibitors (TKIs) are currently the preferred therapy for patients with advanced ALK-positive NSCLC.

While TKIs can induce response rapidly, there have been instances of sudden rapid disease worsening on TKI discontinuation, a phenomenon termed as ‘disease flare’<sup>[1]</sup>. This phenomenon has widely been documented in

association with both epidermal growth factor receptor and ALK TKI cessation<sup>[2]</sup>. Patients with disease flare have shorter post-TKI survival and worse outcomes<sup>[3]</sup>. However, clinical features associated with flare or lack of flare response are not well defined.

Here, we describe three cases of ALK-positive NSCLC in non-smokers at our institute, who did not develop disease flare despite prolonged TKI cessation and had sustained response with prolonged survival. We also review the characteristics of cases previously published in the literature, who had advanced ALK-positive NSCLC and developed disease flares, and contrast these with our case series (*Table 1*).

Study	Age (yrs)/gender	Disease sites before TKI initiation	Prior treatment	ALK testing	ALK TKIs	Disease status before TKI cessation	PFS on ALK TKIs (months)	Sites of disease recurrence	Post-ALK TKI cessation outcome
<b>DISEASE FLARE CASES</b>									
Pop et al., 2012 <sup>[2]</sup>	50/F	Left upper lung mass, left cervical, supraclavicular and mediastinal LAD	Cisplatin-pemetrexed & bevacizumab × 6 cycles » bevacizumab maintenance Docetaxel	FISH	Crizotinib	PD	5.5	Left supraclavicular, mediastinal LAD and brain metastasis	Died 2 weeks after TKI cessation from flare
Kuriyama et al., 2013 <sup>[1]</sup>	50/M	Left lung nodule and mediastinal LAD	Neoadjuvant cCRT with cisplatin & vinorelbine Adjuvant carboplatin & paclitaxel × 4 cycles	FISH	Crizotinib	PR	10	Mediastinal LAD	Died 5 weeks after TKI cessation from disease flare
Spake et al., 2019 <sup>[10]</sup>	68/F	Bone metastasis of the femur & spine	-	-	Alectinib	PD	-	Bone metastasis	Died 4 weeks after TKI cessation from disease flare
<b>PROLONGED DISEASE CONTROL CASES IN THIS SERIES</b>									
Current study	65/M	Brain, lymph nodes, liver and left femur	-	NGS v1	Crizotinib Alectinib Brigatinib Lorlatinib	PR	8 12 30 -	Leptomeningeal disease	Died 11 months after TKI cessation.
	84/M	RML lung mass and brain metastasis	-	NGS v1	Brigatinib	PR	Ongoing PR (most recent follow-up progression free at 20 months)	-	Off TKI for 8 months before reintroducing at lower dose which patient took for 2 months then stopped again.
	88/F	Left pleural nodule and hilar mass	Adjuvant cisplatin & vinorelbine	NGS v1	Alectinib	PR	47 months confirmed progression-free (died on 48th month post-TKI initiation)	-	Ongoing PR for initial 3 months of TKI cessation during the second year of treatment. Died 8 months after complete TKI cessation due to heart failure without evidence of disease progression.

Table 1. Published ALK-positive NSCLC cases with disease flare upon TKI discontinuation compared with cases at our institute.

Abbreviations: ALK, anaplastic lymphoma kinase; cCRT, concurrent chemoradiation; F, female; FISH, fluorescence in situ hybridisation; IHC, immunohistochemical staining; LAD, lymphadenopathy; M, male; NGS, next-generation sequencing; PD, progression of disease; PFS, progression-free survival; PR, partial response; TKI, tyrosine-kinase inhibitor; v1, variant 1.

## CASE DESCRIPTION

### Case 1

A 65-year-old male had lung adenocarcinoma with metastasis to the brain, liver, and bones. Next-generation sequencing (NGS) on a tumour specimen revealed *EML4-ALK* translocation variant 1 (v1). No other co-mutated pathogenic variants were seen. He started crizotinib 250 mg twice daily (the only ALK TKI at that time approved for use in the first-line setting) and remained on it for approximately 8 months until there was disease progression in the liver. He then started alectinib 600 mg twice daily. Twelve months later, a liver biopsy of a worsening lesion demonstrated preserved adenocarcinoma histology; NGS showed acquired *ALK I1171N* resistance mutation, *CDKN2A/B* loss and *ALK-ARHGAP10* rearrangement without detectable *EML4-ALK* translocation. Alectinib was discontinued and he started brigatinib 180 mg daily with partial response for two and half years, until he developed intracranial disease progression. He underwent whole brain radiation therapy and subsequently started lorlatinib. He was unable to tolerate lorlatinib due to extreme fatigue and personality changes, despite dose reduction to 50 mg daily; and after two months, he went back to brigatinib. After an additional nine months of brigatinib, the extracranial disease remained

under control but there was neuro-cognitive decline along with concerns of worsening leptomeningeal disease. The patient elected hospice care under which he remained off ALK TKI for eleven months before his death.

### Case 2

A 72-year-old male had a left lower lobectomy and mediastinal lymph node dissection for lung adenocarcinoma (pT2aN0M0). He declined adjuvant chemotherapy. Surveillance scans over twelve years eventually revealed a right middle lobe lung mass with a solitary metastatic deposit in the right frontal lobe surrounded by vasogenic oedema. He had Gamma Knife radiosurgery while awaiting diagnostic work-up. A right lung mass biopsy revealed moderately differentiated adenocarcinoma with NGS revealing *EML4-ALK* translocation v1 with co-mutated *CTNNB1 S37F* variant. He started brigatinib but after 5 months of treatment marked by dosing interruptions and reduction to 60 mg once daily, brigatinib was held due to continued poor tolerance. The patient declined radiation to the oligometastatic lung lesion. He remained off brigatinib for over 8 months with continued partial response in the lung mass (Fig. 1). Brain imaging showed no new metastases. The patient elected to restart treatment at 30 mg once daily as he was concerned

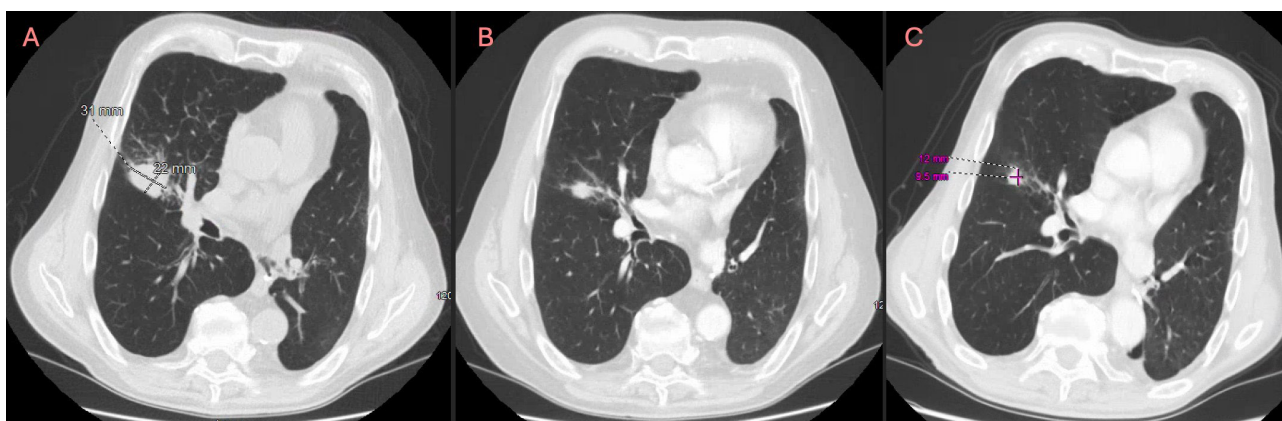


Figure 1. A) Computerized tomography (CT) scan of the chest showing a 3.1 x 2.2 cm mass in the right middle lobe suggestive of relapse of lung adenocarcinoma; B) Repeated CT scan after 5 months of brigatinib therapy showing decrease in size of lung mass; C) Latest CT scan after patient had been off brigatinib for 8 months showing continued partial response in lung mass.

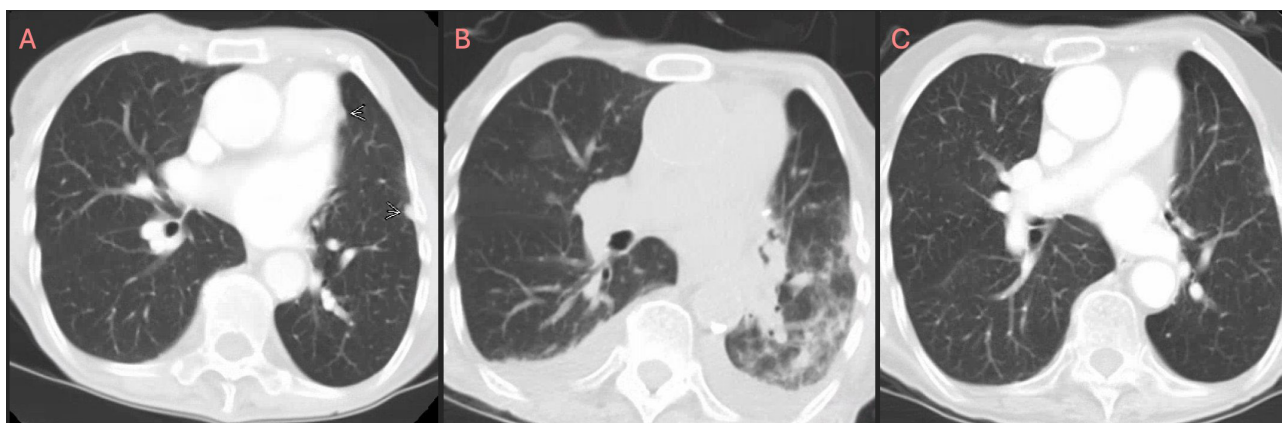


Figure 2. A) Initial CT chest showing left-sided peripheral pleural nodule indicative of a metastatic focus; B) CT chest showing left lower lobe consolidation consistent with pneumonia along with small bilateral pleural effusions due to alectinib; C) Follow-up imaging 7 months after stopping alectinib showing resolution of left lower lobe consolidation and bilateral pleural effusions.

about being off therapy for prolonged period. He took this for two months then held it again due to recurrent neuropathy. Follow-up imaging after two months showed stable findings. Repeat imaging 4 months subsequently off treatment again demonstrated stable findings of sustained partial response previously demonstrated. He continues to be under surveillance off brigatinib.

### Case 3

An 80-year-old female underwent left upper lobectomy and mediastinal lymph node sampling for lung adenocarcinoma (*T1N1M0*). She received four cycles of adjuvant chemotherapy and had no evidence of disease on surveillance imaging for eight years. Then, a positron emission tomography scan revealed a hypermetabolic left-sided pleural nodule and a left hilar mass. Bronchoscopy with biopsy revealed a recurrent lung adenocarcinoma. NGS positive for *EML4-ALK* translocation v1 and *SMAD4* copy number loss. She started alectinib 300 mg twice daily with almost complete response for nearly three and half years before stopping medication, due to prolonged recovery from pneumonia and heart failure exacerbation. Follow-up imaging after seven months off-therapy showed resolution of pleural effusion and other inflammatory infiltrates with stable cancer-related findings (Fig. 2). She enrolled in hospice care due to her physical decline and passed away a month later.

### DISCUSSION

Acquired resistance to TKI after an initial response to therapy occurs frequently in advanced ALK-positive NSCLC<sup>[2]</sup>. However, the kinetics of disease progression is heterogeneous, with accelerated disease progression seen attributed to the rapid growth of the drug-sensitive clone on TKI discontinuation<sup>[2]</sup>. As a result, several studies have recommended that instead of stopping the TKI and waiting for a prolonged 'washout' period before initiating subsequent therapy, a better strategy would be to immediately substitute the new therapeutic agent or add the new agent on top of the TKI to prevent a disease flare<sup>[4]</sup>.

It is difficult to predict which patients will develop a disease flare<sup>[3]</sup>. However, a shorter time to progression on TKI, the presence of symptoms on disease progression or CNS/pleural metastasis have been linked with development of flare<sup>[3]</sup>. However, these are not consistently observed, as illustrated in our case series as patients with brain and pleural metastasis did not develop flare despite prolonged TKI discontinuation. An important feature shared by all patients in this series relates to their tumour response status at the time of ALK TKI discontinuation. All patients had at least ongoing partial response. Moreover, they generally had low-volume disease and a low neutrophil-lymphocyte ratio, which are all prognostically favourable. We hypothesise that characterising the specific *EML4-ALK* variant and concurrent co-alterations may provide additional context on the heterogeneous treatment outcomes in ALK-positive NSCLC.

Both v3 and TP53 co-mutation status are independently associated with increased metastases at the time of diagnosis and shorter progression-free survival post-TKI therapy, with highest risk of mortality in ALK-positive NSCLC with v3 and TP53 mutations combined<sup>[5]</sup>. Of note, all our patients had v1 and wild-type TP53.

While responses to immune checkpoint inhibitors are well known to be potentially durable even without ongoing treatment, this is not well characterised with targeted therapy in solid tumour patients. Our case series serendipitously demonstrated that disease control of at least six months or greater without flare could be seen in selected ALK-positive NSCLC patients even while off ALK TKI. This is notable as it is plausible that intermittent dosing of ALK TKI may delay the emergence of acquired resistance, extrapolating from a preclinical model of ALK fusion-driven lymphoma<sup>[6]</sup>, a phenomenon similar to that described for drug-addicted BRAF V600 mutant melanoma<sup>[7]</sup>. However, intermittent targeted therapy dosing trials in melanoma failed to demonstrate proof of concept, and did not show superiority and with variable overall survival outcomes compared to continuous dosing depending on the study population<sup>[8]</sup>. Although these studies failed to confirm preclinical models, it had been thought that insufficient integration of evolutionary models in the study design may account for the disappointing results<sup>[9]</sup>. ALK-positive NSCLC, particularly v1 and wild-type TP53 status, may be a suitable patient population for such investigations of dose optimisation strategies, given that relatively long duration of therapy with newer generation ALK TKI is not only associated with cost considerations, but also with the development of toxicities.

### CONCLUSION

Prolonged disease control including sustained tumour responses lasting at least six months without disease flare despite TKI discontinuation can be observed in ALK-positive NSCLC patients. Tumour response at the time of treatment discontinuation, line of therapy, overall disease burden, fusion variant and co-alteration status can affect the prognosis of these patients after ALK TKI cessation. Dose-schedule optimisation studies are warranted in advanced stage ALK-positive NSCLC to evaluate therapeutic and cost-effectiveness of alternative intermittent approaches, compared to conventional continuous dosing of targeted therapy.

---

## REFERENCES

1. Kuriyama Y, Kim YH, Nagai H, Ozasa H, Sakamori Y, Mishima M. Disease flare after discontinuation of crizotinib in anaplastic lymphoma kinase-positive lung cancer. *Case Rep Oncol* 2013;**6**:430–433.
2. Pop O, Pirvu A, Toffart AC, Moro-Sibilot D. Disease flare after treatment discontinuation in a patient with EML4-ALK lung cancer and acquired resistance to crizotinib. *J Thorac Oncol* 2012;**7**:e1–2.
3. Park EH, Lee HY, Kim JW, Yeo CD. Disease flare after discontinuing gefitinib in a patient with lung adenocarcinoma and concomitant epithelial growth factor receptor mutation and anaplastic lymphoma kinase translocation. *J Thorac Dis* 2017;**9**:E543.
4. Chافت JE, Oxnard GR, Sima CS, Kris MG, Miller VA, Riely GJ. Disease flare after tyrosine kinase inhibitor discontinuation in patients with EGFR-mutant lung cancer and acquired resistance to erlotinib or gefitinib: implications for clinical trial design. *Clin Cancer Res* 2011;**17**:6298–6303.
5. Christopoulos P, Kirchner M, Bozorgmehr F, Endris V, Elsayed M, Budczies J, et al. Identification of a highly lethal V3+ TP53+ subset in ALK+ lung adenocarcinoma. *Int J Cancer* 2019;**144**:190–199.
6. Rajan SS, Amin AD, Li L, Rolland DC, Li H, Kwon D, et al. The mechanism of cancer drug addiction in ALK-positive T-Cell lymphoma. *Oncogene* 2020;**39**:2103–2117.
7. Das Thakur M, Salangsang F, Landman AS, Sellers WR, Pryer NK, Levesque MP, et al. Modelling vemurafenib resistance in melanoma reveals a strategy to forestall drug resistance. *Nature* 2013;**494**:251–255.
8. Algazi AP, Othus M, Daud AI, Lo RS, Mehnert JM, Truong TG, et al. Continuous versus intermittent BRAF and MEK inhibition in patients with BRAF-mutated melanoma: a randomized phase 2 trial. *Nat Med* 2020;**26**:1564–1568.
9. Chahoud J, Anderson AR, Zhang J, Brown J, Gatenby RA. Evolutionary dynamics and intermittent therapy for metastatic cancers. *J Clin Oncol* 2023;**41**:4469–4471.
10. Spake CS, Reid DB, Daniels AH. Rapid progression of metastatic panspinal epidural non-small cell lung cancer after discontinuation of Alectinib. *World Neurosurg* 2019;**122**:590–592.