



THE CONCOMITANT OCCURRENCE OF HIDRADENITIS SUPPURATIVA AND FOURNIER'S GANGRENE

Georges Khattar^{1*}, Elie Bou Sanayeh^{1*}, Marina Makram², Hussein Rabah³, Saif Abu Baker¹, Salman Khan¹, Catherine Hong¹

¹ Department of Internal Medicine, Staten Island University Hospital/Northwell Health, New York, USA

² Touro College of Osteopathic Medicine, New York City, USA

³ Department of Sleep Medicine, Emory School of Medicine, Atlanta, USA

* Contributed equally

Corresponding author: Elie Bou Sanayeh **e-mail:** elie.h.bousanayeh@gmail.com

Received: 21/03/2024 Accepted: 03/04/2024 Published: 23/04/2024

Conflicts of Interests: The Authors declare that there are no competing interests.

Patient Consent: The patient's healthcare proxy consented to the publication of the images related to the case and to sharing the patient's clinical history.

This article is licensed under a **Commons Attribution Non-Commercial 4.0 License**

How to cite this article: Khattar G, Bou Sanayeh E, Makram M, Rabah H, Abu Baker S, Khan S, Hong C. The concomitant occurrence of hidradenitis suppurativa and Fournier's gangrene. *Titolo articolo. EJCRIM* 2024;11:doi:10.12890/2024_004493

ABSTRACT

Background: Fournier's gangrene represents a life-threatening necrotising infection affecting the perineal region, while hidradenitis suppurativa is characterised by a chronic inflammatory skin condition. The simultaneous occurrence of both conditions is exceedingly rare.

Case description: A 42-year-old female with a documented history of severe untreated hidradenitis suppurativa presented for shortness of breath, fever and lethargy, along with extensive wounds and skin breakdown involving the left axilla, perineum, lower back, lumbosacral region and bilateral gluteal areas, extending to the perineum. Upon presentation, the patient was in a state of septic shock, and a diagnosis of actively manifesting Fournier's gangrene was established at the site of the pre-existing hidradenitis suppurativa lesions. Despite the implementation of an aggressive multidisciplinary approach incorporating surgical interventions, antibiotic therapy and intensive care measures, the patient's condition deteriorated, culminating in septic shock, multi-organ failure and eventual demise. In this report, we discuss both clinical entities, their similarities and differences, and the possible mechanisms by which they may have co-occurred.

Conclusion: The co-existence of hidradenitis suppurativa and Fournier's gangrene poses unique challenges, given the rapid progression of Fournier's gangrene within the context of hidradenitis suppurativa, potentially suggesting the latter as a predisposing factor. This case underscores the importance of vigilant screening and management of hidradenitis suppurativa.

KEYWORDS

Fournier's gangrene, hidradenitis suppurativa, septic shock, skin and soft tissue infection

LEARNING POINTS

- Clinicians should be aware of the potential association between hidradenitis suppurativa and Fournier's gangrene, especially in patients with shared risk factors.
- Both conditions present diagnostic and treatment challenges, emphasising the importance of a thorough differential diagnosis and a tailored selection of antibiotics.
- Proactive and continuous care is crucial in managing chronic diseases such as hidradenitis suppurativa to prevent severe complications, for example Fournier's gangrene.



INTRODUCTION

Hidradenitis suppurativa is a chronic skin disorder with unclear aetiology and pathogenesis^[1]. Follicular occlusion is believed to initiate disease development, resulting in cyst formation, abscesses and, in severe cases, sinus tracts and scarring due to an excessive inflammatory response^[1]. Fournier's gangrene is a rapidly spreading polymicrobial infection affecting the perineal, genital and perianal regions, progressing from superficial to deep fascial layers^[2]. It can lead to septic shock, with high fatality rates despite aggressive treatment. Thus, timely diagnosis and intervention are critical for improving outcomes^[2].

The rare co-occurrence of hidradenitis suppurativa and Fournier's gangrene has been reported only once in the literature, posing diagnostic challenges and complicating treatment^[3]. Hidradenitis suppurativa may impair wound healing and the immune response, potentially leading to a worse prognosis. In this report, we present a fatal case of Fournier's gangrene occurring in a patient with pre-existing hidradenitis suppurativa, providing a detailed examination of the patient's clinical trajectory, diagnostic assessments and therapeutic interventions. Additionally, we analyse both clinical conditions, elucidate shared characteristics and distinctions, and explore potential mechanisms underlying their co-occurrence.

CASE DESCRIPTION

The patient, a 42-year-old woman, had a history of untreated hidradenitis suppurativa for 14 years, an unspecified prothrombin gene mutation and recurrent deep venous

thromboses managed with rivaroxaban. She reported non-adherence to medication, including oral clindamycin, intralesional triamcinolone and infliximab, despite being diagnosed with Hurley Stage III hidradenitis suppurativa. Socially, she had a 10-pack-year smoking history, with no reported illicit drug use.

The patient presented to the emergency department with severe lethargy, shortness of breath and fever persisting for 2 days. She was hypotensive (blood pressure: 51/35 mmHg), tachycardic (heart rate: 105 beats per minute), and febrile (temperature: 38.2°C). Her oxygen saturation was 97% while receiving 2 litres of oxygen via a nasal cannula. Physical examination revealed extensive wounds in the left axilla, perineum, and lumbosacral and bilateral gluteal areas that extended into the perineum. There was evidence of Hurley Stage III wounds in these areas with many wounds within close proximity of each other, some exhibiting visible tunnelling or sinus tracking between them. The ulcers extended into the subcutaneous tissue and were predominantly located over bony prominences, including the spine over transverse processes, as well as the ischium and ilium of the pelvis (Fig. 1).

Laboratory analysis showed leukocytosis (48,000 cells/ μ l), anaemia (haemoglobin: 8.9 g/dl), high anion gap metabolic acidosis (pH: 7.26), elevated lactate levels (3.5 mmol/l), a pro-B-type natriuretic peptide level of 70,000 pg/ml and a creatinine level of 3.2 mg/dl, collectively suggesting multi-organ failure secondary to septic shock.

The chest, abdomen and pelvis computed tomography (CT) scan showed pulmonary oedema and acute pulmonary

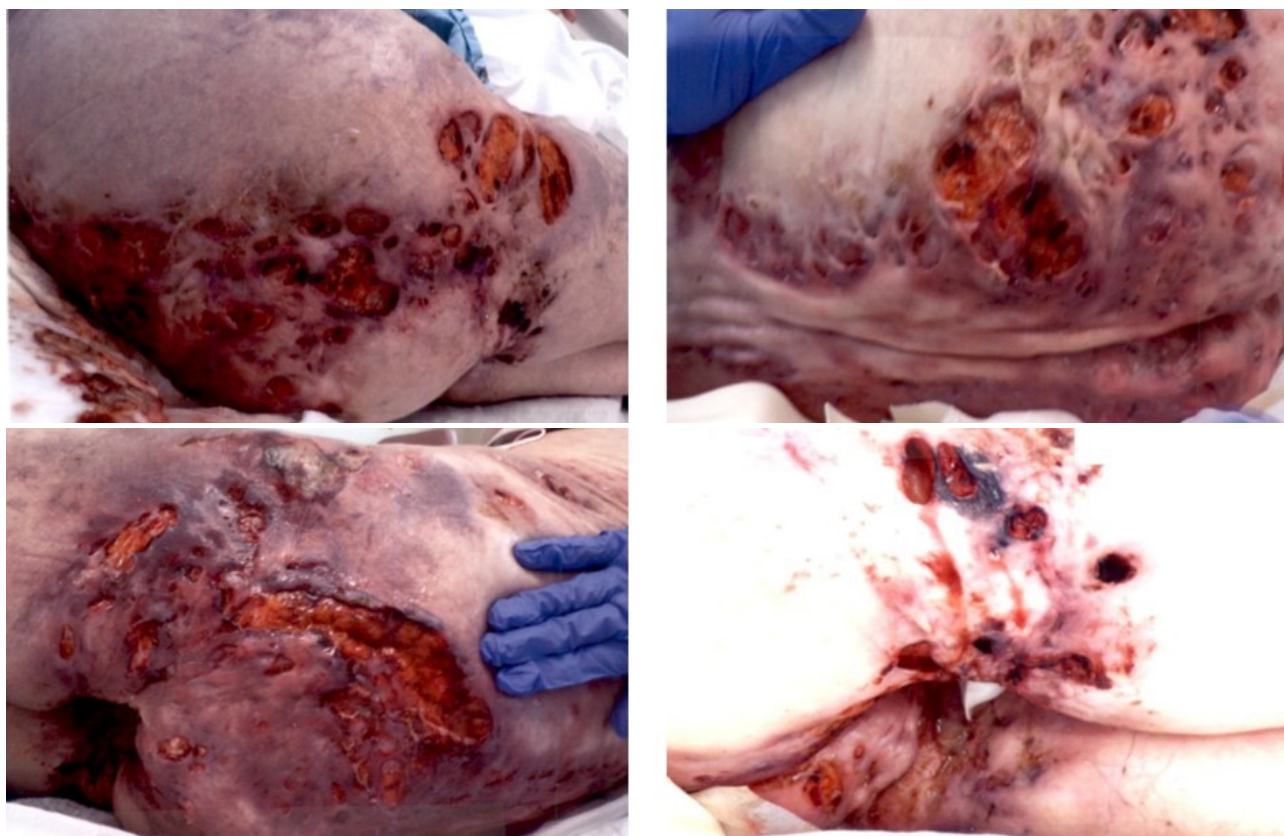


Figure 1. Photographs of the patient's skin lesions prior to surgical debridement.

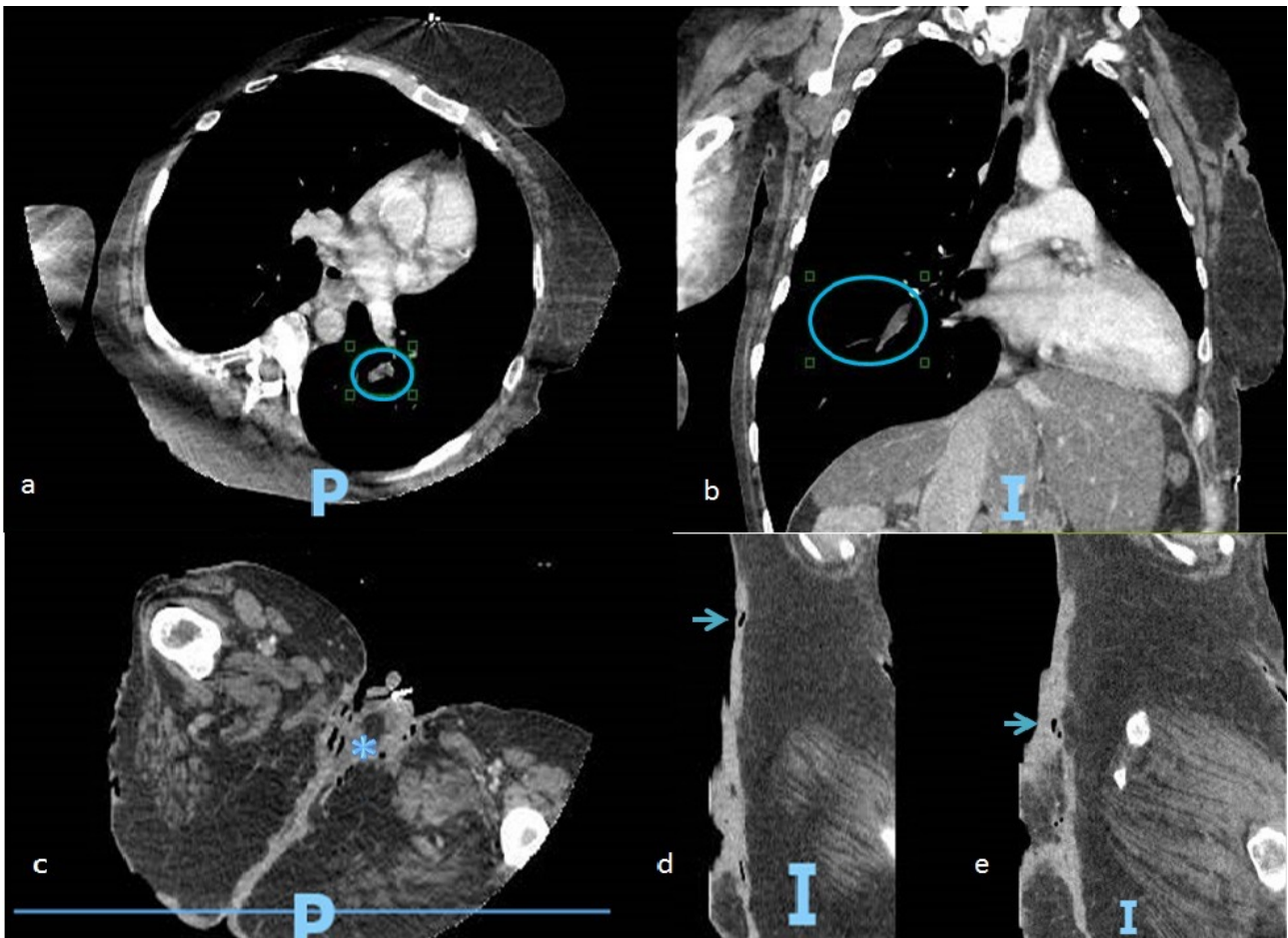


Figure 2. CT scan of the chest, abdomen and pelvis illustrating bilateral segmental pulmonary embolisms (A, B) and necrotising lesions with fat stranding and subcutaneous gas present in the pelvic area (C), extending into the lumbar region of the lower back (D, E).

emboli in the segmental and subsegmental branches of both lower lobe pulmonary arteries, with evidence of right heart strain. Additionally, the CT scan identified a thrombus in the right common iliac vein and revealed subcutaneous emphysema extending from the back into the perineum and buttocks, raising concerns about the possibility of necrotising fasciitis (Fig. 2). A transthoracic echocardiogram revealed global myocardial hypokinesia consistent with sepsis-induced cardiomyopathy, with a left ventricular ejection fraction of less than 20%.

In response to haemodynamic instability, the patient received fluid resuscitation and initiation of norepinephrine plus vasopressin. Heparin was administered for venous thromboembolism, and initial antibiotics included cefepime, vancomycin and metronidazole. Bedside debridement was performed by plastic surgeons for source control. Tissue cultures grew methicillin-resistant *Staphylococcus aureus* (MRSA), and blood cultures yielded multi-sensitive *Streptococcus agalactiae*, leading to antibiotics adjustment to meropenem and linezolid. On day 5, the patient was intubated due to severe toxic-metabolic encephalopathy. The patient was receiving nutritional support via an orogastric tube with a high-protein, high-calorie diet. Despite comprehensive surgical debridement septic shock persisted, requiring the addition of dobutamine to ongoing treatment with norepinephrine and vasopressin.

The patient's condition worsened, resulting in anuric acute kidney injury by day 8. Due to severe haemodynamic instability, the healthcare proxy opted for comfort care measures. Regrettably, the patient passed away on the ninth day of admission due to complications of septic shock from Fournier's gangrene.

DISCUSSION

This is a case of fatal Fournier's gangrene in a middle-aged woman, that developed likely due to untreated severe hidradenitis suppurativa. In 2019, Magdaleno-Tapial et al. provided a brief report on this association, presenting a case of Fournier's gangrene in a 38-year-old patient with the triad of pyoderma gangrenosum, acne and hidradenitis suppurativa, known as PASH syndrome^[3]. The patient underwent surgical debridement followed by the application of autologous partial skin grafts in a second-stage procedure^[3]. This case was suggested as the first reported instance of Fournier's gangrene associated with hidradenitis suppurativa^[3].

Fournier's gangrene is a polymicrobial infection^[4] with predisposing factors including diabetes mellitus, alcoholism, trauma, malnutrition and immunosuppression^[2]. Diagnosis is clinical, with symptoms such as sudden pain and swelling of the perineal structures, purulence, crepitation and fever^[2]. Imaging can aid in uncertain cases, and the presence of

subcutaneous emphysema on radiographs can support the diagnosis, although its absence does not rule it out^[5]. The Fournier's gangrene severity index score is a predictive tool for mortality^[5], with rates reaching 75% when the score exceeds 9^[5]. In our patient, the score was 15, primarily due to abnormalities in temperature, heart rate, serum creatinine, haematocrit, bicarbonate, and white blood cell count. Treatment of Fournier's gangrene includes surgical debridement, fluid resuscitation and broad-spectrum antibiotics^[4].

Risk factors for hidradenitis suppurativa include mechanical and chemical irritation, smoking, obesity, substance use and autoimmune/endocrine conditions^[6]. The role of bacteria in hidradenitis suppurativa pathogenesis is controversial^[6]. Diagnosis primarily relies on clinical evaluation, with histologic examination being optional but valuable for excluding differential diagnoses^[6].

Hidradenitis suppurativa evolves through three distinct stages. Initially, it may manifest as pustules or nodules, which subsequently develop into abscesses, marking the onset of Hurley Stage I^[7]. Progression of the disease leads to recurrent abscess formation, accompanied by the development of subcutaneous sinus tracts, characteristic of Hurley Stage II^[7]. Finally, similar to our patient, these sinus tracts become interconnected and diffuse, resulting in extensive involvement of the affected area, with minimal to no unaffected skin remaining, indicative of Hurley Stage III^[7]. Comparatively, Fournier's gangrene can often be 'clinically silent' at its onset, especially in an immunocompromised host^[8]. Developing subcutaneously before cutaneous signs are appreciable, this contributes to the fatality of the process as it may easily be missed^[9]. Here, it is important to highlight differences in the presentation of hidradenitis suppurativa and Fournier's gangrene. Generalised oedema, necrosis and widespread erythema are not typically seen in hidradenitis suppurativa. In the photographs provided, generalised oedema and erythema can be appreciated around the necrotised tunnels of hidradenitis suppurativa (Fig. 1). These findings led us to believe that there were two distinct processes occurring simultaneously. When considering the location (perineum and buttocks) of the wounds and CT findings, Fournier's gangrene was highly suspected as the second process.

In our case, untreated severe hidradenitis suppurativa caused skin breakdown, acting as entry points for bacteria, leading to a polymicrobial infection progressing to Fournier's gangrene. Clinical signs including pain, swelling, purulence and crepitation, supported by CT scan findings, confirmed a Fournier's gangrene diagnosis.

A thorough examination of both diseases reveals shared risk factors, including smoking, poor nutrition and a sedentary lifestyle, which contribute to immune dysfunction and mechanical stress^[2,6].

Moreover, the transition from abscess formation to sinus formation in the development of hidradenitis suppurativa, predominantly in the perineum and buttocks, creates an

environment conducive to Fournier's gangrene onset. While the role of bacteria in hidradenitis suppurativa pathogenesis is not fully elucidated, sinus tracts provide a direct pathway for bacterial exacerbation^[10]. *S. aureus*, commonly found in hidradenitis suppurativa flare-ups^[4], was identified in our case along with *S. agalactiae*. Although the presence of *S. aureus* aligns with its prevalence on the skin and in hidradenitis suppurativa patients, the identification of *S. agalactiae*, typically residing in the genital and gastrointestinal tracts, is noteworthy^[4]. This unexpected presence could be attributed to either direct external contamination from faecal or urinary sources, or indicative of fistulisation connecting the internal mucosa to the epithelial tissue^[10].

Another mechanism explaining the hidradenitis suppurativa-Fournier's gangrene association is the immune dysfunction induced by hidradenitis suppurativa. The persistent activation of T-cells in hidradenitis suppurativa results in an exhausted phenotype characterised by reduced proliferative capacity, diminished cytokine production and impaired cytotoxicity^[11]. Simultaneously, the overproduction of pro-inflammatory cytokines disrupts the cytokine balance, perpetuating tissue damage and immune dysregulation^[11]. This cytokine environment and impaired immunity create a local tissue environment susceptible to bacterial colonisation. Moreover, the chronic inflammatory state of hidradenitis suppurativa hinders wound healing, providing a continual entry point for bacteria and amplifying the risk of Fournier's gangrene development^[10]. Once Fournier's gangrene is established, hidradenitis suppurativa's immune dysfunction^[11] contributes to an excessive systemic inflammatory response, manifesting as widespread endothelial dysfunction, increased vascular permeability and potentially facilitating the progression to septic shock^[12,13].

Treatment necessitates a tailored approach, including surgical debridement and personalised antibiotic therapy. Unfortunately, the poorly managed chronic hidradenitis suppurativa and the patient's experience of various sepsis-related complications, added significant complexity to our case, leading to refractory septic shock. While this case report provides valuable insights into the potential hidradenitis suppurativa-Fournier's gangrene association, conclusions based on a single case cannot be generalised. Therefore, further research is needed to explore the hidradenitis suppurativa-Fournier's gangrene relationship comprehensively.

CONCLUSION

This case emphasises the importance of vigilant monitoring and consistent outpatient primary care engagement in preventing severe complications in chronic conditions such as hidradenitis suppurativa. It also highlights the necessity for collaboration and multidisciplinary care when managing complex clinical presentations.

REFERENCES

1. Prens E, Deckers I. Pathophysiology of hidradenitis suppurativa: an update. *J Am Acad Dermatol* 2015;**73**:S8–S11.
2. Lewis GD, Majeed M, Olang CA, Patel A, Gorantla VR, Davis N, et al. Fournier's gangrene diagnosis and treatment: a systematic review. *Cureus* 2021;**13**:e18948.
3. Magdaleno-Tapiál J, Valenzuela-Oñate C, Martínez-Doménech A, Sánchez-Carazo JL, Pérez-Ferriols A. Image gallery: Fournier gangrene in a patient with severe hidradenitis suppurativa. *Br J Dermatol* 2019;**181**:e59.
4. Castillejo Becerra CM, Jaeger CD, Rose JR, Beecroft NJ, Shah NC, Posid T, et al. Microorganisms and antibiogram patterns in Fournier's gangrene: contemporary experience from a single tertiary care center. *J Urol* 2020;**204**:1249–1255.
5. Laor E, Palmer LS, Tolia BM, Reid RE, Winter HI. Outcome prediction in patients with Fournier's gangrene. *J Urol* 1995;**154**:89–92.
6. Seyed Jafari SM, Hunger RE, Schlapbach C. Hidradenitis suppurativa: current understanding of pathogenic mechanisms and suggestion for treatment algorithm. *Front Med (Lausanne)* 2020;**7**:68.
7. Ballard K, Shuman VL. Hidradenitis suppurativa. 2023 Apr 17. In: StatPearls [Internet]. Treasure Island (FL): StatPearls Publishing; 2024 Jan.
8. Malik AM, Malik NH, Ahsan MR, Shakeel M, Chaudhry AM, Hamid MR. Fournier's gangrene: an analysis of factors affecting mortality and morbidity. *JAMC* 2016;**28**:518–521.
9. Ro JY, Divatia MK, Kim K-R, Amin MB, Ayala AG. Penis and scrotum. In: Cheng L, MacLennan GT, Bostwick DG, editors. *Urologic Surgical Pathology* (fourth edition), Amsterdam: Elsevier; 2020 p. 853–901.
10. Jemec GBE. Clinical Practice. Hidradenitis suppurativa. *N Engl J Med* 2012;**366**:158–164.
11. Melnik BC, John SM, Chen W, Plewig G. T helper 17 cell/regulatory T-cell imbalance in hidradenitis suppurativa/acne inversa: the link to hair follicle dissection, obesity, smoking and autoimmune comorbidities. *Br J Dermatol* 2018;**179**:260–272.
12. Matusiak L, Bieniek A, Szepietowski JC. Increased serum tumour necrosis factor-alpha in hidradenitis suppurativa patients: is there a basis for treatment with anti-tumour necrosis factor-alpha agents? *Acta Derm Venereol* 2009;**89**:601–603.
13. Delano MJ, Ward PA. The immune system's role in sepsis progression, resolution, and long-term outcome. *Immunol Rev* 2016;**274**:330–353.