

Abiotrophia defectiva Endocarditis: A Rare Cause with Aggressive Systemic Embolisation and Need of Valve Replacement

Ana Cochicho Ramalho¹, Sofia Marques Santos¹, Joao Abecasis², Rui Rodrigues³, Francisco Araújo¹, Helena Cantante¹

¹ Internal Medicine Department, Hospital Lusíadas, Lisboa, Portugal

² Cardiology Department, Hospital Lusíadas, Lisboa, Portugal

³ Cardiothoracic Surgery Department, Hospital Lusíadas, Lisboa, Portugal

Doi: 10.12890/2023_003702 - European Journal of Case Reports in Internal Medicine - © EFIM 2023

Received: 30/11/2022

Accepted: 02/12/2022

Published: 09/01/2023

How to cite this article: Cochicho Ramalho A, Marques Santos S, Abecasis J, Rodrigues R, Araújo F, Cantante H. *Abiotrophia defectiva* endocarditis: a rare cause with aggressive systemic embolisation and need of valve replacement. *EJCRIM* 2023;10: doi:10.12890/2023_003702.

Conflicts of Interests: The authors declare there are no competing interests.

Patient Consent: The patient verbally agreed to the collection of data and publication of this report.

This article is licensed under a [Commons Attribution Non-Commercial 4.0 License](https://creativecommons.org/licenses/by-nc/4.0/)

ABSTRACT

Infective endocarditis (IE) is a well-described infectious disease, one with increased morbidity and mortality being the third or fourth most common life-threatening infection syndrome.

Abiotrophia defectiva is a non-motile, catalase negative, gram-positive coccus in a chain, which can be isolated from the oral cavity, intestinal, and genitourinary tracts. IE due to this agent is rare and associated with heart valve destruction, congestive heart failure, and high embolisation rates, these being the major mortality causes.

We present a case of IE due to this agent, complicated with a stroke, and splenic and renal infarction, with the need for aortic valve replacement.

This article highlights the gaps of knowledge left by the rarity of this disease, which range from its diagnosis to its treatment, and what we need to mitigate such gaps, supported with a case description of a successful treatment of this infection.

LEARNING POINTS

- Infective endocarditis due to *Abiotrophia defectiva* has usually an indolent course, but the embolisation potential is very high.
- The major causes of mortality with this species are congestive heart failure due to valve destruction and the presence of multiple emboli.
- Surgical intervention rates are high with *Abiotrophia defectiva*, reaching 50% of cases.

KEYWORDS

Infective endocarditis, *Abiotrophia defectiva*, embolisation, vegetations, valve destruction.

INTRODUCTION

Infective endocarditis (IE) is a well-described infectious disease, one with increased morbidity and mortality being the third or fourth most common life-threatening infection syndrome after sepsis, pneumonia, and intra-abdominal abscess^[1,2].

The most common organisms implicated in IE include *Staphylococcus* and *Streptococcus* species; however, multiple other agents can cause this infection. *Abiotrophia defectiva* previously belonged to the nutritionally variant streptococci group described by Frenkle and Hirsch^[3], since it is pyridoxine-dependent. With the advances in DNA hybridisation techniques, it is now the only species in its genus^[4]. It is a non-motile, catalase negative, gram-positive coccus in a chain, which can be isolated from the oral cavity, and intestinal and genitourinary tract^[5].

The clinical course may be indolent, but it is also associated with heart valve destruction, congestive heart failure, and high embolisation rates, these being the major mortality causes^[6].

We present a case of IE due to this agent, complicated with a stroke, and splenic and renal infarction, with the need for aortic valve replacement.

CASE DESCRIPTION

A 65-year-old man, with essential hypertension, hypercholesterolemia, and valvular heart disease (with a previous implantation of an aortic bioprosthesis six years before), was admitted to the emergency department (ED) due to a five-hour course of mild dysarthria and aphasia (Fig. 1). At observation he was afebrile and normotensive, with a regular heartbeat and an aortic murmur, grade III/VI, at auscultation. Neurological examination confirmed mild dysarthria and aphasia, with a National Institute of Health Stroke Scale (NIHSS) of 2. Magnetic resonance displayed an insular stroke (left middle cerebral artery territory) (Fig. 2).

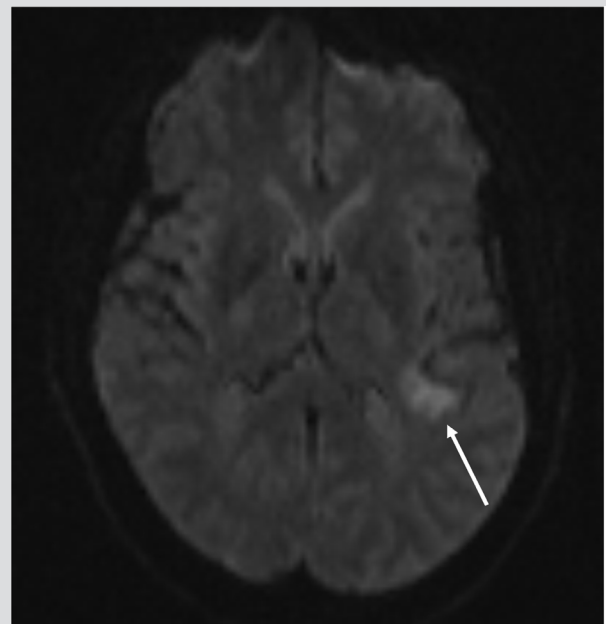
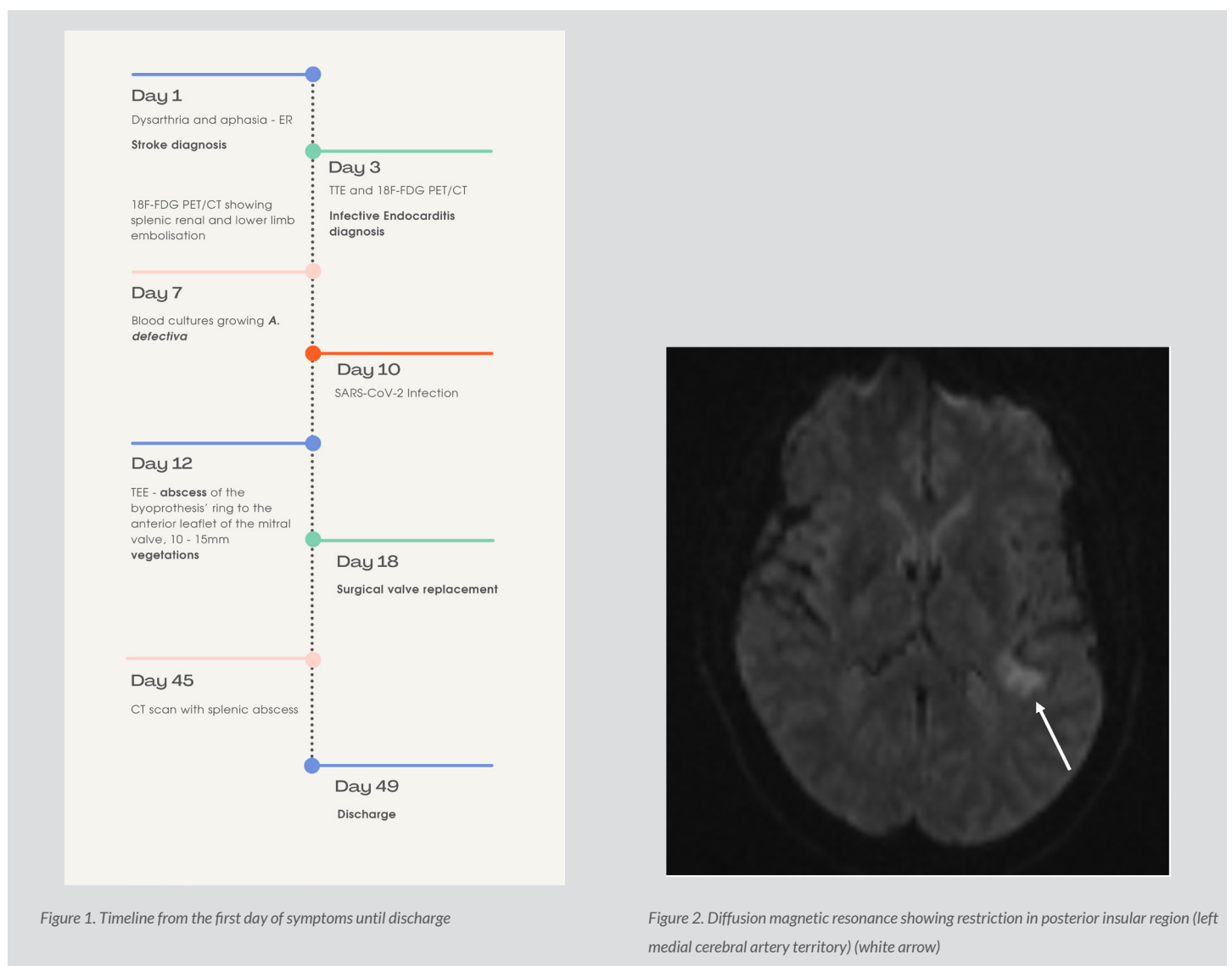


Figure 1. Timeline from the first day of symptoms until discharge

Figure 2. Diffusion magnetic resonance showing restriction in posterior insular region (left medial cerebral artery territory) (white arrow)

Blood analysis showed normocytic normochromic anaemia (haemoglobin 10.8 g/dL), leucocytes of $13.68 \times 10^9/L$ with $9.90 \times 10^9/L$ neutrophils, a c-reactive protein of 4.92 mg/dL and a sedimentation rate of 90 mm/h.

While in the ED, the patient developed fever.

Raising the hypothesis of IE, a transoesophageal echocardiography (TEE) followed (after a normal transthoracic exam [TTE]), showing

thickening of the aortic bioprosthesis cusps with a lumpy contour and increased transprosthetic gradients. It also showed thickening of the posterior aortic root region.

A positron emission tomography/computed tomography scan with 2-deoxy-2-[fluorine-18] fluoro-D-glucose (18F-FDG PET/CT) confirmed aortic valve infection extending to the ascending aorta, and noted splenic and renal infarction, and five other foci of peripheral embolisation in the lower limbs (Fig. 3).

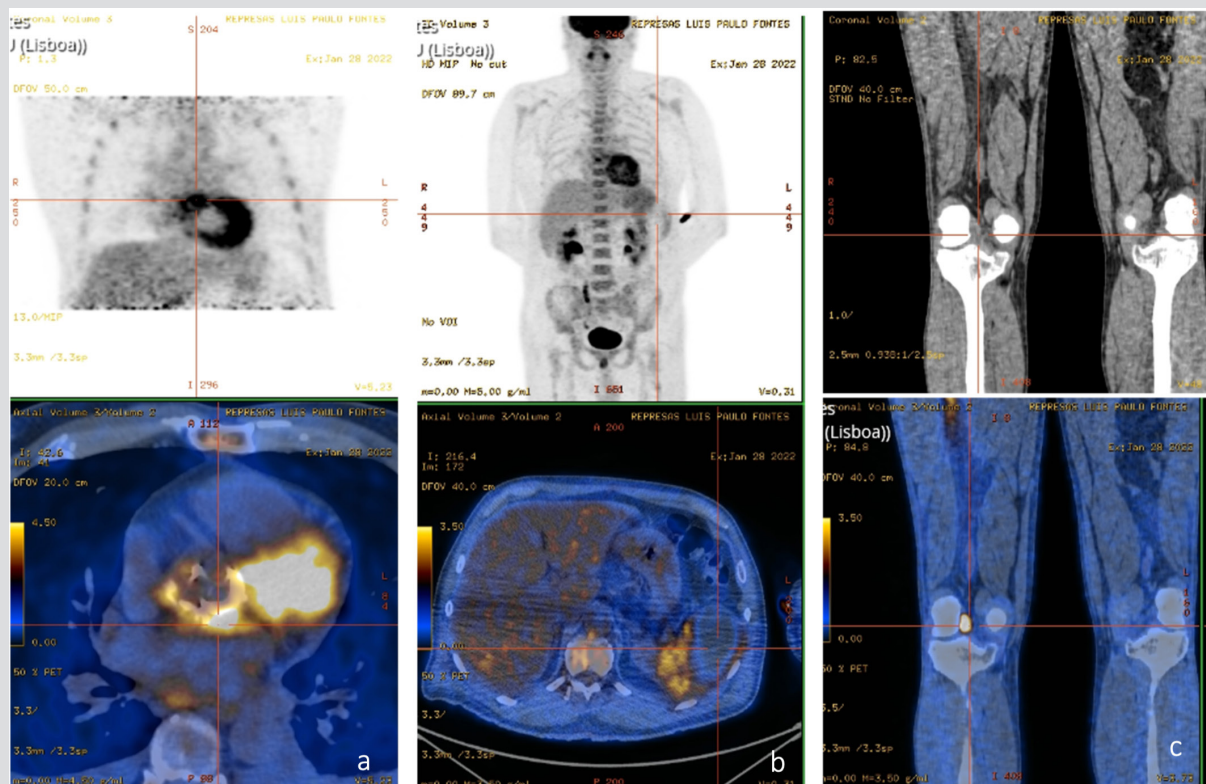


Figure 3. 18F-FDG PET/CT showing aortic prosthesis infection (a), splenic infarction (b), and foci of peripheral embolisation in the lower limbs (c).

With the suspicion of IE, empiric therapy with flucloxacillin, ampicillin, and gentamicin was initiated. Two sets of blood cultures yielded positive results three days later, with growth of gram-positive cocci *A. defectiva*. Due to persisting fever, flucloxacillin and ampicillin were replaced with ceftriaxone (with maintenance of gentamicin). An antimicrobial susceptibility test (AST) was not available at our institution. On day 12, a re-evaluation TEE was performed, revealing an abscess of the entire bioprosthesis ring extending to the anterior leaflet of the mitral valve, and several vegetations measuring between 10 mm and 15 mm. Owing to higher spatial resolution when compared to 18F-FDG PET/CT, a cardiac CT was also requested, being notable for an extensive periprostheses abscess with leaflet involvement. Significant coronary artery disease was also excluded.

Surgical treatment was ascertained after multidisciplinary discussion (due to the risk of ongoing embolisation and the presence of prosthesis dysfunction). However, the patient was, at the time, infected with SARS-CoV-2 (remaining asymptomatic for the whole course of the infection), which postponed the surgery. Valve replacement (with annular reconstruction) took place on the 18th day of hospitalisation. Valve and subsequent blood cultures remained sterile.

The patient completed a total of six weeks of intravenous antimicrobial therapy, and the post-operative transthoracic echocardiography and thorax-abdomen-pelvic CT scan showed a well-placed aortic valve with a minor leak, and slight reduction of the splenic infarct lesion, with an abscess overlying the same area, respectively.

He was discharged with no neurological deficits (NIHSS 0), after recommendations for adequate oral hygiene and mandatory prophylaxis for high-risk procedures were given. Six months after discharge the patient remains symptom free, without any signs of endocarditis or valve insufficiency, keeping a close follow-up with ultrasound control every three months (with gradual reduction of the splenic abscess).

DISCUSSION

The authors present a case of IE due to a rare agent (*A. defectiva*), with numerous severity indicators and a need for surgical intervention, namely several embolic events, enlarging vegetations, and local complications.

A. defectiva is thought to be responsible for 4% to 8% of all cases of IE^[5]. The main difficulties in these cases encompass its identification and difficulty in obtaining an AST that could guide antibiotic treatment.

Significant differences are reported in the tentative beta-lactam epidemiological cutoff values for *A. defectiva*, and such differences may cause different clinical responses to therapy^[5]. An AST was not feasible at our institution. This represents a common setback, and it is related with the fastidious nature of the organism in question.

The European Society of Cardiology (ESC) guidelines recommend six weeks of benzylpenicillin, ceftriaxone, or vancomycin, combined with an aminoglycoside for at least the first two weeks^[2].

Tuohy et al. determined that 83% of *A. defectiva* isolates were susceptible to ceftriaxone at a minimum inhibitory concentration of $\leq 0.5 \mu\text{g/ml}$, while Alberti et al. demonstrated nearly the same (81%)^[5,8]. The use of gentamicin is consensual in the treatment guidelines available. Its use for two weeks is mentioned by both the American Heart Association (AHA) and the ESC. Alberti et al. also established a lack of high-level aminoglycoside resistance^[5].

In the present case, the patient responded well to the combination of ceftriaxone and gentamicin, presenting negative blood cultures after the initiation of such therapy (and posteriorly negative valve cultures).

Besides the rarity of *A. defectiva*, this case is notable for several reasons. It presented with a mild embolic stroke and the first transthoracic and transoesophageal echocardiograms were close to normal.

In prosthetic valve endocarditis, 18F-FDG PET/CT can provide evidence of intracardiac infection and disseminated disease. Its use is important because prosthetic valve-related artefacts often delay echocardiography diagnosis. In the present case 18F-FDG PET/CT confirmed the diagnosis of IE and shed light on the extension of the disease, showing multiple clinically silent embolisation foci.

It is known that *A. defectiva* has a high risk of embolisation, and that the major mortality causes include consequences of multiple emboli or congestive cardiac failure due to valve destruction^[6].

Besides the brain, spleen, kidney, and lower limbs emboli (none of which had life-threatening consequences) a splenic abscess was noted in the last CT scan evaluation before discharge, granting a close follow-up.

Splenic abscess is a rare complication of IE. Splenic infarction is a more common and usually a benign condition. Approximately 5% of patients with splenic infarction will develop abscesses. This can happen either by haematogenous spread with bacteria seeding an infarcted splenic zone, or directly through seeding of the spleen by infected embolised vegetations. Such abscesses are associated with high morbidity and mortality rates, but early recognition can change the prognosis^[7]. In the present case no splenectomy was performed after the reduction of the abscess with antibiotic treatment.

There are several strong evidence-level indications for early surgical valve replacement: signs of severe heart failure, locally uncontrolled infection (abscess, false aneurysm, fistula, or enlarging vegetation), and embolism prevention (according to the vegetations' size and previous embolic events)^[1,2].

A. defectiva endocarditis is difficult to treat, with a failure rate of up to 40% and a need for surgery that can reach 50% of cases^[8]. Despite being eligible in the present case, due to concurring infection with SARS-CoV-2, the procedure was postponed for seven days to be done in the safest way possible.

CONCLUSION

A. defectiva is a rare infection that carries high morbidity and mortality, but it can be successfully treated. The gaps of knowledge left by the rarity of this disease range from its diagnosis to its treatment. Doctors need to be aware of the high embolisation rate that can modify prognosis. Laboratory technicians must pay close attention to positive cocci in blood cultures and acknowledge that specific culture media may be necessary. AST technology must be readily available for treatment guidance and more specific and verified directives are needed for the antimicrobial choice in such patients. Moreover, a multidisciplinary approach is becoming the mainstay of current medical practice, a well-demonstrated point in this case (endocarditis heart team).

REFERENCES

1. Baddour LM, Wilson WR, Bayer AS, Fowler VG Jr, Tleyjeh IM, Rybak MJ, et al. Infective endocarditis in adults: Diagnosis, antimicrobial therapy, and management of complications: A scientific statement for healthcare professionals from the American Heart Association. *Circulation* 2015;**132**:1435-1486.
2. Habib G, Lancellotti P, Antunes MJ, Bongiorni MG, Casalta J-P, Del Zotti F, et al. ESC Guidelines for the management of infective endocarditis: The Task Force for the Management of Infective Endocarditis of the European Society of Cardiology (ESC). Endorsed by: European Association for Cardio-Thoracic Surgery (EACTS), the European Association of Nuclear Medicine (EANM). *Eur Heart J*. 2015;**36**:3075-3128.
3. Frenkel A, Hirsch W. Spontaneous development of L forms of streptococci requiring secretions of other bacteria or sulfhydryl compounds for normal growth. *Nature*. 1961; **191**:728-30.
4. Birlutiu V, Birlutiu RM. Endocarditis due to *Abiotrophia defectiva*, a biofilm-related infection associated with the presence of fixed braces. *Medicine (Baltimore)* 2017;**96**:e8756.
5. Alberti MO, Hindler JA, Humphries RM. Antimicrobial susceptibilities of *Abiotrophia defectiva*, *Granulicatella adiacens*, and *Granulicatella elegans*. *Antimicrob Agents Chemother*. 2015;**60**:1411-1420.
6. Gupta P, Agstam S, Angrup A, Manoj RK, Kanauji, Ray P. Infective endocarditis caused by *Abiotrophia defectiva* presenting as anterior mitral leaflet perforation mimicking cleft anterior mitral leaflet. *J Family Med Prim Care*. 2020;**9**:1229-1231.
7. Elasfar A, AlBaradai A, AlHarfi Z, Allassal M, Ghoneim A, AlGhofaili F. Splenic abscess associated with infective endocarditis; case series. *J Saudi Heart Assoc*. 2015;**27**:210-215.
8. Tuohy MJ, Procop GW, Washington JA. Antimicrobial susceptibility of *Abiotrophia adiacens* and *Abiotrophia defectiva*. *Diagn Microbiol Infect Dis*. 2000;**38**:189-191. [http://dx.doi.org/10.1016/S0732-8893\(00\)00194-2](http://dx.doi.org/10.1016/S0732-8893(00)00194-2).