

Multiple Small Bowel Intussusceptions Detected by Diagnostic Laparoscopy in an Adult Patient with Previously Undiagnosed Coeliac Disease

Valon Saliu¹, Cemal Ulusoy², Andrej Nikolovski¹

¹University Surgery Clinic “Sv. Naum Ohridski”, Skopje, North Macedonia

²Prof. Dr. Cemil Taşçıoğlu Şehir Hastanesi, Istanbul, Turkey

Doi: 10.12890/2022_003391- European Journal of Case Reports in Internal Medicine - © EFIM 2022

Received: 14/05/2022

Accepted: 25/05/2022

Published: 16/06/2022

How to cite this article: Saliu V, Ulusoy C, Nikolovski A. Multiple small bowel intussusceptions detected by a diagnostic laparoscopy in an adult patient with previously undiagnosed coeliac disease. *EJCRIM* 2022;9: doi:10.12890/2022_003391.

Conflicts of Interests: The Authors declare that there are no competing interest

This article is licensed under a [Commons Attribution Non-Commercial 4.0 License](#)

ABSTRACT

Enteric intussusception in adults is usually associated with the presence of a lead point seen on abdominal computerized tomography. However, as intussusception in coeliac disease may not have a lead point, a surgical procedure is often indicated in order to exclude small bowel tumour. We present the case of a male patient who presented with asymptomatic small bowel intussusception. During exploratory laparoscopy, five enteric intussusceptions were detected and a suspicion for coeliac disease was raised. Postoperative duodenal biopsy and CD3 immunohistochemical staining confirmed the diagnosis of coeliac disease, Marsh type 1.

KEYWORDS

Celiac disease, intestine, intussusception, laparoscopy

LEARNING POINTS

- Coeliac disease can present initially with multiple small bowel intussusceptions.
- Intussusceptions in coeliac disease present without a lead point.
- In such cases, diagnostic laparoscopy can help to establish the diagnosis.

INTRODUCTION

Small bowel intussusception is rare in adults, but in children is the most frequent cause of small bowel obstruction^[1,2]. The small bowel is the most common site of ‘enteric’ intussusception, with an overall incidence rate of nearly 50% [3]. The cause is identified in 80–90% of adult cases^[4]. Various benign and malignant conditions are associated with small bowel intussusception, for example coeliac disease, Crohn’s disease, Meckel’s diverticulum, adhesions, endometriosis, enteric polyps, tuberculosis, adenocarcinoma, carcinoid tumours, gastrointestinal stromal tumours, metastatic carcinoma and neuroendocrine tumours^[2]. Benign lesions are the most common (60%), followed by small bowel malignancy (30%); the cause is unknown in 10% of cases^[5].

The presence of a bowel lesion alters normal intestinal peristalsis by serving as ‘a lead point’ and causing the bowel to be telescoped into the following bowel segment. This results in intussusception (invagination) formation^[6]. Due to the frequency of lead points and the possibility of a malignant tumour, surgery is advised in adults with diagnosed intussusception, in contrast to the approach in children, where hydrostatic reduction is the mainstay of treatment^[7].

CASE DESCRIPTION

A 25-year-old man with a body mass index of 20.8 (normal 18.5–24.9) presented without any symptoms of coeliac disease. He was diagnosed accidentally on computerized tomography (CT) urography (indicated by a urologist) performed because of dysuria. A contrast-enhanced abdominal CT scan detected intussusception of the proximal jejunal limb measuring 4 cm in length and without a visible lead point (Fig. 1). Magnetic resonance imaging (MRI) enterography with oral contrast (lactulose) was scheduled but due to the absence of other abdominal complaints the patient did not attend the scheduled examination. However, MRI was performed almost 4 months after the CT scan. It revealed a 6 cm jejunal segment with a thickened intestinal wall described by the radiologist as possible jejunal intussusception (Figs. 2 and 3). Considering the age of the patient and the possibility of a malignant small bowel tumour, scheduled laparoscopic exploration was indicated.

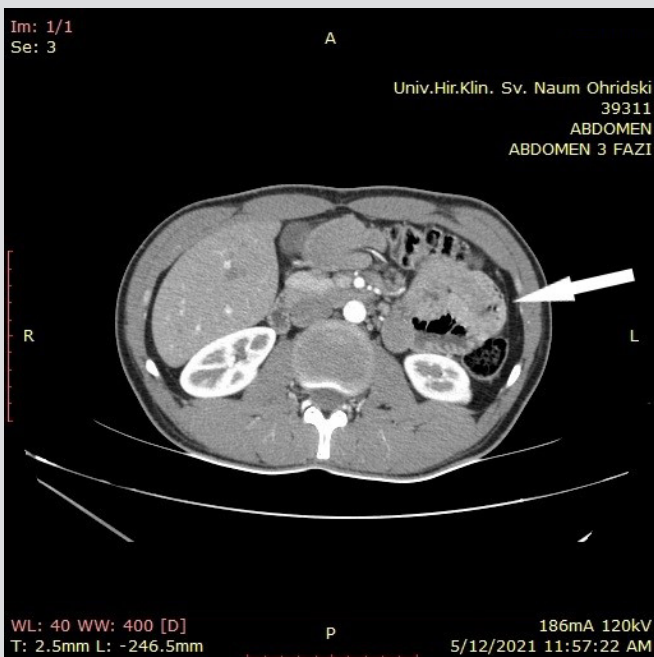


Figure 1. Axial CT scan of the abdomen showing intussusception of the proximal jejunum (arrow)

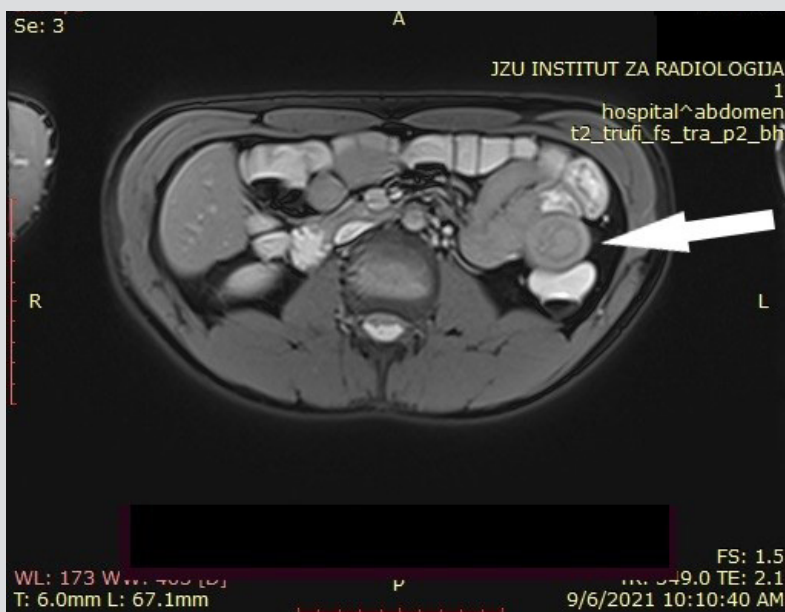
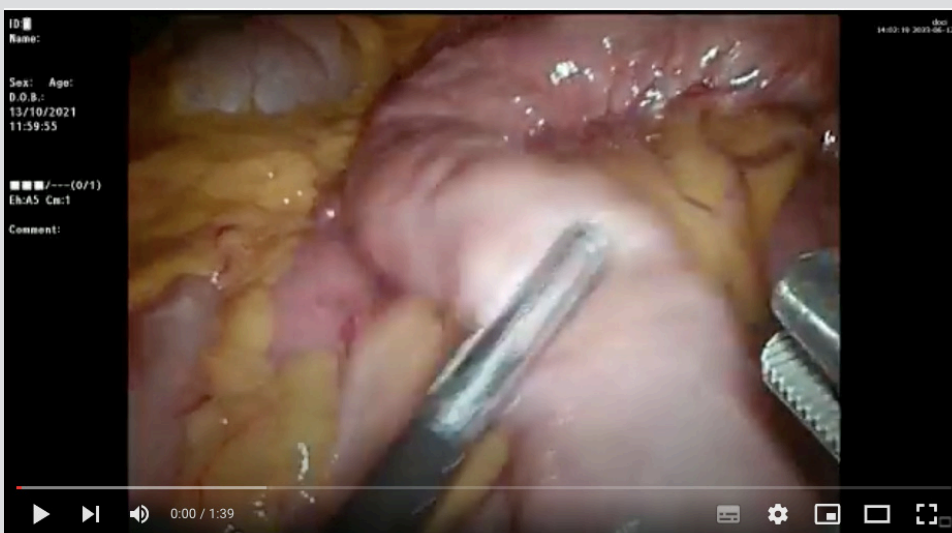


Figure 2. Axial MRI of the abdomen showing the 'target sign' (arrow)

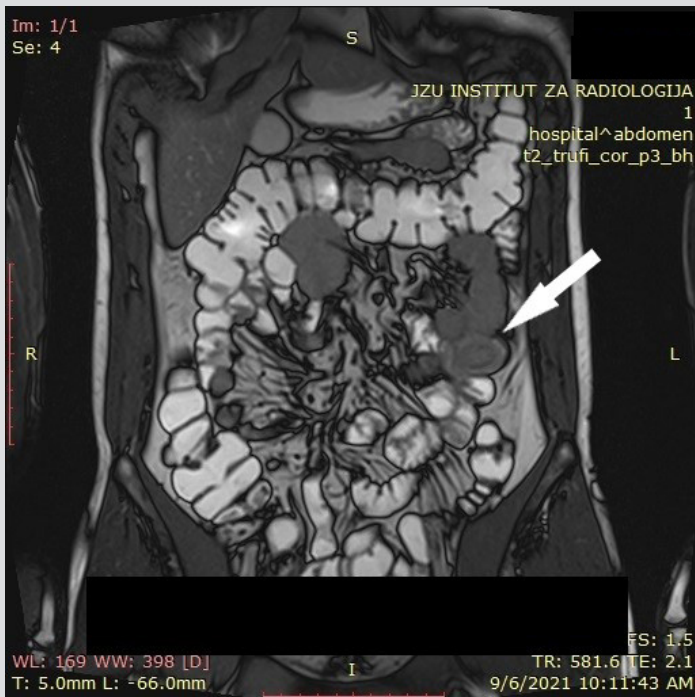

Figure 3. Coronal MRI of the abdomen showing the 'target sign' (arrow)

Intussusception of the proximal jejunum was confirmed during laparoscopy. Further exploration revealed four points of enteric intussusception of the jejunum without signs of intestinal obstruction or vascular impairment of the intestines (*Video 1*). The remainder of the intra-abdominal findings were normal. Neither biopsy nor bowel resection were performed at this point. The postoperative period was uneventful and the patient was discharged at postoperative day 2.



Video 1. Different points of intussusception seen during laparoscopic exploration

Watch the video: <https://youtu.be/IHnfmnlhbmI>

Outpatient duodenoscopy with biopsy was performed after hospital discharge. Histopathology findings revealed oedema in the lamina propria with mononuclear inflammatory infiltration and a preserved villus to crypt ratio. CD3 immunohistochemical staining showed the presence of more than 20 intraepithelial lymphocytes per 100 epithelial cells, which confirmed the diagnosis of coeliac disease, Marsh type 1.

DISCUSSION

Coeliac disease in adults can present as asymptomatic (as in our case) or with constant or recurrent gastrointestinal and non-gastrointestinal symptoms. The most common of these symptoms are abdominal pain, diarrhoea, steatorrhoea, bloating, weight loss, fatigue, skin rash, arthralgia and depression [8]. Conditions associated with coeliac disease include dermatitis herpetiformis, recurrent aphthous ulcers, irritable bowel, iron deficiency anaemia, Down's syndrome, abnormal liver biochemistry, ataxia of unknown cause and Addison's disease [8]. Various tools are used for diagnosis. Tissue transglutaminase antibodies detected by blood tests are sensitive and specific diagnostic markers in patients with coeliac disease. If available, , duodenoscopy with biopsy is the next diagnostic step. In case of a positive antibody test but negative biopsy finding, video capsule endoscopy is indicated [9]. Positive biopsy findings are classified according to the modified Marsh-Oberhuber classification used for disease severity [10]. Additional CD3 immunohistochemical staining is used in case of serological and biopsy discrepancies as it has additional diagnostic value [11].

In cases of current abdominal pain (acute cases) due to intussusception, CT scanning can be used initially as a diagnostic tool. The presence of a 'target sign' should raise suspicion for coeliac disease [12]. Deficient CT and MRI scans in our case resulted in failure to detect the multiple intussusceptions and therefore, a minimally invasive surgical procedure was required in order to establish the diagnosis.

REFERENCES

1. Gonda TA, Khan SUZ, Cheng J, Lewis SK, Rubin M, Green PHR. Association of intussusception and celiac disease in adults. *Dig Dis Sci* 2010;**55**(10):2899–2903. doi:10.1007/s10620-009-1086-8
2. Panzera F, Di Venere B, Rizzi M, Biscaglia A, Praticò CA, Nasti G, et al. Bowel intussusception in adult: prevalence, diagnostic tools and therapy. *World J Methodol* 2021;**11**(3):81–87. doi:10.5662/wjm.v11.i3.81
3. Hong KD, Kim J, Ji W, Wexner SD. Adult intussusception: a systematic review and meta-analysis. *Tech Coloproctol* 2019;**23**(4):315–324. doi:10.1007/s10151-019-01980-5
4. Zubaidi A, Al-Saif F, Silverman R. Adult intussusception: a retrospective review. *Dis Colon Rectum* 2006;**49**(10):1546–1551. doi:10.1007/s10350-006-0664-5
5. Renzulli P, Candinas D. Idiopathic small-bowel intussusception in an adult. *CMAJ* 2010;**182**(3):E148. doi:10.1503/cmaj.090457
6. Marinis A, Yiallourou A, Samanides L, Dafnios N, Anastasopoulos G, Vassiliou I, et al. Intussusception of the bowel in adults: a review. *World J Gastroenterol* 2009;**15**(4):407–411. doi:10.3748/wjg.15.407
7. Lee EH, Yang HR. Nationwide population-based epidemiologic study on childhood intussusception in South Korea: emphasis on treatment and outcomes. *Pediatr Gastroenterol Hepatol Nutr* 2020;**23**(4):329–345. doi:10.5223/pghn.2020.23.4.329
8. Hopper AD, Hadjivassiliou M, Butt S, Sanders DS. Adult coeliac disease. *BMJ* 2007;**335**(7619):558–562. doi:10.1136/bmj.39316.442338.AD
9. Green PHR. The role of endoscopy in the diagnosis of celiac disease. *Gastroenterol Hepatol (N Y)* 2014;**10**(8):522–524.
10. Boschee E, Lacson A, Turner J, Yap J. Duodenal bulb histology in paediatric celiac disease: a case-control study. *J Can Assoc Gastroenterol* 2020;**3**(5):210–215. doi:10.1093/jcag/gwz014
11. Mubarak A, Wolters VM, Houwen RH, ten Kate FJ. Immunohistochemical CD3 staining detects additional patients with celiac disease. *World J Gastroenterol* 2015;**21**(24):7553–7557. doi:10.3748/wjg.v21.i24.7553
12. Tomei E, Diacinti D, Marini M, Mastropasqua M, Di Tola M, Sabbatella L, et al. Abdominal CT findings may suggest coeliac disease. *Dig Liver Dis* 2005;**37**(6):402–406. doi:10.1016/j.dld.2004.10.016