

Is There More to This Case than Pulmonary Alveolar Proteinosis? A Clinical Case Presentation

Tal Frenkel-Rutenberg¹, Amir Dagan¹, Eyal Lotan², Dor Lotan¹, Gad Segal¹

¹Internal Medicine "T", Chaim Sheba Medical Center, Tel Hashomer, Ramat Gan, Israel.

²Department of Diagnostic Imaging, Sheba Medical Center, Tel Hashomer, Ramat Gan, Israel.

Affiliated to the Sackler School of Medicine, Tel-Aviv University.

Doi: 10.12890/2015_000210 - European Journal of Case Reports in Internal Medicine - © EFIM 2015

Received: 05/04/2015

Accepted: 27/05/2015

Published: 29/06/2015

How to cite this article: Frenkel-Ruthenberg T, Dagan A, Lotan E, Lotan D, Segal G. Is there more to this case than pulmonary alveolar proteinosis? A clinical case presentation. *EJCRIM* 2015;2:doi: 10.12890/2015_000210

Conflicts of Interests: The authors declare that they have no conflicts of interest in this research.

Acknowledgements: prior to submission of this case, the authors received an approval of the institutional Ethics Committee.

This article is licensed under a [Commons Attribution Non-Commercial 4.0 License](#)

ABSTRACT

Introduction: Pulmonary alveolar proteinosis (PAP) is a rare disease, associated with excess accumulation of surfactant proteins and lipids in the alveoli.

Clinical presentation: We report the case of a 46-year-old woman with a combined presentation of PAP, myelodysplasia and recurrent miscarriages.

Conclusions: The concomitant presentation of the above might be compatible with a mutation of the haematopoietic transcription factor gene GATA2.

LEARNING POINTS

- Pulmonary alveolar proteinosis (PAP) is caused by accumulation of surfactant proteins and lipids in the alveoli, and presents with progressive exertional dyspnoea and non-productive cough.
- PAP may be part of the clinical presentation of a GATA2 mutation.
- GATA2 mutations have a diverse clinical presentation including myelodysplastic syndrome, PAP, immunodeficiency and vascular/lymphatic dysfunction, and should be suspected in such complex patients.

KEYWORDS

Pulmonary alveolar proteinosis, GATA2; miscarriage, myelodysplasia syndrome, surfactant

INTRODUCTION

Pulmonary alveolar proteinosis (PAP) is a rare pulmonary disease caused by the accumulation of surfactant proteins and lipids in the alveoli, resulting in impairment of gas exchange^[1, 2]. The incidence is believed to be 0.2 per million. PAP potentially stems from three different aetiologies which define three groups of patients: (a) congenital PAP, seen mainly in children; (b) secondary PAP, caused by a decrease in the number of alveolar macrophages and their function^[1]; and (c) acquired PAP, which is the predominant subtype of disease (almost 90% of cases), caused by acquired auto-antibodies against GM-CSF glycol-protein^[2].

PAP usually presents with progressive exertional dyspnoea and non-productive cough with hypoxaemia. Some 20–31% of patients are asymptomatic. Clinical findings include inspiratory crackles (50%), cyanosis (25%) and digital clubbing (29–40%). Because these symptoms are non-specific, the average time to diagnosis is 7 months. Pulmonary function tests demonstrate hypoxia due to pulmonary shunting, and deranged CO diffusion. FEV1 values are usually normal in non-smoking PAP patients^[1]. Imaging studies reveal bilateral infiltrates on chest x-ray, while CT scans show diffuse ground-glass opacities and air-space consolidation with interlobular septal thickening forming a 'crazy paving' pattern^[1,2].

Treatment for symptomatic PAP patients is based on whole lung lavage. Other treatments, effective in cases of acquired PAP, are inhalation or subcutaneous injection of GM-CSF and rituximab, and plasmapheresis^[1,2].

PAP itself, as a single morbidity, is considered to be a uncommon disease. Nonetheless, in rarer cases, it might present as a part of a syndrome (PAP, myelodysplastic syndrome (MDS) and recurrent miscarriages) associated with a mutation in the haematopoietic transcription factor gene GATA2^[3]. The following case presentation describes a patient suspected of, and clinically managed as having GATA2 mutation-associated PAP.

CASE REPORT

A 46-year-old woman was referred to our department from another hospital for the evaluation of worsening dyspnoea over the previous several months. On presentation, the patient described shortness of breath following everyday activity, and a need for supplementary oxygen throughout the night and increasingly during daytime. With room air, the measured oxygen saturation dropped to 81%. She also described diffuse musculoskeletal pain, ruling out a diagnosis of fibromyalgia. She denied frequent cough or haemoptysis, had never smoked, and had no medical, surgical or occupational risk factors for chronic pulmonary disease.

Her medical history revealed several comorbidities, including myelodysplastic syndrome (MDS). MDS had been diagnosed 10 years previously when she underwent an extensive diagnostic work-up for anaemia. Ever since, she had been under haematological surveillance with no directed therapy. A recent bone marrow biopsy had indicated dysplastic changes in all three cell lineages. With regard to her obstetric background, after having four normal pregnancies, she had six miscarriages, four of which occurred before 13 weeks of gestation. No assessment for hypercoagulability had been performed. Additionally, 5 years previously she had been diagnosed with idiopathic epilepsy, and 7 years before the index hospitalization she had experienced a severe case of *Bartonella henselae* infection.

On admission, the patient was alert and orientated. Her vital signs were normal other than decreased oxygen saturation in room air, which was not accompanied by cyanosis. Chest examination revealed normal breathing sounds bilaterally, without wheezing or rhonchi. Bilateral digital clubbing was prominent. The rest of her physical examination was normal. Her blood count demonstrated thrombocytopenia of $54,000/\text{mm}^3$ and the differential blood count showed absolute lymphopaenia ($439 \text{ cells}/\text{mm}^3$ and zero monocytes). A battery of serological tests to examine autoimmunity was performed: antinuclear antibodies (ANA), anti-myeloperoxidase, anti-proteinase 3, rheumatic factor (RF) and complement levels were all within normal values. Other than that, increased levels of lactate dehydrogenase (LDH) and C-reactive protein (CRP) were detected (605 IU/l and 54 mg/l , respectively).

Chest x-ray demonstrated bilateral extensive air-space filling with some sparing of the apices and lateral left base (Fig. 1), representing extensive alveolar infiltrates bilaterally, with rim sparing and a 'crazy paving' pattern on CT (Fig. 2). Pulmonary function tests revealed a predominantly restrictive pattern, with only a small improvement after bronchodilator administration.

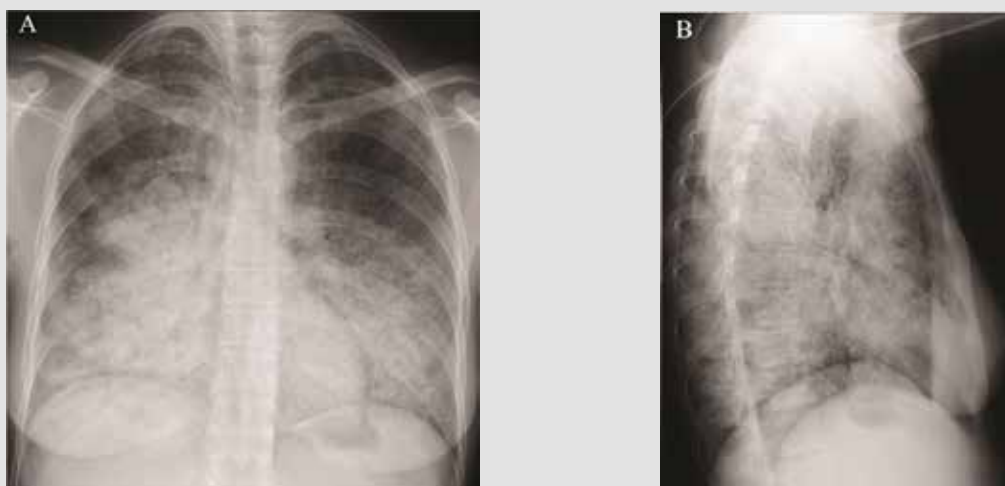


Figure 1: (A) Posteroanterior chest radiograph demonstrates bilateral extensive air-space filling with some sparing of the apices and lateral left base; (B) lateral radiograph of the same patient demonstrates diffuse pulmonary infiltrates that are confluent at both lung bases.

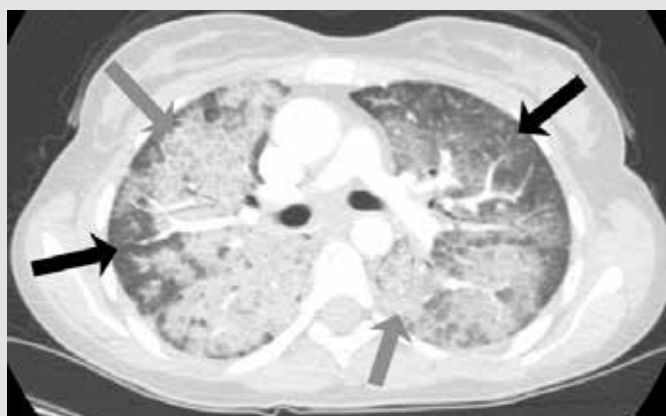

Figure 2: Axial CT scan shows dense air-space disease, with relative sparing of the sub-pleural rim of the lung peripherally (black arrows), and a superimposed interstitial pattern of thickened secondary lobular septa. The typical consolidation of alveolar proteinosis is best seen within the right lung with a 'crazy-paving' appearance (grey arrows).

A diagnostic bronchoscopy was carried out when the patient was first hospitalized: alveolar spaces were found to be filled with a PAS-positive, diastase-resistant acellular proteinaceous material with cholesterol clefts. The alveolar architecture was preserved, without signs of interstitial inflammation or fibrosis, in the lung tissue taken for microscopic examination. The combined macro- and microscopic findings were interpreted as consistent with pulmonary alveolar proteinosis (PAP).

At the beginning of the patient's stay in our department, after consultation with a pulmonologist, and in face of accumulating clinical, radiographic and pathological findings, the diagnosis of PAP was made. Negative testing for anti-GM-CSF antibodies identified the condition as secondary PAP. The patient was referred for a whole lung lavage as a final diagnostic and potentially therapeutic intervention. Unfortunately, a peri-procedural stroke occurred and the patient was transferred to the neurological department for recovery.

DISCUSSION

The simultaneous presentation of secondary PAP, MDS and recurrent miscarriages, along with low monocyte and lymphocyte counts, led us on a quest for a single aetiology. PAP secondary to MDS was found to casually co-appear with Behçet's disease^[4], however our patient did not meet the clinical criteria for Behçet's. Her symptoms are highly suggestive of a single, loss of function GATA2 mutation which causes, via haplo-insufficiency, reduced production of a zinc-finger haematopoietic transcription factor^[3]. The clinical, phenotypic presentation of GATA2 mutation is diverse. It includes immunodeficiency with marked propensity to infections (non-tuberculous mycobacterium, viral and fungal), predisposition to MDS, PAP, dermal pathology, malignancy (mainly viral related), vascular and lymphatic disease, sensorineural hearing loss, miscarriages and hypothyroidism. Laboratory findings reveal circulating monocytopenia, dendritic cell cytopaenia, and B and NK cell lymphocytopenia^[3]. Haematopoietic cell transplantation has been performed successfully in six patients with GATA2 deficiency and resulted in reconstitution of the severely deficient lymphocyte populations and reversal of the clinical phenotype, including severe PAP^[5].

Genetic testing for GATA2 mutation, necessitating full gene sequencing, was not accomplished in our patient. Nevertheless, and notwithstanding the fact that partial sequencing is currently negative, the clinical decision was to manage this patient as a GATA-mutation positive patient due to the high concordance with the clinical features of GATA-mutation positive related cases. After her neurological recovery the patient will be referred for bone marrow transplantation.

SUMMARY

PAP is a rare pulmonary disease that may occur in isolation or as part of a syndrome caused by a GATA2 mutation which also affects the haematopoietic and immune systems. Recognizing those patients with a GATA2 mutation among PAP patients will potentially enable better treatment options to be chosen and possible complications to be predicted. The simultaneous presentation of secondary PAP, MDS and recurrent miscarriages, along with low monocyte and lymphocyte counts, led us on a quest for a single aetiology. PAP secondary to MDS was found to casually co-appear with Behçet's disease^[4], however our patient did not meet the clinical criteria for Behçet's. Her symptoms are highly suggestive of a single, loss of function GATA2 mutation which causes, via haplo-insufficiency, reduced production of a zinc-finger haematopoietic transcription factor^[3]. The clinical, phenotypic presentation of GATA2 mutation is diverse. It includes immunodeficiency with marked propensity to infections (non-tuberculous mycobacterium, viral and fungal), predisposition to MDS, PAP, dermal pathology, malignancy (mainly viral related), vascular and lymphatic disease, sensorineural hearing loss, miscarriages and hypothyroidism. Laboratory findings reveal circulating monocytopenia, dendritic cell cytopaenia, and B and NK cell lymphocytopenia^[3]. Haematopoietic cell transplantation has been performed successfully in six patients with GATA2 deficiency and resulted in reconstitution of the severely deficient lymphocyte populations and reversal of the clinical phenotype, including severe PAP^[5].

REFERENCES

1. Wang T, Lazar CA, Fishbein MC, Lynch JP, 3rd. Pulmonary alveolar proteinosis. *Semin Respir Crit Care Med* 2012;33:498–508.
2. Borie R, Danel C, Debray MP, Taille C, Dombret MC, Aubier M, et al. Pulmonary alveolar proteinosis. *Eur Respir Rev* 2011;20:98–107.
3. Spinner MA, Sanchez LA, Hsu AP, Shaw PA, Zerbe CS, Calvo KR, et al. GATA2 deficiency: a protean disorder of hematopoiesis, lymphatics, and immunity. *Blood* 2014;123:809–821.
4. Handa T, Nakatsue T, Baba M, Takada T, Nakata K, Ishii H. Clinical features of three cases with pulmonary alveolar proteinosis secondary to myelodysplastic syndrome developed during the course of Behçet's disease. *Respir Investig* 2014;52:75–79.
5. Cuellar-Rodriguez J, Gea-Banacloche J, Freeman AF, Hsu AP, Zerbe CS, Calvo KR, et al. Successful allogeneic hematopoietic stem cell transplantation for GATA2 deficiency. *Blood* 2011;118:3715–3720.