



European Journal
of Case Reports in
Internal Medicine

ABSTRACT BOOK OF THE

18th

European Congress of INTERNAL MEDICINE

29-31 August, 2019
Lisbon Congress Centre

GUEST EDITORS

Luís Campos | Nicola Montano



HOW TO CITE

[Surname N, Surname N] et al. [Title of the Abstract]. EJCRIM 2019;6 (S1): [ID] [pages]. DOI: 10.12890/2019_V6Sup1



Publisher: SMC media Srl
Via Giovanale, 7 - 20136 Milan - Italy
ejcrim@smc-media.eu



EFIM

Official Journal of the
European Federation of Internal Medicine
www.efim.org



INDEX

Ambulatory Medicine	1
Cardiovascular Diseases	7
Cerebrovascular and Neurologic Diseases	138
Emergency and Acute Care Medicine	188
Endocrine and Metabolic Diseases	229
Gastrointestinal and Liver Diseases	301
Geriatrics and Multimorbidity	373
Infectious Diseases	394
Kidney and Urinary Tract Diseases	555
Oncologic and Hematologic Diseases	577
Organization and Quality of Health Care	705
Palliative Care	723
Perioperative Medicine	733
Preventive Medicine	735
Rare Diseases	741
Respiratory Diseases	774
Rheumatologic and Immune-mediated Diseases	827
Other	939



AMBULATORY MEDICINE

#110 - Abstract

HOW DO PATIENTS WANT US TO USE THE COMPUTER DURING MEDICAL ENCOUNTERS?

Cédric Lanier¹, Melissa Dominicé Dao², Dave Baer³, Dagmar Haller-Hester¹, Johanna Sommer¹, Noëlle Junod Perron¹

¹ Geneva Faculty of Medicine, Geneva, Switzerland

² Geneva University Hospitals, Geneva, Switzerland

³ Cité Générations Onex, Onex, Switzerland

Background

The Electronic Health Record (EHR) is now widely used during medical encounters. To avoid negative impact on doctor-patient communication, experts in clinical communication have issued recommendations for a patient-centered use of EHRs. However, these recommendations have never been validated by real patients. The aim of our study is to explore patients' preferences regarding doctors' EHR-related behaviours as well as the factors influencing their choice.

Methods

An exploratory study was conducted at two outpatient clinics in Geneva in 2018. French speaking patients, waiting for a medical consultation, were invited to watch videos displaying variations of EHR-related behaviors and indicate which one they preferred. The videos featured 4 specific physician EHR-related behaviours with 2 or 3 variations for each: 1) typing: continuous/intermittent/manual writing; 2) mean of maintaining contact while typing: visual and verbal/verbal/visual; 3) signposting the use of EHR: with/without; 4) position of physicians' hands and bust: on the keyboard and towards the patient/away from the keyboard and towards the patient/on the keyboard and towards the screen. Experienced clinicians blinded to the study identified and validated the videotaped variations of the different EHR-related behaviors. A short questionnaire collected patients' socio-demographics and attitudes/experiences of EHR use. We used multinomial logistic regression to analyze the factors associated with patients' choices.

Results

336 patients watched three different videotaped standardized encounters. A majority preferred intermittent typing versus manual writing or continuous typing (35.7% vs 28.0% or 16.3%). They favored visual and verbal contact (38.9%) over verbal (30.3%)

or visual (13.0%) contact only while typing, as well as signposting the use of EHR versus no signposting (58.9% vs 34.8). Finally, the position with the physician's bust toward the patient and hands away from the keyboard was chosen by a higher proportion of patients (49.7%). The multivariate analyses showed that among all patients' characteristics, only a positive attitude towards EHR was consistently associated with a preference towards intermittent or continuous typing.

Conclusion

Our results confirm patient's positive attitude toward the use of EHR by physicians as well as towards the use of the EHR that follows expert recommendations. Such recommendations should be more consistently taught during medical training.

#118 - Abstract

FROM THE PRIMARY CARE CLINIC TO THE INPATIENT DEPARTMENT AND BACK: CONTINUITY OF CARE AND PROVIDERS

Jenan Awesat, Boris Shvarts, Tali Shafat, Jacob Drieher, Shlomi Codish, Leonid Barski

Soroka University Medical Center, Beer Sheva, Israel

Background

During the last decades recurrent hospitalizations have become one of the main problems facing internal medicine and primary care staff. At our institute, patients are currently admitted sequentially to internal medicine wards. The staff of the primary care clinic does not know the ward's staff, and they have few opportunities for feedback to impact the course of admission.

Aim

To evaluate the effectiveness of an intervention to admit primary care clinic patients to a specific internal medicine ward, in terms of readmission rate, quality of care, patient and staff satisfaction.

Methods

The study included all patients from community clinic "E" who were admitted to internal medicine between June 2015 and December 2016, with two comparison groups: a historical cohort of Clinic "E" (June 2012-Dec 2013) and concurrent cohort of Clinic "A" patient's admissions. Outcomes included readmissions

rates, patients and staff satisfaction. Patients' and hospitalization characteristics were compared between the two clinics. We used generalized estimating equation (GEE) logistic regression model (unstructured matrix) to compare proportions of readmission between intervention vs. control groups, to account for the clustering of the responses by the same patient.

Results

During the study period 2015-2016, 217 patients of clinic "E" were admitted 454 times to ward "F". Meanwhile, 351 clinic "A" patients were admitted 617 times to all internal medicine wards. The historical cohort included 699 admissions of 396 patients of clinic "E" to all wards. Readmission rate during one week was 5.9% in intervention group, 8.0% in historical clinic "E" cohort, and 7.3% in clinic "A" cohort. During one month, proportions were 15.9%, 20.5% and 20.9% respectively. In multivariate analysis, readmission rate during one week was lower among intervention group compared to historical cohort of clinic "E" (OR=2.77 95% CI 1.73-4.44 P<0.001) adjusted to age and gender. During one month, there was a trend toward lower readmission rates in comparison to current cohort of clinic "A" (OR=1.38 95% CI 0.96-1.99 P=0.086) adjusted to age and gender.

Conclusion

Clustering primary care clinic patients to admission in a specific internal medicine ward was associated with decreased readmission rates and improves patient's satisfaction.

#349 - Abstract

THE IMPACT OF 24-HOUR AMBULATORY MEASUREMENT ON ANTIHYPERTENSIVE THERAPY MODIFICATION AND CHANGE IN DIPPER STATUS

Sebastjan Bevc^{1,2}, Jaime Blazquez-Saldana³, Nejc Piko¹, Cvetka Krel¹, Robert Ekart^{4,2}, Radovan Hojs^{1,2}

¹ Department of Nephrology, Clinic for Internal Medicine, University Medical Centre Maribor, Maribor, Slovenia

² Medical Faculty Maribor, University of Maribor, Maribor, Slovenia

³ Autonomous University of Nuevo Leon, Monterrey, Mexico

⁴ Department of Dialysis, Clinic for Internal Medicine, University Medical Centre Maribor, Maribor, Slovenia

Background

The 24-hour ambulatory blood pressure measurement is a useful, noninvasive tool for the evaluation of blood pressure status of the patients. Since arterial hypertension remains an important risk factor for development and progression of chronic kidney disease, the exact evaluation of blood pressure is crucial. The results of 24-hour ambulatory blood pressure measurements should lead to a modification in antihypertensive therapy and consequently optimization of blood pressure. However, less is known about the possible change in dipper status in these patients. The aim of this study was to determine the impact of 24-hour blood pressure

measurements on the change in drug prescriptions and if this change resulted in a decrease in blood pressure and/or dipper status of the patients.

Methods

11 patients (8 women - 72.7%), were included in the study. All patients had two 24-hour ambulatory blood pressure measurements in the period of 6 months. Therapy prior to first and after the second measurement of 24-hour ambulatory blood pressure was recorded. Blood pressure values and dipper status of all patients were recorded in the first and second measurement as well. SPSS statistical software was used for statistical analysis.

Results

The average systolic blood pressure in the first measurement was 150.8 +/- 23.2 mmHg (minimum 125 mmHg, maximum 209 mmHg) and diastolic 85.7 +/- 22.2 mmHg (minimum 58 mmHg, maximum 130 mmHg). 7 patients (63.6%) were either non-dipper (n=3, 27.3%) or reverse-dipper (n=4, 36.4%). Antihypertensive therapy was modified, a significant increase in combination therapy was observed (1 patient before the first measurement (9.1%), compared to 5 patients (45.5%) after the second measurement). Drug therapeutic groups remained unchanged. The average systolic blood pressure in the second measurement was 146.3 +/- 23 mmHg (minimum 109 mmHg, maximum 194 mmHg) and diastolic 83.5 +/- 21.5 mmHg (minimum 69 mmHg, maximum 144 mmHg). We observed change in dipper status where one patient became normal dipper and the number of patients in the reverse-dipper group decrease importantly (4/11 (36.4%) at the beginning vs 2/11 (18.2%) after therapy adjustment).

Conclusion

The results show the importance of 24-hour blood pressure measurement on the optimization of the antihypertensive treatment regimen, emphasizing the prevalence of combination therapy. An increase in combination therapy resulted in better blood pressure control and changed dipper status.

#509 - Case Report

THE TRADITIONAL CHINESE MEDICINE IN THE PRACTICE OF THE PUBLIC HEALTH SERVICE

Tereza Cabral Gomes

Municipal Health Department, Macaé, Brazil

Introduction

The interaction among different therapeutic practices in the ambulatory sphere was strengthened with the implementation in the Brazilian public sector of the National Policy of Integrative and Complementary Practices (NPICP), where Traditional Chinese Medicine (TCM) and other acupuncture practices, such as the Yamamoto New Scalp Acupuncture (YNSA), could reach populations which find it difficult the access to them. The work is

developed in the Municipal Nucleus of Integrative Health (MNIH) in the city of Macaé, as well as auriculotherapy and homeopathy.

Case description

The use of TCM has, as a target, to extend the medication response of conventional practices and decrease the time of use of symptomatic drugs, through the articulation of the TCM with the other medical and paramedical specialties available in the MNIH and in any other health services of the municipality.

The treatment based on the TCM addresses the patient having not only the nature of the disease as a parameter, but also the constitution of the individual restoring their homeostasis, and it is in this context of the therapeutic response that the study develops. To the traditional anamnesis were added the examination of the tongue and pulse, recognizing the constitution of the patient to draw the therapy. The integration of the practices carried out in the MNIH also allowed the association of these to the diagnosis and therapeutics of patients in homeopathic treatment that could be used of parameters such as the physical examination based on the TCM, as well as in the motor physiotherapy in neurological patients when performed simultaneously to the cranial pinning point, YNSA.

Discussion

The MNIH work experience allowed patients with autoimmune and neurological diseases to be treated simultaneously with the Integrative and Complementary Practices associated with conventional therapies, resulting in the reduction of the confirmed inflammatory process in imaging scans and serology tests, improvement of the dynamic balance and improvement of muscle strength and proprioception in neurological disorders and reduction or suppression of symptomatic medications.

The association of TCM with the traditional therapeutic arsenal provided treatment of relevance demonstrated by the clinical improvement and by complementary exams of the patients. Because it does not present side effects nor absolute contraindication, it has a range in pathologies beyond the syndromes traditionally described.

#912 - Abstract

INTEGRATING CONSCIOUS/UNCONSCIOUS FILM MESSAGES AS POST-HYPNOTIC SUGGESTIONS

António Pais-De-Lacerda¹, Noa De Lacerda²

¹ Hospital de Santa Maria, CHULN, Lisbon, Portugal

² Instituto Nacional de Cardiologia Preventiva Professor Fernando de Pádua, Lisbon, Portugal

Background

Suggestions can be answered with or without hypnosis so that they can be used consciously or subconsciously. Post-hypnotic suggestions are intended to generate a particular patient's response in his/her everyday life, in order to drive a modification

of some behaviour or belief, by processing stimuli during hypnosis in a modified state of consciousness. We intended to ascertain the effect of the "conscious" reinforcement in real life, of posthypnotic suggestions - during a playful activity - in which the passive (but emotionally involved) person observes, through the visualization of a movie, a reality of circumstances that mirror his/her own problems.

Methods

Study of 3 clinical cases (1. 24-year-old brother of a 18-year-old girl dying with irreversible disease - does not accept his sister's death; 2. Social isolation in a 45-year-old woman with peritoneal carcinomatosis; 3. Depression in a 56 years old woman with an "impossible" relationship with her mother). All patients underwent 2 sessions of hypnotic trance (15 days apart) with post-hypnotic suggestions. At the end of the second session of the 3 cases, the visualization at home of a particular film (related with the concerned problem) was recommended. Proposed movies: 1. "My Sister's Keeper" (by Nick Cassavetes, USA, 2009); 2. "Y tu mamá también" (by Alfonso Cuarón, Mexico, 2001); 3. "Boulevard" (by Dito Montiel, USA, 2014).

Results

In the 3 cases, there was a change in the unwanted behaviour in a period of less than one month (1. Acceptance and pacification, with a short early mourning depression; 2. Carrying out a long trip to the East that has long been dreamed, but never previously considered for "this actual" moment; 3. Understanding her father's homosexuality and insight into the tolerance of her mother, who never asked for divorce).

Conclusion

The phenomenon of hypnotic suggestions has emphasized the importance of the "cognitive unconscious" in modifying and generating personal behaviours and experiences. The interflow of unconscious post-hypnotic cues with a conscious verbal and non-verbal involvement of both cerebral hemispheres can accelerate and strengthen the behavioural modifications required by both the awakening of memories and the wider promotion of introspection. The visualization of films advised by an internist can promote the understanding of many situations difficult to manage, modifying behaviours and attitudes not only of the patients but also of their relatives.

#1022 - Abstract

STUDY OF PREVALENCE ON ALCOHOLISM AND ASSOCIATED CLINICAL FACTORS IN THE COMMUNITY

Pascual Valdez, Hugo Milione, Gabriela Lourtau, Eduardo Del Cerro, Miriam Otero, Juan Lamelza, Yesenia S Maldonado Torres, Yanina Mancuso, Daniela Mantella Gorosito, Matias Laguzzi, Michelle Schavartz, Nahir Alarcon, Noelia Sanchez, Paula Pañiagua National University La Matanza. Argentina., Buenos Aires, Argentina

Objectives

To quantify the prevalence and periodicity of alcohol consumption in the community, describe the AUDIT questionnaire items, quantifying responses in each one of them

Methods and Population

Prospective, observational, transversal, analytical study. Community of La Matanza. Accidental sampling approach on public roads prior consent. Descriptive and inferential statistics. 594 citizens were approached.

Results

Mean age \pm MAD 25.00 \pm 5.00, ranges: 11-89 years, highest prevalence between 17-23 years. Female predominance (52.8%). 57.9% consume alcohol habitually, 65.5% consumed in the last month. The consumption is daily in 8.2%, sporadic in 40.7% and only weekends in 51.1%. 52.3% drive vehicles. In 19% there are other consumptions. 53.7% have had acute symptoms (abstinence or drunkenness). 3.2% of women who have been pregnant consumed alcohol during the pregnancy. In the AUDIT questions the answers were: consume 2-4 times a month 30.6%; one to two drinks daily 60.5%. 9.9% consume 6 or more drinks in a day. 2.7% have not been able to do their activity once a month for having drunk. 5.1% have monthly regrets for drinking. The 16.2% had a damage by their consumption (the drinker or another person), In 13% someone was worried about their alcoholism. Medium AUDIT 4, people with AUDIT of 8 or more: 44 (7.45%).

Conclusion

Habitual consumption of alcohol is high. The AUDIT detects specific data that interfere with the quality of life.

#1032 - Abstract

COMPARATIVE STUDY OF THE CONTINUITY IN TREATMENT BETWEEN PATIENTS WITH DISORDER BY CONSUMPTION OF SUBSTANCES AND PATIENTS WITH DUAL PATHOLOGY

Pascual Valdez, Marina Riso, Cecilia Castelluccio, Adriana Bulacia Juan A. Fernandez Hospital. Toxicology Division. Government of the Autonomous City of Buenos Aires. Argentina., Caba, Argentina

Objective

To compare the continuity in the treatment for addictions between patients with and without associated psychosis.

Methods

Retrospective, observational, longitudinal and analytical design. We reviewed 180 medical records of patients treated over a year, collecting sociodemographic data, duration of treatment, drug preference, presence or absence of psychosis.

Results

Male dominance, 70% (n 125). Global average age 32.67 years. In patients with psychosis (n36) 29.97 years. Frequency of psychosis 19.44%. Continuity of treatment in patients with and without psychotic disorder: the continuity of treatment in patients with psychotic disorder was 70%, 44.44% and 22.22% at 1, 3 and 6 months respectively. The continuity of treatment in patients without psychotic disorder was 69%, 32.71% and 14.84% at the 1st, 3rd and 6th month. The differences observed in the greater continuity of treatment in patients with psychosis are not statistically significant ($p=0.91$, $p=0.86$ and $p=0.53$ at the 1st, 3rd and 6th month, respectively).

Conclusions

Contrary to what the literature refers to in dual pathology, in our experience, psychotic patients with substance dependence disorders have no less continuity in treatment than non-psychotic patients.

#1687 - Abstract

THE DEVELOPMENT OF AN ALGORITHM FOR IDENTIFYING PRIMARY CARE TREATABLE OUTPATIENT VISITS FOR PATIENTS WITH DIABETES

Wender Lin

Chang Jung Christian University, Tainan, Taiwan

Background

Patients can freely choose health care providers without referral under Taiwan's National Health Insurance program (NHI). Therefore, hospital outpatient departments are crowded with patients whose chronic conditions can be treated in primary care settings. Diabetes is the most common condition mentioned above. This study aimed at developing an algorithm for identifying patients with diabetes whose conditions are treatable in primary care settings.

Methods

Claim data from one million of randomly sampled beneficiaries enrolled in Taiwan's NHI in 2010 was used to develop an algorithm of classifying ambulatory care visits made by patients with diabetes into various primary care groups. Visits in the same group had a similar probability of visiting office-based physicians, similar comorbidities, and the same level of previous health care utilization pattern such as hospitalization, the numbers of emergency department visits, the numbers of drugs prescribed and continuity of care. Classification and regression tree (CART) tool in SAS enterprise miner 13.1 was applied as the classification method. Groups with the probability of being treated in primary care settings higher than 50% were classified as primary care treatable groups.

Results

There were 148,751 visits made by patients with simple diabetes.

About 44% of these visits were treated in tertiary hospitals. After classification tree analysis, patients with simple diabetes can be classified into 22 primary care groups. In the same group, the probability of getting care from primary care settings is similar, as well as the demographic characteristics and health care utilization pattern. The most predictive factors to identify visits treatable in primary care setting were the absence of previous hospitalization, comorbidities, and the number of emergency visits in 6 months. The classification error rate was 43%. The proportion of diabetic patients treatable in primary care setting who were instead treated in tertiary hospitals ranged from 35% to 56% among hospitals.

Conclusion

Nearly half of the patients with simple diabetes who were treated in tertiary hospitals had similar demographic characteristics, comorbidities, and previous health care utilization pattern as those who were treated in primary care settings. Health policy to redirect these patients into primary care settings is warranted to improve the efficiency of the health care system.

#1690 - Abstract

HOSPITAL AT HOME AND THE READMISSION OF PATIENTS TO CONVENTIONAL WARDS – CAN FUNCTIONAL STATUS BE A GOOD PREDICTOR OF RISK AND HOW CAN WE USE IT?

Jose Pedro Tadeu, Joana Malheiro, Heloisa Ribeiro, Maria José Monteiro, Marta Perez, Susana Pereira, João Duarte, Nilton Silva, Luís Teles

Centro Hospitalar de Entre Douro e Vouga, Santa Maria Da Feira, Portugal

Background

Hospital at Home (HaH) is becoming more common in Portugal. This project aims to treat a vast number of pathologies at the patients' homes, being that some require readmission to conventional in-hospital wards, becoming of paramount importance to understand which factors may contribute to this.

Methods

Retrospective study of patients admitted to the HaH Unit between November 2nd and April 30th. Data were collected from the electronic medical record. Comorbidities were evaluated using Age Adjusted Charlson Score (aaCS) and Modified Charlson Score (mCS) and functional capacity was accessed using AVD-DezIs score, a score validated in our hospital, that provides a patient global capacity based on the ability to perform the daily life and instrumental activities. Data was analyzed using SPSS v.20.0. Normality was tested using Kolmogorov-Smirnov test and differences between groups was accessed with Mann-Whitney Test. A value of $p \leq 0.05$ was considered statistically significant.

Results

During the first 6 months of activity we admitted 91 patients,

with median age of 66 (min 21, max 94), 51 (56%) males, 77% of which were admitted from the internal medicine ward. We had 87 discharges, 14 were in-hospital readmissions – 2 to surgery wards (1 programmed, 1 urgent) and 12 to the internal medicine ward (2 due to willingness, 10 because of clinical degradation).

Comparing with the patients that were not readmitted, there were no differences between age (68.5 vs 66, $p=0.785$), duration of in-hospital treatment previous to HaH admission (4.5 vs 3 days, $p=0.491$), aaCS (5.5 vs 4, $p=0.215$), mCS (1.5 vs 1, $p=0.301$). However, the readmitted patients were more dependent (AVD DezIs 82.5 vs 95, $p=0.034$), with bigger dependence on the instrumental activities (1 vs 0, $p=0.029$). Of the 10 readmissions being analysed, 6 were in individuals with more than 65 years. On this age group ($n=47$) there was no difference between aaCS (7 vs 6, $p=0.202$), mCS (3 vs 2, $p=0.214$). Considering AVD DezIs there seems to be a tendency for bigger incapacity on the readmissions (62.5 vs 85, $p=0.088$) with larger dependency on the instrumental activities (4.5 vs 1, $p=0.077$).

Conclusion

Even with such a small sample of patients, we can say that function is a better predictor of in-hospital readmission of HaH patients than comorbidities scores. Although AVD DezIs score being only formally validated for elderly (65+) patients in our Hospital, considering our results we are trying to expand this score to the general hospitalized population.

#2042 - Case Report

THE POTENTIALITIES OF A DAY HOSPITAL IN CLINICAL RESEARCH

Inês Moreira Sousa

Centro Hospitalar Universitário Lisboa Norte, Lisboa, Portugal

Introduction

Residency in Portugal relies on 5 years of clinical practice in different areas of medicine, and in some cases include one year of Internal Medicine internship. Although research is a valuable part of the residency, it mainly results from the effort of the resident, since there is no protected time during residency dedicated exclusively to research and logistic resources are sparse.

We would like to share the potentialities and advantages of day hospital in clinical research.

Case description

Day Hospital is a service specialized in ambulatory assessment (acute or chronic), integrated into the Medicine Department. It is made up of a multidisciplinary team - one administrative, one nurse and one operational assistant in full time and internal medicine and immunology physicians in part-time. It has 4 armchairs in an open space room for monitoring and treatment, a work station for nurses and another for doctors and a private office for medical appointments.

It is a place with excellent conditions to perform clinical research

since it has space with privacy, clinical instruments and a dedicated nurse that could work as a research nurse and help physicians in this job. Additionally, it is located near to the medicine ward, which allows easy access to clinicians and patients.

In the last 5 years, we amplified the use of this resource to develop clinical research. Firstly, with prospective longitudinal study in the diabetes field and currently there is ongoing the recruitment and cardiovascular risk assessment of Parkinson's disease patients and controls in the context of a Ph.D. project of one internal medicine resident. Outpatient parenteral antimicrobial therapy is another area we are now considering for research.

There are good conditions to perform medical histories, physical examination, and cognitive assessment and fulfill questionnaires. It is easy to perform blood and urine collection, and also simple exams like electrocardiography, echography and other non-invasive procedures.

Residency is an excellent opportunity to develop new skills not only in clinical medicine but also in research. There are opportunities and resources, like the Day Hospital, that could help residents who intend to follow an academic career.

Discussion

Day hospital is a service with excellent conditions to develop clinical research, due to its environment characteristics and the human and technical resources available.

#2245 - Case Report

SEVERE ANAEMIA RELATED TO DIOGENES SYNDROME: A CASE REPORT

João Rodrigues Barros, Maria Mercedes Calvo
Hospital do Espírito Santo de Évora, Évora, Portugal

Introduction

Megaloblastic anemia (MA) is caused by abnormal DNA synthesis of red blood cell precursors in the bone marrow. MA progresses gradually, allowing the development of cardiopulmonary compensatory mechanisms, with consequent delayed onset of manifestations (asthenia, dyspnoea, palpitations and jaundice). Diogenes Syndrome is a behavioural disorder characterized by hoarding and self-neglect, with a higher prevalence in females and older age (>60 years). These patients tend to have average or above average intelligence and to live in social isolation refusing help, which can complicate anamnesis and delay diagnosis. A trigger event, such as emotional stress in a predisposed individual, usually with obsessive-compulsive personality traits, can predispose to this disease. Due to frailty, nutritional deficits and lower adherence to treatment, mortality is higher in this population group.

Case description

A 46-year-old divorced female patient with medical history of chronic sciatica, refers to the Emergency Department due to mechanical lumbar pain for the last 7 days. The patient states that she lives with her younger daughter, and gets support from a close

friend. She presents lumbar tenderness points with no neurologic symptoms; however she appears apathetic, pale and tachycardic. She was given analgesia and an analytical control revealed MA with haemoglobin (Hb) of 2.1 g/dL. Peripheral blood smear showed marked anisopoikilocytosis, vitamin B12 and folic acid assays confirmed deficiency, Coombs test and reticulocyte determination were performed and the patient received red blood transfusion (3 units) and began supplementation. After Hb stabilization (5-6 g/dL), she was transferred to the Internal Medicine ward in order to continue etiologic study and further stabilization. On the day of discharge, the patients' close friend revealed that the she was living with her 11-year-old daughter in complete social isolation, marked anxiety (towards her ex-husband), presented severe hoarding behaviour and refused help for basic life care. The patient was discharged with anti-depressive and anxiolytic medication and went to live with her mother. Five months after, the patient recovered (Hb of 12 g/dL), regained weight and is now moving back to her house with her daughter.

Discussion

This case aims to demonstrate the importance of clinical suspicion and external information, that allowed to diagnose a case of severe anaemia and an unusual psychiatric pathology in a patient presenting with unrelated complaints.



CARDIOVASCULAR DISEASES

#13 - Abstract

BNP-PESI CORRELATION. BINDEX STUDY: COMPARATIVE ANALYSIS WITH STUDENT TEST FOR CONTINUOUS VARIABLES IN 30 PATIENTS WITH VENOUS TROMBOEMBOLISM. TRIENNIAL EXPERIENCE (2016-2018)

Maurizio Maria Ciammaichella

St. John's Hospital, Rome, Italy

Background

The BINDEX study, acronym resulting from "Brain natriuretic peptide – pulmoNary embolism severity inDEX", enrolled 30 patients with venous thromboembolism between the ages of 48 and 82. In all patients, the pre-lysis Pulmonary Embolism Severity Index (PESI) was measured and the pre-lysis BNP was dosed (NV=0-100 pg/ml). A comparative analysis with Student's "t" parametric test was carried out to verify if there is a significant relation between the pre-lysis BNP values and the pre-lysis PESI values.

Methods

The pre-lysis BNP values were compared with the pre-lysis PESI values for the 30 enrolled patients. Therefore, the test calculates the relative value (RV) of the t index to be associated to the differences detected according to the following formula: $t = (M1 - M2) / \sqrt{DS12 / N1 + DS22 / N2}$.

Results

Student's "t" test applied to the 30 patients shows a highly significant correlation ($p < 0.001$) of the two variables in question (pre-lysis BNP and PESI Values) and, thus, not attributable to chance. In fact, the "t" value obtained is 5.58 and the VC (critical value) of "t" for $p = 0.001$ is 3.659 with GL=29.

Conclusion

The "BINDEX" study shows how, in the group of 30 patients with venous thromboembolism (central pulmonary embolism), there is a highly significant correlation between the two variables in question: pre-lysis BNP and pre-lysis PESI. This correlation shows an absolute positive concordance according to Student's comparative analysis "t" test and is an expression, not of casual association, of a strong correlation between the pre-lysis BNP values and the pre-lysis PESI values.

#14 - Abstract

TAPSE-PESI CORRELATION. TAPESI STUDY: COMPARATIVE ANALYSIS WITH STUDENT TESTING FOR CONTINUOUS VARIABLES IN 30 PATIENTS WITH VENOUS TROMBOEMBOLISM. TRIENNIAL EXPERIENCE (2016-2018)

Maurizio Maria Ciammaichella

St. John's Hospital, Rome, Italy

Background

The "TAPESI" study, whose name comes from "TAPSE - Pulmonary Embolism Severity Index", enrolled 30 patients aged between 48 and 82 years with venous thromboembolism hospitalized in Complex Structure Internal Medicine for Emergencies Complex Structure in the period January 2016-December 2018. All patients were subjected to: thoraco-abdominal and pelvic CT with contrast medium; pulmonary angiography with loco-regional fibrinolysis; echocardiography with measurement of pre-lysis Tricuspidal Annular Plane Systolic Excursion (TAPSE) (NV > 2 cm). In all patients, the PESI score was measured pre-lysis and the TAPSE score was also measured pre-lysis (VN > 2 cm).

Methods

In the 30 patients enrolled with central pulmonary embolism the values of TAPSE pre-lysis with the values of PESI pre-lysis in the 30 patients enrolled were examined and compared. The test then calculates the relative value (RV) of the index t to be associated with the difference found using the following formula: $t = (M1 - M2) / \sqrt{DS12 / N1 + DS22 / N2}$.

Results

The Student's "t" test applied to the 30 patients showed a highly significant correlation ($p < 0.001$) of the two variables tested, which therefore cannot be attributed to chance. In fact, the value of "t" obtained is 14.96 and the CV (critical value) of "t" for $p = 0.001$ is 3.659 with GL = 29.

Conclusion

The "TAPESI" study showed that in the group of 30 patients with venous thromboembolism (central pulmonary embolism) there is a highly significant correlation between the two variables considered: TAPSE pre-lysis and PESI pre-lysis.

#40 - Medical Image

JUST HEART FAILURE?

Cristina Lojo, Pedro J. Maese, Isabel Melguizo, Jose Antonio Mira
Hospital Valme, Sevilla, Spain

Clinical summary

A 76-year-old male was admitted due to constitutional syndrome, dyspnea and edema. Examination manifested hypotension, S3 audible, bilateral crackles and bimalleolar edema. Chest radiography shows cardiomegaly and pulmonary congestion. Analytically, renal failure, high natriuretic peptide levels and proteinuria. Abdominal ultrasound was normal. The echocardiography shows concentric left ventricle hypertrophy and advanced diastolic dysfunction (restrictive cardiomyopathy due to infiltrative pathology). Cardiac MRI suggests cardiac amyloidosis. The free chains in urine and plasma are elevated (expense of lambda chains). We performed a rectal mucosa biopsy positive for Congo red staining and bone marrow aspirate that confirms the diagnosis of multiple light chain myeloma and therefore primary amyloidosis.

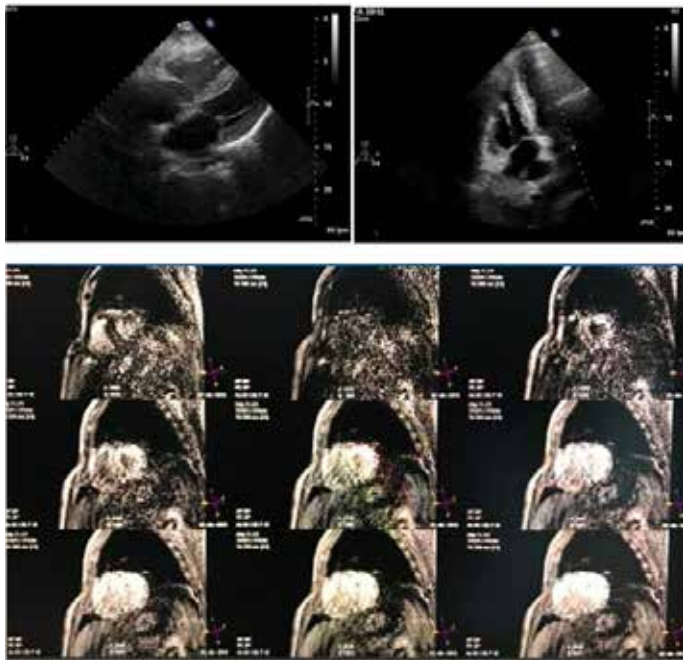


Figure #40.

#64 - Abstract

IMPACT OF PRETREATMENT WITH ACETYLSALICYLIC ACID ON THE SEVERITY OF A FIRST MYOCARDIAL INFARCTION

Ana Rita Moura, Mariana Saraiva, Nuno Craveiro, Maria João Vieira, Kevin Domingues, Vitor Martins
Hospital Distrital de Santarém, Santarém, Portugal

Background

Guidelines on the use of acetylsalicylic acid (ASA) for primary prevention of cardiovascular disease (CVD) are conflicting and

a reflection of no robust evidence accounting for unequivocal favourable benefit-to-risk balance of its use. An eventual advantage of ASA in reducing the severity and prognostic impact of a first episode of acute myocardial infarction (AMI) could be seen has an additional argument for the use of ASA in primary prevention. The present study aimed to evaluate the influence of ASA on the presentation, severity and in-hospital prognosis of AMI in patients without history of CVD.

Methods

Retrospective study based on the analysis of patients without previous evidence of CVD that were diagnosed with type 1 AMI in a district hospital between January 2016 and December 2017. The analysis was dichotomized according to whether or not patients were taking ASA previous to the event. The following endpoints were evaluated: type of AMI, angor refractoriness, maximal troponin, ejection fraction (EF), coronary grade flow (TIMI score), arrhythmic and mechanical complications, and in-hospital death.

Results

The study was accomplished for a total of 150 patients with a mean age of 71.6 ± 9.5 years, of which 71.3% were male. The group of patients that was receiving ASA (16.7%) was significantly older and had a higher prevalence of hypertension (96.0% vs 72.5%, $p=0.01$), and diabetes (68.0% vs. 29.2%, $p < 0.001$). Regarding the endpoints studied, in the group of patients taking the drug there was a lower prevalence of AMI with ST segment elevation (24.0% vs. 36.7%, $p=0.26$), lower prevalence of refractory angor (4.0% vs. 11.7%, $p=0.46$), a lower troponin elevation (7065 vs. 33412.0, $p=0.78$), a higher median EF (55.2 ± 3.5 vs. 47.5 ± 6.3 , $p=0.52$), less cases with TIMI score 0 or 1 (40.0% vs. 60.0%; $p=0.79$), lower complication rates (4.0% vs. 7.6%, $p=1$) and less in-hospital death (0% vs. 1.7%). However, none of the observations was associated with statistical significance.

Conclusion

The present study revealed that, although statistical significance was not reached, prior use of ASA to a first AMI was associated with a better profile of different parameters reflecting the extent and severity of the event. Adequately powered trials are needed to evaluate the relevance of these findings.

#71 - Abstract

INCREASED BETA BLOCKERS AND STATINS AND DECREASED CYTOPROTECTORS IN MYOCARDIAL INFARCTION: A COMPARISON OF HOSPITAL DRUG USE IN 2013 AND 2018

Ainagul Sarsenova, Lazzat Zhamaliyeva, Damira Zhamankulova
West Kazakhstan Marat Ospanov State Medical University, Aktobe, Kazakhstan

Background

Mortality from acute myocardial infarction (AMI) in Kazakhstan

remains high. In 2014, 2016 and 2017, in Kazakhstan, the clinical guidelines and standards on improving care for patients with AMI were updated. The aim of the study was to compare drug prescriptions for patients with AMI before and after the intervention.

Methods

The inpatient data of all patients with AMI who were discharged in 2013 (n=169) and 2018 (n=168) from the Medical University Clinic of Aktobe (Kazakhstan) were used.

Results

The average age of patients was 65.8 (13.4) and 63.7 (11.6), $p = 0.18$, in 2013 and 2018 respectively. The proportion of men was 72% (95% CI 65-79) and 77.4% (95% CI 71-84), presence of arterial hypertension was 76.3% (95% CI 70-83) and 84.5% (95% CI 79-90) in 2013 and 2018 respectively. A statistically significant reduction of trimetazidine from 53.8% (95% CI 46-61) in 2013 to 17.2% (95% CI 11-23) in 2018 and meldonium from 24.4% (95% CI 18-31) to 1.79% (95% CI 0-4) was revealed. At the same time, an increase in beta-blocker prescriptions was detected from 62.7% (95% CI 55-70) to 99.4% (95% CI 98-100), statins from 4.6% (95% CI 1-8) up to 100%.

Conclusion

The practice of drug therapy of AMI has changed significantly over 5 years, from 2013 to 2018. Highly effective drugs were used to all patients. Cytoprotectors with unproven effectiveness have almost completely ceased to be used.

#73 - Abstract

RISK FACTORS FOR CHRONIC THROMBOEMBOLI AFTER PULMONARY THROMBOEMBOLISM

Nuno Leal, Andreia Freitas, José Ribeiro Almeida, Marta Sousa
Centro Hospitalar de Vila Nova de Gaia/Espinho, Vila Nova De Gaia,
Portugal

Background

After an acute pulmonary embolism (PE) most of the thromboemboli achieve complete resolution. However, a significant proportion of patients will present chronic residual thromboemboli with an increasing risk of chronic thromboembolic pulmonary hypertension (CTPH) that can be as high as 4%.

The need for the definition of risk factors for residual thromboemboli is of uttermost importance for future prediction models of prognosis that identify patients with higher risk of CTPH.

Methods

We included all patients with PE followed in "Internal Medicine "Thromboembolism" consultation who were taking oral anticoagulants and presented Computerized Tomography

Angiography (CTA) or Ventilation/Perfusion Scintigraphy (VPS) performed at least 3 months after diagnosis.

Data were collected by consulting the computerized clinical process and were stored and treated statistically using IBM SPSS Statistics 25 software.

Results

In this study 148 subjects were included. Complete clearance of thrombi occurred in 92 (62.2%) and residual thrombi remained in 56 (37.8%) patients.

There was no association between history of cancer, trauma, hormonal therapy and oral contraceptives, pregnancy, smoker status and obesity, at diagnosis, and chronic residual thrombi.

There was a statistically significant association between chronic residual thrombi and previous history of thromboembolic event ($p < 0.05$; OR 3.12, CI 95%) and also presence of pulmonary infarction on the first diagnostic imaging study ($p < 0.05$; OR 1.98, CI 95%).

Conclusion

Despite anticoagulation, the presence of residual thrombi at least 3 months after PE was 37.8% using CTA and/or VPS. This percentage was reported to be between 20 to 30% in previous studies, although most of them used only CTA. The exact magnitude of residual thrombi as a factor of increased risk of CTPH is yet to be clearly defined.

We concluded that pulmonary infarction and previous thromboembolic event was positively associated with chronic thrombi.

#74 - Abstract

DAYLIGHT SAVING TIME TRANSITIONS AND CIRCULATORY DEATHS: A STUDY IN THE VENETO REGION OF ITALY

Roberto Manfredini¹, Rosaria Cappadona¹, Fabio Fabbian¹, Alfredo De Giorgi¹, Giulia Capodaglio², Ugo Fedeli²

¹ University of Ferrara, Ferrara, Italy

² Epidemiological Department, Veneto region, Padua, Italy

Background

Janszky & Ljung (N Engl J Med 2008) first reported an association between daylight saving time (DST) transitions and an increased frequency of acute myocardial infarction (AMI).

Methods

We performed a retrospective analysis on the archive of mortality records of the Veneto Region of Italy ($\approx 4,900,000$ inhabitants) from January 2000 to December 2015. Deaths were classified according to ICD-9 and ICD-10 broad categories used in standard reports of mortality statistics. The number of deaths observed in each of the 7 days after the spring and the autumn shift (post-transitional weeks) was compared with the mean number of deaths registered in the corresponding week-day of the 2 weeks

before and the 2 weeks after the post-transitional week (reference period).

Results

A total of 10,387 circulatory deaths were registered in the Spring and Autumn post-transitional weeks through study period. No overall excess mortality was found in the post-transitional weeks with respect to the reference period in both Spring and Autumn. When analyzing the day-of-week pattern of mortality, a statistically significant excess of deaths was registered on Tuesday only in the Spring ($p=0.011$), but not in the Autumn post-transitional week.

Conclusions

In agreement with previous studies on AMI and stroke, a significant excess of death was observed on Tuesday, only after the Spring shift. Phase advance, sleep deprivation and disruption of circadian rhythms could play a role. A proposal by European Commission of discontinuing seasonal changes of time is now pending at the European Parliament.

#75 - Abstract

DAYLIGHT SAVING TIME TRANSITIONS AND ACUTE MYOCARDIAL INFARCTION: A META-ANALYSIS OF THE AVAILABLE EVIDENCE

Roberto Manfredini¹, Fabio Fabbian¹, Rosaria Cappadona¹, Alfredo De Giorgi¹, Maria Elena Flacco², Lamberto Manzoli¹

¹ University of Ferrara, Ferrara, Italy

² Regional Healthcare Agency of Abruzzo, Pescara, Italy

Background

After the first observation by Janszky & Ljung (N Engl J Med 2008), it has been debated whether daylight saving time (DST) transitions could be associated with a higher frequency of acute myocardial infarction (AMI). We performed the first meta-analysis aimed at evaluating the risk of AMI following DST transitions.

Methods

We searched cohort or case-control studies evaluating the incidence of AMI, among adults, during the weeks following spring and/or autumn DST shifts, versus control periods. A summary odds ratio of AMI was computed after: (1) spring, (2) autumn, or (3) both transitions considered together. Meta-analyses were stratified by gender and age.

Results

Seven studies from five countries (Sweden, United States, Croatia, Finland, Germany) were included in the analyses, and total population was >115,000 subjects. A significantly higher risk of AMI (Odds Ratio [OR]: 1.03; 95% CI: 1.01-1.06) was observed during the two weeks following spring or autumn DST transitions. However, although AMI risk increased significantly after the spring shift (OR: 1.05; 1.02-1.07), the incidence of AMI during the

week after winter DST transition was comparable with control periods (OR 1.01; 0.98-1.04). No differences were observed by age or gender.

Conclusion

A modest, but significant, increase in the risk of AMI is confirmed after DST transitions, particularly after the Spring shift, regardless of gender and age. Disruption of circadian rhythms and even mild sleep deprivation secondary to phase advance may be potential underlying factors. These findings, which require additional evidence, may support the European Commission proposal of DST shifts discontinuation.

#99 - Abstract

CARDIOVASCULAR RISK FACTORS IN PATIENTS WITH ACUTE HEART FAILURE IN AN INTERNAL MEDICINE SERVICE DURING A YEAR

Rita Reis Correia, Fabia Cruz, Pedro Leite Vieira, Sandra Martin, Maria Eugenia André

Amato Lusitano Hospital, Castelo Branco, Portugal

Background and Aim

The onset of Heart Failure (HF) may be delayed or aggravation prevented with modifying risk factors. Almost all these factors are the same for cardiovascular risk. For example: the control of hypertension will delay the onset of HF and reduce mortality; Statins reduce the rate of cardiovascular events and mortality; there is also reasonable evidence that they prevent or delay the onset of HF. This study aims at characterizing the prevalence of cardiovascular risk factors in patients with acute HF in an Internal Medicine Service (IMS).

Methods

A prospective, cross-sectional, observational study of hospitalized patients diagnosed with acute HF in an IMS, April 2017 to April 2018. On admission, the degree of HF was assessed by the NYHA scale. The presence of cardiovascular risk factors and cardiovascular disease (CVD) was evaluated. Transthoracic echocardiography was performed to evaluate left ventricular ejection fraction (EF). Patients in palliative care were excluded. Analysis was performed by SPSS.

Results

118 patients were included (59.3% women, average of 84±7.9 years old). 84.6% in III and IV classes of NYHA. 60.5% with preserved HF. The average of BNP at entrance was 803±797µg/dL. The average hospitalization time was 12±15.4 days.

Cardiovascular risk factors: 47.5% with dyslipidemia; 39.6% with diabetes mellitus; 70.3% with hypertension and 15.3% with chronic kidney disease. On average the sample presented two risk factors.

39% presented CVD (stroke or ischemic heart disease). The CVD

correlates with mortality ($p < 0.05$). The patient with cardiovascular disease presented lower EF (48.6% vs 55.2%; $p = 0.05$).

The average of high-density lipoprotein cholesterol (HDL) was 38.3 ± 13 mg/dL; low density lipoprotein cholesterol (LDL) was 71.7 ± 30.7 mg/dL; triglycerides was 108.7 ± 61.6 mg/dL.

Regarding the patients with dyslipidemia history, 78.6% were on medication with statins that presented lower lipid profile: total cholesterol (118 ± 34 vs 178.5 ± 43 , $p = 0.01$), LDL (61.7 ± 30 vs 101 ± 28 , $p < 0.05$), triglycerides (97.89 ± 40.6 vs 177 ± 114 , $p < 0.01$).

Conclusion

The presence of CVD is an important factor of severe heart failure and mortality in our sample. The importance and efficiency of the use of statins in the control of the lipid profile was thus verified. The control and prevention of cardiovascular risk factors are of great importance in patients with HF to minimize their onset and progression.

#100 - Abstract

IRON DEFICIENCY IN PATIENTS WITH ACUTE HEART FAILURE IN AN INTERNAL MEDICINE SERVICE DURING A YEAR.

Rita Reis Correia, Fabia Cruz, Pedro Leite Vieira, Sandra Martin, Maria Eugenia André

Amato Lusitano Hospital, Castelo Branco, Portugal

Background

Iron deficiency (ID) is the leading cause of anemia in patients with heart failure (HF). Several studies have demonstrated that ID is an independent factor of poor prognosis in HF (without anemia). This study aims at characterizing the prevalence of anemia and ID in hospitalized patients with acute HF in an Internal Medicine Service (IMS).

Methods

A prospective, cross-sectional, observational study of hospitalized patients diagnosed with acute HF in an IMS, April 2017 to April 2018. On admission, the degree of HF was assessed by the NYHA scale. The presence of comorbidities was evaluated. The presence of anemia (hemoglobin $\text{♀} < 12$ g/dL and $\text{♂} < 13$ g/dL), ferropenia (serum iron < 40 $\mu\text{g/dL}$, ferritin < 15 ng/mL or transferrin saturation $< 20\%$) was checked. Transthoracic echocardiography was performed to evaluate left ventricular ejection fraction (EF). Patients in palliative care were excluded. Analysis was performed by SPSS.

Results

118 patients were included (59.3% women, average of 84 ± 7.9 years old). 84.6% in III and IV classes of NYHA. 60.5% with preserved HF. The average of BNP at entrance was 803 ± 797 $\mu\text{g/dL}$. The average of hospitalization time was 12 ± 15.4 days.

Most frequent comorbidities: atrial fibrillation (78.8%), hypertension (70.3%) and diabetes mellitus (39%). On average,

they presented 3 comorbidities.

Anemia was present in 37.1% of men and 66.7% of women. The average of serum iron was 54 ± 45 $\mu\text{g/dL}$, ferritin was 265.7 ± 293 ng/mL and transferrin saturation $19 \pm 16.3\%$. The iron deficiency was present in 52.7% of the sample.

There was an association between anemia and iron deficiency ($p < 0.05$). The patient with ferropenia presented lower hemoglobin (11 vs 12.2 g/dL; $p < 0.05$).

Lower transferrin saturation had reduced ejection fraction and a class III or IV NYHA ($p < 0.05$). Iron serum and transferrin saturation correlated inversely with mortality ($p < 0.05$).

Conclusion

Iron deficiency was the most frequent cause of anemia in our sample. The lower transferrin saturation and iron serum correlated with the mortality regardless of the presence of anemia. As such, the results are in agreement with the current literature showing the importance of measuring iron deficiency with or without anemia.

#109 - Case Report

YOUNG WOMAN WITH CHEST PAIN

Neuza Soares, Ana Cunha, Francisco Ferrão, Maria Majob, Clara Gomes, Fernando Friões

Centro Hospitalar São João, Porto, Portugal

Introduction

Prinzmetal's angina (PA) is a temporary increase in coronary vascular tone (vasospasm) causing a marked, but transient reduction in luminal diameter. Patients are predominantly younger women who may not have the classical cardiovascular risk factors. However, smoking is one of the major risk factors for coronary spasm.

Case description

The authors describe a case of a 40-year-old woman, smoker, with a history of recurrent episodes of breathlessness and chest pain for the past 20 days. These episodes would occur randomly at rest, especially late at night, thereby waking up the patient. In the emergency department, she was conscious, normotensive and normocardic. The electrocardiography showed a heart rate at 61 bpm and ST-segment depression was noticed in V3, V4, V5 and V6. Echocardiography showed areas of hypokinetic middle apical on the anterior and lateral walls. The troponin I level was 0.139 $\mu\text{g/L}$. She did treatment with AAS 300 mg, ticagrelor 90 mg and low-molecular-weight heparin 1mg/kg and she was admitted in intermediate care unit. On the next day, she received cardiac catheterization that ruled out coronary artery disease. Cardiac resonance was also unchanged. However, chest pain returned and cardiac catheterization was repeated. Once again, even with no coronary artery disease, a significant increase in caliber after intracoronary nitrates had revealed. The symptoms disappeared gradually with up-titration of a calcium channel blocker and a nitrate.

Discussion

The provocative test is not firmly established. Most patients with PA respond to medical management with nitrates and calcium channel blockers, with dramatic improvement in their symptoms. Our patient also improved with medical management. Patients with medically refractory symptoms and those who have organic stenosis on coronary angiogram can be treated with intracoronary stenting of the vasospastic segment.

#111 - Case Report

AMYLOIDOSIS AND CARDIAC MAGNETIC RESONANCE

Filipa Lucas¹, Miguel Alves², Fredo Renato Roberto¹, Ana Teresa Boquinhas¹, Carolina Spulveda¹

¹ Hospital de Cascais, Cascais, Portugal

² ULS Nordeste, Bragança, Portugal

Introduction

Advances in cardiac imaging, especially with cardiac magnetic resonance (CMR) may provide a method for evaluation of cardiac involvement and have resulted in greater recognition of light-chain (AL) cardiac amyloidosis in everyday clinical practice.

AL amyloidosis is a rare and multisystem disease characterized by deposition of misfolded immunoglobulin light chain (LC) in the heart, that causes a restrictive cardiomyopathy.

Case description

We describe the case of a 50-year-old melanodermic male that is followed at our Hospital with AL amyloidosis diagnosed since 2016, with renal and cardiac involvement. He has also a medical history of heart failure (NYHA II-III) with chronic pleural and pericardial effusions, 1st-degree atrioventricular block; nephrotic syndrome; α -sickle cell carrier; monoclonal gammopathy IgG lambda and bilateral pulmonary embolism (2016), chronically medicated with bisoprolol, torasemide, ivabradine, spironolactone, and rivaroxaban. At the time of diagnosis, the echo showed left ventricular hypertrophy with moderately impaired function and typical apical sparing. A CMR demonstrated pleural and pericardial effusions; diffuse subendocardial staining pattern and remarkable difficult “nulling” of the myocardium of the left ventricle after gadolinium administration. An abdominal biopsy was positive for amyloidosis. He underwent 4 CyBorD cycles and bortezomib support therapy, with complete remission. In the last consultation, June 2018, the echo showed a moderately decreased of the left and the right ventricular function and blood and urine tests with NT-pro BNP of 4048 ng/l, hsTnTc 30 ng/L and albuminuria 0.58 g/day with MDRDd 64ml/min.

Discussion

Improved medical recognition is necessary for earlier diagnosis and treatment and prompt outcomes. Ventricular hypertrophy or heart failure without a known case maybe the first red flag for cardiac amyloid fibril infiltration and CMR should be considered.

The CMR analyses heart structure, ventricular volumes and function and is useful in distinguishing ventricular wall thickening as a result of amyloid infiltration. Late gadolinium enhancement adds a unique advantage in evaluating myocardial tissue characterization. T1 mapping can also measure the amyloid burden and the myocyte response to infiltration with advantages for tracking change during therapy. To sum up, CMR is a non-invasive exam that overcomes cardiac biopsy and delayed hyper-enhancement imaging may lead to the development of new classification and prognostic systems.

#121 - Case Report

A 39 YEARS WOMAN WITH SUDDEN HEART FAILURE AFTER PARTUM

Nuno Vieira E Brito, Ricardo Taborda, Paula Alcantara

Centro Hospitalar de Lisboa Norte, Lisboa, Portugal

Introduction

Postpartum cardiomyopathy is a rare condition of unclear origin affecting woman at the late stages of pregnancy of up to 6 months after partum. This condition is often diagnosed late due to variable clinical manifestations and a heart disease that may not be suspected at first, since some symptoms are similar to those caused by pregnancy.

Case description

A 39-year-old African ascendancy female was admitted to the emergency department due to shortness of breath, lower limb edema and fatigue a week after childbirth. She was previously healthy with no relevant medical history with two other healthy children aged 6 and 8 and had a monitored pregnancy. At presentation she was dyspneic with 87% saturation, crackles in both lungs and edema of lower limbs. Her laboratory test showed anemia of 11.2 g/dL a low erythrocyte sedimentation rate, positive D-dimer and an elevation of the NT-proBNP. Due to her recent pregnancy state and partum a chest CT was conducted which excluded the presence of embolism and showed signs of lung stasis and a small pleural effusion. The echocardiography showed a reduced ejection fraction of 39% (by Simpson 4 chambers) with a hypokinetic left ventricle and signs of left heart dilation. She showed no signs of infection had a negative troponin level, serologies for common agents of cardiomyopathy were negative and while she had a positive ANA screening the titer was low and a repeat measure months after was negative relating the value to the short time after pregnancy and delivery. She was immediately started with heart failure therapy with diuretics, spironolactone, beta blocker and later sacubitril with valsartan was indicated due to the maintenance of symptoms with an improvement in NYHA score from III to II. Eight weeks after diagnosis and maintaining therapy with entresto, a new evaluation was performed showing an improved ejection fraction of 55% with no hypokinesia a normalization of NT-proBNP and a NYHA class of I.

Discussion

This case shows a remarkable improvement of a rare serious condition with a normal bad prognosis using the new heart failure modulation therapies. In this case the recuperation of the patient requires constant monitoring as not only can this condition reappear but the long term management of this patients is still unknown and there are no studies using this new class of drugs in these patients or its impact on long term survival and quality of life.

#122 - Abstract

MANAGING RISK OF CONTRAST INDUCED NEPHROPATHY (CIN) FOLLOWING CORONARY ANGIOGRAPHY

Laura Virginia Gonzalez, Jessica Abbey

Great Western Hospital, Swindon, United Kingdom

Background

CIN is a iatrogenic renal injury following administration of intra-vascular radio-opaque contrast media. It is classed as a 25% increase in serum creatinine within 72 hours of contrast exposure. CIN accounts for one third of all hospital-acquired acute kidney injuries. It affects up to 50% of high risk sub-groups following angiography or PCI.

NICE and the European Society of Cardiology (ESC) guidelines recommend to assess the risk of acute kidney injury before offering iodinated contrast agents to adults for emergency or non emergency imaging.

There is a stratification risk according to risk factors: hypotension, IABP, CHF, anaemia, DM, contrast media volume, age>75, serum creatinine >1.5mg/dl or GFR<60ml/min.

The ESC guidelines recommend in each category to reduce the risk of AKI :

Low risk (oral hydration,

Moderate/high risk->alternative imaging, IV hydration pre/post procedure, discontinuation of nephrotoxic drugs, lowest volume of contrast, repeat renal function at 48-72 hours. If necessary treat AKI as per guidelines.

Methods

Retrospective review of 40 patients that had PCI between 12/10/18 – 04/01/19 in our hospital, with the intention to analyse the assessment of risk score and prevention measures taken before having coronary angiogram, as well as the assessment of renal function 48-72 hours later.

Results

18 female, 22 male. Age: 49-92.

Wards: 18 from cardiology, 22 from other medical wards.

CIN risk score:

25/40 patients were low risk for CIN (score ≤ 5)

10/40 scored moderate risk (score 6-10)

5/40 scored high risk (score 11-16)

We were unable to ascertain if nephrotoxic medications were held before procedure or if the contrast volume used was reduced.

Fluid administration:

In the Moderate/High risk (15)

Only 1 patient had IV fluid management as per recommended guidelines. Three had 500ml N. Saline in the Cath lab and 11 patients had no IV fluids pre or post procedure.

Renal function assessment:

- 17/40 had no post-procedure U&Es. From this group, three were high risk, four moderate risk and 10 low risk.
- 9/23 who had U&Es only had them done at 24 hours (before the recommended 48 – 72hrs).

Conclusion

Many of the patients with moderate/high risk score did not receive the recommended hydration, and, even worse, the renal function was not properly measured at 48-72 hours post procedure.

Actions:

To create a protocol for all patients going for c. angiogram, and facilitate the assessment of renal function in ambulatory care if necessary.

Discussion with Cardiologist in progress.

#127 - Case Report

CRITICAL UPPER LIMB ISCHEMIA: AN UNUSUAL PRESENTATION OF EXTRACRANIAL GIANT CELL ARTERITIS

Katalin Mako, Eموke Horvath

University of Medicine and Pharmacy Targu Mures, Targu Mures, Romania

Introduction

Aiming to emphasize the emerging role of Doppler ultrasound in the diagnostic work-up of extracranial presentation of giant cell vasculitis we report the case of a 70-year-old female, who presented unilateral critical upper limb ischemia.

Case description

The patient presented severe rest pain at the left arm limb, coldness, pallor and paresthesia of the left hand. Due to the age and presence of cardiovascular risk factors, atherosclerotic peripheral upper limb arterial disease would have been the most likely diagnosis in this case but the color Doppler ultrasound of the upper limbs revealed severe left axillary arterial stenosis with hypoechoic wall swelling being highly suggestive for arteritis. Temporal artery ultrasound demonstrated occlusion in right side and was suggestive for arteritis in left side; biopsy was performed and confirmed giant cell arteritis. An excellent clinical response was obtained two weeks after initiation of treatment with systemic corticosteroids.

Discussion

Upper limb arterial ultrasound is a simple and quick examination and provides characteristic findings in extracranial giant cell

arteritis and in disease monitoring. The routine use of this method in patients with arm pain or weakness and the fact that atypical localizations of disease are common leads to fewer delayed or missed diagnosis.

#128 - Abstract

INFLUENCE OF STATINS USED IN THE CONTEXT OF PRIMARY PREVENTION ON THE SEVERITY OF A FIRST ACUTE MYOCARDIAL INFARCTION

Ana Rita Moura¹, Mariana Saraiva², Nuno Craveiro², Maria João Vieira², Kevin Domingues², Vítor Martins²

¹ Hospital Distrital de Santarém, Gondomar, Portugal

² Hospital Distrital de Santarém, Santarém, Portugal

Background

Statins role in primary prevention of cardiovascular disease (CVD) is not well-established. An eventual advantage of statins in reducing the severity of a first episode of acute myocardial infarction (AMI) could be seen has an additional argument for its use in primary prevention in high risk patients. The present study aimed to evaluate the influence of the use of previous statin in the form of presentation, severity and short-term prognosis of AMI in patients without history of CVD.

Methods

Retrospective study based on the analysis of patients without previous evidence of CVD that were diagnosed with type 1 AMI in a district hospital between January 2016 and December 2017. The analysis was dichotomized according to whether or not patients were taking statin before the event. The following endpoints were evaluated: type of AMI, angor refractoriness, maximal troponin, leukocytes and C-reactive protein (CRP), ejection fraction (EF), coronary grade flow (TIMI score), number of coronary arteries with significant disease, arrhythmic and mechanical complications, and in-hospital death.

Results

The study was accomplished for a total of 145 patients with a mean age of 70.9 ± 8.7 years. The group of patients that was receiving statin (20.7%) was significantly older and had a higher prevalence of dyslipidemia (83.3% vs 47.0%, $p < 0.001$), and diabetes (53.3% vs. 31.3%, $p = 0.03$). Regarding the endpoints studied, in the group of patients taking the drug there was a lower prevalence of AMI with ST segment elevation (26.7% vs. 37.4%, $p = 0.27$) and refractory angor (3.3% vs. 12.2%); a lower maximum troponin (8958 vs. 28121, $p = 0.56$), leukocytes count (8666.7 vs. 11266.7; $p = 0.69$) and CPR (2.06 vs. 2.52; $p = 0.76$). It was also seen an higher median EF (54.0 vs. 49.0; $p = 0.67$), less cases with culprit lesion with TIMI score ≤ 1 (25.0% vs. 47.8%; $p = 0.06$), lower number of coronary arteries with significant disease (50% vs. 53%) and lower complication rates (0% vs. 8.7%, $p = 0.12$). Those results did not have an impact on the in-hospital mortality rate which was

higher in patients taking the drug (1.7% vs. 0%; $p = 0.37$). None of the results was associated with statistical significance.

Conclusion

This study revealed that, although statistical significance was not reached, use of statin prior to a first AMI was associated with a better profile of different parameters reflecting the extent and severity of the event. Adequately powered trials are needed to evaluate the relevance of these findings.

#129 - Medical Image

COMPLICATED ACUTE MYOCARDIAL INFARCTION - A DOUBLE TROUBLE

Ana Rita Moura¹, Mariana Saraiva¹, Maria João Vieira¹, Miguel Alves¹, Álvaro Laranjeira², Luz Pitta³

¹ Hospital Distrital de Santarém, Santarém, Portugal

² Centro Hospitalar de Lisboa Central, EPE / Hospital de Santa Marta, Lisboa, Portugal

³ Hospital Distrital de Santarém, Santarém, Portugal

Clinical summary

Women, 67-year old, caucasian. Previous history of arterial hypertension controlled with captopril 50mg id and amlodipine 5mg plus valsartan 80mg id. She presented to the emergency department with persistent precordial pain radiating to the left arm and shoulder and dyspnea at rest. At examination she was hemodynamically stable initially but with sudden evolution to hypotension; lung auscultation revealed diffuse wheezing and bibasal crackles. No clear heart murmurs. Enlarged neck veins were seen but no peripheral edema. Electrocardiogram showed ST segment elevation in DIII and aVF and diffuse ST segment depression in V2-V6, DI, aVL. Echocardiogram showed severe mitral regurgitation in the context of papillary muscle rupture. Cardiac catheterization revealed right coronary artery occlusion.

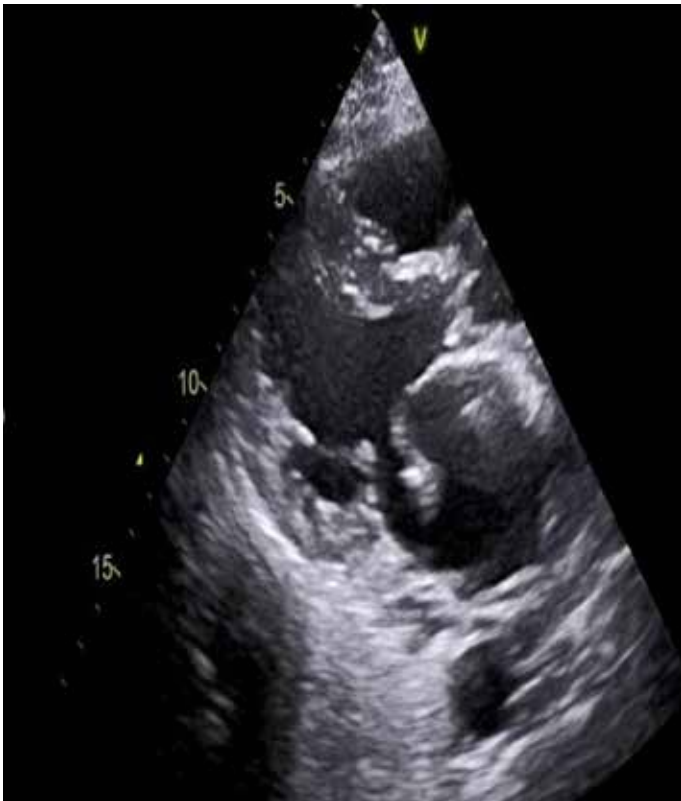

Figure #129. Parasternal long axis view.

#133 - Abstract

IS HEART FAILURE ASSOCIATED WITH HIGH LEVEL OF VISCERAL ADIPOSITY INDEX?

Sakir Ozgur Keskek, Nuri Aslanoglu

Adana City Training and Research Hospital, Adana, Turkey

Background

The Visceral Adiposity Index (VAI), which is an empiric mathematical model, is indicative of fat distribution and function in human body. It is based on body mass index (BMI), waist circumference (WC), triglycerides (TG) and HDL cholesterol levels. The aim of this study was to investigate the level of VAI in patients with heart failure.

Methods

A total of 58 subjects from both genders, with a minimum age of 18 years old, were included in this case control study. The study group was comprised of 26 patients with heart failure and the control group was comprised of 32 healthy subjects. Patients with a diagnosis of chronic disease other than heart failure were excluded. Ejection fraction percentages (EF), BMI, WC, triglyceride and HDL cholesterol levels of all subjects were recorded. The VAI was calculated by $(WC/(39.68+(1.88*BMI)))*(TG/1.03)*(1.31/HDL)$ for males and $VAI = (WC/(36.58+(1.89*BMI)))*(TG/0.81)*(1.52/HDL)$ for females. The MedCalc V17.4 software (Belgium) was used for all statistical analyses. T test or Mann Whitney U test was used for the comparison of the quantitative measurements between the two groups. Chi-square test was used

to test the statistical significance of differences in frequencies.

Results

Groups were matched in terms of age, sex ($p=0.135$ and 0.666 , respectively). There was statistically significant difference between ejection fraction percentages of the groups. Patients with heart failure have lower EF levels (30.8 ± 5.5 vs. 58.4 ± 6.2 , $p<0.001$). The VAI of patients with heart failure was higher than healthy subjects (2.7 ± 2.4 vs. 1.2 ± 0.7 , $p=0.002$).

Conclusion

Visceral adipose tissue is a metabolically active organ and it is an independent risk factor for metabolic alterations and development of cardiovascular diseases. In this study, we have shown high levels of VAI in patients with heart failure. VAI can give an idea about heart failure in various patient populations.

#146 - Medical Image

VARICOSE VEINS

Catarina Carvalho, Rodrigo Rufino, Alexandra Albuquerque, Fátima Campante

Centro Hospitalar Barreiro Montijo, Barreiro, Portugal

Clinical summary

We present an image of varicose veins of an obese male patient, 58 years old in a hemodialysis program, with hypertension admitted in the hospital with the diagnosis of pancreatitis, in need of an intensive care unit.

The varicose veins were previously unknown and this diagnosis was incidental, although the important previous cardiovascular risk.

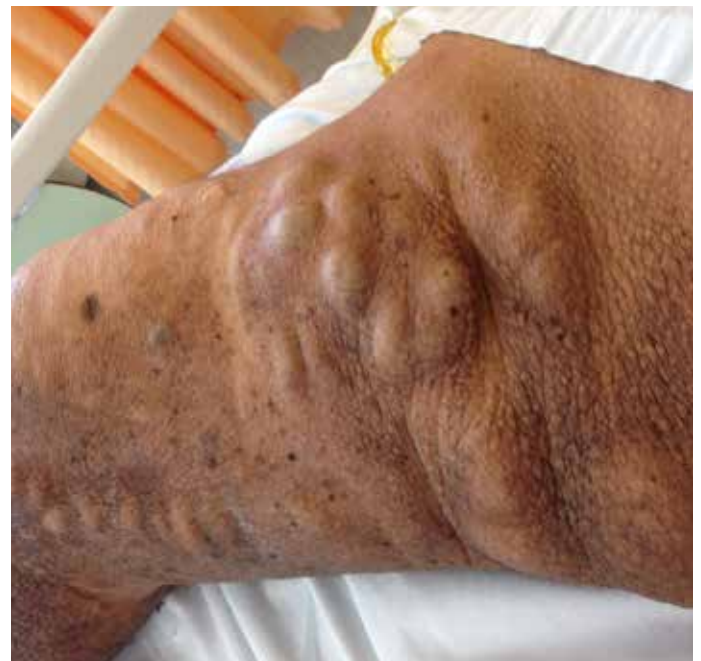

Figure #146. Right thigh.

#150 - Abstract

ATRIAL FIBRILLATION AND STROKE... WHAT WE STILL LACK...

César Matos¹, Rui Marques², Inês Frois Cunha², Ana Filipa Viegas², Margarida Neto³, Ana Gomes²

¹ UCSP Azeitão, Setúbal, Portugal

² Centro Hospitalar Tondela-Viseu, Viseu, Portugal

³ Centro Hospitalar de Setúbal, Setúbal, Portugal

Background

Atrial fibrillation (AF) is a major cause of stroke, with increasing diagnosis and indication for anticoagulation in the majority of the patients. AF, a disease that affects 200,000 Portuguese people, is responsible for one in three strokes. This stroke risk factor is higher than diabetes, hypertension, smoking and sedentarism.

Methods

The study aims a demographic characterization of the population with AF and evaluation of patients with AF with CHA2DS2-VASc \geq 2 who were not under anticoagulation. It was also intended to compare the presence of cardiovascular risk factors among the populations with and without AF as well as to evaluate the differences in mortality in both populations.

Observational and retrospective study of 411 patients hospitalized at the stroke unit in a central hospital in 2017, consulting the SClinico[®] database and statistically analyzed using SPSS[®].

Results

108 patients (26.3%) had previous diagnosis of AF (24 haemorrhagic strokes and 84 ischemic strokes). AF was more prevalent in males in hemorrhagic stroke vs ischemic stroke patients (78.6% vs 53.1%), mean age (79.6 vs 79.3 years) was similar. Among the cardiovascular risk factors (with vs without AF): 24.5% vs 14.3% were diabetics, 71.4% vs 63.3% were hypertensive, 42.8% vs 59.2% had dyslipidemia and with heart failure 30% vs 7%. It was found that in 14.3% hemorrhagic stroke vs 28.6% ischemic stroke, patients did not take antiplatelet or anticoagulant therapy and had a CHA2DS2-VASc \geq 2. In the mean duration of hospitalization in ischemic stroke patients with and without AF 4.6 vs 4.2 days and hemorrhagic stroke with and without AF 9.1 vs 7.2 days. Mortality in this period in ischemic stroke patients with and without AF 14.3% in patients with AF vs 8.7% without AF and in hemorrhagic stroke 28.6% with AF vs 20.4% without AF.

Conclusion

The prevalence of AF accompanies the high rise in life expectancy. There are no differences in cardiovascular risk factors in both populations. The stroke in patients with AF is associated with higher mortality. This study shows the importance of integrated management of AF through a strategy that is based on stroke prevention, symptom management, and risk reduction of comorbidities especially in this age group and more fragile in terms of therapeutic compliance and access to health care.

#154 - Abstract

OBESITY PARADOX IN PATIENTS UNDERGOING PERCUTANEOUS MITRAL VALVE EDGE-TO-EDGE REPAIR USING MITRACLIP[®] PROCEDURE

Karsten Keller^{1,2}, Lukas Hobohm^{1,2}, Martin Geyer², Carl J Lavie³, Thomas Münzel², Ralph Stephan Von Bardeleben²

¹ Center for Thrombosis and Hemostasis (CTH), University Medical Center Mainz (Johannes Gutenberg-University Mainz), Mainz, Germany

² Heart Center Mainz, Center of Cardiology, Cardiology I, University Medical Center Mainz (Johannes Gutenberg-University Mainz), Mainz, Germany

³ Department of Cardiovascular Disease, John Ochsner Heart & Vascular Institute, Ochsner Clinical School, The University of Queensland School of Medicine, New Orleans, United States

Background

Obesity is an important risk factor for cardiovascular diseases (CVD), CVD events and mortality. Despite these negative consequences of obesity on CVD, several studies demonstrated that obese CVD patients had a better prognosis compared to their leaner counterparts, which is called "obesity paradox". The influence of obesity on outcomes of patients with valvular heart diseases (VHD) are sparse.

Mitral regurgitation (MR) is a frequent cause of VHD and an important cause of morbidity and mortality. Patients with severe MR are often referred for surgical or interventional correction. While surgical MR repair is recommended for the majority of patients with severe primary MR (at low surgical risk), transcatheter edge-to-edge valve repair with the MitraClip[®] (Abbott, Menlo Park, CA, USA) for patients at high surgical risk is widely accepted and performed at increasing numbers. We investigated the impact of obesity on adverse in-hospital outcomes in patients with MitraClip[®] implantation.

Methods

We analyzed data on characteristics of patients and in-hospital outcomes for all percutaneous MR repairs using the MitraClip[®] in Germany 2011-2015 stratified for obesity vs. normal-weight/over-weight, excluding patients with rapid weight loss and underweight.

Results

The nationwide inpatient sample included 13,563 inpatients undergoing MitraClip[®] implantations. Among them, 1,017 (7.5%) patients were coded with obesity.

Obese patients were younger (75 vs. 77 years, $P < 0.001$), more often female (45.4% vs. 39.5%, $P < 0.001$), had more often heart failure (87.1% vs. 79.2%, $P < 0.001$) and renal insufficiency (67.0% vs. 56.4%, $P < 0.001$).

Obese and non-obese patients were comparable regarding MACCE and in-hospital death. Adverse in-hospital events (composite outcome of in-hospital death, mechanical ventilation and cardio-pulmonary resuscitation) were more often in non-

obese than in obese patients with a trend towards significance (20.6% vs. 18.2%, $P=0.066$).

Obesity was an independent predictor of reduced adverse in-hospital events (OR 0.75, 95%CI 0.64-0.89, $P<0.001$), but not for reduced mortality ($P=0.355$) and MACCE rate ($P=0.108$). Obesity class III was associated with an elevated risk for pulmonary embolism (OR 5.66, 95%CI 1.35-23.77, $P=0.018$).

Conclusion

We observed an obesity paradox regarding adverse in-hospital events in patients undergoing MitraClip® implantation, but our results failed to confirm an impact of obesity on in-hospital survival or MACCE.

#158 - Abstract

BERBER ETHNIC PATIENTS ADMITTED FOR ACUTE HEART FAILURE IN A CROSS-BORDER HOSPITAL OVER 1 YEAR

Julio Osuna Sánchez¹, Antonio Ubiña Carbonero²

¹ Hospital Comarcal Melilla, Melilla, Spain

² Centro de Salud San Andrés-Torcal, Málaga, Spain

Background

A retrospective descriptive study of Berber ethnic patients admitted for heart failure (HF) in the Internal Medicine service during 2017.

Methods

This is a cross-sectional descriptive analysis of patients admitted to internal medicine for HF in 2017 who were of Berber ethnicity. A detailed study was carried out of all the risk factors presented by the patients, the associated comorbidities, as well as personal history. We have analyzed the discharge reports of our service along with the review of medical records. A descriptive study of the characteristics of patients using frequency measurements was carried out, analyzing the type of sample by seeing whether or not they followed normality.

Results

There were a total of 120 patients hospitalized for HF, of which 50.8% were of Berber ethnicity. 55% were women. The mean age was 73.71 ± 9.74 years. 5% of the patients were institutionalized, 15.8% were dependent for all the basic activities of daily life. 79.2% had social security. Regarding personal history, 25.8% previous ischemic heart disease; 62.5% HBP; 45.8% DM; 34.2% A-fib, 12.5% COPD, 25% dyslipidemia; 5.8% sleep apnea; 10% anemia; previous stroke 6.7% and 9.2% neoplasia (active or not). The most frequent causes of admission were the ischemic cause with 35.4% and the valvulopathy with 33.8%. As an important finding, 8.3% of the patients presented cognitive impairment to some degree. 98.3% of patients had 2 or more pathologies at the time of admission. 21.7% of them had a decreased ejection fraction. The mean stay of hospital admission was 9.88 ± 8.92 days, with 13.3% of patients who died.

Conclusion

The HF is a problem both for public health and for the doctor who must face it every day. Once the prognosis is diagnosed, it becomes ominous, since approximately 50% of patients die within the next 5 years. The diagnosis and early treatment of HF is important to prevent its complications, slow its evolution, reduce its symptoms and avoid the need for hospitalizations once the diagnosis is confirmed. Given our geographical location we have the Berber ethnic group as a reference population, so it was interesting to know how this class of patients was, and create a typical profile of them. Patients admitted for acute heart failure of Berber ethnicity have a multi-pathological profile with multiple diseases that make them patients with a more complicated management in the plant. This is basically due to our geographical location.

#168 - Case Report

A CASE OF AORTIC ROOT ABSCESS AS A COMPLICATION OF ENDOSCOPY

Gregory Offiah, Aine Gorman, Cara Gill, Paul Shiels, Ausaf Mohammad

Midlands Regional Hospital Tullamore, Offaly, Ireland

Introduction

Infective endocarditis (IE) has an incidence of 3-9 per 100,000, with the risk increased by prosthetic heart valves. The in-hospital mortality is 15-22%, with ~40% 5 year mortality. Prevention, recognition and treatment of this potentially life threatening condition are imperative.

Case description

An 81-year-old male presented with melena and hypotension. Past history included aortic valve replacement (AVR), treated with warfarin. On admission, his international normalised ratio was 3.5. Oesophagogastroduodenoscopy (OGD) confirmed an ulcer requiring clipping and the patient was discharged. He represented 6 days later with delirium, cough and fever. His white cell count was $12.6\times 10^9/L$ and C-reactive protein 116 mg/L. He was treated for presumed pneumonia with piperacillin-tazobactam and escalated to meropenem due to persistent pyrexia. Blood cultures (BC) grew enterococcus in one bottle. Two subsequent BC were negative, transthoracic echocardiogram and computed tomography of thorax abdomen and pelvis were normal. Microbiology advised repeat BC two weeks after antibiotics. At this point two sets of BC confirmed enterococcus faecalis, which was highly gentamicin resistant. Transoesophageal echocardiogram and computed tomography angiogram revealed an AVR vegetation and aortic root abscess. He was treated for IE with amoxicillin and referred for a second AVR.

Discussion

8.1% of IE cases are related to endoscopy (gastroscopy - 3.6%). IE is associated with therapeutic OGD in those with cardiac defects. Enterococcus IE is classically associated with

proctosigmoidoscopy. This is the first case describing enterococcus IE post OGD. European Society of Cardiology guidelines do not recommend prophylactic antibiotics for endoscopy. However, this case raises the question of its potential role.

#181 - Case Report

AN IGNORED, ALMOST FATAL, HYPOKALEMIA

Cristina Martins, Diana Gonçalves, Pedro Ribeiro, Armando Carvalho

Centro Hospitalar e Universitário de Coimbra - Hospital Geral, Coimbra, Portugal

Introduction

Hypokalemia is defined as a serum potassium (K) level of less than 3.5 mmol/L. It may result from inadequate K intake, increased K excretion, or a shift of K from the extracellular to the intracellular space, being the second the most frequent cause. When severe (K less than 2.5 mmol/L), it can be a potentially life-threatening imbalance.

Case description

A 60 years old man is admitted to the Intensive Care Unit (ICU), after an episode of cardiac arrest in the Emergency Room (ER), where he presented previously, complaining of progressive muscle weakness and sudden inability to walk. In the ER, he was conscient, but disoriented, hemodynamically stable and afebrile, but with a flaccid tetra-paralysis. While on observation, he progressed into a cardiac arrest. Immediate advanced life support was initiated with successful return of spontaneous circulation. A hypokalemia of 1.5 mmol/L on the blood gas analysis was identified and immediate aggressive correction was initiated. In the ICU, patient's medical history was revised: he had been diagnosed with hypertension (HT) at the age of 40, by his general practitioner; since then he also had persistent hypokalemia (with a mean value of 2.5 mmol/L). No study to exclude secondary HT was made, and the patient was progressively medicated with higher doses of different anti-hypertensive drugs (except for thiazide diuretics), and with oral K tablets. When admitted in the ER, though, he had recently changed his usual prescription and had initiated a high dose thiazide. The hypothesis of a primary hyperaldosteronism was raised and confirmed after dosing of aldosterone plasma levels and plasma renin activity: 340 ng/dL and 0.33 ng/mL/h, with an aldosterone to renin ratio of 1030. Spironolactone and an ACE inhibitor were initiated, with improvement of the patient's HT and K levels. A renal CT was performed revealing a left adrenal adenoma and a right adrenal hyperplasia. After discharge of the ICU, the patient continued his study on the Internal Medicine ward, and was proposed to a left adrenalectomy.

Discussion

The evaluation of a patient with HT depends upon the likely cause and the degree of difficulty in achieving acceptable blood pressure

control. Patients who have clinical clues suggesting the possible presence of secondary HT, like our patient, should undergo a more extensive evaluation. Since it isn't cost effective to exclude secondary HT in every hypertensive patient, it is important to be aware of the clinical clues that may suggest it.

#188 - Abstract

ECHOCARDIOGRAPHIC ASSESSMENT AND CARDIAC BIOMARKERS IN HEMODYNAMICALLY STABLE PATIENTS WITH ACUTE PULMONARY EMBOLISM

João Fernandes Serodio¹, Lígia Pires², Luis Melo¹, Rita Pereira³, Daniel Ferreira³, Nuno Cardim^{3,4}

¹ Department of Internal Medicine IV, Hospital Prof. Doutor Fernando Fonseca, Amadora, Portugal

² Intensive Care Unit, Centro Hospitalar do Algarve, Faro, Portugal

³ Echocardiography Lab, Cardiovascular Centre, Hospital da Luz, Lisboa, Portugal

⁴ Centre for the Study of Chronic Diseases (CEDOC), Nova Medical School Lisboa, Lisboa, Portugal

Background

Acute pulmonary embolism is still associated with significant mortality, morbidity and hospitalization. The role of echocardiography in the diagnosis and management of acute pulmonary embolism in hemodynamically stable patients (APE-HSP) is still uncertain. Our aim was to assess the incidence of echocardiographic signs of right heart overload in acute APE-HSP and to evaluate the performance of cardiac biomarkers to identify right heart strain.

Methods

A retrospective analysis of all APE-HSP hospitalized for acute pulmonary embolism between 2015 and 2017 was performed. All patients underwent transthoracic echocardiography within the first 24h of hospitalization. Several signs of right heart overload were assessed: pulmonary artery systolic pressure (PASP), right ventricle end-diastolic diameter, abnormal septal motion (D-shape), tricuspid annular plane systolic excursion (TAPSE), right ventricle S' wave on tissue Doppler imaging (S'RV) and the presence of right heart thrombus. Laboratory analysis included high-sensitive troponin I and NT-pro brain natriuretic peptide (NT-pro BNP).

Results

The population consisted of 63 patients with median age of 66 years (51-77), 59% female. In this population, 62% of patients presented at least one sign of right heart overload and increased PASP was most frequently found echocardiographic sign (60%). When PASP is excluded from the analysis, up to one third of patients (33%) present with right heart overload. Troponin I was elevated in 32% of cases and NT-pro BNP in 41%. A positive strong correlation was found between troponin I or NT-proBNP and PASP (respectively,

$\rho=0.526$, $p\text{-value}=0.0001$; $\rho=0.547$, $p\text{-value}=0.0003$). TAPSE showed a negative strong correlation with troponin and NT-pro BNP ($\rho=-0.559$, $p\text{-value}=0.0001$; $\rho=-0.577$, $p\text{-value}=0.0002$, respectively). There was a negative correlation between S'RV and NT-proBNP ($\rho=-0.342$, $p\text{-value}=0.0498$).

Conclusion

In conclusion, one third of the patients showed echocardiographic signs of right heart overload, which was similar to the proportion of patients with raised cardiac biomarkers (32% for troponin I and 41% for NT-pro BNP). There was a significant correlation between TAPSE, S'RV or PASP and cardiac biomarkers. Therefore, echocardiography may play an important role in clinical management and risk stratification of APE-HSP.

#199 - Abstract

THE USEFULNESS OF 18F-FDG PET/CT IMAGING IN PATIENTS WITH CARDIAC SARCOIDOSIS

Yutaka Kajikawa, Masae Ikeda, Aki Ueda, Minoru Hirota

National Hospital Organization Fukuyama Medical Center, Fukuyama, Japan

Background

Sarcoidosis is a systemic granulomatous disorder of unknown etiology and can present as a wide variety of clinical courses, depending on the affected organs. Cardiac involvement is often not easy to diagnose, in recent years, newer imaging techniques, such as 18F-FDG PET/CT, have evolved to determine cardiac involvement of sarcoidosis.

The aim of this study was to evaluate the usefulness of 18F-FDG PET/CT in detecting cardiac sarcoidosis.

Methods

We investigated the frequency of organ involvement at the time of diagnosis in 26 patients with sarcoidosis, based on retrospective review of electronic medical records from April 2014 to March 2019.

Results

The study population comprised 8 men (31%) and 18 women (69%), and the average age was 60 ± 16.1 years. Abnormal laboratory findings pertaining to the eye, skin, lungs, and heart were seen in 10 (38.4%), 10 (38.4%), 16 (61.5%), and 6 (23.3%) cases, respectively. Prednisolone treatment was administered in 7 cases (26.9%). The serum levels of angiotensin-converting enzyme and soluble interleukin-2 receptor were 20.4 ± 9.8 U/mL and 565.8 ± 388.0 U/mL, respectively. With regard to the respective electrocardiogram findings, the cardiac sarcoidosis patients (CS group) and the patients with sarcoidosis without cardiac lesion (non-CS group) had similar PQ interval (160.1 ± 27.4 msec vs. 168.7 ± 20.2 msec). Compared with the non-CS group, the CS group had significantly more frequent third degree atrioventricular blocks (2 (33%) vs.

0 (0%), $p < 0.05$). BNP level in the CS group was also higher than that in the non-CS group (290.1 ± 104.4 pg/mL vs. 12.8 ± 12.4 pg/mL, $p < 0.05$). On echocardiography, the intraventricular thickness was less in the CS group than in the non-CS group (4.6 ± 1.7 mm vs. 8.5 ± 1.9 mm, $p < 0.001$). In the CS group, two patients were in the active stage of sarcoidosis, three patients were in the healing or non-active stage of sarcoidosis, and one patient was in the terminal stage of ovarian cancer. 18F-FDG PET/CT imaging was performed on four patients and gallium-67 citrate scintigraphy was performed on three patients. In both cases, 18F-FDG PET/CT was superior to gallium-67 citrate scintigraphy in detecting the cardiac lesion and the activity of sarcoidosis.

Conclusion

This study suggested that 18F-FDG PET/CT can detect both the early and healing stages of cardiac sarcoidosis, in which few perfusion abnormalities and high inflammatory activity are noted before advanced myocardial impairment.

#208 - Abstract

THE HEART OF STROKE - CEREBROVASCULAR RISK ASSESSMENT BASED ON A DESCRIPTIVE ANALYSIS OF 171 PATIENTS

Sara Lopes Fernandes, Rita Ribeiro Carvalho, Luís Graça Santos, Behnam Moradi, Helia Martins, João Morais

Leiria Hospital Center, Leiria, Portugal

Background

Stroke is the leading cause of death in Portugal and it is more frequent in men, aged 65-74 years. The continuum and interrelationship between heart disease and cerebrovascular disease is unquestionable.

Methods

This study presents a descriptive and retrospective analysis of patients with ischemic stroke followed in a Cerebrovascular Risk Consultation, from January 2016 to December 2017.

Results

A total of 171 patients were selected, with a mean age of 65 ± 12 years and 57% males. The main cardiovascular risk factors identified were: arterial hypertension in 142 patients (83%); dyslipidemia in 139 (81%); type 2 diabetes mellitus in 50 (29%), smoking in 39 (23%); alcohol consumption in 32 (19%) and previous cardiovascular events in 43 (25%) cases. Electrocardiographic changes identified atrial fibrillation in 31 patients (18%), 19 of them aged ≥ 70 years, showing the highest prevalence in elderly patients (31%). The Holter records collected in 94 patients showed supraventricular extrasystoles with a trimmed mean of 217 ± 1540 / 24h. Echocardiograms performed on 132 patients revealed septum hypertrophy (> 11 mm) in 89 patients (67%); Left ventricular ejection fraction $< 50\%$ in 9 patients (6.5%) and

left atrium greater than 35 ml/m² in 113 patients (93%). In 10% (n=15) of the cases, a patent foramen ovale was identified, with a higher prevalence among patients ≤ 55 years (n=11, 31%), most of them carrying a thrombophilia gene (85% of patients evaluated).

Conclusion

Patients with ischemic stroke have a high prevalence of cardiovascular risk factors. The results of this series show the rationale and importance for all these patients to be investigated from the cardiac point of view, in order to find out changes in heart rhythm and structural abnormalities, which contribute to a better etiological clarification and help in therapeutic decision.

#220 - Abstract

THE IMPORTANCE OF HEMATOLOGICAL PARAMETERS IN HEART FAILURE PROGNOSIS-EVIDENCE FROM THE REFERENCE STUDY

Mário Barbosa¹, Andreia Matos^{2,3}, Manuel Bicho^{2,3}, Luiz Menezes Falcão^{4,3}

¹ Department of Internal Medicine, Hospital Lusíadas Lisboa, Lisbon, Portugal

² Genetics Laboratory and Environmental Health Institute-ISAMB, Lisbon, Portugal

³ Lisbon Faculty of Medicine, Lisbon, Portugal

⁴ Department of Internal Medicine, Santa Maria Hospital, Lisbon, Portugal

Background

In patients with heart failure (HF), anemia and iron deficiency are predictors of poor long-term outcome.

The purpose of this study was to examine the association of anemia, iron deficiency, and related hematological parameters with early (defined as the period of 90 days post-discharge) rehospitalization due to HF and all-cause mortality, and long-term all-cause mortality in HF patients.

Methods

Anemia, iron deficiency, red cell distribution width (RDW) and erythropoietin (EPO) were assessed in patients hospitalized with acute decompensated heart failure in class III or IV of NYHA to an Internal Medicine ward.

Univariate Cox proportional hazard model was used to assess the relationship between variables and outcomes.

Results

In total, 65 patients were followed for a median of 13.7 (Q1-Q3 6.7-18.9) months. Mean age was 79.2 (SD 10.8) years and 56.9% were female.

The mean left ventricular ejection fraction was 50.38 ± 19.07 %.

Variables associated with an increased risk for early rehospitalization were RDW (hazards ratio [HR] 1.35; 95% confidence interval [CI] 1.16-1.58), anemia (HR 3.81; 95% CI 1.29-11.28), and anemia with iron deficiency (HR 3.50; 95% CI 1.30-9.38).

Increased risk for early mortality was associated with RDW (HR 1.83; 95% CI 1.29-2.59), EPO (HR 1.38; 95% CI 1.04-1.82), absolute iron deficiency (HR 7.22; 95% CI 1.50-34.81), and anemia with iron deficiency (HR 4.48; 95% CI 1.26-15.88).

Variables associated with an increased risk for long-term mortality were RDW (HR 1.31; 95% CI 1.12-1.54) and EPO (HR 1.29; 95% CI 1.11-1.49).

Conclusion

Anemia, iron deficiency, RDW and EPO were associated with early rehospitalization, early mortality, and long-term mortality. Our findings may provide insight into HF prognosis and may raise the interest in some neglected hematological parameters.

#230 - Case Report

LATENT BRUGADA SYNDROME MANIFESTO POSITION WITH PROPAFENONE

Isabel Moreno Lucente, Vanesa Muñoz Mendoza, Letizia Marie Silvie Mournoval Morales, Amalia Inmaculada Fernández Alamán
Hospital Obispo Polanco, Teruel, Spain

Introduction

Brugada syndrome (SBr) is a hereditary cardiac channelopathy with an electrocardiographic morphology similar to that of right bundle branch block. The high incidence of syncope and ventricular arrhythmias suggests that the BrS may be responsible for 5% of the total sudden cardiac death (SCD) and up to 12% of sudden death (SD) in patients without structural heart disease.

Case description

A 79-year-old woman with hypercholesterolemia as the only cardiovascular risk factor, evaluated by the Cardiology service in 1992 for palpitations and a syncopal episode; during the study, Holter of arrhythmias supraventricular extrasystole (ESV) was isolated without episodes of supraventricular tachycardia (SVT) objectivable during the recording. After ruling out structural heart disease, amiodarone was started. After 12 months of treatment, it was discontinued due to subclinical hypothyroidism, starting propafenone. Followed periodic reviews until 1995, being discharged from clinical stability consultations. In 2014, the patient was referred again to consultations for a new syncopal episode. Reinterrogating the patient reports three syncopal episodes from the previous discharge.

The physical examination did not present findings. In the same consultation, an ECG showing supradeslevelization of the ST segment in V1-V2 compatible with the Brugada syndrome "coved type" pattern was performed. Given the new findings, the patient's previous ECGs were systematically reviewed, showing the electrocardiographic fluctuations in relation to taking propafenone and suspending it when SBr is suspected. An electrophysiological study was performed that was interpreted as negative and the study was completed with laboratory tests, chest radiography and echocardiography with normal results.

After the withdrawal of propafenone, the ST segment in the right precordial leads is normalized in ECG. Given the diagnosis of “latent SBr revealed with propafenone”, the patient was instructed to avoid antiarrhythmic drugs, tricyclic antidepressants and first generation antihistamines. Currently, the patient is asymptomatic and without electrocardiographic changes.

Discussion

The BrS is included within the group of channelopathies, a hereditary heart disease with autosomal dominant inheritance, which is associated with ventricular arrhythmias and SCD. Incomplete penetrance and variable expressivity hinder the correct diagnosis, the stratification of the risk of sudden death and the specific therapeutic approach for each patient.

#233 - Abstract

LONG-TERM (10-YEAR) FOLLOW-UP ON PATIENTS DIAGNOSED WITH MYOCARDITIS IN A DISTRICT GENERAL HOSPITAL

Sara Santos, Sara Gomes, Helder Santos, Celia Carmo, Carla Nobre, Boban Thomas

Centro Hospitalar Barreiro-Montijo, Setúbal, Portugal

Background

19 patients diagnosed and treated for myocarditis in a district general hospital in Portugal, between the years of 2009 and 2014, patients were assessed 5 to 10 years later to evaluate the long-term outcome of the disease.

Methods

The patient population had the following features: males (17), females (2), ages (18-38 years), History of cardiovascular risk factors (2), family history of cardiac disease in young age (0), precordial chest pain (17), pleuritic chest pain (9), tiredness/orthopnea (1), Acute systemic disease (14), Abnormal EKG (11), EKG with ST elevation segment (8), T wave inversion (2), Mean troponin peak (10,52), Mean CKMB peak (56,13), Mean RCP (71,77), Leucocytosis (10), neutrophilia (3), Systolic dysfunction on echocardiogram (3), segment changes seen in echocardiogram (5), Pericardial effusion seen on echo (5).

Results

In this cohort of patients only one patient was readmitted with myocarditis and there were no long term cardiovascular complications or mortality.

Conclusion

Our data suggest that the clinical spectrum of myocarditis in Portugal may be benign with a good long-term prognosis devoid of cardiovascular complications.

#239 - Abstract

IMPACT OF ATRIAL FIBRILLATION ON THE IN-HOSPITAL MORTALITY OF SURGICAL PATIENTS

Karsten Keller, Lukas Hobohm

Center for Thrombosis and Hemostasis (CTH), University Medical Center Mainz (Johannes Gutenberg-University Mainz), Mainz, Germany

Background

Atrial fibrillation is the most common sustained cardiac arrhythmia worldwide. It is associated with increased mortality, thromboembolic events, and heart failure. We aimed to investigate the impact of AF on adverse in-hospital outcomes in hospitalized surgical patients.

Methods

The nationwide German inpatient sample of the year 2014 was used for this analysis. Surgical patients were identified based on the code for surgical and interventional procedure codes (OPS codes 5-) and patients were further stratified by atrial fibrillation/flutter (AF; ICD code I48) (source: RDC of the Federal Statistical Office and the Statistical Offices of the federal states, DRG Statistics 2014, own calculations).

We compared surgical patients with and without AF as well as survivors vs. non-survivors in AF patients. Logistic regression models were used to investigate the impact of AF as a predictor for adverse in-hospital outcomes.

Results

Overall, 7,043,514 hospitalized surgical patients (54.5% females, 31.6% aged >70 years) were included in the analysis. Of these, 546,019 patients (7.8%) were diagnosed with AF. Overall, 1.4% of the surgical patients and 5.8% of the surgical patients with additional AF died during in-hospital stay.

All-cause death (RR 6.14 [95%CI 6.05-6.22], $P < 0.001$) and adverse in-hospital events (composite of all-cause in-hospital death, mechanical ventilation, and/or cardio-pulmonary resuscitation) (RR 3.35 [95%CI 3.32-3.38], $P < 0.001$) occurred both more often in patients with AF in comparison to those without.

AF was an important predictor for in-hospital death in surgical patients (OR 1.58 [95%CI 1.56-1.61], $P < 0.001$) and for adverse in-hospital events (OR 1.63 [95%CI 1.62-1.65], $P < 0.001$) independent of age, sex and comorbidities.

Additionally, AF is accompanied with an elevated risk to develop a pneumonia (OR 1.80 [95%CI 1.77-1.82], $P < 0.001$), high-risk pulmonary embolism (PE) (1.56 [95%CI 1.43-1.70], $P < 0.001$), fatal PE (OR 1.64 [95%CI 1.47-1.83], $P < 0.001$), shock (OR 1.84 [95%CI 1.81-1.88], $P < 0.001$), as well as (ischemic or haemorrhagic) stroke (OR 2.50 [2.45-2.55], $P < 0.001$).

Conclusion

AF in surgical patients is associated with higher in-hospital case-fatality rate, higher rate of adverse in-hospital events, pneumonia, high risk and fatal PE, shock and stroke.

#245 - Abstract

SOFA SCORE IS ASSOCIATED WITH INCREASED RISK OF SHORT-TERM MORTALITY IN ACUTE DECOMPENSATED HEART FAILURE.

Adi Elias¹, Walid Saliba², Johad Khoury², Fadel Bahouth¹, Jeries Nashashibi³, Zaher Azzam¹

¹ Internal Medicine B, Rambam Health Care Campus, Haifa, Israel

² Carmel Medical Center, Haifa, Israel

³ Internal Medicine D, Rambam Health Care Campus, Haifa, Israel

Background

Heart failure (HF) is one of the leading causes for hospitalization and mortality. Patients hospitalized due to acute decompensated heart failure (ADHF) are at high risk for short- and long-term mortality. Identifying high risk patients is essential to ensure proper monitoring and management. Sequential Organ Function Assessment Score (SOFA) is considered an excellent score to predict short-term mortality in sepsis and other life threatening conditions. ADHF shares similar pathophysiologic mechanism such as; systemic hypoperfusion and inflammatory state. We aimed to assess the capability of SOFA score to predict short and long-term mortality in ADHF.

Methods

Patients with first hospitalization with primary diagnosis of ADHF were retrospectively identified between the years (2008-2018) using computerized database of Rambam Health Care Campus. The SOFA score was calculated for all patients. Patients were divided into 5 categories by 2 points intervals; Category 1 (0-2 points), Category 2 (3-4 points), Category 3 (5-6 points), Category 4 (7-8 points) and Category 5 (above 8 points).

Results

3232 patients were included in the study, the in-hospital mortality, 10-days and 30-days mortality rate were 7.2% (234 patients), 7.6% (260 patients) and 11% (377 patients) respectively. The SOFA score was significantly associated with in-hospital mortality, 10-days mortality and 30 days mortality. The hazards ratios for 1-point increase in the SOFA score were 1.425 (95% CI, 1.347-1.506), 1.425 (95% CI, 1.347-1.506) and 1.479 (95% CI, 1.394-1.608) respectively.

Furthermore, when divided into the 5 categories as demonstrated above, the hazard ratios for 30 mortality were increased by 2.284 (CI 1.4-3.719) for category 2, 5.48 (CI 3.35-8.975) for category 3, 12.49 (CI 19.4-91.9) for category 4 and 42.2 (CI 19-91) for category 5. The SOFA Score demonstrated a good predictive capability. The areas under the receiver operating characteristic curves for in-hospital mortality, 10-days mortality and 30 days mortality were 0.719 (95% CI, 0.684-0.754), 0.691 (95% CI, 0.655-0.727) and 0.653 (95% CI, 0.622-0.685) respectively.

Conclusion

SOFA score is associated with increased risk of in-hospital and

short-term mortality in acute decompensated heart failure. SOFA can be used as a simple score to screen high risk patients that should be considered for intensive care units. Larger prospective studies are needed to validate our results.

#256 - Abstract

RENIN-ANGIOTENSIN-ALDOSTERON SYSTEM BLOCKADE AND ARTERIAL STIFFNESS IN RENAL TRANSPLANTS RECIPIENTS

Zbigniew Heleniak¹, Sarah Illersberger², Susanne Brakemeier², Alicja Debska-Slizien¹, Klemens Budde², Fabian Halleck²

¹ Department of Nephrology, Transplantology and Internal Medicine Medical University of Gdansk, Gdansk, Poland

² Medizinische Klinik mit Schwerpunkt Nephrologie und Internistische Intensivmedizin Charité Universitätsmedizin, Berlin, Germany

Background

Cardiovascular disease (CVD) is the main cause of death among RTRs (renal transplant recipients). The occurrence of CVDs is affected by a lot of CV risk factors, which increase the arterial stiffness. Pulse wave velocity (PWV) measurement is noninvasive, methods for estimating aortic stiffness. Additionally, renin angiotensin aldosterone system (RAAS) blockade mitigate arterial stiffness in general population.

The aim of this study was to assess the influence of RAAS blockade on aortic stiffness in RTRs.

Methods

344 stable RTRs were randomly enrolled to the study. 204/59.3% of them received RAAS blockers (Angiotensin Convertase Inhibitors - ACEi or angiotensin receptor blockers - ARBs): group RAAS (+) and 140/40.7% RTRs were without such medication: group RAAS (-). The median time of dialysis and after kidney transplantation was 58.5 and 78 months respectively. Immunosuppressive regimen was based on calcineurin inhibitors (tacrolimus or cyclosporin), antiproliferative drug (MMF or MPS) and steroids. In RAAS(-) group more patients used steroids than in RAAS(+). Following parameters of arterial stiffness as brachial ankle and carotid femoral pulse wave velocity (baPWV left and right, cfPWV) were measured in each patient by ABI system 100.

Results

In RAAS (+) group 55.4% of patients used ARBs, 43.8% ACEIs. The majority of RAAS (+) patients received candesartan or ramipril. The mean doses of ARBs and ACEIs were 0.25 and 0.5 of their maximal recommended doses, respectively.

CVD (coronary artery disease, peripheral obliterans artery disease) was diagnosed in 27.9 and 14.3% of patients in RAAS (+) and RAAS (-) group respectively. Graft function as far as serum creatinine and eGFR were 1.58, 1.36 mg/dl and 47.9, 54 ml/min/1.73m² in RAAS (+) and RAAS (-) patients, respectively

The values of baPWV left and right were as follow: 11.9, 11.9m/s (left) and 12.1, 11.7 m/s (right) in RAAS (+) and RAAS (-) group,

respectively. cfPWV was 8 and 7.8 m/s in RAAS (+) and RAAS (-) patients, respectively.

In RAAS (+) patients with CVD, the measurements of arterial stiffness parameters (baPWV right 15 vs 12.9m/s, baPWV left 14.4 vs 13.2m/s and cfPWV 10.6 vs 8.6m/s) shown higher results as compare to RAAS (-) group with CVD.

Conclusion

- RAAS blockade was used in the majority of RTRs population.
- Arterial stiffness was increased in RTRs with CVD.
- RAAS blockade did not ameliorate arterial stiffness in RTRs.

#280 - Abstract

STRESS AT WORKPLACE AND RISK OF ACUTE CARDIOVASCULAR DISEASES IN POPULATION 25-64 YEARS IN RUSSIA/SIBERIA. MONICA-PSYCHOSOCIAL EPIDEMIOLOGICAL STUDY

Valery Gafarov¹, Elena Gromova², Dmitriy Panov², Igor Gagulin², Almira Gafarova², Eldar Krymov²

¹. Collaborative Laboratory of Cardiovascular Disease Epidemiology, Novosibirsk, Russia

². Research Institute of Internal and Preventive Medicine, branch of Institute of Cytology and Genetics SB RAS, Novosibirsk, Russia

Background

The aim is to determine the impact of stress on work on the risk of cardiovascular disease over 16-years of follow-up in an open population of 25-64 years in Russia/Siberia.

Methods

Under the third screening of the WHO MONICA-psychosocial program (MOPSY) random representative sample including both genders aged 25-64 years was surveyed in Novosibirsk in 1994 (n=1346, 48.8% males; mean age 44.9 ± 0.4 years; response rate was 77.3%). Stress at work was assessed by means Karazek scale. New-onset cases of myocardial infarction (MI), stroke were identified from 1994 to 2010.

Results

A high level of stress at work was in 29.5% of men and in 31.6% of women. The middle level was in 48.9% of men and in 50.7% of women ($\chi^2=2.574$ $v=2$ $p=0.276$). The risk of MI over 16-years period in persons experiencing stressful situations at work was as follow: in men HR=3.592 and women HR=3.218 (95%CI 1.146-9.042); stroke risk was in men HR=2.603 (95%CI, 1.06-4.153) and in women HR was 1.956 (95%CI 1.008-3.795). In multivariate analysis risk of MI in men was HR=1.15 (95%CI 0.6-2.2) and in women HR=2.543 (95%CI 1.88-7.351); risk of stroke in men was HR=3.8 (95%CI 1.6-8.8) and in women it was HR=1.95 (95%CI 0.984-3.887). The risk of stroke was higher in those who are living alone, divorced and widowed men HR=4.2 (95% CI 1.5-13.2) and in women with high school or primary education degree HR=3 (95%CI 0.852-11.039).

Conclusion

It was established that a high level of stress at work is not gender-specific. The risk of MI incidence over a 16-years period is higher in women than in men but stroke in men; the risk of myocardial infarction and stroke is affected by the social gradient in both genders.

#285 - Case Report

PULMONARY EMBOLISM – THE GREAT MASQUERADE

Flávia Marília Ferreira Santos, Cátia Faria, Cátia Santos, Vera Frazão, Diana Moura, João Santos

Centro Hospitalar de Leiria, Leiria, Portugal

Introduction

Pulmonary embolism (PE) has a highly variable clinical presentation. Sudden-onset dyspnea is the most reported compliant among patients. Other symptoms include cough, haemoptysis, fever, anxiety, nausea, acute chest, tachycardia, lipothymia, convulsions, cyanosis or edema of the lower limbs.

Case description

We present the case of a 65-year-old male with past medical history of hypertension and diabetes mellitus. He was asthenic, with dyspnea at rest, non-productive cough and loss of strength in the lower limbs. In the past 4 days he had 2 episodes suggestive of lypotimia. He had been previously observed at consultation with the diagnosis of a respiratory infection and empirically medicated with azithromycin. At examination the patient was conscious, cooperative and oriented. Sudoretic, with a heart rate of 129 bpm), with hyperglycemia (360 mg/dL). No changes in cardiac and pulmonary auscultation and no edema in the lower limbs, without suggestive signs of deep venous thrombosis. Blood analysis showed relative neutrophilia without associated leukocytosis. Creatinine 1.54 mg/dL, Urea 12.7 U/L, High sensibility troponin 220, BNP 5720 pg/L. Blood gas gas with hypoxemia and hypocapnia. Chest X ray showed bronchovascular reinforcement on the right, with no evidence of condensation or effusion. Electrocardiogram with sinus rhythm, 122bpm, inversion of the T wave from V1 to V6. Thorax computed tomography and angiography showed PE involving the common trunk and, more extensively, the distal region of both main pulmonary arteries and all emerging lobular arteries as well as some lower predominant segmental arteries. The patient started anticoagulation with lower molwcular weight heparin. Performed transthoracic echocardiogram for stratification of the severity of the condition that did not show affection of the right cardiac cavities function.

Discussion

The authors intend to demonstrate that PE is a serious and potential life- Threatenning condition that may occur with highly variable clinical presentation. Therefore it is very important that the physician to considerate this as a possible hypothesis when

observing patients with a nonspecific or atypical clinic in order to improve outcome.

#301 - Abstract

ABBC (AGE, NT-PROBNP, BARTHEL INDEX AND C-REACTIVE PROTEIN) LONG-TERM SCORE IN THE PREDICTION OF DEATH AFTER AN ACUTE PULMONARY EMBOLISM

José Luis Alonso-Martínez, Francisco Javier Annicchérico-Sanchez, Sara Pérez-Ricarte
Hospital Complex of Navarra, Pamplona, Spain

Background

Several prognostic indexes are available for use in daily clinic to classify the risk of death of patients diseased with pulmonary embolism (PE), generally with a suitable 30 days prediction power. Venous thromboembolic disease has become a disease of the elderly that may cause important aftermaths. We have developed a long-term prognostic score of mortality after a PE based in our registry.

Methods

All consecutive patients image-diagnosed with pulmonary embolism were included, and the survival and the causes of early and late death were traced.

Results

In 611 patients diagnosed with PE, the median age was 76 interquartile range (IQR) 61-79 years, female 342 (56%), They were traced for a median time of 29 IQR 15-63 months. 196 (32%) patients died during the follow-up at a median time of 13 IQR 2.3-47 months. All-causes 30-days mortality was 5.5% and pulmonary related 30-days mortality was 2%. Simplified PESI classified as low risk 6% of dead patients.

Retrograde logistic regression analysis showed Age (β 0.64 $p=$.0005 OR 1.90 CI95% 1.01-1.07), plasma NT-ProBNP (β 0.47 $p=$.001 OR 1.60 CI95% 1-1.0002), Barthel (β -0.49 $p=$.0001 OR 0.61 CI95% 0.96-0.98) and C-Reactive protein (β 0.29 $p=$ 0.01 OR 1.33 CI95% 1.0008-1.008) all of them associated with risk of death with a logit of survival of 9.7%. A score was derivate with Age greater than 75 years: 1.5 points, NT-ProBNP higher than 850 ng/mL: 1 point, Barthel lower than 85 points: 2 points and CRP higher than 30 mg/L: 1 point. A score equal or higher 2 points showed a probability of death of 91% (OR 9.04, CI 95% 3.66-22.33).

Among the dead patients 6 (3%) did not meet any of the parameters. Area under curve ROC showed a value of 0.757 (CI 95% 0.716-0.799).

Conclusion

ABBC score had a high prediction value of death in patients diagnosed with pulmonary embolism. An external validation test would be necessary to confirm our results.

#303 - Abstract

FACTORS INFLUENCING THE LENGTH OF IN-HOSPITAL STAY IN ACUTE PULMONARY EMBOLISM

Francisco Javier Annicchérico-Sanchez, Jose Luis Alonso-Martinez, Sara Pérez-Ricarte
Hospital Complex of Navarra, Pamplona, Spain

Background

In-hospital stay of acute pulmonary embolism (PE) goes being decreased with trend to home treatment in patients with small burden of thrombi and hemodynamic stability and because the use of direct action anticoagulants. We investigate factors associated with the length of hospital stay.

Methods

In 611 patients diagnosed with acute PE with preserved blood pressure, we search for factors influencing the length of stay.

Results

The median age was 76 interquartile range (IQR) 61-79 years, female 342 (56%), median stay 7 (5-9) days.

Male patients had a stay of 7 (6-10) days and mean age of 68±15 years and female patients 7(5-9) and 75±14 years ($p<$ 0.05 and $<$ 0.001 respectively).

The stay of provoked PE was 7(5-9) days and 7(6-10) days in patients with unprovoked PE ($p<$ 0.05). Patients with cancer diagnosed in the evolution had a stay of 8 (6-13) days while patients without cancer has 7(5-9) days ($p<$ 0.01).

Patients with Barthel index lower than 90 ($p<$ 0.05), sPESI higher 1 ($p<$ 0.01) and diabetes ($p<$ 0.05) had higher stay than patients without.

MANCOVA analysis showed the association of length of stay with the age, sPESI and Barthel index ($p=$ 0.006 for the model and $p<$ 0.01 for every one).

Logistic regression model with independent variable unprovoked PE, showed that gender male (OR 1.40 CI95% 1.33-1.29), cancer diagnosed in evolution (OR 0.76 CI95% 0.25-0.77), sPESI (OR 1.31 CI95% 1.04-1.62), Barthel index (OR 0.34 CI95% 0.93-0.96) an diabetes mellitus ($=$ R 1.24 CI95% 1.02-3.53) were independent factors enlarging the in-hospital stay.

Conclusion

Male gender, sPESI, Barthel index and diabetes all influenced on the length of in-hospital stay of patients with PE and preserved blood pressure.

#307 - Abstract

CHARACTERIZATION AND STUDY OF THROMBOEMBOLIC DISEASE: A RETROSPECTIVE HOSPITAL-BASED STUDY

Marta Rafael Marques, Susana Marques Sousa, Dolores Vazquez, Vera Seara, Sónia Fernandes, Maria Luz Dobao

Hospital Center of Póvoa de Varzim / Vila do Conde, Póvoa De Varzim, Portugal

Background

Pathogenesis of thrombosis is multifactorial and usually a risk factor can be identified in over 80% of patients.

Our objective is to analyse the main risk factors for venous and arterial thrombosis and the mechanisms by which they mediate the disease.

Methods

A descriptive and retrospective cohort study of patients with thrombotic events followed at a first level hospital center, from January 2016 to April 2019. Age, gender, diagnosis, risk factors, hemorrhagic and thrombotic events and recurrence score (DASH score) were analysed.

Results

86 patients were included. The median age was 56 (14.92) years and 72.1% were females. The frequency of venous thromboembolism (VTE) was 88.4% and 11.6% for arterial thrombosis (AT). The primary clinical events were: 42 deep venous thromboses (DVT), 12 pulmonary embolisms (PE), 9 DVT and PE, 13 VTE in uncommon localizations and 10 AT. 61 clinical events (70.9%) were considered provoked. The main risk factors for VTE were oral contraceptives or hormone therapy (n=19), surgery (n=8) and immobilization (n=7). Chronic venous insufficiency (n=31) and malignancy (n=9) were also particularly relevant as potential risk factors. The most frequent risk factors for cardiovascular disease were hypertension (n=26) and dyslipidemia (n=26). In 15 patients thrombophilia was detected. Antiphospholipid syndrome was the most common cause of acquired thrombophilia (20%) and, in hereditary thrombophilias, was Leiden factor V mutation (40%). Anticoagulation therapies used were direct oral anticoagulants (n=42), vitamin K antagonists (n=41) and low molecular weight heparin (n=3). Median anticoagulant treatment was 6 (1,12) months. Long-term anticoagulation was considered in 51% of patients. 20% had DASH score > 1 at the end of anticoagulation. The recurrence of thrombosis was 6.9% (mean follow-up of 24.6 months). Haemorrhagic events occurred in 2.3% (only one major bleeding).

Conclusion

As described in the literature, the majority of the thrombotic events were provoked. The correct identification of these risk factors is essential, in order to assess the individual risk of thrombosis and promote more targeted prophylactic and therapeutic options. The use of recurrence scores seems to be a

useful tool at the time of the therapeutic decision, but prospective validation studies are still required. The close follow-up of these patients, as well as the control of the risk factors, could reduce the complications associated with antithrombotic therapy.

#308 - Abstract

IMPEDANCE CARDIOGRAPHY IN THE EVALUATION OF PATIENTS WITH ARTERIAL HYPERTENSION

Helena Martins Da Fonseca¹, Rodrigo Nazário Leão², Pedro Marques Da Silva²

¹ Centro Hospitalar e Universitário Lisboa Central, EPE, Lisboa, Portugal

² Centro Hospitalar e Universitário Lisboa Central, EPE - Núcleo de Investigação Arterial (NIA), Lisboa, Portugal

Background

Arterial hypertension (AH) is responsible for high morbidity and mortality. Despite increasing awareness blood pressure (BP) control rates are suboptimal and approximately half of the patients do not reach the recommended targets. Defined as an increase in BP, AH is characterized by hemodynamic abnormalities in cardiac output, systemic vascular resistance or arterial compliance. Therefore, the approach to AH can be improved by the knowledge of the hemodynamics underlying the BP increase. One of the objectives of our clinical trial was to evaluate with impedance cardiography (ICG) the hemodynamic profiles of a group of treated hypertensive patients.

Methods

Treated hypertensive patients (grade 2 or resistant AH) without heart failure, arrhythmias, ischemic or valvular disease, were prospectively recruited. ICG was performed accordingly with our centre protocol. Patients were classified as vasoconstrictor (systemic vascular resistance >2500 dyn.s.cm⁻⁵.m²), hyperdynamic (cardiac index >4.2 l/min/m²), hypervolemic (thoracic fluid content in male > 34 /kOhm or >24 /kOhm in women) or balanced profile. Demographic variables and therapeutic were registered.

Results

A total of 157 patients, 56% male, aged 63±18 years, with 4±1 anti-hypertensive drugs were included. The mean hemodynamic values were: systolic blood pressure 135±44mmHg, diastolic blood pressure 93±27mmHg, heart rate 65±28 cycles/min, systemic vascular resistance 2665±1904 dyn.s.cm⁻⁵.m², cardiac index 2.8±2.1 l/min/m², thoracic fluid content 32±11/kOhm. Regarding the hemodynamic profile, 54.5% were classified as vasoconstrictors, 20% hyperdynamic, 32.7% hypervolemic, 23.6% presented a balanced profile, 45.2% presented two or three hemodynamic profiles concomitantly.

Conclusion

In this study we found that 76.4% of our patients had uncontrolled hemodynamic profiles. Hypertensive patients treated accordingly

current guidelines frequently do not achieve the BP goals. ICG is a differential technique in the assessment of cardiovascular and hemodynamic status. The application of therapeutic adjustment algorithms, based on the parameters found by ICG, demonstrated that it is possible to improve the diagnosis and prognosis of patients with hypertension. Therefore, ICG can emerge as an important tool to guide anti-hypertensive therapeutic and improve BP control rate.

#331 - Abstract

THE ROLE OF KIDNEY FUNCTION ON SURVIVAL OF PATIENTS WITH LEFT MAIN CORONARY ARTERY DISEASE TREATED WITH PERCUTANEOUS CORONARY INTERVENTION

Igor Balevski¹, Vigor Arva¹, Sandra Burja², Tadej Petreski³, Nejc Piko³, Vojko Kanic¹, Sebastjan Bevc^{3,2}

¹ Department of Cardiology and angiology, Clinic for internal medicine, University Medical Centre Maribor, Maribor, Slovenia

² Medical faculty, University of Maribor, Maribor, Slovenia

³ Department of Nephrology, Clinic for internal medicine, University Medical Centre Maribor, Maribor, Slovenia

Background

Chronic kidney disease (CKD) is associated with a high burden of stable coronary artery disease and an increased incidence of acute coronary syndromes (ACSs). Left main coronary artery (LMCA) disease is the highest-risk lesion of ischemic heart disease, where revascularization with either percutaneous coronary intervention (PCI) or coronary artery bypass grafting (CABG) is needed. Presence of CKD in these patients may increase the risk of complications and mortality connected to revascularization procedures.

The aim of our study was to determine the role of CKD in the survival of patients after undergoing PCI for ACS in LMCA disease.

Methods

In our retrospective study, 102 patients (73 male (71.6%)) were included. All patients underwent primary PCI of LMCA between January 1st, 2008 and December 31st, 2016. The patients were observed from PCI until their death or by December 20th, 2018 (average time of observation was 3.2 years). Mean age of included patients was 70.3 +/- 9.6 years (minimum 52 years, maximum 86 years). CKD was defined as estimated glomerular filtration rate (eGFR) <= 60 ml/min/1.73 m² by using the Chronic Kidney Disease Epidemiology Collaboration (CKD-EPI) equation. Comorbidities, such as arterial hypertension (AH), diabetes mellitus (DM), and dyslipidaemia were recorded. Survival rates were analyzed using Kaplan-Meier survival curves. The Cox regression model was used to assess the influence of CKD, AH, DM and dyslipidaemia.

Results

82.8 % of patients had AH, 40.8 % had DM and 75.8 % had dyslipidaemia. 32.4 % of patients had eGFR <= 60 ml/min/1.73 m². Mean survival time of patients in the CKD group (eGFR <= 60 ml/

min/1.73 m²) was 925 days +/- 213 days (95% CI 507.7-1342.1 days) and in the non-CKD group was 1796 +/- 154 days (95% CI 1495-2097 days). 23 (30.3%) CKD and 28 (58.8%) non-CKD patients died. Kaplan-Meier survival analysis showed higher risk of death for CKD patients (log rank test; p < 0.001). In Cox multivariable regression model, CKD remained a predictor of all-cause mortality in our patients (HR was 1.459 (95% CI 1.255-1.825; P=0.009)). The impact of AH (p=0.444), DM (p=0.272) and dyslipidaemia (p=0.070) on patient survival was not statistically significant.

Conclusion

The results indicate an association between CKD and all-cause mortality in patients after undergoing PCI for ACS in LMCA disease.

#338 - Abstract

PREVALENCES AND CONTROL ASYMMETRIES IN HYPERTENSION IN DIABETIC PATIENTS, BETWEEN URBAN AND RURAL POPULATIONS IN THE NORTH OF PORTUGAL (NUTII)

Mario E Macedo¹, Tiago T Gomes², Maria E Santo³, Pedro M Silva⁴, Rui C Ferreira⁵

¹ Programa Nacional para as Doenças CérebroCardiovasculares da DGS, Porto, Portugal

² USF Covelo, ACES Porto Oriental, ARS Norte, Porto, Portugal

³ ULS Matosinhos, Porto, Portugal

⁴ Núcleo de Investigação Arterial, Medicina 4, Hospital Santa Marta, Lisboa, Portugal

⁵ Serviço de Cardiologia, Hospital Santa Marta, Lisboa, Portugal

Background

High blood pressure is the leading risk factor for cardiovascular morbidity and mortality in Portugal. Hypertension and diabetes frequently coexist, leading to additive increases in the risk of life-threatening cardiovascular events. To deliver an effective and high-quality care to patients, it is very important to know their diseases. Likewise, for health systems to be effective, it is necessary to understand the key challenges in efforts to improve populations health and how these challenges can be changed. The objectives of this study are to estimate the prevalence and control of hypertension in diabetics in urban and rural regions of the North of Portugal (NuttII).

Material and Methods

A retrospective analysis was conducted of all patients-based electronic medical records, during 2017/2018 years. The data belong to adult (age >18years old) populations registered in all primary care centers of the North of Portugal, i.e. approximately 3 million people.

Results

The overall prevalence of hypertension was 31.5%. It was higher in female than in male (32.3% vs 29.9% (p<0.0001)), and control

was 48.9% in male and 54.8% in female ($p < 0.001$). Among patients with diabetes the hypertension was present in 77.7% of males and 79.4% of females ($p < 0.0001$).

According to the different NUTs III the prevalence of hypertension was higher in rural areas (82.5%) than in urban (72.2%). The control varies between 30.1% and 54%, with the higher values in rural areas.

Conclusion

This study identified an increased prevalence and poor control of hypertension in diabetic patients in most rural regions of the North of Portugal. This provides an important opportunity to study the underlying factors and design tailored interventions to address this disparity in health outcome.

#339 - Abstract

PREVALENCES AND CONTROL ASYMMETRIES IN HYPERTENSION, BETWEEN URBAN AND RURAL POPULATIONS IN THE NORTH OF PORTUGAL

Mario E Macedo¹, Tiago T Gomes², Maria E Santo³, Pedro M Silva⁴, Rui C Ferreira⁵

¹ Programa Nacional para as Doenças CérebroCardiovasculares da DGS, Lisboa, Portugal

² USF Covelo, Porto, Portugal

³ ACES Porto Oriental, Porto, Portugal

⁴ ARS Norte; AI4Health CINTESIS; IINFACTS CESPU, Lisboa, Portugal

⁵ ULS Matosinhos, Lisboa, Portugal

Background

High blood pressure is the leading risk factor for cardiovascular morbidity and mortality in Portugal. To deliver an effective and high-quality care to patients, it is very important to know their diseases. Likewise, for health systems to be effective, it is necessary to understand the key challenges to improve populations health and how these challenges can be changed. The objectives of this study are to estimate the prevalence and control of hypertension in urban and rural regions of the North of Portugal.

Material and Methods

A retrospective analysis of all patients-based electronic medical records, during 2017/2018 years, was conducted. The data belong to adult (age > 18 years old) populations registered in all primary care centers of the North of Portugal approximately 3 million people.

Results

The overall prevalence of hypertension was 31.5%. It was higher in female than in male (32.3% versus 29.9%), and control was 48.9% in male and 54.8% in female.

According to the different NUTs III, the prevalence of hypertension varies between 30.5% and 38.6%, with the higher values in rural areas. The control of hypertension have the same tendency with

higher values in urban areas (54%) and the lower values in the rural areas (30.1%).

Conclusion

This study identified an increased prevalence and poor control of hypertension in most rural regions of the North of Portugal. This provides an important opportunity to study the underlying factors and design tailored interventions to address this disparity in health outcome.

#343 - Case Report

HYPONATRIEMIA AND BRUGADA ECG PATTERN: A CASE REPORT

Andrea Pizzuto, Chiara Ferrante, Stefano Pantaleoni, Simona Maria Sipari Merlo, Cesare Poletto, Giuseppe Montrucchio
AOU Città della Salute e della Scienza di Torino - Università degli Studi di Torino, Torino, Italy

Introduction

Brugada syndrome (BrS) is a life-threatening condition due to genetic alteration in cardiac sodium channel with typical ECG pattern. There are two main patterns: type 1 (coved) and type 2 (saddle-back). The term "Brugada phenocopy" (BrP) is used to describe a Brugada-like ECG pattern due to various conditions (e.g. electrolyte disturbances) without genetic mutation.

Case description

We report a case of BrP induced by acute onset of hyponatremia. A 90-years-old male presented with confusion and disorientation. He assumed thiazidic diuretic for arterial hypertension. No personal or familiar history of syncope, arrhythmia or sudden cardiac death; a previous ECG showed absence of typical pattern. Physical examination was unremarkable. Blood tests only showed hyponatremia (114 mmol/L). ECG displayed a new "coved pattern". After fluid replacement and diuretic withdrawal, we observed normalization of sodium value with simultaneous clinical improvement and ECG coved pattern disappearance with signs of "saddle-back pattern".

Discussion

To our knowledge only six other cases described an association between hyponatremia and BrP, and just in four of them hyponatremia was the only electrolyte alteration. Hyponatremia can induce a Brugada-like ECG pattern via reduction of inward sodium current by decreasing its gradient, even in non-mutated channels. Our clinical case can be classified as a type 1B BrP according to classification system proposed by Gottschalk, since provocative testing with a sodium channel blocker has not been performed because the patient declined. Despite it is known that combination of electrolytes imbalance could lead to BrP, hyponatremia alone might be an important cause. We would like to point out that BrP is a benign and reversible condition, so it is important to perform drug challenge to rule out a real BrS.

#346 - Case Report

FLUOROURACIL AND LONG-TERM CARDIOTOXICITY: A CASE DESCRIPTION

Raquel Santos, Mylene Costa, Cristina Rosário
Hospital Pedro Hispano, Matosinhos, Portugal

Introduction

Fluorouracil (5-FU) is a chemotherapeutic drug of the group of fluoropyridines with known cardiac toxicity. The mechanisms of heart damage, that occurs most commonly during the first cycle of administration, include vascular endothelial damage, coronary artery spasm and direct toxicity on the myocardium. Clinically, it manifests acutely as angina, myocardial infarction, arrhythmias, pericarditis and heart failure that lead to withdrawal of 5-FU. However, studies are lacking about its long-term cardiovascular effects.

Case description

We present the case of a 64-year-old woman who was admitted at the hospital with acute heart failure. She had a past history of rectum adenocarcinoma 10 years before treated with surgery and 5-fluorouracil chemotherapy. During the infusion of the drug she developed atrial fibrillation (AF) and the infusion was stopped and not repeated. She was treated with beta-blocker and oral hypocoagulation.

During the current hospitalization, transthoracic echocardiogram revealed impaired right ventricular and normal left ventricular systolic functions, high left ventricular filling pressure and severe pulmonary hypertension (PH).

An extensive study of the heart failure and the PH was performed. No coronary disease was found in heart catheterization that revealed increased pulmonary artery systolic and pulmonary capillary wedge pressures (56 and 30 mmHg, respectively). Cardiac magnetic resonance showed an anterior late intramural enhancement, compatible with nonischemic myocardial fibrosis. The pulmonary ventilation/perfusion scintigraphy suggested a bilateral peripheral pulmonary thromboembolism (PTE). Autoimmune, viral or endocrine causes of heart failure and PH were excluded. There was no evidence of recurrence of rectal adenocarcinoma (after thoraco-abdominopelvic CT, colonoscopy and PET). Myocardial biopsy excluded active inflammation and infiltrative disease.

The final diagnosis was multifactorial PH: pre-capillary PH due to pulmonary thromboembolism and post capillary PH due to heart disease caused by myocardial scar possibly induced by 5-FU. After clinical stabilization, the patient was discharged.

Discussion

In this case, the authors hypothesize that the 5-FU toxicity lead to irreversible heart damage with resulting heart failure with contribution of pulmonary thromboembolic disease and AF. Although rare, long term cardiovascular toxicity of fluoropyridines should always be considered mainly in patients with acute manifestations during or after therapy.

#355 - Case Report

A RARE CAUSE OF INFECTIVE ENDOCARDITIS WITH AN UNFORTUNATE END

Carla Marques Pires, Sandra Correia, Isabel Eira, Renata Carvalho, Cindy Tribuna, Cristina Ângela, Carlos Capela
Hospital de Braga, Braga, Portugal

Introduction

Infective endocarditis (IE) is a disease with a high risk of mortality. Gram-positive bacteria, such as *Staphylococcus* spp. and *Streptococcus* spp. are the main responsables, while gram-negative bacteria are the etiologic agents in a minority of cases, usually included in the HACEK group (*Haemophilus*, *Actinobacillus*, *Cardiobacterium*, *Eikenella* and *Kingella*)

Case description

A 71-years-old male with chronic kidney disease and cystectomy with Bricker derivation as relevant antecedents.

Admitted 28 days in the Urology service for renal failure with bilateral hydronephrosis, treated with bilateral percutaneous nephrostomy. During the hospitalization he developed an urinary tract infection with fever and started empirical antibiotic therapy with ceftriaxone. Later, the urine culture presented an *Enterobacter cloacae* (*E. cloacae*), multi-sensitive, with negative blood cultures.

In view of the deterioration and multiorgan dysfunction he was transferred to the Intermediate Care Unit and the antibiotic was escalated to piperacillin-tazobactam.

The persisting fever and the detection of systolic heart murmur, most evident at cardiac apex, led to the performing of transthoracic and transesophageal echocardiography which revealed a 18x14mm mass on the anterior leaflet of the mitral valve. Three blood cultures were collected, and all revealed an Extended-Spectrum B-lactamase producing *E. cloacae*.

Thus, for native valve IE the patient started gentamicin and meropenem adjusted to renal function. In the first 14 days the patient improved, however a second worsening characterized by fever, generalised congestion and significant anemia occurred. Follow-up echocardiography revealed a 27x12 mm mass on the anterior leaflet and severe mitral regurgitation and new set of blood culture were negative.

For this reason, the patient was transferred to Cardiac Surgery Service for mitral valve replacement by biologic prosthesis. Two days after surgery he developed an acute right inferior limb ischemia caused by septic emboli from mitral valve endocarditis. He was treated with thromboembolectomy. However he died the following day.

Discussion

E. cloacae is a gram-negative bacteria non-HACEK and a rare and extremely severe cause of IE. Nowadays, there are few number of cases reported in the literature and best treatment strategy is not consensual. In this particular case, although target antibiotic therapy and surgery were tried the outcome was negative. Thus, additional studies are necessary to improve our approach.

#361 - Abstract

HEMODYNAMIC EVALUATION OF TREATED HYPERTENSIVE PATIENTS WITH IMPEDANCE CARDIOGRAPHY: RESULTS OF IMPEDDANS STUDY

Rodrigo Nazário Leão¹, Cláudia Janeiro², Helena Fonseca¹, Pedro Marques Silva¹

¹ Núcleo de Investigação Arterial, Hospital Santa Marta, Centro Hospitalar Universitário Lisboa Central, Lisboa, Portugal

² UF Medicina 2.1, Hospital Santo António dos Capuchos, Centro Hospitalar Universitário Lisboa Central, Lisboa, Portugal

Background

The prevalence of arterial hypertension (AHT) in Portuguese adult population is higher than 40%. Historically defined by sustained elevation of blood pressure (BP), AHT results from hemodynamic changes characterized by cardiac output, systemic vascular resistance and/or arterial compliance abnormalities, with significant implications for diagnosis, risk stratification and treatment. Impedance cardiography (ICG) is a noninvasive method for hemodynamic profile evaluation. It allows to access risk and optimize therapy. In this study we analyzed the resistant hypertensive patients with controlled blood pressure values in order to evaluate and characterize their hemodynamic profile by ICG.

Methods

Resistant hypertensive patients without heart failure, ischemic heart disease, valvular heart disease or dysrhythmia were prospectively selected. After ICG were classified as: vasoconstrictor (systemic vascular resistance (SVR) > 2500 dyn.s.cm-5.m²), hyperdynamic (cardiac index (CI) > 4.2 l/min/m² and/or heart rate (HR) > 80 cycles/min), hypervolemic (thoracic fluid (TFC) > 341/kOhm) or balanced (hemodynamic parameters below the established limit values). All patients underwent transthoracic echocardiography to exclude major changes. In this sub-analysis of patients from the IMPEDDANS study we included only those who, according to international recommendations, had office and outpatient blood pressure values within the therapeutic goals.

Results

From 157 initial patients, 38 were included, 57.9% male, with 62±10 years old, under 4±1 antihypertensive agents. The mean hemodynamic values were: systolic blood pressure (BP) 123 ± 13, diastolic BP 75±4, HR 67±11, SVR 2726±29, CI 2.7±0.5, TFC 31±5. According to the hemodynamic profile 63.2% appear to be vasoconstrictors, 13.2% hyperdynamic, 28.9% hypervolemic and 23.7% balanced.

Conclusion

These results suggest that, despite polymedicated and with arterial pressure within the recommended values, the majority of patients were not hemodynamically stabilized, confirming that

BP is an hemodynamic variable supported by several processes, tendentially redundant, in which inhibition of one element tends to favor the activation of another. ICG is, therefore, an useful method in the evaluation of hypertensive individuals, capable of contributing to adequate therapeutic optimization.

#362 - Abstract

EVALUATION OF CARDIOVASCULAR FUNCTIONAL RESPONSE TO ORTHOSTATISM IN TREATED HYPERTENSIVE PATIENTS: RESULTS OF THE IMPEDDANS STUDY

Rodrigo Nazário Leão¹, Cláudia Janeiro², Helena Fonseca¹, Pedro Marques Silva¹

¹ Núcleo de Investigação Arterial, Hospital de Santa Marta, Centro Hospitalar Universitário Lisboa Central, Lisboa, Portugal

² UF Medicina 2.4, Hospital de Santo António dos Capuchos, Centro Hospitalar Universitário Lisboa Central, Lisboa, Portugal

Background

Arterial Hypertension (AHT) is one of the main causes of morbidity and mortality in the world. Generally defined as an increase in blood pressure (BP), it is characterized by hemodynamic changes that have implications for diagnosis, risk stratification and therapy. In this study we intend to characterize the hemodynamic response to orthostatism in a group of treated hypertensive patients using impedance cardiography (ICG).

Methods

Resistant hypertensive patients without heart failure, ischemic heart disease, valvular heart disease or dysrhythmia were prospectively selected. All patients underwent ICG in the supine position and in orthostatism. After ICG, they were classified into patterns: vasoconstrictor (systemic vascular resistance (SVR) > 2500 dyn.s.cm-5.m²), hyperdynamic (cardiac index (CI) > 4.2 l / min / m² and / or heart rate HR > 80 cycles / min), hypervolemic (thoracic fluid (CFT) > 341 / kOhm) or balanced (hemodynamic parameters below the established limit values). All patients underwent transthoracic echocardiography to exclude major morphologic changes.

Results

We included 157 patients, 56.1% males, age 63 ± 10 years, medicated with 4±1 antihypertensives. In ICG, 56.1% were vasoconstrictors, 12.1% hyperdynamic, 33.1% hypervolemic and 23.6% had a balanced hemodynamic profile. In the supine position the patients had systolic blood pressure 135 ± 19 mmHg, diastolic blood pressure 78±10 mmHg, HR 65±11 cycles/min, indexed ejection volume 44±10 ml/m², pre-ejection period 94±18 ms, ejection time 329±18 ms, systolic time ratio 0.29±0.07, RVSI 2655±617 dyn.s.cm-5.m², cardiac index 2.8±0.5 l/min / m² and CFT 31 ± 5 l / kOhm. In the orthostatic position some of these values were significantly higher: diastolic blood pressure 81±13 (p < 0.001), HR 71±13 (p < 0.001), pre-ejection period 116±25 (p

<0.001), systolic time ratio 0.39 ± 0.10 ($p < 0.001$). The indexed ejection volume 40 ± 9 ($p < 0.001$), ejection time 302 ± 47 ($p < 0.001$) and CFT 29 ± 4 ($p < 0.001$) were significantly lower.

Conclusion

Although polymedicated, most patients had an unbalanced hemodynamic profile. The analysis of the impedance waveform with postural modification can be used to clarify the response to orthostatism and to better characterise the hemodynamic phenotype.

#368 - Case Report

INFERIOR VENA CAVA AGENESIS AND DEEP VEIN THROMBOSIS: A RELATIONSHIP TO CONSIDER IN YOUNG PATIENTS

Inês Esteves Cruz¹, Francisco Silva²

¹ Hospital Egas Moniz, Lisbon, Portugal

² CHLO, Lisbon, Portugal

Introduction

Inferior vena cava agenesis (IVCA) is a rare congenital abnormality, with an estimated prevalence of 0.0005–1% in the general population. Embryological dysgenesis seems to be the most commonly proposed origin. Generally is diagnosed after ultrasonographically (US) documented deep vein thrombosis (DVT), abdominal and pelvic computed-tomography (CT) scans or magnetic resonance imaging (MRI). IVCA is found in almost 5% of DVT patients under 30 years old.

Case description

A 20-year-old male, with no relevant personal history, was admitted in ER with back and abdominal pain, with mechanical characteristics and inability to walk, aggravated with Valsalva maneuvers. There was progressive immobilization during hospitalization and subsequent onset of pain in the lower limbs. US was performed with evidence of DVT of both femoral and external iliac veins, and anticoagulation with low molecular weight heparin was initiated.

Abdominal and pelvic CT scan presented agenesis of the distal segment of the inferior vena cava, receiving the perivertebral lumbar veins as venous tributaries. The left renal vein drained into the homolateral lumbar perivertebral vein and the right renal vein drained into the portal system by porto-renal anastomoses. Angiography demonstrated L5 lumbar arteries originated in the medial sagittal artery, with the left L5 lumbar artery hypoplastic and its territory irrigated by anastomoses by the left L4 lumbar artery.

Diagnostic of IVCA-associated DVT was assumed. Thrombophilia screening was performed without abnormalities (antithrombin, protein C, protein S, antiphospholipid antibody syndrome, homocysteine, factor V Leiden [G1691A] mutation and prothrombin gene [G20210A] mutation). It was decided to maintain long-term vitamin K antagonist.

By patient's request, although there is no clinical evidence supporting use of direct factor Xa inhibitors in this condition, therapy with rivaroxaban 20mg/day has been instituted, and in 5 years follow-up there is no evidence of thrombotic events' recurrence.

Discussion

IVCA should be suspected if DVT involving the iliac veins is seen in patients 30 years of age or younger. US is not useful for IVCA diagnosis but CT scans or MRI can provide the diagnosis. Patients with both an anomaly and thrombosis may be at higher risk for thrombotic recurrence, so prolonged anticoagulation, perhaps even life-long, is usually prescribed. No follow-up data are available concerning this indication and use of direct factor Xa inhibitors in these cases.

#370 - Case Report

PERICARDIAL EFFUSION, A DIAGNOSIS EASILY MISSED

Carla Marques Pires, Paulo Medeiros, Cátia Oliveira, Isabel Campos, Rui Flores, Fernando Mané, Alberto Salgado, Nuno Antunes, Jorge Marques

Hospital de Braga, Braga, Portugal

Introduction

Pericardial effusion has multiples aetiologies and according to recent studies in developed countries up to 50% are idiopathic while 5 to 15% are associated with immune and inflammatory diseases. The clinical impact depends on the rate of accumulation, the amount of pericardial fluid and the aetiology.

Case description

A 58 years-old male with multiple cardiovascular risk factors and history of myocardial infarction (MI), submitted to medical approach, in 2005 as relevant antecedents.

Admitted on the 31st of March at the Cardiology Service for MI without ST-segment elevation with left main and three vessel coronary artery disease on the coronarography. For this reason, the patient was submitted to a coronary artery bypass surgery on the 9th of April, without early complications. Discharged 7 days after surgery.

Patient returned to the Emergency Department on June 13th due to exertional dyspnoea with progressive worsening, orthopnoea and pleuritic chest pain. At admission the patient exhibited tachycardia, muffled heart sounds, without hypotension or pulsus paradoxus. Analytically there was no elevation of markers of inflammation and myocardial injury. There were no electrocardiogram changes, but the transthoracic echocardiography showed a large pericardial effusion with right cavities compression. For this reason, the patient was submitted to pericardiocentesis allowing the removal of 1500 ml of pericardial fluid, characterized as exudate according to Light criteria. The bacterial and mycobacterial cultures of pericardial fluid were

negative. In addition, a pericardial drain was kept until the 16th of June and extract a total of 2300 mL. Anti-inflammatory non-steroids were also administered as a complement.

On discharge, 19th of June, the patient was asymptomatic, with a thin layer of pericardial effusion in follow-up echocardiography. At 6 month and one-year follow-up the patient remained asymptomatic and without recurrence of pericardial effusion.

Discussion

The term post-cardiac injury syndromes includes the pericardial inflammation after MI, pericardiotomy or traumatic pericarditis. Such syndromes are presumed to have an autoimmune pathogenesis triggered by initial damage to pericardium.

This must be differentiated from post-surgical pericardial effusion, transudative or haemorrhagic and usually self-limited, and should be suspected if pleuritic chest pain with fever or haemodynamic instability, weeks or months, after surgery occurred.

#396 - Abstract

CAN CLASSIC BIOMARKERS BE PROGNOSTICATORS IN HEART FAILURE? DATA FROM THE REFERENCE STUDY

Mário Barbosa¹, Andreia Matos^{2,3}, Manuel Bicho^{2,3}, Luiz Menezes Falcão^{4,3}

¹ Department of Internal Medicine, Hospital Lusíadas Lisboa, Lisbon, Portugal

² Genetics Laboratory and Environmental Health Institute-ISAMB, Lisbon, Portugal

³ Lisbon Faculty of Medicine, Lisbon, Portugal

⁴ Department of Internal Medicine, Santa Maria Hospital, Lisbon, Portugal

Background

Although the role of natriuretic peptides and troponins as risk stratification markers is gaining importance, the European Society of Cardiology considers that, still, the amount of evidence is not sufficient to recommend its use as heart failure (HF) prognosticators.

We explored the relationship of aminoterminal B-type natriuretic peptide (NT-proBNP) and highly sensitive troponin T (hsTnT) with short-term prognosis (defined as the period of 90 days post-discharge), namely readmission due to HF and overall death, and long-term overall death.

Methods

NT-proBNP and hsTnT were assessed in patients hospitalized with acute decompensated heart failure in class III or IV of NYHA.

Univariate Cox proportional hazard model was used to evaluate the relationship between variables and outcomes.

The optimal cut-off value for each biomarker to predict the events was defined using the Youden Index.

Results

In total, 65 patients were followed for a median of 13.7 (Q1-Q3

6.7-18.9) months. Mean age was 79.2 (SD 10.8) years and 56.9% were female. The mean LVEF was 50.38 ± 19.07 %.

The hazard of short-term mortality increased 0.5% per increments of 100 ng/L of admission NT-proBNP (HR: 1.005, 95% CI: 1.002-1.009, P-value=0.002) and with a cut-off value of 21336 ng/L the risk was 10.5 times greater (HR: 10.524, 95% CI: 3.013-36.757, P-value<0.001).

The hazard for long-term mortality increased 0.3% per increments of 100 ng/L of admission NT-proBNP (HR: 1.003, 95% CI: 1.001-1.006, P-value=0.013) and the risk increased close to 5 times with determinations ≥21336 ng/L (HR: 4.791, 95% CI: 1.885-12.178, P-value<0.001).

Long-term mortality risk increased 0.6% per increments of 100 ng/L of discharge NT-proBNP (HR: 1.006, 95% CI: 1.001-1.011, P-value=0.028).

Long-term mortality risk increased 7.7% per increments of 10 ng/L of hsTnT (HR: 1.077, 95% CI: 1.007-1.151, P-value=0.030).

For values of hsTnT ≥52 ng/L and NT-proBNP ≥21336 ng/L the risk of early readmission increased 8.6 times (HR: 8.607, 95% CI: 1.413-52.427, P-value=0.020).

As for long-term mortality, values of hsTnT≥52 ng/L aggravated the hazard close to 5 times (HR: 4.942, 95% CI: 1.044-23.388, P value=0.044), which heightened to almost 6 times if NT-proBNP at admission ≥21336 ng/L was considered (HR: 5.827, 95% CI: 1.168-29.075, P value=0.032).

Conclusion

Elevated NT-proBNP and hsTnT determinations correlated with short and long-term outcomes. Moreover, their combined use provided complementary prognostic data and superior risk stratification.

#399 - Abstract

COMPRESSION LEG BANDAGING IS BENEFICIAL FOR PRIMARY PREVENTION OF POSTURAL HYPOTENSION AMONG ELDERLY PATIENTS IN AN INTERNAL MEDICINE WARD

Oleg Gorelik¹, Benny Papismadov^{1,2}, Irma Tzur¹, Shimon Izhakian¹, Dana Barchel¹, Muhareb Swarka¹, Hanni Phatel¹, Ilana Livshitz-Riven²

¹ Department of Internal Medicine, Zerifin, Israel

² Department of Nursing, The Leon and Mathilde Recanati School for Community Health Professions (affiliated to Faculty of Health Sciences, Ben-Gurion University of the Negev), Beer-Sheba, Israel

Background

Postural hypotension (PH) is a very common and often symptomatic disorder among elderly hospitalized patients. Little is known about measures for prevention of previously unknown PH in this population. We aimed to evaluate the effectiveness of lower limb high compression bandaging in preventing seated PH during the initial phase of ambulation, among elderly internal medicine inpatients.

Methods

Included were 200 patients hospitalized in internal medicine wards for various acute conditions, aged ≥ 70 years, bedridden for ≥ 12 hours and without a history of PH. Blood pressure, heart rate, dizziness and palpitations were registered before and at 1, 3 and 5 minutes following the first seating. In the intervention group (n=100), high compression extensible bandages were applied along both legs prior to seating. A comparison group (n=100) comprised unbandaged patients who were matched to participants from the bandaged group, by age, sex and bed rest duration. The primary outcome was the development of seated PH (composite of classic and delayed PH), defined according to the current guidelines.

Results

The rate of seated PH was significantly lower in the bandaged than the unbandaged group (27% vs. 51%, $p < 0.001$, relative risk reduction 47%, and the number of patients needed to treat 4.2). On multivariate analysis, not wearing leg bandaging was one of the variables most significantly associated with eventual occurrence of PH ($p = 0.002$, odds ratio 2.65 and 95% confidence interval 1.42–4.97).

Conclusion

During ambulation of elderly inpatients, high compression leg bandaging is beneficial to prevent seated PH.

#400 - Abstract

INSIGHTS FROM THE PREDICTORS OF EARLY READMISSION IN CHRONIC HEART FAILURE (REFERENCE) STUDY

Mário Barbosa¹, Andreia Matos^{2,3}, Manuel Bicho^{2,3}, Luiz Menezes Falcão^{4,3}

¹ Department of Internal Medicine, Hospital Lusíadas Lisboa, Lisbon, Portugal

² Genetics Laboratory and Environmental Health Institute-ISAMB, Lisbon, Portugal

³ Lisbon Faculty of Medicine, Lisbon, Portugal

⁴ Department of Internal Medicine, Santa Maria Hospital, Lisbon, Portugal

Background

Albeit we have assisted to a consistent decline in the rate of heart failure hospitalizations, surprisingly, short-term readmission and mortality persist high, irrespective of clinical innovations and guideline directed management, representing a tremendous health care burden. The main purpose of this study was to characterize at risk patients for early (defined as the period of 90 days post-discharge) readmission due to heart failure and overall death.

Methods

Adult patients admitted, to an Internal Medicine ward, with acute decompensated heart failure in class III or IV of NYHA were assessed.

Subgroup analysis was performed according to the left ventricular

ejection fraction (LVEF) in light of the current European Society of Cardiology guidelines.

Univariate Cox proportional hazard model was used to evaluate the relationship between variables and outcomes.

Results

In total, 65 patients were followed for a median of 13.7 (Q1-Q3 6.7-18.9) months. Mean age was 79.2 (SD 10.8) years and 56.9% were female. The mean LVEF was $50.38 \pm 19.07\%$.

The 90-day post-discharge readmission rate was 33.8% and the 30-day post-discharge readmission rate was 13.8%. The year readmission percentage was 61.5%.

The 30-day mortality prevalence was 10.8% and the 90-day mortality prevalence was 18.5%. The year mortality was 36.9% and 40% of the patients deceased at the end of the follow-up.

The length of stay (LOS) represented a risk factor for short-term readmission in the general population study (HR: 1.022, 95% CI: 1.009-1.036, P-value < 0.001).

In patients suffering from Heart Failure with Reduced Ejection Fraction (HFrEF) short-term readmission risk, due to the LOS, was slightly superior to that of the general population (HR: 1.029, 95% CI: 1.008-1.050, P-value = 0.006).

The number of hospitalizations was related with short-term readmission in the general population (HR: 1.543, 95% CI: 1.224-1.945, P-value < 0.001) and in the Heart Failure with Mid-Range Ejection Fraction (HFmrEF) subgroup (HR: 2.814, 95% CI: 1.075-7.365, P-value = 0.035).

A trend towards the LOS and short-term mortality, close to reaching statistical significance (HR: 1.016, 95% CI: 0.999-1.032, P value = 0.062), was identified in the general population study.

Conclusion

The high short-term readmission and mortality rates acknowledged are consentaneous with other studies. The LOS and the number of hospitalizations were associated with worse short-term outcome.

#407 - Case Report

STROKE AND ENDOCARDITIS - WHEN THE CULTURES ARE NEGATIVE

Marco Ferreira Fernandes, Maria João Correia, Catarina Araújo Faria, Nuno Ribeiro Ferreira, Teresa Mesquita, Luís Campos Hospital São Francisco Xavier, Lisbon, Portugal

Introduction

Blood culture-negative infective endocarditis (IE), occurring in 2-7% of IE cases, is defined as endocarditis without etiology following inoculation of at least three independent blood samples with negative cultures after five days. The frequency is higher in patients who have already been treated with antibiotics. The most frequent agents are fastidious organisms including zoonotic agents and fungi. Stroke is one of the most frequent embolic complications of this clinical condition.

Case description

We report the case of a 70 years old male with a 4 week history of fever and consumptive symptoms. He was treated with cefuroxime, considering the diagnosis of acute bacterial prostatitis. Admitted at the ER with sudden onset of left motor deficit, facial asymmetry and oculocephalic right deviation lasting 6 hours. The neurologic evaluation showed signs consistent with right medial cerebral artery total occlusion, NIHSS 17. CT-angiography revealed M1 segment occlusion of this artery without indication for thrombolysis or trombectomy. Laboratory findings included a normocytic normochromic anemia, without leucocytosis or neutrophilia but a C-reactive protein of 21 mg/dL. Transthoracic echocardiogram documented an aortic valve vegetation with significant leaflets destruction, prolapse and severe aortic regurgitation, confirmed by transesophageal echocardiography. Empiric antimicrobial therapy with ceftriaxone, gentamicin and vancomycin was initiated. Despite favorable laboratory evolution, the patient developed acute heart failure and cardiogenic shock and was submitted to aortic valve replacement with a biologic prosthesis. The pathologic analysis of the valve confirmed the presence of gram + organisms, although the blood cultures remained negative for 6 weeks.

Discussion

Despite extensive valve destruction, cardiogenic shock evolution and systemic embolization with stroke, suggesting systemic involvement by a pathogenic organism, no organism was identified on the repeated blood cultures. Previous treatment with cefuroxime may have contributed for these negative cultures. We point out the surgical valve replacement importance in cases of endocarditis complicated by severe systemic embolization.

#409 - Abstract

THE COMPLEMENTARY ROLE OF NOVEL CARDIAC FIBROSIS BIOMARKERS IN HEART FAILURE PROGNOSIS- A REPORT FROM THE REFERENCE STUDY

Luiz Menezes Falcão^{1,2}, Mário Barbosa³, Andreia Matos^{4,2}, Manuel Bicho^{4,2}

¹ Department of Internal Medicine, Santa Maria Hospital, Lisbon, Portugal

² Lisbon Faculty of Medicine, Lisbon, Portugal

³ Department of Internal Medicine, Hospital Lusíadas Lisboa, Lisbon, Portugal

⁴ Genetics Laboratory and Environmental Health Institute-ISAMB, Lisbon, Portugal, Lisbon, Portugal

Background

The vast data addressing emerging cardiac fibrosis markers as adjunctive to conventional clinical risk factors and natriuretic peptides dosing, led the American College of Cardiology/ American Heart Association to grant Galectin-3 (Gal-3) and Suppression of Tumorigenicity 2 (ST2) evaluation a class II recommendation for heart failure (HF) prognosis, in 2013. Yet, in Europe this

endorsement is not valid.

We studied the association of Gal-3 and ST2 with early (defined as the period of 90 days post-discharge) rehospitalization and overall mortality, and long-term overall mortality in HF patients.

Additionally, aminoterminal B-type natriuretic peptide (NT-proBNP) was considered to test if a multi-marker strategy could yield supplementary information.

Methods

Gal-3, ST2 and NT-proBNP were assessed in patients hospitalized, to an Internal Medicine ward, with acute decompensated HF in class III or IV of NYHA.

Univariate Cox proportional hazard model was used to assess the relationship between variables and outcomes.

Since there are no standardized cut-offs for Gal-3 and ST2, the multiclass Area Under the Curve Receiver-Operator Characteristic (AUCROC) as defined by Hand and Till was used to evaluate the overall performance of each biomarker as a predictor of the outcomes.

Results

In total, 65 patients were followed for a median of 13.7 (Q1-Q3 6.7-18.9) months. Mean age was 79.2 (SD 10.8) years and 56.9% were female. The mean LVEF was 50.38 ± 19.07 %.

Gal-3 correlated with early rehospitalization (HR: 9.886, 95% CI: 2.027-48.214, P-value=0.005), early death (HR: 13.731, 95% CI: 1.650-114.276, P value=0.015) and long-term mortality (HR: 4.492, 95% CI: 1.594-12.656, P-value=0.004).

The combination of elevated NT-proBNP determinations to Gal-3 further increased the risk for the mentioned outcomes (HR: 11.985, 95% CI: 1.962-73.218, P value=0.007), (HR: 18.837, 95% CI: 2.193-161.811, P-value=0.007) and (HR: 78.025, 95% CI: 7.592-801.926, P-value<0.001), respectively.

An association between ST2 and long-term mortality was acknowledged (HR: 4.846, 95% CI: 1.396-16.825, P-value=0.013). The risk augmented if elevated NT-proBNP values were also considered (HR: 5.953, 95% CI: 1.683-21.055, P-value=0.006).

Conclusion

High Gal-3 determinations correlated with early rehospitalization, early mortality and long-term mortality; whereas ST2 predicted long-term mortality.

Combined analysis with elevated NT-proBNP values further increased the outcome risk.

#411 - Abstract

THE PARAMOUNT IMPORTANCE OF RENAL FUNCTION IN HEART FAILURE PROGNOSIS - CONCLUSIONS FROM THE REFERENCE STUDY

Luiz Menezes Falcão^{1,2}, Mário Barbosa³, Andreia Matos^{4,2}, Manuel Bicho^{4,2}

¹ Department of Internal Medicine, Santa Maria Hospital, Lisbon, Portugal

² Lisbon Faculty of Medicine, Lisbon, Portugal

³ Department of Internal Medicine, Hospital Lusíadas Lisboa, Lisbon, Portugal

⁴ Genetics Laboratory and Environmental Health Institute-ISAMB, Lisbon, Portugal

Background

In heart failure (HF) patients renal dysfunction represents impaired tissue perfusion and is a predictor of poor outcome.

We investigated the association of customarily used renal function parameters with early (defined as the period of 90 days post-discharge) rehospitalization due to HF and all-cause mortality, and long-term all-cause mortality in HF patients.

Methods

Baseline and admission urea, creatinine and glomerular filtration rate (GFR) and type 1 cardiorenal syndrome (CRS) were evaluated in patients hospitalized with acute decompensated HF in class III or IV of NYHA.

Descriptive analysis was performed using t test or Wilcoxon Rank test.

Categorical variables were compared using chi-squared test or Fisher's Exact test.

Univariate Cox proportional hazard model was used to assess the relationship between variables and outcomes.

Results

In total, 65 patients were followed for a median of 13.7 (Q1-Q3 6.7-18.9) months. Mean age was 79.2 (SD 10.8) years and 56.9% were female. The mean left ventricular ejection fraction was 50.38±19.07%.

Variables associated with an increased risk for early rehospitalization were baseline urea (HR: 1.098, 95% CI: 1.022-1.179, P-value=0.01), admission urea (HR: 1.048, 95% CI: 1.013-1.084, P-value=0.006), baseline creatinine (HR: 1.111, 95% CI: 1.004-1.229, P-value=0.041), admission creatinine (HR: 1.047, 95% CI: 1.005-1.092, P-value=0.027), admission GFR <30 mL/min (HR: 3.535, 95% CI: 1.467-8.518, P-value=0.005).

Increased risk for short-term mortality was associated with baseline urea (HR: 1.145, 95% CI: 1.032-1.270, P-value=0.010), admission urea (HR: 1.076, 95% CI: 1.021-1.135, P-value=0.006), baseline creatinine (HR: 1.157, 95% CI: 1.009-1.328, P-value=0.037), admission creatinine (HR: 1.127, 95% CI: 1.055-1.204, P-value<0.001), admission GFR <30 ml/min (HR: 9.791, 95% CI: 2.855-33.580, P-value<0.001).

Variables associated with an increased risk for long-term

mortality were admission urea (HR: 1.056, 95% CI: 1.019-1.094, P-value=0.003), admission creatinine (HR: 1.104, 95% CI: 1.054-1.156, P-value<0.001), admission GFR <30 ml/min (HR: 3.906, 95% CI: 1.7208.871, P-value=0.001).

According to descriptive analysis short-term mortality risk was related with prior of chronic kidney disease (P-value=0.024). Type 1 CRS was linked to short-term mortality (P-value=0.004) and long-term mortality (P-value=0.011).

Conclusion

Renal dysfunction was a reliable predictor of worse prognosis as several parameters correlated with the proposed end-points.

#412 - Abstract

THE IMPACT OF LOW BLOOD PRESSURE IN HEART FAILURE OUTCOME - RESULTS FROM THE REFERENCE STUDY

Luiz Menezes Falcão^{1,2}, Mário Barbosa³, Andreia Matos^{4,2}, Manuel Bicho^{4,2}

¹ Department of Internal Medicine, Santa Maria Hospital, Lisbon, Portugal

² Lisbon Faculty of Medicine, Lisbon, Portugal

³ Department of Internal Medicine, Hospital Lusíadas Lisboa, Lisbon, Portugal

⁴ Genetics Laboratory and Environmental Health Institute-ISAMB, Lisbon, Portugal

Background

It urges to define short-term risk stratification given that in heart failure (HF) patients mortality is highest during the first 90 days post-discharge.

Low blood pressure plays a role in HF outcome as it is indicative of lack of tissue perfusion and more severe disease.

Decreased systolic blood pressure (SBP) and diastolic blood pressure (DBP) values correlate with impaired survival.

We studied the association of SBP <100 mmHg and DBP <60 mmHg at admission with early (defined as the period of 90 days post-discharge) all-cause mortality and long-term all-cause mortality in HF patients.

Methods

At admission SBP <100 mmHg and DBP <60 mmHg were evaluated in patients hospitalized, to an Internal Medicine ward, with acute decompensated HF in class III or IV of NYHA.

Subgroup analysis was performed according to the left ventricular ejection fraction (LVEF) in light of the current European Society of Cardiology guidelines.

Univariate Cox proportional hazard model was used to assess the relationship between variables and outcomes.

Results

In total, 65 patients were followed for a median of 13.7 (Q1-Q3 6.7-18.9) months. Mean age was 79.2 (SD 10.8) years and 56.9% were female. The mean LVEF was 50.38±19.07%.

In general population study, the hazard of short-term mortality for patients with admission SBP <100 mmHg was 5.3 times higher than that for patients with admission SBP \geq 100 mmHg (HR=5.330, 95% CI: 1.407-20.193, P-value=0.014).

As for long-term mortality, comparatively to short-term mortality, for the referred value of admission SBP (i.e. <100 mmHg) the risk declined to 3.6 times (HR: 3.629, 95% CI: 1.239-10.631, P-value=0.019).

Subgroup discrimination evidenced that long-term mortality hazard rose up to 6.3 times in the Heart Failure with Reduced Ejection Fraction (HFrEF) subgroup (HR: 6.303, 95% CI: 1.224-32.452, P-value=0.028).

The univariate Cox proportional hazard model estimated an increased risk of 11.1 times for short-term mortality in the HFrEF patients with admission DBP <60 mmHg (HR: 11.116, 95% CI: 1.000-123.564, P-value=0.05).

During follow-up the hazard declined to 8.5 times in the mentioned subgroup (HR: 8.462, 95% CI: 1.662-43.096, P-value=0.010).

Conclusion

The patients with admission SBP <100 mmHg or DBP <60 mmHg evolved with substantial increased risk of short and long-term mortality.

Interestingly, the hazard declined along follow-up which consubstantiates the assumption that the first 90 days post-discharge are critical in HF management.

#425 - Abstract

DESCRIPTIVE STUDY ABOUT THE PREVALENCE, TREATMENT AND CONTROL OF ARTERIAL HYPERTENSION IN THE PATIENTS OF INTERNAL MEDICINE.

Francisco Da Mata Alves, Isabel Arvanas Serrano, Beatriz Guerrero Sanchez, Laura Rueda Carrasco, Aurelia Elena Fuentes Caraballo, Julia Gonzalez Granados, Raquel Rostro Galvez, Rafael Aragon Lara

Hospital Universitario Badajoz, Badajoz, Spain

Background

Primary Objective: to study the antihypertension treatments used in internal medicine patients and their results.

Secondary Objectives: 1) To understand the prevalence of this cardiovascular risk factor in internal medicine patients. 2) To understand if the actual guidelines are used in the clinical practice. 3) To confirm if the treatments are adjusted in the cases in which the control is not maximized.

Material and Methods

Observational and descriptive study in which we included 120 patients discharged from the Internal Medicine service of our Hospital during the first 10 days of May of 2017, from which we excluded the ones discharged because of voluntary discharge or death. To select the patients we used electronic clinical histories

from our National Health Care Data Base (JARA®) and for the statistic analysis we used SPSS® (v15.0.1 de 2006).

Results

We included 120 patients, of which 73 has a diagnosis of arterial hypertension (HT), 42 women and 31 men, (58% and 42%), between the ages of 48 and 97 years old (average 78 years old). 5% of our patients only had dietary measures, 22% with only one antihypertension drug, 43% with an association of two drugs and 30% with three or more drugs.

If we consider the actual guidelines that suggest values lower than 140 mmHg systolic tension and 90 mmHg diastolic tension (and in cases of associated diabetes lower than 130 and 80 mmHg respectively) we observed that 75% of our patients were well controlled with the actual treatment. Between the patients with worst results (50% of them with grade 1 hypertension and 50% with grade 2 or superior hypertension) 78% received a therapeutical readjustment at the moment of discharge.

Discussion

HT is one of the main cardiovascular risk factors and one of the most frequently seen diseases in internal medicine services today. We consider that the majority of our patients are well treated and well controlled. Between the non controlled patients, the majority received a readjustment at discharge, using the actual guidelines, individualizing considering the possible comorbidities and other diseases.

Conclusions

With this study we observed that HT is a very frequent cardiovascular risk factor in our patients and that, in general, is well managed by the internist. It will be interesting to do a temporal follow-up in this patients to determine control after readjustment and quantify the incidence of complications from HT per se and treatment caused.

#426 - Abstract

DESCRIPTIVE STUDY ABOUT THE PREVALENCE OF CARDIOVASCULAR DISEASE, CONTROL OF ITS FACTORS AND ESTIMATION OF RISK IN INTERNAL MEDICINE PATIENTS

Francisco Da Mata Alves, Laura Rueda Carrasco, Aurelia Elena Fuentes Caraballo, Isabel Arvanas Serrano, Julia Gonzalez Granados, Beatriz Guerrero Sanchez, Raquel Rostro Galvez, Rafael Aragon Lara

Hospital Universitario de Badajoz, Badajoz, Spain

Background

Primary Objectives: Study the prevalence of the multiple cardiovascular risk factors (CVRF) either the ones changeable and the non changeable and the prevalence of Cardiovascular Disease (CVD) in our patients. Secondary Objectives: 1) To understand how

usable are the estimate risk tables in our patients. 2) To understand the risk of CV events at 10 years. 3) To see the prevalence of comorbidities the rise the prevalence of CVD.

Methods

Observational and descriptive study in which we included patients discharged from the Internal Medicine service of our Hospital during the first 10 days of May of 2017, from which we excluded the ones discharged because of voluntary discharge or death. We used electronic clinical histories from our database (JARA®) and for the statistic analysis with SPSS® (v 2006). To estimate the CVR we used SCORE tables till the age of 65 and the SCORE OP tables in older than 65.

Results

120 patients (55 female) were included, from 19 to 97 years old (average of 74 yo). 73 with the diagnosis of arterial hypertension (71% with good tensional control), 58 with the diagnosis of dyslipidemia (52% with good control), 44 patients diagnosed of diabetes (64% with good diabetic control), 28 patients had been smokers (currently 50% non smokers). If we consider as a non changeable risk factor sex/age, in relation to women older than 55 yo and men older that 45 yo, we can assume that 86% of our patients have this CVRF. 38% presented at least one major CVD event and 8% at least one minor event. 26% had a glomerular filtration estimation (GFS) less than 60 mL/min (factor of high risk of CVD) and 11% had a GFS less than 30 mL/min (factor of very high risk of CVD). About the risk estimate, 64% had a probability of >10% of having a letal event of CVD in 10 years and only 14% had a probability lower than 5% in 10 years. About the prevalence of comorbidities that raise the CVD risk, 77% of our patients had at least one.

Conclusion

We conclude that majority of our patient have, at least, one CVRF that raise the risk of CVD and that at a higher age there is a higher CVRF and prevalence of CVD events, as expectable. We recognize the good control of the changeable CVRF. Probably because of internal medicine patient profile, the average age and the pluripathology that it include, the results using the risk estimation tables were expectable. It will be interesting to do a follow-up to see the incidence of CVD, evolution of control of CVRF and the applicability of CVD stimation using SCORE tables.

#428 - Abstract

DESCRIPTIVE STUDY ABOUT THE PREVALENCE, TREATMENT AND CONTROL OF DIABETES MELLITUS IN THE PATIENTS OF INTERNAL MEDICINE

Francisco Da Mata Alves, Laura Rueda Carrasco, Julia Gonzalez Granados, Isabel Arvanas Serrano, Beatriz Guerrero Sanchez, Aurelia Elena Fuentes Caraballo, Rafael Aragon Lara, Raquel Rostro Galvez

Hospital Universitario Badajoz, Badajoz, Spain

Background

Primary Objectives – To study the antidiabetic treatments used in the internal medicine patients and the results obtained.

Secondary Objectives: 1) To understand the prevalence of this cardiovascular risk factor in internal medicina patients. 2) To understand if the actual guidelines are used in the clinical practice. 3) To confirm if the treatments are adjusted in those cases in which the control is not maximized.

Methods

Observational and descriptive study including 120 patients discharged from the Internal Medicine service of our Hospital during the first 10 days of May of 2017, from which we excluded the ones discharged because of voluntary discharge or death. To select the patients, we used electronic clinical histories from our National Health Care Data Base (JARA®) and for the statistic analysis we used SPSS® (v15.0.1 de 2006).

Results

We included 120 patients, 50 of which had the previous diagnosis of diabetes mellitus, 28 women and 22 men, between 68 and 90 years old (average 80 years old). 10% were treated only with dietary measures, 19% only with metfomine, 39% with an association of metformine and another oral antidiabetic, 23% oral antidiabetic associated with insuline and 9% only with insuline. The average glicosilated hemoglobine (HbA1c) was from 6.89%. Considering the actual guidelines that suggest levels of HbA1c under 7% we can assume that 68% of our patients are well controlled. Between the patients not controlled 73% are older than 75 years old and 83% received a readjustment in therapy at discharge.

Conclusion

DM is one of the main cardiovascular risk factor and one of the most frequent diseases seen in internal medicine services today. We consider that the majority of our patients are well treated and well controlled (68%) according to the actual guidelines. On the other hand, most of the patients not controlled are older than 75 yeras old and guidelines tend to be less restrictive in the control of this kind of patients (because of the high level of comorbidities and complications): approximately 80% of these patients have the HbA1c less than 8%. Between the other non controlled patients, the majority received a readjustment at discharge, using the actual guidelines and individualized considering the possible comorbidities and other diseases.

It will be interesting to do a temporal follow-up in these patients to determine control after readjustment and quantify the incidence of complications from HT per se and treatment caused.

#439 - Case Report

SEVERE HYPOKALEMIA MIMICS MYOCARDIAL INFARCTION

Yaser Hussein Alwali, Wasim Saeed Derma
Alsadaka Teaching Hospital, Aden, Yemen

Introduction

A severe body potassium deficit may produce remarkable changes in the ECG. These changes can result in incidental findings on the 12 lead ECG or precipitate potentially life threatening arrhythmias. Although usually readily recognized, at times these abnormalities may be confused with myocardial infarction. The objective was to report a case of severe hypokalemia mimicking myocardial infarction.

Case description

A 45 year old diabetic woman was referred from Cholera center to Medical ICU in Alsadaka hospital presented with progressive weakness and shortness of breath. The ECG showed a ST segment depression in lead I, II, aVL, aVF, V3. The initial diagnosis was flaccid V6, quadriparesis for evaluation and non ST elevation myocardial infarction. Cardiac enzymes were within normal limits and echocardiography was not done at that time. A more detailed history revealed that the patient had an episode of acute gastroenteritis with diarrhea and vomiting due to cholera. Serum chemistries were notable for a potassium concentration of <1 mmol/L. With aggressive electrolyte correction, the ECG changes reverted as potassium levels became near normal range.

Discussion

Hypokalemia induced STsegment depression may simulate myocardial infarction. The differential diagnosis might be difficult, especially when ST changes occur in the patients with risk factors.

#444 - Abstract

LENGTH OF STAY AND ACUTE HEART FAILURE

Sandra Díaz De Castellví¹, Francesc Formiga¹, Rafael Moreno-Gonzalez¹, David Chivite¹, Michelle Friscia², Xavier Corbella¹

¹ Bellvitge University Hospital, Barcelona, Spain

² Hospital Esperit Sant, Barcelona, Spain

Background

Heart failure is a major public health concern. It commonly affects older population and has a high morbimortality rate. Our purpose is to evaluate in elderly patients experiencing a first admission for acute heart failure (HF) the importance of HF hospitalization length of stay (LOS) as a predictor of a negative event, either hospital HF unplanned readmissions or all-cause mortality within 30 days.

Methods

We reviewed the medical records of 846 consecutive patients >74

years of age admitted within a three-year period because of a first episode of AHF. LOS was categorized in four quartiles as Q1 0-2 days (n=242), Q2 3-4 days (n=244), Q3 5-7 days (n=173) and Q4 ≥8 days (n 187). The association between LOS and readmissions and mortality were evaluated.

Results

Mean age was 83.5 ± 6 years. There were 59.7% women. The mean of LOS, The median (interquartile range) of LOS was 4 (2-7) days. At 30 days after discharge, 43 patients died (5%) and 113 (13.4%) patients showed an unplanned admission by HF. In total, 156 patients (18.4%) showed a negative event within 30 days after discharge either HF readmissions or death. Multivariate analysis confirmed the association between long LOS and higher risk of presenting combined event of global mortality or HF readmissions (hazard ratio 1.197, 95% CI: 1.023–1.401, p=0.025). Lower systolic blood pressure (Hazard Ratio 0.986), and lower estimated glomerular filtration rate values (Hazard Ratio 0.991) were also associated with a negative outcome within 30 days after discharge.

Conclusion

In elderly patients hospitalized for the first acute HF episode, longer LOS, is a predictor of early global mortality or HF readmission within 30-days after discharge.

#451 - Case Report

FROM PRIMARY TO SECONDARY HYPERTENSION

Sara Santos, Sara Gomes, Célia Carmo, Fátima Campante
Centro Hospitalar Barreiro Montijo, Setúbal, Portugal

Introduction

About 90 to 95% of high blood pressure (HBP) cases are classified as essential, because there is not an identified aetiology. The others are classified as secondary hypertension, since they are a secondary manifestation of an underlying disease.

The authors present a case of a woman with the diagnosis of essential hypertension, that due to sudden resistance to antihypertensive drug therapy, the etiologic study for secondary hypertension had to be redone and a primary hyperaldosteronism was diagnosed.

Case description

A 39 year old, female patient with a know history of hypothyroidism and HBP.

Usual medication: levothyroxine 0.25 mcg, amlodipine 5 mg/ losartan160 mg, amlodipine 10 mg and spironolactone 25 mg.

She was first diagnosed at the age of 36, when she had a blood pressure (BP) of 190/140 mmHg and complaints of intense headache and neck pain.

Secondary etiologies were excluded in an outpatient setting and so essential hypertension was presumed. Her BP values were

stable under the prescribed medication.

The patient got pregnant and had her BP controlled with methyldopa and 6 months after delivery, restarted the previous medication.

On follow up she mentions a BP of 150/100mg, without other complaints.

On her routine blood samples hypokalemia was present.

Therefore the authors decided to repeat the workup for secondary aetiologies.

On blood and urine samples were evident a hyperaldosteronism, high levels of catecholamines and noradrenaline.

Through abdominal computed tomography (CT) scan a mass of well defined limits was seen in the right adrenal gland, with a length of 1.7cm, suggestive of an adenoma.

It was surgically removed and the pathology report confirmed a primary hyperaldosteronism.

After excision the patient no longer needed antihypertensive medication.

Discussion

Conn's syndrome or primary hyperaldosteronism is the most common secondary aetiology for HBP, but it can be a challenge to diagnose.

Initial complaints of headache and neck pain in a young patient with HBP are suggestive but the workup with hormonal dosing is difficult due to physiological variations and also CT scan's low sensitivity for small adenomas.

Probably hormonal changes during pregnancy were responsible for the increase in the adenoma's size and activity, leading to a worsening of symptoms with new onset of hypokalemia and HBP resistant to therapy.

After its excision, the BP was normal, confirming the hypothesis of an unnoticed primary hyperaldosteronism from the beginning.

#472 - Medical Image

ARTERIAL CALCIFICATION

Rodrigo Rufino, Catarina Carvalho, Alexandra Albuquerque, Fátima Campante

Centro Hospitalar Barreiro-Montijo, Barreiro, Portugal

Clinical summary

We present a male 81 years old patient, admitted in the hospital with the diagnosis of chronic heart failure and a history of venous and arterial insufficiency.

As he was complaining of pain in his left knee, we performed a x-ray where it was identifiable the calcification of the popliteal artery.

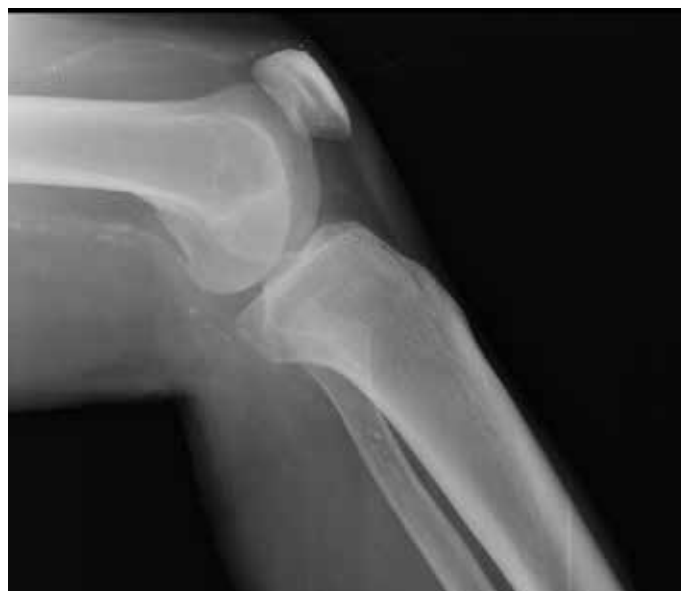

Figure #472.

#483 - Abstract

PREVALENCE OF NEOPLASIA IN PATIENTS WITH PULMONARY EMBOLISM IN AN INTERNAL MEDICINE WARD

Tiago Barroso, Joana Caetano, José Delgado Alves

Hospital Professor Doutor Fernando Fonseca, Amadora, Portugal

Background

In patients with unprovoked pulmonary embolism (PE), the incidence of newly diagnosed cancer is approximately 5%. Our goals were to determine the prevalence of occult cancer in the population of patients admitted in our Internal Medicine ward and to find predictors of occult cancer which could help further investigation.

Methods

Retrospective review of all patients admitted in our Internal Medicine ward with a new diagnosis of PE, between 2010-2017. The presence of occult cancer was defined as any cancer diagnosed at the time of the PE up to one year after discharge. Variables analyzed: clinical and demographic characteristics, provoked/unprovoked PE, known risk factors for PE, CT scan performed for occult cancer screening, proposed predictors of occult cancer: constitutive symptoms (anorexia, weight loss) and laboratory features (complete blood count, erythrocyte sedimentation rate, liver tests, prostate specific-antigen).

Results

A total of 169 patients had a diagnosis of PE, median age of 71 years, 64% women. The most common risk factors were arterial hypertension, tobacco use, obesity and immobilization. A total of 6 cancers were diagnosed: breast cancer (n=2), pancreatic adenocarcinoma (n=1), colon adenocarcinoma (n=1), hepatocellular carcinoma (n=1 and metastases of unknown

primary cancer (n=1). The incidence of occult cancer was 3.8%. The incidence in patients with no known cancer and unprovoked PE was 5.6%. Forty-five abdominal and pelvic CT scans were performed. Of those, an occult cancer was diagnosed in 4 patients. The thoracic CT scan performed for the diagnosis of PE found 1 cancer. The presence of anorexia and weight loss was specific (<5% of patients without cancer), but not sensitive (40% of patients with cancer). Prevalence of the remaining variables was similar in both groups. In 4 of the cancers, symptoms and initial lab evaluation were enough to direct the investigation of the cancer. We did not find any variables that performed clearly better than the clinical judgement of the attending medical doctor.

Conclusion

The incidence of cancer in patients with unprovoked PE is low (5.6%), in line with the values published in the literature. No single clinical or laboratory variable can be used to decide whether screening for cancer should be pursued. Both history and clinical examination can help to decide whether or not to search for cancer in this subgroup of patients and are more useful than screening by CT scan.

#493 - Abstract

DETERMINANTS OF ORAL ANTICOAGULANT PRESCRIPTION IN OLDER PATIENTS WITH NON-VALVULAR ATRIAL FIBRILLATION IN A MEMORY CLINIC: IS IT ALL ABOUT FALLS?

David Folino, François Herrmann, Max Scheffler, Gemma Gabriel, Giovanni B. Frisoni, Gabriel Gold, Dina Zekry, Aline Mendes
Geneva University Hospitals - Hôpital des Trois-Chêne, Geneva, Switzerland

Background

Atrial fibrillation (AF) is the most common arrhythmia in the older population and the main indication of oral anticoagulant (OAC) prescription.

Although the prescription of OAC in patients with AF worldwide increased since the introduction of direct oral anticoagulants, patients with dementia have lower odds of receiving OAC.

We aim to investigate which factors are associated with the prescription of OAC in patients with AF in a memory clinic.

Methods

Cross-sectional retrospective analysis of 613 patients from in-patient and out-patient memory clinic from Geneva University Hospitals. All patients underwent standardized brain MRI and neuropsychological assessment with diagnosis confirmed by an expert. Clinical data, including all comorbidities and ongoing treatment were collected retrospectively from patient's medical records at the time of brain MRI. We compared three subgroups of patients: without AF (N=542), with AF under OAC (N=49) and with AF without OAC (N=22).

Results

Our cohort of 613 patients is composed of 63.8% of female patients, the mean age is 77.5 years old and half of them live alone. 52.3% of patients were diagnosed with Alzheimer's, vascular or mixed dementia.

The prevalence of AF was 12% (71/613), of whom 69% (49/71) had an OAC prescription. Patients with AF without OAC in comparison to patients with AF under OAC and patients without AF had increased prevalence of heart failure (45.5% Vs. 32.7% Vs. 10.7%, $p<0.0001$) and recurrent falls (54.5% Vs. 12.2% Vs. 15.3%, $p<0.0001$). AF patients without OAC take more medications (6.23 Vs. 6.1 Vs. 5.1, $p=0.007$), with increased prescription of antiplatelet (72.7% Vs. 1.4% Vs. 22.6%, $p<0.0001$). Interestingly, clinical scores to assess thromboembolic and hemorrhagic risks were not helpful differentiating AF patients with and without OAC - CHADS₂VASC (0-9 points): 3.84 Vs. 4.14, $p=0.151$ and HAS-BLED (0-9 points): 3.06 Vs. 3.09, $p=0.349$. Patients without OAC had increased prevalence of a past history of upper gastrointestinal bleeding (9.1% Vs. 2%, $p=0.012$) and subdural hematoma (13.6% Vs. 2%, $p=0.015$).

Conclusion

Recurrent falls are the most important clinical factor related to OAC use in AF patients, besides expected contraindications related to gastrointestinal bleeding and subdural hematoma. On the other hand, clinical scores were not significantly associated with the decision to prescribe OAC in this population.

#501 - Abstract

COMPARISON OF HEMODYNAMICS AND PROGNOSIS BETWEEN DIFFERENT ETIOLOGY GROUPS WITH PULMONARY HYPERTENSION DUE TO LEFT HEART FAILURE

Ruilin Quan, Jianguo He

Fuwai Hospital, National Center for Cardiovascular Diseases, Chinese Academy of Medical Sciences and Peking Union Medical College, Beijing, China

Background

Pulmonary hypertension due to left heart failure of different etiology can have different hemodynamics, prognosis and related prognostic predictors. The aim of this study was to identify the differences in hemodynamics and prognosis between two etiology groups.

Methods

We prospectively enrolled patients with pulmonary hypertension due to left heart failure whose etiology were hypertension or cardiomyopathy. Echocardiography, left and right heart catheterization (RHC) were performed at baseline and follow-up was performed every 6 months \pm 2 weeks. We compared baseline characteristics between two etiology groups and separately

performed survival analyses to evaluate prognosis and identify related prognostic predictors.

Results

In total, a cohort of 67 patients was enrolled and the etiology of 20 patients was hypertension while that of others was cardiomyopathy. At baseline, compared to patients with cardiomyopathy, patients with hypertension had a lower left ventricular end diastolic diameter (LVEDD) (59.55 ± 11.56 vs. 46.30 ± 7.97 mm, $P < 0.001$) and right ventricular diameter (RVD) (25.49 ± 8.33 vs. 23.05 ± 9.20 mm, $P = 0.034$) but higher left ventricular ejection fraction (LVEF) (38.85 ± 15.34 vs. $57.25 \pm 10.34\%$, $P < 0.001$) and mean right atrial pressure (RAP) (11.36 ± 6.08 vs. 15.63 ± 4.79 mmHg, $P = 0.009$). Diastolic pressure gradient (DPG) > 7 mmHg was a significant predictor for mortality in patients whose etiology of heart failure was cardiomyopathy (HR: 6.998, 95% CI: 1.357-36.092, $P = 0.020$) and the significance retained after adjusted for age, sex and LVEF in multivariate Cox model (HR: 8.354, 95% CI: 1.316-53.043, $P = 0.024$). However, DPG was not a significant predictor in patients with hypertension in neither univariate nor multivariate Cox analyses.

Conclusion

The hemodynamics and prognostic predictors in patients with pulmonary hypertension due to left heart failure of different etiology can be different. It is essential to find specific hemodynamic predictors and cut-off values in different etiology groups.

#503 - Abstract

REFRACTORY FINDINGS OF CONGESTION: PREDICTORS OF WORSE OUTCOME IN HEART FAILURE - FACTS FROM THE REFERENCE STUDY

Andreia Matos^{1,2}, Mário Teixeira Barbosa³, Manuel Bicho^{1,2}, Luíz Menezes Falcão⁴

¹ Genetics Laboratory and Environmental Health Institute-ISAMB, Faculdade de Medicina da Universidade de Lisboa, Lisboa, Portugal

² Instituto de Investigação Científica Bento da Rocha Cabral, Lisboa, Portugal

³ Department of Internal Medicine, Hospital Lusíadas Lisboa, Lisboa, Portugal

⁴ Department of Internal Medicine, Santa Maria Hospital, Lisboa, Portugal

Background

Hepatomegaly is a cardinal sign of refractory congestion; while the absence of inferior vena cava (IVC) inspiratory collapse is a well-known echocardiographic parameter of congestion.

These findings are indicative of lack of response to diuretics, a marker of reduced tissue perfusion and poorer outcome.

We investigated the association of hepatomegaly and the absence of IVC inspiratory collapse with early (defined as the period of 90 days post-discharge) all-cause mortality and long-term all-cause mortality in heart failure (HF) patients.

Methods

Hepatomegaly and IVC inspiratory collapse were evaluated in patients hospitalized, to an Internal Medicine ward, with acute decompensated HF in class III or IV of NYHA. Descriptive analysis was performed using t test or Wilcoxon Rank test as applicable. Categorical variables were compared using chi-squared test or Fisher's Exact test as applicable.

Results

In total, 65 patients were followed for a median of 13.7 (Q1-Q3 6.7-18.9) months. Mean age was 79.2 (SD 10.8) years and 56.9% were female. The mean left ventricular ejection fraction was $50.38 \pm 19.07\%$.

Hepatomegaly was observed in only 1.9% of the patients that survived the first 90 days post-discharge versus 25% of those who deceased in that period. The difference between the two groups was statistically significant (P -value=0.018).

As for long-term mortality, hepatomegaly was observed in 15.4% of the patients that died, but unremarkable in the survivors (P -value=0.022).

We acknowledged that the absence of IVC inspiratory collapse was far more frequent in the group that died during the first 90 days post-discharge (33.3%) than in the survivor group (9.4%). The difference between the two groups was significant (P -value=0.015). Regarding long-term mortality, the absence of IVC inspiratory collapse was observed in only 2.6% of the patients who survived compared to 30.8% of those who died during follow-up (P -value < 0.001).

Conclusion

Both hepatomegaly and the absence of IVC inspiratory collapse were predictors of short and long-term all-cause mortality. Swift identification of this high-risk group could contribute to improve HF prognosis.

#505 - Abstract

IS BUNDLE BRANCH BLOCK USEFUL IN HEART FAILURE RISK STRATIFICATION? DISCLOSURES FROM THE REFERENCE STUDY

Andreia Matos^{1,2}, Mário Teixeira Barbosa³, Manuel Bicho^{1,2}, Luíz Menezes Falcão⁴

¹ Genetics Laboratory and Environmental Health Institute-ISAMB, Faculdade de Medicina da Universidade de Lisboa, Lisboa, Portugal

² Instituto de Investigação Científica Bento da Rocha Cabral, Lisboa, Portugal

³ Department of Internal Medicine, Hospital Lusíadas Lisboa, Lisboa, Portugal

⁴ Department of Internal Medicine, Santa Maria Hospital, Lisboa, Portugal

Background

Although it has been reported that QRS prolongation ≥ 120 msec, in heart failure (HF) patients, is associated with increased all-cause mortality and even sudden death, there is conflicting data regarding

its direct impact on mortality. Ventricular dyssynchrony as an effect of anomalous conduction could justify the adverse outcome in the case of left bundle branch block (LBBB); while patients with QRS ≥ 120 msec with right bundle branch block (RBBB) morphology frequently have more severe bi-ventricular dysfunction. We analyzed the association of LBBB and RBBB with early (defined as the period of 90 days post-discharge) rehospitalization and all-cause mortality, and all-cause long-term mortality in HF patients.

Methods

Bundle branch block was assessed in adult patients admitted, to an Internal Medicine ward, with acute decompensated heart failure in class III or IV of NYHA.

Subgroup analysis was performed according to the left ventricular ejection fraction (LVEF) in light of the current European Society of Cardiology guidelines. Descriptive analysis was performed using t test or Wilcoxon Rank test as applicable. Categorical variables were compared using chi-squared test or Fisher's Exact test as applicable. Univariate Cox proportional hazard model was used to evaluate the relationship between variables and outcomes.

Results

In total, 65 patients were followed for a median of 13.7 (Q1-Q3 6.7-18.9) months. Mean age was 79.2 (SD 10.8) years and 56.9% were female. The mean LVEF was $50.38 \pm 19.07\%$. The presence of LBBB determined a short-term mortality risk 3.4 times superior in the general population study (HR: 3.444, 95% CI: 1.051-11.293, P-value=0.041). In the Heart Failure with Reduced Ejection Fraction (HFrEF) subgroup, LBBB increased the risk for long-term mortality 4.1 times (HR: 4.140, 95% CI: 1.021-16.790, P-value=0.047). Descriptive analysis showed that only 4.7% of the non-early readmitted patients presented RBBB versus 13.6% in the early readmitted patients (P-value=0.049).

Conclusion

In our study LBBB was a marker of short-term mortality risk in the overall population study. Regarding long-term survival, LBBB was also a predictor of worse outcome in the HFrEF subgroup. We were, also, able to detect a link between RBBB and early HF readmission in the general population study. Our findings suggest that bundle branch block implicates a worse outcome in HF patients, prompt recognition of this high-risk group could help to offer tailored treatment in order to improve prognosis.

#526 - Abstract

CAN WE REALLY HAVE CONTROL OVER ARTERIAL HYPERTENSION IN TRAIN CREW?

Yulia Venevtseva, Elena Kazidaeva, Aleksandr Melnikov

Medical Institute of Tula State University, Tula, Russia

Background

Some work demands are specific to train drivers: high emotional and mental demands, small amount of autonomy and skill

discretion. Beside this, train drivers are exposed to several cardiovascular disease risk factors that can result in sudden incapacity due to arterial hypertension (AH). Echocardiography (EchoCG) gives the opportunity to evaluate heart reaction to the antihypertensive therapy.

The study aimed to examine dynamics of EchoCG parameters in train drivers with mild controlled AH.

Methods

A 4-year prospective cohort study was conducted in 53 male workers (train drivers and their assistants) aged 25-59 years with mild controlled AH who received annual health check-ups at a Russian railway company.

15 males were included in 25-39 years' group, 23 - in 40-49 and 15 - in 50-55 years' group. EchoCG was made by Medison EKO 7 using standard M, D and Doppler mode.

Results

No differences between groups were found in 2013: end-diastolic left ventricular diameter was 50.1; 50.4 and 49.9 mm; interventricular septum (IVS) thickness - (M \pm m) 9.9 ± 0.9 , 11.0 ± 1.2 and 10.4 ± 1.0 mm, and posterior wall thickness - 9.4 ± 1.2 ; 10.2 ± 1.2 and 10.4 ± 1.0 mm. In 2017 right ventricle (RV) diameter in the young group got bigger (25.8 ± 1.9 vs 27.3 ± 2.0 mm, P<0.05) and IVS became thicker (9.9 ± 0.9 vs 10.7 ± 1.4 mm, P<0.05). In the 40-49 years' group only ejection volume have decreased from 83.5 ± 9.8 to 75.6 ± 9.9 ml (P<0.01). In the older group no dynamics was found.

To elucidate factors influenced on negative changes in Echo parameters all drivers were divided into 2 groups: 20 males with IVS thickening from 10.2 to 11.7 mm and 33 drivers without changes. Work experience in the first group was significantly bigger (17.3 ± 9.9 vs 13.0 ± 7.8 years), and age of work onset was lesser (25.9 vs 30.5 years). Despite the Echo parameters in 2013 did not differ, RV in the first group in 2017 was greater (28.3 ± 2.3 vs 27.0 ± 1.8 mm; p<0.05).

Total cholesterol level in the first group in 2013 was bigger (5.1 ± 0.7 and 4.6 ± 1.0 mmol/L; p<0.05), but was the same in 2017 (5.4 ± 1.0 and 5.0 ± 0.7 mmol/L). In the second group only total cholesterol has increased (p<0.05).

Conclusion

The main factors affecting negative Echo dynamics in train drivers were work experience, time of work onset and total cholesterol level. The most informative Echo parameters were RV diameter and IVS thickness. Thus, AH may be considered as a controlled risk factor using antihypertensive medication in train crew.

#531 - Abstract

BENEFIT OF SYSTEMIC THROMBOLYSIS IN PATIENTS WITH CHRONIC KIDNEY DISEASE AND PULMONARY EMBOLISM

Lukas Hobohm, Ingo Sagoschen, Thomas Münzel, Karsten Keller
Center for Cardiology, Cardiology I, University Medical Center Mainz,
Rheinland-Pfalz - Mainz, Germany

Background

Renal dysfunction is a well-established risk factor for fatal outcome in various cardiovascular diseases. Previous studies demonstrated that impaired renal function was associated with a poor prognosis in patients with acute pulmonary embolism (PE). Little is known about the use and the benefit of systemic thrombolysis in PE patients with chronic kidney disease (CKD).

Methods

Patients diagnosed with PE based on ICD-code I26 in the German nationwide database were stratified for presence of CKD and compared regarding adverse in-hospital outcomes. (source: RDC of the Federal Statistical Office of the federal states, DRG Statistics 2011-2015, own calculations).

Results

Between January 2011 and December 2014, 320,767 patients with acute PE (53.3% females) aged ≥ 18 years were included in this analysis; of those, 15.5% had a CKD. PE patients with acute kidney injury were excluded from the analysis. PE patients with CKD were older (77.0 vs. 67.0 years, $P < 0.001$), more frequently female (57.9% vs. 52.2%, $P < 0.001$), had more often comorbidities such as coronary artery disease (26.3% vs. 10.8%, $P < 0.001$) or heart failure (40.8% vs. 16.6%, $P < 0.001$) and presented more often with RV dysfunction (31.6% vs. 25.2%, $P < 0.001$) and shock (3.5% vs. 2.6%, $P < 0.001$). Overall, 41,226 (12.9%) patients died during in-hospital stay. PE patients with CKD had a higher mortality rate (16.6% vs. 12.2%, $P < 0.001$) compared to those PE patients without renal dysfunction and thus, a higher risk of in-hospital mortality in the univariate logistic regression model (OR, 1.4 [95% CI, 1.4-1.5], $P < 0.001$).

Systemic thrombolysis was less often administered in PE patient with CKD (3.5% vs. 4.1%, $P < 0.001$). In all PE patients with CKD, thrombolysis was accompanied by an reduced risk to die during hospitalization (OR 0.86, 95% CI, 0.82-0.90; $P < 0.001$). The favorable association between thrombolysis and CKD patients differs across CKD stages. Although, the highest mortality rates were found in PE patients with CKD stage 5 (38.6%), PE patients with CKD stage 5 demonstrated no benefit by thrombolytic treatment (in-hospital death: OR, 1.4 [95% CI, 1.2-1.7]; $P < 0.001$).

Conclusion

CKD is associated with an increased in-hospital mortality rate in PE patients. Overall, systemic thrombolysis was associated with a reduced in-hospital mortality rate in PE patients with CKD. However, in PE patients of CKD stage 5 systemic thrombolysis had no beneficial impact on survival.

#533 - Abstract

IN-HOSPITAL OUTCOMES AFTER PERCUTANEOUS LEFT ATRIAL APPENDAGE (LAA) CLOSURE - 5-YEAR EXPERIENCE IN GERMANY

Lukas Hobohm, Karsten Keller
Center for Cardiology, Cardiology I, University Medical Center Mainz,
Rheinland-Pfalz - Mainz, Germany

Background

The safety and efficacy of percutaneous left atrial appendage (LAA) closure has been demonstrated in randomized trials and prospective cohort studies, while results from large samples are missing. Thus, we aimed to evaluate 5-years experiences of in-hospital trends and safety outcomes of LAA closure in the German nationwide inpatient sample.

Methods

We analyzed data on patients' characteristics and in-hospital safety outcomes for all percutaneous LAA closures in Germany performed between 2011 and 2015 (source: RDC of the Federal Statistical Office and the Statistical Offices of the federal states, DRG Statistics 2011-2016, own calculations).

Results

Overall, 15,895 in-patients were included. Annual number of LAA occlusions increased from 1,347 in 2011 to 4,932 in 2015 (β 1.00 [95%CI 0.95 to 1.01; $p < 0.001$]) with a non-significant uptrend of in-hospital mortality (0.5% in 2011 to 0.9% in 2015; β 0.01 [95%CI -0.09 to 0.32; $p = 0.271$]). Non-survivors were older than survivors (78 [IQR, 73-78] vs. 76 [71-80] years, $P < 0.001$) and showed more frequently important comorbidities including cardiovascular diseases such as heart failure (59.1% vs. 29.8%, $P < 0.001$) and coronary artery disease (58.4% vs. 45.0%, $P = 0.001$), but also cancer (3.2% vs. 1.3%, $P = 0.050$), chronic renal insufficiency (50.6% vs. 27.9%, $P < 0.001$) and COPD (22.1% vs. 10.4%, $P < 0.001$). Important independent predictors of in-hospital mortality were cancer (OR 2.49 [95%CI 1.00-6.12], $p = 0.050$), heart failure (OR 2.42 [95%CI 1.72-3.41], $p < 0.001$), stroke (OR 5.39 [95%CI 2.76-10.53], $p < 0.001$), acute renal failure (OR 13.28 [9.08-19.42], $p < 0.001$), pericardial effusion (OR 5.65 [95%CI 3.76-8.48], $p < 0.001$) and shock (OR 45.11 [95%CI 31.01-65.58], $p < 0.001$).

Conclusion

The use of percutaneous LAA closures increased 3.6-fold from 2011 to 2015 with a non-significant uptrend of in-hospital mortality rate in this real-world setting. Important predictors of in-hospital death were acute renal failure, pericardial effusion and ischemic stroke during hospitalization.

#535 - Case Report

FOR THE FIRST TIME REGISTERED COMPLETE LEFT BUNDLE-BRANCH BLOCK: THE DIFFICULTY OF DIAGNOSTICS ON THE EXAMPLE OF A CLINICAL CASE

Kristina Pereverzeva, Sergey Yakushin, Anastasia Novoselova
Ryazan State Medical University, Ryazan, Russia

Introduction

Identified on an electrocardiogram (ECG), a complete left bundle-branch block (LBBB) in the presence of ischemic symptoms is a basis for suspecting myocardial infarction (MI) in a patient. The tactics of management of such patients is similar to the management of the patients with myocardial infarction with ST-segment elevation.

Purpose

To demonstrate the difficulty of determining the cause of development of LBBB in patients with chest pain.

Case description

Patient C., aged 45, applied on 09/09/18 at 18:30 to the central regional hospital with complaints of general weakness and oppressive, compressive pain behind the sternum, which proceeded at rest, lasting for about 30 minutes. ECG: sinus rhythm, LBBB. On examination: the frequency of respiratory movements is 20 per minute, heart rate (HR) 65 beats/min, blood pressure (BP) is 120/80 mm Hg Art. A alteplase thrombolytic therapy (TLT) was performed according to the scheme. After TLT on an ECG: sinus rhythm, LBBB is not detected. Troponin T 10/09/18 - 0.987 ng/ml. Transferred to the regional clinical hospital for percutaneous coronary intervention. On presentation the state a moderate. SpO₂ 90%. The heart rhythm is correct. HR 60 beats/min, BP: right arm 84/50 mm Hg Art., left arm 120/70 mm Hg Art. On ECG: sinus rhythm, the electrical axis of the heart is rejected to the left. In history: hypertensive disease with max BP 180/100 mm Hg Art during the year; not treated. In blood biochemistry troponins I 0.00 ng/ml → 0.06 ng/ml → 0.00 ng/ml. With coronary angiography: atherosclerotic lesions of the coronary arteries were not detected. On the computed tomography of the chest with a contrast the is of the aneurysm of the ascending aorta with signs of dissection to the level of the arc. An ultrasound examination of the aortic arch vessels on the right in the brachiocephalic stem determines the intimal detachment until its bifurcation, 2 lumens are formed: one, partially thrombosed, has the form of a blind bag, the other takes less than 20%. 13/09/18 at 6:30 - the patient is unconscious, he has bradycardia, turning into asystole, and hypotension; resuscitation is without effect; at 7:00, biological death is attested.

Discussion

ECG changes and increased troponin level typical for MI should not be absolute criteria for excluding other alternative diagnoses. The asymmetry of blood pressure on both arms allowed to suspect dissecting aneurysm in the patient: 84/50 mm Hg Art on the right arm, 120/70 mm - Hg Art. on the left arm.

#545 - Case Report

ACUTE PERICARDITIS AND PARTIAL PERICARDIUM AGENESIS: CASE REPORT AND LITERATURE REVIEW

Carlota Tuñón De Almeida, Jose Antonio Ortiz De Murua López, Sara Muñoz Alonso, Victor Madrid Romero, Victoria Palomar Calvo, Juan José Torres Ramos, Carlos Aldasoro Frías, Montserrat Chimeno Viñas, Luis Miguel Palomar Rodriguez
Complejo Asistencial de Zamora, Zamora, Spain

Introduction

Congenital partial absence of pericardium is an unusual disorder often found incidentally in thoracic surgery, imaging studies or postmortem examinations, because patients are generally asymptomatic. We here present a case of partial pericardium agenesis which was initially diagnosed of acute pericarditis. We aim to report healthcare providers about this rare condition to reduce misdiagnosis and take into account for further differential diagnoses.

Case description

A 46-year-old male with a history of unidentified congenital heart disease was referred to our institution for acute onset of pleuritic chest pain and was diagnosed with acute pericarditis. Symptoms resolved rapidly with non-steroidal anti-inflammatory drugs. Physical and analytical exploration did not show any relevant data. The 12-lead electrocardiogram demonstrated sinus rhythm with right bundle branch block and hourly rotation. The chest X-ray showed a displaced cardiac silhouette on the left, and echocardiogram showed normal right ventricle dilation without other interesting data. In view of the findings, suggestive of possible agenesis of pericardium, a cardiac magnetic resonance imaging (MRI) was performed. Cardiac MRI showed right-sided pericardium but no pericardium present over the lateral wall of the left ventricle and heart apex displaced to the left.

Discussion

We briefly review the literature about this rare congenital anomaly, since approximately 400 cases have been published, and the diagnosis is often necrotic. Chest x-ray and echocardiography are important for suspicion, but CT and cardioresonance are essential to assess the location of agenesis and predict probable future complications, such as herniation of cavities through apical myocardial constriction defects. This is so because the deadly cases published presented agenesis in that area. Most defects go unnoticed for years and are not symptomatic. Only a small group of them should be treated by the closure of the defect or pericardiectomy.

#601 - Medical Image

MASSIVE PULMONARY THROMBOEMBOLISM- MEDICAL IMAGES

Paulo Ferreira¹, Vanessa Machado¹, Cristina Ramalho¹, Hilda Freitas², Natalia Oliveira², Antonio Cabral²

¹ TrofaSaude Hospital Braga Centro, Braga, Portugal

² TrofaSaude Hospital Braga Sul, Braga, Portugal

Clinical summary

A 28 year-old woman with a history of asthma and anxiety came to our hospital with wheezing and anxiety. She presented with tachycardia (sinus). After bronchodilator and anxiolytic therapy, tachycardia remained without dyspnea. We suspected of pulmonary embolism (EP). It was confirmed, with the presence of exuberant massive EP, bilateral, with dilated right cavities at echocardiogram. Adequate therapy was done, with clinical improvement. Currently asymptomatic. The mother of the patient, a nurse at a Central Hospital of our country, thanked us for the care to the daughter and was convinced that another hospital may have considered asthma and anxiety as the only problems she presented, thanking us for saving her daughter's life. An exhaustive study did not detect etiology, yet.

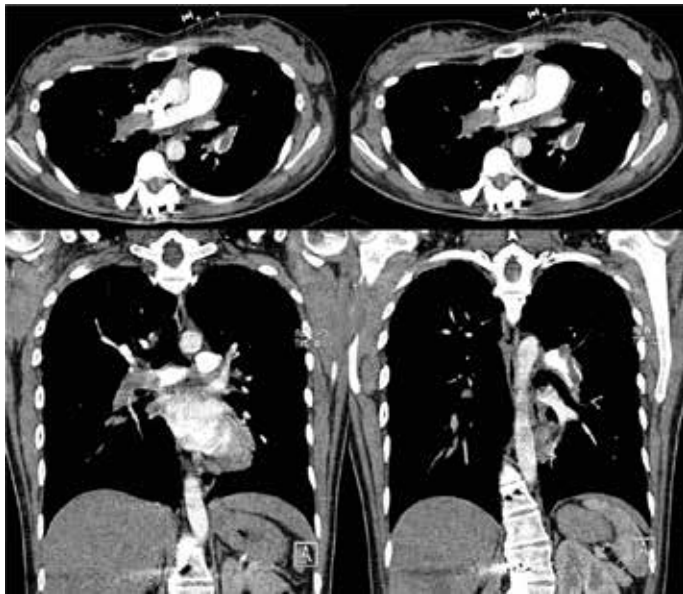


Figure #601.

#605 - Case Report

HEMOLYTIC ANEMIA FOLLOWING MITRAL VALVE REPAIR: A LATE PRESENTATION

Shalini Sri Kumaran

Singapore General Hospital, Singapore, Singapore

Introduction

Mitral valve repair (MVR) has been widely regarded as the optimal surgical procedure to treat mitral regurgitation(MR). Hemolytic anemia is a rare complication following MVR and is often under-recognized. It usually manifests within the first 6 months of the

procedure. We report a case of hemolytic anemia that presented 6 years post MVR.

Case description

A 60-year-old male presented to the hospital with new onset gross hematuria. His medical history was significant for a previous subdural hematoma for which he had underwent a right decompressive craniectomy in 2012 and a MV annuloplasty in 2013 for severe MR. In 2017, he had evidence of mild anterior MV prolapse seen on an echocardiogram. Clinically he appeared lethargic, but his vital signs were stable. He had conjunctival pallor. He was not jaundiced. Cardiovascular examination revealed normal heart sounds and a grade 3/6 pan-systolic murmur over the apex. The rest of his physical examination was normal. Frank hematuria was draining into the urine bag. Investigations revealed anemia with a hemoglobin (Hb) of 7.5 g/dL (baseline 11.5 g/dL) and he received a blood transfusion. His creatinine was normal at 58 umol/L. An extensive urological work-up only revealed candiduria repeatedly. He was started on oral fluconazole, which resolved his hematuria, however, his Hb continued to drop. A hemolytic anemia work-up showed an elevated lactate dehydrogenase (LDH) of 9682 U/L, decreased haptoglobin of < 0.1 G/L, elevated bilirubin of 34 UMOL/L, and a peripheral blood film of fragmented cells in varied sizes and shapes and increased polychromatic cells. The direct antiglobulin test and the Donath Landsteiner test were negative. A bone marrow aspirate and trephine done was also normal. An echocardiogram revealed severe MR with multiple regurgitation jets and very turbulent flow arising from the sub-annular plane which was new. Given the results, he was diagnosed with hemolytic anemia secondary to his now failed MVR. The hematuria was a red herring and he is now awaiting surgery.

Discussion

This report illustrates a case of hemolytic anemia which was initially in doubt as a complication of MVR, not only because of its infrequency, but due to its late presentation and the presence of a red herring. The mechanism of hemolysis has been reported to stem from mechanical trauma due to turbulence of outflow and current literature implies that the optimal treatment remains surgical with re-repair or replacement of the valve as resolution is unlikely on its own.

#624 - Abstract

EMBOLIC RISK STRATIFICATION AND PROGNOSTIC IMPACT OF EARLY SURGERY IN LEFT-SIDED INFECTIVE ENDOCARDITIS

Valentina Scheggi, Bruno Alterini, Lorenzo Roberto Suardi, Filippo Bartalesi, Nicole Ceschia

Azienda Ospedaliero-Universitaria Careggi, Firenze, Italy

Background

In patients with left-sided infective endocarditis and heart failure associated with large vegetations, early surgery has a definite

indication and prevents embolic events. However, optimal timing of surgery for other indications is still unresolved particularly when the presence of large vegetations represents the only indication.

Methods

We retrospectively analyzed 195 consecutive patients admitted to our department between 2013 and 2017 with definite left-sided infective endocarditis according to the modified Duke University criteria. Long-term follow-up was systematically obtained by structured telephone interviews on July 2018.

Available international guidelines were followed to plan diagnostic procedures and treatment strategies. Of the 195 patients, 151 (77%) underwent cardiac surgery, 29 low-risk patients received medical treatment, 10 were not operated due to prohibitive surgical risk and five refused surgery.

We compared surgical to medical therapy, and early to delayed surgery. In addition, we analyzed factors associated with embolic risk. All-cause mortality represented the study end-point.

Results

Overall survival was 78% at 4 years. Patients not operated because of risk or refusal had the worst prognosis, while outcome in high-risk operated patients was comparable to that of low-risk patients treated medically. Early (<2 weeks from diagnosis) surgery was associated with similar survival compared to delayed surgery. Embolic events were detected in 35% of cases, and *Staphylococcus Aureus* etiology was the main risk factor associated with embolism (OR 4, $p < 0.05$). Vegetation size >10 mm was also independently associated with embolic risk ($p = 0.033$) whereas renal failure, age, gender, endocarditis, type of valve, perivalvular extension and degree of valve regurgitation were not.

Conclusion

Compared to low-risk infective endocarditis patients treated medically, those at high-risk showed comparable survival when managed surgically, whereas a conservative approach was associated with an adverse prognosis. *Staphylococcus Aureus* infection and size of vegetations >10 mm were the best independent predictors of systemic embolism. Our data support aggressive surgical management of high-risk IE patients and highlight the importance of etiological characterization in clinical decision-making.

#628 - Abstract

HEART FAILURE: BETWEEN HEART AND PERIPHERAL SKELETAL MUSCULATURE

Paola Paolicelli, Francesca Passerini, Fabiana D'Onofrio, Lucia Donatella Grimaldi, Enrica Settimo, Anna Belfiore, Stefania Pugliese, Piero Portincasa, Vincenzo Ostilio Palmieri

Clinica Medica, Bari, Italy

Background

Congestive heart failure is characterized by dyspnea and reduced

exercise tolerance. The severity of the functional limitation has poor correlation with the degree of left ventricular dysfunction at rest, while peripheral alterations (blood flow, pulmonary, endothelial, neuroendocrine, muscular) can become the limiting factor of the effort.

Aims of the work are: to evaluate the morphological, dynamic and biohumoral alterations of skeletal muscle in patients with chronic heart failure. Secondary objectives are: to evaluate the modifications of these parameters during therapeutic treatment and with some parameters (NYHA class, lower limb edema, degree of stasis liver, skeletal muscle mass).

Methods

The study was conducted on 31 patients (13 males and 19 females, with an average age of 82 ± 8.9) hospitalized for "acute heart failure" and evaluated at the time of hospitalization (T0) and at discharge (T1). The following were performed: clinical evaluation, biohumoral examinations, echocardiography, thoracic, abdominal and muscular ultrasound, elastosonography (2D Share Wave with Logiq E9 XDClear GE ultrasound, stiffness value expressed in m/sec) hepatic, splenic and muscular.

Results

The stiffness of the muscle: at rest it does not differ significantly in the muscle of patients with heart failure compared to that of the control subjects (2.14 ± 0.5 vs 2.1 ± 0.3 , n.s.); in the contracted muscle it increases progressively from patients with decompensation to time 0 (lower limb right 5.03 ± 1.3), to that of patients with decompensation to time 1 (lower limb right 5.8 ± 1.3), to that of normal subject (lower limb right 6.5 ± 0.6 ; ANOVA $p < 0.001$); in the muscle contracted at time T1 is lower in subjects in class NYHA 4 (5.4 ± 1.4) compared to those in class NYHA 3 (6.3 ± 1.1 , $p < 0.04$). Muscle stiffness does not differ with FE values. It correlates negatively with hepatic vein diameter, hepatic stiffness, inferior cava vein dilatation, PAPs (Pearson correlation analysis).

Conclusion

By mean of muscular elastosonography we can hypothesize that the reduction of asthenia (and therefore of the NYHA class) is associated with greater muscular strength and efficacy; in these patients, the involvement of the skeletal muscular apparatus can be a determining factor for the onset of asthenia and reduced tolerance to physical effort. Elastosonography can be an accurate mean of recognizing the presence of deficits in muscle contraction in patients with heart failure.

#630 - Abstract

INCIDENCE AND OUTCOME OF PATIENTS WITH ACUTE PULMONARY EMBOLISM AND PREGNANCY

Lukas Hobohm, Karsten Keller

Center for Thrombosis and Hemostasis (CTH), University Medical Center Mainz (Johannes Gutenberg-University Mainz), Mainz, Germany, Mainz, Germany

Background

Pulmonary embolism (PE) is the leading cause of maternal mortality. Clinical diagnosis of pulmonary thromboembolism in pregnancy remains difficult because of pregnancy associated (physiological) symptoms and signs mimicking PE. We aimed to investigate the incidence, risk factors and outcomes of pregnant women with acute PE.

Methods

Women aged between 18 and 50 years diagnosed with PE based on ICD-code I26 in the German nationwide database were stratified for presence of pregnancy and compared regarding incidence, treatment and outcomes (source: RDC of the Federal Statistical Office and the Statistical Offices of the federal states, DRG Statistics 2005-2016, own calculations).

Results

Between January 2005 and December 2016, 63,246 women with acute PE aged between 18 and 50 years were included in this analysis; of those, 2.9% were pregnant. The in-hospital mortality rate was considerably lower in pregnant women compared to those females without pregnancy (3.5% vs. 7.3%, $P > 0.001$).

Pregnant women with acute PE were younger (31.0 (IQR 27.0/35.0) vs. 41.0 (IQR 32.0/46.0) years, $P < 0.001$), had less often comorbidities such as coronary artery disease (0.4% vs. 1.3%, $P < 0.001$), cancer (0.7% vs. 13.3%, $P < 0.001$), renal insufficiency (0.2% vs. 1.1%, $P < 0.001$), diabetes mellitus (1.1% vs. 5.6%, $P < 0.001$) or heart failure (4.3% vs. 7.0%, $P < 0.001$).

Interestingly, pregnant women with acute PE presented less often with deep venous thrombosis (6.0% vs. 38.5%, $P < 0.001$), RV dysfunction (12.6% vs. 24.4%, $P < 0.001$) and syncope (0.8% vs. 1.5%, $P < 0.001$), but were more often tachycardic (4.2% vs. 3.3%, $P = 0.001$). Notably, presence of shock (3.6% vs. 2.9%, $P = 0.052$) and cardiopulmonary resuscitation (5.5% vs. 5.1%, $P = 0.455$) were not different between pregnant and not-pregnant woman.

Conclusion

The diagnosis and management of PE in pregnant women are aggravated by the physiological changes of pregnancy and the paucity of studies done in pregnant patients. Signs of hemodynamic compromise such as RV dysfunction or syncope were less prevalent in pregnant women with acute PE than in those without pregnancy. Female PE patients aged between 18 and 50 years without pregnancy had a significant higher mortality rate indicating for an outstanding relevance of RV dysfunction,

syncope and important comorbidities such as cancer and heart failure for in-hospital prognosis.

#639 - Abstract

PREVALENCE OF VENTRICULAR ARRHYTHMIAS IN POST-MYOCARDIAL INFARCTION PATIENTS AND THE INFLUENCE OF ELECTROLYTE IMBALANCE

Luis Benjamin Godínez, Gabriel Antonio Rios, Cesar Gerardo López

Instituto Guatemalteco de Seguridad Social, Guatemala, Guatemala

Background

Several studies have shown that the presence of ventricular arrhythmias is an independent risk factor for subsequent mortality in patients recovering from acute myocardial infarction. There is also evidence that the imbalance of magnesium and potassium can influence the development of ventricular arrhythmias. However, this has not been well studied in our population. The aim of the present study was to establish the prevalence of ventricular arrhythmias in post-myocardial infarction patients and the influence of electrolyte imbalance.

Methods

Twenty-four-hour Holter recordings obtained before discharge from the hospital in 147 post-myocardial infarction patients were analyzed for the presence of ventricular arrhythmias. Levels of potassium, magnesium and peak troponin were obtained, and multivariate analyses were calculated.

Results

Ventricular arrhythmias were present in 78.2% of the patients, more than 10 premature ventricular beats per hour were recorded in 4.1% of the patients, and nonsustained ventricular tachycardia was present in 3.4% of the patients. The presence of ventricular arrhythmias was not statistically significant when compared with Holter recordings obtained from patients for reason other than myocardial infarction. In patients older than 75 years old, levels of potassium greater than 5 mmol/l and magnesium lower than 2 mg/dl predicted a 35.2% appearance of multifocal premature ventricular beats and in the same age group levels of potassium lower than 4 mmol/l and levels of magnesium lower than 2 mg/dl predicted a 58% appearance of one premature ventricular beat per hour.

Conclusion

This study shows that approximately 22% of patients recovering from acute myocardial infarction presented with less than one premature ventricular beat per hour in Holter recordings obtained before discharge from the hospital, and only around 5% of patients showed frequent (more than 10 premature ventricular beats per hour) ventricular arrhythmias. The electrolyte imbalance was associated with both more complex ventricular arrhythmias and more frequent premature ventricular beats.

#644 - Case Report

EMBOLIC STROKE AS INITIAL PRESENTATION OF INFECTIVE ENDOCARDITIS - DUKE CRITERIA REVISITED

Mariana Fidalgo, Tiago Gregório

Centro Hospitalar Vila Nova Gaia / Espinho, Vila Nova De Gaia, Portugal

Introduction

Infective endocarditis (IE) refers to infection of one or more heart valves. It can present as an acute and rapidly progressive infection or have an insidious evolution with nonspecific symptoms. Complications of IE are mostly due to septic embolization, which can present in the form of embolic stroke.

Case description

A 20-year-old male patient presented to the ER with sudden onset of imbalance and facial asymmetry after physical exertion. He reported occasional fever and fatigue in the previous months and a history of dental treatments in the preceding year.

At presentation he was febrile (40°C), tachycardic (165 bpm) and normotensive (109/64 mmHg). Neurologic examination showed an aphasia, right homonymous hemianopia, right-sided hemiparesis with facial involvement and right-sided hypoesthesia, with a NIHSS score of 10. Blood tests showed an elevated C-reactive protein (4.4 mg/dL) with normal WBC. A cerebral CT scan with angio CT showed an occlusion of the left middle cerebral artery. The patient underwent thrombolysis and thrombectomy, with complete recanalization and neurologic improvement (NIHSS of 4).

Blood cultures were collected and sent for microbiology, along with the thrombus retrieved from thrombectomy. A transesophageal echocardiogram revealed a vegetation in the mitral valve suggestive of endocarditis with associated severe valve insufficiency. An empiric course of antibiotics was started (vancomycin plus gentamicin).

Microbiology of both blood cultures and thrombus isolated a *Streptococcus anginosus*. A definite diagnosis of IE was established based on modified Duke criteria and antibiotics were switched to ceftriaxone plus gentamicin, according to susceptibility tests. The patient underwent valve replacement surgery and had a complete recovery, with no neurological deficits.

Discussion

The modified Duke criteria are an important diagnostic tool in infective endocarditis. Positive blood cultures are one of the major criteria, but, as this case report demonstrates, it is also possible to isolate the pathogenic organism from septic embolus sent to the brain. Therefore, it is reasonable to send clots retrieved from thrombectomy for microbiological culture if the patient presents with fever or any other sign or symptom suggestive of septic embolization due to infective endocarditis.

#662 - Abstract

HEART RATE VARIABILITY, QT INTERVAL DISPERSION AND TPEAK-TEND INTERVAL IN PATIENTS ON LONG-TERM HORMONE THERAPY FOR ADVANCED PROSTATE CANCER

Andrei Cristian Dan Gheorghe, Gabriela Silvia Gheorghe, Ana Ciobanu, Andreea Simona Hodoroagea, Ioan Tiberiu Nanea

Prof Th Burgele Hospital, Bucharest, Romania

Background

The antiandrogenic hormonal therapy is very useful in the treatment of advanced prostatic cancer but there are not data about their possible cardio-vascular effects.

Aim

To evaluate the effects of direct androgen receptor inhibitor enzalutamide in advanced prostate cancer on the cardiac electrical parameters in patients (pts) in sinus rhythm (SR)

Methods

We evaluated 40 men (pts) with advanced prostate cancer treated by orchiectomy and enzalutamide. We noted clinical history and excluded pts with atrial fibrillation, NYHA III and IV class heart failure (HF), acute myocardial infarction (AMI) within the last 6 months, chronic renal disease stages IV-V. We performed ECG, Holter ECG and evaluated QT interval dispersion (QTd), Tpeak-Tend interval (Tpe) in V5 lead, heart rate variability (HRV) using standard deviation of normal-to-normal interval over 24 hours (SDNN-24h), the square root of the mean squared differences of successive NN intervals (rMMSD) and the rate low frequency/high frequency (LF/HF) at the beginning of the treatment (V1) and 6 months later (V2). We noted in each pts the variations of the QTc, QTd, Tpe, SDNN 24 h, rMS-SD, LF/HF between V1 and V2 and Lown class of ventricular premature beats (VPB) on Holter ECG. Statistical analysis was performed using Epi Info 8: paired t-test for comparing the differences and correlation test.

Results

Pts were 71.8 +/-10 years old. 77.5% pts had arterial hypertension, 52.5 % stable angina, 25 % old myocardial infarction, 22.5% diabetes mellitus, 20 % chronic renal disease grade I-IIIb. They were stable throughout the study. Mean LVEF was 60+/-5%, and did not vary. Between V1 and V2 67.5% pts had a statistical significant increase of the QTd (+ Δ QTd) and 25 % pts a non significant increase of Tpe (ΔTpe). Mean +ΔQTd was 93+/-10 ms, mean +ΔTpe was 11+/-6 ms. 60 % pts had a significant decrease of SDNN-24. 50 % of them having concomitant increase of QTd. There was no change of the rMMSD and LF/HF ratio between V1 and V2. We did not note an increase in the number or severity of VPB between V1 and V2.

Conclusion

67.5% pts with advanced prostate cancer receiving enzalutamide

for 6 months had a significant prolongation of QTd and 60 % a significant decrease of SDNN-24 suggesting an increase of the myocardial electrical instability. During this period there was no change in the number or severity of VPB.

#665 - Abstract

OBSERVATIONAL CASE-SERIES STUDY OF ANTICOAGULANT THERAPY IN NON-VALVULAR ATRIAL FIBRILLATION IN A NON-SELECTED COMMUNITY POPULATION

Andrei Cristian Dan Gheorghe¹, Gabriela Silvia Gheorghe², Cristina Elena Georgescu², Alina Stefania Luiceanu², Andrei Georgian Florescu², Andreea Simona Hodoroagea², Ioan Tiberiu Nanea²

¹ Prof Th Burgehele Hospital, Bucharest, Romania

² Prof Th Burgehele Hospital, Bucuresti, Romania

Background

New oral anticoagulants (NOAC) are increasingly prescribed for stroke prevention in patients with non-valvular atrial fibrillation (NVAF).

Purpose

The objective of this study is to provide a view on anticoagulant therapy in an unselected, real-world, population of patients with NVAF, treated in a community setting.

Methods

Retrospective, observational case-series study of NVAF patients using antithrombotic K antagonists (AVK) (acenocumarol) or NOAC (apixaban, rivaroxaban or dabigatran) for stroke prevention, as recorded in our specialized-care center. The study includes consecutive patients that presented between Jan 1st and Dec 31st 2018, who were assessed for stroke risk using CHA₂DS₂-VASc score and for bleeding risk using HAS BLED score.

Results

A total of 186 patients diagnosed with NVAF (mean age 72.2 ± 9.7 years, 53.8% women, 71% from urban areas) were evaluated in a cardiac ward. Upon admission, 85 patients (45.7%) had received no anticoagulant therapy, 36 (19.4%) were treated with NOAC and 63 (33.9%) with AVK. 24 patients (38.1%) treated with AVK were within therapeutic international normalized ratio range (INR of 2-3). 146 patients (78.5%) were assessed with an increased risk of stroke (CHA₂DS₂-VASc score ≥1 for men and ≥2 for women) of which, 64 (43.8%) had no previous stroke prophylaxis; 20 patients (51.3% of total low-risk patients) were treated with either AVK or NOAC. Following reassessment, 163 patients (87.6%) received prophylaxis with OAC of which, 58.9% with NOAC. While 33 patients (17.7%) with low risk received OAC, 16 patients (10.9%) with medium and high risk remained untreated because of HAS BLED risk ≥ 3. 16 patients (9.8% of total treated) developed a minor hemorrhage when administered AVK (4.6%), NOAC (10.9%).

Conclusion

Our study shows that in the real world nearly one in two patients with NVAF remains untreated and two thirds of those receiving AVK are not therapeutically controlled in the community. Upon reevaluation in a cardiac ward, 90% of moderate and high-risk patients received oral anticoagulant medication, without serious bleeding events. We observed the increased use of NOAC, with more minor bleeding than with AVK.

#668 - Abstract

INFERIOR VENA CAVA FILTER: RETROSPECTIVE ANALYSIS IN A THIRD LEVEL HOSPITAL

Sergio Moragón Ledesma, Laura Abarca Casas, Lucía Ordieres Ortega, Christian Mario Amodeo Oblitas, Irene García Fernández-Bravo, Jorge Del Toro Cervera, Francisco Galeano Valle, Pablo Demelo Rodríguez

HGU Gregorio Marañón, Madrid, Spain

Background

The role of anticoagulation in venous thromboembolism has been broadly documented in the last decades. Preventing the migration and extension of the thrombus is the main therapeutic goal; however, in certain situations anticoagulation is either contraindicated or ineffective. In this scenario, inferior vena cava filters (IVCF) may be useful to prevent the thrombus from reaching pulmonary circulation.

Methods

From a cohort of patients with venous thromboembolism, we selected those who required introduction of IVCF in a third level hospital. Demographic data of the patients and characteristics of each filter were collected. A descriptive retrospective analysis was obtained through our local database.

Results

The sample included 1956 patients with VTE; 57 patients (2.9%) required IVCF placement. Median age of IVCF patients was 68.84 years, with relative predominance for masculine gender. Among cardiovascular risk factors, arterial hypertension was registered in 50.9% of the sample, diabetes mellitus (14%), dyslipidemia (24.6%) and smoking (10%). 5.3% had suffered from ischemic heart disease and cerebrovascular disease. Ongoing cancer was involved in 36.8%, and 1.8% had peripheral arteriopathy. On the previous month, 33.3% had suffered a severe bleeding event, and 19.3% had a recent surgery. Thrombocytopenia (<50.000/mm³) was shown in 3.5%. Furthermore, 54.4% of patients presented pulmonary embolism (with or without deep vein thrombosis), and 45.6% had only deep venous thrombosis. Concerning filter characteristics, the most frequent type was Celect®, nevertheless the data was not collected in 72% of the cases. 50.9% of the implanted filters were permanent, and 49.1% retrievable, of which approximately half were removed. Finally,

complications were registered in 19.3% of patients, being inferior vena cava thrombosis the most frequent one, followed by filter obstruction or inclination.

Conclusion

Although anticoagulation is the mainstay of treatment for venous thromboembolism, inferior vena cava filter might be a useful alternative when anticoagulation is not a choice. However, due to the lack of evidence regarding this procedure and the risk of complications, confronting risks and benefits must always be taken into account. New prospective randomized trials are required to broaden the current knowledge about IVCF.

#671 - Case Report

A RARE CASE OF “NON-RHEUMATIC” GIANT LEFT ATRIUM

Maria João Castro¹, Filipa Cordeiro², Sofia Carvalho², Sara Borges², Pedro Carvalho², Márcia Souto², José João Monteiro², Fernando Gonçalves², José Pedro Guimarães², Miguel Móz², José Ilídio Moreira²

¹ ULSNE, Bragança, Portugal

² CHTMAD, Vila Real, Portugal

Introduction

Giant left atrium (GLA) is a rare condition with a reported incidence of 0.3%, and following mainly rheumatic mitral valve disease. Rheumatic heart disease represents the main cause of giant left atrium, but other etiologies have been reported. GLA has significant hemodynamic effects and requires specific management.

Case description

A sixty-seven-year-old Caucasian woman was admitted for progressive exertional dyspnea. She had a history of mitral valve replacement with a Starr-Edwards prosthetic valve twenty-eight years before due to rheumatic mitral stenosis, atrial fibrillation, pacemaker implantation nine years earlier and chronic kidney disease. The chest X-ray revealed a marked cardiomegaly with a cardiothoracic ratio of 0.95. Computed tomography revealed a giant left atrium (GLA), causing compression of other cardiac chambers and lungs. Transthoracic echocardiography confirmed the striking dilation of left atrium (LA), which measured 78 mm in anteroposterior diameter and 1500 ml in three-dimension volume. There was also severe pulmonary hypertension, pressure overload of the right ventricle and normal systolic function of both ventricles. Transesophageal echocardiography revealed no prosthetic valve dysfunction and marked spontaneous echo contrast in LA, although adequate hipocoagulation. Pulmonary function tests revealed severe restrictive and obstructive pattern.

Discussion

The patient was diagnosed with GLA, a rare condition mainly associated with rheumatic heart disease that can cause embolic

events, sudden cardiac death and symptoms related with compression of the adjacent structures. It was considered that dyspnea was associated with the compression of the lungs and airways and with severe pulmonary hypertension. The management of this entity is not well established, particularly the role of LA reduction in the absence of mitral native valve disease or prosthesis dysfunction. Since it was decided the surgical risk was very high, the patient was discharged with medical therapy.

#681 - Abstract

CORRELATIONS BETWEEN VITAMIN D DEFICIENCY AND VASCULAR RIGIDITY PARAMETERS IN HYPERTENSIVE PATIENTS

Ovidiu Cosmin Iancu¹, Daniela Adina Moteli², Petru Bucuras³, Abhinav Sharma⁴, Florina Buleu⁴, Simona Dragan⁴

¹ Regina Maria Private Clinic, Timisoara, Romania

² Fresenius Nephrocare Clinic, Timisoara, Romania

³ Emergency County Hospital Pius Brinzeu, Timisoara, Romania

⁴ University of Medicine and Pharmacy Victor Babes, Timisoara, Romania

Background

In adults, low levels of vitamin D have been reported to be associated with hypertension. The aim of this study was to evaluate the relationship between vitamin D levels and vascular rigidity parameters in hypertensive patients.

Methods

145 patients were selected from a database of 680 hypertensive subjects addressed to our clinic in 2018. We obtained informed consent for participation in the study. Mean age was 63.6±6, 24.4% female and 75.6% male, under antihypertensive treatment, without confirmed coronary artery disease. Diabetic patients were excluded from the study. Blood pressure was measured according to the 2018 ESC/ESH Guidelines: 20% were stage 1, 43% stage 2 and 37% stage 3. We recorded anthropometric parameters (BMI). Echocardiographic measurements were taken in M-mode, 2D, continuous and colour Doppler using VIVID7 GE ultrasound. Serum levels of 25-OH vitamin D3 (25-OH D3) were determined by ELISA. Aortic pulse wave velocity (PWVAo) was determined using the Arteriograph device. Carotid intima-media thickness (CIMT) was measured using high resolution ultrasound and RRI by duplex Doppler in the intrarenal segmentary arteries. Ankle-brachial index (ABI) was measured using the standard Doppler technique. Albuminuria was measured in urine samples with dipstick. Glomerular filtration rate (GFR) was calculated using CKD-EPI formula. The Pearson correlation test was used for interpretation of results.

Results

Mean values: SBP was 146.6±18.8mmHg, DBP 86±12mmHg, GFR 51.95±10.7ml/min/1.73m², IVS 12.8±2.2mm, LVPW 12.4±1.78mm, EF45.9±6.7%, 25-OH D3 24.57±4.49ng/mL. Pearson linear correlation model: 25-OH D3 significantly correlated

with BMI ($p<0.003$), albuminuria ($p<0.031$), CIMT ($p<0.0001$), ABI ($p<0.0001$), PWVAo ($p<0.0001$) and RRI ($p<0.0001$).

Linear regression model: significant predictors considering 25-OH D3 as dependent variable were GFR ($p<0.001$), CIMT ($p<0.004$), ABI ($p<0.011$) and RRI ($p<0.0001$).

Association between 25-OH D3 deficit and gender did not establish a significant correlation (Mann-Whitney U Test, $p=0.428$).

Two by two comparisons between HT stages revealed significant differences between stages 1 and 3 ($p<0.001$) and 2 and 3 ($p<0.001$) regarding 25-OH D3 deficit.

Conclusion

The results of this study are suggestive for a potential contribution of 25-OH D3 deficit to vascular rigidity in hypertensive patients. Future studies should clarify the consequences of correcting this deficit on the improvement of vascular rigidity parameters according to the stage of hypertension.

#703 - Abstract

INCIDENCE OF UNKNOWN VENOUS THROMBOEMBOLISM IN PATIENTS ADMITTED IN INTERNAL MEDICINE DEPARTMENT FOR DYSPNOEA AND / OR RESPIRATORY FAILURE

Mattia Bellan¹, Bonometti Ramona¹, Emma Avitabile¹, Silvia Strada¹, Micol Giulia Cittone¹, Elena Boin¹, Eleonora Rizzi¹, Azzurra Re¹, Flavio Bobbio², Mauro Campanini², Margherita Girino³, Giulia Comola¹, Mario Pirisi¹

¹ Department of translational medicine, Università del Piemonte Orientale, Novara, Italy

² Internal Medicine Department, AOU Maggiore della Carità, Novara, Novara, Italy

³ Internal medicine Department, Ospedale Santo Spirito, Casale Monferrato, Italy

Background

The diagnosis of pulmonary embolism (PE) is notoriously underestimated. Compression ultrasound (CUS) is a simple, cheap and safe diagnostic tool, characterized by a sensitivity > 90% and an approximate 95% specificity for symptomatic deep vein thrombosis (DVT).

Methods

In the present study we plan to evaluate, in patients hospitalized in internal division for dyspnoea and/or respiratory failure, with a diagnosis of acceptance other than PE, the additional diagnostic power of CUS. 218 patients were consecutively recruited and underwent to CUS within 72 hours from hospital admission. In case of positive result, a lung CT scan was performed to rule out PE, when not contraindicated.

Results

We recruited 218 patients (109 females; 50.2%); the median

age was 84 [75-88] years. We reported a positive CUS in 24 (11.0%) patients. Out of them 23 patients showed a proximal vein involvement, while 1 patient had solely bilateral paraneoplastic distal thrombosis. The Wells score for PE indicated an unlikely diagnosis (≤ 4) in 18/24 patients (72.0%).

Following the positive result of CUS, 8 patients underwent a CT scan with confirmed PE in 7 subjects (3.2% of the whole population). The Wells score for PE indicated an unlikely diagnosis in 6/7 patients (85.7%).

Conclusion

This study confirms that the prevalence of PE in patients admitted for dyspnea/respiratory failure is largely underestimated and suggests that the current risk scores are probably inadequate when applied in clinical practice.

The routinary use of CUS in respiratory failure might significantly contribute in improving the diagnostic accuracy.

#739 - Abstract

HAEMOGLOBIN: ANOTHER FACTOR FOR CONSIDERATION TO SELECT PATIENTS WITH ACUTE PULMONARY EMBOLISM FOR OUTPATIENT TREATMENT?

Diogo Raposo André, Fabiana Gouveia, Rafael Nascimento, Teresa Raposo André, António José Chaves, Maria Luz Brazão
Hospital Central do Funchal, Funchal, Portugal

Background

Acute Pulmonary Embolism (PE) results from occlusion of the pulmonary circulation whose clinical condition depends on the existence of previous cardiopulmonary pathology, the size of the thrombus, the number of embolic episodes and the neurohormonal response to the event. The HESTIA (cH) criteria, developed by Zondag, identify which patients with right ventricular dysfunction have a low risk of developing an adverse event in the outpatient setting, allowing them to perform the treatment safely at home. In this study, similarly to cH, we sought to determine if haemoglobin (Hb) values at admission may be helpful in identifying low-risk patients who are able to comply with outpatient therapy earlier.

Methods

A retrospective study of patients diagnosed with PE at a Central Hospital from January to December 2017. Of the 117 patients with a diagnosis of acute PE, only 68 had a complete blood count at admission and no indication according to cH for early outpatient therapy. The data obtained were treated by IBM SPSS Statistics® Version 25 and the Pearson Chi-Square, Spearman's Rho and Logistic Regression tests were used.

Results

Of the 117 patients, 68 had no criteria cH for outpatient treatment (42 women), with a mean age of 70.35 years (± 15.34). Of these, it was found that the group with lower Hb levels had longer

hospitalizations with an average of 13.95 days (\pm 10.70). The existence of a 30-day mortality / re-hospitalization risk ratio was observed when there was a low Hb value (Pearson Chi-Square test, $p = 0.035$). It was found that in this group of patients there is an inverse relation of Hb values with mortality / re-hospitalization at 30 days ($\rho = -0.276$; $p = 0.023$). Logistic regression complements the above results, noting that higher levels of Hb provide a lower 30-day mortality / re-hospitalization risk (OD 0.699, CI 95% 0.506 to 0.967, $p = 0.030$)

Conclusion

Hb at admission is an analytical data to consider since it may help in increasing the sensitivity and specificity of cH, identifying patients with or without indication for early ambulatory therapy. It was found that patients with reduced levels of Hb on admission had a higher mortality / re-hospitalization risk at 30 days and that high levels of Hb are associated with a lower risk of death or re-hospitalization.

#745 - Case Report

STROKE AND PULMONARY EMBOLISM: WHEN LEFT AND RIGHT ARE NOT APART

João Barbosa Martins, Mariana Formigo, Magda Costa, Sandra Barbosa, Jorge Cotter

Hospital Senhora da Oliveira, Guimarães, Portugal

Introduction

Atrial septal defects are the third most common type of congenital heart disease, however the overall incidence of stroke due to these defects still remains unknown.

Case description

A 73-year-old man presented at the emergency room with dysarthria, labial commissure deviation to the left side, facial right side paresis, strength reduction on the right upper and lower limb, with more than 6 hours of development. The only relevant background he presented were a prostatic neoplasia formerly treated by surgery and radiotherapy, epilepsy secondary to infection and dyslipidemia. His vital signs were significant for blood pressure of 170/87 and his physical examination revealed the previously reported deficits and a normal heart auscultation. Electrocardiogram presented sinus rhythm and head and neck computed tomography (CT) with contrast administration revealed a focal occlusion on the left Sylvian segment, with no possibility of mechanical intervention. Laboratory test were significant for elevated c-reactive protein and thus a chest X-ray was performed, revealing mediastinal congestion. After admittance and at early deficits recovery, the patient complained of 2 months lasting dyspnea and consequently, a thoracic contrast CT was briefly asked. This exam revealed a voluminous thrombus present at the right pulmonary artery and other at the left lower lobe pulmonary artery. A transthoracic echocardiogram, later confirmed by a transesophageal echocardiography revealed an aneurysmatic

movement of the interatrial septum with a patent foramen ovale and spontaneous right-to-left interatrial shunt. Anticoagulation and the remaining etiological study were promptly initiated. At discharge the patient almost totally recovered from the deficits and continued home anticoagulation, while waiting for cardiac atrial septum repairing procedure.

Discussion

In this case atrial septal aneurysmatic movements with a patent foramen ovale seemed to have a significant contribution to the thromboembolic phenomenon.

#761 - Abstract

THE USE OF DIRECT ANTICOAGULANTS AND ANTI-VITAMIN K DRUGS IN SCHEDULED ELECTRICAL CARDIOVERSION: A STUDY OF DAILY CLINICAL PRACTICE

David González Calle, Ana Elvira Laffond

Hospital Universitario de Salamanca, Salamanca, Spain

Background

In the past few years, several randomized trials comparing efficacy and security of direct anticoagulants (DOACs) and of anti-vitamin K (AVK) before scheduled electrical cardioversion in FA have been published. Notwithstanding, the differences found were not statistically significant. Therefore, it is important to record and analyze the results of these treatments in real daily practice.

Methods

Scheduled electrical cardioversions performed under treatment with either DOACs or AVK during a period of 24 months were retrospectively analyzed. Baseline clinical characteristics of both groups of treatment were compared. Results in terms of efficacy (stroke, transient ischemic attack, myocardial infarction or systemic embolism) and security (bleeding) were registered up to two months after electrical cardioversion. Time of anticoagulant therapy prior to electrical cardioversion was also compared.

Results

During the period of study 320 electrical cardioversions were performed, 32% under treatment with acenocoumarol ($n = 104$), 30% with rivaroxaban ($n = 94$), 23% with apixaban ($n = 73$), 8% with dabigatran ($n = 26$) and 5% with edoxaban ($n = 17$). There were statistically significant differences in certain baseline clinical characteristics between the patients treated with DOACs and with AVK, such as age (60.1 years old vs 66.1 years old, $p \leq 0.001$), creatinine serum levels (0.94 vs 1.12 mg/dl, $p = 0.01$), CHA₂DS₂VASc (1.94 vs 2.74 points, $p = 0.001$) and HAS-BLED (2.19 vs 2.61 points, $p < 0.01$). Incidence of thromboembolic events was low in both groups: one event in the group of rivaroxaban and three non-fatal strokes in the group of acenocoumarol. Bleeding episodes were also infrequent in both groups: one major digestive bleeding with rivaroxaban and three major bleedings

with acenocoumarol, including one fatal bleeding ($p = \text{NS}$). Time of anticoagulant therapy prior to electrical cardioversion was significantly lower in the group of DOACs (27.3 days vs 39.9 days, $p = 0.001$). Spontaneous cardioversions were more frequent in the group of DOACs (27 patients, 12.8%) than in the group of AVK (4 patients, 3.8%, $p < 0.01$).

Conclusion

Treatment with DOACs in scheduled electrical cardioversion is an effective and safe alternative to conventional treatment with AVKs, with the advantage that time until electrical cardioversion is reduced. Our results show that AVKs are still routinely used, in spite of cardioversion delay and the worse results shown in clinical trials and clinical registers.

#762 - Abstract

PALPITATIONS: DIAGNOSTIC VALUE OF KARDIA MOBILE DEVICES

Jospeh Kazibwe, Sarah Halmer, Michael Coupe, David Ferguson
Furness General Hospital, Barrow-In-Furness, United Kingdom

Background

Palpitations are amongst the top ten reasons for medical admissions in the NHS (National Health Service). Kardia devices may provide a symptom-rhythm diagnosis for patients with paroxysmal palpitations that are not associated with syncope. We set out to assess the diagnostic value of Kardia mobile devices in this population.

Methods

Data were collected from patients given devices from 27th July 2017 to the 3rd September 2018 at Furness General Hospital. Both univariate and bivariate analyses were done using SPSS. Non-parametric statistical analyses were carried out as the data were not normally distributed. The level of significance was 0.05.

Results

Only two patients could not use the devices due to software incompatibility. There were twice as many females as were males ($N=60$ and $N=30$ respectively). The median age was 47 years (19-77). The median number of days patients had the Kardia device was 57 (6-133). The median number of ECGs sent for analysis was 5 (0-102).

The main diagnoses were; Sinus Tachycardia $n=16$ (18%), Normal Sinus Rhythm $n=33$ (37%), Supra Ventricular tachycardia $n=9$ (10%), Atrial Fibrillation $n=9$ (10%), Atrial Ectopics $n=21$ (23%), Sinus Bradycardia $n=2$ (2%).

Younger patients appeared to stay with the devices for a longer time (Spearman's correlation, P value 0.005). However, there was a correlation between the patient's age and number of ECGs they sent out (P value 0.117). Similarly, there was no correlation between the number of ECGs sent out by the patient and the days they stayed with the device (P value 0.534).

Conclusion

Mobile Kardia devices are a valuable tool in the diagnosis of paroxysmal palpitations without associated syncope.

#765 - Case Report

AORTIC DISSECTION: AN UNUSUAL PRESENTATION

Rosário Eça, João Alves Teixeira, Pedro Duarte Mesquita, Cláudia Janeiro, Raquel Mesquita, Inês Santos

Centro Hospitalar Lisboa Central, Lisbon, Portugal

Introduction

Aortic dissection is relatively uncommon although it is the most common acute aortic condition requiring urgent therapy. It is a serious condition that can have catastrophic consequences if not detected and managed early. The classification of aortic dissection is based on the anatomical location and duration of symptoms. The Stanford system is more widely used and classifies aortic dissections as type A, involving the ascending aorta and its arch, and type B, involving the descending aorta. Aortic dissections can also be classified as acute, when presenting with <2 weeks symptoms or chronic (>2 weeks). The typical presentation of type A dissections include severe acute chest pain, frequently radiating to the upper back (more than 80% of the patients), occasionally accompanied by dyspnoea, syncope or stroke. Although most patients present with an acute onset, rarely aortic dissections can have a painless course and be accompanied by systemic disease symptoms like malaise, fever and weight loss.

Case description

This is a case report of a 48-years-old man, smoker, without history of hypertension, presenting to the emergency department with thoracic pain but had medical release with the diagnosis of anxiety. In 2 months the pain disappeared. However he developed persistent low-grade fever, night sweats, malaise, weight loss. These symptoms were associated with elevated acute phase biomarkers, like ferritin and c-reactive protein. He denied other symptomatology, most importantly pain and respiratory complaints. A CT scan was ordered, after an initial abnormal chest radiography, revealing slight mediastinal adenopathy, a small pericardial effusion and an unexpected type A aorta dissection. Patient underwent surgical intervention with replacement of the resected aortic by a graft with full recovery. Pathological investigation of the aortic specimen demonstrated intense inflammation with neutrophilic infiltrati.

Discussion

Chronic aortic dissection manifested with features of systemic disease in absence of the more typical symptoms has been rarely reported. Such atypical presentation can make the diagnosis of an aortic dissection particularly challenging, especially when no typical signs are present. In these cases, cross sectional imaging is of crucial importance. Differential diagnosis of aortic dissection

associated with a systemic clinical scenario should include, among many causes, isolated ascending aortitis, infectious aortitis in the setting of a known inflammatory disorder as giant cell arteritis.

#777 - Case Report

FROM RENAL FAILURE TO AMYLOIDOSIS THROUGH HEART FAILURE

Andrea Boccatonda, Giulio Cocco, Cosima Schiavone
Università degli studi G.d'Annunzio Chieti, Chieti, Italy

Introduction

Cardiac amyloidosis is a clinical condition that previously went undiagnosed and thought to be uncommon, but, recently, it is increasingly recognized as reason of heart failure. Moreover, advances in cardiovascular imaging techniques and newer modalities of treatment lead to early diagnosis, thereby limiting further amyloid deposition and modifying disease course. In this case report, we discuss a 76 years old male admitted for acute renal failure and cardiogenic shock with subsequent workup confirming a diagnosis of cardiac amyloidosis.

Case description

A 76 years old Caucasian male presented to our Internal Medicine department with diffuse bone pain and sudden onset shortness of breath. His medical history was notable for benign prostatic hypertrophy and recent removal of a colic polyp.

On initial physical examination, he had a blood pressure of 90/60 mmHg with pulse rate of 82 beats per minute (bpm). He had bilateral rales on lung examination and normal heart sounds with no murmurs or gallops on auscultation. His lower extremities were cool to touch with mild pitting edema bilaterally. Electrocardiogram (ECG) showed LBBB and low voltages in the limb leads. Chest radiograph demonstrated bilateral patchy opacities consistent with pulmonary edema.

Given the clinical finding of congestive heart failure, high-dose diuretic therapy was initially attempted. Due to the persistently high levels of urea and creatinine, and the poor response to diuretic therapy, the patient underwent dialysis with resolution of the picture of pulmonary congestion.

Subsequently, patient performed an echocardiogram that showed a dilated left ventricle (LV) with severe left ventricular hypertrophy and reduced LVEF of 30%-35%. Due to the discordance between the degree of LV thickness and QRS voltage on ECG, cardiac amyloidosis was considered as a possible etiology of the cardiomyopathy.

Cardiac magnetic resonance (MR) revealed greater late gadolinium enhancement at the base than at the apex, highlighting a base-to-apex gradient. The patient underwent to biopsy of abdominal fat that demonstrated advanced systemic light-chain amyloidosis.

Discussion

Our case demonstrates how cardiac involvement is fundamental in the pathophysiology of amyloidosis. Furthermore, the

discrepancy between the echographic finding and the ecg allows to place a strong diagnostic suspicion, so as to direct the patient to the biopsy.

#787 - Case Report

RECURRENT DVT AND THROMBOCYTOPENIA IN A YOUNG PATIENT

Ana Alwina Stan
MCA HEALTH CARE, Tirgu-Mures, Romania

Introduction

Deep venous thrombosis (DVT) is a manifestation of venous thromboembolism (VTE). DVT most commonly involves the deep veins of the leg or arm, often resulting in potentially life-threatening emboli to the lungs or debilitating valvular dysfunction and chronic leg swelling. Early recognition and appropriate treatment of DVT and its complications can save many lives. The goals of pharmacotherapy for DVT are to reduce morbidity, prevent post-thrombotic syndrome, and prevent pulmonary embolism.

Case description

We present the case of a 45 year old patient with a history of right hemicolectomy and segmentary resection of the descending colon post abdominal trauma and a vertebro-basilar stroke. He was first admitted in the Internal Medicine Department in Nov 2017 for DVT of the right femoro-popliteal-calf axis (total occlusion), confirmed by ultrasonography. At that time he also presented pancytopenia, which was investigated: bone marrow analysis (hyperplastic red series, macroblastic and erythroblastic cells), upper digestive endoscopy (gastritis and esophagitis), abdominal ultrasound (possible lesion adjacent to the left inferior renal pole). Anticoagulation with LMWH was started and later switched to acenocoumarol. A vitamin B12 deficiency was later established, followed by supplementation and consequent improving of hemoglobin and leukocyte levels. Throughout the year 2018 the patient also complained of fatigue and weight loss (aprox 6 kg), so neoplastic causes were investigated: abdominal and pelvis CT, colonoscopy (no pathological findings). In January 2019 he complained of swelling of the left calf, which was confirmed as DVT of the left popliteal, posterior tibial and fibular veins. Recent blood work still shows thrombocytopenia.

Discussion

Considering the recurrent DVT and history of stroke in this patient, a primary thrombophilia was taken into account, especially since a low platelet count does not seem to protect against VTE (testing is ongoing). If confirmed, appropriate measures will be implemented- indefinite anticoagulation, possibly switching to NOACs.

#801 - Abstract

CARDIAC ARRHYTHMIAS IN PREGNANT WOMEN WITH STRUCTURALLY NORMAL HEART: MANAGING AND PERINATAL OUTCOMESAliya Smagulova¹, Ayan Abdrakhmanov^{1,2}, Bayan Ainabekova¹¹ NpJSC «Astana Medical University», Nur-Sultan, Kazakhstan² JSC National research cardiac surgery center», Nur-Sultan, Kazakhstan**Background**

Normal physiologic changes during pregnancy may trigger arrhythmias. Risk of arrhythmias during pregnancy is relatively higher in patients with structural heart disease or a prior history of arrhythmias. However, data on pregnant women with structurally normal heart is limited.

Purpose

We aimed to evaluate the fate of arrhythmias and perinatal outcomes in pregnant women with structurally normal heart in this study.

Methods

50 pregnant women with structurally normal heart and identified cardiac arrhythmias were enrolled in the study (one center, prospectively collected data). Mean age of patients: 28.9±5.7 years, mean gestation age 22.9±6.9 weeks. Baseline clinical characteristics, maternal and fetal events during pregnancy and postpartum were investigated.

Results

Supraventricular tachycardia (n=20; 40%), atrial (n=5; 10%) and ventricular (n=16; 32%) premature beats were the most frequent arrhythmia in this study. Ventricular tachycardia was identified in 3 (6%) patient, third degree atrioventricular block – in 6 (12%) cases. Arrhythmia was first documented in 30 (60%) pregnant women. Arrhythmias were most frequently happened during the 2nd trimester (n=36; 72%). In 31 (62%) cases of intolerable symptoms of tachyarrhythmias cardioselective β -blockers were required. Catheter ablation was needed for 22 (44%) patients with drug refractory and hemodynamically significant arrhythmias. All ablation procedures were performed without fluoroscopy. Acute success was in all of the 22 patients. Permanent pacemaker was implanted for 6 (12%) patients with complete heart block. In one case was documented a procedural complication (ileofemoral venous thrombosis). Inferior vena cava filter and anticoagulation were used in this patient, follow-up period was without complications. Obstetric outcomes: preterm delivery was none declared, spontaneous vaginal delivery was in 31 (62%) cases, vaginal-assisted was in 6 (12%) women, Cesarean delivery was in 13 (26%) patients. Intrapartum hemorrhage was 325.9±214.3 ml. In one case (2%) developed pre-eclampsia. Neonatal outcomes: birth weight was 3421±711 grams, 5 minute Apgar's score was 8.4±1.4. Congenital malformations in newborns was not documented. There were no maternal and neonatal death.

Conclusion

the most common arrhythmias in pregnant women with structurally normal heart are supraventricular tachycardia and premature beats. It is associated with good pregnancy and neonatal outcomes

#803 - Case Report

NON CARDIOGENIC ACUTE PULMONARY EDEMA

Alejandra García García, Eva Cervilla Muñoz, Neera Toledo Samaniego, Irene García Fernández- Bravo, Ana Torres Do Rego, Elena Bello Martinez

Hospital General Universitario Gregorio Marañón, Madrid, Spain

Introduction

We present the case of a 74-year-old woman with diagnosis of hydrochlorothiazide -induced pulmonary edema.

Case description

We present the case of a 74-year-old woman with a personal history of permanent atrial fibrillation under treatment with acenocumarol, pacemaker carrier, rheumatic valvular heart disease (moderate aortic stenosis, mitral mechanical prosthesis and tricuspid regurgitation), chronic hepatitis B viral infection and autoimmune hypothyroidism. She had had previous severe adverse reactions with antihypertensive combined drugs in two occasions: with hydrochlorothiazide/valsartan and amilorid/ hydrochlorothiazide.

The patient was derivated to the emergency room from the Allergy Day Hospital. While performing an allergy provocation test with hydrochlorothiazide she rapidly developed hypotension, fever (37.8 °C), dyspnea and desaturation with congestive symptoms. The patient required intensive care management with non invasive mechanical ventilation and vasoactive support. She evolved favorably with rapid improvement of the congestive symptoms after supportive management and diuretics.

Blood analyses revealed transient leukopenia 700/ μ L (Neutrophils 300/ μ L; Lymphocytes 300/ μ L), eosinophilia was not observed. Hemoglobin and platelets were within normal range and no renal, hepatic or ionic alterations were observed. C-reactive protein and Nt-proBNP were mild elevates (5.4 mg/dL and 2686 ng/L respectively). Chest X-ray showed bilateral pleural effusion and vascular redistribution without consolidation images. Blood and urine cultures were negative. An echocardiogram was performed without changes in the left ejection fraction, valvulopathies or contractility compared to the previous one performed a few months earlier ambulatory.

Discussion

There have been sporadic reports of hydrochlorothiazid causing noncardiogenic pulmonary edema as an idiosyncratic reaction. The onset of symptoms typically occurs quickly after ingesting the medication, often within an hour. Due to the rare incidence of this reaction, the diagnosis of HCTZ-induced pulmonary

edema is often made only on re-exposure to the medication and may masquerade as septic shock and acute respiratory distress syndrome from a pneumonia. The possible mechanisms of the pulmonary edema still remain unknown.

#805 - Case Report

TAKOTSUBO SYNDROME (TTS) VS ACUTE MYOCARDIAL INFARCTION (AMI): AN ATYPICAL CASE OF CARDIAC ARREST

Ana Catarina Trigo¹, Marta Vilaça¹, João Caiano Gil¹, Ana Sofia Correia², Nuno Moreno², Liliana Carneiro¹

¹ Medicine Department/Internal Medicine Service, Hospital Pedro Hispano, Matosinhos Local Health Unit, Matosinhos, Portugal

² Medicine Department/Cardiology Service, Hospital Pedro Hispano, Matosinhos Local Health Unit, Matosinhos, Portugal

Introduction

A myocardial infarction with nonobstructive coronary arteries (MINOCA) is a “working diagnosis” that must fill out the acute myocardial infarction (AMI) criteria, the presence of non-obstructive coronary arteries on angiography and the absence of other explicative clinical entities. Differential diagnosis from Takotsubo syndrome (TTS) and myocarditis can be challenging. TTS is a transient ventricular contractile dysfunction, more common in postmenopausal women, usually triggered by physical/emotional stress. Left ventriculography, echocardiography and cardiac magnetic resonance imaging (MRI) are crucial diagnostic tools. TTS and AMI have been considered mutually exclusive, but they can coexist and lead to each other.

Case description

A 54-year-old postmenopausal woman, without cardiovascular diseases, collapsed at home after a sudden thoracic pain. A history of emotional stress was reported on the days before, with no previous episodes of chest pain or viral illness. Immediate basic life support was performed by her family, followed by advanced life support by the prehospital emergency medical service. The initial cardiac arrest (CA) rhythm was ventricular fibrillation (VF). ECG after recovery demonstrated sinus rhythm, cardiac rate of 89 QRS complexes per minute, QRS interval of 0.088s, QTc interval of 0.483s, abolition of R waves in leads V1 to V3, with no alteration of ST segment or any arrhythmia. Emergent angiography showed normal coronary arteries, and ventriculography revealed extensive left ventricular contractility disorder typical of TTS. Subsequent studies showed substantial recover of ventricular function in 24h. MRI revealed ischemic late gadolinium enhancement pattern on distal anterior and lateral segments consistent with AMI. No prothrombotic conditions were found. An implantable cardioverter-defibrillator (ICD) was inserted, and the patient was discharged with bisoprolol, statin and dual antiplatelet therapy.

Discussion

Our patient fulfilled the European Society of Cardiology criteria

for both AMI and TTS; we still do not know which occurred first. Both can be complicated by VF and CA, with a frequency of 3% and 4-6% respectively for TTS. There are no clinical guidelines regarding electrophysiologic studies nor ICD therapy for long-term management of patients with TTS who experience CA. Notwithstanding this, our patient remains asymptomatic six months after the event, and no arrhythmias, shocks or antitachycardia pacing therapies were recorded on her ICD.

#819 - Case Report

AN UNUSUAL CAUSE OF PERICARDITIS

Cátia Costa Oliveira¹, Catarina Quina Rodrigues¹, Isabel Durães Campos¹, Carla Maria Marques Pires Rodrigues¹, Paulo Medeiros¹, Luís Dias¹, Jorge Marques¹, João Maciel²

¹ Hospital de Braga, Braga, Portugal

² Centro Hospitalar de S. João, Porto, Portugal

Introduction

In the current era of antibiotic therapy, purulent pericarditis (PP) is a rare entity.

Case description

A 75-year-old woman went to the emergency department for retrosternal pain of pleuritic features with dorsal irradiation with about 1 week of evolution. The patient had sustained hypotension associated with poor peripheral perfusion and had initiated vasopressor support with noradrenaline. The electrocardiogram showed sinus bradycardia and a slight ST segment elevation with superior concavity in DI and aVL. She performed AngioTC that excluded acute aortic syndrome and pulmonary thromboembolism. Analytically, there was elevation of C reactive protein (400 mg/dL), Pro-BNP (10000 pg/ml) and creatinine (2.1 mg/dL). Transthoracic echocardiography (TTE) showed preserved biventricular function and moderate-volume pericardial effusion with fibrin appearance. Due to hemodynamic instability, pericardiocentesis was performed with initial output of 300 cc and then 650 cc of purulent fluid. Its analysis showed normal triglyceride counts and Gram staining showed the presence of bacterial colonies (later confirmed the presence of *Streptococcus anginosus* and *intermedius* strains) and started piperacillin/tazobactam and linezolid. Repeated thoracic CT showed findings suggestive of mediastinitis and a subcarinal foreign body image (patient with a history of accidental ingestion of fishbone days before the onset of symptoms). After oral contrast administration, there were no signs of extravasation into the mediastinum. The patient presented an improvement in her condition and was transferred to the cardiothoracic surgery department with the diagnosis of purulent mediastinitis/PP. It was performed a chest exploration and mediastinal/pericardial lavage. She repeated TTE showing a thin layer of pericardial effusion and the thoracic CT showed bilateral pleural effusion, and a multiloculated consolidation at the right lung, associated with subsegmental atelectasis of the adjacent lung parenchyma. Despite the initial clinical improvement, the patient eventually

evolved with respiratory septic shock with the isolation of a multiresistant strain of *Klebsiella pneumoniae* in the sputum, eventually dying.

Discussion

PP occurs more frequently in individuals with previous pericardial manipulation or disease, alcoholism, immunosuppressed patients or patients on a regular hemodialysis program. Its rapid diagnosis is essential since, although rare, in the absence of proper treatment can be lethal.

#822 - Abstract

DISRUPTION OF BALANCE OF OXIDATIVE STRESS-ASSOCIATED ANGIOGENESIS IN HEART FAILURE

Andreia Matos^{1,2}, Mário Teixeira Barbosa³, Manuel Bicho^{1,4}, Luíz Menezes Falcão⁵

¹ Genetics Laboratory and Environmental Health Institute-ISAMB, Faculdade de Medicina da Universidade de Lisboa, Lisboa, Portugal

² Instituto de Investigação Científica Bento da Rocha Cabral, Lisbon, Portugal

³ Department of Internal Medicine, Hospital Lusíadas Lisboa, Lisboa, Portugal

⁴ Instituto de Investigação Científica Bento da Rocha Cabral, Lisboa, Portugal

⁵ Department of Internal Medicine, Santa Maria Hospital, Lisboa, Portugal

Background

Hypoxia may be a concomitant state in heart failure patient, inducing the disruption of the balance of oxidative stress-associated angiogenesis. Soluble fms-like tyrosine kinase-1 (sFlt-1 or VEGFR1) and erythropoietin (EPO) activates neovascularization and reduces apoptosis. We investigated the role of these biomarkers in heart failure (HF) patients.

Methods

In the total of 59 hospitalized patients with acute decompensated heart failure in class II or IV of NYHA were assessed the biomarkers of sFlt-1 and EPO. These biomarkers were determined by ELISA. Subgroup analysis was performed according to the left ventricular ejection fraction in light of the current European Society of Cardiology guidelines. Mann-Whitney test, Spearman correlation, and ANCOVA analysis were applied. Statistical significance was considered for $P < 0.05$.

Results

Mean age 80.66 (SD 10.78) years and 52.9% were female. Mean ejection fraction was $48.45 \pm 17.68\%$, with 28.1% presenting HFrEF < 40%, 21.1% HFmEF 40-49% and 50.9% HFpEF. Higher levels of sFlt-1/sVEGFR1 were associated to patients with HFrEF comparing with HFmEF (HFrEF: 118.35 ± 63.47 pg/mL versus HFmEF: 79.13 ± 27.39 pg/mL, $P = 0.033$). EPO and sFlt-1/sVEGFR1 were directly correlated ($r = 0.856$, $P = 0.034$).

Conclusion

In our study, higher levels of sFlt-1/sVEGFR1 were found in patients with HFrEF, which may untangle a possible role of hypoxia status in the angiogenic profile of heart failure patients.

#830 - Case Report

A CASE OF SEVERE PLATIPNEA ORTHODEOXIA SYNDROME, SECONDARY TO PATENT FORAMEN OVALE IN AN ELDERLY WOMAN

Felice Crudele, Costanza Marchiani, Giulia Bandini, Maria Grazie D'Alfonso, Fabio Mori, Alberto Moggi-Pignone

University of Florence, Florence, Italy

Introduction

The Platypnea-Orthodeoxia syndrome (POS) is a rare clinical manifestation characterized by dyspnea with arterial blood desaturation (drop of $Pao_2 > 4$ mmHg or $Sao_2 > 5\%$), which occurs when the patient is sitting or standing up and regresses in the supine position. The main cause of this syndrome is an intra-cardiac shunt and other causes reported in the literature are pulmonary shunts and hepato-pulmonary syndrome.

Case description

An 87-years-old Italian woman was transported to the emergency room because of fever and flu symptoms for a few days. At the entrance, she was alert, hemodynamically stable, with only bibasilar inspiratory crackles on chest auscultation and no cardiac murmurs. She was former smoker and was on treatment for arterial hypertension. She suffered from orthostatic hypotension and was recently visited by a pneumologist for episodes of dyspnea, without evidence of respiratory impairment. During ER hospitalization, arterial desaturation was detected with the digital pulse oximeter, confirmed by arterial blood gas analysis (Pao_2 45mmHg), in the absence of dyspnoic symptoms, for which oxygen (FiO_2 60%) was administered via Venturi mask and a lung angio-CT was performed to exclude a pulmonary embolism. A transthoracic echocardiogram showed normal global function, without valve pathology or pathological shunts. Due to the persistence of severe arterial desaturation (up to Sao_2 60%), with the appearance of dyspnea, the patient underwent non-invasive ventilation (NIV) and, once stabilized, transferred to our department. It was therefore progressively tried to wean the patient from the NIV and during these attempts, it was shown that the patient maintained excellent values of Sao_2 in the supine position and instead bad values of saturation in orthostatism. Therefore, POS was diagnosed and a contrast echocardiogram was performed showing interatrial shunt, exacerbated in sitting position. So the patient was subjected to a transesophageal echocardiogram and to percutaneous closure of patent foramen. In the following days of hospitalization, the patient remained hemodynamically stable and with good saturation values even in a sitting position.

Discussion

We report the case of an elderly woman in whom patent foramen ovale diagnosis was made associated with platipnea orthodeoxia syndrome. This case shows that although rare and difficult to diagnose, POS can be detected with a careful physical examination, followed by an adequate diagnostic and therapeutic iter.

#847 - Case Report

EFFUSIVE (AND VIRAL) COINCIDENCES

Filipa Rodrigues, Carmen Valdivieso, Eugénia Madureira, Pedro Verão, Andreia Diegues, Ana Rita Silva
ULSNE, Bragança, Portugal

Introduction

The causes for pericarditis and pericardial effusion are multiple, usually divided into inflammatory and non-inflammatory and, in most cases, the cause of the effusion is determined with a thorough history and physical exam.

In developed countries, this condition is, not surprisingly, most often idiopathic or due to viral infection although neoplastic, tuberculosis or myxedema should be considered.

Case description

Presenting a case of two males admitted to medical ward during the same period:

First, a 56 year-old with medical background of aortic stenosis, presented with severe abdominal pain in the upper quadrants and chills of 1 week, with no other findings. Lab results revealed GGT: 121 U/L with normal ALT and AST levels, and a normal EKG. Abdominal CT scan and echocardiogram showed a 35 mm pericardial effusion. Pericardiocentesis was performed with hematic fluid outlet and negative BK in sputum and hemocultures. Further lab tests showed EBV VCA IgG: 14.39; EBV VCA IgM: 5.67 and EBV EBNA IgG: 19.76, being this the most probable etiology. The patient improved with colchicine and aspirin and was discharged with a follow up consult.

The second case: a 32 year-old male, with past medical history of autism, presented with dyspnea, fever and productive cough of 3 days. Lab tests showed hs-CRP: 19.25 mg/dL. A CT scan revealed a subacute 40 mm pericardial effusion. Pericardiocentesis was performed with 900 mL of serous fluid outlet with negative BK in sputum and hemocultures. More detailed lab tests revealed, EBV VCA IgG: 59.40; EBV VCA IgM: 0.20 and EBV EBNA IgG: 16.15, furthermore confirming the EBV infection as the most probable etiology. This patient also improved with colchicine and aspirin and was discharged.

Discussion

Viral pericarditis does not have a well-known frequency, although some studies point up to a number from 30% to 50%, most of them connected to the coxsackie viruses, with some studies identifying EBV as a close second.

Even though EBV is highly prevalent, affecting more than 90%

of individuals worldwide, cardiac involvement of this virus is seldom reviewed in the literature, since it is a very uncommon presentation, particularly pericarditis with sizable effusion.

The course of EBV induced pericarditis, although rare, is usually benign and uncomplicated, but this case serves as an example that we should think with an open mind when making a diagnosis.

#849 - Case Report

DRESSLER SYNDROME – BECAUSE AN ACUTE MYOCARDIAL INFARCTION IS NOT ENOUGH!

Tiago Pais, Cláudia Diogo, Bruno Cabreiro, Ana Ponciano, Joana Leite, Catarina Faria, José Leite, Célio Fernandes

Department of Internal Medicine, Centro Hospitalar de Leiria, Leiria, Portugal

Introduction

After an acute myocardial infarction (MI), there is a high risk of cardiac complications: mechanical (rupture of the papillary muscle and ventricular wall), immunological or iatrogenic. Dressler syndrome (DS) occurs in <4% of patients with MI and typically occurs 1 to 6 weeks after the event. The hallmarks are pleuritic chest pain, fever, pericardial friction and elevation of inflammatory markers. It is thought to be associated with hypersensitivity reaction, in which the antigens released by the injured myocardial muscle produce antibodies against the pericardium, pleura and lungs. An important differential diagnosis is peri-infarct pericarditis, which usually occurs within the first four days after MI and is usually transient.

Case description

We present the case of a 55-year-old male with known cardiovascular risk factors such as arterial hypertension, type 2 diabetes mellitus, smoking habits and obesity (body mass index=35.4). He had history of non-ST segment elevation MI 12 days ago with a subocclusion of the right coronary artery submitted to angioplasty with placement of 2 stents. In the emergency department, he presented a sharp chest pain, not relieved with rest, without irradiation and associated with nausea and dizziness. At admission he was afebrile, with normal cardiac sounds and the remaining examination was unremarkable. Blood tests revealed elevation of inflammatory markers (C-reactive protein (CRP 67.8mg/dL), with no increase in myocardial necrosis markers and an NTproBNP <70pg/mL. The EKG showed inversion of T waves in V5-V6, DII, DIII and aVF and on echocardiogram he had an estimated preserved ejection fraction, inferior hypokinesia and inferior pericardial hyperechogenicity. He initiated lysine acetylsalicylate and colchicine with clinical improvement.

Discussion

Although the patient did not present the typical symptoms or signs, the conjunction of chest pain, elevated CRP, pericardial hyperechogenicity after 2 weeks of the MI let us conclude that is most probably a DS case. Although the incidence of

post-myocardial injury syndrome has been decreasing due to improvement of the methods of coronary reperfusion, the relapses are frequent (about 10-15% in the first 6 months). Larger MI, marked troponin elevation, minor ejection fraction, anterior infarct location correlate with worse outcomes and a poor prognosis.

#850 - Medical Image

AORTIC DISSECTION - THE DEMAND OF A HIGH INDEX OF SUSPICION

Leonor Naia¹, Flávio Pereira¹, Tiago Rabadão¹, Margarida Eulálio¹, Elsa Rocha²

¹ Baixo Vouga Hospital Center - Internal Medicine Department, Aveiro, Portugal

² Baixo Vouga Hospital Center - Emergency Department, Aveiro, Portugal

Clinical summary

An 88-year-old woman, admitted for muscle strength deficit in the upper limbs and backache with 5 hours of evolution. Medical history of arterial hypertension and ascending aortic aneurysm. At admission: normotensive, without further changes. Blood tests, 12-lead ECG and cranioencephalic CT scan without changes; thoracic radiography with enlargement of the mediastinum and dilation of the aortic arch. She entered in cardiorespiratory arrest. The echocardiography showed pericardial effusion associated to aortic dissection with cardiac tamponade; pericardiocentesis was attempted, without success. Aneurysms are usually asymptomatic, constituting an incidental diagnosis. Aortic dissection requires a high index of suspicion, as its prognosis is closely related to timely diagnosis and treatment.

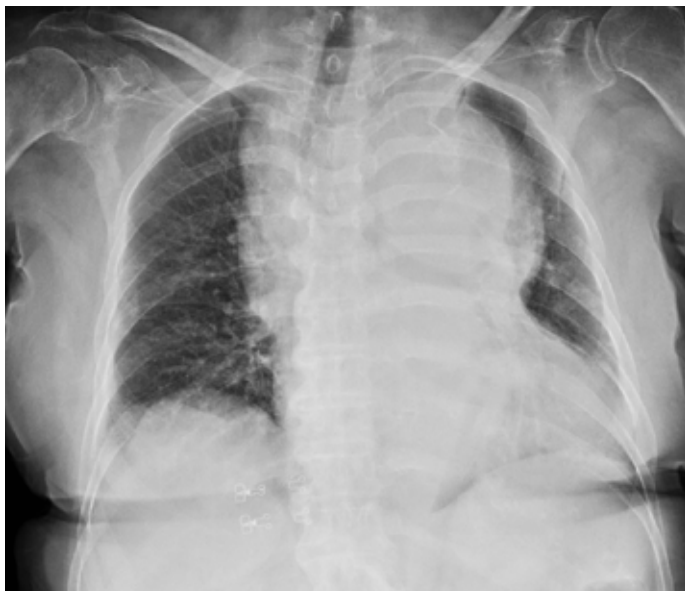

Figure #850.

#883 - Case Report

DYSPNEA, A SYMPTOM TO INVESTIGATE

Isabel Maria Dias Martins Freitas, Tatiana Salazar, Ana Lima Silva, Pedro Rodrigues, Cláudia Maio, Jorge Salomão, Ana Luísa Cruz, Augusto Duarte

CHMA- Famalicão, Famalicão, Portugal

Introduction

Chronic thromboembolic pulmonary hypertension (CTEPH) is an uncommon but well-recognized cause of pulmonary hypertension (PH). It is characterized by intra-luminal thromboembolism and subsequent vascular remodeling of pulmonary arteries, causing stenosis. It is observed in 2-4% of patients after acute pulmonary embolism (PE) and related with significant morbidity and mortality. We aim to alert for CTEPH as an important cause of PH.

Case description

A 75-year-old female with a history of restrictive syndrome, dyslipidemia and arterial hypertension presented to the emergency department with a six-month progressively worsening dyspnea at rest. There was no history of deep vein thrombosis or PE. Pertinent physical exam findings included a pulse rate of 112 beats/minute, respiration rate of 26 breaths/minute and pitting edema in both lower extremities. Labs were significant for D-dimer >4400 ng/mL and pro-BNP of 10421 pg/mL. The electrocardiography presented with Q1T3S3 pattern and artery blood gas (FiO₂ 0.21) revealed type 1 respiratory failure. Chest computed tomography angiography (CTA) excluded signs of thromboembolism in the main pulmonary arteries but could not exclude thrombus in the sub-segmental arteries. For this reason, anticoagulant therapy was initiated. Transthoracic echocardiogram suggested signs of severe pulmonary hypertension with a normal left ventricular ejection fraction. The ventilation/perfusion scan confirmed peripheral pulmonary thromboembolism. Prothrombotic workout was unrevealing and other causes of pulmonary hypertension were excluded. Right heart catheterization revealed a mean pulmonary artery pressure of 39 mmHg, pulmonary vascular resistance of 8.38 mmHg, cardiac index of 2.95 l/min/m² and pulmonary wedge pressure of 6 mmHg confirming the diagnosis of CTEPH. An antagonist of endothelin receptor associated with rivaroxaban was the treatment of choice with patient referral to thromboendarterectomy.

Discussion

CTEPH is an important cause of pulmonary hypertension and should be specifically considered in the diagnostic workup. The prognosis is poor, with progressive pulmonary hypertension, right ventricular failure, and ultimately death, in the absence of treatment. CTEPH can occur in patients without an history of thromboembolic event. Dyspnea can be the first manifestation, emphasizing the importance of its etiologic investigation, since CTEPH is potentially treated by pulmonary thromboendarterectomy.

#886 - Case Report

WHEN THROMBOLYSIS IS CONTRAINDICATED IN HIGH-RISK PULMONARY EMBOLISM

Isabel Maria Dias Martins De Freitas Freitas, Tatiana Salazar, Ana Lima Silva, Patrícia Rocha, Sara Pereira, Ana Luísa Cruz, Augusto Duarte

CHMA- Famalicão, Famalicão, Portugal

Introduction

Pulmonary embolism (PE) is the most severe form of venous thromboembolism and is associated with high morbidity and mortality rates. Its presentation is variable and non-specific, making its diagnosis a real challenge. Rapid intervention and reestablishment of pulmonary flow reduce mortality.

Case description

82-year-old male admitted for a wake-up stroke, with neurological deficits clinically compatible with the territory of the right middle cerebral artery, of probable cardioembolic etiology. Evidence of occlusion of a large vessel (M1) and with reperfusion criteria, for which he was submitted to thrombectomy, with clinical improvement, with residual neurological deficits persisting. At the 15th day of hospitalization the patient evolved with hemodynamic instability and shock. He underwent computed tomographic pulmonary angiography, which confirmed bilateral acute PE. Transthoracic echocardiography revealed again severe right ventricular systolic dysfunction, assuming high-risk PE. Given the absolute contraindication for thrombolysis, he underwent percutaneous pulmonary embolectomy, with improvement of bilateral perfusion and decrease of pulmonary arterial pressure from 81 mmHg to 55 mmHg. After hemodynamic recovery, vasopressor support was suspended, with no immediate complications of the procedure.

Discussion

This case aims to highlight the importance of PE in the differential diagnosis of shock, as well as the need to recognize percutaneous interventions as a valid alternative therapeutic option for surgical embolectomy, although not always available, in patients with high-risk PE and with a formal contraindication for thrombolysis.

#889 - Case Report

"UNDER PRESSURE". AN UNUSUAL CASE OF PULMONARY HYPERTENSION DUE TO BILATERAL DYSFUNCTION OF DIAPHRAGM

Carolina Defendini

Sapienza University, Internal Medicine Unit, Rome, Italy

Introduction

We present a case of a 74 years old man with an acute respiratory failure associated with bilateral dysfunction of diaphragm.

Case description

On day 4 after a laparoscopic prostatectomy the patient was admitted to our department for a type II respiratory failure with hypoxemia and hypercapnia. A chest X-ray showed elevation of both hemidiaphragms. The patient, never a smoker and without any occupational exposure, ten years earlier underwent a quadruple CABG with good residual left ventricular performance. A non-invasive ventilatory support failed in normalization of the arterial blood gas values, therefore he was intubated and ventilated for 24 hours. A transthoracic echocardiography showed a systolic pulmonary artery pressure estimated at 80 mmHg, a dilated right section with lowered performance of right ventricular wall. A thoracic CT angiography excluded pulmonary embolism but showed elevation of both hemidiaphragms and atelectasis of pulmonary bases. Autoimmune pathologies were also ruled out. Pulmonary function test showed both obstructive and restrictive pulmonary lung disease with FEV1 36%, FVC 32%, DLCO 35% ERV 200ml of predicted values in sit. Lung perfusion scintigraphy showed low perfusion at both lung bases. Right heart catheterization confirmed severe precapillary pulmonary hypertension with a RAP10 mmHg, mean PAPm 75 mmHg, PAWP 12 mmHg and a cardiac output 4.15 L/min. EMG and ENG confirmed signs of neurogenic damage of right phrenic nerve and decreased amplitude of cMAP of both phrenic nerves. The patient started therapy with Tadalafil and respiratory rehabilitation; was discharged 20 days after the normalization of arterial blood gas values.

Discussion

Unilateral weakness of one hemidiaphragm is more common and can be asymptomatic, while bilateral paralysis can cause significant respiratory failure. The mechanism responsible of pulmonary hypertension is the chronic alveolar hypoventilation with hypoxia and hypercapnic vasoconstriction. In our patient we can hypothesize that an idiopathic unilateral phrenic paralysis existed before CABG surgery for the presence of right side elevation in a preoperative chest X-ray. The contralateral nerve might have been damaged during the cardiac surgery, considered as the most common of all traumatic causes. This condition was clinically silent until laparoscopic prostatectomy during which air was blown into the abdomen, pushing the diaphragm upwards and reducing the expansion of the chest, thus causing acute respiratory failure.

#908 - Case Report

PATENT FORAMEN OVALE AND STROKE: ON THE SUBJECT OF TWO CLINICAL CASES

Ana Barbosa, Olinda Miranda, Inês Fonseca, Margarida Rocha, Helena Sarmento, Jorge Cotter

Hospital da Senhora da Oliveira, Guimarães, Portugal

Introduction

The patent foramen ovale (PFO) is the most common congenital heart defect affecting the adult population, being present in

25% to 30% of the individuals. Although most patients are asymptomatic, a variety of clinical manifestations may occur, including cryptogenic stroke (CS).

Case description

Case 1

Woman, 46 years old, history of dyslipidemia and stroke for 1 year with left hemiparesis (4+) and dysmetria in the finger-to-nose test. Admitted to the emergency department due to headache, dizziness and paresthesia in the left hemiface. At the end of the examination, hemihypoesthesia of the face and left central facial paresis were observed. In the head computerized tomography (CT): "...small cerebellar sequelar hypodensity...". No other alterations were documented in the initial study. Transesophageal echocardiogram (TEE) showed PFO, with right-to-left shunt documentation. Given the occurrence of two cerebrovascular events, she was targeted for PFO closure.

Case 2

Male, 41 years old, with no relevant past medical history, travelled to the emergency department due to acute vertigo syndrome. Head CT without changes. On admission, the patient also underwent head magnetic resonance imaging: "... a lesion in the upper slope of the left cerebellar hemisphere, translating a recent ischemic lesion." No other alterations were documented in the initial study, except in TEE which revealed PFO with a right-to-left shunt at rest.

Both cases have Internal Medicine outpatient follow-up to control cardiovascular risk factors.

Discussion

With these clinical cases the authors seek to emphasize the importance of excluding PFO in patients with cryptogenic stroke.

#910 - Medical Image

EXTENSIVE TYPE B AORTIC DISSECTION INVOLVING FEMORAL ARTERIES

José Eduardo Mateus¹, Gabriel Atanásio², João Valente²

¹ Internal Medicine Department, Centro Hospitalar e Universitário de Coimbra, Coimbra, Portugal

² Internal Medicine Department, Centro Hospitalar Vila Nova de Gaia / Espinho, Vila Nova De Gaia, Portugal

Clinical summary

A 58-year-old man presented to the emergency department with intense abdominal pain lasting for two hours. He had a history of hypertension, smoking and previous cocaine abuse. On observation he was hypertensive. Computed tomographic angiography of the thorax and abdomen revealed type B aortic dissection extending from the left subclavian artery to both femoral arteries. There were no signs of malperfusion, thus the patient was medically managed. One week later, despite using five different classes of antihypertensive drugs, blood pressure remained uncontrolled, motivating a thoracic endovascular aortic

repair with clinical improvement. The 10 year survival of patients with acute dissection ranges from 30–60%, which highlights the need of a high index of suspicion.

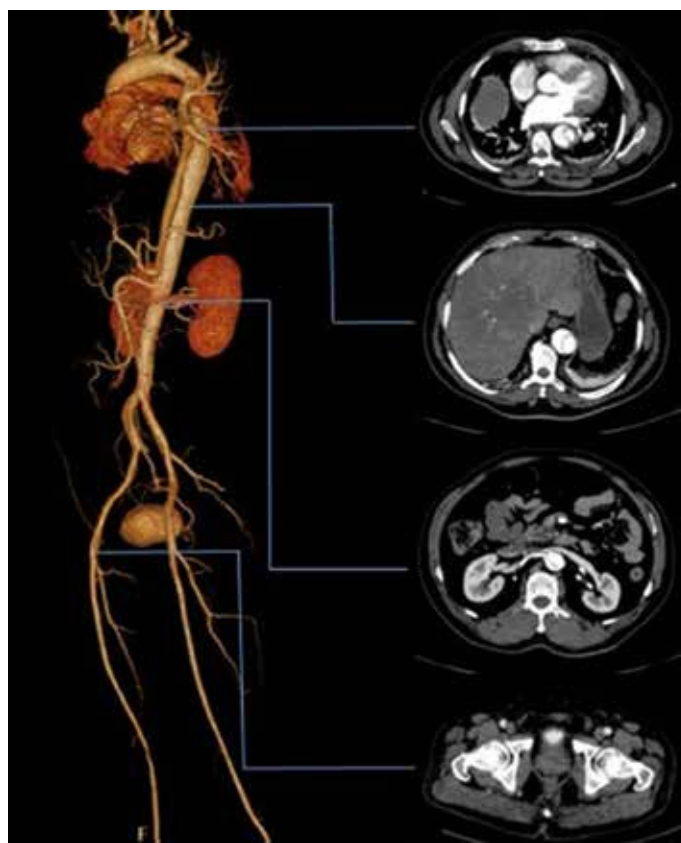


Figure #910. CT three-dimensional reconstruction of aortic dissection extending from left subclavian artery to femoral arteries (lateral incidence and four transverse plane sections).

#917 - Abstract

HEART FAILURE WITH REDUCED EJECTION FRACTION – IS THERE ANY DIFFERENCE IN BEING A WOMAN?

Ana Neto, Daniel Seabra, Inês Oliveira, Aurora Andrade, Paula Pinto

Tâmega e Sousa Hospital Center, Penafiel, Portugal

Background

Heart failure (HF) with reduced ejection fraction (HFrEF) affects more men than women but with several sex differences in the underlying disease. Women are more likely to have hypertension and valvular disease, but less coronary artery disease. Sex-specific data focused on cardiovascular (CV) disease have been increasing steadily, yet is not routinely collected nor translated into practice.

Purpose

Characterize a cohort of patients (pts) with HFrEF admitted in a HF Clinic (HFC) and identify gender-related features of HF, regarding clinical findings and prognosis.

Methods

Unicentric retrospective analysis of pts followed in a HFC since 3/2011. Included pts with reduced ejection fraction (EF) (<50%) and previous diagnosis for at least 6 months; they were divided in two groups: male (G1) and female gender (G2). Peripartum cardiomyopathy pts were excluded. Clinical, demographic, analytical, electrical and echocardiographic characteristics and major CV events - HF hospitalization (HFhosp) and mortality (from CV cause (CVm) and non-CV cause (nCVm)) were analysed.

Results

Included 374 pts with a mean age of 60.6 ± 13.2 years. G2 consisting of 93 pts (25%). The mean age of G2 was higher (63.5 ± 13.4 vs 59.7 ± 13.4 years, $p=0.015$) with predominance of non-ischemic etiology (76 vs 54%, $p<0.001$). Regarding non-ischemic cardiomyopathy, G2 presented less frequently with alcoholic etiology (6 vs 54%, $p<0.001$). There were no significant differences in CV risk factors prevalence, except for hypertension (71 vs 59%, $p=0.041$) and smoking (4 vs 49%, $p<0.001$).

The female group correlated negatively with the presence of atrial fibrillation (AF) (20 vs 40%, $p<0.001$), presented with higher EF at admission and during follow-up (FU) in the HFC ($p<0.001$). During the FU, G2 had lower number of clinical events - HFhosp ($p=0.032$) and mortality ($p=0.008$). No differences between NYHA class at admission and FU.

Conclusion

In this cohort, women with HFREF were older, had more hypertension but with lower prevalence of AF. Regarding etiology, female gender presented higher prevalence of non-ischemic etiology, particularly non-alcoholic cardiomyopathy, with higher EF at admission and FU. Concerning clinical events, they had less HFhosp and lower mortality rate comparing with men.

#920 - Abstract

IMPACT OF SYSTEMIC ATHEROSCLEROSIS ON CLINICAL CHARACTERISTICS AND SHORT-TERM OUTCOMES IN PATIENTS WITH DEEP VENOUS THROMBOSIS

Mir Abolfazl Ostad, Lukas Hobohm, Thomas Münzel, Karsten Keller

University, Mainz, Germany

Background

Venous thromboembolism (VTE) and arterial thrombotic disorders were considered as separate disease entities for a long time. This differentiation of thrombotic disease with regard to arterial and venous origin is based on anatomical differences and differences in clinical presentation. Venous thrombi are mainly composed of red blood cells and fibrin while arterial thrombi are mainly composed of platelets. Despite these differences, a large body of evidence in recent years questioned this oversimplification of separated diseases. Atherosclerosis and VTE

are accompanied by cardiovascular mortality and links between both entities were reported. We aimed to investigate the impact of systemic atherosclerosis on adverse outcomes in patients with deep venous thrombosis and thrombophlebitis (DVT) and to identify differences in DVT patients with and without systemic atherosclerosis.

Methods

The German nationwide inpatient sample was used for this analysis. Patients admitted for DVT were included in this study and stratified by systemic atherosclerosis (composite of coronary artery disease, myocardial infarction, ischemic stroke, and/or atherosclerotic arterial diseases). We compared DVT patients with (DVT+Athero) and without (DVT-Athero) systemic atherosclerosis and analysed the impact of systemic atherosclerosis on adverse outcomes.

Results

Overall, 489,679 patients with DVT (55.7% females) were included in this analysis. Among these, 53,309 (10.9%) were coded with concomitant systemic atherosclerosis with age-dependent incline. Concomitant PE (4.1% vs. 3.8%, $P=0.001$) was more frequently in DVT-Athero and risk for PE in DVT patients was independently associated with absence of systemic atherosclerosis (OR 0.87 [95%CI 0.83-0.91], $P<0.001$). In-hospital mortality (3.4% vs. 1.4%, $P<0.001$) and adverse in-hospital events (2.2% vs. 0.8%, $P<0.001$) were more prevalent in DVT+Athero compared to DVT-Athero; both, in-hospital mortality (OR 1.52 [95%CI 1.41-1.63], $P<0.001$) and adverse in-hospital events (OR 1.49 [95%CI 1.40-1.58], $P<0.001$) were affected independently of sex, age and comorbidities by systemic atherosclerosis.

Conclusion

DVT patients with concomitant systemic atherosclerosis were associated with poorer outcomes. Systemic atherosclerosis was associated with isolated DVT (without concomitant PE) indicating for a link between atherosclerosis and VTE.

#922 - Abstract

IMPACT OF ATRIAL FIBRILLATION/FLUTTER ON THE IN-HOSPITAL MORTALITY OF ISCHEMIC STROKE PATIENTS

Mir Abolfazl Ostad, Lukas Hobohm, Philip Wenzel, Thomas Münzel, Christine Espinola-Klein, Karsten Keller

University, Mainz, Germany

Background

Stroke is the second leading cause of death worldwide. The enormous morbidity of this condition results of an interplay between the caused neurological impairment going along with emotional and social consequences, and a high risk for stroke recurrence. In the United States of America more than 690,000 adults suffer from an ischemic stroke each year.

Ischemic strokes, which are caused by atrial fibrillation/flutter (AF) are frequently more devastating than those without AF. The purpose of our study is to investigate the impact of AF on adverse events in hospitalized ischemic stroke patients and estimate the elevated impact of AF for occurrence of these adverse events.

Methods

The nationwide German inpatient sample of the years 2005-2015 was used for this analysis. Ischemic stroke patients were identified by ICD code I63 and stratified by AF (source: RDC of the Federal Statistical Office and the Statistical Offices of the federal states, DRG Statistics 2005-2015, own calculations). Logistic regression models were used to investigate the impact of AF on adverse in-hospital events and adjusted for age, sex and comorbidities to prove the independence of the associations.

Results

Overall, 2,958,697 hospitalized ischemic stroke patients (50.5% females, 65.4% aged >70 years) were included in the analysis. Of these, 849,466 patients (28.7%) were diagnosed with AF. Overall, 9.0% of the stroke patients died in-hospital. The case fatality rate increased with growing age and was higher in stroke patients with than without AF (13.0% vs. 7.3%, $P<0.001$).

AF was an important predictor for in-hospital death (OR 1.30 [95%CI 1.28-1.31], $P<0.001$) and adverse events during hospitalization independently of age, sex and comorbidities. Deterioration of patients' prognosis due to AF was especially pronounced in younger patients.

Conclusion

AF in ischemic stroke patients is associated with higher in-hospital mortality and higher rate of adverse events during hospitalization independently of age, sex and comorbidities.

#924 - Abstract

PREDICTORS OF IN-HOSPITAL MORTALITY IN PATIENTS WITH COPREVALENCE OF PULMONARY EMBOLISM AND ISCHEMIC STROKE – BENEFIT OF SYSTEMIC THROMBOLYSIS

Mir Abolfazl Ostad, Lukas Hobohm, Thomas Münzel, Karsten Keller

University, Mainz, Germany

Background

Pulmonary embolism (PE) is a frequent complication in immobile stroke patients and an important cause of death. Without prophylaxis for venous thromboembolism (VTE), approximately 75% of the stroke patients with hemiplegia develop a deep venous thrombosis and 20% a PE, which is fatal in 1-2% of the patients. Remarkably, the risk for occurrence of deep venous thrombosis correlate strongly with the degree of paralysis with predilection in the paralyzed leg. We aimed to identify factors and comorbidities,

which are different between PE patients with (PE+Stroke) and without ischemic stroke (PE-Stroke), investigate predictors of in-hospital death and evaluate, whether systemic thrombolysis in these critical ill patients is beneficial.

Methods

Patients were selected by screening the nationwide sample for PE (ICD-code I26) and were stratified by ischemic stroke. In PE+Stroke patients, we compared survivors with non-survivors and examined predictors of in-hospital death as well as the benefit of systemic thrombolysis (source: RDC of the Federal Statistical Office and the Statistical Offices of the federal states, DRG Statistics 2011-2014, own calculations).

Results

The nationwide sample comprised 346,586 hospitalized PE patients (53.3% females) in Germany between 2011 and 2014; among these, 6,704 (1.9%) patients had PE+Stroke. PE+Stroke revealed a substantially higher in-hospital mortality than PE-Stroke (28.9% vs. 14.5%, $P<0.001$). While age, cancer, chronic lung diseases, renal insufficiency, coagulation abnormalities, atrial fibrillation/flutter and diabetes mellitus (DM) type 2 were independent predictors of an increased case-fatality rate, female sex, obesity and arterial hypertension (AHT) were connected with better survival. Systemic thrombolysis was not connected with a survival benefit in PE+Stroke in general (35.5% vs. 27.9% in-hospital deaths, $P<0.001$), but led to improved survival in PE+Stroke patients, who had to undergo cardio-pulmonary resuscitation (OR 0.548 (0.358-0.840), $P=0.006$).

Conclusion

Females, obese and hypertensive patients had a better survival PE+Stroke. Systemic thrombolysis was not connected with survival benefit in general, but might be beneficial in those, with cardio-pulmonary resuscitation.

#939 - Case Report

UPPER LIMB DEEP VEIN THROMBOSIS AT YOUTH: AN UNCOMMON CASE REPORT

Inês Pereira Oliveira, Filipa Leal, Luís Nogueira, Mari Mesquita, Paula Pinto

CHTS, Penafiel, Portugal

Introduction

Thoracic Outlet Syndrome (TOS) results from neurovascular compression at the thoracic outlet, being the neurogenic subtype is the most common (90%). Venous (vTOS) and arterial TOS are rare (7% and 3%, respectively).

We present a case report of a young patient with upper extremity deep vein thrombosis (UEDVT) in the setting of vTOS due to an anatomic variant: an uncommon clinical situation, which implies significant morbidity if not identified and timely treated.

Case description

A 19-year-old female patient with no relevant past medical history, no usual medication, repetitive physical activity, smoking habits or drug abuse, presented to the emergency room with pleuritic thoracic pain and right arm swelling. No previous similar symptoms.

Physical examination showed inflammatory signs of the arm, present bilateral radial pulse and no collateral circulation. Compression maneuvers were negative.

Increased d-dimers on blood analyses. Doppler ultrasound (US) revealed deep vein thrombosis of the right subclavian vein (SV). Thoracic CT showed signs of pulmonary embolism and identified a clavicular osteophyte compressing the SV. Anatomic similarities on the left, with no evidence of thrombosis.

She was diagnosed with UEDVT. Unsuccessful catheter-directed thrombolysis was performed and non-vitamin K oral anticoagulants were initiated.

Anti-phospholipid syndrome and thrombophilia were excluded later on medical appointment. Repeated doppler US revealed left arterial and bilateral venous compression. Surgical decompression with first rib resection has been planned for definitive therapy.

Discussion

Vascular TOS is infrequently encountered in clinical practice, namely with simultaneous venous and arterial compression, as reported.

VTOS in the setting of anatomical variants as osteophytosis at youth is particularly rare, since these are usually related to ageing and bone degeneration. Repetitive upper limb physical activity is a quite more common cause of vascular compression at the thoracic outlet, increasing the likelihood of thrombosis if associated with a hypercoagulability status, smoking habits or contraceptive medication. All these were excluded.

The approach of this pathology is defying due to the lack of randomized controlled trials concerning the issue and overall rarity of the syndrome. There is high risk of recurrence and post-thrombotic syndrome, leading to significant morbidity and highlighting the importance of a timely and appropriate diagnosis and intervention.

#944 - Abstract

USE OF FERRIC CARBOXYMALTOSIDE IN PATIENTS WITH HEART FAILURE AND IRON DEFICIENCY IN A MULTIDISCIPLINARY HEART FAILURE UNIT

Amalia Veronica Perez Papadopulos, Sara Hernandez Araque, Lucia Florio, Gabriela Ormaechea
Hospital de Clinical, Montevideo, Uruguay

Background

Heart failure (HF) is important cause of morbidity and mortality, with high impact on health costs due to hospitalization. Comorbidities such as iron deficiency should be considered in

the management of patients with HF since it can hinder patients prognosis. Evidence suggests that treatment of iron deficiency, despite the existence of anemia, improves symptoms, functional capacity and quality of life.

Our objective was to determine the clinical impact of intravenous iron administration in a population of patients with HF with reduced left ventricular ejection fraction (R-LVEF) who present iron deficiency with/without anemia in a Multidisciplinary HF Unit.

Methods

Prospective cohort study. Patients included: HF with R-LVEF, >18 years; stable clinical situation; informed consent. Patients who received iron/erythropoietin, transfused in the last 3 months, or history of anaphylaxis were excluded.

Iron deficiency was defined: ferritin <100ug/l or 100-300ug/l and transferrin saturation index <20%. Intravenous carboxymaltose iron was administered according to ferric metabolism and hemoglobin (Hb). Minnesota Quality of life test (MQLT) and 6-minute walk test (6MWT) were made. NTproBNP and NYHA class of initiation were controlled. Protocol: if Hb <14 mg/dl, 1000 mg of iron was administered; if Hb 14-15 mg/dl: 500 mg. Control 6 weeks with haemogram, NYHA class, NTproBNP, MQLT, 6MWT. Quantitative data were expressed in medians and interquartile ranges, were compared by Mann Whitney test before and after treatment with iron; qualitative variables were expressed in relative frequency and compared by Chi2 test. $p < 0.05$ was considered significant.

Results

Thirty patients were included: 19 women; median age 73 years, ischemic etiology 14; baseline median Hb: 12.5mg/dL; basal ferritin 80.5 ug/l, LVEF 30% median; median MQLT value 62 points and median 6MWT 155 meters. After iron administration, significant improvement in quality of life was observed with median 43.7 points ($p=0.0001$), improvement in median 6MWT 210 meters ($p=0.0001$). NYHA improved in 10 patients and maintained it in 11 ($p=0.12$); NTProBNP: 14 patients decreased, 8 increased ($p=0.29$). No adverse effects were reported.

Conclusion

The experience with the use of ferric carboxymaltose in patients with iron deficiency in our Heart Failure Unit was significantly beneficial giving improvement in clinical parameters independent of the existence of anemia. It is the first experience in our country and supports international research.

#954 - Abstract

A NEW RISK ASSESSMENT MODEL FOR THE STRATIFICATION OF THE THROMBOEMBOLISM RISK IN MEDICAL PATIENTS: THE TEVERE SCORE

Manuel Monti¹, Sergio Timpone², Iginio Fusco Moffa³, Paolo Diego L'Angiocola⁴, Francesco Borgognoni¹, Giovanni Maria Vincentelli²

¹ Usl Umbria 1, Assisi, Italy

² Fatebenefratelli Hospital, Rome, Italy

³ USL Umbria 1, Perugia, Italy

⁴ Gorizia Hospital, Gorizia, Italy

Background

In hospitalized medical patients, the VTE risk is notable. Nevertheless, the available assessment model (TPF) is generally underused.

In this work, we propose an ex novo risk assessment model based on the elaboration of the clinical data exhibited by the TEV patients. Differently from previous studies, the proposed approach does not exploit pre-established models, resulting in a more valid and easy-to-use score.

Methods

We performed a double case-control observational study. For each case of VTE, we enrolled two consecutive patients without VTE of equal sex and age group (18–50, 50–55, 55–60, 60–65, 65–70, 70–75, 75–80, >80 years). The study involved both the EM and the IM Departments of 23 hospitals and universities in Lazio and Umbria (Italy).

Results

We analyzed the data of 1215 patients, 409 with VTE (50% – deep venous thrombosis (DVT), 9.9% – pulmonary embolism (PE), 40.1% – PE+DVT) and 806 case-control. 222 patients (30%) were in charge to the EM department while 520 patients (70%) to the IM one. The TEV risk factors with more statistical significance ($p < 0.01$) are: previous VTE, active cancer, known thrombophilic condition, immobilization, chronic venous insufficiency, hyperhomocysteinemia, central venous catheter, recent hospitalization. Obesity, recent surgery, family history of VTE, hormone therapy and treatment with drugs that stimulate hematopoiesis are resulted at intermediate statistical significance ($p < 0.05$ but > 0.01). A multiple logistic regression was used with robust standard errors and forward selection of the candidate variables using the Bayesian information criterion. A new score is developed, the “TEVere Score”, which shows an higher specificity and sensitivity (respectively 43.3 and 87.5, with accuracy 72.1) compared with the Padua, the Kuscer and the Chopard score. TEVere score also exhibits a greater predictive validity for thromboembolism risk (AUROC 0.7266; 95% CI, 0.71 to 0.73) than the Kuscer score (AUROC 0.6891; 95% CI, 0.67 to 0.70) ($p = 0.0093$).

Conclusion

The results obtained by this study show that information on

environmental risk factors, coagulation factors, and comorbidity lead to higher accuracy in the prediction of the VTE risk in medical area. In daily practice, our clinical model (TEVere score) may be the preferred one for its good predictive performance and since its factors are easier to be determined, especially in EM. These results may provide guidance for thromboprophylaxis and form the basis for a management study.

#962 - Case Report

MULTIPLE THROMBOTIC EVENTS IN A PATIENT WITH PATENT FORAMEN OVALE - A SUCCESSFUL CASE

Daniel Neves Sebaiti, Alexandra Briosaa, Filipa Ferreira, Ana Rita Pereira, Ana Marques, Isabel João, Prof Dr Helder Pereira
Hospital Garcia de Orta, Almada, Portugal

Introduction

Patent foramen ovale (PFO) is an anatomical interatrial communication that persists into adulthood. Closing the PFO is controversial, particularly in older patients, and the results of the studies have been contradictory.

Case description

We present a rare case of a 69 years old male, Caucasian, with history of hypertension and diabetes and several thrombotic events in a short period of time (from March 2015 to July 2015) which included 8 transient ischemic attacks, one stroke with hemorrhagic transformation, and one episode of pulmonary thromboembolism. Etiological investigation was negative, therefore the thromboembolic events were considered to be cryptogenic. The later thrombotic events occurred despite anticoagulation therapy. The transcranial Doppler showed a “shower-curtain” pattern, suggesting the presence of a right-to-left shunt. Transesophageal echocardiography (TOE) showed PFO with spontaneous right to left shunt visible with color Doppler, no other abnormalities were found, pulmonary venous return was normal, left ventricle had normal chamber size and systolic function and normal thoracic aorta. Considering the recurrent episodes of thrombotic events even under effective anticoagulation and attending to the characteristics of the foramen ovale (spontaneous significant shunt) the patient was considered for percutaneous PFO closure.

Under general anesthesia, cardiac catheterization was performed, guided by transesophageal echocardiography and radiology, confirming PFO dimensions (6.99 mm x 24 mm, using sizing balloon), and proceeded with PFO closure using Amplatzer 25mm device, but due to significant mismatch between the septum primum and septum secundum, a significant residual shunt was observed in TOE with bad apposition of the device in the septum primum. Considering the significant number of paradoxical thrombotic events, it was important to have absence of residual significant shunt, therefore the device was replaced by a larger sized one, Amplatzer 30 mm, with significant reduction of residual shunt, without obstruction of adjacent valves our veins.

Discussion

Echocardiographic follow-up showed no residual shunt and maintaining good apposition of the device. No thrombotic event was documented during almost six years of follow up. This case illustrates the importance of patient selection, besides the controversy around percutaneous closure of PFO. Aneurysmatic atrial septum is usually seen as a risk factor for stroke, but in this case the septum was normal.

#963 - Abstract

THE IMPACT OF PRO-THROMBOTIC, ATHEROGENIC AND ANTIOXIDANT PLASMA STATUS ON LONG TERM PROGNOSIS IN YOUNG PATIENTS AFTER ACUTE CORONARY SYNDROME (ACS)

Daniel Neves Sebaiti, Alexandra Briososa, Paula Fazendas, Filipa Ferreira, Ana Rita Pereira, Ana Marques, Helder Pereira
Hospital Garcia de Orta, Almada, Portugal

Background

Free radicals have an important role in tissue lesions pathogenesis in different pathologies, including in atherosclerotic plaque formation and, therefore, in thrombus formation, which may have a central role in developing acute coronary syndrome in young age. In a previous study, we observed that, the group of patients that had acute coronary syndrome in young age, presented a significantly lower total value of antioxidant plasma status compared with the control group and reference values.

Aims

Analysis of long-term influence of pro-thrombotic, atherogenic and total antioxidant states factors in patients that had an acute coronary syndrome in young age.

Methods

The study population included 23 patients admitted for acute coronary syndrome between January 1995 and June 1998. The male/female ratio was 87%/13% and mean age was 35 years (22-40 years). None of the patients had diabetes or diagnosis of familial hypercholesterolemia.

Blood samples were collected 16.5 (+/- 10.7) months after ACS. Laboratory tests: plasma antioxidant status (PAS) (colorimetric method measured in Trolox equivalent), Lipoprotein (a), Apolipoprotein A and Apolipoprotein B (Nephelometry technique), Apolipoprotein E (immune-electro-diffusion method), factors VII e VIII activity. None of the patients were lost on follow-up.

Results

Mean follow-up period 13.7 years; 3 deaths. Fifteen patients presented major cardiovascular events: heart failure 4 patients; new ACS 11 patients; 6 patients underwent percutaneous coronary intervention for stable coronary artery disease. PAS:

1.21 (0.1) mmol/L, Apo B 1.28 (0.37) g/L, Apo E 45.6 (17.3) mg/L, Homocystein 10.9 (2.87) μ mol/L, Lip (a) 0.24 (0.81) g/L, Apo A 1.14 (0.22) g/L, VII 114 (109)%, VIII 50 (42)%, vWF 99(40)%. Patients that had major cardiovascular events had significantly higher levels of Lip (a) e vWF (Mann-Whitney Test $p < 0.05$). The ROC analysis of this parameters presented an AUC of 0.84 and 0.79 respectively, with a cut-off for Lp (a) of 0.195 (73% sensitivity, 75% specificity) and vWF 90% (73% sensitivity, 75% specificity) (Fig 1). There was no statistically significant difference in PAS and in the other evaluated laboratory parameters.

Conclusion

Total plasma antioxidant status was lower in the ACS patients compared with the control group. Occurrence of MACE was not associated with a lower level of antioxidant activity. Higher values of pro-thrombotic and atherogenic factors such as Lip (a) e vWF were associated with a worst prognosis after the first ACS.

#966 - Abstract

ASSOCIATION BETWEEN TOBACCO CONSUMPTION AND SEVERITY OF ARTERIAL HYPERTENSION

Paola Sposito¹, Veronica Torres¹, Florencia Sacchi¹, Caroliona Acosta¹, Lucia Pomies¹, Lia Carlevaro², Mariana Drever³, Maximiliano Pereda⁴

¹ University of Uruguay, Montevideo, Uruguay

² CASMU, Montevideo, Uruguay

³ Hospital Maciel, Montevideo, Uruguay

⁴ MUCAM, Montevideo, Uruguay

Background

Smoking and hypertension (HTA) are two of the main cardiovascular risk factors (CVR). The association between smoking and hypertension determines a risk increase 4.5 times higher. Smoking could be linked to poor control of blood pressure and be modifiable if the patient stop smoking. Alterations in the circadian rhythm of blood pressure and fundamentally nocturnal hypertension have been postulated as predictors of cardiovascular risk.

Aim

To assess the association between smoking and cardiovascular risk in hypertensive patients based on circadian rhythm of arterial blood pressure.

Methods

Analytical, cross-sectional observational study, 3 hospital centers participated. Inclusion criteria: hypertensive older than 18 years who have undergone Ambulatory Blood Pressure Monitoring (ABPM) in a period of 3 months. Exclusion criteria: pregnant women. Variables: age, sex, smoker, Tobacco Year Package Index (IPA), diabetes mellitus and sleep apnea hypopnea syndrome, body mass index, chronotherapy, variability patterns and nocturnal

arterial hypertension in ABPM. Analysis by Chi square test or Fisher exact test, software used STATA v.12.0.

Results

Of a total of 245 ABPM, 202 patients with a diagnosis of hypertension were included in the analysis, average age 55.4 years, 144 women and 58 men. Current smokers: 16.3% Average IPA 38.4. In the total number of patients included, patterns of variability were observed Dipper (90/202) 44.5% and Non-dipper (60/202) 32.6%. Current smokers patients presented risk variability patterns 54% Non Dipper (30%) and Riser (24%) in greater proportion than non-smokers 47% Non Dipper (32%) and Riser (15%) although there was no statistically significant relationship $p=0.6295$. Nocturnal HTA was observed in a high percentage of patients regardless of their smoking status: 61% smokers, 66% non-smokers $p = 0.1354$. HTA nocturnal without chrono therapeutic treatment 71%. As for the gender, nocturnal HTA was observed in 83% of male smokers vs. 59% of women, obesity in 50% of male smokers vs. 39% of female and diabetes in 33% of male smokers vs. 17% of female.

Conclusion

In the studied population, the current smoker patient with hypertension had a tendency to present patterns of blood pressure variability of higher CVR as well as a relationship between male sex and the presence of nocturnal hypertension was observed. The cessation of tobacco consumption could be important in the control of hypertension. A large number of patients presented nocturnal hypertension.

#975 - Medical Image

A CASE OF TRICUSPID INSUFFICIENCY AND ANEURYSM

Duarte André Ferreira, Mauro Fernandes, Margarida Temtem, Tatiana Henriques, Maria Luz Brazão
Hospital Central do Funchal, Funchal, Portugal

Clinical summary

An 83-year-old woman, with a history of atrial fibrillation presented to the emergency department with a week history of orthopnea, chest pain and effort dyspnea. On examination she was afebrile. On auscultation: holosystolic murmur and decreased vesicular murmur at the bases with fervors. Considerable edema to the knees. Laboratory evaluation revealed troponinT 0.027 ng/mL, NT-proBNP 2114 pg/mL, d-dimers 1070 ng/mL. Postero-anterior chest radiography showed significant cardiomegaly. Computed tomography angiography presented exuberant dilation of the right atrium, pleural effusion bilaterally and some pericardial effusion. Transthoracic echocardiogram was also performed. The patient was admitted to cardiology for right heart failure, with severe tricuspid insufficiency and probable aneurysm.

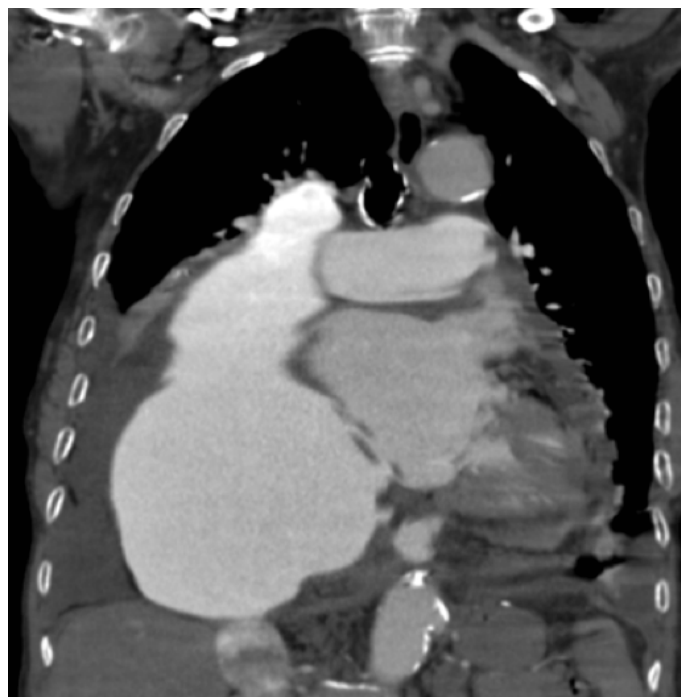


Figure #975. Computed tomography showed a significant cardiomegaly and exuberant dilation of the right atrium.

#987 - Case Report

PAINFUL LEFT CERVICAL SWELLING IN A HEALTHY 44-YEAR OLD MAN – A CASE OF A COMPLETE LEFT INTERNAL JUGULAR VEIN THROMBOSIS

Diogo Santos Ferreira, Joana Andreia Cabrera, Cristina Almeida Pinto, Dulce Mendonça Pinheiro, Vitor Paixão Dias
Centro Hospitalar Vila Nova de Gaia/Espinho, Vila Nova De Gaia, Portugal

Introduction

Less than 5% of deep vein thrombosis is due to thrombosis of the internal jugular vein (IJV). It may be provoked by insertion of catheters or have an underlying genetic, malignant or inflammatory disease.

Case description

An otherwise healthy 44-year old man presented to his attending doctor because of a painful left cervical swelling, following strain with his left arm over the previous week. The swelling was of about 5cm in diameter, hard, non-tender superficially and slightly warm. Three days later, the cervical ultrasound showed a complete left IJV thrombosis with a central heterogenous thrombus and he was advised to be seen at the local Emergency Department. A Computed Tomography Angiography (CTA) confirmed the diagnosis and excluded pulmonary thromboembolism. He was admitted to the Internal Medicine ward for etiological study and treatment with subcutaneous low-molecular weight heparin 80 mg twice a day.

From his background, he was a smoker of half a pack since he was 20 years old and consumed half a bottle of wine during the

weekend (lunch and dinner). He denied any family history of thromboembolic diseases.

During the hospital stay, the swelling progressively responded to anticoagulant therapy and the patient improved symptomatically. The prothrombotic blood study was unremarkable. However, the image in the original CTA of a slight adipose tissue densification in the lesser gastric curvature led to an upper endoscopy study, with findings compatible with esophagus neoplasm. The biopsy confirmed the diagnosis of adenocarcinoma with little cohesion and presence of signet ring cells. The current stage is cT3N+M0 and he was proposed peri-operative chemotherapy with FLOP (5FU, Folinic acid, Oxaliplatin, Docetaxel).

Discussion

This case highlights the importance of a thorough study of IJV thrombosis and shows a rather unusual presentation of a rare neoplasm in a young smoker and otherwise healthy individual. In fact, paraneoplastic thrombosis may be found in about half the cases of IJV thrombosis. However, the most frequent location of the tumor is the ear, nose and throat region. Also, it enforces the fact that esophagus cancer can be very insidious symptomatically, as the subject presented with no esophageal or constitutional symptoms. This represents a rare case of an IVJ thrombosis caused by a tumor outside the head and neck region as the first symptom of the disease.

#988 - Case Report

AN UNUSUAL CASE OF “MASKED” HYPERTENSION AND THE IMPORTANCE OF A CORRECT BLOOD PRESSURE EVALUATION

Diogo Santos Ferreira, José Mário Bastos, Telmo Borges Coelho, Luís Silva Andrade, Vítor Paixão Dias

Centro Hospitalar Vila Nova de Gaia/Espinho, Vila Nova De Gaia, Portugal

Introduction

ESC/ESH latest arterial hypertension guidelines recommend that blood pressure (BP) should initially be measured in both upper arms. This case highlights the potential consequences of an incorrect BP measurement.

Case description

An otherwise healthy 75-year old man was sent to the Emergency Department (ED) after a routine evaluation by his attending doctor showing a marked asymmetry of BP between his two upper arms (190/108 mmHg right arm versus 132/74 mmHg left arm), which was confirmed in the ED. BP in both legs was 220/90 mmHg. The patient denied pain, paresthesia or weakness in both arms. All limbs were warm and well perfused. However, the left pulse was weaker and slightly delayed.

The patient had no relevant medical history and was not under any medication. He regularly assessed his BP in his left arm and denied any history of arterial hypertension. He was a heavy smoker (as much as 3 packs a day), active since he was 10. Previous data

showed LDL values of 160 mg/dL (2014) and 137 mg/dL (2017). Blood work was unremarkable. An electrocardiogram showed T-wave inversion in DII, DIII, aVF, V5-V6, with criteria of left ventricular hypertrophy and enlargement of left atria (Figure 1). Chest radiograph was unremarkable. Computed Tomography Angiography showed left subclavian artery stenoses of about 1,5-2 cm (Figure 2). He was discharged, scheduled follow-up with a Vascular Surgeon and prescribed acetylsalicylic acid, rosuvastatin-ezetimibe and azilsartan.

Discussion

This case underlines the importance of a correct measurement of BP, especially in both upper arms initially – as both the attending doctor’s and self-evaluation was always made in his left arm, this arterial hypertension was probably “masked” for years. As a result, there were already signs of cardiac remodeling to this unrecognized hypertension. ESC/ESH guidelines indicate that a consistent and significant systolic BP difference between arms (i.e. >15 mmHg) is associated with an increased cardiovascular risk, most likely due to atheromatous vascular disease, and if there is a difference in BP between arms, the arm with the higher BP values should be used for all subsequent measurements.

Atherosclerosis is the most common cause of subclavian artery stenoses. Often patients present during their sixth or seventh decades of life, and they have associated peripheral arterial disease risk factors such as smoking, diabetes mellitus, hyperlipidemia and hypertension, some of which were present in this subject.

#991 - Abstract

HYPERKALEMIA, HEART FAILURE AND PATIROMER IN MULTIMORBIDITY PATIENTS

Raquel Rodil-Fraile¹, Gregorio Tiberio-Lopez²

¹ Clínica San Miguel, Pamplona, Spain

² Complejo Hospitalario de Navarra, Pamplona, Spain

Background

The objective of the present study is to evaluate Patiromer tolerance and effectiveness in a multimorbidity population.

Methods

Observational study. Multimorbidity patients with sintomathic chronic heart failure (CHF) and hyperkalemia in follow-up by the Internal Medicine of Complejo Hospitalario de Navarra since March to November 2018.

For data analysis student t-test for paired samples we were performed. All tests were performed using STATA version 9 (Texas, NC).

Results

We included 8 patients (M/W: 7/1) with an average age of 80 years. The Barthel index media was 90 points. The comorbidity index measured by the Charlson scale was 9 points. Six patients had HF with reduced ejection function (HFrEF) and two had HF

with preserved ejection function (HfpEF). 50% (4) of the patients had advanced chronic kidney disease (CKD) (stage 4), followed by 37% (3) with CKD with stage 3b. 75% (6) of the patients received ACE/ARB and 12.5% (1) received ARM treatment. The mean potassium levels before treatment were 5.7. All patients received treatment with resinalcio, with regular tolerance.

After adjustment of basal medication and initiation of Patiromer, follow-up of patients was performed. 75% (6) of the patients received treatment with sacubitril-valsartan at a dose of 24/26 mg twice a day, with good tolerance, and 88% of the patients (7) received treatment with ARM at a mean dose of 23 mg per day (12.5-25 mg). The potassium levels after the modifications was 4.7 ($p < 0.001$).

75% of patients received patiromer 8.4 g/day, with good tolerance and no side effects; the remaining 25% received Patiromer 8.4 g twice a day.

Conclusion

The treatment with Patiromer, apart from the good tolerance and palatability, is a good alternative for the optimization of the treatment of HF, as well as for the treatment of hyperkalemia secondary to CKD or pharmacological treatment.

#997 - Abstract

EARLY FOLLOW-UP VISIT BY A MULTIDISCIPLINARY HEART FAILURE TEAM AFTER HOSPITALIZATION FOR ACUTE HEART FAILURE – IMPACT IN THE OUTCOMES

Sofia Furtado¹, Rita Homem², Ana Rita Santos³, Joana Maurício⁴, Sérgio Maltês³, Inês Felizardo Lopes¹, Mariana Popovici¹, Inês Lopes Da Costa¹, Inês Egídio³, Inês Nabais⁵, Francisco Adragão⁶, Catarina Rodrigues³, Luís Campos³, Inês Araújo³, Cândida Fonseca³

¹ Centro Hospitalar Universitário Lisboa Central, Lisboa, Portugal

² Hospital Garcia de Orta, Lisboa, Portugal

³ Centro Hospitalar Lisboa Ocidental, Lisboa, Portugal

⁴ Hospital Prof. Doutor Fernando Fonseca, Lisboa, Portugal

⁵ Hospital de Cascais, Lisboa, Portugal

⁶ Centro Hospitalar Universitário do Algarve, Portimão, Portugal

Background

An early follow-up visit within 7 to 14 days after hospitalization for acute heart failure (AHF) is associated with lower readmission rates and is currently the standard of care in the European Guidelines for HF. Our purpose was to describe the use of an early follow-up visit by a multidisciplinary HF team (combining specialized medical and nurse care) in the transition care of HF patients, after discharge from the hospital, and to analyze its association with early readmission for HF and all-cause mortality.

Methods

Retrospective cohort study of patients consecutively admitted to a HF Unit for AHF in one year (from 11/2017 until 10/2018). Exclusion criteria: death before discharge; transfer to another

hospital. We compared patients who were evaluated in a follow-up visit 7 to 14 days after discharge from the hospital, where treatment adjustments could be made by the HF specialist, with those who were not evaluated. Primary outcomes: readmission for AHF and all-cause mortality at 3 months after discharge. Cox proportional hazards regression was used.

Results

Of 181 admissions for AHF, 153 were analyzed. Patients were 77±11 years-old; 54% were male and 46% had reduced left ventricular ejection fraction. At discharge from the hospital, median NT-proBNP was 3258 (1429-5995) pg/mL. One-hundred and thirty-six (89%) patients were referred to a follow-up visit by the same multidisciplinary HF team within 7 to 14 days after discharge, of which 79% (n=107) complied. The mortality rate after 3 months was 6.5% (n=10) and the AHF readmission rate was 14.7% (n=22).

An early follow-up visit was independently associated with a lower risk of readmission for AHF at 3 months (crude HR 0.32, 95% Confidence Interval (CI): 0.14-0.75, $p=0.008$; adjusted HR 0.26, 95% CI: 0.10-0.66, $p=0.004$) and a lower combined risk of all-cause mortality or readmission for AHF at 3 months (crude HR 0.37, 95% CI: 0.18-0.78, $p=0.009$; adjusted OR 0.32, 95% CI: 0.13-0.72, $p=0.006$).

Conclusion

We found a high compliance with an early specialized follow-up visit after hospitalization for AHF. A multidisciplinary HF team visit in the vulnerable transition period after hospitalization for AHF is feasible and was associated with lower risk of HF readmission and death from all-cause at 3 months, mostly due to preventable readmissions.

#1004 - Case Report

AN EMERGENCY

Elsa Araújo, Manuel Barbosa, Marta Pereira, Vítor Costa, Bárbara Sousa, Helena Vilaça

Unidade Local de Saúde do Alto Minho, Viana Do Castelo, Portugal

Introduction

Hypertensive emergencies (HE) are characterized by acute, severe elevation in blood pressure (BP) associated with the presence or impendence of target-organ dysfunction. HE is uncommon, with an estimated population incidence of 1 to 2 cases per million per year.

Case description

A 50-year-old male, caucasian, with a history of recently diagnosed hypertension (HT), dyslipidemia and smoking habits presented to the emergency department (ED) because of headache and blurred vision with 24 hours of onset. Despite presenting a BP of 220/110 mmHg he was medicated with antihypertensive therapy and was discharged with a therapeutic adjustment.

He returned to the ED the next day with worsened complaints. His BP was 191/103 mmHg and ocular fundus examination showed bilateral papilledema and scattered hemorrhagic exudates, findings consistent with hypertensive retinopathy. His admission labs were significant for anemia, thrombocytopenia and acute kidney injury. Proteins and erythrocytes were detected in urinary sediment and the electrocardiogram presented criteria of left ventricular hypertrophy. Brain computed tomography, renal echography and renal arterial doppler were unremarkable.

The patient was admitted to the intensive care unit for HE with multiple target-organ dysfunction: hypertensive retinopathy and thrombotic microangiopathy with thrombocytopenia, hemolytic anemia and acute kidney injury. He was started on labetalol perfusion for 24 hours for BP control and, later, with oral antihypertensive therapy.

The remaining etiological study excluded other causes of HE and secondary HT.

The patient's BP profile was controlled using triple antihypertensive therapy (angiotensin-converting enzyme inhibitor, calcium channel blockers and β -blockers). The patient maintained vigilance in internal medicine consultation and nephrology. Currently, 1 year after the HE episode, the patient has progressed to chronic kidney disease (CKD) with estimated glomerular filtration rate at 50ml/min/1.73m².

Discussion

HE are acute and life threatening, so doctors need to recognize and treat them immediately so as to reverse the target organ injury. In this case, given the patient's delay in seeking help, as well as the delay in diagnosis and initiation of treatment, the patient maintained target-organ dysfunction, with progression to CKD.

#1016 - Case Report

CLINICAL-EVOLUTION PARTICULARITIES OF EBSTEIN'S ANOMALY

Nicoleta Dima¹, Elena Rezus¹, Roxana Ganceanu-Rusu¹, Andreea Clim², Minela Aida Maranduca¹, Viorica Ungureanu², Adelina Parlapan², Codruta Badescu¹, Ciprian Rezus¹

¹ "Grigore T. Popa" University of Medicine and Pharmacy, Iasi, Romania

² "Sf. Spiridon" Clinical Emergency Hospital, Iasi, Romania

Introduction

Ebstein's anomaly is a congenital heart defect characterized by an anomaly of the tricuspid valve apparatus. It consists in attaching apical septal and posterior tricuspid valve to the right ventricle wall, with subsequent atrialization of right ventricle. It is a rare condition that occurs in 1 out of 210 000 people, which represents less than 1% of all congenital heart malformations and may develop asymptomatic at many patients until the third and fourth decades of life, representing a significant public health problem.

Case description

59-year-old patient diagnosed at age of 26 with the Ebstein's

anomaly, delaying surgery, occupational exposure to respiratory hazards for about 30 years (metal powders environment), with recurrent episodes of bilateral ankle thrombophlebitis at the age of 37 when chronic oral anticoagulation was initiated, with a history of syncope episode, associating secondary polycythemia. The patient is hospitalized with serious overall condition in the context of global cardiac decompensation. Explorations carried out reaffirms cardiac malformation - atrial septal defect ostium secundum type, membranous ventricular septal defect with two-way shunt in left ventricle and right atrium, with dysplasia and reshuffle the tricuspid valve, the right ventricle atrialized 50%, tricuspid stenosis and tricuspid regurgitation grade III (gradient RA/RV 60 mmHg), with signs of moderate pulmonary hypertension. The presence of secondary polyglobulia required repetitive therapeutic phlebotomy.

Discussion

Ebstein's disease presents a survival rate of 5% to the 5th decade of life. Surgical treatment in our patient's replacement of the tricuspid valve would not be enough to correct developed ventricular dysfunction and increased operator risk. Congenital heart malformations require special attention, interdisciplinary approach and periodic clinical monitoring because of complications that can develop with impaired quality of life - pulmonary hypertension, hyperviscosity syndrome and arrhythmias.

#1034 - Abstract

CLINICAL DETERMINANTS OF THE PR INTERVAL DURATION IN SWISS MIDDLE-AGED ADULTS: THE COLAUS STUDY

Marylène Bay, Peter Vollenweider, Pedro Marques-Vidal, Federica Bocchi, Etienne Pruvot, Jürg Schläpfer

Lausanne University Hospital, Lausanne, Switzerland

Background

Prolonged PR interval is associated to adverse outcomes, such as atrial fibrillation or cardiovascular and all-cause mortality. However, data on determinants of the PR interval are scarce. We aimed to identify the clinical and biological determinants of the PR interval duration in the general population.

Methods

Cross-sectional study conducted between 2014 and 2017 in a representative sample of the Swiss population. PR interval duration was assessed by a 12-lead electrocardiogram and categorized into prolonged (≥ 200 ms) or normal (< 200 ms) for analysis. Covariates were obtained either by questionnaire, interview, physical examination or blood testing. Determinants were identified using stepwise logistic and results were expressed as multivariable-adjusted odds ratio (OR) [95% confidence interval]. A further analysis was performed after adjusting for antiarrhythmic drugs, P-wave contribution to the length of PR interval (P duration/PR duration*100 ratio), electrolytes (kalemia, calcemia, magnesemia) and previous history of coronary heart disease.

Results

Overall, 3668 participants with measurable PR interval duration were included (55.6% females; mean age 62 ± 10 years). Prolonged PR interval was found in 365 (9.9%) participants. Stepwise logistic regression identified male sex (OR 1.49 [1.09-2.04], $p=0.012$); older age (65-74 years: OR 2.47 [1.78-3.43], $p<0.001$, and ≥ 75 years: OR 4.56 [3.13-6.64], $p<0.001$); increased height (per 5 cm, OR 1.16 [1.07-1.26], $p<0.001$) and hypertension (OR 1.45 [1.14-1.85], $p=0.003$) as positively associated and, at the opposite, current smoking (OR 0.64 [0.44-0.85], $p=0.015$) and high resting heart rate (≥ 70 beats/min, OR 0.46 [0.32-0.65], $p<0.001$) as negatively associated with prolonged PR interval duration. After further adjustment for the other covariates, male sex, older age and increased height remained positively, and high resting heart rate negatively associated with prolonged PR interval. Conversely, hypertension and current smoking were no longer associated.

Conclusion

In a sample of the Swiss middle-aged population, male sex, older age and increased height significantly increase the likelihood of a prolonged PR interval duration, whereas high resting heart rate significantly decreases it.

#1051 - Abstract

FEATURES OF NUTRITION IN YAKUTIA AND MORTALITY RATE FROM CIRCULATION SYSTEM DISEASES

Milana N. Petrova

M. K. Ammosov North-Eastern Federal University Institute of Medicine, Yakutsk, Russia

Background

The ability of the people to survive in difficult conditions, when in the winter - 50, in the summer + 40, and at the same time skillfully organizing their food is a special phenomenon in the material culture of the Yakut people. Yakut cuisine is based on national traditions, it absorbs the best elements of the northern kitchen tradition, includes a wide variety of dishes. Among the factors that have the greatest impact on the population's health indicators, the nature of nutrition plays an extremely important role: fatty foods that help survive in harsh climatic conditions contribute to the disturbance of lipid metabolism and the manifestation of circulatory system diseases.

Purpose of the study. To conduct a comparative analysis of mortality from diseases of the circulatory system in selected districts of the Republic of Sakha (Yakutia).

Methods

In July-August 2017, a survey was conducted using a sampling method for quota sampling ($n=870$), based on the structure of the general population by respondent employment. 745 questionnaires were distributed in 26 settlements of the Oymyakonsky, Tomponsky, Suntarsky, Namsky, Ust-Aldansky,

Verkhne-Vilyuysky uluses and Mirninsky districts, with a total population of 55,188.

Results

Mortality from circulatory system diseases has a certain tendency to decrease $y = -5,303x + 462.4$; $R^2 = 0.269$; from cerebrovascular diseases $y = -2.399x + 102.6$; $R^2 = 0.774$; from CHD slightly reduced $y = -1.066x + 177.0$, $R^2 = 0.059$; from AMI, negative dynamics have not been observed since 2000 $y = 0.497x + 29.41$, $R^2 = 0.344$. When analyzing the mortality of the population of the studied areas as a whole from diseases of the circulatory system in 2015-2016, most cases observed in Oimyakon ulus (1194.4-1354.2: 100000 population), from AMI (65.7-44.8: 100000 population) and from cerebrovascular diseases (219.1-179.1: 100000 population). There were more deaths from coronary heart disease in Tompon ulus (277.1-289.4: 100,000 population).

Conclusion

1. Given this situation, it is extremely important to pay attention to the diagnosis of circulatory system diseases in primary care facilities;
2. To conduct routine inspections among the nomadic peoples.

Acknowledgement. The abstract was published with the financial support of the Russian Foundation for Basic Research, the project "The Problem of Valorization and Popularization of Nutrition Culture of the Peoples of the North in Modern Conditions (on the Example of Yakutia)" No. 17-21-08001.

#1055 - Abstract

HEART FAILURE WITH MIDDLE-RANGED EJECTION FRACTION – A DISTINCT ENTITY OR AN INTERMEDIATE CLASS?

João Pedro Pais¹, Ana Sofia Matos¹, Ana Nascimento¹, Francisco Teixeira Da Silva¹, Miguel Romano¹, Rui Silva², Francisca Cardoso¹, Diana Guerra¹

¹ Unidade Local de Saúde do Alto Minho, Viana Do Castelo, Portugal

² Centro de Medicina de Reabilitação de Alcoitão, Alcoitão, Portugal

Background

Heart failure with middle-ranged ejection fraction (HFmrEF) is described as the presence of symptoms of HF, a left ventricular ejection fraction (LVEF) between 40% and 49%, high levels of natriuretic peptides and a structural heart disease or diastolic dysfunction. However, guidelines lack an evaluation of the differences between this new class and the two most known classes [HF with preserved ejection fraction (HFpEF) and HF with reduced ejection fraction (HFrEF)]. While some studies defend HFmrEF as a progression from one of the two existing classes, others present HFmrEF as a distinct entity, with specific clinical and demographic characteristics. With this work we intend to describe the clinical and demographic characteristics of patients with HF followed in an outpatient heart failure clinic.

Methods

The clinical files of all the patients followed in an Internal Medicine coordinated heart failure clinic, between April of 2014 and October of 2018 were collected. Patients without diagnostic criteria for heart failure were excluded. The demographic variables, comorbidities and clinical characteristics of heart failure were analysed. Statistical tests were performed using SPSS v25 software.

Results

A total of 315 clinical files were analysed. 63 patients were excluded for not meeting the criteria for diagnosis of HF. Of the remaining, 70 (27,8%) had a LVEF inferior to 40% (HFrEF), 33 (13,1%) had an LVEF between 40% and 49% (HFmrEF) and 130 (51,6%) had a LVEF over 50% (HFpEF). 18 patients (7,5%) were still being studied. In HFmrEF we observed a male predominance (60,6%), similar to HFrEF and higher than HFpEF. In HFmrEF, the median age at diagnosis was 83 years (being 73 years in HFrEF and 84 in HFpEF). HFmrEF patients had an intermediate prevalence of alcoholism, valvular disease, history of depression and smoking. HFmrEF patients had a significantly higher prevalence of coronary disease and a lower prevalence of chronic obstructive pulmonary disease as compared with HFrEF and HFpEF. When evaluating the etiology of HF, patients with HFmrEF had a significantly higher prevalence of ischaemic etiology.

Conclusion

Our results suggest that HFmrEF shares some characteristics with HFrEF and HFpEF, which favours the hypothesis that HFmrEF results from progression of one of the other types of HF, rather than representing a distinct entity. However, our work involves a small number of patients and further studies are required for a better understanding of this entity.

#1071 - Abstract

COULD RENAL MICROVASCULAR DAMAGE AND 25-OH VITAMIN D DEFICIT PREDICT PROGNOSIS IN HEART FAILURE?

Florina Buleu¹, Daniela Adina Moteli², Ovidiu Cosmin Iancu³, Ana-Maria Pah¹, Vladiana Turi¹, Petru Bucuras⁴, Ruxandra Maria Christodorescu¹, Simona Dragan¹

¹ University of Medicine and Pharmacy Victor Babes, Timisoara, Romania

² Fresenius Nephrocare Clinic, Timisoara, Romania

³ Regina Maria Private Clinic, Timisoara, Romania

⁴ Emergency County Hospital Pius Brinzeu, Timisoara, Romania

Background

Vitamin D deficiency, highly prevalent in heart failure (HF) patients increases arterial stiffness and has been associated with increased mortality risk. Renal resistive index (RRI) is a specific marker correlated with microvascular damage. The purpose of the study was to correlate arterial stiffness represented by vascular calcification biomarkers, 25-OH vitamin D3 levels, and RRI with parameters of left ventricular function in heart failure patients.

Methods

90 patients with a history of heart failure longer than 12 months, NYHA class II-III were selected from a database and divided into 3 groups based on left ventricular ejection fraction (LVEF): HF with preserved ejection fraction, group A (n=30), HF with mid-range ejection fraction, group B (n=30), and HF with reduced ejection fraction group C (n=30). Serum levels of 25-OH vitamin D3 were determined by ELISA. Left ventricular volumes (LVTSV, LVTDV) and LVEF were measured by echocardiography. Aortic pulse wave velocity (PWV) was determined using the Arteriograph device. Carotid intima-media thickness (CIMT) was measured using high resolution ultrasound and RRI was measured by duplex Doppler in the intrarenal segmentary arteries. Peak systolic velocity (PSV) and minimum end-diastolic velocity (EDV) were determined using angle correction and RRI was defined as (PSV-EDV)/PSV. The Spearman correlation test was used for the interpretation of the results.

Results

Serum levels of 25-OH vitamin D3 were significantly lower in group C compared to the other groups (17.35±4.51 vs 23.86±4.85 vs 26.29±4.97 ng/ml, p<0.0001).

25-OH vitamin D3 values were significantly correlated with cardiac parameters: LVTDV (r=-0.503, p<0.001), LVTSV (r=0.541, p<0.001), LVEF (r= 0.602, p<0.001), aortic PWV (r=-0.723, p<0.001) and also with IMT (r=-0.464, p<0.001).

RRI values were significantly correlated with cardiac parameters: LVTDV (r=0.355, p<0.001), LVTSV (r= 0.387, p<0.001), LVEF (r=0.534, p<0.001) aortic PWV (r=0.734, p<0.0001) and 25-OH vitamin D3 (r=-0.667, p<0.0001).

A significant association between serum vitamin D3 and RRI (Chi2 test, p <0.001) was established.

Conclusion

Measurement of arterial stiffness is a convenient, inexpensive and reliable method in heart failure patients.

RRI and 25-OH vitamin D3 deficit appear to be significantly correlated with the severity of the disease in HF patients.

Both markers might contribute to prognosis and treatment adjustments in these patients.

#1094 - Case Report

PERIMYOCARDITIS IN THE YOUNG - STILL A CHALLENGE

Estela Ferrão, Francisca Pulido Valente, Filipa Alves Santos, Maria José Grade, Luisa Arez

Algarve University Hospital Center - Hospital Portimão, Portimão, Portugal

Introduction

In the clinical practice we can find a spectrum of myopericardial syndromes whose classification depends on the degree of myocardium vs pericardium involvement, including pure

pericarditis and myocarditis, myopericarditis and perimyocarditis. However the terms are commonly misused.

The diagnostic and therapeutic approach is challenging, the etiology is mainly idiopathic and although the natural history is mainly benign, it can also evolve to a permanent cardiomyopathy.

Case description

A 19-year-old healthy man, presented to the emergency room with a 5 days history of headache, fever, productive cough, and a pleuritic chest pain since the day before. He referred a similar episode 3 weeks before, that had started with diarrhea, with spontaneous resolution.

Physical exam: Bibasal rales in the 2/3 of the right hemithorax.

Laboratory results: Total CK 1016 IU/L, 617 IU/L hs troponin T 1376 ng/l, proBPN 1479 pg/ml, CRP 205 mg/L. Serology, auto immunity and coagulation studies: negative. Negative pneumococcus and legionella urinary antigens

ECG: Inferolateral ST elevation and ST depression in V1.

Chest X ray: interstitial infiltrate in right pulmonary basis

Transthoracic echocardiography: reduced left ventricular global systolic function with left ventricular ejection fraction <40%, more marked hypokinesia in the posterolateral region.

He started empirical antibiotherapy directed to a possible atypical pneumonia. A cardiology evaluation was made. He was put on AAS, colchicine and medical therapy for heart failure with reduced ejection fraction and evolved clinical and analytically well.

Discussion

This case highlights the difficulty when diagnosing myopericardial syndromes since they can have a very variable clinical presentation, mimicking other clinical conditions including coronary acute syndromes, that must be ruled out because of their gravity.

Particular to the patient was that we could not exclude an atypical pneumonia as a rare cause of his perimyocarditis, despite the gastroenteritis history.

Because of the potential evolution to a dilated cardiomyopathy the optimal and timely diagnosis, treatment and follow up are crucial.

#1112 - Case Report

A 24-YEAR-OLD MAN WITH DEEP VEIN THROMBOSIS WITH NO APPARENT CAUSE

Ricardo De Los Rios De La Peña, Estefanía Martínez De Viergol Agrafojo, Ángela Soler Gómez

Hospital Universitario Puerta del Mar, Cádiz, Spain

Introduction

Deep vein thrombosis is a disease in which the blood fails to return from the peripheral venous system due to an obstruction of the vein that runs through an accumulation of platelets that form a thrombus. It is much more frequent in the lower limbs than in the upper limbs, as well as in women more than men. Among the possible risk factors for suffering this disease are smoking,

pregnancy, immobility, recent surgery, cancer or coagulation disorders, and others. Treatment involves anticoagulation full doses in acute disease and prophylaxis dose after a period of initial treatment, which can vary between 6 and 12 months.

Case description

A 24-year-old man attended the emergency department due to an enlarged left lower limb, with pain and redness. As an important background, it is important not to be a smoker, not to present cardiovascular risk factors, to have been operated on for intestinal obstruction with months of life and to have had a sedentary habit the previous month due to study reasons. In the emergency department, the patient is treated with analgesia and a first dose of anticoagulation, analytical is extracted with coagulation and a Doppler ultrasound of the affected limb is requested, where a thrombus that occludes the venous circulation of the left femoral and inguinal vein is discovered. Enter internal medicine for broader study. He is tested for coagulation disorders and serologies, being normal. To complete the study, thorax and abdomen CT angiography is requested, where a genetic venous malformation is found, an aplasia of the inferior vena cava, which causes the patient's thrombosis. Upon discharge, anticoagulation was prescribed with Edoxaban 60 mg for 6 months, being replaced by Rivaroxaban 10 mg, which should be taken for life.

Discussion

The duration of anticoagulation is not yet securely established. Most authors describe a minimum of 6 months of treatment, with subsequent revisions for suspension or change treatment. In cases of genetic malformation of blood vessels, as was our case, several studies have described the need for anticoagulation at prophylactic doses for life, since the recurrence of thrombosis has been proven in the majority of patients who stopped treatment.

#1113 - Medical Image

ISCHEMIA-INDUCED PATTERN OR INCIDENTAL FINDING?

Paulo Duarte Medeiros, Ana Sá, Vanessa Palha, Teresa Pimentel, Narciso Oliveira, Carlos Capela

Hospital de Braga, Braga, Portugal

Clinical summary

This is the ECG of a 77yo woman with history of hypertension that presented to the emergency room with complaints of epigastric pain that started 2h before.

On her physical examination we highlight an irregular heart rhythm and a tender abdomen.

The ECG revealed a ventricular trigeminy pattern, HR 75/min. Myocardial necrosis markers were negative. We performed an abdominal ultrasound that revealed thickened mesoappendix fat, which helped us making the diagnosis of appendicitis.

Acute appendicitis is a common diagnosis, but in this case the patient lacked other symptoms and the pain was mainly epigastric;

thus, we also ruled out the possibility of atypical myocardial infarction presentation. Finally, we should know that ventricular trigeminy does not signify myocardial ischemia.

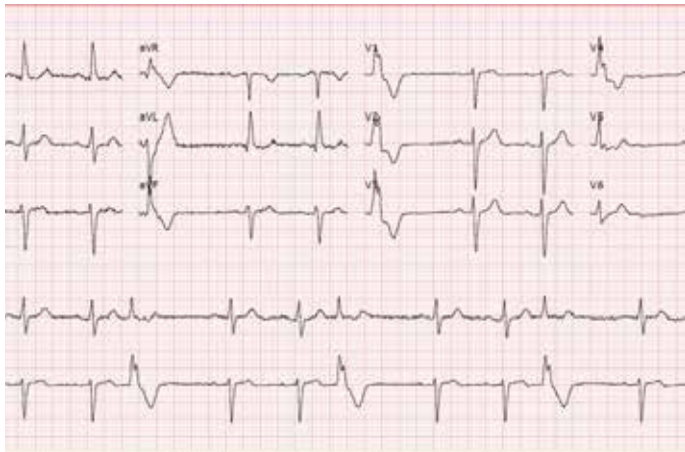


Figure #1113. Ischemia-induced pattern or incidental finding?

#1123 - Case Report

HIGH BLOOD PRESSURE DIFFERENCE BETWEEN BOTH UPPER LIMBS AS A DEBUT OF SUBCLAVIAN STEAL SYNDROME

Mario Salcedo¹, Sergio Palacios-Fernandez², María Sahuquillo¹, Jon Ortiz¹, Cristina Campo¹, Carmen Morata¹, Francisco Javier Salcedo Aguilar³

¹ Hospital Universitario y Politécnico La Fe, Valencia, Spain

² Hospital Clínico Universitario San Juan, San Juan De Alicante, Spain

³ Hospital San Pedro, Logroño, Spain

Introduction

A 53-year-old woman referred to external consultations of Internal Medicine for significant blood pressure difference between both upper limbs.

Personal background: smoking, arterial hypertension since one year ago, dyslipidemia and chronic ischemic heart disease (acute myocardial infarction with stent implantation 8 years before).

Case description

Physical examination revealed a blood pressure in the upper right limb of 140/90mmHg and 190/110mmHg in the left one.

Measurement of central arterial pressure was performed by flattening tonometry (Sphygmocor® system), which obtained a value of 160/100mmHg.

Subsequently, the following study was carried out:

- Echocardiogram showed slight septal hypertrophy without evidence of aortic coarctation;
- CT-angiography of supra-aortic trunks revealed a proximal focal critical stenosis in the right brachiocephalic trunk;
- Arteriography confirmed this stenosis. There was a retrograde (reversed) blood flow in the right vertebral artery. The right arm was supplied by blood flowing in a retrograde direction down the right vertebral artery at the expense of

the vertebrobasilar circulation. This is called subclavian steal syndrome;

- A brain MRI showed cortico-subcortical infarcts in areas of border zone, which suggested previous episodes of cerebral hypoperfusion.

Given the cerebral repercussion of this stenosis, and the risk of hypoperfusion with antihypertensive treatment, the patient is awaiting revascularization, despite the haemodynamic complexity of this procedure.

Discussion

In the initial diagnostic evaluation of a patient with hypertension, blood pressure should be systematically measured, and determinations should be made in both arms. When there is a blood pressure gap higher than 10mmHg between both upper limbs, a vascular study of the supra-aortic trunks must be carried out, ruling out stenosis of the subclavian artery, aortic coarctation or less common problems, such as brachiocephalic trunk stenosis. The most frequent etiology is the presence of arteriosclerotic lesions.

The measurement of central blood pressure can assist with the intensity of pharmacological treatment in these patients, until the defect is corrected.

#1131 - Abstract

VASCULAR RISK IN ELDERLY

Sara Muñoz Alonso, Victor Madrid Romero, Victoria Palomar Calvo, Carlota Tuñón De Almeida, Ana Isabel Rodrigo Martín, María Esther Fraile Villarejo, Montserrat Chimeno Viñas
Complejo Asistencial De Zamora, Zamora, Spain

Background

The elderly, patients over 65 years old, are increasing population figures in developed countries. Vascular diseases are leading causes of mortality and disability in elderly people.

In this study we evaluated vascular risks factors (hypertension, dyslipidemia and diabetes) in patients hospitalized in internal medicine and whether there are differences between elderly, very elderly and great elderly.

Methods

Observational descriptive retrospective study.

Patients were divided into three age groups: elderly (65-79 years), very elderly (80-89 years) and great elderly (more than 90 years). We analyzed vascular risk factors (hypertension, dyslipidemia and diabetes) in each age group as well as the percentage of total dependency measured by the Barthel scale.

Results

304 patients admitted to internal medicine were obtained, of which 50 were excluded because they were under 65 years old, hence n= 254 patients.

22.8% were elderly (total dependency 13.8%), 56.3% were

very elderly (total dependency 45%) and 20.9% were great elderly (total dependency 58.5%). Differences were found in the proportion of hypertensive patients according to their age range ($X^2=7.6$, $p<0.05$), the very elderly and great elderly had higher blood pressure (76.9% and 77.8%) than the elderly (58.6%). In the rest of the vascular risk factors evaluated (diabetes, dyslipidemia) they were not found in greater proportion in the very elderly and great elderly patients.

Conclusion

It is clear that high blood pressure and age are directly related. We need to be cautious and individually evaluate the start or maintenance of drugs for vascular risk control. The main factors to be taken into account in this population group are life expectancy, comorbidity and functional capacity.

Since more than half of the very elderly are totally dependent in this study, perhaps vascular risk control drugs should not be used in this population group.

#1137 - Abstract

ASSOCIATION WITH NEW-ONSET ATRIAL FIBRILLATION AND CANCER: A RETROSPECTIVE STUDY

Alda Tavares¹, Sara M. Pinto², Mário Bibi², Rute Ferreira², Cristina Rosário²

¹ Department of Medical Oncology, Hospital Pedro Hispano, Matosinhos Local Health Unit., Matosinhos, Portugal

² Department of Internal Medicine, Hospital Pedro Hispano, Matosinhos Local Health Unit., Matosinhos, Portugal

Background

An association between atrial fibrillation (AF) and cancer has been reported, likely because of systemic inflammation, shared risk factors, and common disease states underlying both conditions in ageing populations. Recent studies suggest that cancer increases the risk of new-onset AF (NOAF). The aim of this study was to describe clinical characteristics associated with NOAF in cancer patients.

Methods

A retrospective study was conducted, among patients (pts) admitted with AF in our Internal Medicine Ward, between April of 2014 and June of 2015. The pts with a cancer diagnosis in the last 60 months were selected and epidemiological and clinical data were collected. Active cancer was defined for diagnosis of cancer or any anti-cancer treatment within 6 months before admission. Statistical analysis was performed with SPSS® software v25; values $p<0,05$ were considered statistically significant.

Results

Among 214 pts admitted with AF, 19 (8.8%) had a diagnosis of cancer in the last 60 months. Of whom, 14 (33.7%) had active cancer. Breast (21.1%), colorectal (21.1%), lung (15.8%) and

prostate cancer (15.8%) were the more frequent types of cancer. Metastatic disease presented in 5 pts (26.3%).

NOAF was diagnosed in 7 pts (36.8%) with a diagnosis of cancer in the last 60 months and 6 (42.9%) with active cancer. Comparing clinical characteristics between the groups with/without a new-onset AF, no significant differences were found concerning age, sex, and comorbidities. Attended to a type and metastatic cancer, only pts with active lung cancer had a higher rate of new-onset AF with significant difference ($p=0.036$).

The median interval of diagnosis AF and cancer was 23 months (1-147). No significant differences were found concerning the rates of NOAF between groups with a diagnosis of cancer in the last 24, 12, 6, and 3 months.

Anti-cancer therapy in the last 6 months was executed in 8 pts (42.1%): surgery in 4, chemotherapy in 4, radiotherapy in 4, and hormonotherapy in 4 pts. A NOAF was more frequent in the group submitted to treatment, but not statistical significance.

Conclusion

In this retrospective study, only active lung cancer was associated with NOAF. Larger studies for evaluating the association with AF and cancer are needed, to identify cancer parameters associated with NOAF.

#1157 - Abstract

TROPONIN TRENDS IN PATIENTS WITH MYOCARDITIS: A CASE SERIES

Vera P Sarmiento, Bruno Piçarra, João Pais, Mafalda Carrington, Ana Rita Santos, Margarida Massas, Diana Coutinho, Tereza Veloso, José Aguiar

Hospital do Espírito Santo de Évora, Évora, Portugal

Background

It is generally understood that patients with myocarditis present with a descending troponin curve, unlike patients with acute coronary syndromes, though the evidence for this belief is not clear. We designed this study to determine the troponin trends in patients with myocarditis.

Methods

We have identified all patients admitted with MRI-confirmed myocarditis to the Cardiology ward of a central hospital, from 2014 to 2016. We registered socio-demographic and clinical variables, including the individual troponin values obtained for each patient. We analysed the data descriptively, comparing the groups in relation to the different troponin trends found. Patients with less than three troponin measurements were excluded.

Results

There were 54 patients admitted with myocarditis to the Cardiology ward, from which 42 (78%) were men, median age 33 (IQR 24,5-48), 42 had at least one cardiovascular risk factor, more frequently hypertension, and two patients had previous

episodes of myocarditis. There were 35 patients (65%) reporting an infection in the previous 30 days. All patients, except one, presented with pain, 20 patients had documented fever, 30 (56%) patients presented with ST elevation in the 12-lead EKG. We included 42 patients in the troponin trend analyses (the remaining 12 had less than three troponin values measured). For 25 patients (62%) the troponin increased in the first hours to days of presentation, and then began its descending curve (inverted U-shaped curve). Most of these patients had a maximum troponin value at 6-24h of presentation. In 16 cases, the troponin followed a descending-only curve. In one case, there was a second increase in troponin at 72h of presentation, followed by a decrease of its value.

Conclusion

The troponin trends of patients with myocarditis is varied. In our series, more than half of the patients presented an inverted U-shaped curve, similar to that of acute myocardial infarction patients. Therefore, the troponin trend does not seem a reliable tool to support the differential diagnosis between myocarditis and acute coronary syndromes, though larger studies are needed in order to confirm our findings.

#1162 - Medical Image

LIPODERMATOSCLEROSIS

Sara Braga, Joana Ribeiro

Hospital Sousa Martins, Guarda, Portugal

Clinical summary

Lipodermatosclerosis (LDS) is a skin inflammation occurring usually in the legs, caused when venous blood doesn't return to the heart. Increased blood pressure in the veins can cause diffusion of substances, like fibrin, out of capillaries, leading to ulceration. Recurrent ulceration and necrosis can develop LDS. In advanced LDS the proximal leg swells from chronic venous obstruction and the lower leg shrinks from chronic ulceration and necrosis resulting in the inverted coke bottle appearance of the lower leg. These legs belong to a 46-year-old man with a congenital pulmonary valve stenosis, whose treatment (after commissurotomy and tricuspid ring implantation) is based on medication and follow-up of heart failure, sometimes presenting severe decompensation which leads to hospitalization.

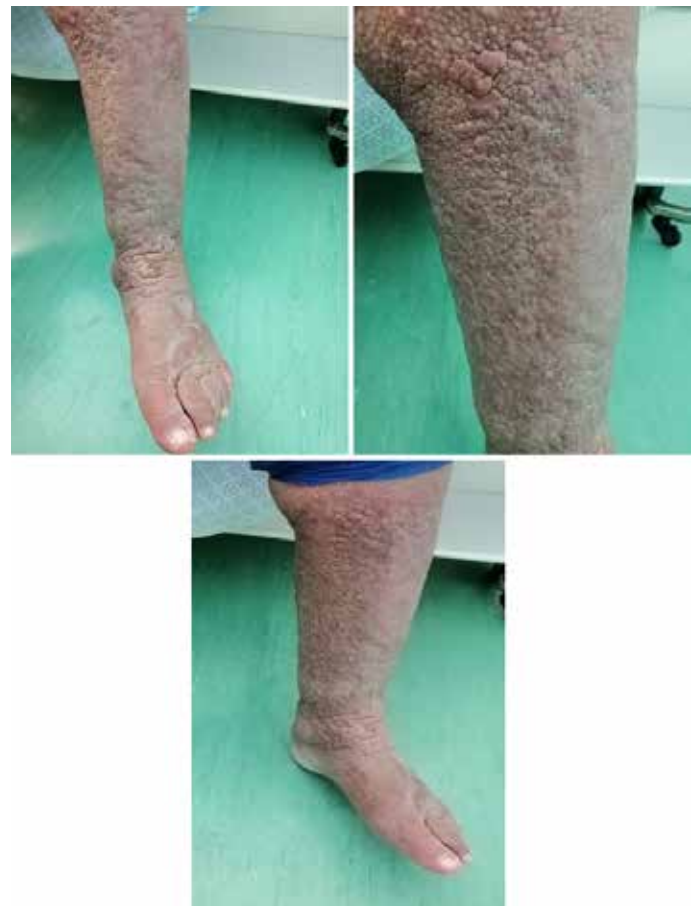

Figure #1162. Lipodermatosclerosis, male, 46 years old.

#1163 - Medical Image

LIVING WITH A COMPLETE ABDOMINAL AORTA THROMBOSIS

Luisa Costa, Andreia Silva, Ana Rodrigues, Carolina Ferreira, Jesus Garrido, Carla Lima, Sérgio Lemos

Centro Hospitalar Tondela Viseu, Viseu, Portugal

Clinical summary

A 54-year-old man, presented to the emergency department with back pain and anuria. On examination, his blood pressure was 190/120 mmHg, no femoral pulse and collateral abdominal circulation. Laboratory evaluation identified serum creatinine of 9.9 mg/dL, hyperkalemia of 7.6 mmol/L and blood urea nitrogen level of 292 mg/dL, that motivated hemodialysis support. A contrasted abdominopelvic computed tomography revealed a mural thrombus causing total occlusion of the abdominal aorta immediately below the emergence of the superior mesentery artery, including renal, iliacs and femoral arteries, with exuberant collateral circulation. Treatment consisted of conservative measures and chronic hemodialysis. The patient died two years later, after a pancreatitis, remaining autonomous until that day.

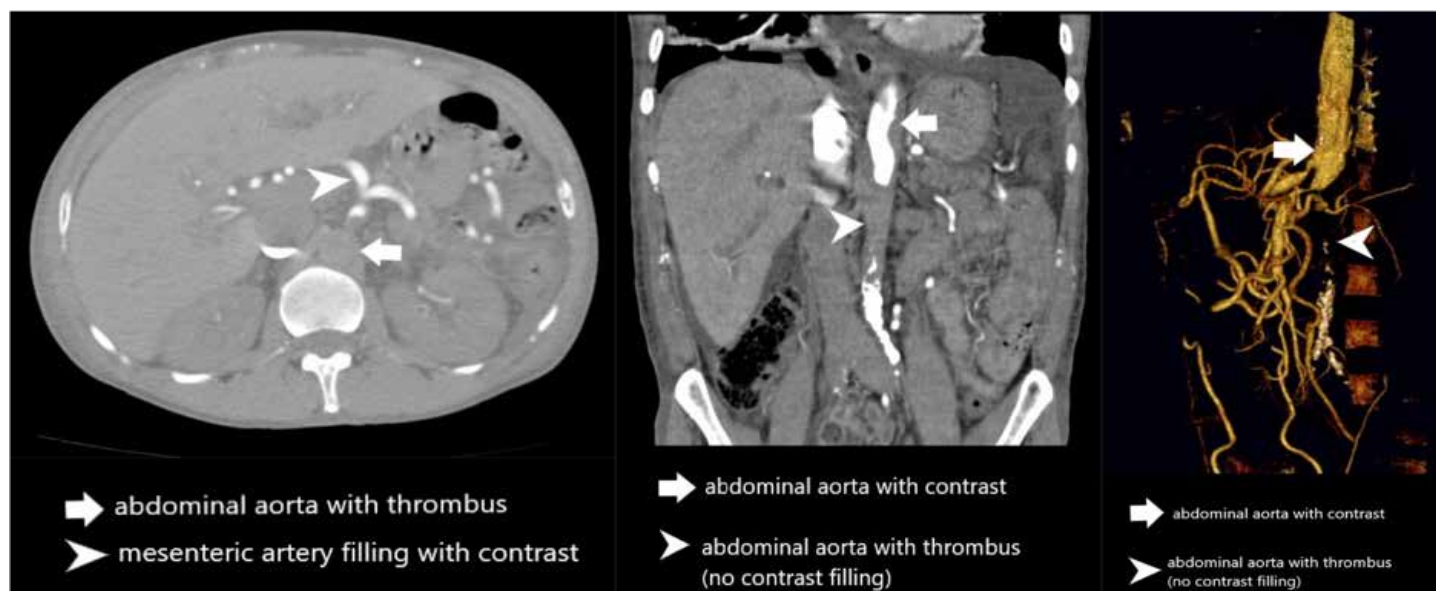


Figure #1163. CT scan - Abdominal aorta thrombus.

#1169 - Abstract

ATRIAL FIBRILLATION AND HEART FAILURE: A COMBINATION FOR DISASTER?

Sara Moreira Pinto, Alda Tavares, Mário Bibi, Rute Morais Ferreira, Cristina Rosário

Hospital Pedro Hispano, Oporto, Portugal

Background

Atrial fibrillation (AF) is the most common sustained arrhythmia. Its development and stability are directly related to the patients morbidity, such as Heart Failure (HF). If on one hand HF promotes AF, this one also influences the course and exacerbations of HF. We analysed patients admitted with AF and HF, in terms of demographic, treatment approach and risk of readmissions.

Methods

A retrospective study was conducted among patients admitted in an Internal Medicine Ward, between April of 2014 and June of 2015. The patients with AF were selected and epidemiological, clinical and analytical data were collected and analysed. Statistical analysis was performed with SPSS® software v25; values $p < 0,05$ were considered statistically significant.

Results

A total of 236 admissions and 214 patients were examined, with a median age of 77 years and 66% of women. A total of 41% of AF were classified as inaugural. Fifty percent of patients had the diagnosis of HF at admission, in which 53% were in class II of NYHA; 12% in class I; 22% in class III and 2% in class IV. Of these patients, only 65% were anticoagulated at discharge, mostly with vitamin K antagonists (75%), 9% with apixaban, 8% with dabigatran and 3% with rivaroxaban. Sixteen percent of patients had an ejection fraction lower than 35%. During hospital admission 8% of patients with AF and HF died and 17% died in the first year after discharge.

When it comes to anticoagulation and poor outcome, 10% of anticoagulated patients died in the first year compared to 39% of deaths in non-anticoagulated patients ($p=0.001$). In terms of readmissions in the first 6 months, there were 76 readmissions in AF and HF patients, compared to only 54 readmissions in patients without HF.

Conclusion

With population aging, HF and AF will be more prevalent, making the diagnosis, stratification and correct treatment more important. Only by acting on both, we can manage a better quality of life for our patients, free from exacerbations, hospital admissions and symptoms. We verified a worst outcome in patients that were not anticoagulated at discharge, as expected. According to several studies, catheter ablation is a possibility we need to consider in patients with ejection fraction lower than 35%. In our study, there were a significant percentage of patients (16%) that could had benefited from this treatment. More studies will be necessary in order to demonstrate efficacy and safety of this procedure, as well as the real impact in the lives of our patients.

#1170 - Abstract

ANTICOAGULATION IN PATIENTS WITH ATRIAL FIBRILLATION AND CHRONIC KIDNEY DISEASE: A RETROSPECTIVE STUDY

Sara Moreira Pinto, Mário Bibi, Alta Tavares, Rute Morais Ferreira, Cristina Rosário

Hospital Pedro Hispano, Oporto, Portugal

Background

Atrial fibrillation (AF) is the most common sustained arrhythmia and is directly dependent on patient morbidity, such as chronic kidney disease (CKD). There is a clear dichotomy between these

entities, being indispensable the evaluation of CKD and its stage before starting anticoagulation. If on one hand, in stages 3 and 4 of CKD the main concern is the thrombotic risk, in stage 5 the hemorrhagic risk is more substantial. As so, it became imperative to find alternative strategies for those patients.

Objective: Analysis of demographic data and treatment approach in patients with CKD and diagnosis of AF.

Methods

A retrospective study was conducted, among patients admitted in our Internal Medicine Ward, between April of 2014 and June of 2015 with AF. Epidemiological, clinical and analytical data was collected and analysed.

Results

A total of 236 admissions and 214 patients were examined, with a median age of 77 years and 66% of women. A total of 41% of AF were classified as inaugural. Twenty percent of patients had stage 3 CKD, 7% had stage 4 CKD and 1% had stage 5 CKD. Of these patients, just 57%, 56% and 67% respectively were anticoagulated at discharge, even with clear superior CHA₂DS₂-VASc (median of 4) when compared to HAS-BLED (median of 1). Vitamin K antagonists were the first choice in anticoagulation, prescribed in 70% of stage 3 CKD, 44% of stage 4 CKD and 100% of cases in stage 5 CKD. The preferred direct oral anticoagulant (DOAC) was apixaban in 15% of stage 3 CKD patients and 44% of stage 4 CKD. Rivaroxaban was used in 11% of patients in stage 3 CKD. No patient was proposed to closure of auricular appendix.

Conclusion

The presence of CKD in AF patients plays a big role in the decision of anticoagulation, being in many cases responsible for the decision of not anticoagulate. This may reflect the fact that fewer than 50% of patients with AF and CKD were anticoagulated at discharge in our cohort. On the other hand, vitamin K antagonists remain the preferred drugs, most likely because they are older and are able to be monitored through INR. There is a need for more prospective studies that show the efficacy of auricular appendix closure, as well as studies in the safety of DOACs. Even so, regarding DOAC, apixaban is the only currently approved by United States Food and Drug Administration in all stages of CKD, presenting with a low hemorrhagic risk.

#1216 - Abstract

INFLUENCE OF DISABILITY ON LONG-TERM PROGNOSIS OF HEART FAILURE PATIENTS WITH PRESERVED EJECTION FRACTION

Aicha Alaoui-Quesada, Aída Gil-Díaz, Yonay Ramírez-Blanco, Dolores Pérez-Ramada, Héctor Rosario-Mendoza, María Eugenia Arkuch-Saade, Alicia Conde-Martel

Hospital Universitario de Gran Canaria Dr. Negrín, Las Palmas De Gran Canaria, Spain

Background

Heart failure is a frequent syndrome seen in Internal Medicine, being predominant in our patients the advanced age, multimorbidity and preserved ejection fraction. The natural history and optimal treatment of these patients remains unclear. Recognition of prognostic risk factors is relevant to identify patients with advanced heart failure who could benefit from a closer follow-up and need of palliative referral.

Methods

We performed a prospective observational study of patients from Internal Medicine consultations with chronic heart failure and preserved ejection fraction. We collected demographic and clinical characteristics including functional capacity measured with the Barthel index, analytical and echocardiographic parameters, emergency visits and hospitalizations due to heart failure decompensation. We analyzed the association of mortality between categorical variables with Chi-square or Fisher test and T-Student or Mann Whitney test for the categorical and continuous variables. We obtained the predictive mortality variables with a Cox regression model.

Results

160 outpatients were studied with a follow up of 2 years, being 38.8% males with an average age of 79.35 and 61.2% women with an average age of 79.91. The most frequent comorbidities were: hypertension (98.1%), atrial fibrillation (73.7%), anemia (69.3%) and chronic renal failure (58.6%). The observed mortality was 45.6%. The main cause was a cardiovascular origin (63.3%), being 94.7% of them due to refractory heart failure. There were no sex differences. Variables associated with mortality were: age ($p=0.028$), ischaemic cardiopathy (OR 2.22, $p=0.026$), hyperuricemia (OR 2.25, $p=0.019$), frailty (OR 4.05, $p=0.002$), creatinine plasmatic levels ($p=0.005$), hemoglobin ($p=0.002$), sodium ($p=0.007$), Barthel index below 60 (OR 2.93, $p=0.014$) and more than 6 days of hospitalization during the previous year (OR 4.50, $p=0.002$).

Predictive mortality variables in the multivariable Cox regression were Barthel index <60 points (HR 3.32. IC95% 1.67-6.60. $p=0.001$), creatinine >2 mg/dl (HR 5.75. IC95% 2.17-15.19. $p<0.001$), sodium <140 mEq/L (HR 2.04. IC95% 1.06-3.95. $p=0.034$) and more than 6 days of hospitalization in the last year (HR 3.53. IC95% 1.28-9.76. $p=0.015$).

Conclusion

Patients with preserved ejection fraction had a high long-term death rate. Poor functional basal status determined by Barthel index, renal insufficiency, plasmatic sodium and hospital admission predicted mortality.

#1217 - Abstract

DYSLIPIDEMIE DURING DIFFERENT THERAPEUTIC DISEASE

Marina Noniashvili

Tbilisi State Medical University, Tbilisi, Georgia

Background

Study of lipid spectrum changes during different therapeutic pathologies.

Methods

Retrospectively was studied the history of 267 patients (181 women and 86 men, whose average age was 42+15,1 years). They were treated with different diagnoses: thyroid pathologies (97 patients), respiratory system diseases (106), kidney pathologies (20), pathology of joints (37), and gastrointestinal diseases (7). Age groups were allocated: under 40 years: -125 patients, above 40 years: -142 patients. The lipid spectrum indicators, the characteristics of dyslipidemia and the results of antilipid treatment were assessed.

Results

Lipid spectrum was examined in 89,7% with thyroid gland pathology. Dyslipidemia was revealed in 46%, and was treated 50%. During the respiratory system pathologies, the lipid spectrum detection was done 4 times less in 24% of patients, dyslipidemia was revealed in 46%, only 8,3% ($p < 0,05$) was treated by antilipid medicine. In kidney pathologies lipidogram was conducted in 40%, Dyslipidemia was detected only in 12.5%. The rate of lipid spectrum detection was the lowest in patients with joints diseases and was examined in 10.10%, dyslipidemia was revealed in 25% ($p < 0,05$). The lipid spectrum in patients with gastrointestinal system pathologies was investigated in 85,7%, and only in 16.6% was detected dyslipidemia.

In patients with thyroid pathologies according to the lipid spectrum, were revealed high rates of triglycerides and total cholesterol -32, 5% and 25% -isolated high rates of total cholesterol; Hypertriglyceridemia 15%, common cholesterol and low Density lipoproteins in 10%, all atherogenic fractions was increased in 17.5%. In patients with respiratory diseases increased total cholesterol have been reported in 41.6%; high rates of triglycerides and total cholesterol in 25.3%; all atherogenic fractions was increased in 25%; only in 8% high rates of triglycerides was revealed. ($p=0.5$).

Conclusion

Thus, patients with chronic pathologies of thyroid gland have high levels of dyslipidemia and treatment. Insufficient control of the lipid spectrum was revealed in patients with respiratory system diseases, kidneys, joints' and other pathologies. High frequency of lipid spectrum detection and low levels of dyslipidemia were observed during gastrointestinal pathologies. Thus, in patients with different therapeutic pathologies it is recommended to control lipid spectrum regardless of age, especially if you have a risk factors of CVS diseases.

#1220 - Abstract

IN-HOSPITAL MORTALITY IN HEART FAILURE NONAGENARIAN PATIENTS. RECANIC SUBANALYSIS.

Aída Gil-Díaz¹, Jose María García Vallejo¹, Elvira Sáez-Martínez¹, Iván Marrero-Medina¹, Melitón Dávila-Ramos², Alina Pérez-Ramírez³, Antonio García-Quintana¹, Alicia Conde-Martel¹

¹ Hospital Universitario de Gran Canaria Dr. Negrín, Las Palmas De Gran Canaria, Spain

² Hospital Universitario Nuestra Señora de La Candelaria, Santa Cruz De Tenerife, Spain

³ Hospital Universitario de Canarias, San Cristobal De La Laguna, Spain

Background

Heart failure is the first cause of admission in older patients. Age and multimorbidity are related. Nevertheless, some studies have suggested that geriatric components (frailty, cognition, nutrition or functional status) play a role in the prognosis of these patients. It is important to identify elderly patients with worse prognosis in order to improve the medical care and quality of life.

Methods

We performed a prospective multicenter observational study in the Canary Islands hospitals (RECANIC) with patients admitted in Cardiology and Internal Medicine departments due to heart failure. In this abstract we considered only patients older than 75 years. We collected demographic and clinical characteristics including functional capacity measured with the Barthel index, NYHA functional class, left ventricular ejection fraction (LVEF), analytical parameters, treatments and clinical evolution. We compared nonagenarian prognosis with older than 75 years with Chi-square or Fisher test for categorical variables and T-student or Mann-Whitney test for the categorical and continuous variables. We obtained the predictive mortality variables with a multivariable logistic regression.

Results

2200 patients were registered in the RECANIC study, out of which 1365 were older than 75 years old, with 193 nonagenarians. Nonagenarians were mostly women ($p < 0.001$), presenting more renal insufficiency ($p < 0.001$), cognitive impairment ($p < 0.001$), institutionalization ($p = 0.012$) and worse functional status in the Barthel index ($p < 0.001$) compared to 75-89 year old patients. Preserved LVEF was the most prevalent finding in both groups. Respiratory infections were the main cause of heart failure decompensation. Mortality of nonagenarians was greater (16.1 vs 9.6%) than patients within 75-89 years ($p = 0.009$). Variables associated with mortality in nonagenarians were: dyslipidemia ($p = 0.007$), cognitive impairment ($p = 0.012$), renal function measured by GFR (MDRD) below 30 ($p < 0.001$), NT-proBNP ($p = 0.007$) and potassium serum levels ($p < 0.001$). Predictive mortality variables of nonagenarian inpatients in the multivariable logistic regression were: masculine gender (HR 5.04. IC95% 1.54-16.51. $p = 0.008$), Barthel index < 60 (HR 3.44. IC95% 1.20-9.87. $p = 0.021$) and GFR < 30 (HR 14.36. IC95% 4.42-46.66. $p < 0.001$).

Conclusion

Nonagenarians constitute 8.77% of the total admissions due to heart failure. In-hospital mortality is superior to less elderly patients and is related to sex, poor functional capacity and renal insufficiency.

#1227 - Abstract

DIABETES AND CARDIOVASCULAR RISK - ANALYSIS OF PATIENTS FOLLOWED IN THE MEDICAL CONSULTATION OF DIABETOLOGY

Natália Teixeira Nunes Teixeira¹, Ana Rita Paulos¹, Ana Mestre², Marta Cerol¹

¹ Hospital Distrital Santarem, Santarém, Portugal

² Hospital Distrital Santarém, Santarém, Portugal

Background

Diabetes mellitus (DM) is closely associated with cardiovascular disease (CV), which is a huge challenge considering the prevalence, resources mobilized for treatment and inherent morbidities. Macrovascular complications continue to be one of the most common causes of death. Objectives - characterization of the cholesterolemic profile in a group of patients with DM, CV risk analysis and therapeutic strategies.

Methods

Retrospective study of patients with DM, followed in a Diabetology consultation in 2017. Data were collected between the first and last visit performed in the referred period, through SClinico and the statistical analysis performed in Excel.

Results

The total number of patients was 108. The mean disease duration was 17 years, the male gender predominated (51%), the most frequent age group was 61-70 years old, with a mean age of 64.5 years and 87% were type 2 diabetics. Mean hemoglobin A1C was 8%, and about 56% of patients were obese. Presence of hypertension in 76.4%, dyslipidemia in 61.4%, sedentary lifestyle in 38.7% and smoking in 8.7% of the cases. Regarding LDL cholesterol levels, 81.4% had values > 70 mg / dl and 78.3% had HDL <60 mg / dl. The mean overall cardiovascular risk (CVR) according to the ASCVD risk score was elevated by 31.2%. 62% had statins, 87.4% antihypertensive therapy, 39.8% antiplatelet aggregation and 7.6% oral hypocoagulation. The most commonly prescribed statins are simvastatin, followed by atorvastatin. The most common macrovascular complications were coronary disease (42.03%), peripheral arteriopathy (19.27%) and cerebrovascular disease (13.68%).

Conclusion

In view of the results obtained, the therapeutics directed to this area of the disease should be optimized and intensified, namely in the selection of the statin more appropriate to the RCV profile.

#1232 - Case Report

CONVOLUTED SIMPLICITY: A CASE OF ORTHOSTATIC HYPOTENSION, HIDING MULTIPLE UNRELATED CONTRIBUTORY CAUSES

Pietro Di Francesco, Alice Monti, Elisa Ceriani, Davide Villa, Giorgio Mantoan, Nicola Montano, Eleonora Tobaldini

Department of Internal Medicine, Fondazione IRCSS Ca Granda, Ospedale Maggiore Policlinico, and Department of Clinical Sciences and Community Health, University of Milan, Milan, Italy

Introduction

Orthostatic hypotension is a clinical manifestation of an underlying disease that in older patients is commonly related to an autonomic nervous system dysfunction. While Occam's razor prompts us to look for a common origin, a single mechanism might hide multiple predisposing factors.

Case description

A 81 y.o. man presented to the emergency department (ED) after two pre-syncope episodes. Medical history included type 2 diabetes, colon cancer recently treated with an emicolectomy and previous history of pre-syncope episodes.

In ED, physical examination revealed a systolic murmur, ECG showed first degree AV block and blood test revealed acute pre-renal failure. The bed-side echocardiogram showed mild pericardial effusion without tamponade. Thus, we performed a chest CT, that was negative for aortic dissection but it revealed a right hemi-diaphragmatic elevation that causes a significant compression of the right heart and a left shift of mediastinum.

The patient revealed significant orthostatic hypotension while echocardiogram highlighted a moderate dynamic subaortic stenosis exclusively in orthostatic position.

The patient was treated with low dose bisoprolol and intravenous hydration for subaortic stenosis and pre-renal failure. No surgical options were available for hemi-diaphragmatic elevation.

After few days of treatment, the patient had no more orthostatic hypotension; the echocardiogram was repeated and it showed normal trans-aortic velocity even during standing.

Thus, this patient had three different factors that contributed to decrease cardiac output causing pre-syncope. First, cardiac subaortic stenosis, treated with beta-blockers. Second, the mechanical compression of the elevated diaphragm. Finally, hypovolemia, which worsened the pre-existing conditions and that was treated with fluid supplementation.

Discussion

A careful evaluation of all the possible mechanisms involved in the pathogenesis of a disease and an accurate use of echocardiography, not only in static but also in dynamic situation, helped finding the correct treatment in this tricky situation that could, at first glance, lead to a misinterpretation of the available data.

#1242 - Abstract

MARKERS OF CALCIUM METABOLISM IN CALCIFIC AORTIC VALVE DISEASE

Madina Khasanovna Baikulova¹, Elena Vital'Evna Shcheglova², Olga Igorevna Boeva²

¹ Regional Clinical Cardiology Centre, Stavropol, Russia

² Stavropol State Medical University, Stavropol, Russia

Background

Disturbances of mineral metabolism are common among elderly people and are potentially involved in the development of calcifying aortic valve disease. In particular, in chronic kidney disease, when electrolyte disorders are especially pronounced, high levels of calcium and phosphate significantly increase the risk of valvular heart disease. In addition, primary hyperparathyroidism is associated with the risk of aortic stenosis. These data suggest that some characteristics of calcium metabolism may determine susceptibility to calcific aortic valve disease in the general population of patients who do not suffer from severe concomitant pathology. The aim of the study was to test the hypothesis about the association of blood levels of calcium metabolism markers, such as parathyroid hormone, vitamin D and ionized calcium, with calcifying aortic valve disease.

Methods

The objects were 108 patients with tricuspid aortic valve calcification over the age of 65 years. Calcification and aortic valve stenosis were verified using transthoracic echocardiography. A comparison group consisted of 58 patients without signs of aortic valve pathology, comparable to the main group by sex, age, clinical features, anamnesis, structure of cardiovascular pathology and drug therapy. Serum concentrations of human intact parathyroid hormone and 25-hydroxy vitamin D were detected by ELISA.

Results

In patients with calcifying aortic valve disease, serum concentrations of parathormone and ionized calcium were significantly lower. The 25OH level of vitamin D was significantly lower in women of the both groups. The correlation analysis has shown no association of parathyroid hormone and 25OH vitamin D with echocardiography and laboratory parameters.

Conclusion

Thus, in patients with cardiovascular pathology, the presence of calcifying aortic valve disease is associated with lower serum concentrations of parathyroid hormone and ionized calcium, which may indicate their pathogenetic role in this disease.

#1253 - Case Report

STRESS CARDIOMYOPATHY

Claudemira Fernanda Pinto, Filipa Silva, Maria Inês Matos, Maria Teresa Brito, Joana Tender Vieira, Mariana Ferreira Almeida, Bruno Besteiro, Jorge Almeida

Centro Hospitalar de São João, Porto, Portugal

Introduction

Stress Cardiomyopathy (CMS) is characterized by transient systolic dysfunction of the left ventricle, and may sometimes mimic an acute myocardial infarction, in the absence of obstructive coronary artery disease.

Case description

We describe a case of an 87-year-old man, who was brought to the emergency department (ED) after a fall, without loss of consciousness, chest pain or palpitations, with right thoracic and temporal trauma. He had been lying down for several hours until was found by a relative. In terms of past medical history he had hypertension, heart failure with preserved ejection fraction, atrial fibrillation and epilepsy. On initial evaluation at ED he complained of chest compressive pain, was conscious, disoriented, blood pressure of 155/99 mmHg, pulse of 71/min, respiration of 16/min and oxygen saturation was 98% in room air. Cardiovascular and pulmonary examination was normal and his abdomen was soft without tenderness. No pain at palpation of the spine. The EKG showed left axis deviation, Q waves in the inferior leads, V1 and V2. The blood tests on admission showed anemia of Hb 10.6 g/dL, thrombocytopenia of 76,000x10⁹/L (already present in 2016), normal C-reactive protein, BNP level of 1088 pg/ml. INR 1.9. Chest X-rays did not show rib fractures, hemo/pneumothorax. Brain CT scan at admission and at 24 h without evidence of intra- or extra-axial traumatic or hemorrhagic lesions. There was an elevation of high sensitivity troponin I up to 758 ng/L. Was evaluated by Cardiology, who performed a transthoracic echocardiography that showed moderate to severe dysfunction of the left ventricular, mid-apical akinesia and vigorous contractility of the basal segments. In view of the typical findings previously described and the stress induced by the fall and, the hypothesis of Takotsubo syndrome was considered and the patient was admitted in the Internal Medicine Department. During the hospitalization, favorable evolution was observed; the patient remained asymptomatic, with hemodynamic stability and progressive reduction of troponin I (maximum value of 758.3 ng /L to 119.3 ng/L at the time of discharge). Repeated EKG revealed evolution with inversion of T waves in the anterior wall. Myocardial perfusion scintigraphy showed a left ventricular perfusion without changes.

Discussion

CMS is a diagnosis of exclusion in patients with suspected ACS, with favorable prognosis. This case is highlighted by its atypical characteristics with absence of cardiovascular symptoms and installation timing.

#1263 - Abstract

VENOUS RECANALIZATION AFTER A THROMBOEMBOLIC EVENT IN A TUNISIAN POPULATION

Mohamed Sami Zrida^{1,2}, Maroua Mrouki^{1,2}, Yosra Cherif^{1,2}, Fatma Ben Dahmen^{1,2}, Meya Abdallah^{1,2}

¹ Tunis El Manar University Faculty of Medicine of Tunis, Tunis, Tunisia

² Regional Hospital Ben Arous, Internal Medicine Department, Ben Arous, Tunisia

Background

The aim of this study was to assess the prevalence of recanalization in control imaging of patients followed for venous thromboembolic disease at the end of treatment with vitamin K antagonists (VKA) and to investigate the factors that may influence it.

Methods

A prospective, longitudinal and descriptive study involving patients with venous thromboembolic disease treated by VKA was conducted in an internal medicine department between January 2015 and December 2017. Control imaging was performed for each patient at the end of the agreed period of anticoagulation. The studied population was subsequently divided into two groups according to the absence or presence of venous recanalization in the control imaging in order to investigate its influencing factors.

Results

Sixty patients were included in this study whose average age was 56 years. Twenty-nine patients were male and 31 were female. Eighty percent (n=53) of patients lived in urban areas and 12% (n=7) lived in rural areas. Fifty (83%) patients had deep vein thrombosis (DVT), 9 (15%) had pulmonary embolism (PE), and one (2%) had superficial thrombophlebitis. Twenty one (35%) were smokers and 19 (32%) were obese. Two patients had a family history of venous thromboembolism (VTE) and 3 had a personal history of VTE. Seventeen percent of the studied population had varicose veins in the lower limbs. High blood pressure was noted in 18 (30%) patients, diabetes in 11 (18%) patients, dyslipidemia in 11 (18%) patients, cardiac pathology in 3 (5%) patients, hypothyroidism in 4 (7%) patients and active cancer in 2 (3%) patients. Twenty-two percent (n=13) of the total patients had recent surgery and 3 (5%) patients had an orthopedic cast. The agreed period of treatment was 6 months in 92% (n=55) of cases, 3 months in 6% (n=4) of cases and 1 month in 2% (n=1) of cases. At the control imaging, 65% (n=39) of the patients had totally recanalized and 33% (n=20) had partially recanalized. A complete absence of recanalization was noted in only one case (2%) after 6 months of treatment with AVK. Among the factors studied, only the urban / rural living environment had a statistically significant effect on venous recanalization.

Conclusion

VTE is a common and multifactorial disease. The determination of the optimal duration of anticoagulation remains a challenge

for clinicians. Control imaging is not common during therapeutic follow-up of VTE cases. However, it may help to optimize the duration of anticoagulation.

#1276 - Case Report

CHAGAS CARDIAC DISEASE, A DISEASE THAT MUST BE KEPT IN MIND

Irene Cortes Verdasca¹, Miguel Ferreira², Pedro Mota³, Nuno Cardim³

¹ Hospital São Francisco Xavier, Lisboa, Portugal

² Hospital Beatriz Angelo, Lisboa, Portugal

³ Hospital da Luz, Lisboa, Portugal

Introduction

The term Chagas disease is used for the general disease caused by *Trypanosoma cruzi*, a protozoan parasite. The disease is a heterogeneous condition with a wide variation in clinical course and prognosis. Although the majority of infected individuals remain asymptomatic throughout life, some develop only conduction defects and mild segmental wall motion abnormalities, others develop severe symptoms of heart failure, thromboembolic phenomena, and lifethreatening ventricular arrhythmias.

Case description

A 34-year-old woman natural from Argentina, living in Portugal for nine years, with history of Chagas' disease acquired by congenital transmission, presented to the outpatient clinic with a 2-week history of palpitations. There were no other symptoms or signs of disease at physical examination. Laboratory evaluation confirmed the diagnosis of Chagas' disease by positive IgG serologic test for *Trypanosoma cruzi*; the remaining laboratory evaluation as cardiac markers, thyroid function, inflammatory parameters were normal. The electrocardiogram, 24-hour Holter monitoring and cardiac event recorder showed no arrhythmia or no relationship between symptoms and changes in heart rate or rhythm. Further cardiovascular assessment by transthoracic echocardiogram documented left ventricle cavity at the upper limit of normal with non-hypertrophied walls, with normal ejection fraction and global longitudinal strain, but with infolateral hypokinesia and decreased regional longitudinal strain in this wall. Cardiac magnetic resonance imaging was performed and it revealed dilated left ventricle with segmental alterations (lower wall and apex) with preserved global systolic function; dilated right ventricle without evident changes in regional kinetics and increased T1 and T2 native to the left ventricle, although there was no late enhancement (possible fibrosis and diffuse inflammation). These findings were suggestive of chronic Chagas' myocardiopathy, an early form (indeterminate phase).

Discussion

Chagas disease is an important cause of heart failure. Assessment of cardiac disease in patients with confirmed infection by protozoan trypanosome *cruzi* is crucial to detect early cardiac

impairment and risk stratification before symptoms develop. Characterization of the indeterminate phase has been challenging and it is imperfect because early manifestations can be subtle.

#1280 - Abstract

UNATTENDED COMPARED TO ATTENDED OFFICE BLOOD PRESSURE AND TO 24-HOUR BLOOD PRESSURE MONITORING IN STABLE HYPERTENSIVE PATIENTS

Jan Filipovsky, Jitka Mlikova Seidlerova, Stepan Mares
Charles University Medical Faculty, Pilsen, Czech Republic

Background

Measurement of unattended automated office blood pressure (uAutoBP) may eliminate white-coat effect. This method was used in the recently published SPRINT study. We studied the relationships of uAutoBP to office blood pressure (OBP) measured by the physician and to 24-hour ambulatory blood pressure monitoring (ABPM).

Methods

Stable treated hypertensive subjects were included in this study which was performed in four Czech hypertension centres. uAutoBP was measured with the BPTru device (six measurements), after uAutoBP, OBP was measured six times in the office: three times with auscultatory method (auscOBP), followed by three oscilometric measurements (oscOBP). 24-hour ABPM was performed within one week from the clinical visit.

Results

Data on 172 subjects aged 63.7 ± 12.4 years with OBP $127.6 \pm 12.1/77.6 \pm 10.0$ mm Hg are reported. uAutoBP was by $8.5 \pm 9.0/3.0 \pm 6.1$ mm Hg lower than auscOBP and by $8.6 \pm 8.6/1.9 \pm 5.7$ mm Hg than oscOBP; these differences were relatively homogeneous in all the centres. The uAutoBP-auscOBP difference increased with the auscOBP level and it did not depend on any other factor (age, number of antihypertensive drugs, presence of diabetes, lipid disorders or kidney disease, interval from the morning drug intake). 24-hour mean BP was by $4.2 \pm 12.1/3.5 \pm 7.8$ mm Hg lower than auscOBP and by $4.3 \pm 11.0/0.5 \pm 6.9$ mm Hg higher than uAutoBP; the correlation coefficients of 24-hour mean BP with OBP and with uAutoBP did not differ (p for difference ≥ 0.13).

Conclusion

Compared to uAutoBP, OBP gives higher values, both when measured with auscultatory or oscillometric method. Contrary to some previous studies, we did not prove that uAutoBP would be associated to ABPM more closely than OBP.

As we have no prognostic data with uAutoBP and the inter-individual variability of the OBP – uAutoBP difference is large, uAutoBP cannot replace classic OBP.

#1290 - Medical Image

THE PHANTOM OF A WELL KNOWN PATHOLOGY

Sara Gomes, Francisco Gomes, Teresinha Ponte, Filomena Carneiro, Fatima Campante

Centro Hospitalar Barreiro Montijo, Barreiro, Portugal

Clinical summary

79-year-old man with history of heart failure presents with dyspnea and worsening limb edema. A posteroanterior chest radiograph showed an enlarged cardiac silhouette and a well-delineated, homogeneous rounded opacity, near the right horizontal fissure. The patient initiated diuretic treatment, with complete resolution of the opacity at discharge. Decompensated heart failure causes bilateral pleural effusion resulting in obliteration of the costophrenic sinus; sometimes there is accumulation in the minor fissure – the so called vanishing, pseudo or phantom tumor. Early recognition of this radiological finding is important to prevent unnecessary diagnostic procedures and therapeutic errors.

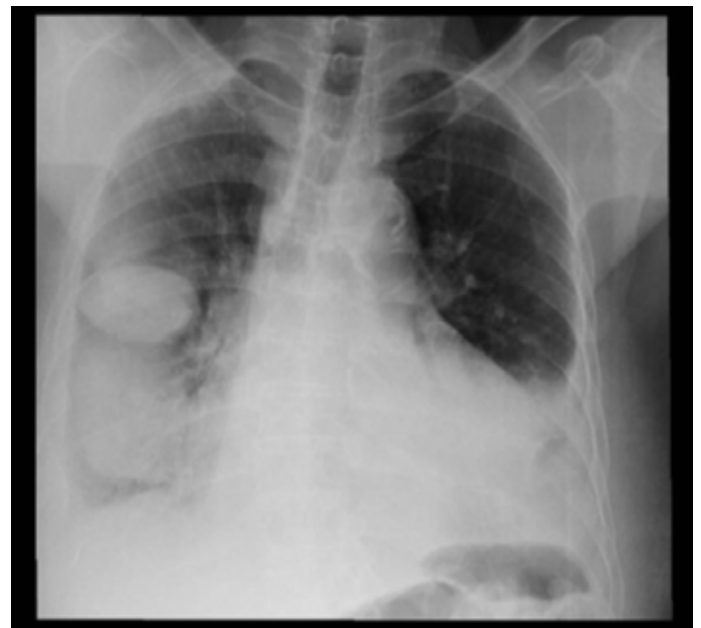

Figure #1290. Posteroanterior chest radiograph.

#1293 - Case Report

THE CURE AND THE CAUSE - ANTHRACYCLINE-INDUCED CARDIOTOXICITY, A CASE REPORT

Sara Gomes, Catarina Medeiros, Maria Loureiro, Otilia Simoes, Filipa Ferreira

Hospital Garcia de Orta, Almada, Portugal

Introduction

Anthracyclines are a very effective anticancer therapy with promising results, specially when administered in higher dosages. Unfortunately they are also associated with an increased risk of

heart failure (HF) leading to significant morbidity and mortality, which in light of the growing life expectancy of cancer patients might become an issue on the long term.

Case description

A 52 year-old woman presented in the emergency department complaining of shortness of breath and palpitations for 3 days. Two years before she was diagnosed with breast cancer, treated with neoadjuvant chemotherapy with doxorubicin, cyclophosphamide and paclitaxel, adjuvant radiotherapy and total left mastectomy. She denied previous history of chest pain, HF or other cardiovascular symptoms, and echocardiograms prior and after chemotherapy were unremarkable. At presentation the high sensitive T Troponin was 714 ng/L (rising to 2860 ng/L), the EKG showed left bundle branch block morphology (previously known) and the echocardiogram revealed a dilated left ventricle with global hypokinesia leading to a severely reduced ejection fraction. Acute coronary syndrome decompensating a previously unknown HF was the presumptive diagnosis.

The coronarography showed a large thrombus occluding the distal segment of the right coronary artery, which was treated with mechanical aspiration and anticoagulation. Cardiac MRI confirmed severely depressed left ventricle ejection fraction with exuberant apical hyper trabeculation, suspicious of a cardioembolic etiology for the infarction; there was no late gadolinium enhancement suggesting infarction scar. After diuretic and vasodilator therapy during hospital admission, the patient was asymptomatic at discharge.

Discussion

The decision to use anthracyclines is based on the baseline cardiac function. The toxicity of doxorubicin is related to its cumulative dose and is usually evident within 30 days of administration of the last dose, but it may occur 6 to 10 years after administration. Combination with other drugs, radiotherapy, preexisting cardiac diseases or other risk factors contribute to the severity of anthracycline induced cardiomyopathy. In this particular patient, she presented acutely in the ER with a complication of its previously undiagnosed cardiomyopathy. This case enlightens the crucial role of regular assessment to allow early detection of cardiac involvement and implementation of therapeutic measures.

#1297 - Abstract

RISK FACTORS FOR LONG-TERM MORTALITY IN PATIENTS WITH VERIFIED PULMONARY EMBOLISM OF HIGH AND INTERMEDIATE RISK

Valentin A. Kokorin¹, Elena A. Kochmareva^{1,2}, Vladimir A. Khlebnikov¹, Vladimir Yu. Titov¹, Varvara P. Rymberg¹, Valentin V. Malimon¹, Ivan G. Gordeev¹

¹ Pirogov Russian National research medical university, Moscow, Russia

² City Clinical Hospital #15 named after O.M. Filatov, Moscow, Russia

Background

Pulmonary embolism (PE) is a fearsome state with high incidence and mortality rate. Risk factors (RF) and scales in patients with acute PE are currently actively studied in terms of a short-term prognosis. However, in the long-term RF for negative outcomes are less examined.

We aimed to identify the risk factors for long-term mortality in patients with verified PE.

Methods

150 patients with PE of intermediate and high risk of lethal outcome were enrolled. PE was verified by computed tomographic pulmonary angiography and/or Echo. To assess further outcomes, the patients were contacted by phoned 36 months after discharge from the hospital. Contact was lost with 42 patients, so the final analysis included data from 118 patients aged from 25 to 92 years (mean age 66 years), of which 73 women (61.9%) and 45 men (38.1%). The patients were divided into the groups of favorable and unfavorable course of the disease. The IBM SPSS Statistics, version 23 program was used for statistical analysis.

Results

All-cause mortality rate at 36 months was 56 of 118 (47%). The following factors were associated with the fatal outcome: positive test for heart-type fatty acid binding protein (H-FABP) at admission (30,0% vs 39,7%, $p < 0,05$, OR 3,54, CI 95% 1,6-7,7), age >70 years (38,1% vs 58,2%, $p < 0,05$, OR 2,3 CI 95% 1,1-4,7), systolic blood pressure (SBP) <100 mmHg (41,9% and 68,0%, $p < 0,05$, OR 2,9 CI 95% 1,1-7,5), SpO₂ <90% (39,5% and 64,9%, $p < 0,05$, OR 2,8 CI 95% 1,3-6,3), history of atrial fibrillation (AF) (40,7% and 70,4, $p < 0,05$, OR 3,4 CI 95% 1,3-8,7), syncopal episodes at presentation (38,7% vs 62,8%, $p < 0,05$, OR 2,6 CI 95% 1,2-5,8), BOVA score ≥ 3 points (36,0% vs 55,9%, $p < 0,05$, OR 2,2 CI 95% 1,06-4,76), simplified PESI scale >2 points (22,9% vs 57,8%, $p < 0,05$, OR 4,6 CI 95% 1,8-11,4), creatinine clearance (Cr Cl) <60 ml/min (38,3% vs 56,9%, $p < 0,05$, OR 2,1 CI 95% 1,01-4,43), left ventricle ejection fraction (LVEF) <50% (40,8% vs 80,0%, $p < 0,05$, OR 5,8 CI 95% 1,8-18,6).

Conclusion

Thus, the following RF were associated with long-term mortality in patients with PE of high and intermediate risk: positive test for H-FABP at admission, age >70 years, SBP <100 mmHg, history of AF, syncopal episodes, BOVA score ≥ 3 points, sPESI scale >2 points, Cr Cl <60 ml/min and LVEF <50%.

#1299 - Case Report

MASSIVE ASCITES AND RECURRENT PLEURAL EFFUSION, THERAPEUTIC AND DIAGNOSTIC CHALLENGE

Shkelqim Muharremi¹, Emilija Nikolovska², Dafina Janevska², Ance Volkanovska², Ana Karadzova², Filonid Aliu³, Biljana Ivanovska Bojadziev⁴, Kire Shuperliski⁵, Aleksandar Manolev⁶, Viktorija Caloska Ivanova²

¹ Institute of Nephrology, Struga, Macedonia, Former Yugoslav Republic of

² University Clinic of Gastroenterohepatology, Skopje, Macedonia, Former Yugoslav Republic of

³ University Clinic of Cardiology, Skopje, Macedonia, Former Yugoslav Republic of

⁴ PHO Dr.Biljana Ivanovska Bojadziev, Skopje, Macedonia, Former Yugoslav Republic of

⁵ PHO Dr.Shuperliski, Kocani, Macedonia, Former Yugoslav Republic of

⁶ PHO Polyclinic Manolev, Skopje, Macedonia, Former Yugoslav Republic of

Introduction

Massive ascites and recurrent pleural effusion of unknown origin is an uncommon condition, which represent a diagnostic and therapeutic challenge. Patient with delayed diagnosis and treatment may have a poor prognosis.

Case description

A 34-years-old male was referred to our department due to 12-months progressive abdominal distention with massive ascites and pleural effusion of unknown origin.

By thorough investigations, he was diagnosed as chronic calcified constrictive pericarditis. He received pericardiectomy and had an uneventful postoperative course.

He was doing well at 3-month follow-up and has returned to work.

Discussion

Extracardiac manifestations, such as massive ascites, recurrent pleural effusion and liver cirrhosis, were rare in patient with constrictive pericarditis. Pericardiectomy can be a radical solution for the treatment of chronic constrictive pericarditis. In order to avoid delayed diagnosis and treatment, physicians have to bear in mind this rare manifestation of chronic calcified constrictive pericarditis.

#1312 - Case Report

COULD ATRIAL FIBRILLATION LEAD TO HEMICOLECTOMY? A CASE REPORT

Deborah Blanca, Ludovico Furlan, Olivia Milani, Nicola Montano, Eleonora Tobaldini

Department of Internal Medicine, Fondazione IRCSS Ca' Granda, Ospedale Maggiore Policlinico and Department of Clinical Sciences and Community Health, University of Milan, Milan, Italy

Introduction

Atrial fibrillation (AF) is the most common cardiac arrhythmia worldwide.

Physicians should consider the thrombotic and haemorrhagic risk before starting anticoagulant therapy.

Case description

A 75-year-old man presented to emergency department with haematochezia; esophagogastroduodenoscopy was negative for acute bleeding. The patient had a history of kidney failure in previous transplant and permanent AF, despite ablation, so he started anticoagulant therapy. Four months before hospital admission, he had acute anaemia due to gastric ulcer. Three months later, he underwent auricula closure using WATCHMAN device; anticoagulant therapy was discontinued and a dual antiplatelet therapy (clopidogrel + aspirin) was started.

When he was admitted to our department, antiplatelet therapy was discontinued. We performed colonoscopy, that showed colic blood oozing and haemostatic clips were positioned. After the recurrence of bleeding, colonoscopy was repeated; the procedure was complicated by iatrogenic gut perforation. An urgent abdominal cavity surgical toilet was therefore performed for a faecal peritonitis; surgeons crafted sigma terminal colostomy. In postoperative intensive care unit, calcium heparin for prophylaxis and aspirin were prescribed. After surgery, patient had a new episode of bleeding from colostomy; endoscopy was performed and two clips were placed for active bleeding.

Later, he was transferred to our internal medicine department for ventilator-associated pneumonia. Patient was discharged with single antiplatelet therapy after 28 days of hospitalization. Three days after discharge, the patient came back for recurrence of pneumonia and C.difficile enterocolitis.

Discussion

The patient had a CHA2DS2-VASc risk stratification score equal to 2 (only for age) with an annual stroke risk of 2.2%. He had a high risk of bleeding due to age, anticoagulant, kidney failure and recurrent gastrointestinal bleeding. The patient underwent the placement of WATCHMAN device, a procedure that requires anticoagulant and then dual anti-platelet therapy for several months, despite the higher bleeding risk. Any treatment should be tailored on patients, taking into account risks and benefits.

#1315 - Abstract

CARDIAC AUTONOMIC DERANGEMENT IS ASSOCIATED WITH WORSE NEUROLOGICAL OUTCOME IN THE VERY EARLY PHASES OF ISCHEMIC STROKE

Alice Monti¹, Roberto Maria Sacco², Serena Serafino², Michele Tassi², Gianluca Gallone², Giuseppe Torgano², Eleonora Tobaldini¹, Nicola Montano¹

¹ Department of Internal Medicine, Fondazione IRCSS Ca' Granda, Ospedale Maggiore Policlinico, and Department of Clinical Sciences and Community Health, University of Milan, Milan, Italy

² Department of Emergency Medicine, Fondazione IRCSS Ca' Granda, Ospedale Maggiore Policlinico, Milan, Italy

Background

Acute ischemic stroke (AIS) is associated with autonomic dysfunction whose prognostic role is debated. The aim of this study is to evaluate the prognostic value of heart rate variability (HRV) and the role of stroke localization on autonomic control.

Methods

Patients with AIS and sinus rhythm were enrolled in the Emergency Department (Ospedale Maggiore Policlinico, Milan). Autonomic parameters were recorded at the onset (T0) and after thrombolysis. Neurological deficit was assessed at the onset using NIH Stroke Scale (NIHSS); residual disability was rated at 3 months with modified Rankin Scale (mRS). Spectral and symbolic analyses were used to assess HRV. Low frequency and high frequency are respectively markers of sympathetic and vagal modulation in spectral analysis. Symbolic analysis provides 0V% as index of sympathetic modulation and 2LV% and 2UV% as markers of vagal modulation.

Results

We enrolled 41 patients (mean age 68.0 ± 12.8 ; mean NIHSS 9.8 ± 6.4). A prevalent parasympathetic modulation was found in patients with NIHSS ≥ 14 compared to those with NIHSS < 14 . The group with worse mid-term outcome (mRS 3-6) showed higher 2UV% and lower 0V% than patients with lower disability (mRS 0-2). Right-sided stroke showed an association with higher respiratory vagal control.

Conclusion

Patients with a major neurologic impairment in the acute phase of ischemic stroke have an autonomic profile characterized by a prevalent vagal modulation. Considering mid-term outcome, patients with minor functional independence showed a prevalent vagal modulation along with a loss of sympathetic rhythmic oscillation. This autonomic profile may reflect a greater cardiovascular risk in this group of patients.

#1321 - Abstract

COMBINED DIURETIC THERAPY IN A COHORT OF OUTPATIENTS WITH HEART FAILURE: EXPERIENCE OF A CONTINUITY OF CARE UNIT

Cristina Sánchez Sánchez, Miguel Pedromingo Kus, Maria Escamilla Espinola, Juan Igor Molina Puente, Rebeca Sanchez Gonzalez, Ana Cristina Antolí Royo, Victoria Hernández Jiménez, Dolores Lopez Fernandez, Demetrio Sánchez Fuentes
Complejo Asistencial de Ávila, Ávila, Spain

Background

Congestion is the most frequent clinical feature in heart failure (HF), and a main cause of hospital admission. For this reason, diuretics are widely recommended in this population. Once diuretic resistance develops, different therapeutic strategies may be adopted, including combined diuretic therapy (CDT).

Methods

Retrospective observational study of outpatients with HF followed by the Continuity of Care Unit (CCU) in Avila, Spain, from October 2016 through March 2019. Percentage of patients with CDT, diuretics employed, hospital admissions and death rate were analysed.

Results

223 patients with HF were included. 51.6% of them were female. Mean age was 83.69 (SD 7.9). Most patients (78.5%) had a preserved left ventricular function. 81.2% were under combined diuretic therapy (CDT): from them, a 42.6% were treated with a two diuretic combination strategy, 31.8% with three and 6.7% with four. 43.6% had renal failure and the majority (60.1%) presented with a NYHA class II HF. Diuretics most commonly used were as follows: furosemide (98.3%), potassium-sparing diuretics (spironolactone or eplerenone) (85%) and thiazide diuretics (hydrochlorothiazide or chlorthalidone) (54.1%). On the contrary, acetazolamide and SGLT2 inhibitors were only used in 11.6% and 6.6% of the cases, respectively. The admission rate was similar in both groups of patients (CDT vs one-no diuretic use): 41.7% vs 42.9%, respectively. The death rate was slightly higher in the CDT group (23.8% Vs 16.7%).

Conclusion

In our observational study, the majority of patients with HF were treated with CDT. In accordance with previous studies, the predominant diuretic used was furosemide, followed by a combination with aldosterone antagonists and/or thiazides. Although not significant, a higher death rate trend was observed amongst patients with CDT, and a similar admission rate in both groups of patients (combined/non-combined) was noted. However, larger sample size studies, with detailed multivariate analysis, should be performed to confirm these data.

#1325 - Abstract

OUT-OF-HOSPITAL CARDIAC ARRESTS IN A LARGE METROPOLITAN AREA: SYNERGISTIC EFFECT OF EXPOSURE TO AIR PARTICULATES AND HIGH TEMPERATURE

Elisa Marsala^{1,2}, Eleonora Tobaldini^{1,2}, Simona Iodice¹, Rodolfo Bonora³, Matteo Bonzini^{1,4}, Annamaria Brambilla⁵, Giovanni Sesana³, Valentina Bollati^{1,4}, Nicola Montano^{1,2}

¹ Department of Clinical Sciences and Community Health, University of Milan, Milan, Italy

² Department of Internal Medicine, Fondazione IRCSS Ca' Granda, Ospedale Maggiore Policlinico, Milan, Italy

³ ASST Grande Ospedale Metropolitano Niguarda, Milan, Italy

⁴ Department of Preventive Medicine, Fondazione IRCSS Ca' Granda, Ospedale Maggiore Policlinico, Milan, Italy

⁵ Emergency Care Unit, Fondazione IRCSS Ca' Granda, Ospedale Maggiore Policlinico, Milan, Italy

Background

Air pollution and climate change are intrinsically linked emerging hazards for global health. High air particulate matter (PM) levels may trigger out-of-hospital cardiac arrest (OHCA). High temperature could act synergistically with PM in determining OHCA.

The aim of the present study was to investigate the combined effect of PM exposure and temperature on the number of ambulance call-outs for cardiac arrest in a large European metropolitan area with population >4 million.

Methods

We evaluated the association between ambient pollution exposure, temperature, and the rate of OHCA on a 2-years study period, allowing us to investigate 5761 event by using a Poisson model for count data with lag distributed term. Results were further confirmed by bidirectional case-crossover analysis. OHCA diagnosis, defined as sudden cessation of cardiac mechanical activity in the absence of any traumatic cause of cardiac arrest, was based on the call to the dispatch center and confirmed by the ambulance crew based on the results of clinical assessment.

Results

We observed a joint effect of PM and temperature in triggering cardiac arrest. The maximum effect was observed for high levels of PM experienced 3 days before the cardiac event, in the presence of high temperature.

Conclusion

The present study helps to clarify the controversial role of PM as OHCA determinant. It also highlights the role of increased temperature as a key factor in triggering cardiac events. This evidence suggests that tackling both air pollution and climate change might have relevant impact in terms of public health.

#1330 - Abstract

CARDIAC AUTONOMIC CONTROL IN PATIENTS WITH END-STAGE LUNG DISEASE

Giulia Coti Zelati¹, Gabriel Dias Rodrigues², Giorgio Mantoan¹, Alice Monti¹, Camilla Cirelli¹, Paolo Tarsia³, Valeria Rossetti³, Letizia Corinna Morlacchi³, Ilaria Righi⁴, Francesco Blasi³, Stefano Aliberti³, Nicola Montano¹, Eleonora Tobaldini¹

¹ Internal Medicine, Fondazione IRCCS Cà Granda, Ospedale Maggiore Policlinico, Milan, Italy and Department of Clinical Sciences and Community Health, University of Milan, Milan, Italy

² Physiology and Pharmacology, Biomedical Institute, Fluminense Federal University, Niterói, Brazil

³ Respiratory Unit and Cystic Fibrosis Adult Center, Fondazione IRCCS Cà Granda Ospedale Maggiore Policlinico, Department of Pathophysiology and Transplantation, University of Milan, Milan, Italy

⁴ Thoracic Surgery and Lung Transplantation Unit, Fondazione IRCCS Cà Granda Ospedale Maggiore Policlinico, Milan, Italy

Background

Cardiac autonomic control (CAC) is impaired in chronic obstructive, restrictive and mixed pulmonary diseases. However, the interplay between CAC and severity of end-stage lung has not been studied yet. Analysis of heart rate variability (HRV) is a noninvasive tool to study CAC. Our aim is to investigate the effects of lung disease severity on CAC.

Methods

49 patients on the waiting list of lung transplantation (Tx; 19 men and 30 women, age 38±15 years old) and 49 healthy non-smoking controls (HC; 22 men and 27 women, age 40±16 years old) were enrolled in this case-control study. Tx were divided into two groups, according to disease severity evaluated by the Lung Allocation Score (LAS). Ten minutes ECG and respiration were recorded. Spectral analysis identified low frequency (LF, sympathetic) and high frequency (HF, vagal) patterns. Symbolic analysis identified three patterns, 0V% (sympathetic), 2UV% and 2LV% (vagal). For comparisons Mean-Whitney U test was used. Data are presented as median and interquartile range.

Results

Compared to HCs, Tx patients had higher markers of sympathetic modulation and lower markers of vagal modulation. Patients with higher LAS had lower levels of sympathetic and higher levels of vagal modulation compared to less severe patients.

Conclusion

According to these preliminary data, compared to HCs Tx patients have higher markers of sympathetic modulation and lower markers of vagal modulation.

Nevertheless, more critical patients seem to have an autonomic profile characterized by lower sympathetic and predominant vagal modulation. This pattern can be due to a loss of sympathetic rhythmic oscillation and a subsequent prevalent respiratory modulation of heart rate in patients with a more severe disease.

#1364 - Case Report

BILATERAL DEEP VEIN THROMBOSIS WITH FACTOR V LEIDEN DEFICIENCY: A CASE REPORT

Noemi Iakab¹, Noemi Katalin Sidlovszky, Adriana Habor^{1,2}

¹ Emergency Country Hospital, Targu Mures, Romania

² University of Medicine and Pharmacy, Targu Mures, Romania

Introduction

The genetic mutations involved in hereditary thrombophilias represent life-long prothrombotic risk factors, which require long term anticoagulant or antiplatelet therapy.

Case description

We present the case of a 29-year-old male patient, who underwent eye surgery due to traumatic injury on his right eye.

Anterior vitrectomy was performed followed by a period of 2 week immobilization, without thromboprophylaxis. The patient presented to the emergency department shortly after discharge, feverish and with progressive pain and swelling on his right calf. Routine laboratory examinations show positive d-dimer, CRP, mild leucocytosis and slightly elevated liver enzymes. Venous ultrasound described subacute total occlusion of the distal portion of the right femoral vein, and bilaterally on the popliteal veins. Pulmonary angio-CT was performed to exclude any thromboembolic event. Abdominal ultrasound and CT revealed liver steatosis; antiphospholipid antibody testing was negative, thrombophilia panel showed Factor V G1691A Leiden deficiency. Initially Enoxaparin therapy was instated, followed by oral acenocumarol, with close INR monitoring.

Discussion

Prolonged immobilization and Factor V Leiden deficit represent the risk factors for developing deep vein thrombosis in this particular patient's case, who was diagnosed with hereditary thrombophilia.

#1386 - Abstract

ABDOMINAL AORTIC ANEURYSMS AND SECONDARY PREVENTION: ARE WE DOING A GOOD JOB?

Cristina Limia Vita¹, Lucía Paz Fajardo¹, Marta Carmen Esles Bolado¹, Andrea González Pascual¹, Ofelia Casanueva Soler²

¹ Internal Medicine Service. Hospital Sierrallana., Torrelavega, Spain

² Family and community medicine service. Hospital Sierrallana., Torrelavega, Spain

Background

Patients with abdominal aortic aneurysm should be considered candidates to secondary prevention and, therefore, be of benefit of statin therapy. Numerous studies support the use of statins as treatment for aortic aneurysm, establishing a relationship between statin treatment and reduction of complications.

Our aim was to evaluate the proportion of patients with a diagnosis of abdominal aortic aneurysm in which treatment with statins was established as secondary prevention tool.

Methods

We collected data of every patient who has been diagnosed by an image tool of abdominal aortic aneurysm in Hospital Sierrallana, where a population of 165,000 are covered and have place for 260 patients, in 2018 and we have compared information among patients who were already taken statins, those that started statin treatment after the diagnose and those who never received statins before nor after.

Results

22 patients have been included. 22.73% were women, 77.27% men, with an average age of 75.73 years.

We considered several cardiovascular risk factors: smoking habit (59.59% were smokers), hypertension (72.72%), Mellitus diabetes type 2 (22.72%) and dyslipemia (72.72%)

We gathered data about the aneurysm size resulting an average size of 5.1 cm. The smallest one measured 2.8 cm and the biggest one 8.2 cm.

Patients who were receiving statin treatment before being diagnosed of aneurysm, 54.54%, carried on with it afterwards.

Between those who previously weren't taken statins (45.45%), only 50% started treatment after been diagnosed, meanwhile statins weren't administrated to the rest of the group.

Related to patients who were already on statins and kept going on it afterwards (54.54%), 66.6% didn't present aneurysm growth, rupture or demise (almost during 2018). 25% experienced growth of the aneurysm and 16.6% rupture of it.

Conclusion

Hence, despite the fact that our sample of patients is small because of our hospital characteristics, we can conclude that; even though statin therapy reduces aneurysm complications, sometimes professionals don't care about that and they don't begin this treatment after the aneurism diagnosis like secondary prevention. So, it seems reasonable to advise starting statin therapy in the presence of aortic aneurism in patients who weren't already under it.

#1397 - Medical Image

FROM THE ACUTE CORONARY SYNDROME TO A PAST OF SYPHILIS

Ana Corte Real¹, Pedro Brás², Vera Ferreira², Sílvia Aguiar², Lurdes Ferreira², António Fiarresga², Rui Ferreira²

¹ Centro Hospitalar do Oeste - Hosp. de Caldas da Rainha, Caldas Da Rainha, Portugal

² Centro Hospitalar Lisboa Central - Hosp. de Santa Marta, Lisboa, Portugal

Clinical summary

70 year-old male, with well controlled dyslipidemia and type 2 diabetes, allergic to aspirin and on pre-exposure prophylaxis (HIV), presented with a sudden and persistent chest pain, after an autolimited episode in the previous day. EKG showed inferior ST-segment elevation myocardial infarction. He took triflusal and ticagrelor loading dose. Invasive coronary angiography documented 2 right coronary culprit lesions, both were treated with drug eluting stents. Aneurysmatic segments were also noted in the left anterior descending and proximal circumflex artery. Transthoracic echocardiogram revealed inferior hypokinesia, aortic root (41 mm) and proximal ascending aorta (37 mm) dilation. Syphilis serology demonstrated previous infection, that the patient confirmed properly treated 15 years before.

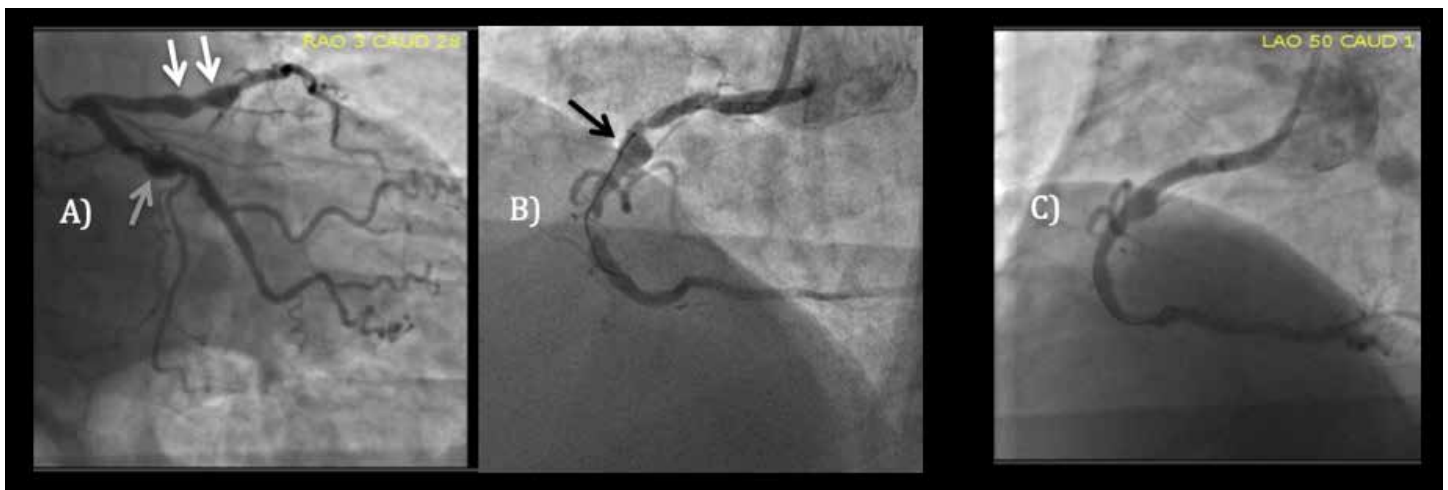


Figure #1397. Invasive coronary angiography showing: A) 50-60% lesion between two aneurysmatic segments in the left anterior descending artery (white arrows), as well as proximal circumflex artery aneurysm (grey arrow); B) culprit lesions in the proximal (80%) and mid segment (99%) of the right coronary artery, note the aneurysmatic segment between the two lesion (black arrow). C) Angiographic final result.

#1399 - Abstract

ATRIAL FIBRILLATION AND SEPSIS - A CALL TO ADDRESS ANTICOAGULATION

Mário Bibi, Alda Tavares, Sara Moreira Pinto, Rute Ferreira, Cristina Rosário

ULSM, Porto, Portugal

Background

Atrial fibrillation (AF) episodes are frequent among septic patients (24%) and its prevalence increases with the severity of the infection (40% in septic shock patients). In spite of that, the AF European guidelines do not mention the septic patient. In a predispose heart, sepsis can elicit AF by inducing a considerable stress response.

A recent study detected a great variability in the decision to initiate anticoagulation during the septic episode among different hospitals and even in the same wards. Nowadays, there are no recommendations for anticoagulation after the septic episode.

Methods

A retrospective study was conducted among patients admitted in an Internal Medicine Ward, between April of 2014 and June of 2015 with diagnosis of AF. Epidemiological, clinical and analytical data was collected and analysed. The objective was to compare AF management in patients with and without sepsis. Statistical analysis was performed with SPSS software v25; values of $p < 0,05$ were considered statistically significant.

Results

A total of 236 admissions and 214 patients were examined. The median age was 77 years and 66% of patients were women. Twenty-seven individuals also had a diagnosis of sepsis. There were more inaugural AF diagnoses in patients with sepsis than without (51.9% vs. 39.2%, respectively; $p=0.209$). The patients with sepsis were less frequently anticoagulated (36.4%), than subgroup

without sepsis (66.8%), with significance difference ($p=0.005$). No statistical significance was found when compared the mortality and readmission rates among septic and non-septic patients.

Conclusion

Our data suggests a different AF care in septic patients, as septic patients were less anticoagulated at discharge. In spite of the apparent lack of impact in the mortality and readmissions rates, we did not study the stroke occurrence nor the anticoagulation initiation after discharge.

There is a growing need to address the AF management in the septic patient. Until then, it can persist some confusion among practitioners and false believes of self-limited AF.

#1406 - Case Report

FROM THE MOUTH TO THE HEART AND BRAIN

Maria João Palavras, Flávia Santos, Ana Albuquerque, Rita Carvalho, Filipa Alçada

Hospital de Santo André, Leiria, Portugal

Introduction

In Portugal, stroke is the leading cause of death. Across the world, it is estimated that 1 in every 6 people will have a stroke, one person suffers a stroke each second and a person dies of stroke every 6 seconds. An ischaemic phenomenon is the most common. Ischaemic strokes are frequently distinguished as thrombotic, embolic or lacunar.

Endocarditis is an important, although less common, cause of cerebral embolism. Patients who develop native or prosthetic valve infective endocarditis have an elevated risk of stroke and consequently have a significant mortality and morbidity rates, especially due to the frequent concomitant multiple sites of brain embolization.

Case description

The authors present a case of a 77 year-old male who was admitted by right hemiparesis and fever (38°C). He had a history of hypertension and dyslipidemia. A CT-scan revealed recent right temporoparietal and left frontal ischemic lesions. Atrial fibrillation was diagnosed by electrocardiogram. The transthoracic echocardiogram revealed a moving mass close to the mitral valve, which induced severe mitral regurgitation. Sequential blood cultures isolated multiple colonies of *Peptococcus* spp.. Penicillin and gentamicin were started and the patient was admitted to a cardiac intensive care unit.

Discussion

The *Peptococcus* spp. is very rarely described as the cause of infective endocarditis, and endocarditis itself is a rare cause for stroke. The treatment for this particular patient involved a multidisciplinary approach, including cardiac surgery to the severely damaged valve and extraction of multiple damaged teeth. It is also unclear whether a preexisting rheumatic heart disease may have contributed to valve damage, which brings some discussion on anticoagulant options.

#1408 - Abstract

RATES OF AND RISK FACTORS FOR CORONARY REVASCUARIZATION IN PATIENTS WITH SUSPECTED UNSTABLE ANGINA AND NORMAL HIGH-SENSITIVITY TROPONIN

Shahar Geva Robinson¹, Tali Shafat^{1,2}, Avi Shimony³, Doron Zahger³, Khen Moscovici⁴, Roni Gilis⁴, Carlos Kafri³, Victor Novack^{1,2}, Lior Fuchs¹

¹ Internal Medicine Division, Soroka University Medical Center, Faculty of Health Sciences, Ben-Gurion University of the Negev, Beer Sheva, Israel

² Clinical Research Center, Soroka University Medical Center, Beer Sheva, Israel

³ Department of Cardiology, Soroka University Medical Center, Faculty of Health Sciences, Ben-Gurion University of the Negev, Beer Sheva, Israel

⁴ Goldman Medical School, Faculty of Health Sciences, Ben-Gurion University of the Negev, Beer Sheva, Israel

Background

In this study, we sought to assess the rates of and define predictors for coronary intervention among patients with acute coronary syndrome (ACS) and normal high-sensitivity cardiac troponin (hs-cTn).

Methods

Data were collected from patients hospitalized with suspected UA and exhibiting normal hs-cTn (troponin T, Normal < 14 ng/L) who underwent diagnostic angiography between the years 2010-2017 in Soroka University Medical Center, a 1100 bed tertiary hospital. Follow-up data were collected up to 1 year after the index hospitalization.

Results

Out of 356 patients who met the inclusion criteria, 181 underwent revascularization (50.8%). Using multivariable analysis, dyslipidemia was found to have the highest association with the performance of coronary intervention (OR 4.54 95% CI 2.46-8.40 p<0.001). The other risk factors included smoking (OR 2.53 95% CI 1.47-4.34 p=0.001), family history of CAD (OR 2.36 95% CI 1.15-4.87 p = 0.02), DM (OR 2.11 95% CI 1.28-3.48 p=0.004), age>65 (OR 1.84 95% CI 1.06-3.19 p =0.029) and previously known ischemic heart disease (OR 1.67 1.03-2.70 p=0.037). After 1-year follow-up, the group of patients who underwent revascularization had a greater rate of clinically-indicated repeated angiographies (13.8% vs 4.0% p=0.001), however, there was no significant difference in revascularization events (4.4% vs 2.3% p=0.27) and there was no cardiovascular-related mortality in either group. The composite outcome of all-cause mortality, repeated revascularization or non-fatal MI (MACE) was higher in the intervention group (10.5% vs 2.9% p=0.004)

Conclusion

In the present study, half of the patients hospitalized due to suspected ACS with normal hs-cTn, who were assessed by angiography, underwent revascularization. After 1-year, cardiac mortality remained the same, repeated coronary angiography rates were significantly higher among the revascularization group, but repeated revascularization rates were not higher. To corroborate the utility of revascularization for these patients, more studies are needed.

#1420 - Medical Image

ASYMPTOMATIC TYPE A CHRONIC AORTIC DISSECTION

Emanuel Ferreira Costa, Daniela Dantas Rodrigues, Margarida Robalo, Joana Sotto Mayor, Filipa Costeira, Pedro Cerdeira Ribeiro, Sofia Esperança, António Oliveira Silva
Hospital de Braga, Braga, Portugal

Clinical summary

Computed tomography images were obtained to study neoplastic cause as etiology of left pleural effusion after cytological analysis of pleural fluid revealed the presence of basophilic cells, with nucleus cytoplasm ratio increased in an 88-year-old female patient otherwise asymptomatic except for complaints of fever, productive cough, and dyspnea who was admitted for treatment of a respiratory infection. The images show an extensive thoracic and abdominal aorta dissection from the ascending aorta root to the origin of the renal arteries, with a continuous double lumen image and aneurysmal dilatation of the aortic root, with a caliper of 5.3 cm. After 5 months of follow-up for a chronic type A aortic dissection, the patient remains asymptomatic with medical therapy.

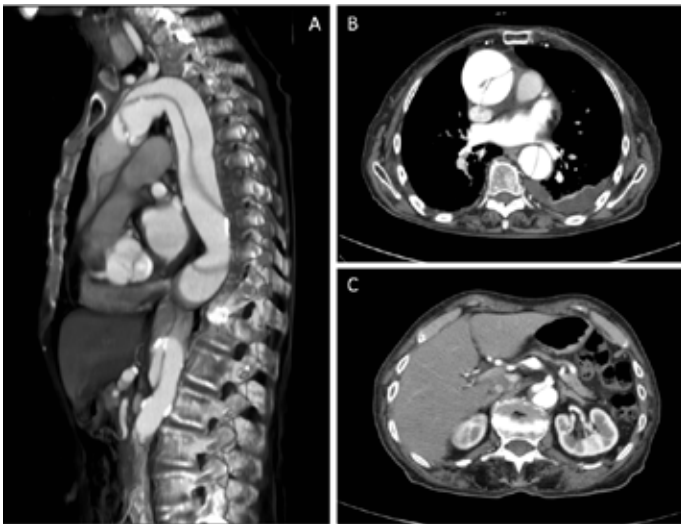


Figure #1420. A- 3D reconstruction image of CT-scan in the sagittal plane showing the extent of aortic dissection with continuous double lumen imaging. B- CT-scan image in the transverse plane showing aneurysmatic dilatation in the ascending aortic root. C- CT-scan image in the transverse plane showing the terminal portion of the false lumen.

#1424 - Abstract

PROGNOSTIC VALUE OF MEAN BILATERAL PROXIMAL EXTENSION OF THE CLOT IN PULMONARY EMBOLISM IN SINGLE CENTRE

Valdis Gibietis, Dana Kigitovica, Sintija Strautmane, Kitija Meilande, Verners Roberts Kalejs, Anastasija Zaichenko, Kristine Make, Andris Skride
Riga Stradins University, Riga, Latvia

Background

Ghanima et al. have proposed mean bilateral proximal extension of the clot (MBPEC) as a radiological score for risk stratification of acute pulmonary embolism (APE) patients. Higher MBPEC score has been associated with increased severity of APE. The aim of this study was to assess the validity of this score in a larger patient cohort.

Methods

The prospective cohort study included consecutive patients in a single centre from June 2014 till April 2019 presenting with APE confirmed by CT pulmonary angiography. Patients were followed up for one year. MBPEC score (1-4) was expressed by calculating the mean value of the largest affected pulmonary artery (subsegmental=1, segmental=2, lobar=3, main=4) in each lung and rounding up to a whole number. Clinical characteristics, treatment modalities and outcomes were assessed in association with MBPEC score.

Results

The study included 392 patients, MBPEC score was 1 in 18.1% (n=71), 2 in 28.8% (n=113), 3 in 20.4% (n=80), and 4 in 32.7% (n=128). Mean heart rate, systolic blood pressure, and pulmonary

embolism severity index (PESI) value did not show any significant association with MBPEC score ($p>0.05$). Higher MBPEC score was significantly associated with elevated Troponin I value (abnormal in 40% of patients with MBPEC=1; 48.8% with 2; 61.7% with 3; 75.8% with 4, $p<0.001$) and higher mean D-dimer value (12.0, 11.8, 14.0 and 17.0 mg/L, respectively, $p<0.001$). Mean B-type natriuretic peptide and serum creatinine were not associated with MBPEC. Thrombolysis was performed in 6 (4.7%) patients with MBPEC=4, no patients with MBPEC=1, one patient with MBPEC=2 and one with MBPEC=3 ($p=0.009$). 30-day mortality was not significantly different between MBPEC score grades ($p=0.798$). 1-year mortality, after exclusion of patients who died in 30 days, was significantly associated with MBPEC score (mortality 8.8%, 37.3%, 25.0%, 11.1%, respectively) with the highest mortality in MBPEC=2 group. Duration of anticoagulation therapy (above or below 6 months) was not associated with MBPEC ($p=0.127$).

Conclusion

Higher MBPEC score was associated with thrombolysis, elevated Troponin I, and higher D-dimer level. The highest long-term mortality was demonstrated in patients with MBPEC=2. PESI score and short-term (30-day) mortality was not associated with MBPEC. In our patient cohort, MBPEC score did not demonstrate convincing accuracy for risk stratification in APE. Further studies are required to assess its potential.

#1428 - Case Report

"FULMINANT" ENDOCARDITIS

Luis Gonçalves Vicente, Carlos Candeias, Ana Baptista, Mario Lazaro

Centro Hospitalar Universitário do Algarve - Faro, Faro, Portugal

Introduction

Endocarditis (IE) is a rare endocardial infection, that may present with high rates of mortality and severe complications such as septic embolism. Diagnosis is based on modified Duke criteria and should be suspected in patients with fever and cardiac risk factors such as valvular prosthesis, cardiac devices and congenital heart or valve disease. Long-term antibiotic therapy is the basis of the treatment while valvular surgery is indicated just in specific cases.

Case description

We report the case of a 69 years old female with known medical history of valvular heart disease (aortic and mitral mechanical prosthesis and pacemaker) and pancreatitis lithiasis. Was admitted to Gastroenterology ward due to acute pancreatitis having a positive clinical response until day eight. The patient then starts with night fever, chills and left upper limb phlebitis with purulent exudate. Laboratory findings showed an elevated inflammatory marker and acute renal failure. After blood was taken for culture a course of flucloxacillin was commenced. 24h

later starts with headache, blurry vision and a decrease in visual acuity. Non contrast head CT scan showed and multiple cerebral and retinal embolism of likely infectious etiology. Was evaluated by Ophthalmology and diagnosed with infectious endophthalmitis with retinal hemorrhage suggestive of Roth spots. Further tests showed a Methicillin-resistant *Staphylococcus aureus* (SA) in hemocultures and upper limb phlebitis exudate. Therefore, by Duke's criteria, started antibiotic therapy due to IE in a prosthetic valve. At day fourteen the patient starts with new motor deficits with the Non contrast head CT scan showing three new hemorrhagic lesions. Transesophageal echocardiogram (TEE) revealed no vegetative lesions. Was then transferred to coronary intensive unit where end up being intubated and mechanically ventilated due to respiratory failure. There was progressive clinical worsening with multiorgan dysfunctions. She was transferred to a non-cardiac intensive care unit where she died 12 days after the onset of the first symptoms.

Discussion

IE is a potentially lethal infection if antibiotic treatment is delayed. Even with prompt initiation of treatment, the mortality rate and incidence of significant complications remains high, particularly in susceptible patients such as the elderly and those with vascular prostheses, cardiac pacemaker or SA infection. This case illustrates the challenge of IE management.

#1437 - Abstract

NUTRITIONAL STATUS (NS) IS A MAJOR RISK FACTOR FOR MORTALITY IN THE HEART FAILURE (HF) POPULATION: RESULTS FROM A CONTINUITY OF CARE UNIT (CCU).

María Escamilla Espínola, Juan Igor Molina Puente, Cristina Sánchez Sánchez, Miguel Pedromingo Kus, Rebeca Sánchez González, Ana Cristina Antolí Royo, Victoria Hernández Jiménez, Dolores López Fernández, María Rocío García Alonso, Manuel Martín Casado, Demetrio Sánchez Fuentes
Complejo Asistencial de Ávila, Ávila, Spain

Background

Malnutrition is still a major and underestimated concern in patients with HF. Nowadays, an easy and efficient validated tool for controlling the NS, in any patient, relies on the CONUT Score (CONUT-S). The aim of our research was to evaluate the association between two variables, mortality and NS, in an HF cohort, based on the CONUT-S.

Methods

Retrospective observational cohort study of 228 outpatients with HF followed by the CCU in Avila, Spain, from October 2016 through March 2019. Data were anonymously examined. The CONUT-S was used to calculate the NS (employing one immune indicator and two biochemical parameters). We classified patients into four groups, according to their NS: severe-moderate-light

undernutrition, or normal state of nutrition. Remaining data referred to the CONUT-S are summarized elsewhere (Ulbarri et al. Nutr. Hosp. 2005). We studied the association between NS and mortality. Differences in baseline characteristics were analyzed by the chi-squared test. Significance was set at a p-value <0.05.

Results

228 outpatients with an HF diagnosis comprised the CCU database. Complete information was only available in 172 of them, selecting them for final analysis. The mean age was 83.7 years (SD 7.9), with a similar proportion of men (47.7%) and women (52.3%). The mean follow-up time amongst all patients was 12 months. 45 patients were classified as NYHA class I (NYHA-I), 103 patients as NYHA-II and 24 as NYHA-III. 128 patients (74.4%) had undernutrition (light, 46%; moderate, 26.7%; severe, 1.7%). 36 (20.9%) patients deceased, and 33 of them (19.2%) had some nutritional disorder. HF was the most frequent cause of death (20 patients dead for this reason). The mean follow-up time amongst deceased patients was 9.9 months. The association found between mortality and NS was assessed using the chi-squared test, and was found to be statistically significant ($X^2 = 25,29$, $p < 0.001$).

Conclusion

In our observational study, almost 75% of patients had evidence of malnutrition. Results obtained from the association between mortality and NS was statistically significant. Malnutrition in HF patients has a poor prognosis.

#1441 - Case Report

HEART-BREAKING INHALERS

David Prescott, Ana Isabel Brochado, Margarida Pimentel Nunes, Inês Branco Carvalho, Isabel Montenegro Araújo, Beatriz Donato, Rita Sérvio, José Luís Ferraro, Vasco Evangelista, António Martins Baptista, José Lomelino Araújo
Hospital Beatriz Ângelo, Loures, Portugal

Introduction

Takotsubo cardiomyopathy (TCM), also named as stress-induced cardiomyopathy, is a rare reversible cardiac syndrome. Like acute cardiac syndromes, it is characterized by chest pain of abrupt onset with ST-segment elevation and elevated cardiac ischemic biomarkers. However, unlike myocardial infarction, there are no critical coronary lesions in invasive coronariography. Echocardiography and invasive ventriculography will show left ventricular apical ballooning, a hallmark of the pathology. Its' pathophysiology is not completely understood, but often correlates with episodes of physical or emotional trauma, likely mediated by endogenous catecholamine production, with subsequent myocardial dysfunction by myocyte injury or ischemia from arterial spasm.

Case description

In this case report we present the case of a forty-seven year old

premenopausal woman who is admitted with a two-day history of precordial pain. She mentioned worsening of her asthma the week before, with need to resort to her inhaled 100ug salbutamol, using up to 2 full inhalers (400 doses) during the week. She had no other possible triggers. On initial observation she had bilateral wheezing on lung auscultation. Biochemical analysis showed heart ischemia and overload with elevated troponin of 2 ug/L and NT-proBNP of 2200 pg/mL. ECG showed T-wave inversion in Lead II. Chest X-ray had no visible changes. Echocardiography revealed systolic dysfunction, left ventricle apical ballooning, an akinetic apex and hypokinetic ventricle walls. During hospital stay she maintained a good clinical evolution with resolution of symptoms and biochemistry changes. Repeat echocardiography at the 6th day of admission showed normal systolic function without ventricular dyskinesia or other changes. After discussion with Cardiology, she was discharged on the 8th day on antiplatelet therapy and referenced to CT-angiography for non-invasive cardiovascular risk staging.

Discussion

Beta-adrenergic agonists are derivatives of epinephrine and stimulate the autonomic sympathetic nervous system, promoting bronchodilation. Towards higher doses, their abuse may serve as a form of exogenous catecholamine administration. There are increasing reports of TCM induced by beta-2-agonist use, especially in post-menopausal women. Since the association is being increasingly recognised, it is extremely important to exclude beta-agonist use as a precipitant, particularly in asthmatic or COPD patients.

#1443 - Abstract

END-ORGAN DAMAGE IN A SERIES OF HYPERTENSIVE PATIENTS

Rui Files Flores, Joana Rita Lopes, Maurício Peixoto, Guilherme Alpedrinha, Sofia Caridade
Hospital of Braga, Braga, Portugal

Background

Our primary goal is to access the prevalence of end-organ damage in hypertensive patients from an outpatient consult.

Methods

We selected patients from an outpatient consultation of a tertiary hospital care center. All patients from July 2018 to March 2019 were inserted. Information regarding date of the outpatient consultation, gender, age, degree and cause of hypertension, antihypertensive classes in use, records of blood pressure values and the presence of target organ damage were collected.

Results

During 9 months, 73 patients were evaluated for a total of 103 consultations. Thirty-four patients were male (46.6%) and 39 were female (53.4%). The mean age was 49.8 years and the median age

45 years. After dividing patients according to the probable cause of hypertension, we found 31 cases (42.5%) of essential hypertension and 14 cases (19.2%) of secondary hypertension. The remainder had no established etiology at the time of the conclusion of this report. In the group of secondary hypertension, we found 6 patients with obstructive sleep apnea, 4 with renal artery stenosis, 2 with aldosterone-producing adrenal adenomas, 1 with chronic kidney disease and 1 with Cushing's syndrome. Twenty-three percent of patients (n=17) had vascular complications related to arterial hypertension with the following distribution: 13.7% of kidney disease (n=10), 12.3% of cerebrovascular disease (n=9), 6.8% of cardiovascular events (n=5) and 2.7% cases of peripheral arterial obstructive disease (n=2). Sixty-three percent (n=46) were medicated with dihydropyridine calcium channel blockers in mono or polytherapy. Mineralocorticoid receptor antagonists (n=2, 2.7%) and central adrenergic agonists (n=2, 2.7%) were less frequently used. The majority of patients (n=44, 60.2%) presented blood pressure within target values.

Conclusion

The mean age of patients found in the outpatient consult was relatively low. Nevertheless, the prevalence of end-organ damage remains high. In the group with vascular events, there was a greater proportion of renal disease secondary to arterial hypertension, followed by cerebrovascular events, both causing serious morbimortality. This case series reflects the importance of blood pressure control beginning in a young age to prevent micro and macrovascular complications of arterial hypertension.

#1448 - Case Report

END-STAGE HEART FAILURE AND DYSAUTONOMIA

Diana Ferrão¹, Tiago Alpoim², Guilherme Assis¹, Luís Nogueira-Silva¹, Clara Machado-Silva¹, Pedro Ribeirinho-Soares¹, Catarina Pereira¹, Fernando Nogueira¹, José Marques¹, Jorge Almeida¹

¹ Centro Hospitalar e Universitário de São João, Porto, Portugal

² Instituto Português de Oncologia do Porto Francisco Gentil, Porto, Portugal

Introduction

Amyloidosis is a group of disorders characterized by a defect in protein folding that leads to extracellular anomalous protein deposition in the form of insoluble aggregates - the fibrils. The deposits can virtually occur in any organ, namely the kidney, autonomic nervous system and heart.

Case description

A 75-year-old patient with long term rheumatoid arthritis medicated with immunosuppressants was admitted with decompensated heart failure (HF). She was diagnosed with de novo auricular fibrillation with slow ventricular response, which was interpreted as the HF decompensating factor. She maintained bradycardia of ~40 beats per minute with periods of hypotension

and it was decided to proceed to pacemaker implantation. Despite subsequent heart rate control, she had persistent respiratory failure, peripheral edema refractory to high dose diuretics and symptomatic orthostatic hypotension. She was submitted to a TILT test that confirmed the dysautonomia. The echocardiogram showed marked biventricular and septal hypertrophy, mainly of the right ventricle. The patient was submitted to an endomyocardial and subsequently salivary gland biopsy (to improve the yielding of the findings), which was positive to amyloid substance. The etiologic diagnosis of amyloidosis showed no signs of monoclonal gammopathy. The serum amyloid A protein was positive and when combined with the history of rheumatoid arthritis led to a presumptive diagnosis of type A amyloidosis causing ventricular hypertrophy, with persistently decompensated HF, and dysautonomia. The attempt for definitive identification of the amyloid protein was inconclusive. The patient was discharged and in the next few months she kept relative clinical stability. Ten months after her discharge she was admitted to the emergency room with aggravated respiratory failure and was diagnosed with bilateral community acquired pneumonia. Her clinical status deteriorated rapidly, with multiorgan dysfunction, and she died one week after admission and one year after being diagnosed with systemic amyloidosis.

Discussion

AA amyloidosis is a rare disease that can occur in patients with underlying chronic inflammatory diseases, such as rheumatoid arthritis. Cardiac involvement is uncommon and when present confers bad prognosis. Therapeutic options are still limited and rely mainly on the control of the underlying inflammatory process.

#1460 - Case Report

AN ATYPICAL VIRAL PRESENTATION

Isabel Montenegro Araújo, Margarida Pimentel Nunes, Inês Branco Carvalho, David Ferreira Prescott, Ana Brochado, Vasco Evangelista, Sofia Mateus, António Martins Baptista, José Lomelino Araújo

Hospital Beatriz Ângelo, Loures, Portugal

Introduction

Deep vein thrombosis (DVT) is a manifestation of venous thromboembolism, a common pathology in the Internal Medicine wards. Anticoagulation (AC) is the only therapy known. There are recognised triggers whose correction allows, in most cases, the suspension of AC after a stipulated time. However, the challenge is when the cause is not easily identifiable, and the time of therapy becomes unknown.

Case description

The authors report the case of a 29-year-old man with a history of recurrent tonsillitis and active smoking (17 pack-years). No relevant family history. Emergency Department (ED) due to right low back pain, irradiating to the inner thigh area, associated with

premature surfeit, for 1 week. Without trauma, inactivity or recent travels, fatigue, asthenia, weight loss or infectious disease suspect. No signs of bleeding disorder. First ED admission at the beginning of the symptoms discharged with medication for mechanical low back pain without improvement. Current admission, abdominal ultrasound presenting endoluminal filling of the inferior vena cava, with involvement of primitive iliac and hypogastric veins, suggestive of acute/subacute partial thrombosis. Laboratory with abnormal liver biochemical tests with cytocholestatasis. Admitted to medical ward and a full body tomography was performed confirming extensive thrombosis. Started treatment with enoxaparin 80 mg every 12 hours (2 mg/kg/day) and complementary exhaustive investigation to rule out the triggering cause.

Of all the research on autoimmune, infectious diseases and malignancies, the positivity of Epstein-Barr (EBV) VCA and EBNA IgM antibodies, with very high titles, and anti-Cytomegalovirus IgM, but in a very low title, was highlighted. A multidisciplinary discussion was held with Vascular Surgery and Microbiology and it was considered the acute EBV infection the most probable diagnosis, although with an unusual presentation, with vascular thrombotic and hepatic involvement.

After documentation of thrombus chronicity without relevant post-thrombotic syndrome and viral seroconversion, anticoagulation was suspended at 6 months of therapy without recurrence of thrombotic phenomena after 1 year follow-up.

Discussion

DVT is a frequent diagnosis in MI wards, although occurrence in young age, with no clear triggering factors, created a diagnostic challenge only possible to solve with extensive research and multidisciplinary cooperation, allowing the correct therapy and clinical guidance.

#1505 - Case Report

A HEART IN A HEART-SHAPED SHELL

Ana Isabel Andrade Oliveira, Joana Morais, Olga Pires, Inês Burmester, Filipa Rodrigues, Mariana Devesa, Maria João Regadas, Paulo Gouveia

Hospital de Braga, Braga, Portugal

Introduction

Constrictive pericarditis is a rare cause of diastolic heart failure (HF), frequently presenting without a clear etiology. In the developing world tuberculous pericarditis is the most common etiology, while in the developed world previous cardiac surgery, idiopathic pericarditis and chest radiotherapy are the most common causes. When these patients present with multiple comorbidities the correct diagnosis and treatment may be delayed.

Case description

A 68-year-old man with history of HFpEF, atrial fibrillation, right nephrectomy and alcoholism presented with dyspnea, orthopnea, paroxysmal nocturnal dyspnea, nocturia, asthenia, decreased

tolerance for small efforts and 5 Kg of weight loss in the last month. Ascites, bimalleolar edema, jugular venous distension and decreased murmur in the left hemithorax were evident on examination. Laboratory tests showed normocytic normochromic anemia, and the thoracic x-ray revealed a pericardial calcification and pleural effusion, confirmed by CT scan. The CT also revealed ascites, cirrhotic liver and a mass in the left lobe, characterized by MRI as hepatocellular carcinoma. The subsequent study was positive to hepatitis C (genotype 3a). The echocardiogram showed inspiratory deviation of the interventricular septum to the left ventricle and a dilated vena cava without inspiration collapse; cardiac catheterization identified ventricular pressure curves with square root morphology “dip and plateau” and pulmonary hypertension. With these findings, the diagnoses of idiopathic calcified constrictive pericarditis and hepatocarcinoma were assumed. The patient was discharged after stabilization with diuretics, oriented to radiofrequency ablation and cardiology consult. However, one month later he was readmitted with deteriorating cardiovascular and kidney function, resulting from the progressive diastolic dysfunction, rapidly escalating to cardiogenic shock and anuric renal failure that resulted in his death a few days before the scheduled pericardiectomy.

Discussion

Constrictive pericarditis should be suspected in patients with clinical features of right-sided heart failure. In most cases, like ours, the underlying cause is unknown. Pericardiectomy can confer a long-term survival benefit and help in etiology determination. This case was challenging because he presented cirrhosis, hepatocarcinoma and constrictive pericarditis all diagnosed at the same time, making difficult the etiology assessment and therapeutic adjustments.

#1518 - Case Report

ESSENTIAL THROMBOCYTHEMIA-RELATED ACUTE MYOCARDIAL INFARCTION: A SMALL SERIES OF TWO CASES

Carlos Pinhão Ramalheira¹, Regina Costa², Silvia Monteiro², Francisco Gonçalves², Rui Baptista², Lino Gonçalves²

¹ Hospital Prof. Fernando Fonseca, EPE, Lisbon, Portugal

² Centro Hospitalar e Universitário de Coimbra, Coimbra, Portugal

Introduction

Essential thrombocythemia (ET) is a myeloproliferative disorder characterized by expansion of the megakaryocytic elements in the bone marrow, with a persistent increase in the platelet count. The clinical course of untreated ET is dominated by thrombosis, constituting the major causes of morbidity and mortality. Nevertheless, coronary artery thrombosis in ET patient is rare, especially without traditional risk factors.

Case description

We present two cases of myocardial infarction in context of TE

with no other known cardiovascular risk factors. Both patients are a 32 year-old male (Patient 1) and a 47 year-old male (Patient 2) presented in the ER with chest pain as the main complaint. Both were already diagnosed with TE, however only the eldest was correctly medicated for this condition. Both had a normal physical examination and ECG with ST elevation in the anterior leads as well as increased cardiac enzymes at admission. During angiography, both patients had lesions in the left anterior descending (LAD) artery. Patient 1 was referred to surgery since the occlusion involved proximal segments of the left coronary artery, while Patient 2 was submitted to balloon dilatation and stenting. Platelet counts were persistently elevated. At discharge, both patients were treated with dual anti-platelet therapy and citoreductive therapy, and follow-up in Hematology and Cardiology consults.

Discussion

Patients with high platelet counts should be evaluated thoroughly. A platelet-mediated mechanism should be considered in a patient with myocardial infarction without traditional risk factors.

#1523 - Case Report

THROMBOPHILIA AND PULMONARY EMBOLISM

Sara Almeida Ramalho, Tomás Nunes, Elena Pirtac, Ana Gomes, João Namora Santos

Hospital Garcia de Orta, Almada, Portugal

Introduction

Venous thromboembolism (VTE) is related with environmental factors but can also be potentiated by existent hereditary thrombophilia. Factor V Leiden is the most frequent, followed by prothrombin gene mutation 20210A.

We present a clinical case of pulmonary thromboembolism (PTE) associated with an hereditary thrombophilia.

Case description

Male, 60 years old, without known personal clinical history, admitted in the emergency department with tiredness and dyspnea. He had been bedridden for some days, about 1 month before, for flu-like symptoms. The patient had family history of profound venous thrombosis (mother and maternal relatives).

At admission he was afebrile, blood pressure 132/93 mmHg, rhythmic pulse, 114ppm, with right basal crackles on auscultation. The remaining observation was normal and he did not presented clinical signs of profound venous thrombosis. The laboratory results revealed leukocytosis, elevated T troponin and elevated d-dimers. The electrocardiogram showed sinus tachycardia and the thoracic x ray was normal. The transthoracic echocardiogram revealed dilation of right chambers and signs of pulmonary hypertension (pulmonary artery systolic pressure 67 mmHg). Given the possibility of PTE, the patient performed a thoracic computed tomographic angiography which revealed signs of

bilateral pulmonary artery thrombosis. The diagnosis of PTE of intermediate-high-risk (PESI score 110 points) was confirmed. The patient was medicated with non fractionated heparin (NFH) and transferred to an Internal Medicine ward. NFH was changed for low molecular weight heparin and then to apixaban. Given the patient's family history, a search for thrombophilias was performed and heterozygous prothrombin gene mutation 20210a was detected. The patient was discharged under apixaban and referred to the outpatient consultation of venous thromboembolism.

Discussion

The risk of VTE associated with prothrombin gene 20210A mutation is 3-4 times higher in heterozygosity, being even higher in homozygosity. However, testing the presence of hereditary thrombophilias is controversial. This search might be important in patients with VTE younger than 50 years old and with at least 1 first degree family member with history of VTE, as illustrated in this case. It should be considered to investigate the presence of the same mutation in asymptomatic relatives, since they can benefit from the eviction of oral contraceptives and preventive and counselling measures in situations of higher risk of VTE.

#1526 - Abstract

A LOOK OVER 7 YEARS OF PERICARDITIS

Regina Costa, Cátia Ferreira, Nelson Pedro, Lélita Santos, Armando Carvalho

Coimbra Hospital and University Centre, Coimbra, Portugal

Background

Acute pericarditis is the most common disorder involving the pericardium. Despite being recorded in approximately 0.1-0.2% of hospitalized patients and 5% of patients admitted to the Emergency Department for nonischemic chest pain, the exact incidence and prevalence of acute pericarditis are still unknown and therefore epidemiological studies are largely lacking.

Methods

Retrospective study in which were included all patients admitted to an Internal Medicine department meeting acute pericarditis criteria between January 2012 and December 2018. Clinical and demographic data were analyzed through Microsoft Excel 2018 and SPSS v23.

Results

Our sample had 34 patients, 70.6% (n=24) were men, corresponding to 0.02% of all admissions to the Internal Medicine department. Mean age was 59.6 years. Concerning the classification, the majority (88.2%,n=30) had acute pericarditis, 5.9% (n=2) chronic and the remaining were constrictive. Recurrence of symptoms was detected in three patients (8.8%). Slightly more than half was idiopathic (55.9%,n=19), 29.4% (n=10) were infectious of which 40% were due to tuberculosis. Chest pain was the most common finding on physical examination (61.8%,

n=21), followed by dyspnea (53.0%, n=18) and fever (32.4%, n=11). Were performed 227 serological tests searching for infectious diseases and eight suggested viral etiology. On admission 79.4% (n=27) of the patients performed an echocardiogram, of which 85% had pericardial effusion. Only 17,6% (n=6) had typical ECG changes. The mean treatment time was 8.6 weeks. 58.8% of the patients were treated with colchicine and/or NSAIDs; 64.7% were prescribed antibiotics and 29.4% required steroids. Some factors of poor prognosis were identified: 14.8% had severe pericardial effusion; 20.6% developed miopericarditis and 26.5% were under anticoagulant medication.

Conclusion

The authors found both similar and quite distinct results compared to other centres. This may be explained by the relatively benign course of the disease and low yield of diagnostic testing, since the priority is to exclude complications and identify high risk patients in whom a more comprehensive evaluation should be performed, discouraging the establishment of a definite etiology and a better characterization of this entity.

#1533 - Abstract

MORTALITY PREDICTORS OF INFECTIOUS ENDOCARDITIS – A TERTIARY CENTER EXPERIENCE

Alexandra Briosa, Andre Esteves, Ana Broa, Ana Rita Pereira, Ana Marques, Sofia Alegria, Daniel Sebaiti, Ines Cruz

Hospital Garcia de Orta, Lisbon, Portugal

Background

Despite advances in medicine, infectious endocarditis (IE) is still one of the leading causes of morbidity and mortality in patients with valvular heart disease

Aim: To determine the independent predictors of hospital mortality in IE patients.

Methods

Single center retrospective study including suspected / confirmed patients (dts) during the last 12 years (2006-2017). A univariate and multivariate analysis was performed to determine the independent predictors of mortality

Results

174 pts, 75% (n=131) males, mean age of 61±16 years. 41.3% had previous history valvular disease, mainly degenerative disease (24.4%). 54% had hypertension, 25.3% previous heart failure (HF), 12.8% HIV infection and 9.3% previous history of neoplasia. At admission, 58.3% (n=98) had constitutional symptoms and 53.5% had murmur at auscultation (n=91). Native valve IE occurred in 74.1% of the cases (n=129), affecting especially the aortic valve (54%, n=94). The most frequent isolated agent was *Staphylococcus aureus* (*S. aureus*) (24.7%, n=43), followed by

Enterococcus (12.1%) and Streptococcus viridans (11.5%). 20.1% had no identified agent on cultures.

The main complication was HF (42.1%), followed by local valvular complications (35.7%), such as valvular destruction (21.2%) and abscess (14.3%). There were embolic complications in 33.9% of the cases. One third of the pts (33.9%) underwent surgical intervention. The mortality rate was 29.9% and septic shock was the main cause of death (35.6%).

In-hospital mortality was associated with previous HF ($p=0.003$), *S. aureus* ($p=0.048$) or Streptococcus group agents ($p=0.014$), especially Streptococcus viridans ($p=0.039$), days of hospitalization ($p=0.001$), left ventricular (LV) dysfunction ($p=0.012$), perivalvular abscess ($p=0.007$), development of HF ($p<0.001$) or septic shock ($p<0.001$) and with medical treatment only ($p<0.001$). The logistic regression showed that the days of hospitalization (OR: 0.96, 95% CI 0.93-0.98, $p=0.001$), presence of LV dysfunction (OR: 5.95, 95% CI 1.3-25, $p=0.0017$), development of HF (OR: 4.2, 95% CI 1.4-12.7, $p=0.009$) or septic shock (OR: 12.7, 95% CI 3, 5 - 45.1, $p<0.001$) and the use medical treatment only (OR, 0.052, 95% CI 0.011 - 0.243, $p<0.001$) were considered independent predictors of mortality.

Conclusion

IE is associated with high hospital morbidity and mortality. For the observed population, the predictors of mortality were mostly clinical. Surgical treatment plays an important protective role.

#1545 - Case Report

MINOCA, A "WORKING DIAGNOSIS"

Ana Cochicho Ramalho, Claudia Jesus, Inês Rossio, Filipa Moleiro, Helena Vitorino, Eduarda Comenda, Mário Barbosa, Nadine Monteiro, Sofia Marques Santos, Helena Cantante
Hospital Lusíadas Lisboa, Lisboa, Portugal

Introduction

One to 13% of myocardial infarction (MI) occur in the absence of obstructive coronary artery disease. The diagnosis is made fulfilling the universal criteria of MI, without coronary artery stenosis $> 50\%$, and no clinically specific cause for the acute presentation. Some presentations of acute MI with ST segment elevation (STEMI) that in the angiography failed to show the presence of obstruction, were labelled as false-positive STEMI's and no further evaluation or therapy ensued.

Case description

77-year-old female, with cardiovascular risk factors of hypertension, hyperlipidaemia and obesity, also with the diagnosis of hypothyroidism. In use of nebivolol, levothyroxine and lansoprazole. She presented at the emergency department with acute chest discomfort, at rest, irradiating to the left arm, accompanied by nausea and vomiting. She was hypertensive – 203/102 mmHg and had no other noticeable features on examination. The Electrocardiogram showed a sinus rhythm (78

bpm) and a ST segment elevation in D1 and aVL leads, and a ST depression in V3 and V4 leads. The highly sensitive troponin levels were 33 ug/L at admission, reaching a maximum of 46.01 ug/L. She also had a total Creatine Kinase of 1076 UI/L, and a fraction MB of 69.8 ng/mL, and the analysis were otherwise unremarkable. The echocardiography showed akinesia of the apical septal and apical lateral segments, and a normal systolic function.

Acetylsalicylic acid, Ticagrelor and UFH were administered, followed by an emergency catheterization with no sign of obstruction of the coronary arteries. The ventriculography suggested Tako-Tsubo syndrome.

While recovering it was noticed an auricular fibrillation with rapid ventricular response.

A Cardiac Magnetic Resonance disclosed a reduced ejection fraction (38%), hypokinesia of the middle and apical segments of the lateral wall and of the middle segment of the inferior wall. The late gadolinium enhancement showed transmural of 50-75% in the same segments, compatible with MI.

The patient had a Killip Kimbal I progression, and was discharged under acetylsalicylic acid, apixaban, a statin, a b-blocker and an ACE inhibitor.

Discussion

MINOCA is a "working diagnosis", a term that should be used when no specific clinical diagnosis is apparent, sheltering the importance of investigating the underlying aetiology, so the answers to "what's the pathophysiology behind the event?" and "how should we manage such patients?" becomes more and more clear throughout the evolving years.

#1546 - Case Report

MARANTIC ENDOCARDITIS

José Brito-Da-Silva¹, Ana P. Ferro², Ana Lisa Lima², Luísa Guerreiro²

¹ Department of Medical Oncology, IPO-Porto, Porto, Portugal

² Department of Internal Medicine, Hospital Pedro Hispano, Matosinhos Local Health Unit, Matosinhos, Portugal

Introduction

Nonbacterial thrombotic endocarditis (NBTE) is a rare condition, with no sex predilection; in almost 80% of cases, an underlying malignant condition is present. Patients are typically asymptomatic until embolization, and up to one half of the patients present with an embolic phenomenon.

Case description

A 58-year-old woman, diagnosed in 2013 with uterine adenocarcinoma, on follow-up to date, and under hypocoagulation due to deep vein thrombosis of the right leg in the past 2 months, presented to the emergency room with slurred speech and a minor central facial paresis, being diagnosed an ischemic stroke. Cerebral CT-scan did not show acute ischemic lesions. Given the elevated thrombotic risk due to her personal history, hypocoagulation was started with a low-weight molecular heparin.

A transthoracic echocardiogram was performed, showing a filiform structure on the anterior leaflet of the mitral valve, confirmed by transesophageal exam, suggestive of vegetation. All the clinical data pointed to a prothrombotic state, namely the history of a malignancy and the occurrence of two different episodes of thrombosis in recent months (both venous and arterial); having in consideration that signs of infection were never present during her stay, the diagnostic hypothesis of a marantic endocarditis was risen. Blood cultures were drawn, as well as a comprehensive study in order to exclude possible negative-culture endocarditis, with agents such as *Coxiella burnetii* and *Bartonella* spp. A thoraco-abdomino-pelvic CT scan was performed, showing newly detected pulmonary nodules and a peritoneal lesion on the right hepatorenal space, raising the hypothesis of disease progression. Given the patient's clinical stability and a high clinical suspicion of the endocarditis being the expression of a paraneoplastic syndrome, she was discharged and oriented to her assistant oncologist, in order to complete the study of a possible progression of the malignant disorder.

Discussion

Treatment of NBTE usually consists of systemic anticoagulation and therapy directed at treating the underlying malignancy or associated condition. It must be continued anticoagulation indefinitely due to the high risk of recurrent systemic embolization. Despite therapy, the prognosis from NBTE is generally poor, therefore its recognition is very important to initiate treatment and try to modify this course of events.

#1556 - Case Report

PROGRESSIVE EXERCISE SYNCOPES: A CLINICAL CASE

Vera P Sarmiento, João Pais, Diogo Brás, Mafalda Carrington, Margarida Massas, Ana Bernardo, Vasco Neves, Tereza Veloso, Pedro Semedo, Bruno Piçarra, José Aguiar
Hospital do Espírito Santo de Évora, Évora, Portugal

Introduction

Syncope is a transient sudden loss of consciousness due to an acute compromise of the brain vascular flow. Its differential diagnosis is broad, and the identification of those caused by cardiac diseases is paramount in avoiding preventable deaths.

Case description

66 yo men, previously treated for hyperlipaemia, with history of Hodgkin lymphoma 30 years ago. Two months before, the patient suffered a non-ST myocardial infarction (NSTEMI), for which he was submitted to a coronary catheterization with coated stenting of the right coronary (RC). He was under double antiaggregation, beta-blocker, angiotension II receptor blocker (ARB) and statin since then. Two months after discharge, the patient came in to A&E due to repeated short-lived episodes of light-headedness, blurred vision and sweating, at times followed

by loss of consciousness, from which he spontaneously recovered in seconds. These episodes happened in the context of physical effort since his discharge, and were progressively triggered by less intense exercise. On the day the patient presented to the A&E, he suffered two syncopes at rest. At examination: HR=54 bpm, BP=96/54 mmHg, SpO₂ 98% at room air, afebrile. Heart, lung sounds and neurologic exam were unchanged. Laboratory findings showed an increase of troponin I to 1.16 ng/dL (reference <0.036) with normal inflammatory markers and Hb 11.8 mg/dL. The EKG showed sinus rhythm at 60bpm, with T-wave inversion at DIII and aVF, and repolarization changes in DI and aVL, similar to previous tests. The heart ultrasound showed dilated right chambers with decreased systolic function of the right ventricle (TAPSE 13mm). Pulmonary embolism was excluded on CT. A new NSTEMI was assumed as the most probable diagnosis and the patient was admitted to the Coronary ICU. On the first day of admission, he suffered a symptomatic sinus bradycardia at 23bpm, with sinus pauses lasting for more than 3s. A temporary pacemaker was inserted and a coronary angiography was performed, showing a stent thrombosis of the RC. Clots were aspirated with flow recovery and no residual lesion. The patient was kept anticoagulated and was restarted on low-dose beta-blockers. The pacemaker was removed without complications.

Discussion

The clinical history is crucial when assessing patients with episodes of syncope. In this case, the repeated syncopes were akin to a RC angina due to stent thrombosis, likely with involvement of the sinus artery, resulting in symptomatic bradycardia with decreasing levels of exercise,

#1557 - Abstract

MONTEVIDEO'S OBESITY AND BARIATRIC SURGERY PROGRAM (PCOB): PRE-OPERATIVE ECHOCARDIOGRAMS ANALYSIS

Eugenia Thomas, Gustavo Bruno, Lucia Spangenberg, Andrea Vaucher, Álvaro Huarte
Hospital Maciel, Montevideo, Uruguay

Background

Obesity is a chronic epidemic disease that affects life quality and causes greater morbidity and mortality. It's an independent cardiovascular risk factor, developing symptomatic coronary disease, atrial fibrillation and heart failure (HF). Patients with advanced obesity stages who suffer from HF, excluding other aetiologies, are diagnosed of obesity cardiomyopathy characterized by a preserved left ventricular ejection fraction (LVEF).

Describe anatomical and functional left cardiac echocardiographic alterations in a population of morbid obese patients.

Methods

An analytical study was performed in Maciel's Hospital Obesity and Bariatric Surgery Program (Montevideo-Uruguay) between

June 2014 and September 2016. The inclusion criteria were 18 to 64 years old, a body mass index (BMI) greater or equal to 40 kg/m² or greater to 35 kg/m² with comorbidities. Patients with cardiomyopathy of known aetiology, atrial fibrillation, hyperthyroidism and poor echocardiographic window were excluded. A preoperative transthoracic echocardiogram was performed. These variables were defined according the Interamerican Society of Echocardiography and Cardiovascular Imaging: left ventricle mass, left atrium diameter, left ventricle diastolic diameter, interventricular septum, posterior wall, LVEF and diastolic dysfunction (DD). The diagnosis of left ventricular hypertrophy (LVH) was made based on the index of left ventricle mass indexed to high 2.7. These variables were analysed.

Results

We included 79 patients, 66 (83.5%) women, age average was 45.8 ± 10.22 years. The median BMI was 53.1 ± 9.05. Of these patients 50 (63.29%) had HT and 33 (41.77%) DM. LVH was diagnosed in 56 (70.88%), being the excentric hypertrophy pattern the most frequent (53.2%). 20.25% of the patients evidenced DD and 41.77% increased left atrial size. LVEF was greater than 50% in 97.5% of the cases. It was found a positive correlation (0.22) between BMI and LVH (p: 0.047). In order to understand which covariables are influencing LVH linear additive models were used. None of them were significative. Considering the Akaike's information criteria and the number of significant coefficients, the best model included IMC, LDL and HT variables (LVH~BMI + LDL + HT + BMI * LDL). Contribution to the development LVH was 8.8 for HT and 1,55 for IMC.

Conclusion

Eccentric LVH is the most frequent echocardiographic alteration in obese patients. The most important variable related to LVH development is HT, but BMI is a significant factor implied.

#1561 - Case Report

EMOTIONAL STRESS INDUCED SPONTANEOUS CORONARY ARTERY DISSECTION

Mulham Shikh Hamdon, Victoria Gonzalez
Wayne State University, Detroit, United States

Introduction

Spontaneous coronary artery dissection is an important yet often forgotten cause of ACS, especially in women presenting with acute myocardial infarction. Although frequently associated with varying precipitating risk factors, we are presenting a case, intense emotional stress alone leading to dissection and no other identifiable underlying predisposing risk factors

Case description

A 47-year-old woman with no cardiovascular risk factors was admitted for acute ST-segment elevation myocardial infarction.

She reported no home medications including hormonal therapy and has no smoking or recreational drug use history. The night prior to her arrival, she recalled having a very stressful event. The following morning, she was awoken by severe substernal chest pain which was constant and radiated to the left chest. Also she had 2 episodes of non-bloody emesis. The initial EKG showed ST elevation in leads V1, V2, and V3 with no reciprocal changes. A bedside echocardiogram showed ejection fraction of 50% with apical hypokinesis, so she had immediately coronary angiography which revealed spontaneous coronary artery dissection (SCAD) of the proximal left anterior descending artery with TIMI 3 flow throughout the coronary tree. No intervention was performed and there was complete resolution of ST-segment elevation post-cardiac catheterization. The patient was treated with dual antiplatelet therapy and was discharged home with plan for follow-up computed tomography angiography in 3 months.

Discussion

This case is a unique example of non-atherosclerotic SCAD presenting in a patient with no predisposing risk factors and solely precipitated by emotional stress. Once believed to be a very rare condition, spontaneous coronary artery dissection, has become an increasingly important differential for the cause of myocardial infarction in women 43 to 52 years of age. The underlying etiology of SCAD appears to be multifactorial, however, up to 20% of cases are labeled as idiopathic. Typically, patients have a clearly identifiable predisposing arteriopathy; fibromuscular dysplasia being the most common. Others include postpartum status, multi parity, connective tissue disorders, systemic inflammatory conditions, and hormonal therapy. Most patients do not have conventional risk factors for coronary artery disease. Interestingly, the patient presented in this case had no such arteriopathies. This patient also lacked any history or evidence of another causes.

#1564 - Case Report

SINCE EMBRYO IS THE HEART FORMED – A CASE REPORT OF LEFT VENTRICLE NONCOMPACTION

Rebeca Martins Natal, Vasco Neves, Pedro Ventura
Local Health Unit of Guarda, Guarda, Portugal

Introduction

Left Ventricle Noncompaction (LVNC) is a rare cardiomyopathy, with unknown prevalence, characterized by exuberant left ventricle (LV) trabeculation. It has been suggested that may be due to a dysfunction of the cardiac embryogenesis. Clinical manifestations can occur at any age and include heart failure (HF), arrhythmias, thromboembolic events and sudden cardiac arrest.

Case description

The presented clinical case refers to a 49-years-old male, former smoker (19 pack-year units) with personal history of obesity grade I, obstructive sleep apnea, depression and LV slight dilatation

documented echocardiographically 15 years ago, after an episode of angor; without further follow-up. Chronically medicated with amitriptyline. No relevant family history. This patient attended our outpatient clinic with complaints of easy fatigue with progressive worsening in the last 3 months. First complementary exams revealed no relevant findings in laboratory results, EKG with complete left bundle branch block previously unknown; transthoracic echocardiography showed dilated cardiomyopathy with severe systolic function depression (ejection fraction (EF) of 33%), hypokinesis of the septum, apex and inferior wall; Holter 24h without alterations. Posteriorly, myocardial scintigraphy excluded underlying ischemia or necrosis and, finally, cardiac magnetic resonance revealed trabeculated LV myocardium, especially in the medial and distal segments of the lateral, anterior and inferior walls, with noncompaction criteria. Patient was then referred to the cardiology clinic, started classic treatment for HF with reduced EF and was subsequently placed an implantable cardioverter defibrillator (ICD).

Discussion

With the advent of new cardiac imaging techniques, LVNC has been increasingly diagnosed, and may be a more common cause of HF than previously assumed. There are no standardized diagnostic criteria. Treatment consists of the treatment of HF, if present, and consider anticoagulation, as well as placement of ICD.

#1575 - Case Report

OSBORN WAVE IN HYPOTHERMIA

Viktor Malyarchuk¹, João Gomes², Daniela Meireles¹, Joel Pinto¹, Jorge Henriques¹

¹ Centro Hospitalar do Baixo Vouga, Aveiro, Portugal

² Centro Hospitalar e Universitário de Coimbra, Coimbra, Portugal

Introduction

Hypothermia can cause very characteristic changes in electrocardiogram (EKG) though the slow conduction of impulses through the potassium channels. This results in an increase in all intervals. J wave or Osborne wave although isn't pathognomonic (as it also appears in hypercalcemia, intracranial hypertension, subarachnoid hemorrhage, Brugada syndrome and others), it is the most specific EKG finding in hypothermia. It is characterized by a positive deflection of J point (end of QRS complex and beginning of ST segment) and represents the distortion of the earliest membrane repolarization phase. Its more prominent in V2-V5 and its height is proportional to the severity of the hypothermia.

Case description

An 87 years old female, with a history of hypertension, type 2 diabetes and early stages of dementia. Presented to the emergency department (ED) with an altered state of consciousness (apathy and language alterations) that began 4 days earlier, at that time she was medicated with etizolam and rivastigmine due to insomnia and dementia.

At admission at the ED, she had general weakness and was normotensive (blood pressure of 125/65 mmHg), dehydrated, hypothermic (tympanic temperature 34.8°C) and bradycardic at 40 beats per minute (bpm). Neurological examination showed left hemiparesis, facial left paralysis and global aphasia. EKG showed sinus bradycardia at 40bpm, prolonged QT and Osborne J wave. Analytical study without relevant changes, with normal TSH, free T4 and normal troponins. Urinalysis showed leukocyturia and nitrituria. Chest X-ray was normal and head CT scan showed no acute hemorrhagic or ischemic lesions.

The patient started empiric ceftriaxone, peripheral warming with thermic blanket, fluid therapy and flumazenil. After reaching a temperature of 36°, she showed clinical improvement as well as hemodynamic stability, recovery of state of consciousness and neurological deficits. A repeated EKG was normal, without any J wave.

Discussion

Although Osborne's J-wave is not the most frequent or pathognomonic electrocardiographic abnormality of hypothermia, it is important to recognize it because it may be confused with ST elevation and may lead to unnecessary treatments. The authors present this case for the documentation of this classic electrocardiographic alteration, not always recognized, but important for the establishment of differential diagnoses.

#1592 - Case Report

ANTIPHOSPHOLIPID SYNDROME PRESENTING AS CONGESTIVE HEART FAILURE

Anilda Barros, Rita Homem, Maria Garcia, Vanda Spencer
Hospital Garcia de Orta, Almada, Portugal

Introduction

Antiphospholipid syndrome (APS) is an autoimmune multisystemic disease characterized by persistently elevated levels of procoagulant antiphospholipid antibodies (aPL), predisposing to recurrent venous or arterial thrombosis. It may occur in isolation (primary APS), this being the most frequent form, or associated with other autoimmune disorders, infections, malignancies or drug use (secondary APS). The clinical manifestations are heterogeneous and vary according to the affected vascular territory, with venous thromboembolism being the most common consequence.

Case description

The authors present the case of a 70-year-old man, with a history of hypertension and type 2 diabetes, hospitalized for enlightenment of massive ascites and peripheral edema of 1-month evolution. From the initial exams performed, echocardiogram showed signs of right ventricular overload and dysfunction, with pulmonary embolism (PE) being later diagnosed by lung scintigraphy. In the aetiological study it was established the final diagnosis

of primary APS, based on the presence of one clinical criteria (confirmed venous thrombosis) plus one laboratorial criteria (circulating anticardiolipin antibodies IgG type), and the patient started oral anticoagulant therapy with Warfarin for target INR values between 2 and 3.

Discussion

This case intends to emphasize the initial presentation of PE as an congestive heart failure and the importance of the diagnosis of APS for an adequate therapeutic approach of these patients requiring special care. Although the new direct oral anticoagulants have several benefits in the treatment and prevention of venous thrombosis in the general population, their efficacy in APS still awaits confirmation in specific studies and only the use of Warfarin or other vitamin K antagonists is recommended.

#1593 - Medical Image

AORTIC ANEURISM OCCLUSION

Nuno Bernardino Vieira, [Alexandra Avila](#), Vanda Conceição, Maria José Grade, Luísa Arez

Serviço de Medicina 3 - Unidade Hospitalar de Portimão do Centro Hospitalar Universitário do Algarve, Portimão, Portugal

Clinical summary

A 75-year-old male came to the Emergency Room due to a 2-day course of intense pain in the lower limbs and oliguria, with a previous history of severe peripheral arterial disease. Physical examination revealed an abolishment of the pulses in the lower limbs. A CT angiography showed acute occlusion of aortic aneurysm (3.4 cm maximum caliber) below the emergence of the superior mesenteric artery. It involves the right renal artery, which was occluded. The left kidney presents stenosis in its path, with an emergency located immediately above the occlusion. Below celiac trunk he had complete occlusion of the aorta. The case was discussed with the vascular surgery of the reference hospital.

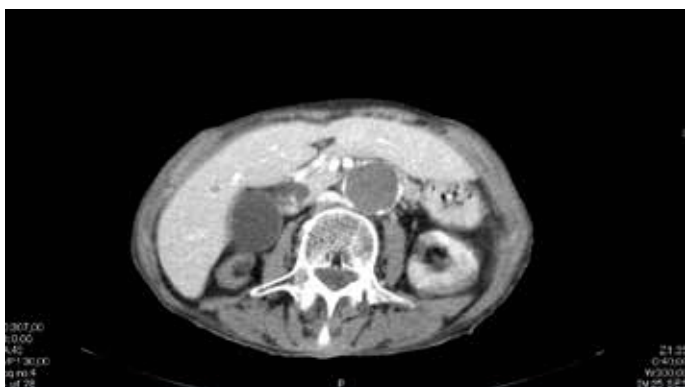

Figure #1593

#1600 - Abstract

AORTIC ELASTIC PROPERTIES ABNORMALITIES AS AN EARLY MARKER OF THE DEVELOPMENT OF AORTOPATHY IN PATIENTS WITH BICUSPID AORTIC VALVE

[Andrey Rudoy](#), Yaraslau Valiuzhenich, Aleksandr Bova, Aleksey Uryvaev

Belarusian State Medical University, Minsk, Belarus

Background

Bicuspid aortic valve (BAV) is a common congenital heart defect. Pathological changes affect both the valve complex and the aortic wall, which leads to the development of aneurysm / vessel dissection. The low predictive value of the currently used markers of adverse events leads to the search for new indicators that can characterize abnormalities in the microarchitecture and biomechanics of the vascular wall.

The aim of the study was to evaluate the elastic properties of the aorta in patients with a bicuspid valve by the method of two-dimensional speckle-tracking echocardiography in patients with BAV with aneurysm and without.

Methods

We examined 47 patients (22 patients with BAV, 25 healthy volunteers). For the first time in the Republic of Belarus, a two-dimensional speckle-tracking echocardiography of the ascending aorta to evaluate aortic wall function was performed. Student's test was employed to compare, respectively, continuous and categorical variables between different groups. Spearman and Pearson coefficients were employed to evaluate linear relationships between categorical and continuous parameters, respectively.

Results

Aortic dimensions on the Valsalva's sinuses, the sinotubular and ascending section in patients with BAV significantly exceeded the values in the control group ($t=3.18$, $p=0.002$; $t=2.68$, $p=0.01$; $t=3.39$, $p=0.001$). Aortic stiffness in patients with BAV was higher compared with the control group ($t=3.5$, $p=0.001$), while the extensibility and global circular deformation were reduced ($t=2.39$, $p=0.02$; $t=2.48$, $p=0.01$).

An increase stiffness in group with BAV and aneurysm of the thoracic aorta was 16.3 (13) versus 6.12 (4.2), $p=0.05$ in patients with BAV without aneurysm. Besides a reduction in global circular deformation in patients with thoracic aortic aneurysm compared with patients with BAV without aortic enlargement: 7.14 (2.9%) versus 8.6 (3.3%), $p=0.02$ was found.

Conclusion

- Pathological process in patients with BAV spreads to the aortic ring, aortic root and the ascending aorta with the formation of BAV-associated aortopathy.
- BAV-associated aortopathy is characterized by an increase in aortic size at all anatomical levels.

- BAV-associated aortopathy correlates with the violation of the aortic elastic properties at all anatomical levels which manifested by a decrease in global circular deformation, as well as an increase in the stiffness of the vascular wall.

#1610 - Abstract

NON-INVASIVE PERIPHERAL TRANSCUTANEOUS ELECTRONEUROSTIMULATION: NEW POSSIBILITY FOR NON-PHARMACOLOGICAL TREATMENT OF ARTERIAL HYPERTENSION?

Konstantin Yu. Malakhov¹, Valentin A. Kokorin², Alexander A. Gurov¹, Irina V. Kirichok³, Vladimir V. Malakhov¹, Andrey A. Fedorov⁴, Evgeny Yu. Bersenev⁵

¹ Inferum Group - Medical Department, Ekaterinburg, Russia

² Pirogov Russian National research medical university, Moscow, Russia

³ Municipal Polyclinic #175 of the Moscow Healthcare Department, Moscow, Russia

⁴ Physical therapy, Exercise Therapy and Sports Medicine department - Urals State Medical University, Moscow, Russia

⁵ National Research Center of Russia - Institute of Biomedical Problems of the Russian Academy of Sciences, Moscow, Russia

Background

The aim: to assess the efficacy and safety of the non-invasive device for peripheral transcutaneous electroneurostimulation (TENS) in patients with arterial hypertension (AH)

Methods

We performed 2 randomized sham-controlled studies involving 105 patients. In the first one, 77 patients (24 men, 53 women, mean age 62.5±11.6 years) were allocated to active treatment and sham control groups in ratio 1:1. In the second one, 28 patients (8 men and 20 women, mean age 70.1±6.9 years) suffering from AH and comorbid disorders were allocated to active treatment and sham control groups in ratio 3:1. All patients with the verified AH diagnosis had taken the recommended pharmacotherapy but did not achieve target blood pressure (BP) levels. The patients underwent the procedure of TENS 3 times per day for 14 days using device ABP-051 (Ekaterinburg, Russia). In control group, the procedure was performed using sham devices. In the second study, BP rates were monitored for 14 days after the treatment course.

Results

Both studies showed similar antihypertensive effect of the method. At the end of the treatment period, the significant decrease of systolic BP on 15.1±3.6 mm Hg ($p<0.05$) and diastolic BP on 6.0±0.8 mm Hg ($p=0.06$) was found. BP decrease was observed regardless of the AH grade. The combined results of the both studies showed that target BP was achieved in >80% of the patients (84.6% and 81.0%, respectively). There was no significant change of the BP values in the control

groups ($p<0.05$). The follow-up after the treatment showed that antihypertensive effect was maintained for 14 days. During the treatment period, there were no specific adverse effects related to the procedure.

Conclusion

The study showed antihypertensive effect of the non-invasive transcutaneous electrostimulation in patients with AH, who did not reach the target BP levels on pharmacotherapy. Further studies are necessary to confirm our preliminary results.

#1614 - Case Report

NOT EVERYTHING THAT RESEMBLES PNEUMONIA, IS PNEUMONIA. DIAGNOSTIC TECHNIQUES VS CLINICAL SEMIOLOGY

Juliana Chen Xu, Dolores Vazquez, Sónia Da Costa Fernandes, Angela Coelho, Teresa Pinto
CHPVVC, Póvoa De Varzim, Portugal

Introduction

Pulmonary embolism (PE) results from an alteration in the elements comprising Virchow's triad which leads to the obstruction of either the pulmonary artery or one of its branches. Certain conditions increase the risk for this alteration, such as prolonged bed rest, genetic mutations, neoplastic lesions, and others.

Clinic of PE is not pathognomonic, so it is essential to make a differential diagnosis to distinguish it from other pathologies such as pneumonia.

Notwithstanding that the Computed Tomography Angiography (CTA) is the gold standard test for the diagnosis of PE, its availability is not widespread, especially in smaller hospitals.

Case description

70-year-old male. History of obesity, hypertension, active smoking, non-functioning pituitary macroadenoma, chronic lung disease.

The patient resorted to the emergency department (ED) due to cold sweats and sudden pleuritic pain at the base of the right hemithorax without cough, sputum or dyspnea. Physical examination showed hemodynamical stability, afebrile, saturation of 94% on room air. On auscultation: no murmurs; with crepitations in the right hemithorax base.

Diagnostic techniques and procedures (DTP) showed right base condensation and C-reactive protein 7.38mg/dL with mild leucocytosis ($11.87 \times 10^9/L$).

The patient was hospitalized for community-associated pneumonia with significant pleuritic pain and empirical antibiotic therapy was initiated.

During hospitalization, and considering that the patient still presented severe pleuritic pain with need for therapeutic escalation to control pain, without fever, cough or expectoration, and with inflammatory parameters remaining stable, it was considered the possibility of PE, which was later confirmed by

CTA, the corresponding condensation image being a pulmonary infarct area. In the echocardiographic study, the patient exhibited dilated right chambers and signs of pulmonary hypertension.

On follow-up consultations, head CT showed an expansive homogeneous lesion with osseous molding of 16x26mm at the sellar pavement, of probable tumoral residue/relapse. MRI was requested.

Discussion

During the stay in the ED, the chest X-ray image was prioritized, considering it to be pneumonia, delaying the PE diagnosis and the probable paraneoplastic etiology.

The purpose with this case is to demonstrate the importance the clinical semiology holds, the signs and symptoms being the indicators for the diagnosis and to avoid neglecting these when giving preference to the DTP.

#1627 - Abstract

THE SIGNIFICANCE OF PRE-EXISTING LEFT VENTRICULAR REMODELING IN RELATION TO RISK STRATIFICATION IN NON-ST ELEVATION MYOCARDIAL INFARCTION

Madalina Andreea Munteanu¹, Camelia Nicolae²

¹ Clinical Hospital Th. Burghel, Bucharest, Romania

² University of Medicine Carol Davila, Bucharest, Bucharest, Romania

Background

Background: Left ventricular remodeling is the process by which ventricular size, function and shape are regulated by mechanical, genetic and neurohormonal factors. The occurrence of pre-existent left ventricular (LV) remodeling in a non-ST elevation myocardial infarction (NSTEMI) carries significant risk.

Methods

Methods: We retrospectively analyzed 36 patients (23 men and 13 women) with NSTEMI according to the adapted guide. The average age is 69.1±13.4 years. The analysis was carried out based on the results of echocardiography (ECHO) according to classical criteria for defining LV geometry in the moment of presence as the development of myocardial infarction. We have also used the Grace Score in relation with LV remodeling for stratification of NSTEMI.

Results

Results: All patients were analyzed. LV remodeling was observed in 34 patients (96%). 20 (55%) presented concentric hypertrophy, 8 (23%) concentric remodeling and 6 (18%) eccentric hypertrophy. We grouped patients in 3 groups depending on their Grace Score: low grade risk with Grace <108, intermediate risk with Grace Score between 109-140 and high risk with Grace Score > 140. Thus, in the study group, the type of remodeling associated with the Grace Score shows for high risk-75% concentric hypertrophy and 25% concentric remodeling, for intermediate risk-50% eccentric

hypertrophy, 25% concentric remodeling and 25% concentric hypertrophy and for low risk-50% concentric remodeling, 34% eccentric hypertrophy and 16% concentric hypertrophy.

Conclusion

Conclusions: Concentric hypertrophy is mainly associated with the study group, consisting of NSTEMI patients with a high risk Grace greater than 140. The presence of concentric ventricular hypertrophy, echocardiography diagnosed on hospitalization of patients with NSTEMI could advocate for the formulation of the immediate indication of PCI.

#1634 - Abstract

HOW ARE PATIENTS WITH SACUBITRIL-VALSARTAN? BASIC HEART FAILURE UNIT OF SECOND LEVEL HOSPITAL

Carlota Tuñón De Almeida, Maria José Ruiz Olgado, Victor Madrid Romero, Carlos Aldasoro Frias, Sara Muñoz Alonso, Victoria Palomar Calvo, Juan José Torres Ramos, Montserrat Chimeno Viñas, Luis Miguel Palomar Rodríguez

Complejo Asistencial de Zamora, Zamora, Spain

Background

Description of clinical and analytical profile of patients who started treatment with sacubitril-valsartan in its first years of commercialization in a basic heart failure unit.

Methods

Descriptive and retrospective review of patients through the evaluation of each patient's medical record who started treatment with sacubitril-valsartan from 31st January 2017 to 7th February 2019.

Results

In our sample, a total of 115 patients were analysed, 92 of which (80%) were male and 23 (20%) female. Age average was 72.6 years, with a typical deviation of 9.5 years, and a range of 45 to 87 years. Heart failure etiology was: ischemic (38.3%), dilated without ischemia (40.9%), and valvular (2.6%). More than half of the patients (53%) had Atrial Fibrillation.

The average LVEF was 32% (typical deviation of 10). Average glomerular filtration rate (before treatment was initiated) was around 61 ml/min.

As for the previous treatment in relation to heart failure, 100% of the patients were treated with angiotensin-converting enzyme inhibitors and angiotensin receptor blockers, 74% of them received antialdosteronic treatment, 92.2% had a beta blocker, and 86.1% diuretic treatment (mostly furosemide). 12.2% took ivabradine and 6% amiodarone.

Of these patients, 31 (27%) were implantable automatic defibrillator (IAD) carriers, of which 12 of them (40%) had ischemic heart failure. On the other hand, 4 of the patients (3.5%) were carriers of Cardiac-resynchronization therapy (CRT), and

16 (13.9%) carriers of both IAD-CRT. The rest of them, a total of 59 patients (51.3% approximately half the sample), had no device implanted on them.

Analytical data, previous to establishment of the new treatment, were: average pro-BNP of 3486 pg/mL, potassium of 4.6 mEq/L, sodium of 140 mEq/L and haemoglobin of 13.9 mg/dL.

Based upon NYHA functional class, 6 patients (5.1%) had a functional class I, 59 (50.4%) had a functional class II, 32 (27.4%) a functional class III, and finally, 5 patients (4.3%) were in functional class IV.

Conclusion

Patients of our Heart Failure unit who received Sacubitril/Valsartan, did it within the indications of the latest guides of clinical practice, published in 2016, having a high rate of previous beta blocker and antialdosteronic use. In future studies, we will evaluate if the evolution of the patients in our sample was similar to those included in the PARADIGM-HF study, regarding clinical and analytical improvement, and reduction of events in their follow-up.

#1661 - Case Report

SEQUENTIAL NEPHRON BLOCKADE – A CLINICAL CASE OF SEVERE DIURETIC RESISTANCE

Mariana Fidalgo, Beatriz Samões, Sofia Pereira, Manuela Sequeira
Centro Hospitalar Vila Nova Gaia / Espinho, Vila Nova De Gaia, Portugal

Introduction

Diuretic resistance is a frequent problem in heart failure [HF] patients, with an estimated prevalence of 20-30%. It refers to the inability to alleviate congestive symptoms despite appropriate or escalating diuretic dosages.

Case description

A 75-year-old man presented to the ER with progressive worsening of peripheral edema, dyspnea to increasingly smaller efforts and orthopnea.

He had multiple cardiovascular risk factors, hypertensive cardiopathy (NYHA II/IV) with preserved left ventricular ejection fraction [LVEF] (under furosemide and bisoprolol), pulmonary hypertension and permanent atrial fibrillation (under apixaban). He had chronic kidney disease and COPD GOLD A, with no recent exacerbations.

At presentation he had a BP of 118/84 mmHg, HR of 90 bpm (arrhythmic and irregular), polypnea and no fever. Cardiac and pulmonary auscultation was globally hypophonic. Abdomen was distended, with significant wall edema. He had bilateral leg and thigh edema.

Blood work: discrete creatinine elevation with no other significant alterations. Arterial blood gas: hypercapnic respiratory insufficiency with $pO_2 < 60$ mmHg. Chest x-ray revealed small bilateral pleural effusion. Transthoracic echocardiogram showed

right ventricle dysfunction and minor LVEF reduction. Abdominal echography found severe abdominal wall edema with no significant ascites.

Patient was admitted for therapeutic optimization. He was started on intravenous furosemide, under regular control of renal function and ionic balance. Despite increasing dosages (max.160mg/day), patient's weight remained stable with no improvement of congestive signs and symptoms.

On day 6 he was started on sequential nephron blockade with double diuretic therapy (furosemide plus metolazone). This resulted in a significant elevation of urinary output with gradual improvement in effort capability and no worsening of renal function. At discharge he no longer had respiratory insufficiency and had lost 17.5 kg. Follow-up appointment: patient was stable in NYHA II/IV under furosemide alone.

Discussion

Diuretic efficacy is evaluated based on weight loss and/or urinary output. Sequential blockade of sodium reabsorption in different nephron segments with two or more diuretics of different classes generates a synergic effect that counteracts several resistance mechanisms and significantly increases diuresis. Under close monitoring, it is a very safe and effective strategy to achieve congestion relief in the resistant patient and should not be feared.

#1663 - Case Report

THE DIAGNOSTIC CHALLENGES OF A CASE OF AORTIC DISSECTION

João Corrêa, Ana Branco, Eduardo Cernadas, Dália Estêvão, Ana Rita Elvas, Leopoldina Vicente

Serviço de Medicina Interna - Centro Hospitalar Universitário Cova da Beira, Covilhã, Portugal

Introduction

Aortic dissection is a disruption of the medial layer provoked by intramural bleeding, resulting in separation of the aortic wall layers. Aortic dissection is relatively rare (incidence estimated at 6 cases per 100,000 persons per year) but has an elevated mortality rate, of up to 20%. Early and accurate diagnosis and treatment are crucial for survival.

Case description

Female patient, 77 years-old, comes to the emergency room (ER) with intense pain in the superior thoracic and cervical regions, with acute onset whilst resting in a sitting position 30 minutes after dinner, associated with nausea and vomiting. In the ER, patient presented as hypotensive, with a normal and regular heart rate, without asymmetries in peripheral pulses or alterations on cardiac and pulmonary auscultation, benign electrocardiogram (ECG), slight elevation of myocardial necrosis markers with progressive descent, acute renal failure, slightly elevated inflammatory markers and interstitial infiltrate on chest radiography without mediastinal widening. With fluid resuscitation chest pain ceased

and hemodynamic stability was achieved. During ward admission, never again did the patient have intense chest pain or hypotension. Upper endoscopy was performed which revealed peptic esophagitis and hiatal hernia. Patient also developed atrial fibrillation with rapid ventricular response, left-side pneumonia, acute decompensated heart failure and left pleural effusion that evolved to bilateral. Consecutive chest radiography revealed a progressive increase in cardiac silhouette and mediastinal widening so a computed tomography (CT) scan and transthoracic (TT) echocardiogram were requested. TT echocardiogram showed an ascending aortic dilation of 60mm and images suggestive of the presence of thrombus on the aortic wall. Urgent thoracic CT angiography was performed and revealed a type I aortic dissection.

Discussion

A patient presenting with chest pain can be a diagnostic challenge given the wide array of possible causes that range from benign to life-threatening situations. This becomes especially true in the elderly population in whom signs and symptoms may be more difficult to appreciate and who may have co-existing diseases that can explain the symptoms, as in this case.

While, an aortic dissection often presents acutely as a catastrophic illness with severe chest pain and acute hemodynamic compromise, other forms of presentation and evolution should be considered.

#1667 - Abstract

IRON DEFICIENCY IN HEART FAILURE- A RETROSPECTIVE STUDY

Sofia Gomes Brazão¹, Ana Luisa Correia², João Filipe Gomes³, Ana Filipa Correia⁴, José Pedro Fernandes⁵, Fábio Salgueiro Rego¹, José Bernardes Correia², José Pereira Moura³, Armando Carvalho⁴

¹ Internal Medicine, Coimbra, Portugal

² Centro Hospitalar e Universitário de Coimbra e Faculty of Medicine, Coimbra, Portugal

³ University of Coimbra, Coimbra, Portugal

⁴ Coimbra, Coimbra, Portugal

⁵ Portugal, Coimbra, Portugal

Background

Recently iron deficiency (ID) has played an important role in heart failure (HF). These conditions are associated with poor clinical status and worse outcomes. The 2016 European Society of Cardiology Guidelines recommended that intravenous ferric carboxymaltose (FCM) should be considered in symptomatic patients with heart failure with reduced ejection fraction (HFrEF) and ID (serum ferritin <100 µg/L, or ferritin between 100–299 µg/L and transferrin saturation <20%) in order to alleviate HF symptoms. The aim of this study was to characterize the diagnosis and management of ID anaemia in patients with HF.

Methods

A retrospective cohort study was conducted on patients admitted

in an internal medicine ward between May and October of 2018 with the diagnosis of HF and anaemia.

Results

Four hundred and ninety seven patients were analyzed, of whom 195 had HF and anaemia. The median age was 85 year old and 58.5% were female. An echocardiogram evaluation was performed in 49.2% of the patients and 35.1% had HFrEF. BNP was tested in 90.25% of the patients with a mean value of 833 pg/mL. Most of the patients had chronic kidney disease on stage 3 (35.4%) and only 4.6% had no kidney damage. The average haemoglobin was 9.5 mg/dL. Ferritin levels were evaluated in 81% of the cases, with an average ferritin of 318mg/L. Only 26.2% had absolute iron deficiency (Ferritin <100µg/dL), and 32.8% had ferritin in the range of 100-300 µg/L. From the patients with ferritin levels less than 300µg/L, 96.3% were tested for transferrin saturation which was inferior to 20% in 39.5% of the cases. Mortality in the 6 month follow-up period was 38.5%, with 8.7% not surviving past the initial admission. Of the 178 patients surviving the initial admission, there was a total of 92 hospital readmissions directly related to HF within the follow-up period. Oral iron therapy was prescribed in 27.2% patients on discharge. Only 9.74% had intravenous iron therapy and 21% had blood transfusion.

Conclusion

This study shows the impact of HF on readmission and mortality rates. Although some studies have reported the benefits of FCM treatment in patients with HF, ID is still an underdiagnosed entity. In our opinion, it is important to screen for ID even in the absence of anaemia as FCM treatment has shown improvement in functional capacity and quality of life.

#1671 - Abstract

EVALUATION OF PATIENTS WITH ACUTE PULMONARY EMBOLISM, ACCORDING TO TROPONIN & CREATININE AT ADMISSION AND IT'S PROGNOSTIC IMPACT

Fabiana Gouveia, Diogo Raposo André, Rafael Nascimento, Teresa Raposo André, Rita Vieira, João Miguel Freitas, Luz Brazão
Hospital Central do Funchal, Funchal, Portugal

Background

Pulmonary embolism (PE) is a fatal entity in which risk stratification plays a key role. The determination of Troponin T (TpT) - cardiac necrosis marker - and Creatinine (Cr) - a marker of renal dysfunction - may be useful in the short-term prognostic evaluation of PE patients.

Methods

Retrospective analysis of patients diagnosed with PE at a Central Hospital in 2017. Of the 117 patients with the diagnosis of acute PE, only 116 performed an analytical evaluation at the entrance. These were stratified according to the values of TpT, Cr and the

Early Mortality Risk (EMR) developed by the European Society of Cardiology (ESC): right heart dysfunction, cardiac biomarkers, Pulmonary Embolism Severity Index (PESI) score and hypotension/shock. The data obtained were treated by IBM SPSS Statistics® Version 25 and the Pearson Chi-Square, Linear Association and ROC Curve tests were used.

Results

Of the 116 patients, TpT was only evaluated in 90 (58 women and 32 men). As shown by EMR, TpT is one of the factors included in the cardiac biomarkers group. In this study, TpT evidenced the presence of a relationship with statistical significance for EMR, as found in previous studies (95% CI, $p=0.005$). In this sense, we proposed to determine the association between EMR and altered values of Cr on admission.

Of the 116 patients with a determination of Cr value at diagnosis, 76 were women. According to the EMR stratification, 19 patients had a low risk of early mortality and 18 patients at high risk. Of the study sample, 50% had a high Cr - defined as a value above the estimated median of 1.01 (min 0.5, max 5.3).

It was found that there was a statistically significant association between the EMR of ESC and the altered values of Cr at the time of diagnosis with Pearson Chi-Square Test (95% CI, $p=0.012$). However, the ROC curve shows that the altered values of Cr do not have great discriminative power in relation to mortality (AUC=0.632).

Conclusion

Each factor alone does not have sufficient discriminative power to measure mortality, due to its low specificity and sensitivity, but it is possible to estimate the risk of early mortality in the diagnosis of acute PE.

#1673 - Medical Image

HEPATIC CYST, A DIFFERENT MANIFESTATION

Bruno David Freitas, Ana Garrido Gomes, Maryna Telychko, Sandra António

Hospital de Santarém, Santarém, Portugal

Clinical summary

88 year old woman, with known history of hypertension, chronic heart failure and myelodysplastic syndrome, presented in Emergency Department with dyspnoea of progressive onset without other symptoms. As part of workup, the patient underwent CT scan (thorax and abdomen) which revealed a hepatic cyst (145mm in diameter) that compressed right heart cavities. After exclusion of other causes as pulmonary embolism, pulmonary hypertension, respiratory infection as well as hydatid cyst, it was drained with resolution of dyspnoea.

The analysis of content was compatible with pure biliary cyst.

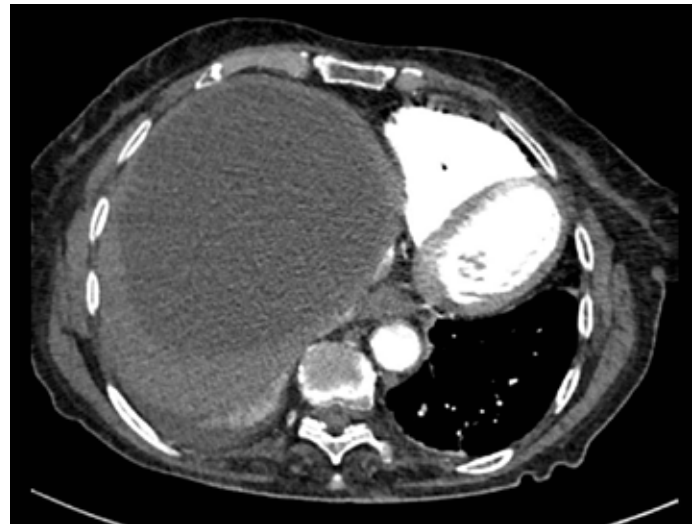


Figure #1673.

#1709 - Abstract

THE IMPACT OF HYPERTENSIVE PREGNANCY DISEASES IN AN INTENSIVE CARE UNIT

Isabel Montenegro Araújo¹, Inês Vieira Santos², Ursula Segura¹, Carlos Pereira¹, Patrícia Patrício¹, António Messias¹

¹ Hospital Beatriz Ângelo, Loures, Portugal

² Hospital Espírito Santo de Évora, Évora, Portugal

Background

Hypertensive disease occurs in up to 10% of pregnancies, establishing one of the major causes of maternal morbidity and mortality. It is the main cause of prematurity as well as admission to the ICU. In Portugal, it is the second cause of maternal death. These disorders may complicate 5%–10% of all pregnancies and are the leading cause of maternal and perinatal mortality and morbidity worldwide. Several risk factors are known to determine its occurrence, and it is important to monitor the women who present them to avoid such outcome.

Methods

The authors present the analysis of the obstetric population admitted to an Intensive Care Unit (ICU) whose cause of admission was hypertensive pregnancy disease (preeclampsia, eclampsia, HELLP syndrome) or in which it manifested during hospitalization. The demographic characteristics, personal antecedents and control of the risk factors prior to hospitalization were evaluated, as well as the evolution during the same. The clinical processes (of the hospitalization of obstetrics, birth unit and the intensive care unit) of all the patients admitted by the pathology previously described in the SMI during the period from February 2012 to March 2019.

Results

During the referred period, there were 126 hospitalizations of pregnant or puerperal patients. Admissions of hypertensive complications were present in 51 patients (corresponding to 41%

of admissions) and as a cause of admission in 39%, that is, the majority of these women.

Women ages were between 21 and 45 years. Most of the hospitalizations took place in the puerperium (42 hospitalizations - 82%). Among the relevant medical antecedents, pre-gestational hypertension or gestational hypertension, with insufficient control, was especially important, and it should be noticed that in some cases the pregnancy was not monitored and it was not possible to determine or classify the hypertensive disease as present before 20 weeks of gestation. Among the patients with hypertensive disease, there were no maternal deaths, however, 5 fetal deaths occurred (one after admission to the ICU).

Conclusion

The control of risk factors is of high importance in order to avoid an unfavourable outcome in this population. Good follow-up of these women during gestation, as well as tight surveillance during the peri-parturition period, is important, since hypertensive disease can have devastating consequences.

#1728 - Case Report

PULMONARY VALVE ENDOCARDITIS

Inês Mendes, Maria João Baptista, Francisco Araújo, José Lomelino Araújo

Hospital Beatriz Ângelo, Loures, Portugal

Introduction

Right heart infective endocarditis represents 5-10% of all endocarditis. Pulmonary valve endocarditis corresponds to 1-2%, usually in people using IV drugs or having some congenital cardiopathy.

Case description

We present a 72 year caucasian male, with a medical history of an aortic mechanic valve (4 years before), type 2 diabetes mellitus and hip replacement 3 months before. No toxicophilic habits.

He presented in the ER with fever and productive cough. Blood tests revealed inflammatory parameters and the X-ray showed a hypotransparency in the right superior lobe. He was diagnosed with a pneumonia and started amoxicillin and clavulanic acid plus azithromycin.

For a better characterization, he did a thoracic CT that revealed an extensive pneumonia and a trans-thoracic echocardiogram that showed a normal aortic valve.

During the investigation, there was a blood culture positive result for *Streptococcus Gallolyticus* and a switch to ceftriaxone. He went through an upper endoscopy (chronic gastritis) and colonoscopy (normal). He finished 14 days of ceftriaxone and withdrawal asymptomatic, with negative control blood cultures.

One month later, he went back to the ER, presenting with fever and cough.. This time he had a transesophageal echocardiogram that showed a pulmonary valve vegetation (18x11mm), with a normal aortic valve. There was again a positive blood culture for

S. Gallolyticus. Cardiothoracic surgery suggested conservative approach, so the patient completed 4 weeks of benzathine penicillin and 2 weeks of gentamicin. He repeated the trans-thoracic echocardiogram at the 22nd day, showing a vegetation 18x7 mm (with moderate pulmonary valve insufficiency associated). Withdrawal asymptomatic, with negative blood cultures.

Again, one month later he went back to the ER, presenting with fever, repeated the echocardiogram showing a bigger vegetation (22x12 mm). This time he went under surgery with a pulmonary valve substitution after completing 2 weeks of benzathine penicillin and 2 weeks of gentamicin.

Discussion

We must suspect of pulmonary valve infective endocarditis when the patient presents with the tricuspid syndrome: repeated respiratory events, anemia and microscopic hematuria. Usually the isolated microorganism is a *S. aureus* or a B group *Streptococcus*. It has a better prognosis than the left heart endocarditis. There are no guidelines for pulmonary valve endocarditis specifically but the few case reports in literature usually describe a surgery after 4-6 weeks of antibiotic.

#1729 - Abstract

THE COST OF HEART FAILURE IN A SECONDARY HOSPITAL

Maria João Morgado Nabais Baldo

ULS Guarda, Guarda, Portugal

Background

The HF is a serious public health problem worldwide with high morbidity and mortality. In 2012, HF cost 102 billion euros worldwide. Despite of the high prevalence of this pathology, there are few studies that approach this pathology from an economic point of view. The objectives are: 1. To evaluate the cost of patients with HF treatment in a secondary hospital. 2 To evaluated which variables has most influenc

Methods

The methodology was retrospective observational study with static analyses (SPSS 24) The population was all patients hospitalized in the internal medicine ward for 8 months with the primary diagnosis of HF in ICD-10. Exclusion criteria were: less than 18 years of age, transfer to other hospital, abandonment and discharge against medical orders, poorly coded process and hospitalization period <24 h. They were organized in groups: Demography, Diagnosis Complementary Diagnostic Tests, Pharmacological Therapy, Clinical Data, Procedures, Professionals and Hospitalization.

Results

The HF patient (n°156) is predominantly: female (54%), aged 83.85±7.641, with a rankin 1-3, with chronic HF (88.6%) in NYHA IV (97.5%), with a HFmEF (34.8%), ischemic etiology (24.7%), an

infection being the main cause of decompensation (50.6%). They have 5, 96±2.43 comorbidities (most frequent HTA (88.6%)). They stayed 12.7±7.942 days in the hospital, 51.9 % went to their own home (with a mortality rate of 5,1%). In the Clinical data: BP: 89.79±22.43, HR: 79.73±18.61, Hb: 11.07±2.141, O₂: 2.083±0.299, pH: 7.423±0.087, CI C: 31.0%. The total cost was 64841.6 €, (4103.90±2563.36) and a total daily cost of 355.99±113.91. complementary diagnostic tests accounted for 15.55% of costs (100858.04 €), procedures represent 14.27% (112004.45 €), pharmacological therapy 4.41% (28649.94 €), health professionals 18.02% (116848.58 €) and hospitalization 44.67% (289767.05 €). No strong correlation was demonstrated between the various variables in the bivariate analysis. In the parametric tests it was identified: difference between days of hospitalization and patient autonomy (t: 0.017), and in the cause of decompensation and the days of hospitalization (δ : 0.034) but that were not reflected in the total cost

Conclusion

There are different factors that aggravate the HF and consequently should aggravate the costs but this fact has not been proven in this study. Although the characteristics of the HF are well defined, the study of her cost still an unknown area and need more investigation

#1736 - Abstract

HOMOCYSTEINE AND ALL-CAUSE MORTALITY IN RETINAL VEIN OCCLUSION

Paula Reyes-Suárez, Candelaria Martín-González, Esther Martín-Ponce, Antonio Martínez-Riera, Alina Pérez-Ramírez, Julio Alvisa-Negrín, M.J Sánchez-Pérez, J Viña-Rodríguez, Melchor Rodríguez-Gaspar

Servicio de Medicina Interna, Hospital Universitario de Canarias. Universidad de La Laguna, San Cristóbal De La Laguna, Spain

Background

Increased homocysteine has been considered as a potential risk factor for retinal vein occlusion, a condition that includes central retinal vein occlusion or branch retinal vein occlusion. Retinal vein occlusion has been associated with an increased risk of cardiovascular morbidity and mortality. The aims of this study were to evaluate the relationship between homocysteine and the different types of retinal vein occlusion, and to analyse the prognostic value of homocysteine levels on long-term mortality in these patients.

Methods

We measured serum homocysteine levels in 477 consecutive patients with retinal vein occlusion who were followed up as outpatients.

Results

We included 254 men and 223 women, aged 62.9±12.8 years. 70% had branch retinal vein occlusion and 30% central retinal vein

occlusion. Only 58 patients (12.9%) lacked a history of vascular risk factors and 143 patients (31.8%) had more than three cardiovascular risk factors. 48 patients (10%) showed previous cardiovascular diseases. 73 patients (15.8%) died and the follow-up period was 89.9±52.5 months. Subjects with higher homocysteine levels showed a higher mortality ($p < 0.001$), especially among those with branch retinal vein occlusion. Homocysteine > 15 $\mu\text{mol/L}$ significantly predicted all-cause mortality with an HR of 2.07 ($p = 0.025$) after adjusting for other variables.

Conclusion

In patients with retinal vein occlusion, higher levels of homocysteine were independently related to all-cause mortality. This relationship was more significant for patients with branch retinal vein occlusion but not with central retinal vein occlusion.

#1770 - Abstract

EPICARDIAL ADIPOSE TISSUE (EAT) IN CHRONIC HEPATITIS C AND IN NON-ALCOHOLIC FATTY LIVER DISEASE (NAFLD) IS ASSOCIATED WITH CARDIOVASCULAR DAMAGE

Giovanna Oberti¹, Giordano Sigon², Roberta D'Ambrosio³, Giuseppina Pisano¹, Paolo Francione², Rosa Lombardi³, Pietro Lampertico⁴, Anna Ludovica Fracanzani⁵

¹ Ca' Granda IRCCS Foundation, Milan, Italy

² Policlinico Hospital, Milan, Italy

³ University of Milan, Department of Pathophysiology and Transplantation, Milan, Italy

⁴ CRC AM e A Migliavacca Center for Liver Diseases, Milan, Italy

⁵ Gastroenterology and Hepatology. Fondazione Ca' Granda IRCCS Ospedale Maggiore Policlinico, Milan, Italy

Background

Alcoholic Fatty Liver Disease (NAFLD), the most common liver disease in developed countries with a prevalence of about 30%, is considered the hepatic manifestation of metabolic syndrome, thus patients with NAFLD are at risk for cardiovascular damage. Chronic hepatitis C (CHC) has been associated to different clinical conditions including insulin-resistance and development of atherosclerosis. Epicardial adipose tissue (EAT), considered the true visceral fat, has been proposed as a cardiometabolic risk factor in patients with NAFLD.

Aim. To evaluate the role of EAT in NAFLD and CHC patients.

Methods

From 2015 to 2018, 130 patients with CHC (mean age 57.8 ± 11.8 yrs), 148 patients with NAFLD (mean age 56.9±7.5) and 290 controls of general population from the same geographic area (mean age 57.5±10.8) were enrolled. Clinical and biochemical parameters, cardiovascular assessment, (carotid intima media thickness (IMT) and carotid plaques and EAT thickness by ultrasound) were evaluated at enrollment. We arbitrarily

considered as increased the EAT value higher than the mean of controls (3.8±2.6 mm).

Results

Despite higher prevalence of hypertension (56% vs 24%, $p < 0.0001$), diabetes (26% vs 3%, $p < 0.0001$), hypercholesterolemia (55% vs 24%, $p < 0.0001$), and higher BMI (28.3±4.1 vs 24.8±5.3, $p < 0.0001$) of NAFLD than CHC, patients with NAFLD and CHC had similar atherosclerotic damage (carotid IMT 0.81±0.2 vs 0.82±0.2 mm, $p = 0.4$), carotid plaques (34% vs 35%, $p = 0.98$), while cardiac parameters E/A > 1 (34% vs 46% $p < 0.0001$) and EAT (5.5±2.8 vs 7.1±2.6 mm, $p < 0.0001$) were significantly higher in patients with CHC. Considering as increased EAT thickness value > 3.8 mm (mean of controls) we evaluated variables associated with increased EAT at multivariate analysis. Increased EAT was significantly associated with carotid IMT (OR 8.5, 95%CI 2.2-33, $p = 0.001$), and E/A (OR 0.2, 95%CI 0.1-0.4, $p < 0.0001$). Taking in to account all metabolic parameters at multivariate analysis the presence of HCV infection was significantly associated with increased EAT (OR 6.8, 95%CI 1.4-33, $p < 0.001$).

Conclusion

In conclusion, patients with CHC have cardiovascular damage comparable to patients with NAFLD. EAT thickness may represent a good tool for the identification of patients at risk of cardiovascular damage and should be performed in patients with CHC.

#1778 - Abstract

CHARLSON COMORBIDITY AND AVD-DEZIS SCORES IN PATIENTS ADMITTED DUE TO HEART FAILURE DECOMPENSATION: PREDICTIVE CAPACITY OF MORTALITY AND READMISSIONS

Diana Isabel Dias, Filipe Machado, Andreia Tavares, Heloisa Ribeiro, Yolanda Martins

Entro Douro and Vouga Hospitalar Center, Santa Maria Da Feira, Portugal

Background

In 1987, Charlson proposed a prognosis predictor score combining the patient age with his comorbidities (aCC-age adjusted Charlson comorbidity index) later updated as an in-hospital mortality predictor (mCC-modified Charlson comorbidity index). The AVD-DezIs score is a functional score validated in our hospital since 2013 that provides a patient global capacity pontuation based on the ability to perform the daily life and instrumental activities. We aim to evaluate the hability of these scores predicting 1 and 3-years mortality, emergency department and ward 30-days readmissions due to heart failure (HF) decompensation.

Methods

The 1 January-31 December 2016 discharged patients with discharge diagnosis of "congestive/left/non specified systolic/

non specified dyastolic HF" accordingly to portuguese validated Heterogeneous Diagnosis Group were analysed. The 1 and 3-years mortality, emergency department and ward 30-days readmissions comparative analysis accordingly to the aCC, mCC and AVD-DezIs scores was done using SPSS v.25 and $p < 0.05$ was considered as statistically significant.

Results

We have analysed 327 patients (33.3% male, 77±10 years) which presented a median mCC score of 10, aCC of 11 and AVD-DezIs of 6.1. The 30-days emergency department readmission rate was 30.6% (n=100), 17.4% (n=57) were hospitalized again and mortality rate was 20.8% (n=68) at 1 year and 13.5% (n=44) on 3 years after discharge. There was not significant difference on mCC between groups regarding and aCC scores groups 1-year mortality (2.69±1.89 vs 2.30±1.76, $p = 0.11$) and 3-years mortality (2.36±1.79 vs 2.39±1.80, $p = 0.94$) but higher aCC and mCC scores were associated with more frequent emergency department readmissions at 30-days (2.22±1.66 vs 2.82±1.78, $p = 0.01$). No relation was found between mCC and 30-days inward readmissions (2.30±1.69 vs 2.69±2.16, $p = 0.15$). The aCC analysis demonstrates similar results. In the AVD-DezIs score analysis, statistical significant association was noted between a lower functional score and the 1-year mortality (mdn=4.00; AIQ 9 to 0 vs mdn=10-; AIQ 18 to 0; $p = 0.00$). There was no statistical association between AVD-DezIs score and the 3-year mortality and readmissions.

Conclusion

In HF the patient functional status seem to relate with 1-year mortality but comorbidity scores relate more with the early emergency readmissions. However, new prognosis predictor scores are needed and patients should have individualized health care in order to prevent readmissions and delay death.

#1780 - Case Report

AN UNUSUAL CASE OF CARDIAC CACHEXIA

Francisco D'Orey, Bruno Sousa, Rosa Alves, Tiago Judas
Hospital Garcia de Horta, Almada, Portugal

Introduction

Cachexia and unexplained weight loss are common presentations in the Internal Medicine wards, frequently representing a diagnostic challenge for the internist

Case description

We present a case of a 78 year-old man with admitted to the ward for investigation of significant weight loss, weakness and severe hyponatremia (Sodium 118 mmol/L). He had a past medical history of a low grade colon adenoma and ischemic heart disease. He was not a smoker or a drinker. On examination he had mild peripheral oedema, was hypotensive and had signs of cachexia.

On the analytic investigation he was pancytopenic, had a marked elevation of the ESR, and markers of hepatic cholestasis. His chest

radiograph showed a left-sided pleural effusion. Pleural liquid had characteristics of a transudate with cytology negative for malignancy. The thoracic-abdominal-pelvic computerized tomography did not show and suspicious lesions. We collected a bone marrow biopsy which showed signs of medulla hypoplasia but did not show any evidence of hematopoietic malignancy. Due to high suspicion of occult malignancy he underwent a positron emission tomography (PET) which did not highlight any suspicious lesions for malignancy or systemic infection but did show signs of pericardial calcifications. In view of this he had an echocardiogram which confirmed a constrictive pericarditis. We increased diuretic therapy with good symptomatic results. He was discharged with from our ward with outpatient follow-up in Cardiology with the aim of pericardial decortication.

Discussion

This case represents a serious and longstanding manifestation of chronic pericarditis. Due to the significant picture of weight loss and cachexia, an occult malignancy seemed to be the most likely diagnostic hypothesis. With this case the authors demonstrate the significance of pursuing an exhaustive clinical investigation and keeping a high level of suspicion for less common causes of cachexia. In this challenging case the diagnosis turned out to be a syndrome of Cardiac Cachexia secondary to a constrictive pericarditis. Cardiac cachexia is a neuroendocrine and metabolic syndrome characterized by an anabolic-catabolic unbalance which leads to a state of weakness and cachexia.

#1781 - Case Report

A VERY DIFFERENT SEIZURE

Alexandra Coimbra, Jorge Prazeres, Raquel Rodrigues, Tânia Vassalo, Fernanda Mendes
Santa Maria Hospital, Lisbon, Portugal

Introduction

The syndrome of reversible posterior encephalopathy, is an entity that begins to be more present in the clinical spirit, which contributes to a rapid diagnosis, with direct implication in the reversibility of the signs and symptoms.

Case description

Woman, 40 years, leucodermic, autonomous, no relevant personal history. Paroxysmal episodes of palpitations and anxiety, one week later an episode of sudden alteration of the state of consciousness and mandibular contraction. In the emergency department: hypertension (205 / 110mmHg), tachycardia (130 beats per minute), apyrexia, without meningeal signs. During observation with four episodes of generalized seizures. In the post-critical period, on neurological examination: paresis of the left upper limb grade 4 (scale of Medical Research Council). Treated with anticonvulsant therapy (sodium valproate and levetiracetam) and antihypertensive (labetalol infusion). Laboratory evaluation without alterations (namely elevation of the acute phase parameters, thyroid function and toxic

research). Unchanged cranioencephalic computer tomography scan, electrocardiogram with sinus tachycardia, transthoracic echocardiogram with left ventricular hypertrophy, fundoscopy without alterations. Admitted in the Intensive Care Unit and after in the Medicine ward. Electroencephalogram showing non-specific encephalic dysfunction. Cranioencephalic magnetic resonance with changes suggestive of reversible posterior encephalopathy syndrome. Doppler ultrasound of the neck and transcranial vessels and posterior cervical computed tomography with angiography compatible with long and stenotic dissection of the left internal carotid artery and presence of mural thrombus without surgical indication. Study of secondary hypertension: elevation of catecholamines and metanephrines; scintigraphy with metaiodobenzylguanidine and renal ultrasound was normal. After tension control cranioencephalic magnetic was normal; catecholamines and metanephrines with a significant reduction of the dosed values; doppler ultrasound of the vessels of the neck with almost total recanalization. Patient is asymptomatic under anticonvulsive, antihypertensive and antiaggregating therapy.

Discussion

This entity presents nonspecific signs and symptoms, but when conjugated at any given moment, they should raise the suspicion. The imaging method of choice for documentation is magnetic resonance, sometimes unavailable. The spontaneous carotid dissection have some cases related with this syndrome.

#1790 - Abstract

PADUA SCORE: PREDICTOR OF THROMBOTIC RISK AND PROPHYLACTIC ANTICOAGULATION THERAPY IN HOSPITALIZED PATIENTS

Joao Figueira, Paulo Ramos, Rodrigo Vicente, Vasco Tiago, Fernando Aldomiro
Hospital Professor Doutor Fernando da Fonseca, Lisbon, Portugal

Background

Venous thromboembolism (VTE) is considered the leading cause of preventable death in hospitalized patients. Better prognosis depends on early stratification of thrombotic risk and prophylaxis. Guidelines recommend the use of prophylactic anticoagulation with low molecular weight heparin (LMWH) in hospitalized patients who have high risk of VTE. Padua score and IMPROVE bleeding risk score (IBRS) are important stratification tools to assess thrombotic and haemorrhagic risk in hospitalized patients. The use of these scores in reducing thrombotic events is not yet consensual. The objective of this study was to determine the applicability of the Padua and IBRS scores in the decision for prophylactic anticoagulation in patients hospitalized in an Internal Medicine department.

Methods

A retrospective analysis of the electronic case files of patients admitted to an Internal Medicine department between June

and December of 2017 was carried out, and the Padua and IBRS scores were applied. The anticoagulant therapy decision and VTE episodes were assessed.

Results

Initially 640 patients were included, but 4 patients were excluded for insufficient data and 145 for having undergone therapeutic anticoagulation, leaving a sample of 491 patients. In these, the haemorrhagic risk according to IBRS was evaluated; 118 were classified with high haemorrhagic risk and were excluded.

In the remaining 373 patients, the Padua score was applied; 130 were classified with low thrombotic risk and 243 with high thrombotic risk.

In the low thrombotic risk group, in 44.6% (58) prophylactic LMWH was used and 55.4% (72) did not undergo anticoagulation. In this group there was 1 thrombotic event in the anticoagulated group and no thrombotic event in the non-anticoagulated group. Amongst the 243 patients with high thrombotic risk, in 56.8% (138) prophylactic LMWH was used and 43.2% (105) did not undergo anticoagulation. In this group, there was 1 thrombotic event in the anticoagulated group and 2 thrombotic events in the non-anticoagulated group.

Conclusion

We found that the decision to initiate prophylactic anticoagulation was not concordant with that recommended by the Padua score in about 50% of the patients. The clinical decisions did not result in significant differences in the number of thrombotic events. More studies are needed to evaluate the applicability of risk scores in the decision for prophylactic anticoagulation for VTE prevention in hospitalized patients.

#1811 - Abstract

HYPERTENSION: COMPARING REAL-LIFE PATIENTS IN AN INTERNAL MEDICINE WARD TO THE EUROPEAN SOCIETY OF CARDIOLOGY ARTERIAL HYPERTENSION GUIDELINES

Ivo Barreiro, Rosário Silva, Patrícia Almeida, Amélia Pereira
Hospital Distrital da Figueira da Foz, EPE, Figueira Da Foz, Portugal

Background

Hypertension is a leading cause of the global burden of disease, doubling the risk of cardiovascular diseases.

New guidelines for the management of hypertension have been recently published by the European Society of Cardiology. It recommends that a stricter approach on lowering blood pressure (BP) levels is beneficial.

Report's objective was to evaluate if hospitalized patients with hypertension in our institution have adequate BP control at discharge, and if there were patient characteristics more prevalent in the non-controlled group.

Methods

A cross-sectional, observational study report regarding patients hospitalized in the Internal Medicine wards in our institution, with the diagnosis of hypertension.

Results

154 patients included in the study. 53.2% were male; 29.9% elderly and 63% very elderly. 16.2% of patients had ischemic coronary disease (ICD); 36.4% had diabetes; 42.2% had heart failure (HF); 31.8% had atrial fibrillation (AF); 76.6% had chronic kidney disease (CKD). 27.3% of patients were being treated with angiotensin-Converting Enzyme inhibitors (ACEi); 15.6% with Angiotensin Receptor Blockers (ARB); 23.4% with Calcium Channel Blockers (CCB); 68.2% with loop diuretics; 3.9% with thiazide-like diuretics; 11.7% with potassium-sparing diuretics; 36.4% with beta-blockers; 14.3% with single-pill combinations (3.9% with ACEi+CCB; 3.9% with ARB + CCB; 1.9% with ACEi+thiazide-like diuretics; 3.9% with ARB+thiazide-like diuretics; 0.6% with ACEi+CCB+thiazide-like diuretics); 3.9% with other drugs. 5.8% of patients were not taking any antihypertensive medication. Median systolic BP (SBP) values were 126.2 ± 15 mmHg; and 41.6% of patients had controlled SBP levels. Median diastolic BP (DBP) values were 67.2 ± 12 mmHg; 81.8% of patients had controlled DBP levels. 33.8% of patients had both SBP and DBP values controlled. 58.6% of patients with uncontrolled SBP were males. 31.1% were elderly, 58.9% were very elderly, 13.3% had ICD, 41.1% had diabetes, 36.7% had HF, 27.8% had AF; 74.4% had CKD. Out of patients with uncontrolled SBP, 62.2% had mean levels lower than target SBP levels. There were no statistically significant differences between patient characteristics or pharmacological therapy of patients with controlled or uncontrolled BP.

Conclusion

The amount of patients with controlled hypertension is subpar, mostly due to patients with BP profiles lower than target levels. There were no statistically significant differences between each subgroup regarding characteristics and pharmacological therapy

#1821 - Abstract

PREVALENCE OF VALVULAR HEART DISEASE IN A GUATEMALAN HOSPITAL

Luis Benjamin Godínez, Gabriel Antonio Rios, Juan Francisco Barrios, Gonzalo Díaz, Mervyn Steven Galindo
Instituto Guatemalteco de Seguridad Social, Guatemala, Guatemala

Background

The burden of valvular heart disease (VHD) in the Guatemalan population is scarcely known. The prevalence of valvular disease increases sharply with age, owing to the predominance of degenerative etiologies. Valvular heart disease remains common in developing countries, because of the prevalence of rheumatic heart diseases and by the increase in that of degenerative valve diseases. Aortic stenosis and mitral regurgitation are the two most common

types of valvular disease in industrialized countries. The study aim was to assess the prevalence of VHD in the Guatemalan population.

Methods

We perform an observational retrospective study of the in-hospital population of a teaching hospital from 2016 to march of 2019. We review the echocardiography reports from 1,209 patients in look for VHD and demographic data. The continuous variables were expressed with dispersion measures and the categorical variables in frequencies and percentages. Student's t test was used to compare quantitative data; The chi-square test was used to compare qualitative data.

Results

Of the 1,209 patients, 798 (66%) were men, the mean age was 62 years and the most common diagnosis were heart failure (33%) and ischemic heart disease (13%). VHD was present in 48% of the population and mitral insufficiency was the most common valvulopathy and was present in 29% of the patients and it was most prevalent in men (66%). Patients with mitral regurgitation had an average Left ventricular ejection fraction (LVEF) of 37% SD = 17 and patients without mitral regurgitation had an average LVEF of 50% SD=18% (P <0.001). In aortic insufficiency, the average LVEF was 40% SD=18 and without aortic insufficiency, the mean LVEF was 47% SD=18% (P <0.001). In the case of mitral stenosis, the average LVEF was 27% SD=10 and without mitral stenosis 51% SD=17% (P <0.001). In aortic stenosis, the average LVEF was 29% SD=13 and without aortic stenosis the LVEF was 51% SD = 17% (P <0.001).

Conclusion

VHD was common in our study population and was present in nearly 1 of every 2 patients. Mitral insufficiency was the most prevalent valvulopathy. VHD also has a profound effect in LVEF and patients with either insufficiency or stenosis had a much lower LEVF.

#1849 - Abstract

THE NEUTROPHIL/LYMPHOCYTE INDEX AND ITS CORRELATION WITH TROPONIN AND PATIENTS WITH ACUTE CORONARY SYNDROME WITH STEACS/SCEST

Astrid Paola Hernández, Gabriel Antonio Ríos

Instituto Guatemalteco de Seguridad Social IGSS, Guatemala, Guatemala

Background

The neutrophil/lymphocyte index is an inflammatory marker of prognostic value in cardiovascular diseases¹. It has been proposed as a new indicator of the systemic inflammatory state of the patient and has been correlated with the prognosis in different cardiovascular pathologies. The aim of this study was to correlate the neutrophil / lymphocyte index with troponin I levels in patients with acute myocardial infarction with and without ST segment elevation.

Methods

Transverse retrospective analytical study that included 55 patients, more than 18 years old, with a history of arterial hypertension, diabetes mellitus and ischemic heart disease and with STEACS/ SCEST who underwent levels of triponine I, Neutrophil Index/ Lymphocyte. These laboratories were performed in the first blood count performed after the onset of symptoms, after their arrival at the hospital. The Pearson correlation coefficient was used; Chi square was used for categorical variables and student t for numerical variables for the other variables.

Results

Of the 55 patients included, 47 (85%) were male and 36 (65%) patient with SCEST. Risk factors were 56% with hypertension, 29% with type II diabetes mellitus, 7% with ischemic heart disease and 7% with chronic smoking. Our analysis showed a null correlation between the neutrophil/Lymphocyte index and troponin I levels. Low correlation index with R2 of 0.0001.

Conclusion

Therefore, to affirm that this index can be included in prognostic scales of acute myocardial infarction can be debatable. In the subanalyses, no significant difference was found between neutrophil/ lymphocyte in patients with or without ST elevation.

#1853 - Medical Image

ACUTE LIMB ISCHAEMIA – AN IMAGE OF EXTENSIVE AORTIC-ILIAC THROMBOSIS

Filipa Taborda, Maria João Lobão

Hospital de Cascais, Cascais, Portugal

Clinical summary

A 65-year-old woman, with a history of ischaemic cardiopathy, dyslipidaemia and prior stroke, presents to the Emergency Room referring pain in both legs for 4 days. A doppler ultrasound excluded venous thrombosis and she was discharged. On the following day, she returns with mention of aggravated limb pain, now extended to inferior quadrants of the abdomen. It was then evident a low temperature of the limbs, though symmetric, with signs of hypoperfusion. During her stay, she refers paresthesias and skin become marbled, rapidly progressing to cyanosis, feet paralysis and absence of any sensation. A computed tomography angiography showed an extensive aortic-iliac thrombosis with irreversible acute limb ischaemia. The patient recused revascularization surgery, given the risks, dying in hours.

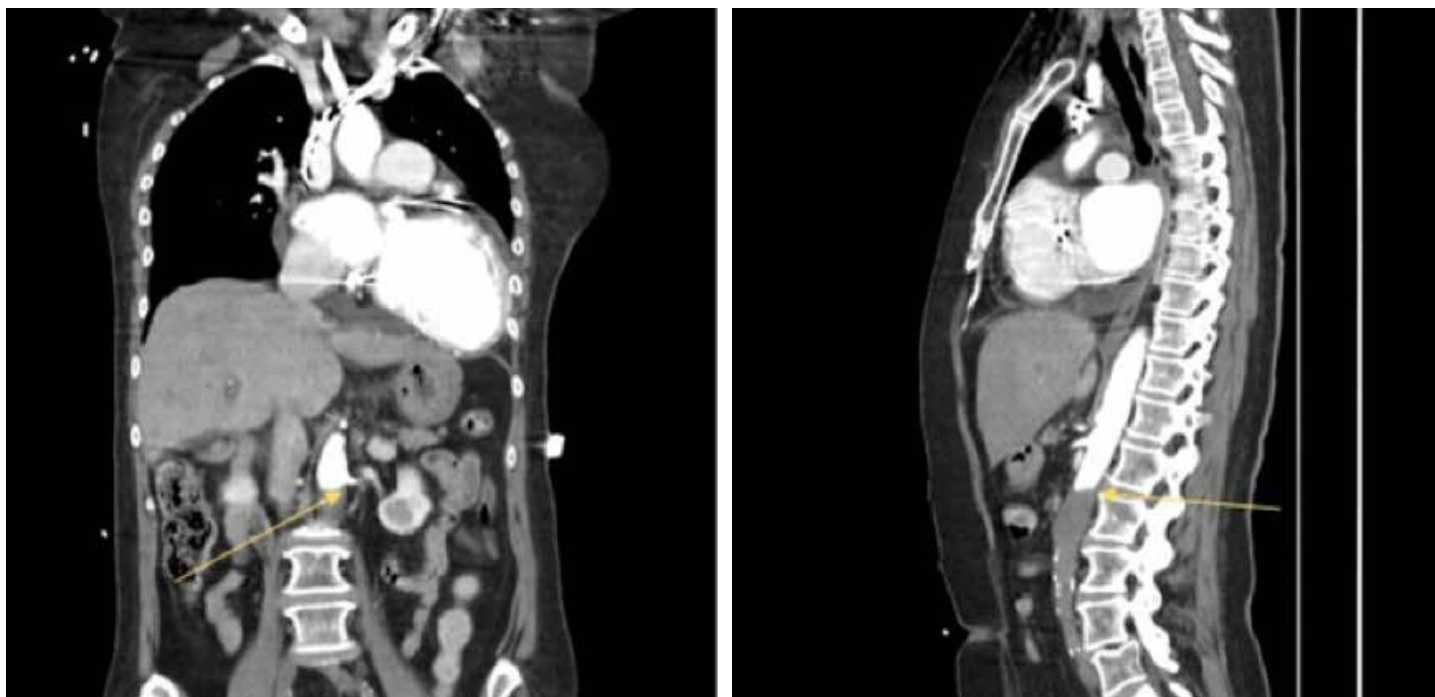


Figure #1853.

#1859 - Case Report

DELAYED PULMONARY EMBOLISM DIAGNOSIS DUE TO A “HISTORY” OF CONTRAST ALLERGY

José João Martins, Ana Margarida Mosca, David Garcia, Rosário Araújo, António Oliveira E Silva
Hospital de Braga, Braga, Portugal

Introduction

Approximately 112 out of 100,000 people will have an acute pulmonary embolism (PE) in their life, making it a common disease. However, the clinical presentation is very unspecific and often leads to delayed recognition. The ideal diagnosis tool is a contrast-enhanced computed tomography (CT) of the lungs. The contrast used has an incidence rate of 0.15 to 0.7 percent of adverse reactions with only a small proportion of those being fatal.

Case description

The patient is a 70-year-old male, independent, with multiple risk factors for thrombotic events and a history of previous venous thrombosis. He presented to the emergency department with a dyspnea of acute onset accompanied by pain in the right hemithorax, he denied any other symptoms. His physical examination was unremarkable. Analytically a type 1 respiratory failure and an elevated C-reactive protein were present. Given the high pre-test likelihood of PE the next step would be an imaging study, however venous ultrasonography was unavailable and the patient told a story about feeling very unwell when around 30 years he received a contrast injection and had to take intravenous medications. Therefore, it was opted to perform a CT scan of the lungs without contrast. The scan revealed only chronic abnormalities such as emphysema and fibrosis. The patient was

then admitted to the medical ward on with a temporary diagnosis of tracheobronchitis and started on a course of doxycycline. Given the lack of recovery a few days later, a contrast-enhanced CT scan of the lungs with pre-medication to reduce the chances of allergy was performed. The exam showed multiple perfusion deficits on the territory of the median lobar artery of the right lung confirming the existence of PE. The patient was started on therapeutic anticoagulation with improvement in his clinical status, he was discharged a few days later with oxygen supplementation which he eventually stopped because it was no longer needed.

Discussion

A clinical case that demonstrates a common issue: non-documented allergies. In the case of our patient it is impossible to measure the impact that the delayed diagnosis of PE had on his prognosis. Had the diagnosis happened sooner the patient would have had a shorter hospital stay and perhaps more of his lung functional capacity could have been rescued. The reverse is also true, the patient could have had an anaphylactic shock with the contrast administration. We hope that this clinical case serves as a reminder of the importance of documenting allergies,

#1898 - Case Report

HEMOPTYSIS AS A RARE AND LIFE-THREATENING PRESENTATION

Daniel Duarte, João Araújo, Ricardo Cordeiro, Carina Rôlo Silvestre, Aurora Bragança, António Domingos
Centro Hospitalar do Oeste - Torres Vedras, Torres Vedras, Portugal

Introduction

Hemoptysis is a manifestation of numerous diseases, including airway diseases, infection, trauma, coagulation disorder, rheumatologic and pulmonary vascular diseases.

Rupture of thoracic aortic aneurysm (TAA) usual present with severe chest or back pain. However, massive hemoptysis can be a rare and life-threatening presenting symptom due to aorto-bronchopulmonary fistula.

We present a case of a patient with rupture of TAA and aorto-bronchopulmonary fistula who presented with back pain and hemoptysis.

Case description

A 85-year-old man, salesman, with personal history of pulmonary tuberculosis in childhood and benign prostatic hyperplasia.

Presented to the ER with moderate to large hemoptysis and back pain for a few hours. Physical examination revealed hypotension, hypoxemia and lung auscultation with decrease of breath sounds in the left side.

Blood tests showed anemia with no other alterations. Chest radiography revealed a widened mediastinum and pleural effusion. CT scan was performed and showed TAA with filiform rupture and large hematoma (8 cm), moderate hemothorax and small pneumothorax.

Aminocaproic acid was prescribed and the patient was promptly transferred to Vascular Surgery. Endovascular aortic repair with stent-graft was performed in the operating room. Postoperative period was complicated by hemothorax, small pneumothorax and respiratory infection.

Flexible bronchoscopy was performed and revealed blood clots without active bleeding or presence of bronchial fistula.

Patient was discharged after 57 days without symptomatology and integrated into a pulmonary rehabilitation program.

Discussion

In the literature there are few cases of TAA presenting with hemoptysis. The most frequent symptom of TAA rupture is chest or back pain, although acute and massive hemoptysis can be present. Aorto-bronchopulmonary fistulas are the main cause of hemoptysis and constitutes a surgical emergency. Other symptoms such cough, dyspnea and wheezing can be present.

Chest radiography show a widened mediastinum, enlargement of TAA or pleural effusion (hemothorax). CT scan is the optimal imaging test to detect and measure TAA and identify rupture.

Endovascular aortic repair of the TAA is characterized by the placing of a stent-graft and is now the preferred technique for treatment. Comparing to the open thoracic aorta surgery, endovascular aortic repair is a less invasive approach.

In our case an early diagnosis and treatment was essential given the severity and risk of death of the patient.

#1918 - Medical Image

CYCLING WITH LERICHE SYNDROME

Rui Osório, Ana Sofia Moreira, Ramiro Sá Lopes, Teresa Salero, Yessica Costa

Centro Hospitalar do Algarve - Hospital de Faro, Faro, Portugal

Clinical summary

Leriche's syndrome is a thrombotic occlusion of the abdominal aorta and/or iliac arteries, a subtype of peripheral disease and associated with increased cardiovascular risk. An active 55-year-old male with history of alcoholism, smoking, arterial hypertension and poorly controlled heart failure, with no prior complains, was brought to the ER in cardiac arrest. After reversal, the patient was admitted to the intensive care unit. Due to jaundice and elevated hepatic enzymes, a contrast-enhanced CT was preformed showing complete occlusion of the abdominal aorta distal to the origin of the right renal artery without opacification of the left renal artery. The important network of collateral vessel allowed him to remain asymptomatic, riding his bicycle every day to work, prior to this event.

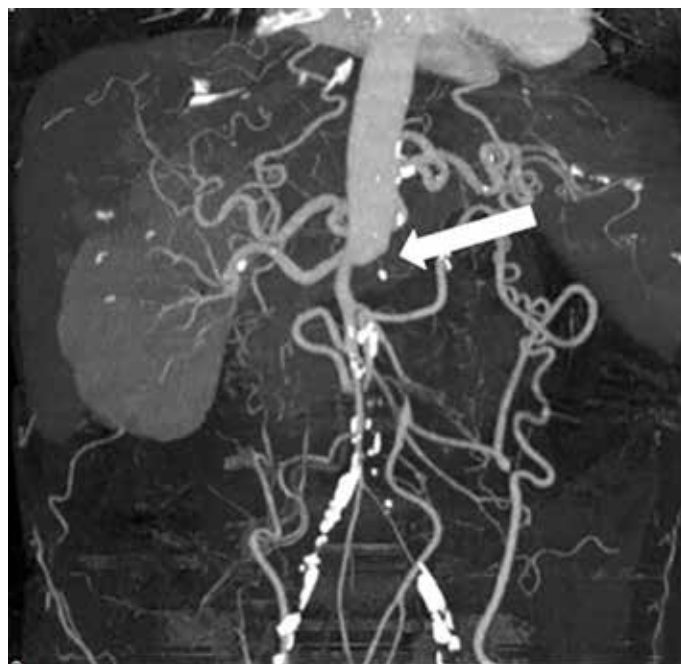

Figure #1918. Occluded aorta with collateral circulation.

#1925 - Abstract

VENOUS THROMBOEMBOLISM RISK ASSESSMENT IN MEDICAL HOSPITALIZED PATIENTS AND EVALUATION OF OUTCOMES: A PROSPECTIVE, SINGLE CENTER ANALYSIS

Sara Garez Gomes, João Gramaça, Teresinha Ponte, Filomena Carneiro, Fátima Campante

Centro Hospitalar Barreiro Montijo, Barreiro, Portugal

Background

More than half of in-hospital medical patients have increased venous thromboembolic risk, which may be significantly reduced

with primary thromboprophylaxis. There are studied risk scores, among them the Padua Prediction Score for Risk of Venous Thromboembolism. We also had in consideration an increased bleeding risk in patients with thrombocytopenia ($<50,000/\mu\text{L}$), active gastroduodenal ulcer or a bleeding event in the previous 3 months.

Methods

This is a non-interventional prospective analysis of 32 hospitalized medical patients evaluated in one given day, applying the Padua score and recording 45-day all-cause mortality, thromboembolic and bleeding events, emergency room (ER) admission and second hospitalization. We excluded patients under therapeutic hypocoagulation.

Results

Of the 32 patients in the overall population, 7 were doing therapeutic hypocoagulation. In the remaining intention-to-prevent (ITP) population 64% (14 patients) had a Padua score ≥ 4 ; in this group there were 5 (35%) not doing primary thromboprophylaxis, 2 with no discriminated reasons and 3 (12%) due to increased bleeding risk. In this small analyzed sample, there was a 45-day all-cause mortality rate of 12.5% in the overall population, but of just 4% (1 fatality) in the ITP population. There were no thrombotic or bleeding events in the 45-day span; the 45-day all-cause ER admission in the ITP population was 28%, even though there was only 1 instance of new hospitalization in this group (4%), of a unrelated cause (pneumonia). The recorded fatality was of a patient with a risk score of 5 in which the enoxaparin dosage was reduced to 20 mg id due to renal function; alas there was no recorded cause of death.

Conclusion

The authors think in order to infer statistically significant data we need to increase the analyzed sample, possibly involving other medical centers, as well as increasing the follow-up time. Interestingly we observed that all the 45-day ER admissions were patients with a score ≥ 4 , with a median of 5 and average of 5.29; a 2012 Harvard analysis using this score found no relationship between administration of anticoagulation and reduced rate of VTE or mortality, however a Padua ≥ 4 was associated with increased all-cause mortality.

#1928 - Case Report

OVERLAPPING HEPATORENAL AND CARDIORENAL SYNDROMES: TWO CLINICAL ENTITIES OR ONE COMPLEX SYNDROME

Dina Rodriguez Pita, Salvador Morais Sarmiento, Andreia Amaral, Hugo Inácio, Sofia Mateus, Daniela Marto, Ana Brito, Miguel Leite, Catarina Espírito Santo, Catarina Salvado
Centro Hospitalar Universitário Lisboa Central, Lisboa, Portugal

Introduction

Hepatorenal (HRS) and cardiorenal syndrome (CRS) are both severe conditions with common pathogenic features.

HRS is a complication of chronic liver disease or fulminant hepatitis, where splanchnic vasodilation leads to decreased glomerular function rate (GFR).

CRS is a condition in which damage to one organ (heart or kidney) can lead to acute or chronic dysfunction of the other, resulting in reduced cardiac output, elevation of central venous pressure, and renal dysfunction.

Both syndromes result in arterial under filling and accumulation of fluid in the extracellular and extravascular spaces. The reduced effective arterial blood volume promotes sodium and water retention by activating the sympathetic nervous system as well as the renin-angiotensin-aldosterone and vasopressin systems.

Given their intertwined pathogenic mechanisms, the treatment of one may lead to the benefit of the other. For instance the administration of human albumin with vasoconstrictors, used to treat HRS, has a positive impact also on the cardiorenal regulation systems. The authors describe a case of overlapping HRS and CRS where this approach was crucial to treatment success.

Case description

A 53-year-old man with alcoholic liver disease presented with exertional dyspnoea, orthopnoea and abdominal distention. Physical examination showed jugular vein distension, decreased air movement over the lower third of both lung fields, abdominal distension, flank dullness, and peripheral edema.

Laboratory results revealed factor V 32.5%, aspartate transaminase 1566 U/L, alanine transaminase 1727 U/L, total bilirubin 3.68 mg/dl, and prothrombin time 2.5, GFR: 29 mL/min/1.73, brain natriuretic peptide level 1706 pg/mL; and sero-ascitic albumin gradient >1.1 g/dl. Imaging revealed ascites and portal hypertension.

Clinical status kept worsening despite HRS standard treatment; but improvement was achieved after inotropic intervention.

Discussion

New insights into the pathophysiological mechanisms behind hepatorenal syndrome have challenged the conventional model of liver-kidney disease, supporting the heart as an important mediator of the untoward renal effects. In this case, poor clinical response after conventional therapy of HRS and improvement after introduction of inotropic therapy (traditionally reserved for CRS) suggests cardiac dysfunction as a relevant trigger or perpetrator of HRS.

Overlapping HRS and CRS is probably best considered as one complex clinical syndrome rather than two separate entities.

#1930 - Abstract

PULMONARY EMBOLISM: AN APPROACH IN INTERMEDIATE CARE UNIT

Rui Osório, Margarida Viana Coelho, Domingos Sousa, Ramiro Sá Lopes, Sílvia Castro, Cristina Granja

Centro Hospitalar do Algarve - Hospital de Faro, Faro, Portugal

Background

Although all the cardiovascular diagnosis and treatment advances the morbidity and mortality of pulmonary embolism (PE) remains high. Annual incidence of venous thromboembolism (VTE) is around 23-69 cases per 10 000 population, the PE represent approximately one-third of the VTE cases. It is estimated that around 10% of patients with acute PE die during the first 1-3 months, 1% of patients admitted to hospital die of acute PE and 10% of all hospital deaths are PE-related.

Methods

A retrospective observational study was made with patients admitted in the intermediate care unit (IntCU) during the year 2018. The patients were characterized by gender, age, time of admission in the ICU and hospital, symptoms, severity index (PESI, hypotension (Systolic blood pressure < 90 mmHg), elevated troponin and natriuretic peptide (BNP), echocardiography changes), thrombolysis, destiny at discharge, outcome and mortality rate.

Results

In one year, 16 patients were admitted in the IntCU, 50% male and 50% females, the mean age was 62,8 years, the mean average time in the IntCU was 5,3 days and in the hospital was 17,9 days. The main described symptoms were shortness of breath (40%), chest pain (24%), fatigue and syncope (12% each). Most patients admitted in the IntCU came from de emergency department (56.25%), and most of them were transferred to the Internal Medicine ward to continue treatment and investigation. The PESI index average was 132 (representing class V, very high risk), 25% presented hypotension on admission, 56.3% presented an increased BNP, 81.3% increased Troponin I and 81.3% presented echocardiographic changes. 55,6% of patients were submitted to thrombolysis with rt-PA (one didn't complete the perfusion due to hemorrhagic dyskinesia). All the very high-risk patient (n=5) did thrombolysis and 66.7% of the intermedian high risk (n=4 of 6) patient also were submitted to thrombolysis. The mortality rate was 6.25%.

Conclusion

Severe forms of acute PE have 10 to 24.5% of mortality (in 30 days) and close monitoring and possible thrombolysis may be advice. Thrombolysis resolves thromboembolic obstruction and reduces pulmonary artery pressure and resistance increasing cardiac output. In fact, up to 92% of patients appear to responded favorably to thrombolysis. The severe forms of acute PE seem to benefit of thrombolysis, and such treatment and close monitoring should be done in an IntICU environment.

#1933 - Medical Image

ABDOMINAL AORTIC ANEURYSM – AN AWFUL SURPRISE

Filipa Botelho De Viveiros Cardoso, Teresa Souto Moura

Centro Hospitalar Universitário Lisboa Central, Lisboa, Portugal

Clinical summary

Abdominal aortic aneurysm (AAA), is relatively common and has high mortality (tenth most common cause of death in the Western world). Risk factors are: male, age (>50 years), smoking, hypertension and atherosclerotic vascular disease. Computer angiography is the gold standard for diagnosis and immediate surgical repair indicated for aneurysms with symptoms or expanding >0.5 cm in 6 months.

I hereby present an infrarenal AAA, with 10 cm, which was contained in the retroperitoneum and therefore poorly symptomatic. When it ruptured the patient's abdomen increased suddenly and had livor. Despite fast diagnosis, imaging and surgery, the hemodynamic instability prevailed and survive only 3 days.

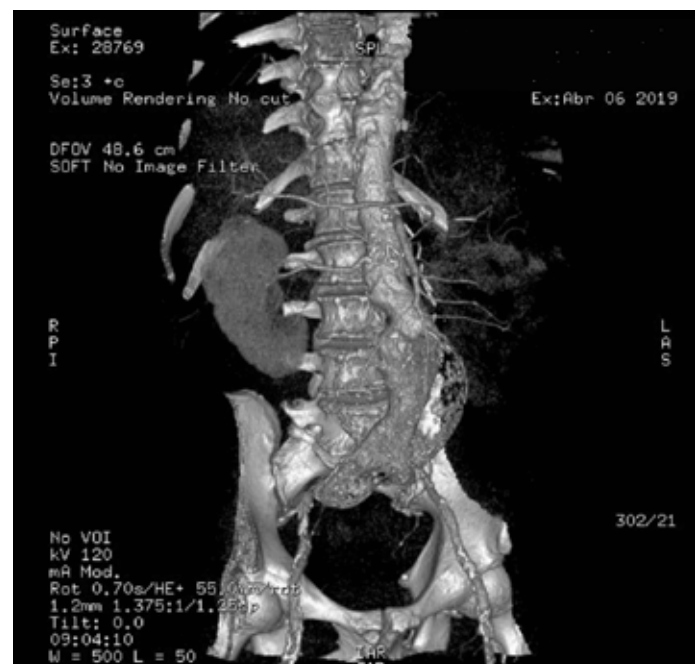

Figure #1933.

#1937 - Case Report

ARRITMOGENIC POTENTIAL OF MACROLIDS - A CLINICAL CASE

Sónia Coelho¹, Ana Vera Marinho², Marisa Miranda², José Luiz Luzio², Paulo Martins²

¹ Centro Hospitalar Universitário Cova da Beira, Covilhã, Portugal

² Centro Hospitalar e Universitário de Coimbra, Coimbra, Portugal

Introduction

Acquired long QT syndrome (LQTS) may complicate treatment with some antibiotics, such as macrolides, involving the risk of torsades de pointes.

Case description

Female, 33 years old, smoker. Admitted with community acquired pneumonia (CAP), requiring invasive mechanical ventilation and aminergic support. Intravenously azithromycin and amoxicillin/clavulanic acid (amoxiclav) were initiated. On the 6th day of hospitalization at the Intensive Care Unit, continuous electrical monitoring showed prolongation of the QT interval, confirmed by electrocardiogram (ECG). This condition evolved with torsades de pointes, followed by cardiac arrest in ventricular fibrillation, recovering spontaneous circulation after immediate defibrillation. Serum potassium, magnesium, calcium and troponin values were normal. No changes were observed in transthoracic echocardiogram. She suffered two more cardiac arrest in a shockable rhythm, with successful defibrillation. Cardiac catheterization showed post-capillary pulmonary hypertension, without coronary disease. Pulmonary embolism was excluded by thoracic angiotomography. Diagnosis: acquired LQTS, secondary to azithromycin. A temporary pacemaker was implanted, "protecting" the progressive decrease of the QT interval, being withdrawn days later, with a normal ECG. Her respiration improved gradually. Cardiac magnetic resonance revealed no changes. Genetic study was negative for channelopathies. At the secondary prevention level she implanted a transvenous implantable cardioverter-defibrillator.

Discussion

The arrhythmogenic risk of some groups of antibiotics (quinolones and macrolides), including acquired LQTS, is known. According to guidelines, azithromycin is commonly used, associated with amoxiclav for the treatment of CAP. This clinical case illustrates the cardiovascular risk of this option. The majority of arrhythmias related to the use of quinolones and macrolides occurred in patients with risk factors for QT prolongation. In the present case, the only risk factor is the female gender, which in the literature review seems to be more affected. Therefore, the choice of antibiotic should respect a careful analysis of the existence of risk factors for QT prolongation, including the combination of therapies with arrhythmogenic potential. In patients at high risk, we should consider other options or electrocardiographic monitoring.

#1943 - Case Report

THINKING OUTSIDE THE BOX: GRADE III ARTERIAL HYPERTENSION IN ELDERLY PATIENT

Cristiana Drăganescu¹, Octavian Zara¹, Cornelia Voiculescu¹, Alice Balaceanu¹, Ion Dina¹, Ruxandra Jurcut²

¹ Hospital Saint John, Bucharest, Romania

² Fundeni Hospital, Expert Center for Rare Cardiovascular Genetic Diseases, Bucharest, Romania

Introduction

High blood pressure in elderly patient involves etiological and treatment particularities. Associated with asymptomatic or

minimally symptomatic genetic diseases, it requires complex investigations. Obstructive hypertrophic cardiomyopathy may occur in the context of both metabolic and neuromuscular genetic diseases as well as chromosomal dysfunctions. Severe form is rarely associated with grade III hypertension, especially in the elderly patient without renal disease.

Case description

A 72-year-old patient is referred to an Internal Medicine Department to investigate an elevated blood pressure above 200 mmHg. The patient was diagnosed with blepharospasm several years ago and treated with botulinum toxin. Family history reveals neurological and renal disorders in first degree relatives.

Patient had ambulatory treatment with beta blocker, conversion enzyme inhibitor and statin. The electrocardiogram showed left ventricular hypertrophy. Cardiac ultrasound revealed severe obstructive hypertrophic cardiomyopathy. Genetic testing and additional investigations have diagnosed multiple impairments in an elderly patient with minimal symptoms.

Discussion

The elderly patient with grade III hypertension and inherited cardiac and neurological disorder is a challenge regarding the diagnostic and treatment.

#1967 - Case Report

DONEPEZIL AS A CAUSE OF CARADIOGENIC SYNCOPE - ELDERLY HEAVEN OR HELL?

Cátia Fava Gaspar, Helena Greenfield, Liliana Carneiro
Hospital Pedro Hispano, Matosinhos, Portugal

Introduction

Due to population ageing, it has become more common in daily practice to find elderly patients medicated with anti-dementia drugs, Donepezil being a highly prescribed drug, but not free of adverse effects.

Case description

The authors present the case of an 80-year-old woman, with a history of hypertension, dyslipidaemia, obesity and incipient dementia medicated with Donepezil 10 mg, once daily. The patient was admitted in the cardiology ward of the Internal Medicine department, for the evaluation of two episodes of syncope of undetermined aetiology. Initially the syncopal episodes were assumed to be in the context of an acute myocardial infarction without ST segment elevation since the patient had cardiovascular risk factors and the high sensitivity troponin raised to a maximum of 2345 ng/L. To confirm that presumptive diagnosis, a transthoracic echocardiogram was performed, and it showed a slightly decreased left ventricular systolic function associated with apical akinesia, suggestive of Takotsubo stress induced cardiomyopathy. A cardiac magnetic resonance confirmed the diagnosis. Upon review of the patient's history, a QTc prolongation

was found on the patient's admission electrocardiogram (ECG), with an initial QTc duration of 522 milliseconds. The patient had no dysrhythmias on cardiac monitoring. A confirmatory ECG confirmed long QT syndrome. An exhaustive review of patient medication was performed, and Donepezil was the only possible causative drug identified. Cessation of Donepezil resulted in normalisation of the QT interval (417 milliseconds). The patient remained asymptomatic, with no recurrence of dizziness or syncope.

Discussion

The importance of preserving cognition and global function and of delaying dementia onset and progression is evident to all, however it is important to recall that drugs are not free of side effects. In the case of Donepezil, and other anti-dementia agents, the risk of QT prolongation and subsequent cardiac arrhythmias is known and an initial ECG should be performed before initiating therapy. This case illustrates a long-term side effect, reminding us of the importance of taking a thorough drug history while considering potential drug toxicity/interactions as part of the comprehensive geriatric assessment

#1971 - Abstract

"THE GREAT MASQUERADER": A RETROSPECTIVE OBSERVATIONAL STUDY ON ACUTE PULMONARY EMBOLISM ON A SECONDARY HOSPITAL

Filipe Cunha Santos, João Rodrigues, António Barbosa, Joana Caires, Maria João Baldo, João Correia
ULS Guarda, Guarda, Portugal

Background

Acute pulmonary embolism (PE) is the third leading cause of cardiovascular disease and it presents on a wide range of severity. This study aims to investigate the clinical, laboratorial and tomographic features of patients with PE admitted to a secondary hospital.

Methods

We conducted a retrospective observational study at a secondary hospital and reviewed all patients hospitalised in 2018 with a primary or secondary diagnosis of PE from ICD10.

We excluded patients younger than 18 years old, deceased in the first 24h, transferred to another hospital, not admitted and those with missing data.

Clinical, laboratorial, and tomographic data was collected and statistical analysis performed using IBM® SPSS® Statistics 25.0.

Results

We studied 59 patients, with a mean age of 75.6±16.1, from which 54.2% were males.

The most frequent symptoms at presentation were dyspnea (64.9%), chest pain (35.1%), fatigue (40.4%) and fever (22.8%).

Hypoxia was present in 60.3% patients, tachycardia in 44.1%, tachypnea in 33.9%, hypertension in 23.7%, hypotension in 13.6% and 5.1% were admitted to the intensive care unit. 49.2% had a respiratory tract infection. Mean Wells score was 3.2±2.5, with the most frequent being 1.5. Mean PESI was 130.3±43.9. Most frequent comorbidities were hypertension in 55.9%, type 2 diabetes in 27.1%, dyslipidemia in 27.1% and heart failure in 25.4%. The most frequent risk factors were immobilization for more than 48h in the last month in 30.5% and previous hospitalization in 27.1%. Mortality rate was 13.6%, from which 37.5% were in-hospital.

We found a linear correlation between LDH and hospitalization days ($p<0.001$), as well as bilateral PE ($p0.052$), but not its extension. There was a correlation between BNP and hospitalisation days ($p0.038$). There was a statistically significant difference between the color of the Manchester triage and the extension of PE ($p0.025$). No difference was found with hospitalisation days.

We found no association between the PESI or Wells score and the tomographic features or days of hospitalisation.

No difference was found between vital signs, hemoglobin, creatinine at presentation and tomographic features.

We found no difference between age or tomographic features and days of hospitalisation.

Conclusion

There seems to exist an association between LDH, BNP and hospitalization days. We found a correlation between LDH and the color of the Manchester triage with tomographic features. No other associations were found.

#1977 - Abstract

MANAGEMENT OF ATRIAL FIBRILLATION IN PATIENTS WITH AN ACTIVE CANCER: A RETROSPECTIVE STUDY

Alda Tavares, Mário Bibi, Sara Moreira Pinto, Rute Morais Ferreira, Cristina Rosário

Hospital Pedro Hispano, Oporto, Portugal

Background

Management of Atrial fibrillation (AF) in patients (pts) with active cancer can be challenging. Limited data are available because cancer pts were frequently excluded. The aim of this study was to describe clinical characteristics and prescription of anticoagulants (ACs) in pts with AF and with/without active cancer.

Methods

A retrospective study was conducted, among pts admitted with AF in an Internal Medicine Ward, between April of 2014 and June of 2015. Epidemiological and clinical data were analysed according to presence/absence of active cancer (diagnosis or any anticancer treatment in last 6 months, metastatic or recurrent disease). Statistical analysis was performed with SPSS® software v25, and values of $p<0,05$ were considered statistically significant.

Results

Among 214 pts admitted, 16 had active cancer: 9 pts had the diagnosis made and 8 were submitted to anticancer therapy in the last 6 months, 5 had metastatic disease and 4 had a recurrence. The most common sites of cancer were breast (25,0%), gastrointestinal (25,0%) and lung (18,8%). The median time between the diagnosis of cancer and admission was 4 months (range: 0-82).

An apparently higher rate of male sex and younger people occurred in cancer pts, without significant difference. The rate of cardiovascular risk factors (CVRF), heart disease, previous stroke or thromboembolic event was higher in non-active cancer pts, without significant difference. Similar CHA₂DS₂-VASc and HAS-BLED scores rates were obtained in the two groups. New-onset AF was diagnosed 95 pts (44,4%), of these 6 had cancer (37,5%). Death during hospitalization occurred in 23 pts, with a higher rate in cancer pts (p=0,018).

To the date of discharge, ACs was prescribed to 5 cancer pts (45,5%) and 112 non-cancer pts (62,2%). Antagonists of vitamin K were prescribed in 82 pts, direct oral anticoagulants in 30 and low-molecular-weight heparin in 5. No significant differences were found concerning class ACs prescription and contra-indications in the 2 groups. Contraindication to ACs was identified in 6 cancer pts (anaemia, recent major surgery/stroke, haemorrhage, pericardial effusion and pericarditis).

Conclusion

Face to non-cancer pts, active cancer pts have similar rate of CVRF and comorbidities, but they have a higher mortality. They appear to be similarly treated with anticoagulant therapy. Larger studies on the optimal anticoagulation strategy of cancer patients with AF are needed.

#1995 - Case Report

LEFT VENTRICULAR THROMBUS CHALLENGE: A CASE REPORT

Dina Rochate^{1,2}, Svitlana Hhihoryan¹, Maria José Grade¹, Luísa Arez¹

¹ Centro Hospitalar Universitário do Algarve – Unidade de Portimão, Portimão, Portugal

² Hospital do Divino Espírito Santo de Ponta Delgada, Ponta Delgada, Portugal

Introduction

Left ventricular thrombus (LVT) is a potential cause of thromboembolic complications such as stroke. The overall prevalence in the general population is low. The prototypical substrate is a recent anterior myocardial infarction (MI) with an akinetic apex. Few cases after an old MI are described. Anticoagulant therapy with Warfarine is the preferred therapy.

Case description

Male, 59 years old, caucasian with history of MI 10 years before, heart failure (CHF) and hypertension, medicated. Previously

asymptomatic when initiates fatigue with progressive aggravation, edema of the lower limbs (LL), scrotum, abdomen and decrease of the urinary output. On physical examination the patient was hypotensive (BP 99/76 mmHg), with a systolic murmur in the mitral area, pulmonary auscultation with bilateral crackling, edema of the abdominal wall, scrotum and LL. Analytically with anemia (Hb 13.7 mg/dl) and pro-BNP 6471 pg/ml. Infra-ST V6 and T wave inversion in the precordial leads already known in electrocardiogram. He was hospitalized for decompensated CHF, went on diuretic reinforcement with a good edema and respiratory response, and performed an transthoracic echocardiogram (TE) showing severely dilated left ventricle (LV) with severely depressed global systolic function, FEj 17% and diffuse hypokinesia. In the apical level a hyperechogenic and heterogenic image, discretely movable, suggestive of thrombus. Contrast-TE confirmed severely diminished global systolic function (FEj 13%) and apical thrombus with dimensions of 30x25mm. The case was discussed with cardiology and anticoagulation in therapeutic dose with enoxaparin was initiated and switch for oral anticoagulation with Warfarin for life. 13 days later the patient developed right hemiplegia, dysarthria with deviation of the labial commissure and worsening of consciousness. An Angio-CT was performed which excluded hemorrhagic lesions and no indication for thrombectomy. One day after, with no neurological deficits, it was assumed Transient Ischemic Attack in a context of low cardiac output.

Discussion

The diagnosis of intracardiac thrombi remains clinically relevant, with associated risks of systemic embolization. There are uncertainties in the management of LVT as data on the use of non-vitamin K antagonist anticoagulants is limited, and their use instead of warfarin cannot be recommended. This case report shows the embolic risk even under classic anticoagulant, highlighting the need for more studies with other drugs.

#1997 - Medical Image

MASSIVE CARDIOMEGLY IN A PATIENT WITH HEART FAILURE

Adriano Pacheco Mendes, André Gonçalves Mendes, Ruben Raimundo, Isabel Lavadinho, Isabel Soles

Unidade Local de Saúde do Norte Alentejano, Portalegre, Portugal

Clinical summary

We report a case of a 74-year-old woman, previously independent in activities of daily living and with a established diagnosis of heart, that was admitted in the emergency department complaining of severe leg edema, persistent dyspnea at rest, exercise intolerance and paroxysmal nocturnal dyspnea aggravated over the past 4 months. According to her personal and medical history, she had been not attending to her medical appointments and, therefore, the close heart failure monitoring that was demanded. A massive cardiomegaly was seen on chest radiograph and on chest ct scan (cardiothoracic ratio 0.85). There was no evidence of pleural

effusion and echocardiography revealed an extreme extreme dilation of both atria and severe mitral and tricuspid regurgitation.

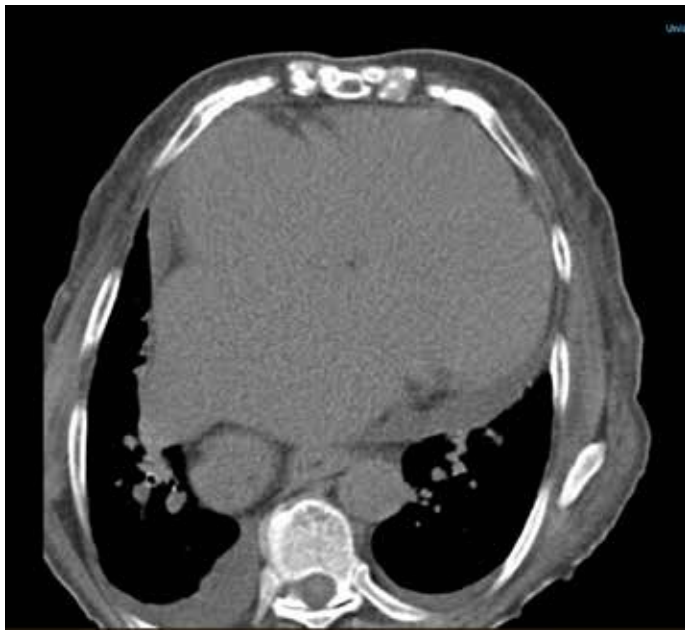


Figure #1997. Massive cardiac enlargement due to heart failure.

#2008 - Case Report

INVERTED TAKOTSUBO CARDIOMYOPATHY

Diana Pires Fernandes¹, Miguel Tavares², Andrés Carrascal¹

¹ Unidade Local de Saúde do Nordeste, Bragança, Portugal

² Centro Hospitalar Universitário do Porto, Porto, Portugal

Introduction

Takotsubo syndrome is a stress-related cardiomyopathy in which changes in the segmental kinetics are capable of causing ventricular dysfunction. In this clinically reversible pathology that is more common in postmenopausal women, although the physiology is not fully understood, it appears to exist changes in the adrenergic receptors and in the local/serum levels of catecholamines. Inverted Takotsubo is a rare variant in which the pattern of kinetic changes is antagonistic to the more common alterations of basal hyperkinesia and apical ballooning.

Case description

We present a 60-year-old woman with a history of hypothyroidism, smoking, and severe emphysema associated with alpha 1 anti-trypsin deficiency.

Activated prehospital emergency due to sudden onset of dyspnea and syncope, so she was intubated by deterioration of consciousness, agonal respiration with severe metabolic/respiratory acidosis, and atrial flutter that reverted spontaneously to sinus rhythm. In the emergency room, given the clinic of acute cardiac insufficiency and a slight elevation of biomarkers, tachyarrhythmia was assumed as the precipitating event after exclusion of ionic disturbances, acute cranioencephalic event and pulmonary thromboembolism. The patient was admitted for intensive care.

In the control electrocardiogram, T-wave inversion was verified in the anterolateral leads and an echocardiographic evaluation was performed, limited to the subcostal plane due to severe emphysema. The findings of moderate left ventricular dysfunction with akinesia of the medial portions of all walls and preservation of apical contractility suggested an inverted Takotsubo pattern. The patient underwent cardiac catheterization, which confirmed the kinetic changes and absence of significant coronary disease, and was extubated without intercurrents at 48 hours, when the context of labor conflict and anxious personality was reached. Pheochromocytoma was excluded and beta-blocker initiation was performed with good response.

Discussion

A picture of acute cardiac failure in which elevation of biomarkers and electrocardiographic changes may be present, makes stress cardiomyopathy mimic other conditions, particularly acute myocardial infarction. Thus, the observation of alterations in segmental contractility by echocardiography allows this distinction to be made. If, until recently, the diagnostic criteria involved exclusion of coronary disease, recent records show that it can coexist but it isn't responsible for the ventricular changes

#2015 - Medical Image

A RARE ECG PATTERN ASSOCIATED WITH MYOCARDIAL INFARCTION

Luciana Faria¹, João Caiano Gil², Adriana Alves²

¹ Centro Hospitalar Póvoa de Varzim/Vila do Conde, Vila Do Conde, Portugal

² Unidade Local de Saúde de Matosinhos, Matosinhos, Portugal

Clinical summary

A 68-year-old male presented to the emergency department complaining of anterior chest pain for 2 hours. Initial ECG (panel A) showed upsloping ST depression and tall T waves in leads V1-V5, and an initial troponin I test was normal. An ECG 10 minutes later, revealed ST elevation (panel B). Emergent coronary angiography showed an occlusion of the left anterior descending artery, which was successfully treated with a drug-eluting stent. Hyperacute T waves are an early sign of acute ischemia, characteristically, broad-based and symmetrical, with increased amplitude and often associated with reciprocal ST depression in the precordial leads and elevation in aVR – the Winter pattern. This pattern should be recognized early and prompt cardiologist consultation along with serial ECG should be done.

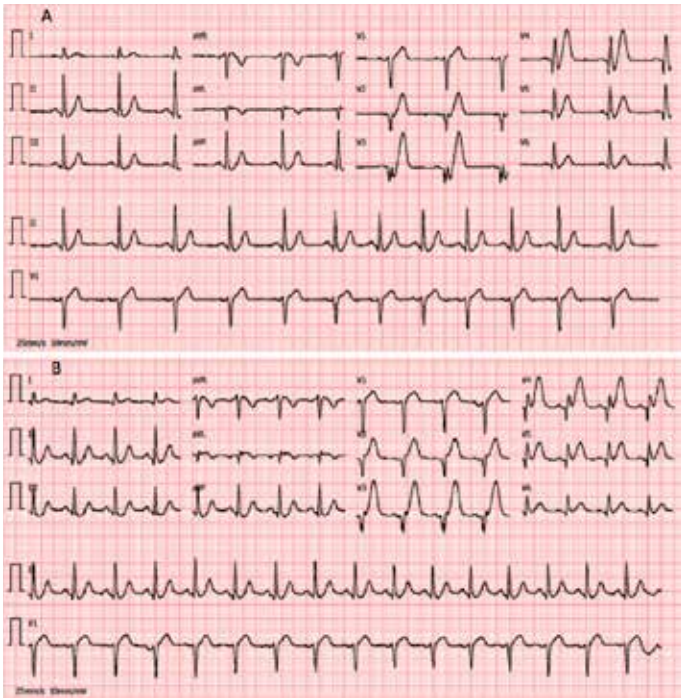


Figure #2015. ECG A and B.

#2016 - Case Report

A CASE OF A HIDDEN HEYDE SYNDROME

Daniela Soares Santos, Ana Luisa Nunes, Arsénio Santos, Armando Carvalho

Centro Hospitalar e Universitário de Coimbra, Coimbra, Portugal

Introduction

Heyde syndrome is the association between aortic stenosis and bleeding from gastrointestinal (GI) angiodysplasia. GI bleeding via arteriovenous malformation (AVM) results from acquired von Willebrand syndrome. Von Willebrand factor (VWF) is assumed to be critical in the pathway for adequate suppression of angiogenesis. Patients with Heyde syndrome are assumed to be at increased risk for bleeding due to mechanical destruction of von Willebrand multimers, as they pass turbulently through the narrowed aortic valve. Although some patients with this syndrome have normal VWF levels, other mechanisms of angiodysplasia such as decreased gastrointestinal perfusion have been implicated. In this case, we present our experience with this syndrome.

Case description

A 82 years-old Caucasian female was sent to internal medicine for chronic anemia study. She had a previous hospital admission by normocytic normochromic anemia requiring transfusion of packed red blood cells (PRBCs). Esophagogastroduodenoscopy revealed antral erythema and gastric biopsy was compatible with autoimmune gastritis. Had normal full colonoscopy and labeled red blood cell scintigraphy failure to identify active bleeding sources. Anti-parietal cell antibodies were positive. It was initiated intramuscular B12 vitamin replacement with improvement, but hemoglobin continued to drop. Patient had history of diabetes,

arterial hypertension and hypothyroidism.

In our first observation she referred asthenia, without blood losses. Presented pallor and a systolic murmur. Blood test showed iron deficiency anemia with hemoglobin 6.3 g/dL. An echocardiogram revealed severe aortic stenosis with aortic valve mean pressure gradient of 44 mmHg and aortic valve area of 0.7 cm². It was necessary regular transfusion of PRBCs although oral iron replacement. Patient was submitted to an aortic valve replacement by a bioprosthetic Crown 21 valve. At three weeks follow up presented symptoms improvement and normal hemoglobin (12.5 g/dL). Iron replacement was suspended. At six months follow up patient's hemoglobin was stable at 12.1 g/dL with normal ferritin at 140 ng/mL.

Discussion

Physicians need to be thoughtful and consider Heyde syndrome in patients with aortic stenosis. Only aortic valve replacement can solve anemia and surgery must be considered. Our case shows that sometimes we have more than once disease causing a problem remembering the importance of follow up.

#2020 - Case Report

REFRACTORY INFECTIVE ENDOCARDITIS: DON'T FORGET BRUCELLA ENDOCARDITIS!

Anis Hariz¹, Mohamed Salah Hamdi¹, Imen Boukhris¹, Nour El Houda Gueddich², Ines Kechaou¹, Samira Azzabi¹, Lamia Ben Hassine¹, Chakib Kooli¹, Eya Cherif¹, Narjess Khalfallah¹

¹ Charles Nicolle Hospital, Tunis, Tunisia

² Principle Military Hospital of Instructions of Tunis, Tunis, Tunisia

Introduction

Occurrence of Brucella infective endocarditis (BE) is rare. Its frequency is less than 1% of infective endocarditis. Brucella melitensis is usually the responsible bacteria. BE usually involves valve remodeled by rheumatic disease or congenital malformation. The clinical presentation of endocarditis is usually belated in comparison to the acute phase of the disease. Heart failure may be the revealing feature of BE. We herein report the case of a seemingly refractory infective endocarditis revealing BE.

Case description

A 56-year-old farmer with no medical history was admitted for a two-month story of nocturnal fever. Physical examination noted a patient with recent orthopnea and left facial palsy with recent aphasia. He had a fever of 38.7 °C. Signs of right and left-sided heart failure were observed, as well as the presence of diastolic murmur in the aortic area. Examination also showed splenomegaly. Laboratory evidence of inflammation were found. Estimated glomerular filtration rate was altered at 40 ml/min. Cerebral computed tomography highlighted the presence of ischemic lesions. Transthoracic cardiac ultrasound showed highly altered aortic valves, aortic regurgitation. Infective endocarditis was highly suspected; as such, transesophageal echocardiography

was performed confirming the presence of vegetations on the aortic valve. Blood cultures were initially negative. The patient was treated with a combination of amoxicillin and gentamycin. Clinical outcome was unfavorable as the fever persisted. One week later, blood cultures were confirmed positive to *Brucella melitensis*. Wright serology was performed and also positive. Diagnosis of BE with neurological and renal involvement was thus retained.

The patient received appropriate antibiotic therapy with a combination of rifampicin and Doxycycline with rapid regression of fever. Laboratory evidence of inflammation also subsided. Aortic valve replacement was then successfully performed and microbial culture confirmed the diagnosis of BE.

Discussion

BE is a rare but serious condition potentially leading to severe cardiac valves destruction. It remains the leading cause of death in brucellosis. It requires early diagnosis with an urgent and aggressive therapeutic attitude. While blood culture may not necessarily be positive in case of infective endocarditis, it's important to consider bacteria such as *Brucella* especially given an adequate clinical context. Treatment is based on appropriate antibiotic therapy and valve replacement.

#2021 - Case Report

TIREOTOXICOSIS: AN INTOXICATED HEART

Telmo Borges Coelho, Mariana Brandão, Henrique Elvas, Diogo Ramalho, Maria Alves, Paula Ferreira, Manuela Sequeira, Vítor Paixão Dias

Centro Hospitalar Vila Nova de Gaia|Espinho, Vila Nova De Gaia, Portugal

Introduction

Amiodarone-induced thyrotoxicosis (AIT) is common in patients with heart failure (HF) and may precipitate arrhythmic events and exacerbation of HF. It is secondary to iodine overload or a direct toxic effect, resulting in destructive thyroiditis.

Case description

We report the case of a 88-year-old man with multiple cardiovascular risk factors and history of HF usually in NYHA functional class I, and paroxysmal atrial fibrillation (AF), medicated with amiodarone and apixaban.

The patient was admitted for clinical worsening of HF (minimal effort dyspnea, orthopnea and nocturnal paroxysmal dyspnea) and palpitations. At admission to the emergency department, he had an AF with rapid ventricular response (RVR), with difficult heart rate control (HR), even after infusion of amiodarone. Chest radiography suggested the presence of pulmonary congestion and bilateral pleural effusion.

During hospitalization, the thyroid hormone assay revealed TSH and free T4 values, of respectively <0.005 $\mu\text{IU/ml}$ and 3.53 ng/dL , suggesting AIT as a precipitating factor in the episode of AF with RVR and exacerbation of HF. The ultrasound evaluation of the thyroid demonstrated cystic nodularities with benign

characteristics. Treatment with Prednisolone and Thiamazol besides bisoprolol and digoxin (for HR control) was started and Amiodarone was suspended.

The patient showed progressive improvement of symptoms after intensification of diuretic therapy. He underwent a transthoracic echocardiogram, which showed worsening of left ventricular ejection fraction. The patient was discharged under thiamazol and prednisolone and will be followed as outpatient.

Discussion

The case illustrates the complex interaction between thyrotoxicosis and AF, both with potential for decompensation of preexisting heart disease. In this patient, a rhythm control strategy with amiodarone in order to eliminate AF as a precipitant of clinical exacerbation of HF culminated in the development of AIT, resulting in a worsening of underlying dysrhythmia and cardiopathy, which could be fatal. Thus, there seems to be a fine line between cause and consequence in the worsening of the clinical condition of a previously stable patient with multiple co-morbidities. The authors emphasize the relevance of thyroid function assessment in AF and HF settings, as well as the importance of a high degree of clinical suspicion for AIT, since persistent therapy with amiodarone may lead to significant morbidity and mortality

#2033 - Abstract

EFFICACY AND SAFETY OF BALLOON PULMONARY ANGIOPLASTY IN PATIENTS WITH CHRONIC THROMBOEMBOLIC PULMONARY HYPERTENSION-PORTUGUESE CENTER EXPERIENCE

Daniel Sebaiti, Alexandra Briosas, Rita Calé, Filipa Ferreira, Maria José Loureiro, Sofia Alegria, Silvia Vitorino, Pedro Santos, Debora Repolho, Gonçalo Morgado, Helder Pereira

Hospital Garcia de Orta, Almada, Portugal

Background

In patients with chronic thromboembolic pulmonary hypertension (CTEPH) refused for pulmonary endarterectomy (PEA) and in patients with residual or recurrent pulmonary hypertension (PH) after PEA, the only treatment available in Portugal, until recently, was pulmonary vasodilator therapy (PVT).

Aims

evaluate immediate efficacy and safety of balloon pulmonary angioplasty (BPA) beyond PVT in patients with non-operable CTEPH or residual/recurrent PH. A Portuguese initial single center experience.

Methods

From December 2017 to December 2018, we performed a total of 57 BPA sessions in 12 patients. Hemodynamic and clinical aspects were evaluated at diagnosis, before the 1st session (on PVT) and after the last session of BPA in 7 consecutive CTEPH

patients (mean age 61 years, 57% female) who completed the BPA treatment (mean of 5 sessions per patient). A detailed analysis in terms of technical aspects and procedure related complications was performed for the 57 procedures.

Results

Technical aspects: femoral access was used for all procedures; a total of 230 vessels were treated in 139 segments (mean of 4.0 ± 1.9 vessels in 2.4 ± 1.0 segments per session); most frequent type of treated lesions was web lesions (71%); 11 pressure-wire guided sessions for patients with mean pulmonary artery pressure (PAP) >40 mmHg. The median duration between CTEPH diagnosis and first BPA was 55 months and from first to last BPA session was 4 months. WHO FC II, III, IV distribution was 6/1/0 after PVT, respectively. After BPA, there was significant additional improvement of mean PAP ($p=0,026$) and 86% of patients improved to WHO FC I; there was a trend for decrease in pulmonary vascular resistance, improvement of cardiac index and NT-proBNP reduction. Procedure-related adverse events occurred in 24% of the interventions, and they were all minor: 3 distal wire perforations; 4 pulmonary artery dissections (no need for intervention); 5 mild to moderate haemoptysis; 3 reperfusion edemas (grade 2, without need of mechanical ventilation); 2 access site complications and 1 contrast nephropathy KDIGO AI staging 1.

Conclusion

Balloon pulmonary angioplasty on top of pulmonar vasodilator therapy further improves short term hemodynamics and functional class in this group of patients. BPA can be safely performed, there was no need of invasive ventilation or surgery and no procedural-related death.

#2039 - Case Report

CAN THE LIGHTNING STIKE TWICE?

Estefânia Tupin, Tiago Pacheco, Rita Valente, Filipa Cardoso, Isabel Germano

Centro Hospitalar Universitário de Lisboa Central, Lisboa, Portugal

Introduction

Antiphospholipid syndrome is an autoimmune disease in which autoantibodies are formed that facilitate the formation of blood clots in arteries and veins. It is more common in women and is diagnosed usually between the age of 30 and 40 years old.

Case description

The subject of this case report is a man with 42 years old with a diagnosis of HIV-type 1 infection under antiretroviral therapy with undetectable viral load and good immune status, chronic hepatitis C, neoplasm of the rectum treated with surgery, radiotherapy and chemotherapy without relapse, erectile dysfunction, deep venous thrombosis of the left inferior limb in 1999, intravenous drug use in the past, over 20 years ago and heavy smoking habits.

He was admitted in the hospital after several weeks of pain in

the inferior right limb. He has had complaints of intermittent claudication for several months and an arterial Doppler had been asked for. In the emergency room an arterial and venous Doppler was made and he was diagnosed with deep venous thrombosis of the right limb. But the Doppler also identified multiple atheromatous plaques with diffuse distribution, superficial femoral artery occlusion as well as segmentar occlusion of the homolateral posterior tibia and peroneal arteries, raising suspicion for a thromboangiitis obliterans also known as Buerger disease.

During his hospitalization a thoraco-abdominal-pelvic CT scan was made to exclude cancer. An acute pulmonary thromboembolism was diagnosed despite the absence of symptoms. He was observed by Vascular Surgery because of the suspicion of Buerger disease and tobacco eviction and anti-aggregation with aspirin and statin use for a LDL lower than 100 were recommended. Anti-coagulation with anti-vitamin K was initiated. The vascular study came positive for anti-beta2 GP1 antibody in two measures separated by three weeks compatible with a diagnosis of antiphospholipid syndrome.

Discussion

This case presents a diagnostic challenge. Buerger disease is a rare condition and usually does not affect larger vessels so deep venous thrombosis is not a common presentation neither is pulmonary thromboembolism. Plus the arterial Doppler did not identify haemodynamic significant lesions in the left limb. On the other hand antiphospholipid syndrome is rare in men, the anti-beta2 GP1 antibody count was positive but very low and hardly explains the diffuse atherosclerotic lesions at such a young age.

#2041 - Abstract

ADMISSION TO AN INTERNAL MEDICINE WARD: AN OPPORTUNITY FOR ABDOMINAL AORTIC ANEURYSM SCREENING

Sara Raquel Pereira Martins, Ana Maria Oliveira, Tânia Araújo Ferreira, Catarina Castelo Branco, Ricardo Marinho, Gabriela Teixeira, João Neves, Luis Loureiro

Centro Hospitalar do Porto, Porto, Portugal

Background

Abdominal aortic aneurysm (AAA) screening has been shown to effectively reduce AAA-related mortality in asymptomatic older men. Ultrasonography (US) is the preferred method due to its high sensitivity and specificity, safety, reproducibility and low-cost. Portugal lacks any organized AAA screening program and the results of the first population-based screening were recently published, reporting a 2.1% prevalence of AAA. Internal medicine ward admission might provide an opportunity for screening, since many patients not only meet the criteria for it but also have a high prevalence of risk factors for AAA. This study seeks to assess if US could be easily learned and correctly performed by internal medicine doctors and if AAA screening in internal medicine ward would be justified.

Methods

5 internal medicine (IM) residents received 5 hours of abdominal aortic US measure training with an experienced US operator; after which they performed the AAA screening from November 17-April 19. Inclusion criteria: males aged 65 or above, admitted in the IM Ward. Exclusion criteria: previously known AAA. 100 randomly selected patients had US scan performed by 2 of the IM residents, blinded to each other's results. 24 (24%) of those were repeated by a Vascular Surgeon (VS), also blinded to previous results. Aortic diameter >3cm was considered aneurysmatic. Statistical analysis was performed using SPSS v21.0

Results

Prevalence of AAA was 9% (n=9). Intraclass correlation coefficient (ICC) between IM residents measurements (n=100) was 0,96 (IC 95% 0.94-0.97) and Wilcoxon Signed Ranks Test reported no difference between such measurements [measure 1 median: 16.85 (IQR 15.40-19.58), measure 2 median:17,00 (IQR 15.00-19.70); p=0,86] . ICC between both the IM residents and the vascular surgeon measurements (n=24) was 0,97 (IC 95% 0.94-0.98) and Friedman test also described no difference between those 3 measurements (measure 1 median:18,60 (IQR 14.43-33.93), measure 2 median:18,25 (IQR 14.68-35:43); measure by VS median:18,00 (IQR 14.67-34.20); p=0.747]. AAA diagnosis by IM was 100% accurate when reviewed by a VS.

Conclusion

IM residents with minimum US training appear to perform aortic US accurately. AAA prevalence in IM wards seems to be higher than reported in the general population. Hospitalization at IM ward could represent an opportunity for AAA identification, improving such patients care without adverse sequelae.

#2051 - Medical Image

MASSIVE BIATRIAL DILATATION

Mário Ferreira, Marta Fonseca, Sara Magno, Catarina Melita, Lílíana Fernandes, Zélia Neves, João Machado
Hospital Prof Doutor Fernando Fonseca, Lisboa, Portugal

Clinical summary

76-year-old woman, with history of chronic obstructive pulmonary disease, Cor Pulmonale, valvular cardiopathy and atrial fibrillation is admitted to the hospital in anasarca for decompensated chronic heart failure.

Chest radiograph in Antero-Posterior projection presented massive cardiomegaly and subcarinal angle >90°, with important bilateral lung restriction.

The transthoracic echocardiogram revealed normally dimensioned left ventricle with conserved systolic function, although D-SHAPE pattern was observed. To emphasize, a marked biatrial dilatation (LA 68 cm², vol=312 ml and RA 74 cm², vol=375ml) and dilatated right ventricle with decreased longitudinal function and severe tricuspid insufficiency (PSAP=58mmHg).

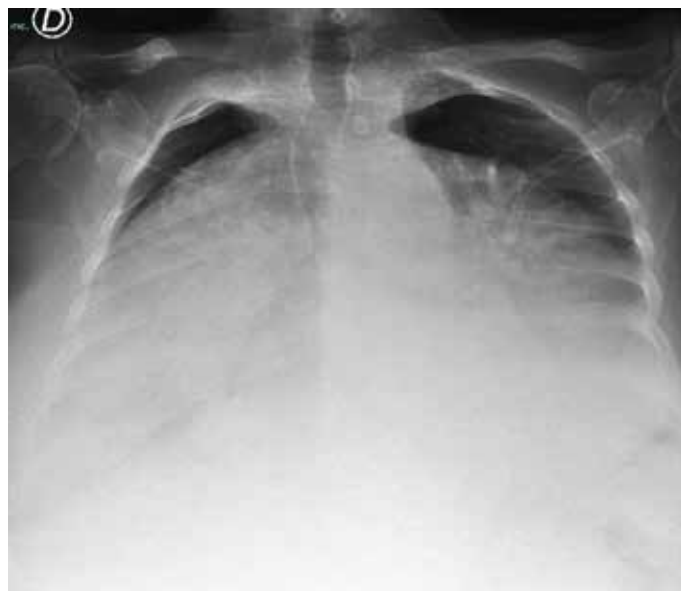


Figure #2051. Antero-posterior chest radiograph.

#2053 - Abstract

HYPERTENSIVE DISORDERS IN PREGNANCY. INTERNIST INSIGHT

Maria Gema Pelayo García

Internal Medicine Department, Hospital Punta de Europa, Algeciras. UGC-AGS Campo de Gibraltar, Algeciras, Spain

Background

Hypertensive disorders of pregnancy (pre-eclampsia, eclampsia, haemolysis, elevated liver enzymes, and low platelets (HELLP) syndrome and gestational hypertension) affect up to 10% of pregnancies. Women with a hypertensive disorder of pregnancy have increased risks of post-pregnancy hypertension, ischaemic heart disease, and stroke. The aim of our analysis is to outline the decisive factors that can contribute in development of this adverse clinical outcome.

Methods

We conducted a descriptive, observational study and collected data from clinical charts between 2016-2018 in our hospital linked to maternal and gestational age, pre-existing medical conditions as pregestational diabetes, hypothyroidism, chronic hypertension, fist pregnancy, multifetal pregnancy, past history of preeclampsia and lowering-blood pressure treatment.

Results

N: 24. Age: <25yr: 7 (29%), 25-35 yr:10 (41.6%), >35-45 yr:8 (33%). Nuliparity: 15 (62.5%). One set of twins in one pregnancy. Gestational age: 20-35 wk: 50%. Hypothyroidism: 5 (21%), previous hypertension: 5 (21%). In 2 cases, HELLP syndrome was suspected and diagnosed. Breastfeeding was desired in most cases, 79%. Intensive intravenous antihypertensive treatment was used in 8 women (33%). Oral labetalol, enalapril and calcium channel blockers were the most widely prescription applied after hospitalization.

Conclusion

Most affected patients are nulliparous. Half of the cases present with new-onset hypertension and proteinuria at ≥ 34 weeks of gestation. All pregnant women with new onset hypertension or worsening hypertension after 20 weeks gestation should be evaluated for preeclampsia. Consequently, a comprehensive approach is mandatory to address this distressing complication. Cardiovascular disease prevention in women with hypertensive disorders of pregnancy should include blood pressure monitoring initiated soon after pregnancy.

#2055 - Medical Image

MITRAL RHEUMATIC DISEASE

Hugo Miguel Rodrigues Almeida¹, Beatriz Rodríguez², Sonia Canadas³, Rita Fernandes¹, João Correia⁴

¹ Hospital Sousa Martins, Guarda, Portugal

² ULS Guarda, Salamanca, Spain

³ Complejo Asistencial Universitario de Salamanca, Guarda, Portugal

⁴ ULS Guarda, Guarda, Portugal

Clinical summary

A 56-year-old woman, from Africa, presented a sudden clinic of precordialgia, irradiated to the extremities and associated with nausea. No other associated clinic.

Background of rheumatic fever in childhood. No usual medication. Physical exploration emphasizes grade IV / VI systolic murmur, of greater intensity in the mitral focus.

In the diagnostic exams, troponin elevation was observed with no electrocardiographic changes. Echocardiography showed a severely dilated left atrium, with severe mitral valvulopathy (thickening of the valves and severe mitral regurgitation) and moderate tricuspid valvulopathy, with indirect criteria of pulmonary hypertension.

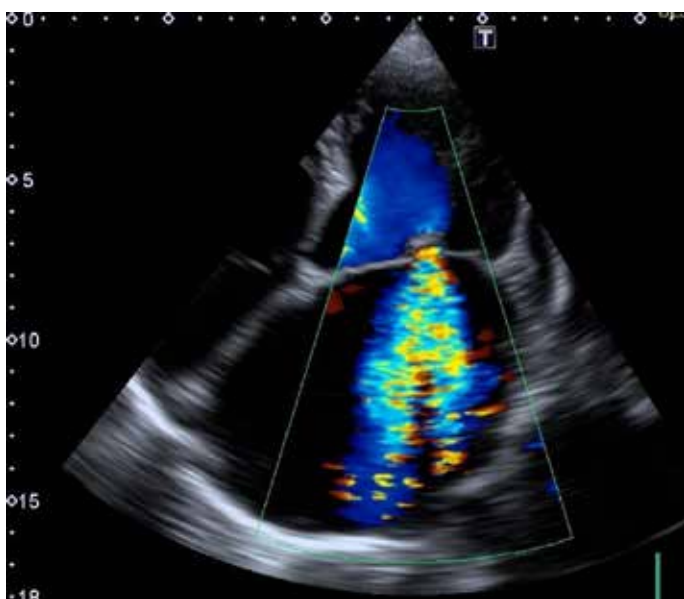


Figure #2055.

#2061 - Abstract

POTASSIUM LEVELS AT ADMISSION IN ACUTE HEART FAILURE- IMPACT ON 90-DAY READMISSION RISK

Sérgio Maltês¹, João Presume¹, Francisco Albuquerque¹, Gonçalo Cunha¹, Bruno Rocha¹, Sofia Furtado², Rita Homem³, Ana Rita Santos¹, Joana Maurício⁴, Inês Felizardo Lopes², Mariana Popovici², Inês Lopes Da Costa², Inês Edígio¹, Inês Nabais⁵, Francisco Adragão⁶, Catarina Rodrigues¹, Inês Araújo¹, Luís Campos¹, Cândida Fonseca¹

¹ Centro Hospitalar Lisboa Ocidental, Lisboa, Portugal

² Centro Hospitalar Lisboa Central, Lisboa, Portugal

³ Hospital Garcia de Orta, Setúbal, Portugal

⁴ Hospital Prof. Doutor Fernando Fonseca, Lisboa, Portugal

⁵ Hospital de Cascais, Lisboa, Portugal

⁶ Centro Hospitalar Universitário do Algarve, Portimão, Portugal

Background

Heart failure (HF) is an increasingly prevalent syndrome and a main cause of hospitalization. Patients admitted due to acute heart failure (AHF) have high risk of early readmission and death. The association between abnormal levels of serum potassium ([K⁺]) at admission in patients with AHF and risk of readmission or death is still a matter of debate. Our goal was to assess the correlation between [K⁺] levels and clinical outcomes in patients admitted for AHF.

Methods

This was a single-center retrospective observational cohort study enrolling consecutive patients admitted for AHF in a HF Unit from 11/2017 to 10/2018. For patients with multiple readmissions, only the first was considered. All-cause admissions, admissions for AHF and all-cause death at 90 days were assessed.

Results

Overall 154 patients were included; 54% were male with a mean age of 77 ± 11 years; 46% had HF with preserved ejection fraction. 40% had ischaemic heart disease and 32% had an hypertensive aetiology; 76% of patients had hypertension, 42% diabetes mellitus and 59% had chronic kidney disease; 72% of patients were treated with a renin-angiotensin-aldosterone system inhibitor (RAASi), 79% with a beta-blocker (BB). When assessing rehospitalization by admission [K⁺] levels <3.5 mmol/L, 3.5-4.5 mmol/L, 4.5-5.5 mmol/L and >5.5 mmol/L, a "J curve" phenomenon was observed, with [K⁺] levels between 4.5-5.5 mmol/L associated with lower readmission rates. This finding was observed regardless of the use of guideline-directed medical therapy (RAASi or BB). In contrast, discharge [K⁺] levels did not correlate with readmission rates. Admission [K⁺] levels outside the 4.5-5.5 mmol/L range were the only predictors of all-cause readmission at 90 days (odds-ratio (OR) 2,778, 95% confidence interval (CI) [1,211; 6,369], $p=0,016$). Admission [K⁺] levels, urea and creatinine were predictors of readmission for HF at 90 days. After adjusting for confounding factors, admission [K⁺] levels was the only predictor

for HF readmissions (adjusted OR 3,236, 95% CI [1,003; 10,101], $p=0.049$). Discharge NT-proBNP log level was the only predictor of all-cause death at 90 days (crude OR 0,038, 95% CI [0.006; 0,375], $p=0.004$)

Conclusion

In our cohort of patients admitted for AHF, [K+] at admission outside the range of 4.5-5.5mmol/L was independently associated with a higher risk of all-cause and HF readmission at 90 days. These results were independent of the use of RASSi or BB. Serum K+ levels may be a useful tool to stratify the risk of readmission.

#2065 - Medical Image

A CASE OF ACUTE AORTIC DISSECTION TYPE A

Rui Osório, Ana Sofia Moreira, Ramiro Sá Lopes, Teresa Salero, Catarina Mendonça

Centro Hospitalar do Algarve - Hospital de Faro, Faro, Portugal

Clinical summary

Acute aortic dissection is an uncommon disorder which can have fatal results. If the treatment is delayed or misdiagnosed can reach mortality rates of 1-2% per hour. Twenty percent of the patients die before reaching the hospital and 30% on admission.

A 63-year-old male, with history of hypertension and aortic aneurysm, was presented in the emergency room with severe chest pain, syncope and hypotension. Troponin I and BNP levels were normal and no changes in ECG were detected. Due to suspicion of aneurism rupture contract-enhanced CT was preformed, which detected an acute ascending and descending aortic dissection (type A – Stanford classification). The patient was rush to third-level hospital to cardiovascular surgery, a valve conduit was place and the patient survived.

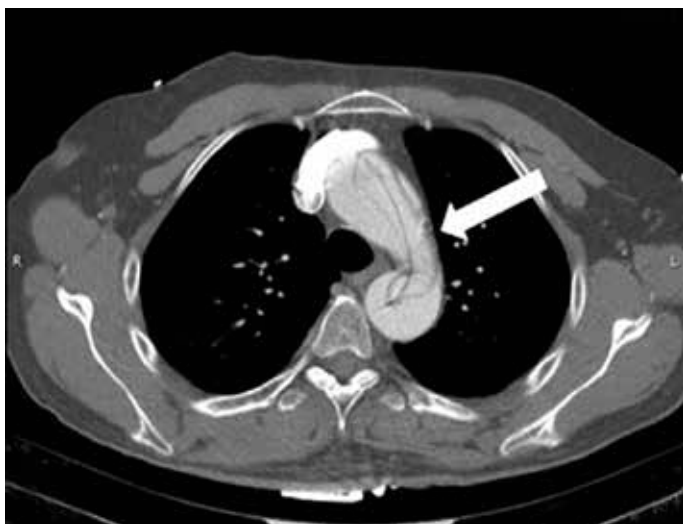

Figure #2065. Aortic arch dissection.

#2082 - Case Report

CARDIOVOCAL SYNDROME – A RARE MANIFESTATION OF PULMONARY HYPERTENSION

Marta Mendes Lopes, Inês Fialho, Catarina Lameiras, Énia Ornelas, Maria Do Céu Dória

Professor Doutor Fernando Fonseca Hospital, Amadora, Portugal

Introduction

Cardiovocal syndrome or Ortner's syndrome refers to hoarseness caused by cardiopulmonary disease and results from left recurrent laryngeal nerve palsy. This nerve arises from the left vagus nerve at the level of the aortic arch ascending between the right pulmonary artery and aorta to innervate the ipsilateral vocal cord muscles. Its close relationship with multiple structures makes it vulnerable to compression, being in rare cases the first manifestation of cardiopulmonary disease including pulmonary hypertension.

Case description

A 59-year-old woman, natural from Guinea-Bissau, without relevant medical history except an iron deficient anaemia, presented with exertional dyspnoea and precordial pain with nine months of duration. Her pain was pressure-like, non-radiating and accompanied by bilateral lower limb oedema. At physical examination, it was noted a systolic murmur in the left sternal border, bilateral basal rales at lung auscultation, bilateral malleolar oedema and also hoarseness with several months of duration that the patient did not value. To investigate for possible heart failure, she underwent transthoracic echocardiogram that revealed a preserved ejection fraction as well as an enlarged right pulmonary artery with an estimated pulmonary artery systolic pressure of 64 mmHg without other relevant findings. Because of the presence of hoarseness and an enlarged pulmonary artery, she underwent laryngoscopy that revealed a left vocal cord palsy. A cervical ultrasound and thoracic CT scan were performed, excluding other causes of recurrent laryngeal nerve compression and confirming an enlarged pulmonary artery. The etiologic investigation of pulmonary hypertension remains in course. The patient's symptoms have improved under optimized medical therapy, however, after one month the hoarseness still persists.

Discussion

In this case we describe an extremely rare cause of vocal cord palsy, which resulted from compression of the left recurrent laryngeal nerve by an enlarged right pulmonary artery. Pulmonary hypertension or some other cause leading to pulmonary artery dilation, whether temporary or 'dynamic' may be responsible for vocal fold palsy, therefore, the presence of hoarseness in a patient with cardiopulmonary disease should alert clinicians for this diagnosis. Moreover, early recognition of the cause of the nerve compression is of extreme importance, since reversibility of the palsy depends on the duration of injury.

#2085 - Medical Image

CHEST PAIN AS A CLINICAL PRESENTATION OF AN AORTIC ANEURYSM

Maria João Gomes, Filipa Ferreira, Inês Bargiela, Sandra Alves
Hospital Professor Doutor Fernando Fonseca, Amadora, Portugal

Clinical summary

The authors present the case of a 78-year-old woman, with medical history of arterial hypertension and atrial fibrillation who was admitted for fatigue and oppressive chest pain. The

laboratory findings included elevated D-dimer levels (3815 ng/dL) and slightly raised troponin T levels. The transthoracic echocardiogram revealed a structurally normal left ventricle with severely impaired systolic function without dyskinesia, an enlarged left atrium and an aneurysmal dilation of the ascending aorta (7 cm) without evidence of dissection. The computed tomography pulmonary angiography excluded pulmonary embolism, but showed an aneurysmal dilation of the ascending and descending thoracic aorta as well as a thrombosed sacular aneurysm of the aortic arch measuring 4,5 x 2,5 cm.

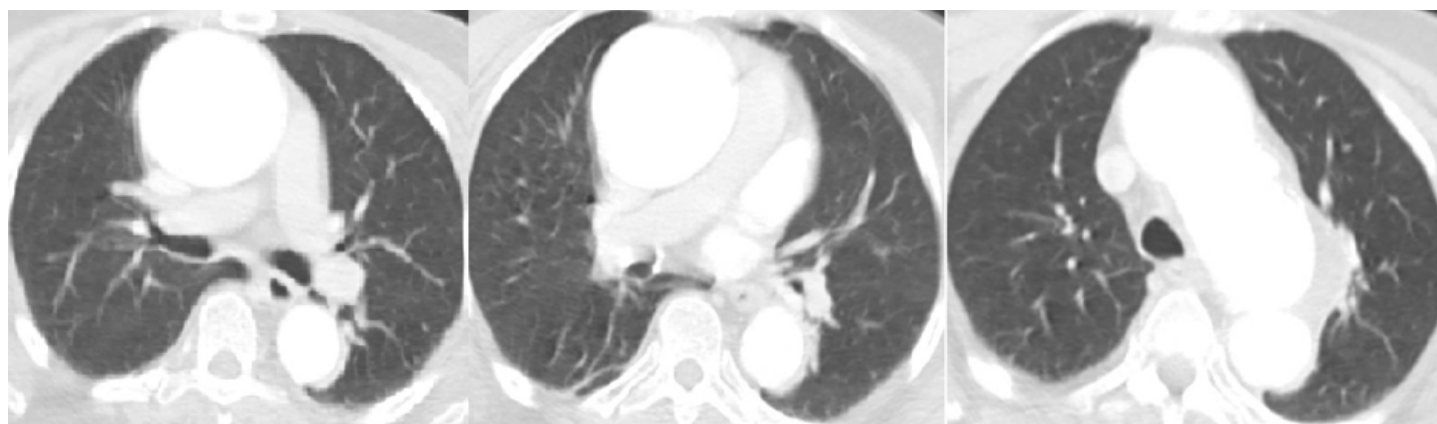

Figure #2085.

#2105 - Case Report

ACUTE PULMONARY OEDEMA AS THE MAIN SIGN OF A THYROID STORM

Rita Carneiro Silva, Mónica Mesquita, Fernando Salvador, Paula Vaz Marques

CHTMAD, Vila Real, Portugal

Introduction

Thyroid storm is the most extreme form of thyrotoxic crisis, however, it often has a poorly specific clinical presentation. Congestive heart failure may be the presenting feature of thyroid storm, with acute pulmonary edema being its most extreme form. The coexistence of these two medical emergencies induces high mortality, making identification and a rapid approach essential.

Case description

A 61-year-old man with a history of alcoholic liver cirrhosis, paroxysmic atrial fibrillation, peripheral venous insufficiency and degenerative osteoarticular disease with spinal stenosis, was brought to the emergency department due to sudden worsening of dyspnea and somnolence. He presented with symptoms and signs compatible with acute pulmonary hypertensive edema, with evident respiratory effort, paleness, sweating, hypertension, tachycardia, scattered crackles on auscultation and marked peripheral edema. After review of systems, the patient also admitted progressive unexplained weight loss, diarrhea and tremors of the upper limbs associated with sweating and feeling of heat. Laboratory results revealed respiratory acidosis,

undetectable TSH (<0.01 mIU/L) and free T4 >100 pmol/L, and a thyrotoxic crisis was diagnosed, highly probable a thyroid storm, according to the Burch-Wartofsky Point Scale. In addition to the supportive treatment with nitrate perfusion, furosemide and non-invasive mechanical ventilation, treatment with antithyroid drugs, inorganic iodide, beta-blocker and corticosteroid was started and he was monitored in an Intermediate Care Unit. The presence of high titer thyrotropin-receptor antibodies confirmed Graves' Disease as the cause of hyperthyroidism. The patient clinically improved, having completed the stabilization and complementary investigation in Internal Medicine ward, and being discharged to consult.

Discussion

This case emphasizes the importance of always investigating all etiologies of acute heart failure according to recommendations. In the presence of heart failure, beta-blocker titration to inhibit the peripheral effects of thyroid hormone requires careful monitoring. It is important to suspect a thyroid storm in the presence of compatible symptoms, even in the absence of previously diagnosed hyperthyroidism, given its poor prognosis when not addressed in a timely manner.

#2110 - Case Report

ANEURYSM OF THE ABDOMINAL AORTA MANIFESTING AS RECURRENT ABDOMINAL PAIN

Daniela Sousa Viana, Guilherme Cardoso, Joana Rua, Carmem Pais, Natália Lopes, Paula Marques

Centro Hospitalar de Trás os Montes e Alto Douro, Vila Real, Portugal

Introduction

Aneurysm of the abdominal aorta (AAA) is the most common arterial aneurysm and often an incidental finding. Most frequently found in women, their elective surgical treatment mortality is estimated in 0.6-5.3%, rising to 40% in emergency situations. Most commonly asymptomatic, they may express through deep back and abdominal pain. When expanded enough to press another local organ or ruptured, symptoms are more significant. Medical imaging is important for diagnosis, surveillance and treatment.

Case description

64 years-old man, with relevant background including hypertension, dyslipidemia, cerebral vascular disease, extensive aortic atherosclerotic disease and an untreated fusiform AAA with 4 cm diameter. The patient had several admissions to the emergency department over four months. He described episodic low back pain, often with abdominal irradiation, assumed in the context of obstructive nephrolithiasis, supported by abdominal CT, and treated symptomatically with temporary remission after discharge. Considering his medical condition and comorbidities, his recent medical history seemed unjustified. Meanwhile, due to known aortic disease, he was under follow-up in vascular surgery and was appointed for elective surgery. Preoperative CT revealed slight irregularity over the posterior lateral wall of the aneurysm with associated periaortic fat densification, suggesting instability, without contrast leak – suggesting ulcerated AAA in need for emergent intervention. After undergoing surgery, six months have passed without any further episodes of abdominal pain. To date, he is with apparent clinical resolution.

Discussion

Recurrent abdominal pain can contemplate a wide range of etiologies. In this case, the recurrent character of the pain should lead to consider a more extensive differential diagnosis, besides renal calculus, diverticulitis and herniation. Screening and follow up are necessary specially with at risk patients after diagnosis. Although the AAA didn't show any signs of rupture, being more likely asymptomatic, its surgical approach induced remission of the symptoms. Therefore, the ulcerated AAA may probably explain the clinical syndrome.

#2111 - Case Report

DISSECTION OF THE AORTA PRESENTING AS DISSEMINATED INTRAVASCULAR COAGULATION

Anis Hariz¹, Mohamed Salah Hamdi¹, Imen Boukhris¹, Nour El Houda Gueddich², Ines Kechaou¹, Lamia Ben Hassine¹, Samira Azzabi¹, Chakib Koolo¹, Eya Cherif¹, Narjess Khalfallah¹

¹ Charles Nicolle Hospital, Tunis, Tunisia

² Principle Military Hospital of Instructions of Tunis, Tunis, Tunisia

Introduction

Disseminated intravascular coagulation (DIC) is a systemic, diffuse and uncontrolled activation of the coagulation process. It results in the formation of fibrin deposits leading to vascular thrombosis but also, hemorrhage secondary to massive consumption of hemostasis factors. Various pathologies may be responsible for DIC especially infectious and neoplastic diseases; aneurysms and dissection of the aorta are a rare cause. We herein report the case of a secondary DIC, revealing a dissection of the aorta.

Case description

A 75-year-old male with a smoking history of 60 P/Y was admitted for petechial purpura and ecchymosis involving the face and the forearms as well as signs of global heart failure. He had a medical history of hypertension with congestive heart failure. Laboratory routine tests were consistent with DIC as it showed low prothrombin time at 30%, elongated partial thromboplastin time, low fibrinogen serum level at 0.8g/l and elevated concentration of fibrin degradation products. Full blood count also noted the presence of low white blood cells count at 2900/mm³, anemia with hemoglobin of 8g/dl and low platelet count at 7000/mm³. Infectious investigations did not yield positive results: blood cultures, as well as the viral serologies, were negative and echocardiography showed no signs of infective endocarditis.

Computed tomography of the abdomen indicated the presence of an aneurism of the aortic arch with dissection and detachment of a calcified intimal flap of the aorta. Diagnosis of a DIC complicating aortic dissection was retained. Clinical outcome was marked by rapid deterioration of respiratory and renal function followed by multivisceral failure resulting in the patient death.

Discussion

DIC is a very serious hematological complication that usually occurs in the presence of severe sepsis or during neoplastic diseases. Nevertheless, other rarer etiologies must always be considered such as allergic reaction, fat embolism, aneurysm and dissection of the aorta as was the case in our patients. Aortic dissection is found to be a rare cause of DIC. Dissection of the aorta remains a rare yet a grave etiology of DIC. It needs to be considered especially if no obvious cause is found in patients with cardiovascular risk factors.

#2124 - Abstract

QUALITY OF ORAL ANTICOAGULATION THERAPY WITH VITAMIN K ANTAGONISTS: 10 YEARS OF EXPERIENCE

Renato Guerreiro, Susana Quintão, Catarina Bastos, Juliana Campos, Inês Sarmento, Irene Verdasca, Jorge Dantas, Rui Morais, José Guia, Filipa Marques, Inês Araújo, Ana Leitão, Cândida Fonseca

Oral Anticoagulation Clinic, Hospital de São Francisco Xavier, CHLO, Lisbon, Lisbon, Portugal

Background

In the era of direct oral anticoagulants, vitamin K antagonists (VKA) still play a central role in oral anticoagulation (OAC). The difficulties in the INR adjustment, in order to achieve an effective OAC are well known. The Time in Therapeutic Range (TTR) > 60% is the recommended indicator to evaluate the efficacy of VKA treatment.

The aim of our work is to evaluate the quality of VKA treatment in an OAC Practice over the past 10 years.

Methods

In a population on VKA, point-of-care INRs were first monitored using the Hyt-Gold, and the Gota v.8.1.3 computer program. We quantified TTR, % of thrombotic and hemorrhagic events related to OAC during 10 consecutive years, in a nursing consultation with medical staff collaboration.

Results

Between 2008 and 2017, an average of 765 (+/- 139) patients were monitored per year. 51% men and 65% (+/- 5) were 70 years old and over. The most frequent indication for OAC is Atrial Fibrillation/Atrial Flutter (mean 52% (+/- 1) patients/year), followed by acute thrombotic events and cardiac valve disease. We performed an average of 10285 (+/- 2118) appointments/year. From 2008 to 2017 the mean TTR were 74, 73, 74, 75, 79, 82, 82, 84, 81 and 82%, respectively. TTR was higher than 60% in 72, 72, 68, 72, 79, 84, 84, 81, 81, 82% of these patients respectively from 2008-2017; major haemorrhages developed in 0.19, 0.49, 0.56, 0.47, 0.54, 0.46, 0.85, 1.37, 0.97, 0.19%; minor bleeding arised in 5.57, 1.09, 2.81, 4.85, 4.03, 4.91, 4.96, 4.34, 6.12, 5.57%; and thrombotic events occurred 0.96, 0.24, 0.22, 0.12, 0.22, 0.0, 0.36, 0.96, 0.81, 0.96% /year.

Conclusion

The permanently high TTR's achieved over the last 10 years, in addition to the minimal rates of thrombotic and/or hemorrhagic events related to ACO, certify the effectiveness and the high quality of the AVK monitoring methodology used in our OAC Clinic.

#2130 - Abstract

SUSCEPTIBILITY AND COMPLIANCE TO INFLUENZA AND PNEUMOCOCCAL VACCINATION IN PORTUGUESE PATIENTS WITH HEART FAILURE: THE PITFALL STUDY

Márcia Agostinho Pereira¹, Gisela Vasconcelos², Lígia Rodrigues Santos², Madalena Vicente¹, Joana Duarte³, Francisco Adragão³, Inês Nabais³, Inês Egídio Sousa³, Inês Costa³, Sérgio Maltês, João Presume³, Inês Araújo³, Cândida Fonseca³

¹ Centro Hospitalar Universitário Lisboa Central, Lisboa, Portugal

² Centro Hospitalar Tâmega e Sousa, Penafiel, Portugal

³ Centro Hospitalar Lisboa Ocidental, Lisboa, Portugal

Background

Heart failure (HF) is a major and raising health problem, with respiratory tract infections being a common trigger of decompensation. Influenza virus and pneumococcal vaccinations are highly recommended in these patients. The aim of this study was to evaluate the vaccination rate for influenza and pneumococcal vaccines in the population with HF and the impact of patient education and active recall in vaccination compliance.

Methods

Prospective interventional study conducted using non anonymized patient survey and electronic health record data of patients seen in a HF Clinic of a general Hospital in Lisbon, between September and December 2018. The knowledge and opinion on those specific vaccines was questioned, as well as previous vaccination status; then, a brief explanation on the importance of vaccination was given; both vaccines were proposed for those not yet immunized. Statistical analysis was carried out using Microsoft Office Excel version 2016 in order to compare vaccination compliance before and after patient education.

Results

186 patients were included, 52.69% male; average age was 74.4 years old; 70.4% had previous compliance to annual influenza vaccination, while only 18.8% was registered for pneumococcal vaccination. Of all patients, 93.5% and only 3.8% were eligible for influenza and pneumococcal vaccinations at no cost, respectively, according to the National Immunization Program (NIP). Nevertheless, in the non compliant groups most patients did not get vaccinated because they "did not think the vaccine was useful", for influenza, and "had never heard of the vaccine", for pneumococcal vaccination. After a brief, one time, educative and active recall, vaccination compliance was 86.0% versus 70.4% (p=0.00027) for influenza vaccination and 83.9% versus 18.8% (p<0.00001) for pneumococcal vaccination.

Conclusion

Insufficient influenza and specially pneumococcal vaccination was registered, despite the high recommendation of both vaccines for HF patients. Among the factors are patient's lack of information, with higher vaccination compliance being achieved after a short

intervention. We hypothesized that pneumococcal vaccination is less recommended by physicians, taking in consideration that few patients knew about its existence. This may be due to the characteristics of the recommendation in the NIP (highly recommended but not free of cost) for that vaccine in HF patients. In a subsequent study we aim to compare the impact of vaccination in HF related events.

#2131 - Case Report

IATROGENIC PERIMYOCARDITIS: A RARE SIDE EFFECT OF MESALAZINE

Diana Vale Carvalho, Pedro Carvalho, Lisa Ferraz, Daniela Meireles, Ana Rafaela Araújo, Ana Raquel Ferreira

Centro Hospitalar Baixo Vouga, Aveiro, Portugal

Introduction

Mesalazine is a widely used drug which is generally perceived as being safe for the treatment of inflammatory bowel disease (IBD). Cardiotoxicity like myocarditis is a rare side effect, present in less than 1% of patients. However, it can be difficult to define the etiology of myocarditis once IBD can lead to myocarditis too.

Case description

A 21-year-old female patient was admitted to our emergency room with chest pain with pleuritic characteristics and palpitations. She had been recently diagnosed with ulcerative colitis and was medicated with prednisolone (15mg/day) and mesalazine 1000 mg twice a day (introduced 15 days before). In the physical examination, she only had fever and she did not show other significant changes. The initial 12-lead electrocardiogram revealed sinus tachycardia. Laboratory tests showed elevated troponin I (297 pg/mL) and C-reactive protein with leukocytosis. The echocardiogram showed a mild depression of the ejection fraction and slight hypokinesia in the basal portion of the inferior wall. She was hospitalized for suspected perimyocarditis and since the patient had been previously medicated with corticosteroids, the dosage was increased to 40 mg/day. Non-steroidal anti-inflammatory drugs or colchicine were not introduced because of the high risk of IBD exacerbation. Since the patient had heart failure mid-range ejection fraction, remodeling therapy was initiated. Cardiac magnetic resonance imaging revealed pericardial effusion, focal ventricular edema, increased ventricular permeability and delayed gadolinium enhancement mainly subepicardial, suggesting focal myocardial fibrosis. Because of mesalazine's cardiotoxicity described in literature, this drug was withdrawn soon after admission. The patient did not show new episodes of chest pain and there was a marked reduction of the patient's troponin levels. The following echocardiogram showed a recovery of the ejection fraction under optimized medical therapy. In the 3-month follow-up, the patient remained asymptomatic.

Discussion

Perimyocarditis is a rare extra-intestinal manifestation of IBD. The differential diagnosis with cardiotoxicity induced by mesalazine

can be challenging in patients with IBD who are treated with this drug. According to literature, mesalazine cardiotoxicity develops about 2-4 weeks after its introduction. In this case, the recent introduction of mesalazine and the clinical improvement after its discontinuation makes it as the most likely etiological agent for perimyocarditis.

#2151 - Case Report

POLYSEOSITIS AND PERIMYOCARDITIS WITH DILATED CARDIOMYOPATHY AND PERICARDIAL EFFUSION: WHEN IDIOPATHIC IS NOT THE ANSWER

Ana Craciun, Leila Duarte, Pedro Antunes Meireles, João Madeira Lopes, João Meneses, Rui M. M. Victorino

Serviço de Medicina 2, Hospital de Santa Maria, Centro Hospitalar Universitário de Lisboa Norte, Lisboa, Portugal

Introduction

Many cases of perimyocarditis and pericardial effusion remain idiopathic in developed countries, however it's most often caused by viral agents, followed by other causes. Very few clinical reports have been published about Chlamydia pneumoniae as a cause of perimyocarditis and even less had development of dilated cardiomyopathy.

Case description

A 37-year-old obese male, with no relevant past medical history besides rhinorrhea and odynophagia in the previous 2 weeks, was admitted at Emergency Service with 10-day evolution of daily fever 38.9°C and pain in epigastrium and right hypochondrium. Physical examination was notable for hypophonic and tachycardic heart sounds and tenderness on deep palpation in the painful areas, with no rebound. Blood tests accused leukocytosis 12350/μL, neutrophilia 10100/μL, erythrocyte sedimentation rate 116 mm, C-reactive protein 33.6 mg/dL, fibrinogenemia 1017 mg/dL and troponin 62 ng/L. Chest X-ray revealed great cardiomegaly with blunting of left costophrenic angle. Echography revealed large pericardial effusion with slight collapse of right atrium, coexisting pericardial thickening and bilateral pleural effusion. Pericardiocentesis drained 850cc of serohematic fluid whose cytology showed erythrocytes 4000/μL and cells 596/μL with 60% neutrophils and biochemical criteria compatible with exudative effusion. Echocardiogram and Myocardial Perfusion Scintigraphy showed dilated left ventricular with global hypokinesia and 40% ejection fraction, with no evidence of necrosis. Thoraco-abdominopelvic CT scan was unremarkable, as well as pericardial fluid and blood tests, except for the antibodies anti-Chlamydia pneumoniae IgA and IgG, which revealed positive. As the patient had spontaneous remission of his clinical and analytical condition, he was discharged with diagnosis of polyserositis and perimyocarditis with dilated cardiomyopathy and pericardial effusion. After 4 weeks the serology Chlamydia pneumoniae IgG and IgA continued positive, consistent with chronic infection.

Discussion

More than 50% of adults have *Chlamydia pneumoniae* specific IgG antibodies as a marker of exposure and reinfection is common. IgA antibodies are important to monitor in repeat infections, as they have a half-life of 5 to 7 days. Besides the spontaneous remission observed, as persistence of the short-lived specific IgA antibodies may be taken as an indication of chronic infection, we can't exclude it as the cause of this clinical picture.

#2156 - Medical Image

PEDICULATED MASS OF THE AURICULAR FACE OF THE ANTERIOR MITRAL VALVE LEAFLET - NOT EVERYTHING IS WHAT IT SEEMS

Mariana Simoes, Viorela-Bianca Cristea, Ana Margarida Monteiro, Maria Sousa Uva, Luiz Menezes Falcao
Medical Center Lisboa Norte, Lisboa, Portugal

Clinical summary

A 71-year-old female patient, with cardiovascular risk factors with target organ lesions was admitted to our department with severe sepsis associated with urinary tract infection with methicillin-resistant *Staphylococcus aureus* in urine culture and bacteremia. Cardiac auscultation showed a mild grade III/VI holosystolic murmur audible throughout the precordium.

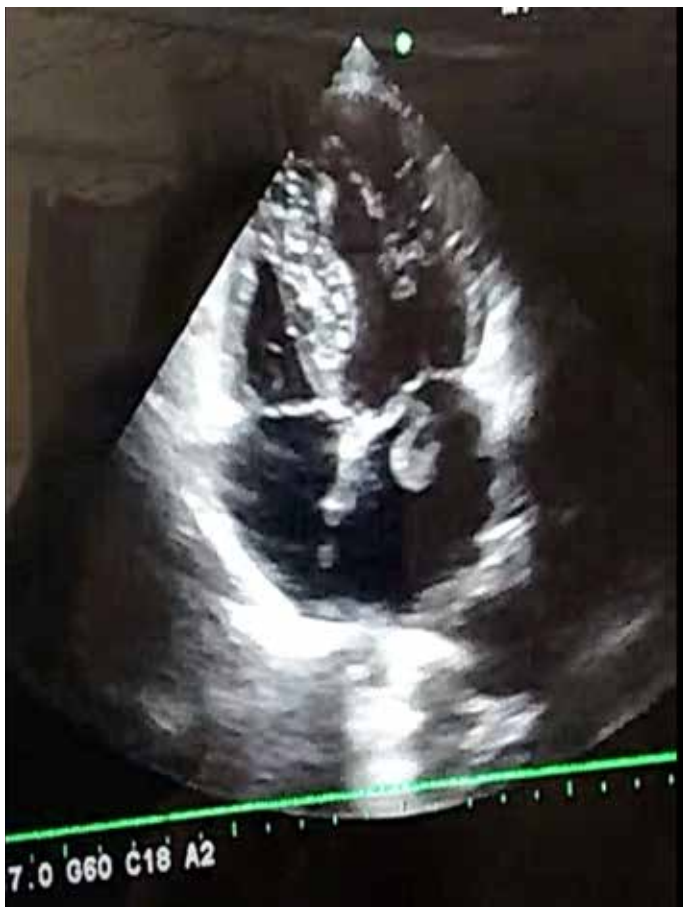

Figure #2156.

To exclude infectious endocarditis, a transthoracic echocardiogram was performed and revealed a pediculated mobile mass on the atrial face of the anterior leaflet of the mitral valve, with a fibroelastic appearance, conditioning mild to moderate mitral insufficiency. This mass was not suggestive of vegetation and raised the possibility of a papillary fibroelastoma. The histological examination revealed it to be, after all, a thrombus.

#2162 - Abstract

DIRECT ORAL ANTICOAGULANTS IN OLDER REAL LIFE PATIENTS WITH NON VALVULAR ATRIAL FIBRILLATION

Renato Guerreiro, Susana Quintão, Catarina Bastos, Juliana Campos, Inês Sarmento, Maria João Correia, Catarina Rodrigues, José Guia, Filipa Marques, Inês Araújo, Ana Leitão, Cândida Fonseca

Oral Anticoagulation Clinic, Hospital de São Francisco Xavier, CHLO, Lisbon, Lisbon, Portugal

Background

Direct oral anticoagulants (DOACs) have become the first line therapy for anticoagulation of patients with non valvular atrial fibrillation (AF) over the last decade. Four drugs of this class have been approved: apixaban, dabigatran, edoxaban and rivaroxaban. They share similar indications and contraindications, but have different dosage adjustment algorithm according to patient's characteristics. Considering the heterogeneity between population in different studies, comparisons head-to-head are not possible, neither between trials populations and real life patients. The aim of our work is to evaluate feasibility and safety of DOACs prescription in the patient's with AF to prevent embolic events, and the occurrence of a hemorrhagic event in patients on long-term anticoagulation over 8 years, monitored in our anticoagulation clinic.

Methods

In a population on oral anticoagulation (OAC) with DOACs, patients with AF were systematically monitored through the Gota v.8.1.3 program, in a nursing consultation with medical support, for 8 years, according to the recommendations of the European Heart Rhythm Association (EHRA). Major thrombotic and hemorrhagic events were analysed.

Results

Total of 523 patients with AF on OAC with DOAC were evaluated, 49.33% men, mean age 77 years (SD 9.8). In this population, 127 (24.28%) patients were on apixaban, 125 (23.90%) on dabigatran, 71 (13.58%) on edoxaban and 200 (38.24%) on rivaroxaban, with dose adjustments for comorbidities. Mean age of each group was 79.4 (DP 8.3), 76.4 (DP 9.4), 77.4 (DP 10.4) and 76.4 (DP 10.4), respectively (P: NS). Concerning major ischemic events, there were 3 cardioembolic strokes in the group of apixaban, with none occurring in the dabigatran, edoxaban and rivaroxaban

groups. Regarding major hemorrhagic events, a total of 19 cases (3.6%), respectively: 3, 4, 1 and 11 were observed in the apixaban, dabigatran, edoxaban and rivaroxaban groups. There was a statistically significant difference between the rivaroxaban and apixaban groups (Tukey's test-95% confidence interval [- 0.045 - 0.017], (P=0.02) with respect to the occurrence of stroke. There were no statistically significant differences between the other groups. There was no statistically significant difference between any of the groups for bleeding events.

Conclusion

Our work was able to demonstrate that, in this real life population, the occurrence of cardioembolic / hemorrhagic events was rare, reinforcing the position of DOACs as first-line drugs even in older patient's.

#2169 - Case Report

PULMONARY ADENOCARCINOMA PRESENTING AS BILATERAL INTERNAL JUGULAR VEIN THROMBOSIS

Guilherme Assis, Joana Rua, Daniela Viana, Nuno Ferreira Silva, Romeu Pires, Paula Vaz Marques
Hospital São Pedro de Vila Real, Vila Real, Portugal

Introduction

Multiple conditions can manifest as cervical edema, deep venous thrombosis (DVT) is one of them. Among this group, internal jugular vein thrombosis (IJVT) is a rare primary presentation and its bilateral involvement is even less common. We are reporting a case of spontaneous bilateral IJVT as a presentation of a pulmonary adenocarcinoma.

Case description

A 54-years-old man presented at the emergency room with bilateral cervical edema also involving the right hemiface, with 3 days evolution and associated pain and redness. Over the last 6 months, he described progressive asthenia, cough and night sweats, whilst, with 3 months evolution, he reported insidious dysphagia and reported episodic cervical edema and hoarseness with spontaneous remission. Recently, due to weigh loss, he conducted routine blood tests, upper endoscopy, colonoscopy and chest x-ray: all negative. Background included past smoking (40 UMA), hypertension, hypercholesterolemia, impaired glucose tolerance, alcohol abuse. No relevant family history was found. Cervical CT showed "scarce ganglionic formations on the internal jugular and supraclavicular levels; suspected IJVT". CTA confirmed "bilateral IJVT, distention of the right internal jugular vein, partial occlusion of both brachiocephalic trunks and left pleural effusion". Once admitted, he initiated anticoagulation with enoxaparin 1mg/kg bid. Further tests revealed normal ferritin, homocysteine, protein electrophoresis, autoimmune study and tumour markers – except CA-125 122U/mL. Biopsy of a supraclavicular nodule revealed "carcinoma, TTF1 negative, low probability of primary

thyroid or pulmonary". Abdominopelvic CT added "disperse mediastinal adenopathy and pulmonary nodules". He later conducted a transbronchial biopsy of the largest mediastinal nodule – subcarinal - that, despite the previous immunophenotypic profile, confirmed stage IV primary pulmonary adenocarcinoma.

Discussion

Spontaneous bilateral IJVT is a rare diagnosis. Local causes have to be excluded - infection (Lemierre's syndrome, sinusitis, otitis), central venous catheter, pacemaker and IV drugs abuse – as well as systemic causes - hypercoagulability state, myeloproliferative diseases, oestrogen use, pregnancy, ovarian hyperstimulation syndrome and neoplasia. Regardless of the involved vascular territory, it is important to search for an oncologic cause, frequently associated to DVP.

#2187 - Case Report

HEYDE SYNDROME: A DIAGNOSIS TO REMEMBER

Rafaela Pereira, Rosário Blanco, Catarina Cunha, Ana Rita Clara, Alexandra Martins, Mário Lázaro
CHUA Faro, Faro, Portugal

Introduction

Blood loss from gastrointestinal tract is one of the biggest cause of iron deficiency.

Angiodysplasia of the small bowel should be considered in the differential diagnosis of gastrointestinal bleeding (GB) when no source of bleeding was identified after a thorough examination. Bleeding from angiodysplasia in patients with aortic stenosis (AS) is designed Heyde syndrome.

Case description

A 70-years-old male patient, with past medical history of heart failure in the context of severe AS, arterial hypertension, atrial fibrillation anticoagulated with warfarine, type 2 diabetes mellitus and obesity, was sent to an Internal Medicine appointment after multiples episodes of acute heart failure symptoms despite optimal medication.

He referred some episodes of hematochezia and the complete study performed revealed an iron deficiency anemia (hemoglobin 10 g/L). It was assumed to be the cause of recurrent heart failure symptoms. Warfarine was changed to a new oral anticoagulant and was performed an upper endoscopy and colonoscopy that were negatives for bleeding.

Although the adjustment in the medication he was still with episodes of hematochezia and after a week of worsening weakness he was admitted to the emergency department. At the admission his vital signs and his physical examination were normal but laboratory tests showed an hemoglobin even lower (60 g/L). Without no other bleeding source evident, he performed a video capsule endoscopy that was consistent with bleeding angiodysplasia in small bowel and the diagnosis of Heyde syndrome

was made. The patient proceeded to aortic valve replacement and one year later he had normal hemoglobin values without episodes of gastrointestinal rebleeding.

Discussion

The association between AS, iron deficiency anemia, bleeding and angiodysplasia need to be recognized. A possible mechanism by which AS may lead to the development of angiodysplasia is through the development of an acquired form of von Willebrand disease that leads to GB. This case supports that hypothesis because after the valvular replacement none episode of significant bleeding was observed.

Until the valve replacement the management of anticoagulant therapy was challenging. In one hand the anticoagulation was absolutely necessary but, in the other hand, the patient was bleeding and needed to be transfused what represented always a risk due to heart failure. Evidence is lacking to support a specific approach.

#2198 - Case Report

PLATYPNEA-ORTHODEOXIA: TWO STORIES, TWO HAPPY ENDINGS...

Daniela Félix Brigas, Francisca Santos, Margarida Madeira, Gonçalo Mendes, Susana Marques, Ermelinda Pedroso
Setúbal Hospital Center, EPE, Setúbal, Portugal

Introduction

Platypnea-orthodeoxia syndrome (POS) is an uncommon condition of positional dyspnoea and hypoxemia, in which symptoms occur when the patient is upright and resolve with recumbency.

We report two different cases that illustrate the challenge of this diagnosis.

Case description

First case is referring to a 77 years old man who was admitted after two months of cough and progressive dyspnoea that improved with lying supine. Arterial blood gas measurement presented O₂ saturation of 84%. Transthoracic echocardiogram documented a paradoxical movement of interventricular septum and right ventricular overload. It was excluded pulmonary thromboembolism and thoracic angiotomography showed only sequelae lesions of fibrotic nature. During hospital stay, it was perceived that hypoxemia was positional, occurring while the patient was upright and resolving while he was recumbent. Transesophageal echocardiogram (TEE) showed interatrial communication, ostium secundum type, with a bidirectional shunting. Posteriorly, patient underwent a successful percutaneous closure of communication, with a final good result and no residual shunting. After the procedure, there was a significant clinical improvement, with no difference of peripheral saturation with positional variation.

Second case is about a 53 years old man with smoking habits who was admitted with a diagnosis of pneumonia. He presented a marked hypoxemia of difficult resolution even after antibiotic

treatment, which worsened with orthostasis. A structural pulmonary disease was excluded, through the performance of computed tomography and bronchofibroscopy. TEE documented a patent foramen ovale with a right-to-left shunting, which was accentuated with 45° head-of-bed elevation, as well as a left atrial appendage (LAA) vegetation. Since *Staphylococcus hominis* was isolated from blood cultures, it was assumed acute endocarditis, which was treated with vancomycin. There was a major clinical improvement and a second TEE showed a free LAA and a bidirectional shunting with no positional variation. It was assumed resolution of POS after treatment of infectious complication, with no need of immediate surgery.

Discussion

These two cases, with very distinctive functional and anatomic components, illustrate the challenge of understanding the exact mechanism by which POS results in clinical symptoms. A suggestive history and positional variation of O₂ saturation are very useful clues for its diagnosis in cases of unexplained hypoxemia.

#2199 - Abstract

READMISSIONS IN HEART FAILURE IN AN INTERNAL MEDICINE DEPARTMENT: A NINE-YEAR COHORT STUDY.

Sílvia Santos Pereira, Rita Homem, Joana Lopes, Eugeniu Gisca, Catarina Valadão, Francisca Delerue, Mário Amaro, Vanda Spencer

Hospital Garcia de Orta, Almada, Portugal

Background

Heart failure (HF) is a chronic and progressive illness with a high prevalence in the elderly. The admissions and readmissions in HF carries out a reduction in life quality, an increase in morbimortality and a burdensome for the healthcare system.

Methods

The authors aim to characterize patients admitted for acute HF in an internal medicine department and the rate of mortality and readmission.

This is a retrospective observational study enrolled all patients discharged from 2008 to 2016 with a primary diagnosis of HF according to International Classification of Diseases (ICD-9). Clinical records and discharged summaries were analysed.

Results

From 2008 to 2016 there were 3190 patients admitted with HF, with a mean age of 77.69 years and 56% of female. In-hospital mortality was 15.5% and the overall mortality in nine years was 54.3%. The most prevalent comorbidity was hypertension, diabetes mellitus and dyslipidaemia.

The readmission rate was 24.3% (775 patients), with a mean of 1.67 readmission per patient (1-19) and the mortality rate in nine years was 51.3%.

Conclusion

The high readmission and mortality rate is due by the temporal inclusion and by the complexity of the patients. It is necessary more studies in HF to understand the real extent of readmissions and to develop measures to decrease it.

#2209 - Medical Image

INTRACARDIAC MASS: WHEN CLINICAL PRESENTATION DIFFERENTIATE BETWEEN ENDOCARDITIS AND MYXOMA

Paulo Almeida, Diana Carvalho, Tiago Rabadão, Margarida Eulálio, Manuela Vieira, Ana Araújo, Eliana Araújo
Centro Hospitalar do Baixo Vouga, Aveiro, Portugal

Clinical summary

Echocardiography is a valuable method for the differential diagnosis of intracardiac mass. Image 1 - voluminous echodense vegetation, friable and adherent to the ring of the mitral valve in a patient with fever, a grade 3/6 apical holosystolic murmur radiating to the axilla and bacteremia by *Staphylococcus aureus*. The final diagnosis was infective endocarditis. Image 2 - echogenic, filiform, mobile and pediculated image, adherent to the interatrial septum in an asymptomatic patient. It was suggestive of left atrial myxoma. It is understandable that a large vegetation on the mitral valve could mimic a left atrial myxoma, on the echocardiogram because of their similar size and site. However, clinical presentation is essential for the differential diagnosis between a myxoma and endocarditis.

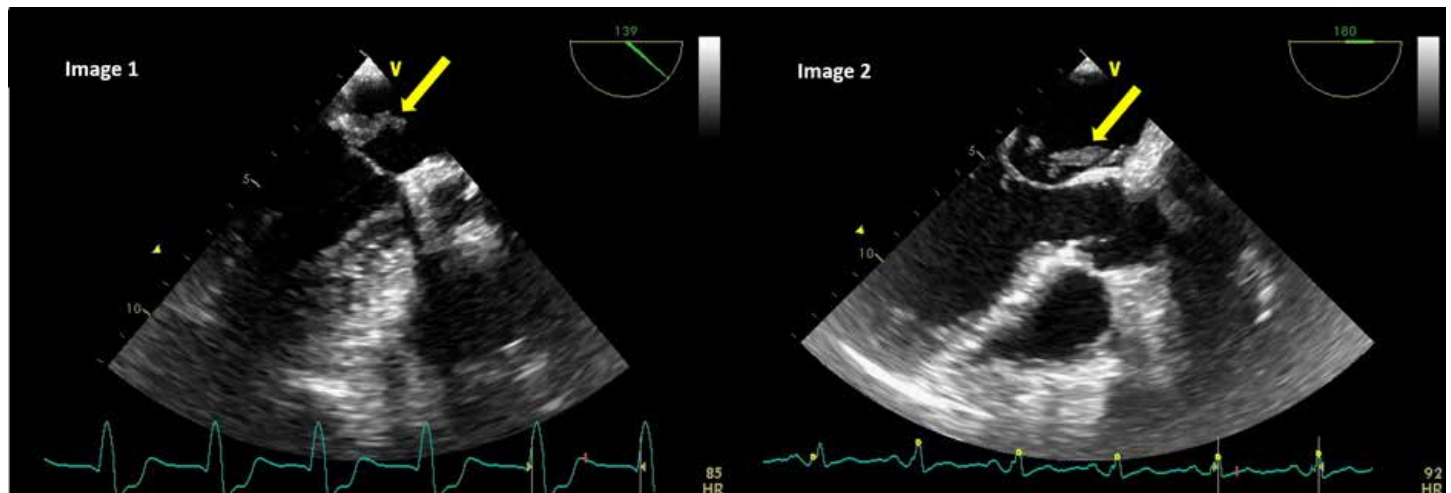


Figure #2209.

#2214 - Case Report

STRESS CARDIOMYOPATHY - THE GREAT IMITATOR

Andreia M. Teixeira, Carla Pereira Fontes, Samuel Fonseca
Centro Hospitalar Entre Douro e Vouga, Santa Maria Da Feira, Portugal

Introduction

Stress cardiomyopathy is characterized by transient regional systolic dysfunction of the left ventricle, but with unobstructed coronary arteries at coronary angiography. The hallmark is the presence of emotional or physical trigger, usual with negative character, which appears to precipitate the event. The pathogenesis is unknown, being postulated mechanisms involving excess of catecholamine, microvascular dysfunction and coronary spasm.

According to literature, it accounts for around 7% of all patients with presumed myocardial infarction and is more prevalent in females.

Case description

A 70 year old man with hypertension and clear cell renal carcinoma was admitted to the emergency room with chest pain and left arm

parathesias one day after initiating treatment with Pazopanib, a tyrosinase kinase inhibitor. He presented with hemodynamic stability and hypofonetic heart sounds on auscultation and no other alterations on physical exam. The electrocardiogram showed 1 mm elevation of ST segment at DI, aVL, v1 and v2 derivations associated with progressive rising of myocardial injury biomarkers with high sensitive troponin I, that raised to 1548.1 ng/L. Echocardiogram showed left ventricle depression (35% by Simpson biplane) and apical left ventricle hypokinesia. Coronary angiography was performed and revealed no coronary obstruction. There was a decrease in troponin I to normal values, electrocardiogram with anterior bundle of left branch block and after 2 days of hospitalization, echocardiogram was repeated and showed recovery of left ventricle function (62% by Simpson biplane) with little regional apical wall abnormal motion.

Discussion

A few cases of reversal ventricular dysfunction by pazopanib are described in literature, although it usually courses with heart failure symptoms and after a short period of treatment, which made it unlikely, in this case, as the symptoms started after one day of therapy.

Stress cardiomyopathy has a clinical presentation that mimics acute myocardial infarction. In most cases the diagnosis is established after a normal coronary angiography, although coronary disease may be present obviating a definitive diagnosis, which raises the suspicion of an underestimated prevalence. Although an increasingly recognized condition, a lot is to uncover in order to establish a consensual approach to this entity.

#2224 - Case Report

PSEUDOANEURYSM OF THE RIGHT SINUS OF VALSALVA

Cátia Carvalho

Centro Hospitalar Universitário de Lisboa Central - Hospital Santo António dos Capuchos, Lisboa, Portugal

Introduction

The pseudoaneurysms of sinus of Valsalva is a serious and rare complication of an infection, trauma or as a complication of a cardiac surgery or procedure.

Case description

We present a caucasian 71 years-old man with hypertensive and valvular cardiopathy (Class III NYHA), under anticoagulation for mechanic valvular prosthesis on both mitral and aortic positions, since 5 years ago. Two days ago, he started with fever and urinary symptoms (pain and sudden urges peeing) and on evaluation he was febrile, hypotensive, pale, without heart murmur, abdominal pain and bilateral oedema of the lower limbs. Laboratory investigation showed neutrophilic leukocytosis (Leu 12,520, Neut 10,150) and a positive c-reactive protein (147 mg/L), an infected urine (40/uL leucocits and presence of nitrites), the x-ray revealed cardiomegaly and electrocardiogram was normal sinus rhythms. It was empirically initiated Ceftriaxone and the cultural exams (blood and urine) revealed an *Enterococcus faecalis* with the increment of Ampicilin due to antibiograma. For the maintaince of the febrile condition, he did a transthoracic echocardiography that showed anterior aortic prosthetic insufficiency, mitral prosthetic valve without alterations, mild hypertrophy of the left ventricle (LV) with dysfunction (ejection fraction: 48%) and inferior septum hypokinesia; which was complemented with a transesophageal ecocardiography that revealed a mitral vegetation (6x4 mm) and a round struture near to the right valsalva sinus (30x30) wich coul be a pseudoaneurysm with a filiform mobile struture (6x2.5 mm) wich could be one more vegetation. He did also a cardiac angioCT that revealed a huge pseudoaneurysm (63x35x48mm) on the LV between aortic and mitral valves, being accepted to cirurgical treatment with the replacement of aortic prosthesis and colocation of Freestyle porcine bioprosthesis on aortic position. He charged one month later, asytmatic.

Discussion

This case re-inforces the team work and the interaction between all the specialities for the great outcome. What seemed to be a urinary infection was a really life threatning clinical condicion.

#2226 - Abstract

NEUTROPHIL-TO-LYMPHOCYTE RATIO AND PLATELET-TO-LYMPHOCYTE RATIO AS PREDICTORS OF VENOUS THROMBOEMBOLISM: A RETROSPECTIVE, SINGLE-CENTER ANALYSIS

João Gramaça, Sara Garez Gomes, Mónica Fidalgo Silva, Teresinha Ponte, Filomena Carneiro, Fátima Campante
Centro Hospitalar Barreiro Montijo, Barreiro, Portugal

Background

There is recent data towards a superiority of the neutrophil-to-lymphocyte ratio and the platelet-to-lymphocyte ratio (PLR) as predictors of the presence or absence of deep vein thrombosis (DVT) when compared to the D-dimer test, the former with a 90.2% sensitivity when ≥ 3.4 and the latter with a 89% specificity when ≥ 230 ; when both positive, the data suggests a 100% specificity, a predictive power greater than the aforementioned D-dimer test when ≥ 500 ng/mL. Despite this, the evaluation included only DVT and excluded the many causes for secondary venous thromboembolism (VTE). We retrospectively evaluated the hypothetic value in a real-life setting of these predictive and readily accessible markers.

Methods

Of a sample of 26 patients hospitalized in a medical ward throughout a 2 year span due to VTE or other causes with a diagnosis of VTE during the hospitalization and without clinical signs of infection we retrospectively evaluated the NLR and PLR at the moment of diagnosis. In all of the cases there was a D-dimer test ≥ 500 ng/mL. We included any type of VTE; we excluded patients treated with imunossupressor drugs or with haemotological malignancy.

Results

In the analyzed sample we had 53.85% with a DVT diagnosis, 57.69% with pulmonary embolism (PE) and 11% with VTE at other anatomical sites. 30.1% of the diagnosed VTE had a NLR < 3.4 and only 1 case (3.85%) had a PLR ≥ 230 ; broadening the PLR cut off to 200 increased the percentage to 26.92%. When looking at the cases with a "double positive" ratio, there were 6 cases (including the solitary one with a PLR > 230); there was one instance of a negative NLR and a positive PLR. Interestingly, in the 8 cases with a NLR < 3.4 , there were 6 with only PE or VTE at other site diagnosed and 2 with only DVT diagnosed. When comparing to studies that included just DVT, the NLR ≥ 3.4 was present in 85.71% of the analyzed DVT cases; looking solely at PE cases, the ratio was positive only in 66.67%.

Conclusion

The authors recognise the sample is small, and that there's a selection bias when looking retrospectively only to patients admitted to a medical ward. Nevertheless when applying these markers to a real-life setting by including a more broad group of

patients, as well as both DVT and PE, we distinguish some putative limitations in its use without the backup of other lab tests. Despite this, these ratios could be valuable when included in composite predictive scores, such as Well's criteria for DVT and the Geneva score for PE.

#2231 - Case Report

A RARE CAUSE OF ACUTE HEART FAILURE

Sara Sarmento Rodrigues, Ana Carmo Campos, Isabel Cruz Carvalho, João Freitas Silva, Marco Narciso, Teresa Fonseca
Hospital Pulido Valente, Centro Hospitalar Lisboa Norte, EPE, Lisboa, Portugal

Introduction

The diagnosis of myocarditis is challenging due to its clinical heterogeneity. Although myocardial biopsy is the gold standard in the diagnostic and prognostic evaluation, its rarely done because of its low sensitivity and invasive approach. Myocarditis accounts for about 9%-16% of cases of non-ischemic dilated cardiomyopathy and about 2-42% of cases of sudden death in young adults. The etiology of myocarditis includes infectious and non-infectious causes and toxic myocarditis is rare. Hydrocarbons, present in paints and solvents, are cardiotoxins potentially causing myocarditis, heart failure and sudden death and in rare cases they may be associated with cardiomyopathy.

Case description

We present a case of a 77-year-old man with an history of cardioembolic AIT due to atrial fibrillation, who presented with a 3-week history of palpitations, chest pain, progressive exertional dyspnea, paroxysmal nocturnal dyspnea and peripheral edema. The patient had no previous heart failure (HF), with an echocardiogram with good global systolic function. In the current episode, the patient had a class III NYHA HF, NT-proBNP elevation (3033pg/mL), normal Troponin T (14 ng/L). Transthoracic echocardiography revealed dilated cardiomyopathy, 33% of ejection fraction and diffuse hypokinesia. Of the remaining etiological studies we highlight negative viral serologies (Borrelia, Coxsachie, HCV, HBV, CMV, EBV, Adenovirus, Lyme D., Rubeola), normal coronary angiography, normal ventilation/perfusion lung scintigraphy and normal thyroid function. The patient reported an exposure, 2 weeks before, to paints and thinners containing halogenated hydrocarbons in great concentration, without protection of the airway. He denied contact with other substances, drugs or recent infections. Dilated cardiomyopathy was assumed to be in the context of acute toxic myocarditis, and therapy was optimized. The echocardiographic reassessment at 5 months showed an important improvement, with an ejection fraction of 43%, presenting a clinical improvement (class I NYHA).

Discussion

This case presented contemplates the criteria for diagnosis of myocarditis, excluding the most common etiologic causes,

assuming a probable toxic etiology, which is a rare cause of acute heart failure, alerting to the importance of high diagnostic suspicion and an exhaustive context of exposure. Ultimately, the patient was spared a myocardial biopsy and was given a presumptive diagnosis of myocarditis based on the clinical and exposure context.

#2236 - Abstract

CARDIOVASCULAR RISK FACTORS PREVALENCE IN PATIENTS ADMITTED TO THE INTERNAL MEDICINE WARDS IN A UNIVERSITY HOSPITAL

Penelope Almeida, Sara Pires, Luísa Serpa Pinto, Guiomar Pinheiro, Carolina Silva, João Araújo Correia
Centro Hospitalar do Porto, Porto, Portugal

Background

Cardiovascular diseases remain as one of the most important causes of death and morbidity in Portugal despite all efforts. The high prevalence of all modifiable cardiovascular risk factors (CVRF) allied to the progressive population-ageing contribute to this scenario. Therefore all knowledge about the aforementioned CVRF is of great matter for the internal medicine physician.

Methods

Retrospective cohort of patients admitted at the Internal Medicine wards of a University hospital, between January 1st of 2015 and December 31st of 2018. Analysis of demographic characteristics and comorbidities. Categorical variables presented as absolute or relative frequency, continual variables presented as medium and standard deviation. The IBM® SPSS Statistics® software was used (version 24).

Results

Of the 2130 enrolled patients, 1172 (55%) were man and the medium age was 74 years (SD +/- 15.5). The overall mortality rate was 11.3% (n=241). 1686 patients had at least one cardiovascular risk factor (CVRF). These patients presented a medium age of 75.4 years (SD +/- 13.8), the majority were man and the mortality rate in this group was 9.8% (n=186). Arterial hypertension (AH) was the most common modifiable CVRF (n=1353, 80.2%), followed by dyslipidaemia (n=912, 54.1%), diabetes mellitus type 2 (n=659, 39.1%), obesity (n=415, 24.6%), active smoking (n=247, 14.7%) or previous smoking (n=371, 22.0%) and hyperuricemia (n=181, 10.7%). When reviewing data by gender, we verified that the prevalence of AH (84.7% vs. 76.6%, p<0.001), dyslipidaemia (58.6% vs. 50.6%, p=0.001) and obesity (31.6% vs. 19.0%, p<0.001) was superior in woman than in man. On the other hand, woman presented an inferior prevalence of active smoking (5.4% vs. 22.1%, p<0.001) or previous smoking (2.5% vs. 37.7%, p<0.001), and also hyperuricemia (11.5% vs.17.2%, p=0.006). The prevalence of diabetes mellitus type 2 didn't change between genders (40.9% vs. 37.6%, p=0.170).

Conclusion

Interestingly, some of our results are substantially different from what we know about the general Portuguese population. This is probably related to the older medium age of the cohort, the majority being post-menopausal woman, but can also mirror a growing tendency of the prevalence in CVRF in woman.

#2239 - Abstract

EVALUATION OF VENOUS THROMBOPTOPHYLAXIS IN MEDICAL PATIENTS ADMITTED TO A INTERNAL MEDICINE WARD OF A GENERAL HOSPITAL

Gonçalo Miguel Amaral Mendes, Margarida Madeira, Mafalda Figueira, Ana Catarina Emídio, Daniela Brigas, Francisca Santos, Diana Neto, Eugénio Dias, Clara Rosa, Ermelinda Pedroso
Centro Hospitalar de Setúbal, Setúbal, Portugal

Background

Traditionally, venous thromboembolism (VTE), which is defined as a deep venous thrombosis (DVT) and pulmonary embolism (PE), is usually considered a complication of major surgery. However, this view has been changing over the last years. The hospitalization for a nonsurgical acute disease is associated with a rise of the VTE risk. The primary objective of this study was to assess which patients were at risk of a VTE and evaluate if those receiving prophylaxis were receiving the appropriate drug in the right dose and frequency. The secondary objective was to determine if the patients suffered a major adverse event during their stay and up to 30 days after discharge.

Methods

The authors performed a retrospective cross-sectional study involving inpatients in the adult internal medicine ward in January 27, 2019. Patients with length of stay less than 48 hours were excluded. In order to assess the risk of VTE the Padua Prediction Score (PPS) was implemented and patients divided in two categories; low-risk for VTE (<4 points), and high-risk for VTE (≥ 4 points).

Results

Of the 59 patients, 26 patients (44%) were female and 33 (56%) patients were male. The mean age was $80,15 \pm 12,99$ years. Atrial Fibrillation (AF) was present in 22 (37%) patients, with a median HAS-BLED of $3,2 \pm 1,03$, of those, 18 (30,5%) patients were already under hypocoagulation, the majority 77,8% ($n=14$), using direct oral anticoagulants.

When we evaluated VTE risk, 53 patients (89,84%) had a PPS ≥ 4 . 42 (71,2%) patients were under anticoagulation, and from this, 18 (42,8%) were not receiving the correct dose. 15 (83,3%) were having underdosage and 3 (16,7%) an excessive dosage. 17 patients who were not receiving thromboprophylaxis, 12 (70,5%) had a PPS ≥ 4 .

Patients did not have an adverse event during their stay or at 30 days after discharge. We were unable to correctly evaluate and

quantificate minor adverse events like local hematomas, however their presence was frequent.

Conclusion

These results provide insight into prescribing patterns. Thromboprophylaxis was inappropriate in 18 patients, 15 of them underdosed and 3 with an excessive dose. 12 patients that had high risk for VTE were not under hypocoagulation, for unknown reason not presented in the clinical file. In order to improve this outcomes, an internal orientation was approved and another evaluation will be made after its implementation.

#2241 - Medical Image

INFECTIOUS ENDOCARDITIS : UNUSUAL CAUSE OF LOWER BACK PAIN

Ivan Cadena, Ana Moura, Joana Canadas, Soraia Teixeira, Manuela Grego, Maria Luz Pitta, Luis Siopa
Hospital de Santarem, Santarem, Portugal

Clinical summary

A 78-year-old woman, with biological aortic prosthesis and atrial fibrillation, was admitted due to low back pain for 3 weeks and severe gait limitation. At the physical exam presented degree III/VI systolic murmur and palpation of low back. Lumbar CT scan revealed "multiple osteolytic lesions in the lumbar bodies". After hospital admission there was fever and cutaneous lesions in the foot. *S. epidermidis* methicillin resistant cultured in the blood. Echocardiogram revealed a vegetation on the biological prosthesis in aortic position. MRI lumbar scan showed diffuse alteration of the D12 and L1, translating inflammatory changes in the context of spondylodiscitis". Vancomycin and rifampicin was administered for 6 weeks, before transitioning to linezolid at completion of 12-week for spondylodiscitis.

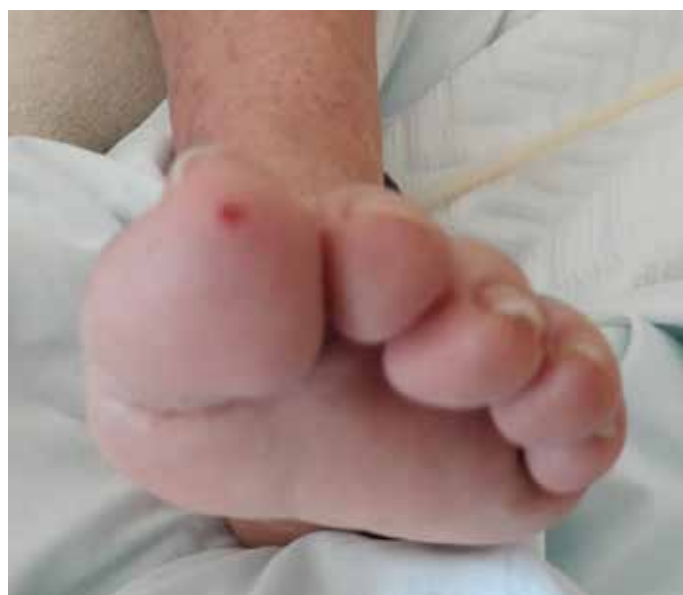

Figure #2241. Janeway cutaneous lesions in the plantar region of the foot.

#2256 - Case Report

LOOKING BEYOND THE RESPIRATORY INFECTION: A DEADLY INTRA-CARDIAC MASS

Vanessa Machado¹, Paulo Ferreira¹, Cristina Ramalho¹, Hilda Freitas², António Cabral², Natália Oliveira²

¹ Trofa Saúde Hospital em Braga Centro, Braga, Portugal

² Trofa Saúde Hospital em Braga Sul, Braga, Portugal

Introduction

Cardiac masses are rare entities that can be broadly categorized as neoplastic or non-neoplastic. Echocardiography is the first-line imaging modality for assessment of intra-cardiac masses. Primary cardiac tumors have a prevalence of 0.001 to 0.03 % in an autopsy series, while metastatic tumors are 20 to 40 times more common. Primary cardiac malignant tumors account for 25% and sarcoma is the most prevalent. Other masses that mimic cardiac tumors include thrombi, pericardial cysts, prominent anatomic structures.

Case description

A 82-year-old man with a medical history of bladder cancer, chronic bronchitis and cardiovascular risk factors was admitted to the Emergency Department of our private hospital with symptoms including cough, mucopurulent sputum and fever. After complementary study, a community respiratory infection hypothesis was assumed and the patient was discharged with empirical antibiotherapy and supportive medical care. A week later, the patient was admitted again to the Emergency Department with maintained cough, mucous sputum expectoration difficult to expel, anorexia and adynamia.

The hypothesis of respiratory infection remained, however because of the presence of elevated inflammatory parameters, anaemia and d-dimer elevation, septic screening was performed and a new antibiotic scheme was started. Computed tomography with angio-tomography was performed. The latter pointed out an intra-cavitary hypodense material (in the right ventricle) with extension to the origin of the pulmonary trunk, possibly related to intra-cardiac thrombus. It also revealed bilateral acute pulmonary thromboembolism, cardiomegaly, bronchiectasis, and pulmonary consolidation. Heparinization was administered. In the attempt to achieve a diagnosis, the echocardiography revealed an intra-ventricular thrombus versus a tumor mass, associated with signs of pulmonary hypertension. Other exams included an urgent request for cardiac magnetic resonance imaging.

The patient presented clinical stability, without complications. The control echocardiography revealed that the intra-ventricular mass had a greater extension, was friable and mobile, conditioning a potential catastrophic embolization. The patient was transferred to a public hospital, evolving briefly to a fatal outcome.

Discussion

The evaluation of cardiac masses may be a diagnostic challenge. We emphasize that it is necessary to valorize the patient's symptoms especially after repeated hospital admissions.



CEREBROVASCULAR AND NEUROLOGIC DISEASES

#12 - Case Report

A CASE OF GUILLAIN-BARRE SYNDROME REQUIRING MECHANICAL VENTILATION IN A 86-YEAR-OLD PATIENT

Angeliki Tsifi, Stela Stefanova, Sofia Avgeri, Evaggelia Sergi, Kyriakos Ntorlis, Anastasios Sakkalis
General Hospital of Nea Ionia -Patision Konstantopouleio, Athens, Greece

Introduction

Guillain-Barre syndrome (GBS) is an acute or subacute polyradiculoneuropathy, usually following infections, inoculations or surgical procedures. Rapid diagnosis and early treatment are important in order to improve the clinical outcome and even achieve full recovery.

Case description

We present an 86-year-old female with hypertension and a medical history of breast cancer treated with radiation and hormone therapy after its surgical removal seven years ago. The patient was originally admitted to the neurology department after a recent respiratory tract infection due to limb weakness accompanied by depressed deep tendon reflexes, which rapidly progressed to paralysis. A lumbar puncture was performed. Cerebrospinal fluid (CSF) features supported the diagnosis of GBS, since they exhibited elevated CSF protein with a normal cell count. The patient further deteriorated, she was intubated due to respiratory failure and she was transferred to the ICU after being started on intravenous antibiotics and on iv immunoglobulin (IVIG), which she received for five days. The patient was successfully extubated on day 5 of her ICU admission, her neurological status gradually improved and she was eventually transferred back to the neurology department with minor limb weakness for further management.

Discussion

Respiratory distress is the leading cause of death in GBS. After a correct diagnosis is achieved, supportive measures, treatment with IVIG or plasmapheresis and continuous monitoring of the patient should be implemented in order to avoid further deterioration and death.

#50 - Case Report

VILLARET'S SYNDROME - A RARE PRESENTATION OF SKULL BASE OSTEOMYELITIS

Rahul Unnikrishnan¹, Baiju Faizal²

¹ Rashid Hospital, Dubai, United Arab Emirates

² Lifecare Hospital, Abu Dhabi, United Arab Emirates

Introduction

Skull base osteomyelitis is a lethal condition, especially in immunocompromised and elderly individuals. Here we report a very rare case of skull base osteomyelitis, presenting as Villaret's syndrome. Our patient presented with multiple lower cranial nerve palsies with right-sided Horner's syndrome.

Case description

71 year old male, smoker & diabetic presented with reduced hearing on right side, associated with purulent discharge from both ears (right > left). Two weeks later, he presented with cough, difficulty in swallowing and hoarseness of voice with nasal regurgitation. Symptoms associated with weight loss of 14 kgs over 4 months. Examination revealed right partial ptosis, lateral gaze palsy and miosis. Bilateral loss of gag and palatal reflexes. Right trapezius and sternomastoid was weak with tongue fasciculations. Deviation of tongue to right side on protrusion. Blood investigations revealed high CRP and ESR. CT Brain revealed retropharyngeal/nasopharyngeal hypodense lesion and erosion of right petrous apex. MRI was suggestive of osteomyelitis of petrous and clivus with infection spreading to the nasopharynx. Transnasal biopsy confirmed chronic osteomyelitis

Discussion

Skull base osteomyelitis is a potentially life threatening infection that classically presents as a complication of severe external otitis, middle ear, mastoid or sinus infection and can result in multiple lower cranial nerve palsies as a result of jugular foramen involvement due to widespread involvement of the skull base. Pseudomonas Aeruginosa has been reported as the most common pathogen involved in skull base osteomyelitis. The presentation of skull base osteomyelitis as Villaret's syndrome, as in our case, is extremely rare.

#67 - Case Report

**SUBACUTE NEUROLOGIC DETERIORATION.
AN UNEXPECTED PATHOLOGICAL FINDING.**

Francisco Mula Falcón, Alberto Romero Alonso, Jose Antonio Mira Escarti

Service of Internal Medicine. Hospital de Valme, Sevilla, Spain

Introduction

Osmotic demyelination syndrome (ODS) develops after rapid correction of severe hyponatremia and can result in serious irreversible neurological consequences if it is not early diagnosed. Clinical manifestations of ODS are quite diverse and typically delayed several days after correction of hyponatremia, making diagnosis truly challenging.

We present a case of a patient with family history of neurodegenerative disorders that developed a rapidly progressive parkinsonism syndrome, dementia and altered mental status several days after correction of hyponatremia.

Case description

A 74-year-old woman was admitted for a 2-week history of asthenia, unsteady gait and bradypsychia. Her family history was notable for Parkinsonism and rapidly progressive dementia in her father. Examination was unremarkable except for time and spatial disorientation and bradypsychia. Laboratory testing showed a hyponatremia of 110 mEq/l with serum hypotonicity. Three days later, sodium was corrected to 134 mEq/l and the patient experienced a clinical improvement.

On the fifth day her condition worsened and drowsiness, tremor, rigidity and myoclonus developed. The patient died after progressive neurologic deterioration. Autopsy was performed and showed findings compatible with ODS. 14.3.3. protein in cerebrospinal fluid was negative.

Discussion

ODS can manifest with a great variety of neurological manifestations, some of them serious and irreversible if it is not early diagnosed. Since it usually occurs a week after correcting hyponatremia, it is important to keep it in mind in patients with history of corrected hyponatremia who later develop neurological symptoms. The best treatment is prevention, which is why the rhythm of correction of hyponatremia is crucial.

#108 - Abstract

**CLINICAL FACTORS RELATED TO MORTALITY
AND DEPENDENCE IN INTRACEREBRAL
HAEMORRHAGE – A RETROSPECTIVE STUDY**

Tiago Jorge Antunes De Sá, Francisco José Alvarez Pérez

Centro Hospitalar da Cova da Beira, Covilhã, Portugal

Background

Haemorrhagic stroke represents 10% of acute cerebrovascular accidents, with an incidence of 24,6/100000 person-year.

Intracerebral Haemorrhages (IH) are caused by a damage of intracerebral small vessels due to chronic hypertension, amyloid angiopathy or coagulopathies. This disorder has a high mortality rate during acute phase and a high risk of dependence during chronic state.

The main objective of this study is to identify epidemiological, clinical and imaging variables associated with mortality during admission and a worse functional outcome after discharge.

Methods

This was a retrospective study that included patients with IH admitted to the CHCB's Stroke Unit during January 2012-December 2016. Patients with ischemic stroke, subdural hematoma, subarachnoid haemorrhage or brain neoplasm were excluded. The information used for this study was obtained through the patient's clinical processes.

Results

A total of 122 patients were available for analysis, 72 male (59%) and 50 female (41%). Mean age was 73,5±11,78. The locations of hematoma were basal ganglia (n=73), lobar (n=36), cerebellum (n=8), brain stem (n=4) and intraventricular (n=1). Sixty-four patients developed in-hospital complications (32 pneumonia, 31 neurologic deterioration, 17 lower urinary tract infections, 19 hydrocephalus). Twenty-two patients died during admission (29,5%), 52 were dependent after discharge 47 were independent. Variables associated with in-hospital mortality were previous stroke, use of antiaggregants, higher glucose level, higher hematoma volume in CT scan, presence of peri-hematoma oedema, intraventricular haemorrhage, lower Glasgow coma scale score, higher NIHSS score, higher ICH score, occurrence of hydrocephalus and presence of neurologic deterioration.

Variables associated with dependence after discharge were age, higher total leukocyte and neutrophil count, higher neutrophil/lymphocyte ratio, higher hematoma volume in CT-scan, intraventricular haemorrhage, lower Glasgow scalescore, higher NIHSS score, higher ICH score, occurrence of pneumonia, and presence of neurologic deterioration.

Conclusion

The hematoma volumes in CT-scan, the presence of intraventricular haemorrhage, lower Glasgow coma scale score and higher NIHSS and ICH scores were associated with a significant increase of in-hospital mortality and worse functional outcomes.

#151 - Case Report

**ALTERED MENTAL STATUS WITH
HYPERTENSION: IS POSTERIOR REVERSIBLE
ENCEPHALOPATHY SYNDROME ONE OF
YOUR DIFFERENTIAL DIAGNOSIS?**

Chaozer Er, Navin Kuthiah, Nicholas Wong Wai Cheong

Woodlands Health Campus, Singapore, Singapore

Introduction

There are many causes of altered mental status (AMS). If AMS is coupled with severe hypertension, we ought to consider posterior reversible encephalopathy syndrome (PRES) as one of the differential diagnoses.

Case description

A 60-year-old Malay gentleman with past medical history of hypertension, hyperlipidaemia, diabetes mellitus and previous stroke, presented to us with 1 day history of fever and new onset of confusion. On examination, he was confused and drowsy with no local neurological deficit. The blood pressure (BP) was 210/121 mmHg on admission. Computed tomography of his brain showed diffuse cerebral oedema with no intracranial haemorrhage or acute infarct seen. Empirical intravenous Ceftriaxone, Ampicillin, Vancomycin and Aciclovir were prescribed to treat patient as a case of meningo-encephalitis. He then underwent magnetic resonance imaging (MRI) of the brain which showed extensive, symmetrical white matter changes involving bilateral frontal, parieto-occipital and temporal regions. The changes were in keeping with PRES. He was treated with intravenous labetalol and monitored closely in the high-dependency unit. His systolic BP was controlled at the range of 150-170 mmHg in the first 24 hours of admission. Further history from his wife confirmed that patient has been non-adherent to his hypertension medication for 1 year. His confusion improved with BP control. He was discharged after 2 weeks of hospitalisation.

Discussion

Patients with PRES typically present with acute onset of headache, confusion, seizures and visual disturbances. It is often associated with high BP. There are many conditions such as stroke, meningo-encephalitis, intracranial bleed and venous sinus thrombosis that can present in similar ways. MRI brain classically shows white matter oedema predominantly localized to the posterior cerebral hemispheres. The mainstay of treatment is BP control. Most patients recover within 2 weeks.

#207 - Abstract

CEREBROVASCULAR DISEASE IN ADULTS LESS THAN 55 YEARS OF AGE – A GREAT CHALLENGE?

Sara Lopes Fernandes, Adriana Bandeira, Hélia Martins, Behnam Moradi, Alcina Ponte

Leiria Hospital Center, Leiria, Portugal

Background

Stroke is an important cause of morbidity and mortality. It is more common in men over 65 years of age, however the incidence in young adults has been increasing (5-20% of all strokes). Although less frequent, it will be in this group that presents greater socioeconomic impact, by leaving patients disable during their productive years of life. This study aims to characterize a

population of patients under 55 years of age, in order to improve preventive measures.

Methods

The present study presents a descriptive and retrospective analysis of patients aged ≤ 55 years followed in a Cerebrovascular Risk Consultation, from January 2016 to December 2017.

Results

Of the 183 patients selected, 45 were under or 55 years (25%). The mean age was 48 years, 51% males. The main reason for the appointment was ischemic stroke (53%), followed by transient ischemic attack (29%) and hemorrhagic stroke (7%). Risk factors include dyslipidemia (67%), hypertension (60%), smoking (40%), alcohol (18%), diabetes (11%) and previous ischemic events (13%). The etiological study showed elevation of LDL values in 89% of the patients, changes in thyroid function in 7% and autoimmune analytical disorders in 23%; thrombophilias were positive for at least one factor in homozygosity in 37% and in heterozygosity in 48%; carotid atherosclerosis was identified in 27% of the patients, Patent Ovale Foramen in 28% and atrial fibrillation was diagnosed in 2% of the cases. During follow-up, 7% presented new cerebrovascular events, 4% convulsions and 9% minor bleeding.

Conclusion

About 25% of the patients followed in Cerebrovascular Risk Consultation were ≤ 55 years. There was a huge number of cardiovascular risk factors, making this population a high risk one before the primary event. However, it should be noted that the etiological study identified thrombophilia in about 37% of the patients and Patent Ovale Foramen in about 28%. In order to prevent cerebrovascular events in this population an aggressive medical treatment of risk factors is crucial, however it is also important to identify and treat secondary causes.

#225 - Case Report

HEMOPERICARDIUM WITH CARDIAC TAMPONADE AFTER INTRAVENOUS THROMBOLYSIS FOR ACUTE ISCHEMIC STROKE

Martim Baltazar Alçada, Marina Boticario, Guilherme Violante Cunha, Pedro Manata, Maria Filomena Roque
Hospital de Santarém EPE, Santarém, Portugal

Introduction

Hemorrhage is the major complication of recombinant tissue plasminogen activator (rt-PA) treatment for stroke. We report a case with new onset of cardiac symptoms prior to thrombolysis in whom hemodynamically significant cardiac tamponade occurred after treatment with rt-PA.

Case description

An 59-year-old woman, with history of cognitive impairment,

hyperlipidemia, epilepsy, hypothyroidism and no previous cardiac history, presented with acute right hemiparesis, dysarthria, facial paralysis within two hours of symptom onset (National Institutes of Health Stroke Scale [NIHSS], 11. On arrival to the emergency room, she was tachycardic. EKG showed atrial fibrillation with rapid ventricular response, so she initiated amiodarone perfusion. Head CT revealed neither hemorrhage nor early ischemic changes. The patient met all qualifying criteria for rt-PA. Initially, the patient had a good response to the rt-PA with improvement in function of her right side and speech. However 45 min after stopping the rt-PA the patient became extremely hypotensive with no response to aggressive fluid administration. Emergent bedside pericardial effusion with fibrin clots with evidence of atrial and ventricular collapse. Pericardiectomy was performed with 600ml of blood aspirated from the pericardial sac with rapid recovery of the hypotensive state and no subsequent bleeding complications.

Discussion

The risk of symptomatic intracerebral hemorrhage and systemic bleeding requiring transfusion, surgery or other aggressive management following administration of rt-PA in ischemic stroke has been well described. However, cases of hemopericardium and cardiac tamponade after intravenous (IV) thrombolysis for ischemic stroke are extremely rare. As in our case, small yet available evidence suggesting that acute ischemic stroke patients presenting with cardiovascular signs should receive comprehensive cardiac evaluation including an echocardiogram, prior to the treatment with IV rt-PA.

#227 - Case Report

“HAND KNOB” STROKE

Cátia Ribeiro Santos, Cátia Faria, Maria João Palavras, João Santos, Célio Fernandes

Centro Hospitalar Leiria - Hospital de Santo André, Leiria, Portugal

Introduction

Cortical ischemic stroke affecting the precentral “hand knob” area is well defined as a clinical entity. However, often its clinical presentation as a pure motor deficit without a sensory deficit and absence of cranial nerve deficit mimics a peripheral nerve damage. The most prevalent risk factors are hypertension and atherosclerosis, with embolic etiology being the most likely underlying pathophysiological mechanism.

Case description

This case report describes a male in his late 70s who presented a history of coronary disease and vascular risk factors. Admitted to the emergency department by sudden onset of motor deficit of the left upper limb with an hour and a half of evolution. It performed a cranial CT scan without revealing acute vascular lesions. Blood analyses were not significant and normoglycemia status. For suspected peripheral nerve damage also performed a cervical CT scan that revealed multiple degenerative changes of the cervical spine,

and was observed by neurosurgery that suggested an isolated motor deficit, but clinical picture not compatible with myelofascicular compression. Subsequently, he performed a reevaluation of the neurological examination, with the patient revealing mild left facial paresis, a monoparesis of the left upper limb of distal predominance (proximal grade 2, distal grade 0). Therefore, he repeated a cranial CT scan 12 hours after admission, showing a small cortical hypodensity in the right precentral gyrus, the hand motor cortex - “hand knob” area. We assumed the diagnosis of ischemic stroke with clinical presentation of isolated hand paresis (pure motor deficit).

Discussion

The presentation of this case aims to alert to a careful evaluation of the cases of acute motor monoparesis, particularly in the geriatric population with vascular risk factors, including the differential diagnosis of acute neurological syndrome and peripheral nerve damage.

#236 - Abstract

STATINS AFTER ISCHEMIC STROKE: HAVE WE CHANGED OUR CLINICAL PRACTICE?

Luis Castilla Guerra¹, Salvador Perez Galera¹, Maria Del Carmen Fernandez Moreno², Antonio Valenzuela Gonzalez¹, Miguel Angel Rico Corral¹, Miguel Colmenero Camacho¹

¹ Department of Internal Medicine. Hospital Virgen Macarena, Seville, Spain

² Department of Neurology. Hospital de Valme, Seville, Spain

Background

Statins have emerged as guideline therapy for secondary stroke prevention. We investigate long-term trends in statin use after ischemic strokes (IS)

Methods

Retrospective study on patients with IS discharged from the Departments of Neurology and Internal Medicine of the Hospital Virgen Macarena, Hospital de la Merced and Hospital de Valme, Seville, Spain, during two periods: between 1999-2001 and between 2014-2016.

Results

We studied 1575 patients, 661 (42%) women, with an average age of 69 (± 10) years. Comparing the two periods we find that now patients are older (mean age 68 ± 10 vs. 71 ± 11 , $p=0.0001$) and have higher frequency of dyslipidemia (32.5% vs 48.9%; $p=0.001$), and hypertension (67.3% vs 73.8%; $p=0.008$). At discharge statins were used in 18.9% of patients as compared to 86.9% ($p=0.0001$), with an increasing trend (1999 15.2%, 2000 15.5% 2001 24.6%-2014 81.6%, 2015 88.2% 2016 89%). Regarding the statin type: in both periods Atorvastatin was the most common prescribed (80 mg 6% vs. 42.7%; 40 mg 5.1% vs 11.1%), followed by Simvastatin (40 mg 0 vs 13.3%; 20 mg 5.8% vs. 12.1%), pravastatin, and fluvastatin; and

most recently rosuvastatin (2.6%) and pitavastatin (3.3%) ($p = 0, 0001$). High intensity statins was used in 11,1% vs. 54.4% patients ($p=0.0001$), though with similar percentage among statin users in both periods (58.7% vs. 62.6% $p=NS$).

Conclusion

There are significant changes in the use of statins in patients with IS. Currently most IS patients receive statins at discharge, though high-intensity statin treatment is clearly underused.

#257 - Case Report

HEMOCHROMATOSIS AND STROKE: AN EXCEPTION TO THE “IRON HYPOTHESIS”

Mariana Soares, Tereza Veloso, Carmen Corzo, Conceição Barata, Inês Ribeiro, Leila Barrocas
Hospital Espírito Santo de Évora, Évora, Portugal

Introduction

It has been hypothesised that increased iron stores, traduced by increased levels of ferritin, could play a role in the pathogenesis of atherosclerosis, representing an independent cardiovascular risk factor. The mechanism behind this hypothesis relies on the ability of iron to increase oxidation stress and regulate immune responses, affecting all the cells involved in the formation and destabilization of the atherosclerotic plaque. Hereditary hemochromatosis, associated in other studies with increased prevalence of ischemic stroke, seems to be an exception to this hypothesis, assuming a protective role against atherosclerosis. We present a case of stroke in a young adult, whose diagnostic study identified increased ferritin levels and made the genetic diagnosis of hemochromatosis.

Case description

A 48-years-old male presented at emergency department due to vertiginous syndrome. Besides age and gender, he presented other cardiovascular risk factors, such as obesity and smoking. The neurologic exam showed no deficits, but the brain CT showed signs of previous occipital infarcts, so we asked for an MRI of the brain, that showed atrophic areas of the left cerebellar hemisphere, probably associated to vascular etiology. The echocardiogram and the carotid dopplers were normal. We proceeded with the study of stroke in the young adult, revealing negativity of all the prothrombotic markers and a high ferritin level. The genetic test was confirmatory of hemochromatosis. The abdominal MRI showed hepatic hypertrophy and iron overload, coincident with chronic hepatopathy. The patient was referred to hepatology and immunohemotherapy consultations, starting periodic phlebotomies.

Discussion

Hemochromatosis has been postulated as protective against atherosclerosis, due to the effect of the mutation in down-regulating the expression of hepcidin, causing a selective

intra-cellular depletion of iron in macrophages, the main cells intervening in the pathophysiology of atherosclerosis. The studies associating hemochromatosis with higher prevalence of stroke, also showed no increased prevalence of carotid stenosis on these patients, suggesting that the mechanism behind this association does not rely on atherosclerosis, but is still to be unveiled. The presented case shows the importance of including ferritin in the study of patients with cardiovascular events, since it is now suggested as an independent cardiovascular risk factor, possible of being corrected with adequate diet and physical activity.

#286 - Case Report

KLUVER-BUCY SYNDROME AFTER HERPETIC ENCEPHALITIS

Raquel Costa¹, Octávia Costa², Inês Carvalho², Sara Varanda², Célia Machado², Ana Filipa Santos²

¹ ULSAM - Hospital Conde de Bertiandos, Ponte De Lima, Portugal

² Hospital de Braga, Braga, Portugal

Introduction

Kluver-Bucy syndrome is a rare entity that results from bilateral injury of the temporal lobe. It is characterized by severe cognitive and behavioral alterations, namely amnesia, visual agnosia, placidity, hypersexuality, hyperorhythmia and hyperphagia. Herpetic encephalitis is the most common infectious cause.

Case description

A male patient, 21 years old, unemployed with no relevant medical history, is taken to the Emergency Department (EM) due to an inaugural convulsive crisis. At admission he was sleepy, had no focal deficits, had no meningeal signs, and was apiretic. He underwent cranioencephalic tomography that showed no alterations, besides low cerebellar tonsils. During the stay in the EM, he had a new convulsive crisis and started a psychomotor agitation with incoherent speech. T 38 ° C was observed. It was prescribed levetiracetam (3000 mg/d) and, on suspicion of meningoencephalitis, acyclovir (750 mg 8/8hrs), ceftriaxone (2 g 12/12hrs) and dexamethasone (10 mg 8/8hrs). He performed cerebral magnetic resonance imaging that revealed bilateral hypersignal in the temporoinsular and temporomesial regions compatible with herpetic encephalitis. From the analytical study carried out to highlight anti-herpes simplex IgG and IgM antibodies positive. During hospitalization, he started to have behavioral changes, with absence of expression of emotions, hypersexuality, hyperphagia, hyperorhythmia and alotriophagy. Kluver Bucy syndrome was diagnosed. The levetiracetam was replaced by lacosamide (200 mg/d) and risperidone (0.5 mg 3/d) topiramate (100 mg/d) and fluoxetine (20 mg/d) were initiated. Fulfilled 21 days of acyclovir. At the time of discharge, he scored 24 on the MMSE; although there was some improvement of the behavior, it maintained serious alterations, namely alotriofagia.

Discussion

Kluver Bucy syndrome may rarely occur as a complication of herpetic encephalitis. The treatment of this infection with acyclovir should be initiated early and a high index of suspicion is essential. The treatment of Kluver Bucy syndrome is challenging; the existing drugs only help to control the symptoms, and the functional prognosis is reserved.

#357 - Case Report

LIMBIC ENCEPHALITIS: CASE REPORT

Carolina Bologna¹, Gabriella Oliva², Marina Lugara², Pasquale Madonna², Paolo Tirelli², Anna Guida², Maria Antonietta De Sena², Maria Gabriella Coppola², Nunzia Silvestri², Claudio De Luca², Ernesto Grasso²

¹ Sea Hospital- ASL Naples, Naples, Italy

² Sea hospital, Napoli, Italy

Introduction

Title: Limbic encephalitis

Limbic encephalitis is a rare disease often associated with small cell lung cancer and breast cancer, rarely associated with mesothelioma.

Case description

The diagnosis of limbic encephalitis in the elderly multipathological patient admitted to an internal medicine unit may be difficult. Description of the case: a 76-year-old patient with heart failure due to chronic hypertensive ischemic heart disease with hypokinetics and severe depression with EF (35%); mitral valvular disease treated surgically; Permanent FA in TAO; pulmonary asbestosis; Stage III IRC K-DOQI, hospitalized for hyponatremia that could be secondary to high-dose diuretic therapy (at the entrance 114 mEq/l, treated with 3% hypertonic solution).

The correction of sodemia does not resolve the patient's confusional state, which shows signs of rapidly progressive dementia with hallucinations and convulsions. Negative brain CT scan. Haloperidol treatment for hyperactive delirium does not improve the picture. Therefore it requires brain MRI with sequence in DWI showing limbic encephalitis. It then performs lumbar puncture for the detection of anti-HU, anti-Ma, anti-NMDA antibodies. The PET study shows a pathology with high metabolic activity in the pleural lymph nodes and middle lung lobe. The hypometabolism of widespread glucose in the brain center. To the CT solid nodular formation with polylobate margins (Dtrv max 65x48mm; IM: 3-251), corresponding to the medial segment of the LM, poorly dissociable from the parietal pleural profile. Needle aspiration is performed with a 21G needle shows mesothelioma.

Discussion

Discussion: the diagnosis of limbic encephalitis in the hospitalized elderly can be complicated due to the possible concomitance of other reasons of confusional state and delirium.

#367 - Case Report

CAROTID ARTERY DISSECTION: A SUSPICIOUS DIAGNOSIS

Inês Moreira¹, Filipa Guimarães², Joana Martins², Ana Monteiro², Inês Chora², Eduardo Eiras²

¹ Instituto Português de Oncologia Francisco Gentil, Porto, Portugal

² Unidade Local de Saúde de Matosinhos, Hospital Pedro Hispano, Matosinhos, Portugal

Introduction

Carotid artery dissection is an important cause of ischemic stroke in young adults, being responsible for up to 25% of such events in this age group. In the absence of trauma, it typically presents as a constant ipsilateral headache of sudden or gradual onset. As many as 20% of patients can develop ischemic stroke without previous symptoms associated with the dissection

Case description

The authors present the case of a 34 year old woman that presented to the emergency room (ER) with a left sided headache that started 10 days ago and escalated in the past few hours. The pain started suddenly during the night and woke her up, was throbbing, with fluctuating intensity. It alleviated with rest and paracetamol and aggravated with physical effort. This was the first episode of this kind. Associated symptoms were bilateral tinnitus, dizziness, phono and photophobia. No fever, sensitive, muscular or visual alterations were reported. She denied history of trauma, physical exercise or sexual relations the night before the start of the symptoms. Physical and neurological examination in the ER and blood workup were normal. Angio-CT revealed a left cortico-subcortical fronto-insular hypodensity suggestive of an acute vascular ischemic lesion. She was admitted for further study. Viral serologies, immunological and Borrelia studies were negative. Cerebrospinal fluid study was also normal. Echocardiogram demonstrated right-left shunt suggestive of patent foramen ovale. Cerebral angio-MRI confirmed the acute ischemic injury and revealed the presence of dissection of the left internal carotid artery. She was medicated with acetylsalicylic acid. Due to an ambiguous image in the MRI, a thoracic angio-CT was ordered, which demonstrated a solid lesion in the lumen of the right intermediate bronchus. Rigid bronchofibroscopy and pathology results confirmed the presence of a typical carcinoid tumor. She underwent right medium and inferior bilobectomy.

Discussion

The diagnosis of carotid dissection is obvious in the presence of cervical trauma but in its absence a high index of suspicion is required. In this case the patient presented with a typical migraine-like headache without recent history of trauma or arteriopathy. The presence of a carotid dissection could have been easily overlooked and a diagnosis of migraine-type headache established if it were not for the red flags that motivated a more complete study. Carotid artery dissection must always be considered in young adults that present with new onset headache.

#401 - Case Report

CEREBRAL AMYLOID ANGIOPATHY - A RARE RELATIVE TO THE ALZHEIMER'S DISEASE

Cármén Ferreira, Mário Monteiro, Alexandra Dias, Daniela Brito, Fernanda Coutinho

CHMT - Centro Hospitalar Medio Tejo, Abrantes, Portugal

Introduction

Cerebral amyloid angiopathy is characterized by amyloid beta peptide deposits in the small and medium cerebral vessels and leptomeninges. It's caused by intracerebral hemorrhage in the elderly and associated with Alzheimer's disease. Its prevalence is 2.3% in individuals aged 65-74 years, 8% between 75-84 years and 12.1% above 85 years. This disease is uncommon in individuals under 60-65 years and very rare under 50 years.

Case description

A 50-year-old male, with history of difficulty to control blood pressure, obesity and alcoholism. He went to emergency care due to acute changes in language and mental confusion. At admission, he had motor aphasia with blocks, difficulty in pronouncing the word thought, without paraphasia, without alterations of comprehension, repetition or appointment. The cranioencephalic tomography (CT) documented: "left posterior occipital encephalomalacia and left superior parietal intra-axial hematoma of indeterminate origin to demonstrate adjacent hypodensity and partial deletion of the regional grooves, suggesting associated edema". AngioCT revealed: "fair-cortical intraparenchymal hematopoietic focus, with only slight cortical extension in some planes, an aspect that defies the hypothesis of ischemic stroke with further transformation marginal sulcal hyperdensity that seems to translate rupture into the subarachnoid space...without occlusions of large vessels and venous thrombosis...lesions of small and large endocranial vessels, infrequent in this age group, considering the hypothesis of amyloid angiopathy..." The echocardiogram, the 24 hours holter and the doppler of the neck vessels had no alterations. Magnetic resonance imaging (MRI) documented: "multiplicity of intracranial hemorrhagic lesions, in multiple stages of evolution, suggestive of angiopathy with gonadotropin". The neurologist suggested the avoidance of antiplatelet drugs, control of vascular risk factors and alcohol withdrawal. A second CT revealed partial reabsorption of the hematoma, so the patient was discharged.

Discussion

The definitive diagnosis of amyloid angiopathy can only be performed by post-mortem brain biopsy, but a probable diagnosis can be made by MRI identifying 2 or more areas of hemorrhage in typical regions. It's rare in individuals younger than 50 years old. We should consider this diagnosis when neurological symptomatology exists and in order to prevent a significant cognitive deterioration and even the premature development of Alzheimer's disease.

#418 - Case Report

MILD ENCEPHALITIS/ENCEPHALOPATHY WITH REVERSIBLE SPLENIAL LESION - A BENIGN CONDITION WITH NOT SO BENIGN DIFFERENTIALS

Margarida Mouro, Ana Martins, Daniel Coutinho, Sofia Nunes, Jorge Velez

Infectious Diseases Department, Baixo Vouga Hospital Centre, Aveiro, Portugal

Introduction

Mild encephalitis/encephalopathy with reversible splenial lesion (MERS) is a rare clinico-radiological entity, particularly in adults, characterized by the magnetic resonance imaging (MRI) finding of a lesion in the corpus callosum. Patients commonly present with mild central nervous system symptoms and almost universally recover fast and without sequelae. Despite its unknown pathogenesis, some reports identified infections, especially viral, vaccinations and some antiepileptic drugs as potential triggers of MERS. We report the case of a 44-year old patient admitted with this diagnosis.

Case description

44-year old male, previously healthy, presented at the emergency department with sudden onset neurological symptoms (ataxia, myoclonus, dysarthria and headache). He also mentioned nausea, vomiting and dizziness starting the day before and a flu-like syndrome in the previous 5 days, but hadn't measured body temperature. At admission he was afebrile, hemodynamically stable, and exhibited facial myoclonus and global aphasia. Blood workup was normal and a brain CT scan revealed no lesions. A lumbar puncture was then performed and the cerebrospinal fluid revealed lymphocytic pleocytosis (56 cells/ μ L) with mononuclear predominance and increased protein concentration (73.7 mg/dL). Intravenous aciclovir 10 mg/kg every eight hours was empirically started. The following day the patient developed confusion and disorientation, with some sporadic agitation. Viral serologies and an autoimmune panel were negative, and an MRI was performed, revealing a high signal intensity on T2-weighted images in the splenium of the corpus callosum, with diffusion restriction, suggesting a transitory lesion of the splenium. The patient was admitted to the Infectious Diseases ward, aciclovir was stopped, and he fully recovered by day 5. A control MRI performed two months after was completely normal.

Discussion

We report the case of a patient with MERS, a usually benign entity with unspecific neurological manifestations and an imagiological diagnosis. Because of its presentation, the differential diagnosis includes a plethora of not so benign conditions. As in most cases reported in the literature, our patient recovered without any sequelae within few days and a subsequent MRI was completely normal.

#430 - Case Report

GENETIC CAUSES OF STROKE: ABOUT A CLINICAL CASE

Joana Carreiro, Maria Guadalupe Benites, Almerindo Rego
Terceira Island Santo Espirito Hospital, Angra Do Heroismo, Portugal

Introduction

Stroke is a leading cause of death and disability in developed countries. In young age, a stroke is most likely related with heart disease, vasculitis and hypercoagulable states.

Case description

This is a case of 32 years old male with family history of stroke in young age (mother, uncle and cousin) that presented with paresthesias of right hemiface and hand. CT scan showed a thalamic lacunar infarct and leukoencephalopathy and the MRI multiple demyelinating lesions, compatible with multiple sclerosis. In the next years the neurological deficits escalated, with dysarthria, cerebellar ataxia and dementia. At 44 years old, due to cognitive impairment, seizures, tetraparesis and dysphagia, he was hospitalized. MRI showed subcortical and basal ganglia hypodensities and leukoencephalopathy. This associated with the family history and the fact that his younger brother died of an hemorrhagic stroke the year before raised suspicion of a genetic cause. The genetic study revealed a mutation in heterozygosity in exon 4 of the NOTCH 3 gene and he was diagnosed with CADASIL (Cerebral autosomal dominant arteriopathy with subcortical infarcts and leukoencephalopathy). Two years later, another two brothers had cerebral ischemic episodes that lead to the diagnosis of CADASIL. The patient died when he was 47 years old.

Discussion

Genetic predisposition to stroke can be categorised in single gene or polygenic disorders, with the first presenting at a younger age, either with stroke or with other clinical features related to the disorder. Like CADASIL, CARASIL (autosomal recessive), Moya-moya disease, Fabry disease and MELAS (Mitochondrial myopathy, encephalopathy, lacticidosis and stroke) may present with stroke in early adulthood.

#473 - Case Report

RADIATION THERAPY CAROTID RESTENOSIS

Marta Soares Carreira¹, Daniela Ferro¹, Andreia M Teixeira², Luís Lemos¹, Margarida Matias¹, Guilherme Gama¹, Paulo Castro Chaves¹, Luísa Fonseca¹, Jorge Almeida¹

¹ Centro Hospitalar Universitário de S. João, Porto, Portugal

² Centro Hospitalar de Entre Douro e Vouga, Santa Maria Da Feira, Portugal

Introduction

Extra-cranial carotid artery stenosis is a well-established vascular complication of radiation exposure which increases the risk of cerebrovascular events.

Case description

A 31-year-old female was admitted to our stroke unit (SU) due to amaurosis fugax (AF) of the right eye. Her prior medical history included a childhood pharynx rhabdomyosarcoma treated with chemoradiotherapy. The patient's recovery period was uneventful, and the cancer did not recur. 22 years later she was admitted to our SU due to a transient loss of vision of the right eye. Extracranial vascular ultrasound examination (EVUE) showed a 75% stenosis of the right internal carotid artery (RICA). The patient underwent carotid artery stenting (CAS) and a 2 months course of dual antiplatelet therapy (DAPT) with acetylsalicylic acid (ASA) 150 mg id and ticagrelor 90 mg 2id followed by monotherapy with ASA. Clopidogrel resistance test was positive. 4 months later she was admitted to our emergency department due to headache. Although computed tomography angiography (CTA) showed narrowing of the RICA, EVUE was normal. A year after CAS, she was again admitted to our SU due to another episode of AF. EVUE showed a 70-80% restenosis of the RICA. CTA confirmed the diagnosis and a balloon angioplasty was performed. Subsequent EVUE showed a stenosis of 50-55%. Aspirin resistance test was positive. She was discharged on DAPT with an higher dose of ASA (250 mg id) and ticagrelor (90 mg 2id). One month after discharge, EVUE showed a similar grade of RICA stenosis.

Discussion

In-stent restenosis is a possible complication of carotid artery stenting which can be managed with interventional procedures such as percutaneous angioplasty with simple balloon. In this case, ASA resistance also contributed to restenosis.

#475 - Case Report

PROBABLE NON-COMPACTED MYOCARDIOPATHY OF THE LEFT VENTRICLE - A LOW FREQUENCY THROMBOEMBOLICAL SOURCE

Rodrigo Rufino, Catarina Carvalho, Alexandra Albuquerque, Fátima Campante

Centro Hospitalar Barreiro-Montijo, Barreiro, Portugal

Introduction

Left Ventricular Non-Compaction (LVNC) is a rare cardiomyopathy, characterized by a prominent left ventricular trabeculae and deep intertrabecular recesses, in the absence of other congenital abnormalities.

LVNC may be of sporadic or familiar nature and its' prevalence is unknown. The main clinical manifestations include heart failure, arrhythmias, cardiovascular arrest and thromboembolic events. LVNC is diagnosed based on clinical and morphological criteria, without a gold standard characteristic, but has several proposed echocardiographic criteria.

Case description

A male 62 year old patient, paraplegic due to a L1 fracture,

goes to the Emergency Department due to paresis of his right upper limb. He was sleepy but easily awakable, disoriented in time, hemodynamically stable, with right central facial and homolateral upper limb paresis. Analytically without relevant alterations and cranioencephalic (CE) computerized tomography (CT) demonstrated bilateral infarcts with inaccurate dating. He was admitted to the Internal Medicine Service for research and rehabilitation for probable ischemic stroke (IS) of the left hemisphere (LH).

During hospitalization, a CE-CT confirmed bilateral border infarcts, suggestive of a cardioembolic source. To complement the study, we performed a 24-hour Holter exam with no alterations, echoDoppler and angio-CT of the vessels of the neck where atherosclerotic plaques were found, with significant stenosis in the right carotid artery, but without urgent surgical indication; and a transthoracic echocardiogram with apical hypertrabeculation, without identifiable thrombi in the left ventricle, suggestive of non-compacted cardiomyopathy. The main diagnosis of stroke in the LH was assumed, with indication for hypocoagulation due to the echocardiographic findings.

The patient remained hemodynamically stable during hospitalization and completed a motor rehabilitation program with improvement of his initial paresis. He is waiting for the results of complementary outpatient exams, namely a cardiac magnetic resonance imaging, and continues investigation in Internal Medicine, Cardiology and Vascular Surgery consultations.

Discussion

This case emphasizes the importance of the etiological investigation of stroke. Analyzing all the possible foci of embolism, namely through the use of echocardiography, allows the diagnosis of rare pathology, as in the likelihood of this case, as we are still awaiting the conclusions of the outpatient study for the definitive diagnosis.

#499 - Medical Image

GLIOBLASTOMA MULTIFORME AND LOWER DEGREE GLIOMA

Maria Beatriz Santos, Magda Garça, Pedro Cota, Joana Carreiro, Paulo Ávila, Rita Vitorino Costa

Hospital of the Holy Spirit of Terceira Island, Angra Do Heroísmo, Portugal

Clinical summary

59 years old male patient, personal history of cervical melanoma. Admitted with holocranial headache, urinary incontinence, behavioral changes and left hemiparesis with hypoesthesia with 15 days of evolution. Cranial CT identified two nodular lesions in the right cerebral hemisphere. Cranial MRI revealed "two expansive lesions in the right hemisphere, conditioning moderate mass effect: a frontal parasagittal lesion behaving like glioblastoma multiforme and a thalamic lesion as a lower degree glioma". The patient underwent neurosurgery in a tertiary hospital and adjuvant chemotherapy. Glioblastoma is the most common

malignant primary brain tumor in adults. Patients may present with a wide range of symptoms from unspecified symptoms to focal neurologic signs.

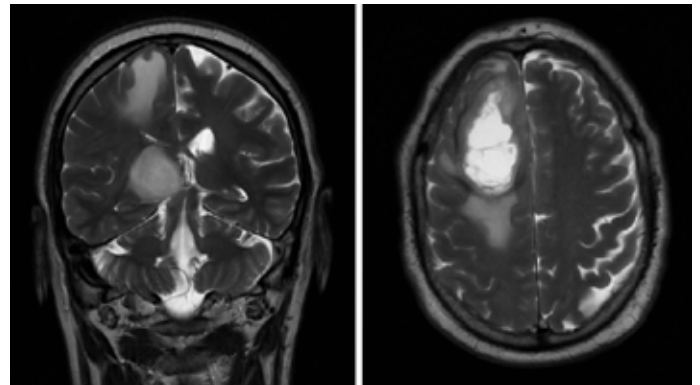


Figure #499. Two expansive lesions in the right hemisphere, conditioning moderate mass effect: a frontal parasagittal lesion (7.1x3.7x5.1cm) behaving like glioblastoma multiforme and a thalamic lesion (2.7x3.6x3.0cm) as a lower degree glioma.

#527 - Case Report

NOT FORGETTING KORSAKOFF

Diogo Faustino, Líliliana Antunes, Rita Pocinho, Isabel Baptista

Central Lisbon University Hospital Centre - S. José Hospital, Lisbon, Portugal

Introduction

Korsakoff syndrome is an uncommon entity, with a reported prevalence 0,5-4,8 per 10000 persons. It typically follows Wernicke Encephalopathy and it represents the irreversible neurologic structural damage secondary to severe thiamine deficiency.

Case description

47-year-old man, with previous history of severe alcohol and tobacco abuse, admitted to the emergency room with severe delirium, ongoing for 3 days with progressive worsening. For the previous months, he had an extremely limited food intake, having isolated himself in his room, only leaving to acquire alcohol (2-3 liters of wine per day) and cigarettes (1-2 packs a day). He was thin, frail with sarcopenia, had visual hallucinations and was disoriented with slowed, disorganized and confabulatory thought. He showed global amnesia, couldn't walk or keep a standing position (neck in anterocolis) and had no abnormal eye movements. Blood analysis showed protein and folate deficiency (Urea 4 mg/dl Creatinine 0.41 mg/dl Albumin 26.0 g/L Hemoglobin 11.2 g/dL Mean Corpuscular Volume 112 fL Folate 1.8 ng/ml), with normal vitamin B12, transaminases and ammonia. Cranial magnetic resonance showed cortical and cerebellar atrophy with widened sulci and an enhanced signal in medial and posterior thalamus

With vigorous and prolonged thiamine and folate supplementation, there was a favorable neurological and cognitive response;

hallucinations ceased and speech coherence was recovered but a profound amnesia persisted, with minor improvement, only recollecting his distant youth.

Discussion

According to the criteria of Caine, the initial clinical picture was consistent with Wernicke Encephalopathy (dietary deficiency together with confusion, disorientation, confabulation and cerebellar dysfunction). The modest improvement of the memory when compared to other cognitive functions, together with the findings on cranial magnetic resonance, suggest the diagnosis of Korsakoff syndrome, with irreversible damage to the thalamus due to prolonged thiamine deficiency.

We highlight the need for an early recognition of Wernicke encephalopathy to ensure prompt and adequate thiamine supplementation in order to avoid the progression to the, mostly irreversible, Korsakoff syndrome, where memory is disproportionately affected when compared to other cognitive functions.

#560 - Case Report

TRANSIENT ISCHEMIC ATTACK VERSUS CONVERSION DISORDER: A CASE REPORT

Miguel Reis Costa, Pedro Pinto, Rosana Maia, Duarte Silva, Irene Miranda, Carmélia Rodrigues, Diana Guerra

ULSAM - Hospital de Viana do Castelo, Viana Do Castelo, Portugal

Introduction

Transient Ischemic Attack (TIA) is defined as a focal and temporary neurologic dysfunction, which is attributable to dysfunction of one arterial territory of the brain. However, there are patients with transient focal neurological symptoms, which are not attributable to focal cerebral ischemia. Psychiatric conditions (like conversion disorder) may imitate a TIA.

Case description

We describe the case of a 62-year-old woman with a medical history of β -Thalassemia and anxiety disorder; family history of sudden cardiac death of a brother. She had an episode of dysarthria, labial commissure deviation to the left side and decrease of strength in the right arm associated with chest pain and fear of eminent death. These deficits were observed by the emergency ambulance crew; however, when in the urgency room she had a normal physical examination – she considered that the deficits had spontaneously resolved in less than 2 hours like had happen before (only this time she decided ask for help). CT scan and CT angiography showed no signs of acute brain injury or vessel alteration. Electrocardiography identified a sinus rhythm associated with few supraventricular premature beats (ectopic atrial escape rhythm was posteriorly confirmed in a 24-hour holter monitoring). Summarized analytics: normal cardiac biomarkers, a hypochromic and microcytic anemia (hemoglobin: 10.3 g/dL), normal electrolytic balance, negative virology serology and a normal lipid panel. Brain MRI revealed

hipersignal focus in periventricular white matter, more prominent in the right frontal lobe probably representing old ischemic infarction areas. Transthoracic echocardiogram identified a slight dilation in the left auricle and signs of left ventricular hypertrabeculation/noncompaction (LVHT), confirmed in cardiac MRI. Electroencephalogram excluded epilepsy. Although the anxiety history and symptoms, considering that the referred deficits had a possible correlation with a vascular area and the confirmation of old infarction regions, the diagnosis of TIA with probable cardioembolic etiology (LVHT) was considered and she began anticoagulation therapy. She had also been referred for a medical genetics consultation.

Discussion

For TIA, the diagnostic challenge is greater, and the “mimic” rate higher, because there is no definitive diagnostic test. Complementary diagnostic procedures may help the diagnosis of TIA; however, clinical judgment remains the cornerstone.

#591 - Case Report

CEREBRAL VENOUS THROMBOSIS - CASE REPORT

Hilda Freitas¹, Natalia Oliveira¹, António Cabral¹, Paulo Ferreira², Vanessa Machado², Cristina Ramalho²

¹ TrofaSaude Hospital Braga Sul, Braga, Portugal

² TrofaSaude Hospital Braga Centro, Braga, Portugal

Introduction

Cerebral vein and dural sinus thrombosis (CVT) is less common than most other types of stroke but can be more challenging to diagnose. The available data suggest that CVT is uncommon. The annual incidence ranges from 0.22 to 1.57 per 100,000, and is more common in women than men, with a female to male ratio of 3:1.

Case description

The authors describe a clinical case of a 66 years old women, autonomous, without known diseases. She went to emergency department sent by Otorhinolaryngology for left temporoparietal headache that started abruptly 15 days before, associated with nausea and vomiting. She had been treated with antibiotics because of sinusitis. Since then she refers attenuation of pain but with maintenance. Neurological examination was normal. She was without fever and with normal blood pressure. Brain Computer Tomography: “The images show left occipital lobar hemorrhage in the resorption phase, surrounded by a halo of vasogenic edema with parietal extension, and the presence of acute subdural blood along the left free border of the cerebellum tent and temporal convexity ipsilateral”. She was hospitalized. She made Computer Tomography Angiography at the admission: “In the study we performed we found asymmetry of the lateral sinuses, due to the lower expression of the left lateral sinus, presenting irregularities in the initial 2/3, coexisting densitometric heterogeneity of the left jugular foramen - partial thrombosis of the left lateral

sinus". Started anticoagulation with Low Molecular Weight Heparin, despite bleeding. At 24h was performed Angio MRI with venoRMN that confirmed de diagnosis and showed favorable evolution. There was a progressive clinical improvement, without complaints on discharge, She kepps maintaining their independence in activities of daily living. Has been accompanied in consultation of Internal Medicine, and is currently asymptomatic. The Study of Prothrombotic conditions, either genetic or acquired thrombophilia, Malignancy, and for inflammatory diseases that can also cause CVT were negative.

Discussion

Although infectious causes of CVT were frequently reported in the past, they are responsible for only 6 to 12 percent of cases in modern-era studies of adults with CVT. Local infections (eg, involving the ears, sinuses, mouth, face, or neck) are typically responsible, although systemic infection is sometimes the only cause. Head injury and mechanical precipitants are less common causes of CVT.

#620 - Case Report

CEREBRAL AMYLOID ANGIOPATHY MIMICKING "TRANSIENT ISCHEMIC ATTACKS"

Carolina Teves Carreiro, Ana Cláudia Furão Rodrigues, Mireille Palmeira, Rui M. Victorino

Hospital de Santa Maria - CHULN, Lisboa, Portugal

Introduction

Cerebral Amyloid Angiopathy is a rare cerebrovascular disease, in which deposition of β -amyloid is found in the media and adventitia of small and mid-sized arteries of the cerebral cortex and leptomeninges. This condition may lead to rapidly progressive dementia, intracranial hemorrhage, or rarely transient neurologic events, although it is often asymptomatic.

Case description

We report a case of a 63 year old man who was admitted to the Hospital Urgency because of a self-limited episodic loss of consciousness. There was a four month history of sudden and transient neurological deficits, namely decreased muscle strength of the left upper limb, dysarthria and blurred vision, associated with subtle new cognitive impairment. The past history included arterial hypertension and septal acute myocardial infarction, two weeks before, on acetylsalicylic acid since then.

On clinical examination, he showed a mild tremor of the left inferior limb in Mingazzini test, without fall, and wide-based gait, with no other alterations. There were no acute findings in CT. He was therefore admitted to Internal Medicine Service, for etiological investigation of recurrent episodes interpreted as transient ischemic attacks.

Cerebral MRI revealed multiple microhemorrhagic foci of peripheral predominance in the right hemisphere, more

pronounced in the cortical and cortical-subcortical frontal regions, as well as in the high left frontal convexity, sparing basal ganglia and brainstem. No evidence of ischemic lesions was found. In conclusion, according to Boston criteria, the imagiological and clinical findings are consistent with the diagnosis of Cerebral Amyloid Angiopathy.

The patient was then followed in outpatients clinic with indication for control of cardiovascular risk factors.

Discussion

This case highlights the importance of considering Amyloid Angiopathy as a differential diagnosis of recurrent transient ischemic attacks, as well as the importance of weighting the risk-benefit of antiaggregation therapy maintenance, in this context considering other comorbidities, because of the high prevalence of hemorrhagic stroke.

#645 - Case Report

THE DIFFICULT DIAGNOSIS OF NEUROSARCOIDOSIS

Karolin Berg¹, Ursula Huber¹, Markus Hofer¹, Sabine Sartoretti-Schefer², Peter E. Ballmer^{1,3}, Eduard Scherer¹

¹ Department of Medicine, Kantonsspital Winterthur, Winterthur, Switzerland

² Department of Radiology, Kantonsspital Winterthur, Winterthur, Switzerland

³ Zürcher RehaZentrum, Davos Clavadel, Switzerland

Introduction

Sarcoidosis is an idiopathic granulomatous multisystem disease with or without involvement of the central nervous system. Neurosarcoidosis occurs in 5-10% of patients of sarcoidosis. A pathological chest X-ray or positive findings in the contrast-enhanced cerebral or spinal MRI is often found. For the definitive diagnosis we need a biopsy with a typical noncaseating granuloma. Neurosarcoidosis is primarily treated with systemic corticosteroids. The second-line treatment includes other immunosuppressive drugs such as methotrexate and infliximab. However, there is no standard recommendation for treatment of refractory neurosarcoidosis.

Case description

A 53-year-old woman was admitted to the hospital because of an episode of vertigo, hypoesthesia in the right arm and leg and a tendency to fall backwards. The general medical examination was normal. A spontaneous nystagmus was revealed on optical Frenzel goggles.

The cerebrospinal fluid revealed increased lactate und protein concentration, a low glucose level and positive oligoclonal bands. Cerebral and spinal MRI showed multiple hyperintense cerebral and nodular meningeal lesions. As differential diagnosis an infectious, a chronic demyelinating, a neoplastic disease or a CNS vasculitis was considered. We found negative liquor

immunoglobulin concentrations for herpes, tuberculosis and borrelia. The FACS analysis was negative and the soluble interleukin-2 receptor was above the reference value. The PET-scan showed multiple active lymph nodes. The biopsy of a paratracheal lymph node revealed single granuloma fragments without necrosis, epithelioid or Langerhans cells. Based on these results, we strongly suspected neurosarcoidosis and a high dose steroid treatment was started, later methotrexate was added.

Discussion

Neurosarcoidosis is a chameleon without pathognomonic clinical symptoms or diagnostic parameters. A definitive diagnosis requires a characteristic clinical picture and a biopsy with histopathological evidence of typical granulomas. Even with nonspecific symptoms, diagnostic tests such as lumbar puncture, contrast-enhanced cerebral and spinal MRI, sIL2-R and PET-Scan can help to diagnose neurosarcoidosis. It is important to improve more specific diagnostic tools and evidence-based treatments for neurosarcoidosis.

#675 - Case Report

PARANEOPLASTIC NEUROLOGICAL SYNDROME ASSOCIATED WITH ANTI-CV2

Laura Pacho Millan, Marta Parra Navarro, Gabriela Casinos Isart, Paula Fernandez Fernandez, Raquel Aranega Gonzalez, Carlos Lopera Marmol, Montserrat Mauri Plana
Hospital de Mataro, Mataro, Spain

Introduction

Patient of 69 years old, active smoker, with pathological antecedents of COPD, sleep apnea syndrome, a bladder tumor that required transurethral resection (TUR) in 2009 and an incomplete Schatzki ring, that consults for two months of pseudobulbar clinic and toxic syndrome.

Case description

Patient of 69 years, who consults for two months of evolution hiccup with high dysphagia and toxic syndrome, without dysphonia. For a week, he had also non-rotating positional dizziness and progressive drowsiness.

The physical examination revealed a tendency to drowsiness without nystagmus, hypoesthesia in the right hand and dorsum of the foot, unstable gait and positive Dix-Hallpike maneuver to the left.

Tumor markers were performed objectifying positive serum enolase, thoraco-abdominal CT and PET-SCAN without evidence of neoformation, lumbar puncture, serial urine cytologies and cystoscopy without evidence of neoplasia. Given these findings, a neurological paraneoplastic syndrome (SNP) was suspected without evidence of active neoplasia.

Systemic corticotherapy was started at a dose of 1 mg / kg / day and subsequently intravenous immunoglobulins and rituximab with improvement of the pseudobulbar clinic.

During admission, the patient presented hyponatremia secondary to SIADH. The patient was discharged following controls in outpatient clinics of Internal Medicine.

Six months later, a control CT scan was performed that showed an anterior mediastinum mass of 69 mm. Therefore, a new PET-SCAN with hypermetabolic activity of this tumor mass was performed. Finally, a mediastinal biopsy was performed by video-assisted thoracoscopy of the lesion obtaining small cell lung cancer as a primary tumor as the definitive diagnosis.

Discussion

A paraneoplastic syndrome associated with onconeurological antibodies CV2 is a very rare condition. Sometimes the symptoms begin before the appearance of the evidence of an active neoformation as in this case.

The clue in this patient for the diagnosis of the paraneoplastic syndrome was the founding of a SIADH, condition that is frequently related in some tumors, like small cell lung cancer.

It is important to suspect a paraneoplastic syndrome associated with anti-CV2 in patients with bulbar symptoms as dysphagia and drowsiness like this patient and antecedents like active smoking. Also it is important to follow out this patients in outpatient clinics to do an early diagnosis of the possible underlying neoplasia.

#686 - Case Report

FLUCTUATING LEVEL OF CONSCIOUSNESS

María De Los Ángeles Gallardo, Cristina Lojo
Hospital Universitario Virgen de Valme, Sevilla, Spain

Introduction

A 70-year-old male with DM 2 and factor V Leiden heterozygosis carrier (previously two episodes of DVT) anticoagulated with Acenocoumarol was admitted for subacute behavioral disorder that progressively associates altered level of consciousness.

Case description

In Emergency Service he was confused, disoriented and presented fever of 38°C. TAC cranial without findings. Analytically shows PCR > 400, CK elevation and hypertransaminasemia. Lumbar puncture was performed with 9 leukocytes and discrete hyperproteinorrachia. He presents progressive worsening of consciousness level with respiratory failure, requiring intubation and admission to the ICU.

In ICU he has fluctuations of consciousness level with generalized tonic-clonic seizures and clones of right extremities. EEG compatible with moderate grade encephalopathy. Phenytoin is started with poor control requiring associating levetiracetam. Serologies and peripheral blood cultures were negative. Cranial MRI was compatible with diffuse pachymeningitis related to cerebral hypotension secondary to lumbar puncture.

Autoimmune encephalitis is suspected, initiating methylprednisolone boluses. New lumbar puncture with autoimmunity study was negative with Protein 14-3-3 positive

in cerebrospinal fluid (CSF). New EEG with periodic lateralized epileptiform complexes (PLEDS) of short interval. The results of new EEG and the positivity of the protein 14-3-3 in CSF with the symptoms are highly suggestive of Creutzfeldt-Jacob disease.

Discussion

In Creutzfeldt-Jacob disease (CJD), rapidly progressive mental deterioration and myoclonus are the cardinal clinical manifestations. Most of the cases are sporadic. The average age for onset is between 57-62 years and there is no gender predilection. The finding of periodic acute wave complexes in the EEG has a high specificity for diagnosis, as well as the 14-3-3 protein test in CSF. Brain biopsy is the gold standard test, but a typical clinical presentation with findings that corroborate MRI, EEG and CSF is sufficient to exclude other causes and establish it as a probable diagnosis.

#687 - Case Report

SUBACUTE MUSCLE WEAKNESS

María De Los Ángeles Gallardo, Cristina Lojo

Hospital Universitario Virgen de Valme, Sevilla, Spain

Introduction

A 45-year-old male with active smoking (60 pack-year) and drinking habits (40 grams of alcohol a day). He was admitted due to myositis of the lower right limb, two years ago. Analytically there was a CPK elevation with muscle weakness. No follow-up. Not usual treatment.

Case description

Now, he presents progressive muscle weakness of two months of evolution, beginning in lower limbs. Associates anorexia, vomiting and weight loss. In addition, he has predominantly proximal weakness with inability to elevate the members counter-resistance, claudication within a few seconds. Analysis shows a hyponatremia of 117, CPK of 12476, increase of transaminases and INR 1.42.

During admission, he presents progressive worsening, appearing: dysphagia, dysphonia, hypoesthesia and hypoactive ROT. Cranial CT without findings. Lumbar puncture without albuminocytological dissociation. Levels of IgA 226. Electromyogram shows axonal motor polyneuropathy. Later, respiratory failure appears, requiring noninvasive mechanical ventilation and treatment with methylprednisolone (1g bolus) and immunoglobulins. Despite this, poor evolution, requiring intubation and admission to the ICU. CT chest and abdomen scan shows bilateral alveolar condensations; signs of abdominal generalized hypoperfusion with mild ascites; without neoplastic signs. Antibiotic therapy with meropenem and vancomycin was initiated. He remains with hemodynamic instability, lactic acidosis and hepatic failure with coagulopathy. Finally, he died from respiratory septic shock and acute liver failure. The autopsy shows bilateral pneumonia and congested liver. The nerve biopsy is compatible with necrotizing myopathy.

Discussion

The origin of necrotizing myositis is toxic, paraneoplastic or autoimmune. The cases associated with statins persist despite the suspension of the drug. Paraneoplastic myopathy is characterized by a rapidly progressive, symmetric and proximal weakness with severe disability. It is associated with lung, breast and gastrointestinal tract cancers. Antibodies against the particle recognition signal (SRP) and 3-hydroxy-3-methylglutaryl-coenzyme A reductase (HMGCR) have been found in 2/3 of patients. The absence of antibodies or the presence of HMGCR antibodies seems to confer an increased risk of cancer. The active search for neoplasia is indicated. Corticosteroids combined with other immunosuppressive therapies and the treatment of neoplasia could improve neurological symptoms. Patients with cancer have worse results.

#742 - Medical Image

ANTERIOR MEDIASTINAL MASS PRESENTING AS MYASTHENIA GRAVIS WITH SIGNS OF IRRITATIVE MYOPATHY

Marília Santos Santos Silva, Raquel Rocha, João Martins, Paulo Ricardo Pereira

Hospital Pedro Hispano - Matosinhos Local Health Unit, Matosinhos, Portugal

Clinical summary

A 43 year-old man presented to the emergency department with a four-month progressive evolution of dysarthria, dysphagia, eyelid ptosis and diplopia with afternoon exacerbation. Marked eyelid fatigability was noted on repetitive eye closure. Anti-acetylcholine receptor antibodies were positive while anti-MuSK and LRP4 were both negative. Electromyography demonstrated a decremental response to nerve stimulation and signs of irritative myopathy, a rare but possible finding in Myasthenia Gravis. Symptoms resolved after pyridostigmine and prednisolone initiation. Computed tomography uncovered a heterogeneous anterior mediastinal mass suggestive of thymic carcinoma, that was excised and revealed a type A thymoma on histology. The patient remains asymptomatic 15 months after treatment suspension.

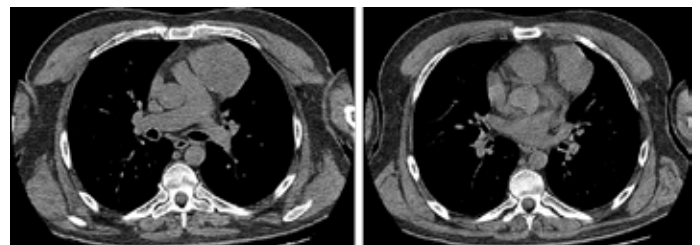


Figure #742. Anterior mediastinal mass - thymoma.

#792 - Abstract

ANALYSIS OF TRIGGERING FACTORS AND MORTALITY PREDICTORS IN A COHORT OF PATIENTS ADMITTED WITH NOT CONVULSIVE STATUS IN AN INTERNAL MEDICINE DEPARTMENT

Lucía Barrera López¹, Alba García Villafranca¹, Ignacio Novo Veleiro¹, Marta Pose Bar², Emilio Manuel Páez Guillán¹, Jonathan Geovany Montoya Valdés¹, Ana Teresa Marques Afonso¹, Néstor Vázquez Agra¹

¹ Internal Medicine Department, University Hospital of Santiago de Compostela, Santiago De Compostela, Spain

² Department of Medicine, Faculty of Medicine and Odontology, University of Santiago de Compostela, Santiago De Compostela, Spain

Background

The non-convulsive status epilepticus (NCSE) is characterized by the association of abnormal electroencephalographic (EEG) activity and subclinical epileptic crisis. It constitutes around 20-30% of the total cases of status epilepticus. Its multiple etiology, variable clinical presentation and the absence of a standardized diagnostic algorithm, makes it difficult to be recognized. The treatment is based on the use of benzodiazepines, antiseizure drugs and general anesthetics. Despite a correct management, NCSE is linked to a high morbidity and mortality and an uncertain prognosis. In this work we aim to characterize the patient diagnosed with NCSE during admission to an Internal Medicine department, as well as to perform an analysis of the potential relationship between clinical-analytical disturbances and the evolution of the status. We also carried out an assessment of the compliance with current recommendations regarding the management of NCSE.

Methods

Cross-sectional observational epidemiological study. All patients diagnosed with NSCE admitted to the Internal Medicine department of the Santiago de Compostela's area between the years 2010 and 2016 were included. Data were analyzed through basic descriptive statistics and univariate analysis.

Results

The sample size was 40 patients (62.5% women) with an average age of 75.86±13.69 years. The most prevalent comorbidity was hypertension (60.55%), followed by chronic kidney disease (51.4%). The most frequent diagnosis at admission was respiratory infection. In 84.2% of patients a brain CT was performed, showing significant alterations in 10.5% of them. At admission, 35% of patients presented changes in the level of consciousness (coma: 3.5%). Focal neurological findings were found in 12.5% of cases. The most used treatment was levetiracetam (71.1%). The use of benzodiazepines was associated with a greater survival, although only a 6.8% of patients were treated with them. None of the patients transferred to the ICU died. During hospital stay, 14 patients died (36.8%). The parameters with a significant higher

frequency in died patients group were hypertension, renal failure, arrhythmias, neuropathy, stroke and levetiracetam treatment.

Conclusion

The NCSE was diagnosed more as a complication than as a reason for admission itself. We found a significant in prognosis regarding the selected treatment, favoring benzodiazepines, despite its low use. The mortality reached the 36.8% and the grade of compliance with current recommendations was low.

#811 - Case Report

VARICELLA ZOSTER VIRUS VASCULOPATHY PRESENTING AS MULTIFOCAL CEREBRAL INFARCTION AND CAROTID ARTERY DISSECTION.

Gregory Offiah, Aine Gorman, Ausaf Mohammad
Midlands Regional Hospital Tullamore, Offaly, Ireland

Introduction

Varicella zoster virus (VZV) can present as a primary or a reactivated latent infection. Rarely, it may reactivate and manifest as vasculopathy.

Case description

A 62-year-old immunocompetent male was admitted with a two-day history of intermittent headache, confusion and fever. Romberg's test was positive, but physical examination was otherwise unremarkable. There was no evidence of a rash. Computed tomography (CT) and magnetic resonance imaging (MRI) of the brain showed non-specific white matter changes in the frontal and occipital lobes. Lumbar puncture revealed a lymphocytic pleocytosis. VZV encephalitis was confirmed by VZV polymerase chain reaction and VZV IgM. He was treated with 21 days of acyclovir.

After initiation of treatment, he complained of diplopia and a right fourth cranial nerve palsy was noted. MRI brain excluded cerebral infarction. One week later, he developed transient left sided paraesthesia. Repeat MRI brain confirmed a subacute lacunar infarct in the right posterolateral thalamus. He was started on methylprednisolone and high dose aspirin. A follow-up MRI brain and angiogram one week later revealed a left internal carotid artery dissection and new right frontal and left anterior thalamic infarcts. He subsequently developed chest pain. CT angiogram confirmed pulmonary embolism. He was treated with a prolonged course of antivirals and steroids for VZV vasculopathy.

Discussion

Greater than 95% of the world's population carry latent VZV with 50% experiencing reactivation. One third of patients with VZV vasculopathy will not present with a rash². It is important to consider VZV in immunocompromised patients presenting with cerebral infarction.

#833 - Case Report

CEREBRAL AMYLOID ANGIOPATHY - A RARE CAUSE OF DEMENTIA

Leonor Naia, Tiago Rabadão, Carlos Rodrigues, Joana Pires, Margarida Eulálio, João Fonseca, Clarinda Neves, Rosa Jorge
Baixo Vouga Hospital Center - Internal Medicine Department, Aveiro, Portugal

Introduction

Cerebral amyloid angiopathy (CAA) is characterized by the accumulation of amyloid substance in small and medium-sized cerebral vessels. Usually asymptomatic, it predisposes to an increased risk of intracranial hemorrhagic events, although ischemic events may also occur. The progressive vascular fragility is responsible for its recurrent and chronic nature.

Case description

Woman, 74 years old, independent in daily life activities, admitted to the Emergency Department for holocranial headache with frontotemporal predominance and short-term memory impairment with 4 months of evolution. Medical history of arterial hypertension, dyslipidemia and hyperuricemia; Medication: omeprazole, olmesartan and atorvastatin. Physical examination: hypertensive (BP 219/96 mmHg), time and space-oriented, with short-term memory impairment and attention deficit, without other neurological deficits. The remaining examination was normal. Cranioencephalic CT scan evidenced numerous infiltrative hypodense areas of the white matter, corresponding to vasogenic edema with bilateral temporo-basal localization, with occipitoparietal and posterior temporal extension. Magnetic resonance imaging (MRI) showed signs of leukoencephalopathy with surrounding edema and multiple supratentorial superficial hemorrhagic lesions, compatible with amyloid angiopathy. The remaining study revealed: hypercholesterolemia (total cholesterol 211 mg/dL and LDL cholesterol 156 mg/dL); 12-lead ECG with sinus rhythm; carotid ultrasound imaging with bilateral carotid atheromatosis, without significant stenosis. During hospitalization, the antihypertensive therapy was optimized, resulting in the normalization of the tension profile and statin treatment was continued. At discharge, the patient maintained short-term memory impairment. The remaining study did not allow to identify other causes for the MRI findings. Given the age at the diagnosis and the exuberance of the lesions, a genetic study (apoE gene) was requested, still awaiting result.

Discussion

CAA is associated with progressive neurological compromise. According to the Boston criteria and given the absence of histopathological confirmation, a "probable" diagnosis of cerebral amyloid angiopathy was admitted. Considering that no treatment is available for CAA and the risk of intracranial hemorrhage, arterial pressure must be controlled and antithrombotic therapy should be avoided. The risks/benefits of statins are still controversial and poorly understood.

#839 - Case Report

POSTERIOR CIRCULATION STROKE: TAKE A HINTS!

Cláudia Oliveira Diogo, Tiago Pais, Ana Ponciano, Bruno Cabreiro, Catarina Faria, Joana Leite, José Leite, Célio Fernandes
Department of Internal Medicine, Centro Hospitalar de Leiria, Leiria, Portugal

Introduction

The main manifestations of impairment of the vestibular system, especially in the acute phase, are dizziness and vertigo. However, the difference between benign peripheral and central causes of vertigo such as stroke remains a clinical challenge. The HINTS exam was developed as a means of assessing patients with the acute vestibular syndrome and consists of three tests: the head impulse (HI) test, characterization of spontaneous nystagmus (N), and test of skew (TS). It is useful to differentiate peripheral and central vertigo and has been shown to have greater sensitivity than neuroimaging in ruling out stroke in patients presenting with acute vertigo.

Case description

We present a case of a 47-year-old otherwise healthy male presented in the emergency department with acute migraine without aura lasting for 9 hours and associated dizziness. Vital signs were stable and clinical examination was unremarkable. Brain computed tomography (CT) did not reveal acute lesions and the patient was diagnosed with peripheral vestibular syndrome. While under observation, he started complaining of nausea, changes in vocal tone and vertigo with imbalance to the left side. He had high blood pressure (BP 151 / 82mmHg) and the monitor showed a heart rate of 73bpm with sinus rhythm. Neurological exam revealed a dysphonia, and a positive Romberg test. Despite being symptomatic, a HINTS test was performed and was positive for skew deviation and non-fatigable bidirectional horizontal nystagmus. Head impulse was difficult to interpret due to lack of patient collaboration. CT Angio showed a foetal emergence of the right posterior cerebral artery and hypoplasia of the left vertebral artery and magnetic resonance of the brain confirmed posterior circulation ischemic stroke.

Discussion

Posterior circulation stroke remains a clinical challenge especially in the acute setting. The HINTS test is quick, non-invasive and can be performed at bedside. Evidence seems to support this test as reliable and effective in differentiating between posterior fossa stroke from peripheral vestibular causes. The presence of one of these subtle oculomotor signs is more sensitive than the combined presence of all other traditional neurological signs to identify stroke as a cause of acute vestibular syndrome. The test provides a clinical tool essential to improve accuracy in diagnosis in emergency setting, making patients eligible for reperfusion therapy and avoiding complications of stroke.

#846 - Case Report

NEUROLOGICAL MANIFESTATIONS OF PRIMARY SJOGREN'S SYNDROME: A CASE OF MONONEURITIS MULTIPLEX

Andreia Freitas, Nuno Leal, Sara Beça, Filipa Borges

Centro Hospitalar Vila Nova de Gaia/Espinho, Vila Nova De Gaia, Portugal

Introduction

Sjogren's syndrome is a systemic autoimmune disease that may affect every organ and system. The involvement of the peripheral nervous system can result in a wide spectrum of neuropathic manifestations. Mononeuritis Multiplex is a rare form of neuropathy characterized by sensory and/or motor deficits in the distribution of an area innervated by individual nerves; pain is common and constitutional symptoms and systemic manifestations of palpable purpura may be present.

Case description

A 71-year-old woman with Sjogren's syndrome began to experience pain in her lower limbs and paresthesias involving the plantar face of the right foot and the 4th and 5th fingers of the right hand. A few days later, purpuric lesions emerged in the lower limbs and paresthesias spread, involving all the right hand with associated pain and paresis. The neurological findings at the emergency service included weakness of the muscles innervated by the right ulnar, medial and radial nerves, and hypoesthesia of the muscles innervated by the sural nerve, bilaterally; the right stilorradial reflex was diminished and both aquilian reflexes were abolished. Petechial lesions were also observed in both legs. Given the severity of the neurological involvement and the patient's personal history, she was admitted to an internal medicine ward. Analytically, the patient presented negative rheumatoid factor, cryoglobulins and serum immunofixation, and normal complement. Thoraco-abdomino-pelvic Computerized Tomography did not show adenopathies. Nerve conduction study was compatible with mononeuritis multiplex. The patient started treatment with 1g/day methylprednisolone at admission and for 3 days, which was switched afterwards to 60mg/day prednisolone. No biopsy of both nerves and muscle was performed because of its doubtful utility. The petechial lesions disappeared and symptomatic improvement was obtained. At time of discharge, the patient presented only decreased wrist flexion and manual dexterity of the right superior limb.

Discussion

Peripheral nerve vasculitis appears to underlie mononeuritis multiplex: inflammatory infiltration of the vessel walls leads to endothelial cell destruction with fibrinoid necrosis, vessel lumen occlusion and ischemia. Prompt immunosuppressive treatment is required to prevent permanent axonal degeneration. Aggressive therapy with steroids and immunosuppressive agents (i.e. cyclophosphamide) may be required; however, even combined therapy does not always yield satisfactory therapeutic results.

#877 - Case Report

FAHR'S DISEASE: A CLINICAL CASE

André Matos Gonçalves, Marisa Roldão, Ana Rita Sanches, Sónia

Cunha Martins, Isabel Ambrósio, Margarida Sousa Carvalho

Centro Hospitalar Médio Tejo, Torres Novas, Portugal

Introduction

Familial Idiopathic Basal Ganglia Calcification (FIBGC) also known as Fahr's Disease, is a rare neurodegenerative disease, genetically inherited or sporadic, characterized by abnormal quantities of calcium deposits in the basal ganglia and cerebral cortex. The disease usually manifests itself in the asymptomatic form through the presence of neurological symptoms: progressive deterioration of the cognitive function, changes in the motor functions and speech, muscle cramping, athetosis, chorea, dystonia, ataxia, seizures, and headaches. The diagnosis, although difficult, is based on clinical, analytic (hypocalcemia), and imaging (calcification of the basal ganglia) elements.

Case description

Next it is described the case of a male, 56 years old, autonomous, with prior history of heart failure, benign prostatic hyperplasia, depressive syndrome, history of acute myocardial infarction, and family history of consanguinity. Patient is being followed by Neurology since 02/2019, from where he has been referred for slow gait, involuntary movements of the upper limbs, and memory loss when performing the activities of daily life. Additionally, presented hypocalcemia in a previous analytic study along as an "exuberant basal-basal calcifications and bilateral tachyma (...) probable Fahr's disease" in a previous brain CT scan. During the neurological examination the patient presented a facial amelioration, slow gait, broad base and stiffness on four limbs, with dystonic movements of the lower limbs. A Brain MRI imaging complementary study was performed which confirmed the brain CT scan results. Analytical study also confirmed hypoparathyroidism with hypocalcaemia. In 03/2019 the patient was admitted in Internal Medicine service, where a new analytical study confirmed the previous results. A genetic test (SLC20A2) was performed and awaits results. The patient initiated the calcium replacement with analytical improvement, being maintained as an outpatient. A follow-up is maintained at Neurology and Internal Medicine consultation.

Discussion

Fahr's disease is a rare neurodegenerative disease, which can range from asymptomatic to the presence of nonspecific neurological symptoms. These characteristics contribute to a difficult diagnosis. The recommended treatment consists of calcium replacement. However, such treatment contributes to a deterioration of the cognitive and neurological state, through the progressive deposition of calcium in the cerebral cortex. Therefore, the prognosis is reserved.

#885 - Case Report

BENDAMUSTINE ENCEPHALOPATHY, A RARE ADVERSE EFFECT

Carolina Amado, Mariana Silva Leal, Tiago Valente, Ana Rocha Oliveira, Marcelo Aveiro, Margarida Cruz
Centro Hospitalar Baixo Vouga, Aveiro, Portugal

Introduction

Bendamustine is a chemotherapy agent used in the treatment of non-Hodgkin's lymphoma as a rescue therapy. Known adverse effects are mainly hematologic and gastrointestinal, although there are few reports of neurological toxicity.

The authors present a case of neurotoxicity after bendamustine-rituximab (BR) treatment.

Case description

A 79-year-old man with follicular lymphoma with diffuse large B-cell lymphoma transformation (R-IPI 2, FLIPI 2, Bulky disease) underwent 8 cycles of R-CHOP. Once he presented partial remission, it was followed by 6 BR cycles and 1 cycle of rituximab. After 2 months, the patient presented to our hospital with asthenia, apathy and periodic disorientation, being observed by Psychiatry and assumed reactive depression. Symptomology got worsened, and the patient was hospitalized. He denied fever or any other symptoms. There was no history of alcohol, tobacco or drugs consumption, nor other relevant medical past history. Physical examination revealed a conscious but slowed down and inattentive patient, without other relevant signs. Blood analysis showed no elevated inflammatory parameters, ionic disturbances or thyroid function alterations; B12 and folate levels were normal; HIV and syphilis serology and auto-immunity study were negative. Cerebrospinal fluid (CSF) analysis were negative and showed no lymphoma or infectious aetiology (bacteria, Herpes simplex 1 and 2 virus, Human herpesvirus 6, John Cunningham virus, Epstein-Barr virus, Cytomegalovirus, Toxoplasma gondii and fungi); serum and CSF anti-neuronal antibodies were negative. Head CT and MRI showed no significant alterations and EEG was compatible with moderate encephalopathy. Thoracic-abdomen-pelvic CT presented stable disease. One month later head MRI, EEG and CSF evaluation were repeated with overlapping results. In light of negative findings from the wide investigation performed, and time causality, it was assumed a severe neurologic sequelae secondary to bendamustine use, enhanced by rituximab. Despite treatment with intravenous steroids and immunoglobulin, the patient died.

Discussion

Bendamustine is generally well-tolerated, although it can cause progressive weakness and encephalopathy. Rituximab is often a cause of chronic encephalopathy and can be considered as an enhancer.

Early drug discontinuation is the first step, but the outcome is variable. Further studies are needed to clarify toxicity mechanisms and rare adverse effects reports are essential to alert physicians to their possibility.

#900 - Abstract

ACUTE ISCHEMIC STROKE IN PATIENTS WITH AND WITHOUT DIABETES MELLITUS

Palmyra Tsiftsi¹, Christina Kotsiari¹, Dimitrios Tsiolpidis¹, Asimina Migdalia¹, Chasan Ali¹, Savvas Katsaridis², Berkay Mollagiousoufoglou¹, Vasilios Tsipizidis¹, Argyrios Tsatsakoulis¹, Theodoros Kostakis¹, Elisavet Makridou¹, Paschalis Karagiozakis¹, Triada Exiara¹

¹ General Hospital of Komotini, Komotini, Greece

² Alexander Technological Educational Institution of Thessaloniki Department of Nutrition and Dietetics, Thessaloniki, Greece

Background

Diabetes mellitus (DM) is a well-established independent risk factor for acute ischemic stroke (AIS). The aim of this study was to identify and compare distinctive patterns between diabetic and non-diabetic population with AIS.

Methods

358 consecutive patients with AIS, who admitted to our hospital during last three years, were studied. Clinical, laboratory and demographical data, risk factors and outcome registered and analyzed. SPSS 20 package was used for statistical analysis.

Results

71(19.8%) patients were diabetic and 287(80.2%) were non-diabetic. The mean age of patients with and without diabetes was 61.4 ± 10.1 vs. 64.2 ± 11.2 , $p=0.034$, respectively. There was no difference between the two populations in the sex ratio. Risk factors in diabetic and non-diabetic population were: hypertension 51 (71.8%) vs 168 (58.5%), $p=0.037$, ischemic heart disease 16 (22.5%) vs 35 (12.2%), $p=0.028$, valvular heart disease 4 (5.6%) vs. 41 (14.3%), $p=0.035$, atrial fibrillation 4 (5.6%) vs. (12.5%), $p=0.048$, renal dysfunction 14 (19.7%) vs. 30 (10.5%), $p=0.022$, previous cerebral infarct 18 (25.4%) vs. 44 (15.3%), $p=0.043$, respectively. The lipidemic profile in diabetic and non-diabetic population was: high density lipoprotein cholesterol (HDL) 36.7 ± 11.4 vs. 51.3 ± 5.4 , $p < 0.001$, low density lipoprotein cholesterol (LDL) 105.3 ± 30.5 vs. 103.7 ± 27.9 , $p=0.83$, triglycerides (TG) 218.3 ± 66.4 vs. 151.3 ± 61.5 , $p < 0.001$, respectively. Complications during the hospital stay were higher in patients with DM. In-hospital outcome, mortality was higher in diabetic patients, 15(21.1%) vs. 35(12.2%), $p=0.045$, respectively.

Conclusion

Patients with DM had higher risk burden for AIS and poorer hospital outcome than non-diabetic patients. Successful control of diabetes and other risk factors is the key to prevent AIS.

#927 - Case Report

SPINAL CORD INFARCTION – ABOUT A CASE REPORT

Marta Dalila Martins, Hugo Pinheiro, Inês Ferreira, João Rocha, Mari Mesquita

Centro Hospitalar Tâmega e Sousa, Penafiel, Portugal

Introduction

Spinal Cord Infarcts are rare and can vary in onset, severity and outcome. The onset of spinal cord infarction is typically abrupt and the consequences are frequently disabling, being largely defined by the vascular territory involved.

Case description

Female, 95 years old and autonomous, with history of hypertension, type 2 diabetes mellitus and anemia. Admitted for study after sudden onset of motor deficits. On the previous day, the patient resorted to the Emergency Service with back pain with anterior bilateral irradiation and supraventricular tachycardia. After adenosine and bisoprolol administration, she returned to sinus rhythm and was discharged. Upon admission, the neurological examination showed mild dysarthria, distal deficits of the upper limbs and absent osteotendinous reflexes other than C5 and C6. Muscular strength in the left lower limb grade 2 and right lower limb grade 3-4, absent osteotendinous reflexes, without urinary retention and with a positive bilateral Babinski sign. Analytically with microcytic anemia and mild renal dysfunction. Brain computed tomography showed incipient signs of atherosclerotic microangiopathic subcortical leukoencephalopathy and discrete bilateral lenticulocapsular lacunar infarcts and non-recent ischemic infarction in the left cerebellar hemisphere. Cervical CT showed degenerative alterations insufficient to justify the clinical presentation. Lumbar puncture was performed and cerebrospinal fluid analysis allowed the exclusion of an infectious etiology of the central nervous system and of Guillain-Barré syndrome. A cervico-dorsal magnetic resonance imaging was then performed, which showed an extensive medullary hyperintense lesion, extending from C6 to D4, presenting central predominance, causing mild spinal expansion. The lesion also presented discrete nodular heterogeneous enhancement. Two diagnostic hypotheses were raised: spinal cord infarction versus longitudinally extensive transverse myelitis. The immunological study was normal with negative anti-neuronal antibodies and aquaporin 4 antibodies favoring the diagnosis of spinal cord infarction.

Discussion

Spinal cord infarction is a rare but often devastating disorder. Patients typically present with acute paraparesis or quadriplegia, depending on the level of the spinal cord involved. Back or neck pain is often present, typically occurring at the level of the lesion. The diagnosis is generally made clinically, with neuroimaging to confirm the diagnosis and exclude other conditions.

#951 - Case Report

VERTIGO: COMMON SYMPTOM, CHALLENGING DIAGNOSIS

Estela Ferrão, Francisca Pulido Valente, Rodrigo Pereira Andrade, Maria José Grade, Luísa Arez

Algarve University Hospital Center; Hospital de Portimão, Department of Internal Medicine, Portimão, Portugal

Introduction

Vertigo and unbalance are common symptoms, responsible for about 3% of the emergency room (ER) visits. Although the majority of their causes are benign, they can represent life threatening situations. About 10% of the cerebellar stroke patients only show vertigo symptoms and the posterior circulation stroke is twice more missed than the anterior one.

Case description

A 67-years-old healthy man, presents to the ER with a sudden onset complaint of vertigo when waking up, imbalance while standing, unsteady walking, nausea, vomiting and occipital headache. The symptoms were worsened by head movement.

He was discharged without being observed by an Internal Medicine specialist, medicated with metoclopramide and betahistine but returned 2 days later, keeping the same clinical picture.

Physical exam: BP 179/117 mmHg. Horizontal right beating nystagmus, not fatigable. Romberg test with preferential leftward fall, ataxic gait, left lateropulsion with gait.

Head CT: without alterations.

ENT observation: Vertigo Syndrome suspicious of a central disorder.

He was admitted with a diagnosis of posterior ischemic stroke, starting therapeutic approach accordingly. Initially he was not able to get out of bed and had a very slow improvement of his disabling symptoms during the hospital stay.

Additional investigation was performed including head MRI, serologies, audiometry and tympanometry, acoustic reflex test, ENT and Neurology observations. Finally, a diagnosis of left vestibular neuritis was made and the patient was discharged with a vestibular rehabilitation program.

Discussion

This case highlights the importance of the Internal Medicine Specialty and its holistic approach to the patient, and also the difficulties when evaluating a patient with complaints of vertigo and dizziness.

Because of the associated high morbidity and mortality, it is crucial to rule-out a stroke in the first place.

Since the imaging tests are not always available or reliable, it is suggested to perform simple tests such as HINTS TEST in the ER setting, to distinguish a peripheral cause from a central cause with a high degree of certainty, in a patient presenting with an acute vestibular syndrome.

The case also emphasizes that even if a preliminary diagnosis is made in the ER, the hospitalized patient should be carefully and

systematically evaluated, because in a high number of cases it may not correspond to the definitive one.

#972 - Case Report

A 78-YEAR-OLD MAN WITH HEADACHE

Flávio Moniz Mendonça, Marina Raquel Santos, [Ana Margarida Temtem](#)

Hospital Central do Funchal, Funchal, Portugal

Introduction

Headache is one of the most common pain symptoms and a frequent cause for doctor visits. A sudden and intense headache can suggest a diagnosis potentially severe more than a recurrent headache. The International Headache Society classifies headache in primary or secondary. Hypnic headache is a rare headache syndrome that may occur either as a primary headache or as a headache secondary to potentially malignant processes. The cause of hypnic headache is not understood. While hypnic headache is rare, the actual incidence and prevalence are unknown.

Case description

The patient is a 78-year-old Caucasian male who presented to an emergency room complaining of a sudden headache that developed only during sleep and causing awakening for minutes to an hour. The patient did not have other symptoms either before or during the event as migrainous symptoms. A careful medical and drug history revealed a known coronary disease approximately for 10 years and had undergone with felodipine/metoprolol, acetylsalicylic acid and simvastatin at that time. There was no allergy history to any drugs. Clinical examination was normal. Highlight the neurological examination did not reveal any change just a probable polyneuropathy from the lower extremities. The patient's laboratory values were normal. Computed tomography of the brain did not show tumors or other lesions, injuries, intracranial bleeding, structural anomalies, infections or other conditions. This case was discussed with neurology, they suggested that was compatible with a hypnic headache. It was prescribed flunarizine and indomethacin once a day, before sleep.

Discussion

This patient's case demonstrates the fundamental importance of the differential diagnosis. An acute, sudden headache can reveal an aneurysm, brain hemorrhage, acute glaucoma, meningitis or even an initial manifestation of a persistent headache as hypnic headache, a rare syndrome headache. This communication is especially important to keep in mind the variety of cases we have to handle in the emergency room.

#1007 - Case Report

DOUBLE DISSECTION

Elsa Araújo, [Manuel Barbosa](#), Raquel Costa, Tiago Mendes, Bárbara Sousa, Helena Vilaça

Unidade Local de Saúde do Alto Minho, Viana Do Castelo, Portugal

Introduction

Spontaneous dissection is an important cause of stroke, particularly in young adults.

Neurologic sequelae may result from cerebral ischemia due to thromboembolism, hypoperfusion, or a combination of both.

Common causes include various degrees of trauma or spontaneous events. The proportion of patients with spontaneous artery dissection who are affected by a known connective tissue or vascular disorder is low.

Case description

A 42 year-old female with no pathological history of relevance was transported to the emergency department with impaired speech and strength deficit on the right side of her body. Neurologic examination revealed mutism, conjugate deviation of the left eye, right homonymous hemianopsia, right central facial paresis and right hemiparesis. The brain computed tomography (CT) with no evidence of injury, however, was not performed thrombolysis for being outside the window time. A cerebral CT angiography showed a cervical artery dissection with distal embolization of the M1 segment of the left middle cerebral artery. The patient was transferred to another hospital for an endovascular procedure which underwent successfully.

Etiological investigation was performed during the course of her hospital stay. The patient presented positive rheumatoid factor, antinuclear antibodies and anti-SSA antibodies. After consultation with rheumatology, a primary Sjogren's syndrome (SS) was considered as the most likely diagnose.

Approximately 8 months after the ischemic event, imaging was reassessed with cerebral CT angiography and it documented ectasia of the cervical segment of the right internal carotid artery, aspect, probably resulting from dissection. A diagnostic cerebral angiography was performed and confirmed chronic bilateral carotid dissection.

The patient evolved well under physical therapy, with complete recovery of the motor and language deficits.

Discussion

The patient had a chronic bilateral carotid dissection in which we could not identify any reason for arterial dissection in our patient except for SS. The occurrence of central nervous system (CNS) disorders in association with SS is considered to be rare and the actual prevalence of CNS involvement with SS is unknown. For this reason and because the possibility of recurrence, this patients must be followed closely, in an individualized approach, paying special attention to new signs of disease activity.

#1033 - Case Report

MYASTHENIA GRAVIS: AN UNEXPECTED DIAGNOSIS

Palmyra Tsiftsi, Dimitrios Tsiolpidis, Christina Kotsiari, Asimina Migdalia, Chasan Ali, Vasilios Tsipizidis, Bilal Bilal, Argyro Boutali, Paris Poursanidis, Triada Exiara

General Kospital of Komotini, Komotini, Greece

Introduction

Myasthenia gravis (MG) is a rare autoimmune neuromuscular disease characterized by fluctuating weakness of certain voluntary muscles rarely involving the respiratory muscles.

Case description

A 77-year-old female with medical history of hypertension well controlled with furosemide and irbesartan and diabetes mellitus type 2 with metformin, was admitted to our hospital with a three-month history of dyspnea on exertion which had progressed at rest. Drugs or trauma that could ventilatory failure was ruled out. The physical and neurological examination and cerebrospinal fluid analysis were normal. Laboratory evaluation and chest X-ray were normal. There was no evidence of pulmonary thromboembolism on the chest CT scan and no evidence of intracardiac shunting or congestive heart failure on the echocardiography. Cardiac brain natriuretic peptide and the pulmonary function tests were normal. Urine legionella antigen, HIV antibody, ANA titer, hypersensitivity panel and fungal serologies were all negative. The patient's dyspnea resolved with rest and supplemental oxygen. The patient was discharged, but re-admitted in three weeks with recurrence of her symptoms. Due to the fact that her symptoms were relieved at rest and fluctuating, a neurologic etiology was considered. Anti-MuSK antibody level was found to be elevated at 27 nM and she was started prednisone and pyridostigmine with good response to her symptoms. One year later she was asymptomatic.

Discussion

It is important to consider neurological causes when dyspnea is unexplained by cardiac and respiratory causes. Patients with positive Anti-MuSK antibody, have higher risk of respiratory failure, but respiratory failure as the initial presenting symptom is unusual.

#1076 - Abstract

MEAN PLATELET VOLUME IN ACUTE ISCHEMIC STROKE IS NOT ASSOCIATED WITH EARLY OUTCOME

Ana Silva Rocha, Filipa Leal, Luís Nogueira, Anabela Silva, Vitor Fagundes, André Paupério, Juliana Lopes, Helena Vilaça, Mari Mesquita

Centro Hospitalar Tâmega e Sousa, Penafiel, Portugal

Background

Ischemic stroke (IS) is one of the major causes of death and disability in the developed world. Platelets respond rapidly to

vascular injury and larger platelets aggregate more easily. Thus, mean platelet volume (MPV) is a marker of platelet reactivity. MPV and platelet count (PC) are inversely associated so that the total platelet mass remains constant. Some studies have demonstrated an association between IS and MPV. However, its correlation with IS severity or functional outcome has not been established yet.

The objective of this study was to assess whether high MPV was associated with early outcome and hospital mortality in acute IS.

Methods

Observational and retrospective study. Clinical data from hospitalised patients with the diagnosis of IS during the year of 2017 was collected. Demographic information, presence of cardiovascular risk factors (CVRF), functional status and a complete blood count (CBC) on admission were assessed. IS was classified according to TOAST classification and IS severity was assessed by NIHSS on admission. MPV was measured using an automated analyser. Functional outcome was classified according to mRankin scale at discharge.

We defined the following exclusion criteria: thrombocytopenia, medication that could affect PC, known disorders of the platelets, peripheral smear with platelet aggregates and no CBC available at admission. SPSS software was used for data analysis.

Results

Our analysis included 113 patients. PC was inversely associated with MPV ($p < 0,001$) and this association persisted even after a thrombotic event.

There was no statistically significant association between any CVRF and MPV. However, patients with history of smoking presented a higher PC ($p = 0,023$) but similar MPV.

NIHSS ranged from 0-28 but there was no correlation with MPV. Patients with LACI IS presented a higher MPV when compared with other subtypes ($p = 0,041$).

About 23,9% of patients underwent thrombolysis and this group presented a lower MPV ($p = 0,015$).

Mean length of hospitalization was $18,32 \pm 15,33$ days and it was correlated with higher PC ($p = 0,09$). MPV was not associated with mRankin scale score on discharge nor with hospital mortality.

Conclusion

Patients with LACI IS had higher MPV. History of smoking and length of hospitalization were correlated with PC. However, there was no evidence that MPV was associated with IS severity, functional outcome or hospital mortality. Further investigation is needed to evaluate the controversial association between MPV and IS outcome.

#1079 - Case Report

AMYOTROPHIC LATERAL SCLEROSIS - A RARE PRESENTATION

Rosana Maia, Marta Moreira, Duarte Silva, Pedro Pinto, Miguel Costa, Edgar Torre, Carmélia Rodrigues, Diana Guerra

ULS Alto Minho - Hospital de Santa Luzia - Viana do Castelo, Viana do Castelo, Portugal

Introduction

Amyotrophic Lateral Sclerosis (ALS) is an incurable and progressive neurodegenerative disease, with an annual incidence of 1-3/100,000 cases. It is characterized by the presence of signs and symptoms of first and second motor neurons, simultaneously.

Case description

Female, 72 years old, hypertensive, diabetic, with dyslipidaemia, non-smoker, autonomous, admitted to the Emergency Department due to worsening of the general state, gait slowing and dyspnoea. Asthenia, anorexia and weight loss (33 lbs) in 10 months. After undergoing Holter-24h, electromyography (EMG), echocardiogram, endoscopic study, bone scintigraphy and abdominal ultrasound, with unremarkable results, her family doctor made a diagnosis of Depression. At the physic examination: conscious, cooperative and oriented, with slowed speech, mucocutaneous pallor, blood pressure 185/74 mmHg, oxygen saturation (SatO₂) 86% (FiO₂ 21%). Cardiac Auscultation (A): S1 and S2 present, rhythmic, grade III/VI systolic murmur. Pulmonary A: respiratory sounds diminished, increased expiratory time. Gasometry (FiO₂ 21%), global respiratory insufficiency (RI): pH 7.35, pCO₂ 71 mmHg, pO₂ 51 mmHg, HCO₃ 40 mmol/L, SatO₂ 88%. Admitted to the Internal Medicine Service for hospitalization. Abdominopelvic CT - adenoma of the right adrenal gland. Mycobacteria cultural exam - negative. Despite normal ambulatory exams results, repeated EMG revealed a motor neuron disease, with bulbar attainment. Due to worsening IR, with acidaemia, non-invasive ventilation was started. The patient was later evaluated by Neurology and Pneumology that corroborated the diagnostic hypothesis placed - ALS. Follow-up: Progressive worsening of clinical condition, having died two months later.

Discussion

The authors intend to highlight the atypical presentation of the disease and the inclusion of this type of pathologies in the differential diagnosis of RI. RI is a life threatening symptom and is the most common cause of death in these patients. It may be the first manifestation of the disease, but it occurs more often months or years after the remaining symptomatology.

#1089 - Abstract

SPONTANEOUS INTRACEREBRAL HEMORRHAGE IN PATIENTS UNDER ANTICOAGULANT OR ANTIPLATELET THERAPY: DATA FROM AHEPA UNIVERSITY HOSPITAL OF THESSALONIKI

Christos Savopoulos, Georgia Kaiafa, Eleftheria Ztriva, Dimitrios Pilalas, Georgios Polychronopoulos, Areti Sofogianni, Georgios Chatzopoulos, Konstantinos Tziomalos, Thomas Tegos, Apostolos Hatzitolios

A' Propaedeutic Department of Internal Medicine, AHEPA University General Hospital, School of Medicine, Aristotle University of Thessaloniki, Greece, Thessaloniki, Greece

Background

The purpose of this study is to study the incidence of spontaneous intracerebral hemorrhage in patients receiving anticoagulant or antiplatelet therapy for secondary prevention of major cardiovascular events and to evaluate the severity of bleeding complications in these patients.

Methods

18 patient who were hospitalized with intracerebral hemorrhage at the A' Propaedeutic Department of Internal Medicine in AHEPA University Hospital of Thessaloniki, in the year 2018-2019, participated in our study. In order to evaluate the severity of the intracerebral hemorrhage, we used the revised Intracerebral Hemorrhage (ICH) score, which was assessed at the time of the patients' introduction. The score estimates the mortality and the good outcome of patients with intracerebral hemorrhage over the next 30 days and includes the calculation of the NIHSS functional scale, the volume of bleeding, its location and origin, and the age of the patient.

Results

Out of the 18 patients, 13 (72.2%) received anticoagulant and / or antiplatelet therapy - 4 anticoagulants, 7 antiplatelet therapy and 2 anticoagulants and antiplatelet therapy at the same time. Patients receiving anticoagulant and / or antiplatelet therapy had a higher ICH score and worse prognosis as shown from the follow up control. Five patients died within the next 30 days. All of them received anticoagulant or antiplatelet therapy.

Conclusion

Spontaneous intracerebral hemorrhage accounts for 10-15% of cerebrovascular strokes. A large proportion of patients with intracerebral hemorrhage receive oral anticoagulants or antiplatelet therapy for secondary prevention of major cardiovascular events . The progression and prognosis of intracerebral hemorrhage is worse in patients under anticoagulant and / or antiplatelet therapy and this appears to be related to the increased volume and extent of the hematoma. For this reason, new studies focus on the research of agents reversing the action of anticoagulant and antiplatelet therapy in cases of life- threatening bleeding complications.

#1110 - Abstract

ASSOCIATION BETWEEN THE MTHFR C677T POLYMORPHISM AND SERUM TOTAL HOMOCYSTEINE IN PATIENTS WITH EPILEPSY

Karima Sifi¹, Sabah Hanachi², Boulfkhad Assia¹, Karima Benmebarek², Salima Zekri¹

¹ Laboratory of Biology and Molecular Genetics Faculty of Medicine Salah Bounider Constantine 3 University, Constantine, Algeria

² Laboratory of Biochemistry of Constantine University Hospital Center, Constantine, Algeria

Background

The plasma content of homocysteine a pro convulsant depends on many factors, including the methylenetetrahydrofolate reductase (MTHFR) C677T polymorphism. The latter causes severe hyperhomocysteinaemia, especially in the homozygous state. To date, many case-control studies have investigated the association between MTHFR C677T polymorphism and epilepsy susceptibility. However, those findings were inconsistent. The objectives of our work were:

- to evaluate the relationship between the methylenetetrahydrofolate reductase C677T polymorphism and plasma homocystinemia (Hcy) on the occurrence of epileptic seizures in epileptic patients.

Methods

Our study included 101 controls and 100 patients with epilepsy from Eastern Algeria. The C677T polymorphism of the MTHFR gene was investigated by PCR / Digestion with restriction enzyme HinfI. Homocystinemia levels were assayed by chemiluminescence.

Results

Homocystinemia was higher in patients with epilepsy ($16.58 \pm 9.79 \mu\text{mol} / \text{l}$) than in controls ($15.80 \pm 8.41 \mu\text{mol} / \text{l}$), (p -value = 0.13231). In controls, our results did not reveal an increase in homocystinemia associated with mutated genotypes T677T and C677T of the MTHFR p -value = 0.111.

In patients with epilepsy, homocystinemias were significantly higher in the T677T and C677T genotypes than in the C677C genotype with respective p -values of ($p = 0.002777$) and ($p = 0.678769$).

Conclusion

Our results showed a relationship between the MTHFR C677T polymorphism and hyperhomocystinemia, which is in agreement with some data from the literature.

#1145 - Case Report

THE RARE SIDE EFFECTS OF ALCOHOL ABUSE

Marinha Silva¹, Inês Carvalho², Eduardo Freitas³, José Nuno Alves², Ana Filipa Santos²

¹ Hospital Santa Maria Maior, Barcelos, Braga, Portugal

² Hospital de Braga, Braga, Portugal

³ Unidade Local de Saúde do Alto Minho, Viana Do Castelo, Portugal

Introduction

Chronic alcohol abuse is a common disorder. Its effects include neurologic complications through both direct and indirect effects on the central and peripheral nervous systems.

Case description

A 43-year-old man, with chronic alcoholism (over 120 g daily), was brought to the emergency department after a two-week period of behavioural changes and psychomotor lentification. There was no history of illicit drug use. On initial assessment he was disorientated in time and place, with speech output reduced, his motor power was normal, sensitive evaluation disclosed no abnormalities and he had a broad-based stance. His blood pressure was normal and he had no fever. Cerebral computerized tomography revealed a callosal hypodensity and global atrophy, with no acute vascular lesions. Laboratory studies disclosed mild macrocytic anaemia and elevated liver enzymes; renal, thyroid and liver function were normal; systemic inflammatory biomarkers and serum ethanol were negative. Abdominal ultrasonography showed signs of steatosis, with no splenomegaly or ascites. Brain MRI confirmed the callosal lesion, with restricted diffusion and showed T2/FLAIR hyperintensities concerning callosal genu, body and splenium, suggesting Marchiafava-Bignami disease diagnosis. He was started on several vitamin supplementation (including IV thiamine), with good clinical outcome.

Discussion

Marchiafava-Bignami disease is an extremely rare affliction characterized by primary degeneration of the corpus callosum associated with chronic alcohol abuse. It may occasionally occur in patients who are not alcoholic but are chronically malnourished. Clinical manifestations include behavioural changes, cognitive deterioration, seizures, dysarthria, spasticity and gait ataxia. There are no treatment guidelines to date. However, case reports of Marchiafava-Bignami disease have shown a favourable response to thiamine, enhancing the synergism between alcohol neurotoxic effects and hypovitaminosis B1. With this case the authors intend to emphasize the importance of the early diagnosis and treatment to prevent irreversible complications, as this disease is often followed by a poor outcome, with rapid progression to coma or death.

#1151 - Case Report

MENINGIOMA – A PECULIAR CAUSE OF AN ISCHEMIC STROKE AND ORTHOSTATIC HYPOTENSION

Frederico De Almeida Garrett Soares Da Silva¹, Maria Inês Simões¹, Helena Rita¹, Luisa Arez²

¹ Centro Hospitalar Universitário do Algarve - Unidade de Portimão - Serviço de Medicina 3A, Portimão, Portugal

² Centro Hospitalar Universitário do Algarve - Unidade de Portimão - Serviço de Medicina, Portimão, Portugal

Introduction

Meningioma is the most common extra-axial brain tumor in adults and commonly originates in the suprasellar, frontobasal, temporobasal, sphenoid wing, or petroclival regions. Tumors situated in these locations often compromise cerebral blood flow by damaging intracranial blood vessels.

While temporary cerebral ischemia has been recognized as a complication of skull base meningiomas, the amount of documented cases of a meningioma causing an ischemic stroke are scarce.

Case description

This case report documents a woman of 87 years old, with history of hypertension, amaurosis since 1998 and a space occupant lesion discovered in 2016 incidentally by CT-scan after a cranio-cephalic traumatism.

Admitted through the emergency room complaining of headache and mention of prosopagnosia with 1 day of progress, the patient had high blood pressure (200/100 mmHg), with rhythmic pulse, no loss of strength or sensitivity alteration upon neurological examination, and laboratory tests showed no relevant changes.

Cranio-encephalic CT scan on admission described the already known lesion, compatible with a 5,5x3.5 cm meningioma on the anterior base of the cranium, producing a mass effect over hypothalamic structures, optic chiasm, mesencephalon, as well as molding of the third ventricle, arteries of the Willis polygon and carotid siphons. There was also evidence of an acute ischemic stroke in the territory of left anterior cerebral artery.

An MRI of the brain was ordered to clarify a potential relationship between the ischemic stroke and the meningioma, but that could not be recognized with certainty.

No indication for surgical intervention was found after discussion with neurology and neurosurgery, and palliative management was the option taken.

Even with adequate control of blood pressure during the hospital stay, the neurological state persisted. Persistent orthostatic hypotension was recognized during the hospital stay, possibly due to direct compressive effects on the medullary centers crucial for the maintenance of systemic blood pressure.

Discussion

Skull-base meningioma is a rare entity, for which clinicians need to be cautioned, due to the possibility of causing neurological

disorders. If surgical intervention isn't possible, there is the need to regular follow-up, blood pressure control and anticoagulation in some cases, in order to minimize the complications resulting from this condition.

#1154 - Case Report

THE VERACITY OF AN ISCHEMIC STROKE DIAGNOSIS

Maria De Araújo Barros Maia, Adriana Watts Soares, Luis Falcão, Virginia Visconti, Luisa Pereira, José Lomelino Araújo
Hospital Beatriz Ângelo, Lisboa, Portugal

Introduction

Ischemic Stroke is one of the major causes of mortality and morbidity in Europe. Hematological causes contribute to 1-4% of all the strokes.

Polycythemia vera is one of the chronic myeloproliferative neoplasms, characterized by clonal proliferation of myeloid cells, clinically distinguished by the presence of an elevated red blood cell mass. 15% or more of the cases can present as ischemic strokes.

Case description

The authors report a case of a 73-year-old caucasian male, with previous history of an ischemic stroke, controlled arterial hypertension, dyslipidemia and smoking habits, that was admitted at the hospital due to sense of imbalance, vertigo, nausea and homonymous left quadrantanopia of sudden onset. The CT scan showed an ischemic lesion of the posterior inferior left cerebellar artery territory. The routine complementary investigation to determine the etiology was inconclusive (normotensive values; low cholesterol levels; sinus rhythm; left atrial dilatation with no thrombus on the transthoracic echocardiography and small calcified atherosclerotic plaque of basilar artery). However persistent erythrocytosis (eryt. 8.04×10^{12}); Hb 17.2 g/dL; Htc 56.8%) and leukocytosis (13,000/L) were noticed, suggesting a possible hyperviscosity syndrome. Further investigation showed normal hemoglobin and protein electrophoresis; microcytosis and hypochromia on peripheral blood smear; iron deficiency (36 ug/dL) and erythropoietin < 0.1 mUI/mL. Polycythemia vera was posteriorly confirmed with identification of the JAK2 V617F mutation. The patient started therapy with phlebotomies and hydroxyurea, with a slow regression of the neurological symptoms and hematocrit correction, until now, with no new events.

Discussion

Although a rare cause of cerebrovascular disease, the importance of this diagnosis relates with the dramatic change of prognosis after correct treatment, with high reduction of future vascular events and with better median survival.

#1155 - Case Report

CEREBELLAR ATAXIA, A CHALLENGE

Catarina Carreira Da Costa, Sofia Perdigão, Victor Paz

CHTMAD - Unidade de Chaves, Chaves, Portugal

Introduction

Cerebellar ataxia is an infrequent clinical entity, which possible resolution is dependent on treatment of the lying cause. The fact that there is an extensive list of possible causes, from hereditary, paraneoplastic, toxic, to neurodegenerative conditions, makes the diagnosis and workup a challenge, and not readily accessible to a generalist mind.

Case description

71-year-old woman presented to the emergency department with a 3 days history of confusion and unsteady, wide-based gait, with inability to walk. The patient had previous history of long-term epilepsy medicated with phenytoin 100mg bid. No recent seizures were reported as well as no recent medication adjustment or history of recent viral or bacterial infections. Cranial CT showed marked cerebellar atrophy. The patient was admitted for further workup. As inpatient, a rapidly progressive clinical picture of severe discoordination of both limbs and torso, with periods of severe agitation with incapability of speaking intelligibly was established. Physical restraints and iv neuroleptics were instituted and lumbar puncture was performed. Cranial MRI was not performed due to patient's agitation.

After neurology consult, drugs measurement was made. Blood serum phenytoin levels were 52 ug/mL, being considered toxic levels above 20 ug/mL. Clinical improvement was evident after phenytoin washout. The patient was discharged without any speech impairment, able to walk with aid, and referred to physical rehabilitation.

Discussion

Cerebellar ataxia is a known secondary effect of phenytoin, mainly when toxic levels are achieved, and should have been a high suspicion diagnosis in this patient. The rate of development, the severity of the clinical picture, and the fact that the patient had a long-term controlled epilepsy with no recent medication adjustment, made it fall behind some diagnosis which intervention could be lifesaving. In this case, the discussion with a neurologist was crucial for the resolution of the case.

#1178 - Case Report

MULTIPLE EMBOLIC STROKES IN FOCAL SEGMENTAL GLOMERULOSCLEROSIS

WAQAR Haider Gaba, Ahmad Thaer Mahdi, Mariam Ghareeb Al Mansoori

Sheikh Khalifa Medical City, Abu Dhabi, United Arab Emirates

Introduction

Nephrotic syndrome (NS) has been associated with high risk of

thromboembolism (TE) among other complications. Studies have shown that the risk of both arterial and venous TE in NS patients are increased up to eight times compared to general population. Arterial TE is less reported and less understood compared to venous TE. Cerebral arteries are among the least reported sites of TE in NS patients.

Case description

Our patient is 19 years old Emirati male who is known to have horseshoe kidney and was diagnosed with NS due to Focal segmental glomerulosclerosis (FSGS) at the age of 17. His disease was difficult to control with multiple immunosuppressive treatments and high doses of steroids. He developed uncontrolled hypertension and progressive chronic kidney disease. He was admitted with hypertensive emergency and steroids induced psychosis. Later he developed CMV pneumonitis that required 6 weeks of Intensive care unit stay, then was discharged to the medical rehabilitation unit.

After 10 weeks of hospital stay, he complained of sudden bilateral visual loss associated with headache. Physical Examination revealed marked loss of visual acuity bilaterally, other cranial nerves were intact. Power in all limbs was slightly decreased but sensation was intact. MRI Brain showed embolic looking multiple territory infarcts of different ages with micro hemorrhages. Follow up CT head showed progression of the infarcts with regression of oedema. MRA brain showed arterial beading and was suggestive of vasculopathy. Extensive young stroke workup showed elevated total cholesterol and LDL, unremarkable trans-esophageal echocardiography, and negative vasculitis and thrombophilia screen. Our final diagnosis was multiple embolic arterial cerebral infarcts secondary to NS and FSGS. He was managed with aspirin, statins and antihypertensives.

Discussion

NS is associated with a hypercoagulable state which can lead to ischemic stroke. In a literature review of 30 cases reported as cerebral arterial TE in NS, the mean age of patients was 40.7 years, and the diagnosis of FSGS was in only 2 of these cases. Our patient is unique in that he is the third case reported to have cerebral arterial TE secondary to FSGS, and the youngest among them. Role of anticoagulants and antiplatelets in primary or secondary stroke prevention for NS remains undetermined. We believe that understanding the risks and morbidity of NS in young strokes is very important in the early detection and prevention of significant morbidity.

#1188 - Case Report

ANCA-NEGATIVE EOSINOPHILIC GRANULOMATOSIS WITH POLYANGIITIS PRESENTING AS MULTIPLE CEREBRAL INFARCTION

Regina Costa, Diogo Carneiro, Bruno Silva, Gustavo Cordeiro

Coimbra Hospital and University Centre, Coimbra, Portugal

Introduction

Eosinophilic granulomatosis with polyangiitis (EGPA) is a multisystemic autoimmune vasculitis which essentially affects small and medium vessels mostly of the lung and skin. It is frequently followed by peripheral eosinophilia and the extrapulmonary involvement is frequently associated with higher morbidity and mortality.

Case description

72 year-old woman admitted to the Emergency Room with left hemiparesis and altered state of consciousness with 12 hours of evolution. She had previous history of asthma diagnosed at age 40, hypothyroidism and dyslipidemia and she had discontinued oral corticoid intake for facial angioedema 4 days ago. Her cerebral CT scan showed a right occipital hypodensity compatible with a subacute vascular lesion but the CT angiography showed absence of any abnormal enhancement. Brain MRI showed multiple subacute occipital ischemic lesions and bilateral hemispheric microbleeds, which pointed to a vasculitic process. Cardioembolic sources were excluded. Patient also presented with eosinophilia of 35.80%. Chest CT was performed showing ground glass areas but no pleural effusion. Autoimmune screening was carried out and was negative, namely anti-neutrophil cytoplasmic antibodies (ANCA). Despite a Five-Factor-Score (FFS 2011) of zero points, due to the neurological involvement it was decided to initiate methylprednisolone in 1g bolus for 3 days, followed by methylprednisolone 1mg/kg/day with progressive improvement of neurological deficits.

Discussion

Despite presenting manifestations for several years, only in this hospitalization it was possible to diagnose the EGPA of this patient who meets 4/6 diagnostic criteria proposed by the American College of Rheumatology. Central Nervous System involvement in EGPA is rare and is more commonly related to cardioembolic stroke. ANCA's are indeed an aid in the diagnosis of EGPA, but their absence should not exclude the diagnosis, since they are present only in about half of the patients.

The prompt diagnosis of the neurological manifestations of EGPA allows an adequate treatment with a significant improvement of the prognosis of the patient. Once diagnosed, patients should be treated readily to prevent relapses and neurological sequelae.

#1206 - Medical Image

EXUBERANT HYDROCEPHALUS

Mariana Silva Santos, Daniela Luz Silva Rodrigues, Rodrigo Rufino, Catarina Carvalho, António Cardoso, Fátima Campante
Centro Hospitalar Barreiro-Montijo, Barreiro, Portugal

Clinical summary

A hydrocephalus is a condition caused by a disturbance of cerebrospinal fluid formation, flow or absorption, leading to an increased volume of this fluid.

Female, 45 years old, prior history of spina bifida causing paraplegia, nephrectomy, chronic kidney disease and several pressure ulcers. The patient was admitted with urosepsis and aggravated renal function, and had been stable for several days. Due to altered state of consciousness, a CT scan was performed and identified an enormous ventricular enlargement, apparently stable and probably related to a Chiari malformation. It should be noted that the patient's neurological exam was normal and there was no apparent cognitive impairment. Also, to our knowledge, the patient had never performed a CT scan.

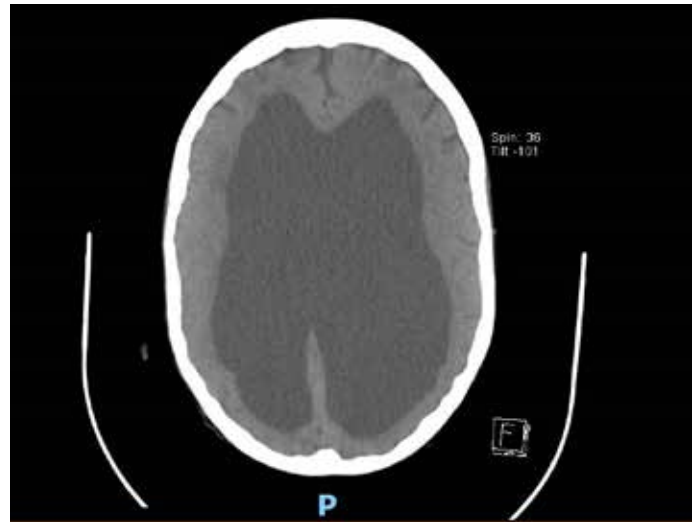

Figure #1206. Exuberant hydrocephalus.

#1213 - Abstract

DETECTION OF ATRIAL FIBRILLATION IN THE POST-STROKE SETTING – EXPERIENCE OF A PORTUGUESE HOSPITAL

Cecília Moreira, Magda Ventura, Emanuel Ferreira, Sara Salvador, Ana Rita Pais, Mário Fontes, João Rosinhas, Adriana Alves
Hospital Pedro Hispano, Matosinhos Local Health Unit, Matosinhos, Portugal

Background

Atrial fibrillation (AF) affects up to 3% of the population over 20 years and can lead to cardioembolism, responsible for about 30% of ischemic strokes. Despite the diagnostic workup, around 30% of the ischemic events remain of unknown etiology - perhaps due to paroxysms of AF. The identification of these events is of major therapeutic importance, favouring hypocoagulation. Currently there are recommendations for continuous ECG monitoring in the initial 24-48 hours. There is no clear evidence for cardiac monitoring afterwards.

Objectives

To describe the type of in-hospital and outpatient monitoring performed in individuals with cryptogenic stroke and to assess when and which exams to perform.

Methods

Retrospective observational study of all patients with a diagnosis of stroke in 2012 and a 5-year retrospective cohort of the ones discharged without etiologic diagnosis according to TOAST classification. In this last cohort, we calculated the rate of AF detection in 3 stages: 1st - admission (ECG upon admission), 2nd - hospitalization (external electrocardiographic continuous monitoring) and 3rd - 5-year monitoring in outpatient setting (ECG or Holter-24h). In the 2nd stage we also calculated the average number of hours until AF detection. SPSS Statistics 25.0 was used for statistical analysis and $p < 0.05$ was considered statistically significant.

Results

In a total of 259 patients included, 42% remained of unknown etiology at discharge. In the 1st stage, AF was detected in 7.8% and, in the 2nd stage, in 9.1% (>50% detected within the first 72h). A total of 88 patients completed the 5-year outpatient follow-up and 7 of these didn't repeat any type of electrocardiographic monitoring. AF was detected in 8.9%, with 50% of the cases detected in the first 12 months. The electrocardiographic reassessment was performed with ECG in 100% of the cases and only 25% did an additional Holter-24h. The diagnostic yield was 6.3% and 9.5% respectively.

Conclusion

The rate of AF detection in our study is similar to other studies and reinforces the need of prolonged cardiac monitoring in order to maximize AF detection. The highest yield was found during the first 72h of hospitalization and within the 1st year of outpatient follow-up, during when the Holter-24h seems to be the most helpful procedure.

The present study shows that there is no standardization in the type or timing of electrocardiographic monitoring but pointed out important information that enabled us to elaborate a protocol of performance.

#1262 - Case Report

NEUROINVASIVE WEST NILE VIRUS INFECTION: REPORT OF TWO CASES

Maysam Jeridi^{1,2}, Yosra Cherif^{1,2}, Maroua Mrouki^{1,2}, Fatma Ben Dahmen², Meya Abdallah^{1,2}

¹ Tunis El Manar University Faculty of Medicine of Tunis, Tunis, Tunisia

² Regional Hospital Ben Arous, Internal Medicine Department, Ben Arous, Tunisia

Introduction

Since its discovery in 1999, West Nile virus (WNV) has been associated with a wide spectrum of clinical features. It's a potentially fatal infection. We report 2 cases of WNV infection with neuroinvasive conditions.

Case description

Case 1

A 26-year-old patient with no medical history was admitted to our department of internal Medicine for lymphocytic meningitis. Physical examination revealed meningism, photophobia, muscle weakness. Laboratory tests showed hemoglobin 13.2 mg/dl, creatine kinase level 1400 U/l (normal range: 125–220 U/l) and C-reactive protein 48.06 mg/l (normal range < 8 mg/l). Cerebrospinal fluid (CSF) analysis showed 165 cells, glucose of 3.7 mmol/l and protein of 0.47 g/l (reference range: 0.15-0.45 g/l). Bacterial blood and CSF cultures were negative. All the serologies of Herpes simplex, Human immunodeficiency virus, hepatitis B, hepatitis C and varicelle Zona virus were negative. The serology of West Nile virus was positive. WNV-IgM and IgG antibodies detection was performed in serum and WNV-IgM tested positive 15 days apart. Magnetic resonance imaging (MRI) showed mild thickening and contrast enhancement of cauda equina nerve roots. Our patient was diagnosed with acute polyradiculoneuropathy due to WNV in an immunocompetent patient. He was treated with Aciclovir during 21 days. Muscle weakness and limb pain improved progressively.

Case 2

A 70-year-old patient with a medical history of diabetes mellitus presented to emergency department with 5 days of fever and headache. Physical examination showed an altered mental status, quadriplegia and aphasia. Laboratory analysis revealed neutropenia and elevated C-reactive protein 78 mg/l. CSF culture was negative. WNV-IgM antibodies tested positive in serum and cerebral MRI showed T2 and FLAIR signal hyperintensity in deep and subcortical white matter of the bilateral parietal lobes. Our patient was diagnosed with acute WNV encephalitis. He was discharged after 21 days with cognitive impairment and residual quadriplegia.

Discussion

In both reported cases WNV infection was revealed by neuroinvasive condition: acute polyradiculoneuropathy and acute encephalitis. Even though rare, neuroinvasive WNV infection should always be suspected during the WNV transmission season. It seems to be potentially fatal in elderly patients.

#1264 - Case Report

GANGLIONOPATHY AND PRIMARY SJÖRGEN SYNDROME: A NEW CASE REPORT

Amal Beya Chatti^{1,2}, Yosra Cherif¹, Maroua Mrouki^{1,2}, Mohamed Sami Zrida^{1,2}, Fatma Ben Dahmen², Meya Abdallah²

¹ Tunis El Manar University Faculty of Medicine of Tunis, Tunis, Tunisia

² Regional Hospital Ben Arous, Internal Medicine Department, Ben Arous, Tunisia

Introduction

In addition to glandular manifestations of Sjogren syndrome (SS), neurological manifestations can involve both peripheral and

central nervous systems. Sensitivomotivo polyneuropathy is by far the most common manifestation found in 60% of peripheral nerve damage. Pure sensory neuronopathy (SN) or ganglionopathy is rarely described. We report a new case of ganglionopathy revealing primary SS.

Case description

A 27 year-old patient with a history of Hashimoto thyroiditis, presented with abolished tendon reflexes, a tendency to fall on standing position and distal dysesthesias of the left arm initially and later progressing to bilateral lower extremities within 6 months. She plained of dry eyes and the Scirmer test was positive. The biological analysis, including diabetes, Hepatitis C, hepatitis B, HIV, anti-neutrophil cytoplasmic antibody, Vitamin levels, and Lyme disease were unremarkable. Electrodiagnostic studies revealed severe sensory neuronopathy (ganglionopathy) in all 4 limbs. Cerebral and spine magnetic resonance imaging revealed T2 hyperintensity in posterior cord. The search for anti-neuronal antibodies was negative. The immunological assessment revealed positive antinuclear antibodies, positive anti-Ro/SSA, anti-La/SSB and anti-RO52 and positive rheumatoid factor. The patient was later tested for paraneoplastic syndrome antibodies, which were negative. Our patient was diagnosed with ganglionopathy Sjörgen and was treated with corticosteroid during 1 year. Electrodiagnostic studies 1 year later showed similar results.

Discussion

We would like to report this case as their ganglionopathy Sjörgen is rare in clinical practice. Nevertheless, other differential diagnosis especially malignancies should be ruled out

#1267 - Case Report

ACUTE POST-INFECTIOUS CEREBELLITIS

Bárbara Pedro, Margarida Monteiro, Catarina Pereira, Tereza Patrícia, Fernando Aldomiro

Hospital Professor Doutor Fernando Fonseca, Amadora, Portugal

Introduction

Acute cerebellitis is a rare neuro-inflammatory syndrome, that occasionally follows systemic viral or bacterial infections, with the majority of cases described in children. But while in children it has been widely studied, less is known about acute cerebellitis in adults, due to the small number of cases reported.

Case description

A 52-year-old woman presented on emergency department with odynophagia, cough and fever with one week of evolution. Since three days, the patient had mild tandem gait difficulty, associated with occipital headaches and vomiting. Neurological examination did not show nystagmus, with postural tremor of both upper limbs, with an intentional component and slight dysmetria, associated with a broad base gait, impossible without support, with tendency to retropulsion. Computerized tomography (CT)

scan of the brain and cerebrospinal fluid (CSF) examination were normal. Serology, viral polymerase chain reaction (PCR) and cultures of CSF were normal. It was assumed an upper airway infection and amoxicillin-clavulanic acid and clarithromycin were started and maintained for 7 days. Blood serology for EBV, CMV, Influenza, HIV, Mycoplasma Pneumoniae, Chlamydia Pneumoniae and Legionella were negative. Brain magnetic resonance imaging (MRI) was normal. The patient's condition improved with motor rehabilitation, and after 2 weeks she was discharged.

Discussion

Acute cerebellitis in adults is a rare entity with a wide range in etiology, clinical presentation and outcome. This case aims to highlight the need for a high index of suspicion for diagnosing this condition in patients who present with an acute cerebellar syndrome in the setting of a febrile illness. Since in the literature, only a few cases of acute cerebellitis in adults have been described, further studies are necessary to establish diagnosis and treatment guidelines.

#1274 - Case Report

AN APHASIC EPILEPTICUS SYNDROME

Catarina Sousa Gonçalves, Nuno Reis Carreira, Marisa Teixeira Silva

CHULN, Lisboa, Portugal

Introduction

An epilepsy syndrome refers to a cluster of features incorporating seizure types, electroencephalographic and imaging features. It may also have distinctive comorbidities such as intellectual and psychiatric dysfunction. Aphasic epilepticus syndrome is a rare condition and it is characterized by aphasia without impairment of other cognitive functions, which is usually associated with structural brain lesions such as stroke, brain tumor and trauma. We report an epilepsy syndrome associated with aphasia in a patient with an acute subarachnoid hemorrhage who presented initially with nonketotic hyperglycemia.

Case description

A 73-year-old woman under anticoagulant therapy with rivaroxaban suffered a head injury after falling. One week later presented an alteration of the state of consciousness and was taken to the emergency room. The lab tests showed nonketotic hyperglycemia and an HbA1c quantified in 14,5%, as well as an acute non aneurysmatic subarachnoid haemorrhage in the left frontotemporal region shown on the tomography. On the third day of hospitalization, after the initiation of the correction of hyperglycemia, the patient was presented with Broca's aphasia, and therefore the EEG concluded a status epilepticus. After introduction of antiepileptics the clinical features disappeared and the following EEG showed absence of epileptic activity.

Discussion

Aphasia is a common symptom of seizure in post-ictal period. Ictal

aphasia prolongation is a rare condition called aphasic epilepticus syndrome. Usually these patients have lesions around and/or on the language cortex. There are also some reports of aphasic epilepticus syndrome in metabolic disorders. Furthermore, focal motor seizure and epilepsy can occur in 25% of nonketotic hyperglycemia. The presentation of aphasic epilepticus syndrome is not common in these patients. Even though it is well known, isolated aphasic epilepticus syndrome is rare and its diagnosis is not easy.

#1291 - Case Report

STROKE OF THE YOUNG ADULT – OCCULT, MULTIFACTORIAL OR CRYPTOGENIC ETIOLOGY?

Filipe Bessa, Pedro Silva Gaspar, Pedro Meireles, João Meneses, Rui Victorino, Catarina Mota
Centro Hospitalar Lisboa Norte - Hospital de Santa Maria, Lisboa, Portugal

Introduction

Ischemic stroke in the young adult requires an exhaustive diagnostic exercise with a wide range of possible etiologic factors. As such, it is increasingly common that some cases have more than one identifiable cause, with different prothrombotic factors that overlap leading to an increased thrombotic risk.

Case description

A 45 year old caucasian woman with no relevant medical background and on oral contraceptives, was admitted with language and writing alterations preceded by lipothymia. On neurologic examination, right central facial paresis and paraphasia with phrase repeating errors were found. The initial CT scan showed a left fronto-opercular sequelae cortico-subcortical lesion and 24 hours after it showed a recent left posterior insular cortico-subcortical lesion, suggesting ischemic lesions on two left median cerebral artery territories. The following investigation revealed a heterozygotic mutation of factor V Leiden and a positive Lupus anticoagulant test, the last not confirmed 12 weeks later. The remaining study of hereditary and acquired thrombophilias were negative. 24-hour Holter ECG was normal. Although asymptomatic, cerebral MRI showed new ischemic lesions on the semioval center and superior frontoparietal white matter. Transcranial and carotid triplex Doppler ultrasound showed the presence of frequent microembolic signs which intensified with Valsalva maneuver and transoesophageal echocardiogram was compatible with right-left shunt. Right heart catheterization was performed, but no patent foramen ovale was found. The contribution of cumulative prothrombotic factors in a young patient (factor V Leiden, oral contraception) was assumed, with concomitant paradoxical embolism due to Right-to-Left shunt of occult origin. The patient was started on anticoagulation with vitamin K antagonist, remaining without new events.

Discussion

The diversity of recognized etiologies for cerebrovascular events in young people requires a thorough investigation and careful follow-up. In addition to the events of undetermined etiology, to which occult sources of embolism frequently contribute, there is an increasing recognition of multifactorial etiology that hinders therapeutic decisions and secondary prevention strategies.

#1324 - Medical Image

FACIAL PALSY AND VESICULAR RASH - A CASE OF RAMSAY HUNT SYNDROME

António Epifânio Mesquita^{1,2}, Andreia Fernandes³, Lara Câmara¹, Francisca Martins¹, Catarina Patrício¹, Vítor Brotas¹

¹ Serviço de Medicina 2.3, Hospital Santo António dos Capuchos, Centro Hospitalar Universitário de Lisboa Central, Lisboa, Portugal

² Departamento de Fisiopatologia, NOVA Medical School, Universidade Nova de Lisboa, Lisboa, Portugal

³ Serviço de Neurologia, Hospital Santo António dos Capuchos, Centro Hospitalar Universitário de Lisboa Central, Lisboa, Portugal

Clinical summary

A previously healthy 77 year old woman presented with a 2 day history of difficulty closing her left eye and facial asymmetry. She reported left sided ear fullness but denied ear pain or rash, hearing loss, vertigo, tinnitus or otorrhea. She denied other neurological symptoms, fever, headache or recent tick bite. There was no history of trauma. On physical examination left sided peripheral facial nerve palsy was evident. Inspection of the left external ear revealed vesicular and crusted rash. Neurological exam was otherwise normal. A clinical diagnosis of Ramsay Hunt Syndrome was made. The patient was prescribed with oral course of prednisone and acyclovir. Two months after the diagnosis the rash has resolved. Facial palsy improved but the patient still needs physical therapy.

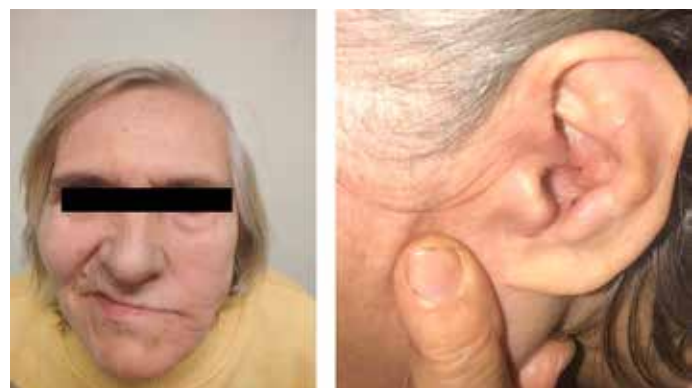

Figure #1324. Left sided facial palsy; vesicular and crusted rash on left external ear.

#1352 - Case Report

SPONTANEOUS INTRACRANIAL HYPOTENSION - CLINICAL CASE

Hilda Freitas¹, Antonio Cabral¹, Natalia Oliveira¹, Paulo Ferreira², Vanessa Machado², Cristina Ramalho²

¹ TrofaSaude Hospital Braga Sul, Braga, Portugal

² TrofaSaude Hospital Braga Centro, Braga, Portugal

Introduction

The diagnosis of spontaneous intracranial hypotension should be considered in patients who present with positional orthostatic headache, with or without associated symptoms, perhaps in the setting of minor trauma, and in the absence of a history of dural puncture or other cause of cerebrospinal fluid (CSF) fistula. Confirmation of the diagnosis requires evidence of low CSF pressure, most often by MRI (eg, pachymeningeal enhancement) or by radioisotope cisternography, and/or evidence of a CSF leak on other neuroimaging studies, mainly computed tomographic (CT) myelography.

Case description

The authors describe a clinical case of a 40 years old women, autonomous, no known diseases or chronic medication. She had headaches with about 1.5 months of evolution. She reported daily holocranial headaches that improved when she lay down. No previous head injury; without Anterior Lumbar Puncture; No history of otitis, and no nasal loss of CSF. Went to the Emergency Department by the intensity and persistence of headache. Se performed brain resonance (MRI) that revealed "subdural suffers, bilateral hemispherical, associated with engorgement of the venous sinuses. The cerebellar tonsils pop up the plane of the magnum hole.". During the hospitalization she made MRI of the cervical-dorsal-lumbar and sagittal column: "Discus prothusions. "Given a clinical suspicion, was performed Isotopic cisternography, which revealed bilaterally D5-D6 fistula. It was observed and oriented in addition by Neurosurgery. She presented a favorable clinical evolution, presenting asymptomatic to the discharge date. Epidural blood patch was performed later. She Has been followed up in consultation of Internal Medicine, being without headache, and asymptomatic.

Discussion

The authors intend with this case to call attention to the diagnosis for a rare pathology, which can often go unnoticed if we do not think about her, and whose diagnosis allowed the patient to solve the problem.

#1357 - Case Report

THE HEADACHE THAT WON'T GO AWAY

Ana Figueiredo Albuquerque, Maria João Palavras, Juliana Silva, Flávia Santos, Helena Carrondo, Célio Fernandes

Centro Hospitalar de Leiria, Leiria, Portugal

Introduction

Cerebral Venous Thrombosis (CVT) is an uncommon disease, with an annual incidence that ranges from 0.22-1.57 per 100,000, representing only 0.5-1% of all strokes. CVT refers to any clot in the cerebral venous system and it is divided into deep, superficial, and dural venous sinuses thrombosis. Several causative conditions have been described in CVT, such as thrombophilia's, inflammatory diseases, trauma and some medications are the main etiologic determinants of CVT.

Case description

We present the case of a woman with 38 years-old of age that came for the third time to the ER with 3-day evolution of occipital headache, photophobia, dizziness and one episode of vomits, with no neurological deficit. The patient had history of recurrent migraine, without other known diseases. Medicated with oral contraceptive since the last 9 months. The physical examination only revealed a discrete right central facial paresis.

The blood analysis showed a leukocytosis $12,8 \times 10^3/\mu\text{L}$, and an elevation of dimers ($=1207 \text{ ng/mL}$). A brain computed tomography without contrast was performed and displayed hyperdense signs in superior longitudinal sinus, with ischemic lesions on both the occipital and parietal lobes. The patient was medicated with a therapeutic dose of low-molecular weight heparin (LMWH; enoxaparin) 1 mg/kg/12h subcutaneously. Later on, the thrombophilia study revealed a MTHFRA1298C homozygous mutation.

Discussion

Cerebral venous sinus thrombosis is an uncommon and delicate condition with unpredictable presentation and prognosis. With this clinical case the authors intend to demonstrate the need to have a high index of suspicion to diagnose the CVT in a patient with migraine, otherwise it may have catastrophic outcomes. This patient had two predisposal factors, the mutation and the oral contraceptive medication, that lead into having a thrombotic event.

#1402 - Abstract

ATRIAL FIBRILLATION AND STROKE - A CHICKEN AND EGG EQUATION?

Mário Bibi, Sara Moreira Pinto, Alda Tavares, Rute Ferreira, Cristina Rosário

ULSM, Porto, Portugal

Background

The interplay between atrial fibrillation (AF) and stroke can be complex. It is well established that AF can lead to ischemic stroke (IS). However, there is a new concept of "neurogenic AF" in which AF appearing after a stroke can rather be a manifestation of the stroke and not the cause of it. This correlation is being investigated and is dependent on the localization of the cerebral injury.

Methods

A retrospective study was conducted, among patients admitted in an Internal Medicine Ward, between April of 2014 and June of 2015. The patients with AF were selected and epidemiological, clinical and analytical data was collected and analysed. The objective was to compare patients admitted with AF to those admitted with AF and stroke. Focus on the characteristics of the AF and underlying cardiopathy and decision to initiate anticoagulation. Statistical analysis was performed with SPSS software v25; values of $p < 0,05$ were considered statistically significant.

Results

A total of 236 admissions and 214 patients were examined. The median age was 77 years and 66% of patients were women. Sixteen individuals also had a stroke in the same hospital admission. There was more inaugural AF diagnosed in patients with stroke than those without (75% vs. 25%; $p = 0.004$). We observed a trend in patients with stroke to had less frequently known cardiopathy (25.0% vs. 56.8%, $p = 0.014$), as well as smaller atriums (median 43.0mm [35,49] vs. 45.4 mm [29-64]; $p = 0.302$). The subgroup of AF plus stroke was less frequently anticoagulated (31% vs. 59%, $p = 0,251$) and had a greater mortality (31% vs. 7%, $p = 0.014$). Readmissions at 12 months were similar.

Conclusion

AF is a known cause of IS and anticoagulation should be initiated when appropriate. However increasingly evidence suggests different mechanisms of AF, including the possibility of a neurogenic AF.

Our data suggests a difference between the AF in stroke and non-stroke patients, which can point to two different types of AF: a cardiogenic-related and a neurogenic-related. It is necessary to further study the AF that happens after an IS and to quantify its recurrence, risk of further strokes and anticoagulation need. Until then, the same indications to anticoagulation should be kept as in "general" AF.

#1433 - Case Report

SUDDEN ABDUCENS NERVE PALSY

David Prescott, Ana Isabel Brochado, Margarida Pimentel Nunes, Inês Branco Carvalho, Isabel Montenegro Araújo, Beatriz Donato, Rita Sérvio, José Luís Ferraro, Vasco Evangelista, António Martins Baptista, José Lomelino Araújo

Hospital Beatriz Ângelo, Loures, Portugal

Introduction

Pituitary macroadenomas represent up to half of suprasellar masses and are larger than 10 mm in size. They may be asymptomatic but generally present with cranial nerve defects, mainly optic chiasm compression with anopsia and sometimes oculomotor palsy. Isolated eye movement nerve palsies are rare, especially when affecting the trochlear and abducens nerves.

However, these changes may happen following cavernous sinus invasion, wall displacement or pituitary apoplexy.

Case description

In this case report we present the case of a fifty-six year old man who presents with a four day acute headache, followed by a two day isolated abducens nerve palsy, with complaint of horizontal diplopia and limited levoversion of the left eye. There were no other neurological changes, namely visual field defects. CT and MRI imaging identified enlargement of the sellar loca due to a left median and paramedian intra-sellar mass measuring approximately 12 by 14 mm, without evidence of haemorrhage, vascular lesions, cavernous sinus displacement or invasion. The mass was causing optic chiasm compression and hormonal dysfunction due to hyposecretion, with asymptomatic secondary hypothyroidism and hypogonadism in biochemical testing. After multidisciplinary discussion with Ophthalmology, Endocrinology and Neurosurgery, the patient was discharged after 8 days on levothyroxine and corticosteroid therapy, referenced to Neurosurgery and Neuroendocrinology follow-up.

Discussion

Ophthalmoplegia usually happens late in the natural history of the tumour and typically after and in conjunction with optic nerve defects, mostly affecting the third cranial nerve. Isolated palsy of the abducens (sixth) cranial nerve is even rarer due to its relatively protected placement inside the cavernous sinus, and therefore is generally affected only after the third and/or fourth cranial nerves. In this case, abducens palsy was seen without optic chiasma or oculomotor defects, even though the tumour was in contact with the optic chiasma and there was no identifiable invasion of the cavernous sinus. There was also no evidence of pituitary apoplexy. Pituitary tumours are a challenging diagnosis, and the differential has to be made with other possible central nervous system changes, namely other tumours and vascular lesions. Treatment is usually by trans-sphenoidal resection, with symptom and hormonal correction in most patients, and imaging follow-up at 3 months' time and then yearly.

#1475 - Case Report

FAHR'S DISEASE: A DIFFERENTIAL DIAGNOSIS OF EPILEPTIC SEIZURE

Gabriela Pereira, Ana Ferreira, Laura Castro, Magda Fernandes, Glória Alves, Jorge Cotter

Hospital Senhora da Oliveira, Guimarães, Portugal

Introduction

Fahr's disease is a rare neurological disorder characterized by abnormal calcified deposits in basal ganglia and cerebral cortex, commonly affects young to middle aged adults and clinical manifestations incorporate a wide variety of symptoms, ranging from neurological symptoms of extrapyramidal system to neuropsychiatric abnormalities of memory and concentration to movement disorders.

Case description

A 52-year-old female presented with sudden onset of generalised tonic-clonic seizure to the emergency department. Diazepam was given as the first-line antiepileptic drug, and the seizure was responsive to the treatment. After the patient regained consciousness, a neurological examination was performed. Abnormal neurological signs including dysarthria, sixth nerve palsy of the right eye and generalised neuromuscular irritability such as muscle cramps and tetany were found. Chvostek's sign and Trousseau's sign were positive. Over the past month, the patient family reported episodes of tonic-clonic movements of the limbs, progressive deterioration of mentality and audio-visual hallucinations with psychomotor agitation.

Laboratory studies including serum calcium 4.9 mg/dl (normal 8.4-10.6 mg/dl), phosphate 7.8 mg/dl (normal 2.3-4.7 mg/dl) and parathormone level 3.1 pg/ml (normal 15-65 pg/ml) demonstrated idiopathic hypoparathyroidism. Additional diagnostic laboratory tests including thyroid hormones and vitamins were within normal range.

Cranial CT scan showed extensive symmetrical intracerebral calcifications in both basal ganglia and radiated crown.

Sonographic examination revealed normal thyroid gland and parathyroid glands.

Parenteral calcium, calcitriol supplementation and intravenous fluid support were started with a favourable outcome.

Discussion

In conclusion, this is a case of a rare neurological disease with a variable prognosis and hard to predict. There is no reliable correlation between age, extent of calcium deposits in the brain, and neurological deficit. A slowly progressive course is usual and there's no standard treatment.

#1503 - Case Report

MULTIFACTORIAL ENCEPHALOPATHY: CHRONIC INTOXICATION BY LITHIUM AND SEPSIS

Maria Duarte¹, Raquel Rocha², Miguel Silva², Susana Marques De Sousa¹, Inês Amaral Neves¹, Filipe Correia²

¹ Centro Hospitalar Póvoa de Varzim/ Vila do Conde, Vila Do Conde, Portugal

² Hospital de Pedro Hispano, Matosinhos, Portugal

Introduction

Lithium is indicated to treat bipolar disease, especially for acute mania and maintenance treatment. However, its mechanism of action has not been fully elucidated. The excretion is renal and, although freely filtered, about 60% is reabsorbed in the proximal tubules. Volume depletion and renal damage are associated with increased reabsorption, leading to chronic intoxication with neurological, cardiac and renal manifestations.

Case description

We present the case of a 67-year-old woman living in a nursing home, dependent on external help for routine daily activities, with history of heart failure, chronic kidney disease (CKD) and bipolar disorder under lithium therapy, 400 mg bid. She was admitted to the hospital for fluctuations in mental status and myoclonic jerks with 10 days of evolution. Brain computed tomography was normal. Serum lithium dosing revealed toxic levels (3.96 mmol/L) and was discontinued. Empirical antibiotic therapy with ceftriaxone was started due to nosocomial urinary tract infection and the patient was transferred to an Intermediate Care Unit for sepsis with haematological, metabolic, neurological and renal dysfunctions. On admission, physical examination showed marked fluctuations in alertness and attention status, oromandibular dyskinesia and upper limbs and palpebral myoclonus. The electroencephalogram revealed diffuse cortical dysfunction without epileptic activity. The patient improved gradually after escalation of antibiotic therapy, adequate hydration and hemodialysis for lithium clearance.

Discussion

Older adults are especially vulnerable to lithium toxicity due to reduced glomerular filtration rate and volume of distribution. In this case, there was already a known CKD and chronic intoxication by lithium led to the initial neurological findings of encephalopathy and neuromuscular excitability, thus emphasizing the importance of clinical and analytical monitoring of patients under narrow therapeutic window drugs. The worsening of neurological status was multifactorial with septic encephalopathy contributing to the greater severity.

#1512 - Case Report

MANAGEMENT OF ASYMPTOMATIC CAROTID STENOSIS IN A PATIENT WITH RECENT ACUTE MYOCARDIUM INFARCTION AND ISCHEMIC STROKE

Maria Duarte¹, Raquel Rocha², Joana Ricardo Pires³, Filipe Correia²

¹ Centro Hospitalar Póvoa de Varzim/ Vila do Conde, Vila Do Conde, Portugal

² Hospital de Pedro Hispano, Matosinhos, Portugal

³ Centro Hospitalar do Baixo Vouga, Aveiro, Portugal

Introduction

Atherosclerosis is a systemic inflammatory disease that mainly affects large and medium-sized arteries. Atherothrombosis of the extracranial carotid arteries may result in ischemic stroke, either by embolism of thrombotic material or low blood flow due to stenosis with inadequate collateral compensation.

Case description

We report the case of a 65-year-old woman with metabolic syndrome and a history of two lacunar strokes and two episodes of acute coronary syndrome without ST-segment elevation:

the first at 63 years of age, treated with coronary artery bypass grafting; the second treated with angioplasty and stenting just three days before new admission in the emergency department, this time due to imbalance. Neurological examination showed nystagmoid saccades in the horizontal pursuit eye movements, mild flattening of the left nasolabial fold and right hemiparesis due to prior stroke, with no other remarkable changes. Brain magnetic resonance imaging revealed multiple ischemic lacunar lesions in the right side of the pons, one of which was acute. Carotid and transcranial Doppler ultrasonography revealed left internal carotid artery stenosis >90 percent and occlusion of the left vertebral artery. Therefore, the patient had a carotid stenosis that did not contribute to the vertebrobasilar stroke but was severe and progressing compared to previous exams. She underwent carotid artery stenting, which occurred without intercurrents.

Discussion

In patients with asymptomatic carotid stenosis (≥ 50 percent), the annual risk of ipsilateral stroke is 0.5-1.0 percent, being recommended intensive medical treatment. For patients with stenosis of 60 to 99 percent and high risk of stroke, revascularization by carotid endarterectomy may be considered. Despite evidence of similar long-term outcomes, carotid artery stenting appears to be associated with a higher risk of periprocedural stroke and death. However, in this case of a patient who had recently undergone coronary artery stenting, the risks of discontinuation of dual antiplatelet therapy for endarterectomy clearly outweighed those of angioplasty.

#1528 - Abstract

STROKE MIMICS ADMITTED TO A STROKE UNIT: A ONE-YEAR CASE SERIES

Margarida Massas, Vera P Sarmiento, Vasco Neves, Ana Bernardo, Maria Piteira, Tereza Veloso, Carmen Corzo, Sílvia Lourenço, Conceição Barata, Luísa Rebocho
Hospital do Espírito Santo de Évora, Évora, Portugal

Background

The differential diagnosis of cerebrovascular diseases (CVD) can be challenging. Several disorders may present similarly to a stroke, prompting the same management, including admission to a Stroke Unit. We aimed to determine and analyse the proportion of cases admitted with non-CVD to a Stroke Unit by any hospital physician in an acute stroke-ready hospita

Methods

We have reviewed the discharge notes of all patients admitted to a six-bed stroke unit during 2018, selecting those with non-CVD as their main diagnosis. We then fulfilled a previously designed database with socio-demographic and clinical variables. We have analysed the data descriptively.

Results

There were 323 patients admitted to the stroke unit during 2018, from which 55 (17%) were diagnosed with non-CVD. Of these, 31 were women (56%). The mean age was 61 ± 16 y.o. The 55 patients were admitted for a mean of 3.7 ± 2.4 days. Almost half the patients ($n=28$) presented with motor and/or sensitive deficits. Other common presenting symptoms were confusion ($n=10$), headache ($n=8$), decreased level of consciousness ($n=8$), vertigo ($n=8$) and speech changes ($n=7$). Only 9 (16%) had Cincinnati criteria for fast-track activation and none was submitted to thrombolysis. NIHSS at admission ranged from 0 to 8 pts (median 2.1, IQR 0 - 3.8), with 47 patients presenting with up to 4 pts. The most frequent diagnosis was epilepsy ($n=9$), followed by headaches ($n=8$). Seven patients had psychiatric disorders, whilst five suffered from global transient amnesia. Four cases were peripheral vertigos and three patients had facial palsy. Three cases were due to side effects of medications, whilst two were caused by low sodium level. Two patients presented with hypertensive crisis. There were seven patients with other less common disorders, and five patients still warrant further investigation.

Conclusion

The rate of patients with non-CVD admitted to this stroke unit is similar to that reported by other units around the world. The great majority of these patients present with diseases that do not benefit from this highly specialized level of care. Nonetheless, it is arguable whether this rate can be decreased, given the need for specialist testing that is not available at the A&E. It would be interesting to study the effectiveness of a stroke team in improving the diagnostic accuracy of stroke in the A&E setting.

#1551 - Case Report

TAKOTSUBO SYNDROME AND CEREBROVASCULAR DISEASE: A CASE ON AN UNCOMMON ASSOCIATION

Margarida Massas, Vera P Sarmiento, Diana Coutinho, Tereza Veloso, Carmen Corzo, Sílvia Lourenço, Conceição Barata, Luísa Rebocho
Hospital do Espírito Santo de Évora, Évora, Portugal

Introduction

Reports of thromboembolic complications in patients with Takotsubo cardiomyopathy have been increasing, being stroke the most common type of thromboembolic complications. However, neither the timing nor the treatment of the thromboembolic event resulting from Takotsubo cardiomyopathy have been well described.

Case description

Female patient, 48 y.o., treated for arterial hypertension and depression, with a two-week history of retrosternal pain with cervical radiation. She was admitted to the A&E department 1h30m after the sudden onset of facial asymmetry and decreased left

muscle strength. On neurological examination: left homonymous hemianopia, left central facial paresis, decreased muscle strength 3/5 and sensitivity of the left arm, dysmetria on the left finger to nose test. NIHSS at admission of 7 pts. After excluding intracranial hemorrhage and contraindications for thrombolysis, the patient was started on alteplase. The contrasted head CT revealed a thrombus in the M2 segment of the right middle cerebral artery (MCA), and she was immediately transferred to the reference hospital for thrombectomy. This was complicated by severe vasospasm of the M1 segment, with complete occlusion of the M2 branch. She was admitted to the Stroke Unit with a NIHSS of 16. Further exams showed inverted T waves on the EKG precordial leads and an increased troponin level. On the echocardiogram there was a marked apical ballooning of the left ventricle with a large thrombus inside (36x25 mm). The coronary angiogram suggested a possible spontaneous coronary dissection of the distal anterior descendant coronary artery. Hence, a diagnosis of an embolic ischemic stroke of the right MCA territory on a patient with a Takotsubo cardiomyopathy, possibly secondary to a spontaneous coronary artery dissection, was assumed. The patient was transferred back to the referring hospital with a NIHSS of 12, which remained unchanged. She was kept anticoagulated and discharged after regression of the LV thrombus.

Discussion

Intracardiac thrombus formation is a relatively common complication of Takotsubo cardiomyopathy, and the incidence of embolic stroke due to this syndrome is low (0 to 9.5%). The association between this heart disorder and cerebrovascular disease still warrants further investigation, considering it seems to be both a cause and a consequence of stroke. In this case, there is a complaint of chest pain two weeks prior to the stroke, making the Takotsubo cardiomyopathy the most likely cause of the stroke.

#1553 - Medical Image

CEREBRAL VENOUS THROMBOSIS: DIAGNOSIS WITH A NONCONTRAST CT

Margarida Massas, Vera P Sarmiento, Vasco Neves, Ana Bernardo, Tereza Veloso, Carmen Corzo, Sílvia Lourenço, Conceição Barata, Luísa Rebocho

Hospital do Espírito Santo de Évora, Évora, Portugal

Clinical summary

Man, 28 years old, history of arterial hypertension, obesity, hypercholesterolemia, smoking habits and alcohol abuse, presented to the A&E with a worsening intense headache over the course of 5 days. On the neurological exam a left horizontal nystagmus was detected. Head CT revealed a spontaneous hyperdensity of the superior sagittal sinus (red arrow head), with a dense delta sign (red arrow), adjacent cortical veins (blue arrow) and right lateral sinus, suggestive of acute venous thrombosis. Cerebral Venous Thrombosis represents approximately 0.5% to 1% of all strokes, with just 25% of these presenting with

headache only. Anatomic variability of the venous sinuses makes CT diagnosis of CVT insensitive without contrast, with abnormal findings present in less than 1/3 of the cases.

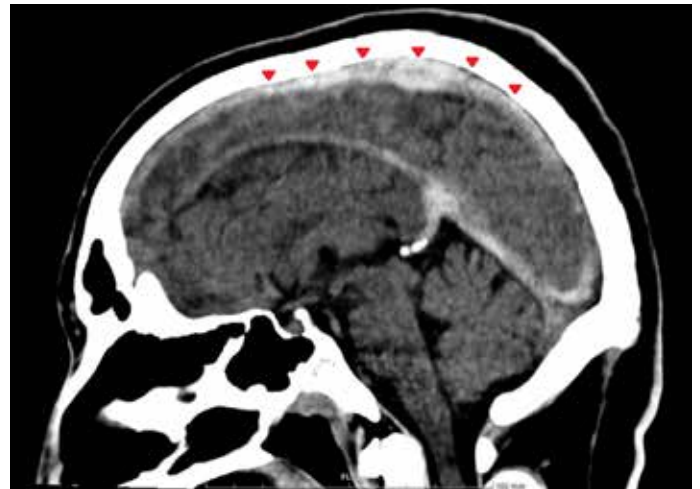


Figure #1553. Sagittal view of a noncontrast head CT. Red arrow head: hyperdensity of the superior sagittal sinus.

#1572 - Case Report

GIANT CELL ARTERITIS IN A 79 YEARS OLD MALE: A CASE REPORT

Ricardo Gomes¹, Ana Patrícia Gomes¹, Isabel De La Cal Caballero, José Proença¹, Ana Campelos², Leopoldina Vicente¹

¹ Internal Medicine Service - Centro Hospitalar Universitário Cova da Beira, Covilhã, Portugal

² IPATIMUP - Institute of Molecular Pathology and Immunology of the University of Porto, Porto, Portugal

Introduction

Giant cell arteritis (GCA) is a chronic inflammatory disease involving large/medium-sized arteries and the greatest risk factor is aging. The diagnosis should be considered in patients from 60 to 80 years old with de novo headaches, abrupt onset of visual disturbances, transient monocular visual loss, jaw claudication, unexplained fever, anaemia, and/or high serum erythrocyte sedimentation rate (ESR) and/or high C-reactive protein (CRP). Given the irreversible pattern of visual loss in most cases, when there is a strong suspicion, prompt treatment might be needed.

Case description

A male patient 79 years old reached the emergency service complaining of severe left occipital headaches, dizziness, asthenia and transient jaw claudication with more than 1 month of evolution. He had been evaluated 3 days earlier with the same complaints and fever with about 8 days of evolution and treated with ciprofloxacin, trazodone and iron supplements due to anaemia. Other symptoms were absent. He had controlled arterial hypertension (telmisartan/hydrochlorothiazide suspended 5 days earlier). The physical examination revealed tenderness of the left temporal artery. Neurological examination and cranial

tomography scan without relevant findings. Without postural hypotension. Lumbar puncture negative to central nervous system infection. Blood results showed anaemia (Hb: 9.8 g/dL) normocytic/normochromic, CRP 25.0 mg/dL and ESR: 110 mm/H. The patient began empirical ceftriaxone (7 days total). After 4 days in the hospital, he claimed sudden visual loss and was evaluated by an ophthalmologist that found cataracts on both eyes. Due to aggravating symptoms we began treatment with 70mg of prednisolone/day with improvement around 48 hours after the visual loss. The vasculitis, bacteriological and viral studies were negative. The histology of biopsy fragment of superficial branch of the left temporal artery revealed giant cell arteritis. The only relevant finding after discharge was transient hyperglycaemia due to corticoids.

Discussion

The diagnosis is based on histopathological or imaging exams (most commonly the temporal artery) given the potential complications related to high dose glucocorticoids. Although the tissue was collected 24h after glucocorticoid therapy, biopsy was positive. Treatment was instituted promptly once the diagnosis of GCA was strongly suspected. Although some studies defend treatment with pulses of intravenous corticoids, we opted for a more conservative approach with 70 mg/day orally.

#1588 - Case Report

SIMULTANEOUS ACUTE HEMORRHAGIC STROKE AND MYOCARDIAL INFARCTION: A MANAGEMENT CHALLENGE

Carlos Candeias, Marco Fernandes, Maria João Correia, João Pedro Marto, Nuno Ferreira, Teresa Mesquita, Luis Campos
Stroke Unit - Hospital S. Francisco Xavier - Centro Hospitalar Lisboa Ocidental, Lisboa, Portugal

Introduction

Simultaneous occurrence of acute myocardial infarction (MI) and Intracerebral hemorrhage (ICH) is uncommon among patients admitted to Emergency Room (ER). Both medical conditions are life-threatening, with a narrow therapeutic time. Even though the acute management of both clinical conditions is well documented in the literature, the management of both conditions, simultaneously, represents a challenge.

Case description

We report the case of a 73 year old male, admitted due to shortness of breath, dyspnea and chest pain lasting 48 hours. In the several hours preceding admission, it was noted he had altered mental status and a blood pressure (BP) of 250/110 mmHg. Physical examination showed a heart rate of 89 bpm, BP of 233/166 mmHg and a pansystolic murmur. Neurological examination revealed that the patient was confused, disoriented and with reduced sensation in his left lower limb and loss of sensation down the left-hand side of his body. He was also noted to have a left sided hemianopia.

Laboratory findings showed a troponin 841 µ/L. Non-contrast CT head showed an acute right parietal ICH, and his ECG showed ST segment elevation with T wave inversion V2-V6 and Q wave in anterior leads. Transthoracic Echocardiogram revealed a left ventricular thrombus and apical aneurysm. Patient was initially treated with non-fractionated heparin (NFH) and strict blood pressure control, as assessment by the cardiology team deemed him unfit for coronary intervention. For the first seven days in the stroke unit the patient had neurological improvements even with NFH treatment. At day eight of hospitalization the patient had a cardiorespiratory arrest but return of spontaneous circulation was achieved following CPR and defibrillation. The patient was then transferred to the coronary intensive care unit and underwent coronary angioplasty and stent placement. Following this the patient was treated with double antiplatelet therapy (APT) and anticoagulant therapy (ACT) with favorable clinical response.

Discussion

A delayed intervention in MI or ICH may result in permanent irreversible morbidity, disability, or even death. But the use of APT and ACT, that are a standard component of acute MI management, may risk worsening the patient's neurological condition. Since there is no clear evidence-based guideline or clinical studies that have addressed the optimal management of this rare co-occurrence, a multidisciplinary team approach is essential to manage these complex patients.

#1595 - Medical Image

CEREBRAL POSTERIOR STROKE

Nuno Bernardino Vieira, Alexandra Avila, Vanda Conceição, Maria José Grade, Luísa Arez
Serviço de Medicina 3 - Unidade Hospitalar de Portimão do Centro Hospitalar Universitário do Algarve, Portimão, Portugal

Clinical summary

An 72-year-old man former smoker was admitted with transient episode of syncope, diplopia, unilateral limb weakness and gait ataxia. On admission, he was alert but he maintained the diplopia and the imbalance. The CT scan doesn't reveal any new vascular lesions. The CT angiography revealed intracranial occlusion of the vertebrobasilar system (right and left vertebral arteries and the proximal third of the basilar artery). A couple of hours after the patient admission, presented clinical worsening with respiratory difficulty, decreased consciousness and left hemiparesis and he needed mechanical ventilation for his transportation to a differentiated unit where he received successful endovascular treatment.

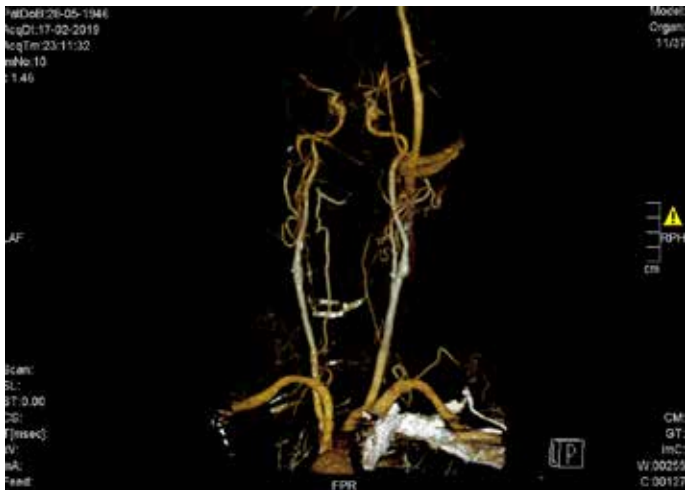


Figure #1595.

#1631 - Case Report

CENTRAL VENOUS THROMBOSIS IN A YOUNG FEMALE

Margarida Gaudêncio¹, João Sousa², Bruno Silva², Ricardo Veiga³, Bruno Rodrigues², Isabel Bessa¹

¹ Internal Medicine Department, District Hospital of Figueira da Foz, Figueira Da Foz, Portugal

² Neurology Department, Coimbra Hospital and University Centre, Coimbra, Portugal

³ Neuroradiology Department, Coimbra Hospital and University Centre, Coimbra, Portugal

Introduction

Central venous thrombosis is an increasingly frequent pathology, which is organized by the presence of thrombotic phenomena in the venous sinuses and cerebral veins. Responsible for 1% of all strokes, turning primarily to young adults. It presents a high variability in its clinical presentation, mode of installation but also etiology.

Case description

The case being reported is of a 46-year-old female patient that was referred to the emergency department for headache with 14 days of evolution, progressive, without photophobia or phonophobia, associated with nausea and paresthesia of upper limb and right hemiface. With a personal history of migraine and abnormal uterine bleeding. Medicated with oral contraceptives. At physical examination, was hemodynamically stable, conscious, oriented and cooperative, with right Barré and non-upper limb myotatic hyperreflexia. Without facial dysmetria and no change in eye movements.

Computed tomography (CT) angiography and venography of brain have shown venous thrombosis of 1/3 of the right transverse sinus, 1/3 posterior of the superior longitudinal sinus, as well as, 1/3 of the upper longitudinal sinus. Analytical exclusion of autoimmune pathology and thrombophilia. Accompanied in consultation of Vascular Risk, having completed 6 months of hypocoagulation

initially with warfarin but for labile INR, changed to edoxaban (60 mg daily).

In elective diagnostic cerebral angiography, was identified a dural arteriovenous fistula that results of the anastomosis of external carotid artery, muscular ramifications of the right vertebral artery, meningeal branches of right upper cerebellar artery with anterograde traction for the left transverse sinus and reflux to the superior sagittal sinus.

She underwent elective endovascular therapy, without intercurrents.

Discussion

Intracranial arteriovenous fistulae constitute a heterogeneous group of vascular malformations, constituting 15% of all malformations. From the anatomopathological point of view, they correspond to the anastomosis between the male arteries and the dural venous sinus. Clinically, this type of malformation may present with more aggressive symptoms to intracranial hypertension, relatively benign symptomatology or even incidental findings. In the literature, this malformation is present in about 1.6% of patients with central venous thrombosis.

#1632 - Case Report

WERNICKE'S ENCEPHALOPATHY – THE CLASSIC TRIAD

Vânia Mendes Junqueira¹, Tânia Lampreia², José Vale²

¹ Centro Hospitalar do Oeste - Hospital de Caldas da Rainha, Caldas Da Rainha, Portugal

² Hospital Beatriz Ângelo, Loures, Portugal

Introduction

Wernicke's encephalopathy (WE) is a neurological disorder characterised by a triad of oculomotor changes, ataxia, and confusion. Is caused by thiamine deficiency mostly due to chronic alcoholism, but other etiologies have been described. Neuropathology shows a hemorrhagic necrosis in the mammillary bodies, tegmentum of pons, periaqueductal area and the dorsal medial nucleus of the thalamus.

Case description

The authors present the case of a 37 years old male, who was brought to the ER because of strange behavior. He had an important history of chronic alcohol consumption and a mild depressive syndrome in treatment. He referred a generalized fatigue that begun 2 weeks before and since that wasn't able to get out of his home. In consequence no alcohol or food intake occurred during this period.

At admission the patient was awake, bradypsycic and unable to sustain attention. He had an ataxic gait, an exuberant horizontal-rotatory nystagmus and a franc limitation in abduction and adduction of both eyes. He reported distal hypoesthesia of the four limbs. Apart from dehydrated and malnourished, the physical examination was normal. Blood tests showed a slight leukocytosis.

Brain CT-scan showed no abnormal findings. At this point WE was very likely so the patient begun immediately thiamine EV. The following diagnostic workup showed a normal serum thiamine level (8.9 mcg/dL), but after thiamine supplementation had began; a folic acid and vitamin B12 deficit; and a negative screening for HIV and syphilis. The lumbar puncture showed no albuminocytological dissociation or pleocytosis. Anti-GQ1b IgG antibody and the microbiological study of CSF was negative. A Brain MRI was unremarkable

We also performed an EMG with the results suggesting a moderate left carp tunnel syndrome and a bilateral L3-L4 and L5-S1 neurogenic compromise. The CT scan of the lumbar spine showed some degenerative alterations without neurologic compression.

A remarkable improvement was seen during hospitalization, presenting at discharge only a slight limitation at abduction of both eyes, a minor nystagmus and the gait ataxia had also diminished.

Discussion

This classic triad in this clinical context should prompt immediately to IV thiamine as WE is associated with a high mortality rate with delayed treatment. Brain MRI can be normal. The frank improvement after a few days of treatment also corroborates our hypothesis. No full recovery was seen probably because of the delay in searching medical advice.

#1721 - Case Report

HYPERBARIC OXYGEN THERAPY IN THE TREATMENT OF CENTRAL RETINAL ARTERY OCCLUSION: A CASE REPORT

Helena Greenfield¹, Cátia Gaspar², Rita Gonçalves¹, Óscar Camacho¹, Lílíana Carneiro¹

¹ Hospital Pedro Hispano, Matosinhos Local Health Unit, Matosinhos, Portugal

² Instituto Português de Oncologia, Porto, Portugal

Introduction

Acute persistent visual loss, defined as a sudden deficit in visual function lasting more than 24 hours, can be caused by etiologies in three main categories: media, retinal, or neural pathway problems. An etiological determination is essential, since some causes, such as central retinal artery occlusion (CRAO), require immediate treatment.

Case description

The authors present the case of a 21-year-old male, who reported to the Emergency Room with sudden, painless vision loss of the right eye (OD), which had started 1 hour previously. His best visual acuity (VA) was hand motion of the OD, preserved in the left eye. Relative afferent pupillary defect was excluded. Biomicroscopy of both eyes was normal. Optical coherence tomography revealed incipient edema of the internal retinal layers of the OD. Retinography with retinal paleness. No further alterations on neurological examination were documented.

Cranial computed tomography angiography scan was normal. A clinical diagnosis of central artery branch occlusion was made, intravenous thrombolytic therapy was performed, with no objective improvement in VA and the patient was referred to hyperbaric oxygen therapy (HBOT), which was started within 7 hours of symptom development. There was a clear notion of VA improvement and upon ophthalmologic evaluation after 5 sessions with VA 3/10 OD and Goldmann visual field (GVF) with central scotoma OD. He completed HBOT with total VA recovery, and GVF with marked improvement.

Discussion

CRAO is an ophthalmological emergency, with longer blood flow interruption leading to severe retinal damage and irreversible vision loss. Therefore, prompt diagnosis and intervention are vital. Traditional therapies, however, have no proven clinical benefit HBOT has emerged as a potential sight-saving procedure when employed in the acute phase, the rationale for its efficacy is related to the retinal dual blood supply. Current knowledge suggests an early administration of HBOT is essential, with the time between onset and the start of oxygen therapy being critical in preserving visual acuity. There is a threshold beyond which retinal cells can no longer recover, so patients presenting within the first 24 hours of symptom onset should be promptly referred to HBOT. A recent meta-analysis of HBOT was shown to achieve visual acuity improvement and was associated with favorable critical outcomes. The authors present this case report as further evidence of HBOT efficacy.

#1726 - Case Report

A 35-YEAR-OLD MALE WITH CLINICALLY ISOLATED SYNDROME OF MULTIPLE SCLEROSIS

Ricardo Gomes¹, Isabel De La Cal Caballero¹, José Proença¹, Luís Abreu², André Leitão², Marta Arenga², Leopoldina Vicente¹

¹ Internal Medicine Service - Centro Hospitalar Universitário Cova da Beira, Covilhã, Portugal

² Neurology Service - Centro Hospitalar Universitário Cova da Beira, Covilhã, Portugal

Introduction

Multiple sclerosis (MS) is the most common immune-mediated inflammatory demyelinating disease of the central nervous system (CNS). The cause of MS remains unknown and there are no unique clinical manifestations but a typical patient is a young adult with one or more episodes of CNS dysfunction, such as unilateral optic neuritis, focal brain syndrome, focal brainstem or cerebellar syndrome, or partial myelopathy during more than 24 hours and without infectious or traumatic cause.

Case description

A male patient 35 years old reached emergency service complaining of sudden decrease of strength on the right

hemibody causing gait impairment and transient dysarthria with 24 hours of evolution. Complaints of diplopia, headache, visual changes, trauma, fever or constitutional symptoms were absent. The neurological exam revealed right central facial palsy, mild dysarthria, right hemiparesis (muscle strength on MRC scale: 3 proximally, 4 distally), generalized myotatic hyperreflexia, right hemiplegic gait and flexor cutaneous plantar reflexes bilaterally. Brain CT-Scan revealed white matter hypodensities bilaterally more evident on the right corona radiata and juxtatrigonal. On the 5th day, brain and spinal cord MRI revealed: «Intense signal in T1 after contrast in juxtaventricular and juxtatrigonal location, left internal capsule, with diverse dimensions as in left corona radiata, hyperintense in T2 and hypointense in T1, some lesions were gadolinium-enhanced. In the C1-C2 segments was seen a small hyperintense lesion in T2 and T2 STIR revealing the right lateral area with well-defined limits and without mass effect signifying probable active inflammatory disorder. Lumbar puncture showed oligoclonal IgG bands, absent in the serum. Infectious CNS and vascular studies were normal. Assuming MS we began acute relapse treatment with 1000 mg methylprednisolone intravenous for five days with almost complete remission of the symptoms while following motion rehabilitation daily.

Discussion

MS is a heterogeneous disorder with variable clinical and pathologic features reflecting different pathways to tissue injury. The diagnosis of MS can be made when they present with a first clinical attack (id est, a clinically isolated syndrome) if a single MRI obtained at any time shows dissemination in space and, as evidence for dissemination in time, by the simultaneous presence of gadolinium-enhancing and nonenhancing lesions. Intravenous high doses steroids are the most used treatment in acute relapses of MS.

#1731 - Case Report

HEMIBALLISM AS A PRESENTATION OF ACUTE STROKE IN YOUNG ADULT

Joana Fontes, Inês Grenha, Elsa Araújo, Manuel Barbosa, Joana Silva, Bárbara Sousa, José Carlos Veloso, Paula Brandão
ULSAM - Hospital Conde de Bertandos, Ponte De Lima, Portugal

Introduction

Movement disorders are a rare presentation of acute stroke with an estimated prevalence at approximately 1%. The most common vascular dyskinesia is hemiballism/hemichorea.

In most cases, the lesions are due to small vessel cerebrovascular disease in the middle or posterior cerebral artery territories, involving the contralateral subthalamic nucleus (STn). Occasionally, lesions are found outside of the STn, including the caudate nucleus, putamen and thalamus.

Case description

A 45-year-old man, with a past medical history of dyslipidaemia, hypertension, alcohol abuse and smoking, presented to the

Emergency Department (ED) with a history of sudden onset of involuntary, irregular and high-amplitude movements of his left upper extremity for around 2 hours with posterior transitory paraesthesia of his left hand.

In the ED, the patient was hemodynamically stable and afebrile. Neurological examination was normal. His laboratory results, including blood sugar were normal, the ECG was in sinus rhythms and the computed tomography scan of the head didn't reveal any acute ischemic lesion. For the clinical suspicion of transient ischemic attack, the patient was treated with one dose of aspirin 300 mg. He was hospitalized in a stroke unit for further investigation.

During the hospitalization, the neurologic deficits did not recur. The complementary laboratory study revealed hyperlipidemia and excluded inflammatory/infectious or hematologic disorders. The electroencephalography didn't show epileptiform activity and the carotid ultrasound was normal. In the magnetic resonance imaging was described ischemic lesions in the right middle cerebral artery territory involving the posterior limb of internal capsule and the caudate and lenticular right nucleus. Echocardiogram didn't detect any potential cardiac source of stroke and holter monitoring didn't identify occult paroxysmal atrial fibrillation.

The aetiology of this acute ischemic stroke presented as hemiballism was established as cerebral small vessel disease. The patient was discharged to home with aspirin 100 mg and high potency statin and motivated to change his lifestyle habits. No further episodes occurred at 1-year follow-up.

Discussion

We report a case of a hemiballism resulting from an acute unilateral caudate lesion which improved spontaneously and didn't require pharmacotherapy. Long-term prognosis in post-stroke hemiballism is generally good and the control of vascular risk factors is crucial in reducing the recurrence.

#1744 - Case Report

DIAGNOSIS DIFFERENTIAL OF A CONVULSIVE STATUS EPILEPTICUS

Giovana Clare Sousa Ennis, Joana Silva Marques, Joana Correia, Bruno Barbosa, Inês Barros, Ana Albuquerque, Rui André
Tondela-Viseu Hospital Centre, Viseu, Portugal

Introduction

The authors present a clinical report of a female patient admitted in the Intensive Care Unit (ICU) with the diagnosis of convulsive status epilepticus, and the diagnostic rationale behind the therapeutic choices that led to her clinical recovery.

Case description

The authors present the case of a 70 year-old female patient, with a history of hypertension, atrial fibrillation and depression and no history of epilepsy or seizures during infancy. In the three previous weeks before hospitalization, she had experienced

adynamia, apathy, memory loss and mood changes, being mainly more depressed having been recently medicated with fluoxetine 20mg. The patient had been hospitalized with the diagnosis of symptomatic normovolemic hyponatremia in the form of generalized tonic-clonic seizures. Although the ionic disorder was corrected the patient maintained frequent seizures, culminating in the absence of recovery of the state of consciousness and transfer to the ICU. The electroencephalogram (EEG) performed was suggestive of status epilepticus. As the patient presented a maintained status epilepticus despite the correction of the hyponatremia, a thorough aetiological study was performed, including a cerebral MRI that excluded structural causes and ruled out central pontine myelinolysis. Cerebrospinal fluid study, including biochemical analysis and virus and bacterial identification was negative. Antiepileptic medication with levetiracetam, sodium valproate and clonazepam was titrated with no new epileptic events or epileptic activity in EEG. Due to neurological stability, weaning of sedative medication and extubation was performed successfully. However, the patient presented an oscillating state of consciousness, ranging from coma to spontaneous reversal, without new alterations in EEG or imaging tests. At this stage the authors suspected of paraneoplastic or autoimmune encephalitis. Given this hypothesis, treatment trial with 1 g of methylprednisolone daily was initiated with significant neurological improvement, and no new episodes of altered state of consciousness.

Discussion

The exclusion of infectious, structural and ionic causes for status epilepticus in adults with no history of epilepsy, should lead to consider the existence of less frequent causes, namely autoimmune or paraneoplastic aetiologies. In clinical practice, diagnostic confirmation isn't usually available before initiating treatment, so diagnostic suspicion is essential for adequate treatment of these patients.

#1752 - Case Report

BRAIN TUMOUR, THE ETERNAL DOUBT: PRIMARY VERSUS SECONDARY?

Miguel Borges Da Silva, Albina Moreira

Hospital Pedro Hispano, Unidade Local de Saúde de Matosinhos, Matosinhos, Portugal

Introduction

Primary tumours of the central nervous system (CNS) have a low incidence in adults, while brain metastases account for more than half of the brain tumours in this age group. Clinical manifestations are diverse depending on the site of the invaded brain. Treatment and prognosis are dependent on the histology of these tumours.

Case description

A 74-year-old woman hospitalized for the study of brain lesions suggestive of neoplasia. The patient presented a clinic with a

2-week evolution of behavioural changes (adynamia, emotional lability, apathy and mnemonic alterations) associated with intense bilateral frontal headaches. Documented at the objective examination: bradifrenia, poor speech, inattention, signs of frontal (palmomentonian on the left and bilateral grasping), some neglect of the left hemibody and ideomotor apraxia in the left limbs. During hospitalization, the patient maintained the same clinical manifestations with increasing adynamia and apathy. She performed nuclear magnetic resonance imaging (MRI) that showed several intracranial lesions (at the level of the corpus callosum and cortico-subcortical and periventricular regions of right predominance) suggestive of primary cerebral neoplasm (glioma), and it was not possible to exclude brain metastases. The study for primary systemic neoplasm as well as cerebrospinal fluid cytology was negative. Stereotactic biopsy showed glioblastoma multiforme.

Discussion

The study of brain tumours in the older population almost always involves the exclusion of primary systemic neoplasm. Although imaging techniques often provide information suggesting a specific histology, biopsy remains essential for the diagnosis and therapeutic orientation of primary CNS tumours. This clinical case is intended to highlight this fact.

#1753 - Case Report

MAGNETIC RESONANCE IMAGING (MRI) TOO SOON – A CASE OF SPORADIC CREUTZFELDT-JAKOB DISEASE (CJD) WITH NORMAL MRI

Pedro Leite Vieira¹, Mariana Ribeiro Santos², Margarida Rodrigues², Álvaro Machado², Sofia Rocha²

¹ Amato Lusitano Hospital, Castelo Branco, Portugal

² Braga Hospital, Braga, Portugal

Introduction

CJD is the most common human prion disease. With a prevalence of 1:1000000 worldwide is a rare, fatal, neurodegenerative disorder included in the group of spongiform encephalopathies, counting the sporadic form (sCJD) for 85-90% of the cases. Typically affects patients in the 70th decade, but could be seen in younger or older (>80s) ones. The most frequent clinical presentation is a rapidly progressive cognitive decline associated with other neurologic manifestations (ataxia, myoclonus, akinetic mute state) according to the location of lesions. The mean survival is 6 months and over 90% of patients die within a year of symptoms onset.

Case description

82-year-old man, previously independent, with history of type 2 diabetes, arterial hypertension, dyslipidaemia and treated prostate adenocarcinoma was admitted to emergency room. His daughter referred a 4-week history gait ataxia, dysarthria and lack of memory for recent facts. At that moment, was unable to drive or walk and needed total help on his daily life activities. Neurologic

examination: disoriented, bilateral intention tremor, finger to nose test dysmetria, stood on a broad base and was unable to walk, despite support. No further changes on physical examination and laboratory tests. The first MRI showed cerebral atrophy and T2 unspecific hyperintensities of subcortical frontoparietal white substance bilaterally. Electroencephalogram: basal activity α 8Hz and no paroxystic activity. Positron emission tomography suggested Alzheimer Disease or Lewy body dementia. Neoplasm, infection, autoimmune diseases, ammonia encephalopathy and lesions of posterior column of spinal cord were excluded. Given the patient clinical deterioration, aphasia, myoclonus and totally bedridden, MRI was repeated and revealed areas of hyperintensity in T2/FLAIR and diffusion restriction on basal ganglia and both thalamus. Tau protein 3800 pg/mL (N<335 pg/mL), phospho-Tau protein 85.3 pg/mL (N<51 pg/mL) and 14.3.3 protein weak positive. As expected, patient died after 4 months.

Discussion

The case reported meets the diagnostic criteria for definite sCJD: clinical, laboratory and imaging findings. It is a very uncommon presentation due to patient's age, but mostly due to the late imaging findings. It also shows the extreme importance of family symptoms description, patient's clinical evolution, as well as clinical suspicion of the most likely diagnosis.

#1775 - Case Report

ISCHEMIC STROKE, BLAME THE INFECTED HEART

Alexandra Prizal Pousinha, Madalena Paulino, Ana Palricas, Ana Nunes Rocha, João Seabra Barreira, José Barata
Hospital Vila Franca de Xira, Vila Franca De Xira, Portugal

Introduction

Infective endocarditis is associated with significant cardiac and noncardiac morbidity. Among many complications, septic embolism has the potential of causing devastating sequelae and even life-threatening clinical situations. As the case presented, ischemic stroke, is frequently a result of embolization to the middle cerebral artery, although any arterial cerebral territory may be affected.

Case description

A 75 years old woman, presents do the Emergency Department with fever and prostration.

Relevant past medical history was hypertensive cardiomyopathy and breast cancer in remission. She was admitted to the enfermary with respiratory infection, and on the fourth day, Escherichia coli came positive on blood cultures, sensible to antimicrobial therapy. During the period of hospitalization, a severe clinical deterioration was observed, with loss of conscience and conjugate gaze palsy to the right, as well as right leg paralysis.

The brain computerized tomography imaging showed right medial temporal and occipital corticossubcortical hypodensity, suggestive of acute ischemic lesion of the right posterior cerebral artery.

Attending the isolation of E.coli in blood cultures, a transthoracic echocardiography was performed, which revealed an image suggestive of a vegetation on the posterior mitral valve leaflet (>12 mm in size), without significant functional repercussion. She was then transferred to the Stroke Unit in the Hospital, and went through magnetic resonance imaging which demonstrated multiple cerebral supra and infratentorial infarctions, whose major lesions were seen in right occipital area, as well as left cerebellum hemisphere, suggestive of cardioembolic origin.

Atransesophageal echocardiogram was contraindicated by the time, given the clinic instability, as the patient developed acute cardiac insufficiency. The cardiac surgery team was also approached for the possible removal of the cardiac vegetation, but the deteriorating status, with respiratory failure and increased oxygen uptake, was decided that any intervention should be delayed. The clinic state aggravated and the patient died on the 22^o day of hospitalization.

Discussion

This case demonstrates that septic cerebral embolization, manifesting as an ischemic stroke, is the most frequent neurologic complication of the infective endocarditis. Many of these lesions are usually asymptomatic, since they are only visible in magnetic resonance imaging (gold standard diagnostic imaging) which can delay the diagnosis.

#1820 - Case Report

A CASE REPORT OF MARCHIAFAVA-BIGNAMI DISEASE

Ivo Castro, Adelaide Figueiredo, Maria Cristina Esteves, Luís Siopa
Hospital Distrital de Santarém, Santarém, Portugal

Introduction

Marchiafava-Bignami is a rare disease characterized by demyelination of the corpus callosum and high mortality rate. It is associated with toxics exposure or nutritional deficit and it's present at patients who have chronic alcohol abuse. Clinically this disease is more frequent in male patients, older than 45-years-old and manifest itself with neurocognitive defects or seizures and goes from mild deteriorating to comatose state. MRI is essential for diagnosis.

Case description

We present a case of a 55-years-old men with history of chronic alcohol abuse with epilepsy associated. Other comorbidities were arterial hypertension, dyslipidemia and insulin-treated type 2 diabetes. The patient was admitted at the hospital with a progressive aggravation in the previous three months with the ascites, asthenia, food refusal, prostration and slow speech, confusing state. After an initial study that presented normal levels of INR, AST, ALT, LDH and ammonia at analytical serum study, normal lumbar puncture and normal head CT scan, the patient was admitted to the ward where he was treated with thiamine and supportive therapy. More studies were conducted as a magnetic resonance imaging which demonstrated changes compatible with

the progression of atrophy and demyelination of the body callus known as Marchiafava-Bignami. The patient died 33 days after in a comatose state and with hospital acquired pneumonia.

Discussion

Although Marchiafava-Bignami's disease is rare, it is associated with high mortality. So we should be aware when patients with a history of alcohol abuse present with neurological changes that are not compatible with clinical and laboratory status.

#1854 - Medical Image

MOYAMOYA DISEASE

Cátia Carvalho, Daniana Condado, César Vieira, Joana Diogo, Rita Monteiro, Carolina Coelho, Rita Bizarro, Angela Ghiletschi, Maria Helena Pacheco, Lurdes Venâncio Pereira, Conceição Loureiro
Centro Hospitalar Universitário de Lisboa Central - Hospital Santo António dos Capuchos, Lisboa, Portugal

Clinical summary

MoyaMoya Disease, also known as spontaneous occlusion of the circle of Willis, is a rare chronic cerebrovascular disease of unknown etiology and is an important cause of non atherosclerotic intracranial arterial disease, characterized by steno-occlusive changes at the terminal portion of the internal carotid artery and an abnormal vascular network. The clinical manifestations include ischemic or hemorrhagic vascular events, seizures, involuntary movements, headache and cognitive impairment. These images are from an 58 year-old portuguese female with a transient involuntary movements of the upper limbs and progressive cognitive impairment. The AngioMR that reveals vascular alterations in agreement with the typical MoyaMoya alterations. Nowadays she is waiting for surgery.

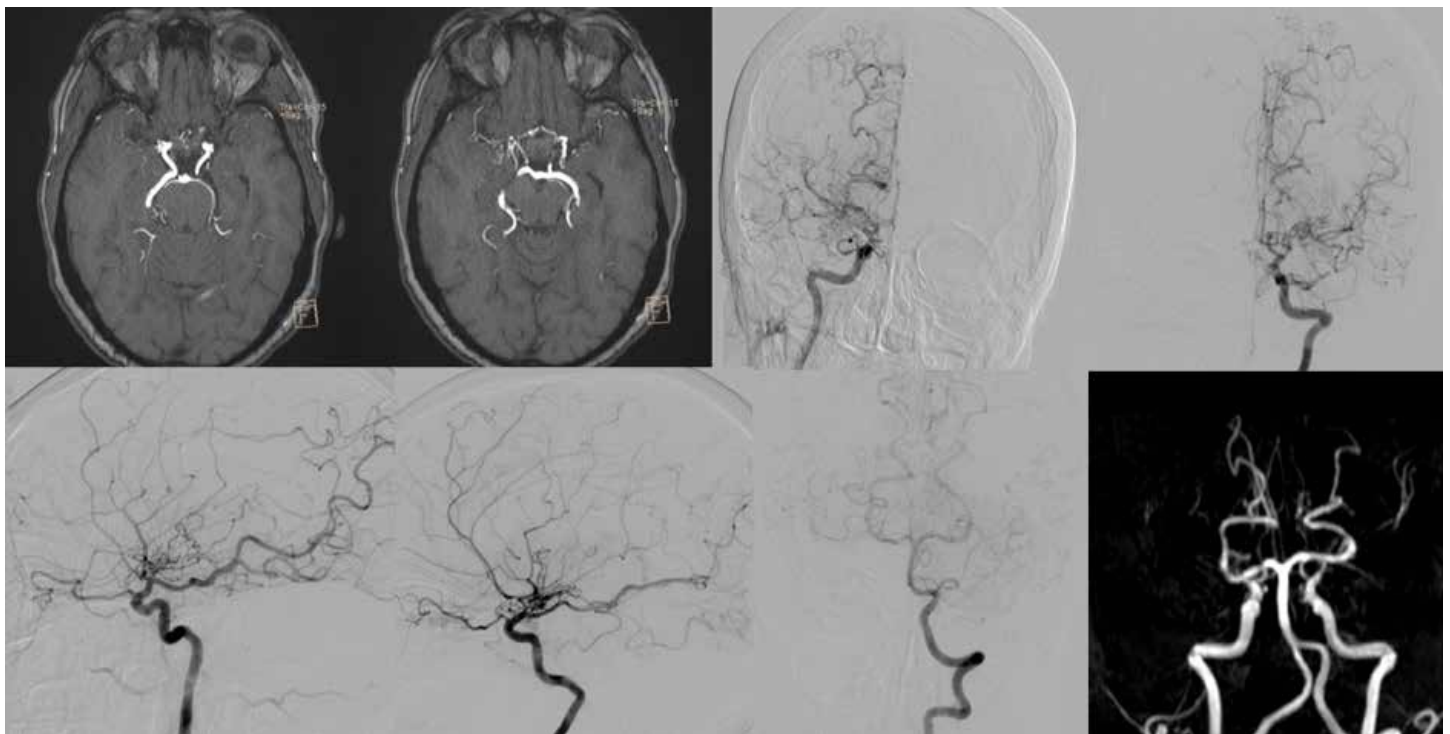


Figure #1854. Cranioencephalic magnetic resonance and cerebrovascular angiography.

#1886 - Case Report

REVERSIBLE POSTERIOR LEUKOENCEPHALOPATHY SYNDROME (RPLS) - A CASE REPORT

Sofia Ramos Gonçalves, Rafael Dias, Patrício Freitas, Rafael Freitas, Pedro Balza, Maria Luz Brazão
Hospital Central do Funchal, Funchal, Portugal

Introduction

Reversible posterior leukoencephalopathy syndrome (RPLS) is a clinical radiographic syndrome of heterogeneous etiologies. The

syndrome is not always reversible, and it is often not confined to either the white matter or the posterior regions of the brain. Case series suggest that is more common in women. The symptoms of RPLS evolve rapidly over hours to days. Hypertension is frequent but not invariable. The hypertensive crisis may precede the neurologic syndrome by 24 hours or longer. The clinical syndrome of RPLS is characterized by headaches, altered consciousness, visual disturbances and seizures. Neuroimaging is essential to the diagnosis of RPLS.

Case description

62-year-old female with a history of arterial hypertension and chronic obstructive pulmonary disease. She presented in the emergency department with complaints of severe headache, over the previous 20 minutes. She mentioned headaches over the previous week. On observation her blood pressure was 197/112 mmHg. While being evaluated the patient presented deviation of both eyes to the left and involuntary movements of the superior upper limb, that rapidly evolve to a generalized tonic-clonic seizure. A noncontrast head computed tomography scan (CT) was performed and showed no significant alterations. She was admitted in the acute stroke unit and performed a noncontrast brain magnetic resonance imaging (MRI) which showed presence of bilateral parietal subcortical and periventricular focal areas of enhanced signal, compatible with RPLS. Over the first days of hospitalization she maintained elevated blood pressure with need for high doses of antihypertensive medication and altered state of consciousness alternating between periods of mild somnolence and periods of confusion and agitation. On the tenth day of hospitalization, another brain MRI was performed and it showed enlarged areas of enhanced signal on the left cerebellum, suspected of being in relation with a stroke/irreversible lesion. After stabilization and improved clinical status, she was transferred to the neurology department.

Discussion

RPLS should be promptly recognized, since it is usually reversible with appropriate management. Clinicians should have a high clinical suspicion, recognize the neurologic syndrome and evaluate for RPLS with brain magnetic resonance imaging (MRI), particularly when evaluating this patients in the emergency department.

#1894 - Case Report

RECURRENT NEUROLOGIC SYMPTOMS - WHAT IS THE CAUSE?

Sofia Gonçalves, Pedro Balza, Luz Brazão
Hospital Central do Funchal, Funchal, Portugal

Introduction

Brain tumors originate in different cells of the central nervous system (CNS) or in systemic neoplastic cells that metastasize to the CNS. The signs and symptoms may be caused by compression of adjacent structures or by increased intra-cranial pressure. High-grade gliomas are malignant and rapidly progressive brain tumors.

Case description

49-year-old female, previously healthy. She was taken to a primary health care facility due to complaints of paraesthesias of the upper right limb and right hemiface, with spontaneous regression. On suspicion of a transient ischemic event she was medicated with clopidogrel. Six days after this event, she presented recurrence of the symptoms. Ten days after the initial episode, she presented

in the emergency department of a central hospital complaining of recurrence of the symptoms but this time associated with dizziness and decreased muscular strength in the right upper limb. Neurological examination performed showed a decrease in muscle strength in the right upper limb (grade 3+/5). A cranioencephalic computed tomography scan was performed and revealed a "left, cystic-necrotic lesion of aggressive characteristics and significant perilesional cerebral edema compatible with glioblastoma". She was admitted to the Neurosurgery department in order to perform diagnostic brain magnetic resonance imaging and surgical planning. The examination of the brain tissue excised during the surgery revealed it to be a glioblastoma multiform (grade IV).

Discussion

Symptoms caused by high-grade gliomas usually develop over days to weeks and, at an early stage, may mimic other pathologies (such as cerebrovascular disease). Therefore, the authors believe they should be taken into account when evaluating patients with neurological complaints.

#1911 - Case Report

VENOUS SINUS THROMBOSIS IN CEREBRAL VEINS AND VENOUS HEMORRHAGE IN POSTPARTUM PERIOD

Lauma Dobelniece^{1,2}, Nauris Zdanovskis¹, Ligita Belasova²

¹ Riga Stradins university, Riga, Latvia

² Vidzemes Regional Hospital, Valmiera, Latvia

Introduction

Compared to arterial diseases, cerebral venous sinus thrombosis (CVST) is rarely seen cause of cerebral infarction. The diversity of clinical symptoms, etiology and radiology findings, makes it less recognizable at the initial presentation. The risk factors of CVST described in literature are trauma, surgery, infections, malignancy, transitory hypercoagulation states (dehydration, oral contraceptives, pregnancy), or permanent hypercoagulability from genetic causes, or it can occur spontaneously.

Case description

A 31-year-old patient, woman, 17 days postpartum, complained about severe headaches for a week and nausea with vomiting. Patient referred that the headaches were the "worst ever" she experienced. For the last 3 days before arriving at the emergency room (ER), the pain was localized more on the left side of the head. A head CT scan was performed and small arteriovenous malformation on the left temporal lobe was described by radiologist. No signs of thrombosis or hemorrhage were seen. Patient was discharged home to continue treatment and examination on outpatient basis. Three days later, she was re-admitted to ER with aphasia (motor>sensor), right side dysmetria and continuous headaches on the left side. Glasgow coma scale – 13/14 points, NIHSS – 6/7 points, mRS – 3 points. MRI head scan revealed sagittal sinus thrombosis, venous hemorrhagic infarction

on the left temporal lobe, small subarachnoid hemorrhage. Patient was hospitalized in neurology ward stroke unit. The laboratory results showed anemia (9.5mg/L), positive ANA, ENA, elevated APCR levels, positive SS-A/Ro60, questionable results of SS-A/Ro52, cytosin in CSF – 12/mm³ with raised lymphocyte count. Patient had no records of other diseases or positive family history, but she had home labor with serious blood loss with no further hospitalization. Patient received anticoagulants, symptomatic therapy, physiotherapy and rehabilitation. Systemic lupus erythematosus diagnosis was suggested by rheumatologist and therapy with hydroxychloroquine was started. Patient had a good recovery with no known neurological deficit and symptom recurrences.

Discussion

Cerebral venous thrombosis is a challenging diagnosis for both – radiologists and clinicians. The changes in CT scan are not always properly seen or interpreted, but the availability of MRI scan usually in ER stage is limited. The proper anamnesis and possible risk factor clarification could help to overcome these difficulties.

#1948 - Case Report

POSTPARTUM STATUS EPILEPTICUS – WHAT IS THE CAUSE?

Sofia Gonçalves, Rafael Dias, Pedro Balza, Duarte Noronha, Teresa Carolina, Armando Morganho, Orlando Sousa

Hospital Central do Funchal, Funchal, Portugal

Introduction

Cerebral vein and dural sinus thrombosis (CVT) is less common than most other types of stroke but can be more challenging to diagnose. Because of its myriad causes and presentations, CVT is a disease that may be encountered not only by neurologists and neurosurgeons, but also by emergency clinicians, internists, amongst others. It is more common in women than men and both pregnancy and the puerperium are amongst the most frequent risk factors for CVT. The pathogenesis of CVT remains incompletely understood and it has a highly variable clinical presentation, headache being the most frequent symptom.

Case description

27-year-old female, previously healthy, presented to the emergency department, one week after delivery, with complaints of paresthesias of the right upper limb of spontaneous resolution and subsequently two, short duration, episodes of seizure, with slow recovery of the state of consciousness, over de previous 24 hours. She also reported cervical-occipital pain that worsened with the supine position and improved when lying down, ever since the postpartum, with no response to analgesia. Neurological examination she presented mydriatic and slowly reactive pupils and unintentional spontaneous movements of the four limbs. A cranioencephalic computed tomography scan was performed and revealed “extensive venous thrombosis of the longitudinal sinus

with venous ectasias in their proximity”. After the examination, the patient presented two generalized tonic-clonic convulsive seizures and one focal convulsive seizure, without complete recovery of the state of consciousness between them and therefore considered to be status epilepticus. Given that the patient was sub-febrile and the study of group B streptococcus, performed peri-partum, was positive, a lumbar puncture was performed and a central nervous system infection was excluded. Anti-epileptic medication and hypocoagulation with enoxaparin was initiated. During hospitalization, transition to warfarin was performed, with a good response. From the etiologic study carried out, the authors highlight the presence of a heterozygotic mutation in the prothrombin gene.

Discussion

Although uncommon, CVT is an important diagnostic to be considered in the etiologic evaluation of recent onset headache. Therefore, the authors consider essential that a thorough, holistic and multidisciplinary approach should be implemented in the treatment of these patients.

#1963 - Case Report

AUTONOMIC DYSREFLEXIA: A FORGOTTEN BUT POTENTIALLY LIFE-THREATENING CONDITION

Alexandre N. Fernandes¹, Maria Inês Vicente^{1,2}, Fredo Renato Silva¹, Ana Paula Antunes¹, Tânia Strecht¹, Carolina Sepúlveda¹, Jana Zelinová¹, Mónica Bettencourt¹

¹ Hospital de Cascais, Cascais, Portugal

² IPO Lisboa, Lisbon, Portugal

Introduction

Autonomic dysreflexia (AD) is a potentially life-threatening syndrome that develops as a complication after spinal cord injury, usually at or above the level of T6. This clinical entity is a paroxysmic dysregulation of the autonomic nervous system due to unmodulated sympathetic reflexes below the injury level in response to noxious or innocuous stimuli. In 85% of cases, the triggers are related with bladder distension and fecal impaction. AD consists of a constellation of signs and symptoms that culminate in marked hypertension. If not recognized and promptly treated it can lead to serious complications, such as seizures, cerebral hemorrhage and eventually death. Several studies showed that medical staff knowledge and awareness is severely lacking in this area.

Case description

A 47-year-old male, residing in a long-term care facility, with medical history of spinal cord injury (C4 level), with subsequent spastic paraplegia, was admitted to our emergency department with a pulmonary infection with global respiratory failure and was given IV antibiotic. Four days after admission he had an episode of severe anxiety associated with diaphoresis and feeling of

impending doom. During this episode he sustained a rise in blood pressure of 177/107 mmHg, with a pulse of 86 bpm and pulse oximetry of 74% saturation. Physical examination and laboratory findings were unremarkable. He was administered captopril and ventilatory support and the episode resolved in half an hour. The following day, he had a similar episode and was managed the same way. Since he had no previous history of hypertension no further evaluation was performed and a diagnosis of AD was made. At this time we realized that the patient had been constipated for 4 days. He was given laxative treatment and normal bowel transit was established. Until he was discharged he didn't experience any similar episode.

Discussion

Spinal cord injury is a devastating health problem that poses particular challenges to the physician. It has been observed that the higher the spinal cord injury level occurs, the greater the risk of AD, with up to 90% of patients with cervical spinal or high-thoracic spinal cord injury being susceptible. Identification and elimination of specific triggers is considered the first line of treatment and the use of antihypertensive drugs should be considered a last resort. The authors highlight with this interesting case the importance of the awareness of this condition, to ensure proper and timely management.

#1985 - Case Report

ARNOLD-CHIARI SYNDROME AS A DIFFERENTIAL DIAGNOSIS OF RECURRENT SYNCOPE

Marta Arriaga Rocha, Joana Maurício, Martim Trovão Bastos, Susana Bastos Heitor

Hospital Prof. Doutor Fernando Fonseca, Amadora, Portugal

Introduction

Arnold-Chiari is a group of deformities of the hindbrain. Issues range from herniation of the posterior fossa contents outside of the cranial cavity to absence of the cerebellum with or without other associated intracranial or extracranial defects. Clinical manifestations are varied, and some patients remain asymptomatic until adults. The most common symptoms are neck pain, headache, muscle weakness, numbness, altered sensitivity and imbalance. Syncope is an unusual manifestation but during a valsalva manoeuvre, intracranial pressure increases and syncopes may occur secondary to vertebrobasilar artery compression. The neurological examination helps in the diagnosis and confirmed by MRI.

Case description

A 19-year-old girl, without relevant personal and family medical history or regular medication was hospitalized by episodes of dizziness and repetitive syncope, after physical effort. At admission she was hemodynamically stable, eupneic and without alterations in cardiopulmonary auscultation. A summary

neurological examination showed tactile and painful hyposthesia of the left hemiface and left limbs; fall of the left upper and lower limb in the extended arms and Mingazzini test with muscular strength score 4/5; left dysmetria and adiadococynesia. Analytically within the reference values. Holter, Echocardiogram and Ecodoppler of the vessels of the neck showed no alterations. CT-cranial-encephalic (CE) revealed cerebellar tonsils insinuating themselves in the occipital foramen, with partial erasure of the regional liquor circulation spaces. For clarification, MRI-CE showed ectopy of the cerebellar tonsils, about 6 mm caudal to the anatomical plane McRae. The Arnold-Chiari syndrome was diagnosed. The patient was discharged with indication to avoid physical effort, particularly isometric exercises or associated with Valsalva maneuver. The patient was referenced to neurosurgery consultation for evaluation of surgical necessity.

Discussion

Arnold-Chiari syndrome is a rare entity of great clinical interest due to the diagnostic difficulty since it mimics other conditions in which cerebellar pathologies are involved. Arnold-Chiari malformations should be considered in the differential diagnosis of recurrent syncope, especially if accompanied by headache, vertigo, or transient sensory or motor symptoms in arms or legs. This case report reinforces the importance of a systematized approach to a common symptom.

#1994 - Case Report

SPONTANEOUS HAEMATOMA CAUSING FEMORAL NERVE PALSY – A COMPLICATION IN THE SETTING OF ANTICOAGULATION

Cátia Fava Gaspar, Helena Greenfield, Liliana Carneiro

Hospital Pedro Hispano, Matosinhos, Portugal

Introduction

Haemorrhage is one of the most well-known adverse events associated with anticoagulation, occurring in 1-4% of patients. When it occurs in locations enriched with nervous structures, such as the iliacus muscle, the consequences could be catastrophic.

Case description

The authors present the case of a 64 year old woman, with prolonged hospitalization due to severe rheumatic mitral and aortic valve disease awaiting valvular replacement surgery. She had a history of dyslipidaemia, first-degree atrioventricular block and atrial fibrillation under anticoagulation with warfarin, which was altered during the inpatient period to low molecular weight heparin adjusted to the patient weight. The patient developed symptoms of right groin pain with lower limb irradiation, without any trauma associated. A computed tomography showed iliacus muscle haematoma with 79x49x119mm. An immediate non-surgical drainage was performed as well as suspension of anticoagulation. During the subsequent days, the patient developed progressive weakness of the right lower limb, attributed

to the nerve compression/strain, which was re-evaluated, due to doubts of the necessity of surgical intervention. A conservative approach was decided on, because of the high risk of more vascular/nervous damage due to the local inflammatory process. On imagiological re-evaluation there was reabsorption of the haematoma which permitted reintroduction of anticoagulation, with no further episodes of haemorrhage documented. However, despite the recovery, an electromyography showed very severe axonal damage of the right femoral nerve and the patient presented no clinical recovery during the rest of her hospital stay, being unable to walk autonomously even after the initiation of a tailored rehabilitation program.

Discussion

The ageing of the population is leading to greater co-morbidity in patients and to a higher percentage of anticoagulated patients. This case shows the importance of being alert to the potential adverse effects of this therapy and of the need to be alert to clinical signs that can make us suspect of complications, such as, haematoma formation and of the need for a close collaboration between medical and surgical specialties in order to detect early complications, which allow us to avoid permanent damage, which, was unfortunately not possible in the case presented above.

#2009 - Case Report

INTERAURICULAR SEPTUM ANEURYSM: A RISK FACTOR FOR CRYPTOGENIC STROKE

Pedro Ribeiro Soares, Margarida Mesquita, Tânia Proença, Carla Andrade, Diana Ferrão, Catarina Pereira, Fernando Nogueira, José Marques, Jorge Almeida
Centro Hospitalar de São João, Porto, Portugal

Introduction

Stroke is the second leading cause of death and the third leading cause of disability worldwide. The presence of interatrial septum aneurysm is a rare malformation that is associated with an increased risk of cardioembolic stroke and is more prevalent in patients less than 55 years of age. The main manifestations of this anomaly are arterial embolism and atrial arrhythmias.

Case description

52-year-old male with type 2 diabetes mellitus, hypertension, dyslipidemia, smoking history and rheumatoid arthritis with complaints of left hemiface and left upper limb paresthesias that had spontaneous resolution in less than 24 hours. He performed a CT scan which was consistent with a lacunar ischemic infarction. Transthoracic echocardiogram showed normal cardiac chambers and the presence of interatrial septal aneurysm, multiperforated, without associated thrombi and a positive right-left shunt. The findings were confirmed by transesophageal echocardiography. He started antiplatelet and statin therapy and was discharged from the ward with indication to perform percutaneous correction of the interatrial septum aneurysm.

Discussion

Anomalies of the atrial septum are associated with a higher prevalence of cardioembolic stroke. The presence of uncomplicated atrial septal aneurysm alone does not require specific treatment and only appropriate follow-up. However, the presence of other anomalies (including patent foramen ovale) or paradoxical embolism should be the subject of an individualized evaluation, namely for percutaneous treatment. The increasing recognition of this pathology and its potential association with cryptogenic stroke is critical for the appropriate treatment of these patients.

#2048 - Case Report

AN IMAGE IS WORTH A THOUSAND WORDS

Ana Isabel Rodrigues, Rita Martins Fernandes, Domingos Sousa, Nuno Mourão Carvalho, Hugo Calderon, Cristina Granja
Centro Hospitalar Universitário do Algarve - Unidade de Faro, Faro, Portugal

Introduction

An altered state of consciousness (ASC) involves a variable combination of inattention, incoherent speech, disorientation, psychomotor agitation, hallucinations, and disturbance in the sleep-wake cycle.

The differential diagnosis in ASC is a great clinical challenge.

Case description

A 69-year-old woman with a past history of hypothyroidism and arterial hypertension presented to emergency department with a 3-day history of headache, dizziness and nausea.

She brought the result of a head magnetic resonance imaging (MRI), performed in another hospital, reporting acute ischemic injury in the cortex of the insula and in the cortex of the right temporal lobe.

On physical exam she was confused, febrile (39.5°C) and with loss of balance. She was admitted to the ward with the diagnosis of ischemic stroke.

On the fourth day of hospitalization her state of consciousness worsened evolving to a score of 5 in the Glasgow Coma Scale (GCS). A lumbar puncture was performed and the cerebral spine fluid (CSF) analysis showed glucose 85 mg/dl, protein 121 mg/dl and white blood cell count 261/mm³ with lymphocytic predominance. Empiric broad-spectrum were started as well as intravenous acyclovir for suspected encephalitis. She repeated the imaging study supporting the hypothesis of herpetic encephalitis. Two days later the Intrahospital Emergency Medical Team was contacted for a seizure. The patient was then admitted to the intensive care unit with coma of unknown origin probably secondary to encephalitis.

The electroencephalogram (EEG) showed neurophysiological aspects supporting the clinical hypothesis of herpetic encephalitis and a follow-up EEG 9 days later showed worsening of epileptiform activity, even after optimization of antiepileptic

therapy. After completing 21 days of acyclovir and suspension of the sedoanalgesia there was no neurological recovery. The patient remained with a GCS of 3 eventually dying at the 24th day of hospitalization.

Posthumously, the CSF analysis utilizing polymerase chain reaction of herpes simplex virus (HSV) type 1 was found to be positive, confirming the diagnosis.

Discussion

HSV encephalitis is associated with a high morbimortality rate and diagnosis should be made promptly, as the early start of treatment has prognostic implications.

This case report is relevant because the first diagnosis was influenced by an imaging exam that masked the viral encephalitis hypothesis and delaying the vital treatment, highlighting the importance of correct imaging in modern medicine.

#2056 - Case Report

MILLER FISHER SYNDROME: CASE REPORT

Raquel Costa¹, Ana Oliveira², Mariana Santos², Joana Braga³, Ana Filipa Santos²

¹ Hospital Conde de Bertiandos, Ponte De Lima, Portugal

² Hospital de Braga, Braga, Portugal

³ Hospital de Santa Maria Maior, Barcelos, Portugal

Introduction

Miller Fisher syndrome (MFS) is a rare variant of Guillain-Barré syndrome (GBS), observed in 1 to 5% of the cases. It is characterized by the acute development of ataxia, ophthalmoparesis, and areflexia.

Case description

A 57-year-old male was admitted to the emergency department with one-day history of progressive gait disorder, dysphonia, dysphagia and paresthesias of the hands. In the week before onset of symptoms he had a mild upper respiratory infection. The patient denied other infectious illnesses or diarrhea. He had no recent vaccinations or travel history, head trauma or unknown bite. There was no history of fever. He had no sphincter dysfunction or diplopia. His past medical history was significant for a monoclonal gammopathy that was being studied for the past 6 years and dyslipidemia medicated with statin. On neurological examination, he was fully alert and oriented to time, place, and person with an intact memory. He had bilateral ptosis and severe supraversion palsy. No facial muscle asymmetry was noticed. His soft palate elevated poorly and he had no gag reflex. There was no sensory or motor deficit in the limbs. A global areflexia was present. The plantar response was flexor. He displayed significant dysmetria on heel-to-shin testing, with gait unsteadiness. Laboratory studies revealed normal complete blood count, comprehensive metabolic panel, thyroid stimulating hormone and cardiac markers; the erythrocyte sedimentation rate was 36 mm/hour. A lumbar puncture was performed, and the cerebrospinal fluid (CSF) analysis

was normal. A possibility of MFS was entertained and intravenous immune globulin (IVIG) was started. Investigation was completed with brain magnetic resonance that showed no evidence of acute infarction or other alterations, and electromyography that revealed signs of axonal sensory neuropathy. The test for anti-GQ1b antibodies and campylobacter were being analyzed at the time of discharged. The patient completed IVIG for 5 days and significant clinical improvement was noticed. At the time of discharged he had normal neurologic exam, being able to ambulate alone.

Discussion

The authors intend to emphasize the importance of an early diagnosis, since if MFS is identified and correctly treated the prognosis is good.

#2092 - Case Report

THE CHALLENGING DIFFERENTIAL DIAGNOSIS OF DEMYELINATING DISEASES

Mariana Ferreira De Almeida¹, Pedro Oliveira Monteiro¹, João Calvão¹, Daniel Ferreira², Maria Inês Matos¹, Luís Nogueira-Silva^{1,3}, Maria Teresa Cardoso¹, Jorge Almeida¹

¹ Internal Medicine Department, Centro Hospitalar São João, Porto, Portugal

² Neurology Department, Centro Hospitalar São João, Porto, Portugal

³ CINTESIS - Center for Health Technology and Services Research, University of Porto, Porto, Portugal

Introduction

Acute disseminated encephalomyelitis (ADEM) is a rare autoimmune demyelinating disease, frequently triggered by viral infections or vaccination. An acute and often rapidly progressive cerebral and spinal cord inflammatory reaction occurs, leading to severe morbidity if not promptly treated.

Case description

A 37-year-old woman, with a history of conization for cervical high-grade squamous intraepithelial lesion, recently vaccinated against human papillomavirus and that reports a respiratory tract infection in the previous month, was brought to the emergency department due to a 3-day headache, urinary retention and constipation. Her husband reported progressive confusion and imbalance.

Her neurological examination showed motor aphasia, inferior limbs paraparesis (proximal dominance) and progressive dysesthesia from T6 level to inferior limbs. The bloodwork was unremarkable; besides a slight protein elevation, the cerebrospinal fluid cytology was normal and the viral meningoencephalitis panel was negative. The cerebral CT scan revealed multiple white matter hypodense lesions, interpreted as meningeal carcinomatosis, reason why she was admitted the Internal Medicine Department. Subsequently, a brain and spinal MRI depicted inflammatory/demyelinating lesions in both cerebral hemispheres, with medullar extension between

T6 and T12 levels, compatible with the diagnosis of ADEM (not suggestive of multiple sclerosis (MS), not excluding neuromyelitis optica (NMO)). Immunologic study (ANA, ANCA, anti-neuronal antibodies, anti-ENA antibodies) was negative; however anti-AQP4 and anti-MOG antibodies are still pending.

Immunosuppressive therapy was instituted with methylprednisolone pulses for 5 days, followed by six daily plasmapheresis sessions. The patient had notorious clinical improvement and was discharged without significant aphasia, able to walk unassisted. Nevertheless, disautonomic manifestations were still significant and the patient started self-intermittent bladder catheterization and sphincter control training.

Discussion

ADEM is a rare demyelinating disease posing a challenging differential diagnosis approach, namely with MS and NMO. Although the majority of patients improve significantly after immunosuppressive therapy, full recovery is less frequent and occurs in less than a half of patients. ADEM most frequently presents as a monophasic disease but recurrences and progression are frequent in MS and NMO.

#2113 - Case Report

IT IS NOT ALWAYS A TIA

Catarina Teles Neto, Marta Valentim, Ana Gameiro, Luís Siopa
Hospital Distrital de Santarém EPE, Santarém, Portugal

Introduction

It is estimated that up to 60% of patients referred with a diagnostic hypothesis of transient ischaemic attack (TIA) do not have this diagnosis confirmed. Any causa of transient neurologic symptoms such as migraine, metabolic disorders, drugs, among others, may mimic a TIA.

Case description

A 75 year-old male with systemic hypertension and chronic obstructive pulmonary disease due to smoking, was brought to the Emergency Room because of an acute confusional syndrome lasting for 1 hour. There was no history of trauma or alcohol/drugs consumption. He was conscious and cooperative, but disoriented in person, time and space and dysarthric speech, but no other neurologic deficit; his vital signs were stable and remaining physical exam was unremarkable. Stroke protocol was activated and his head and neck vessels angio-CT had no acute changes. Arterial blood gas and blood tests were within normal parameters, including negative etanol levels. Because of a NIHSS score of 2 he was not submitted to thrombolytic therapy and was admitted to neurological surveillance. Urinalysis then revealed positive for amitriptyline that he had started the week before. Along with drug suspension, progressive clinical improvement was seen over the first 24 hours. Head MRI was performed without any evidence of vascular lesions, so it was considered as a confusional syndrome associated with amitriptyline.

Discussion

Amitriptyline is a tricyclic antidepressant that inhibits serotonin and norepinephrine reuptake; it also has high affinity to histamine H1 and muscarinic M1 receptors. Although rare, the possibility of an acute confusional syndrome associated with the anti-cholinergic effects of this drugs has been described. It is fundamental to look for any iatrogenic cause when we are before a transient neurological condition.

#2163 - Medical Image

KLEBSIELLA PNEUMONIAE OTOMASTOIDITIS AND MENINGITIS

Inês Vieira Santos¹, Isabel Montenegro Araújo², Catarina Lameiras³, João Gonçalves⁴, Rodolfo Gomes², Rita Faria², Patricia Patricio², António Messias²

¹ Hospital Espírito Santo de Évora, Évora, Portugal

² Hospital Beatriz Ângelo, Lisboa, Portugal

³ Hospital Fernando da Fonseca, Lisboa, Portugal

⁴ Hospital Luz Arrábida, Porto, Portugal

Clinical summary

75-year-old male, history of hypertension and diabetes mellitus, was admitted to the hospital due to a state of consciousness (GCS 10) and fever. Cranioencephalic computed tomography (CE-CT): obliteration of the mastoid and tympanic cavity by tissue component. Lumbar puncture: purulent cerebrospinal fluid (CSF), elevated protein concentration 546mg/dl, hypoglycorrhachia 2mg/dl, and pleocytosis. Evolution in septic shock. Admitted bacterial meningitis and started Ceftriaxone, Ampicillin, and Vancomycin empirically. Subsequently with identification of *K.pneumoniae* in CSF. CE-CT reassessment with otomastoiditis and osteomyelitis with isodense levels of the occipital horns and hydrocephalus. He subject to mastoidectomy with the closure of the liquor fistula with favorable evolution.

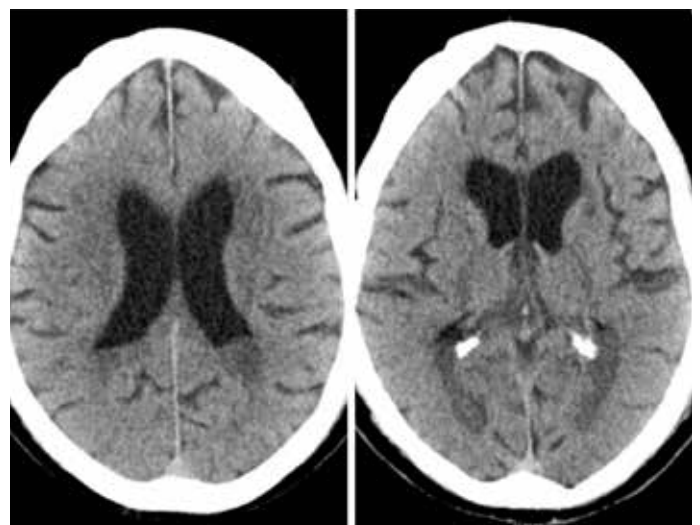


Figure #2163.

#2168 - Medical Image

TO ANTIPLATELET OR NOT ANTIPLATELET, IS THAT THE QUESTION?

Rita Ribeirinho Duarte, Ana Sousa, Francisco Dias Cláudio, Tiago Tribolet Abreu, Margarida Jacinto
Hospital Espírito Santo de Évora, Évora, Portugal

Clinical summary

A 72-year-old man presented to the emergency (ED) with a 12-hour-long headache and diminished strength in his right leg. 3 months earlier, the patient had a loss of conscience and left body hemiparesia. CT and MRI had no acute changes, a diagnosis of acute ischemic stroke was made and he was discharged with clopidogrel. 1 month later, he suffered a small energy trauma, with no injury. The patient had a GCS of 15 and diminished strength on his right arm and leg. CT revealed chronic left frontoparietal subdural hematoma, a right subphalcial hernia and deleted left cisterns. The patient underwent hematoma drainage. Antiplatelet is a well established therapy, but it is not without risks. If stroke diagnosis is not straightforward, one should consider if risks might outweigh the benefits.

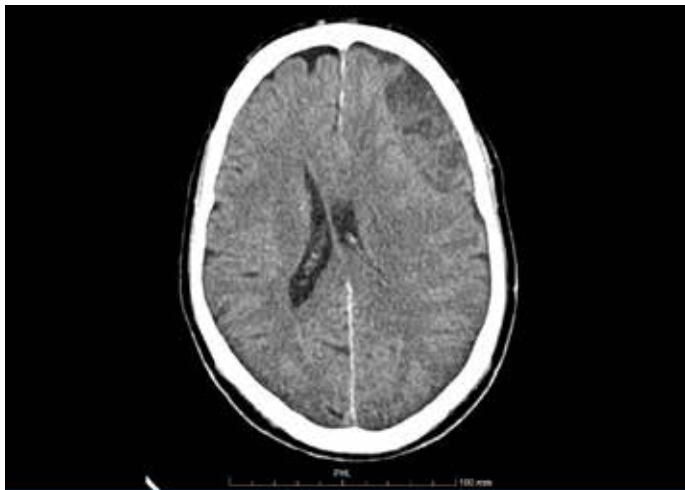

Figure #2168. CT Scan with frontoparietal hematoma and deleted left cistern.

#2170 - Case Report

INFLUENZA H3N1 ENCEPHALITIS – CAN FLUE TAKE OVER YOUR BRAIN?

Rúben Reis, Francisco Pulido Adragãos, Inês Nunes, Armindo Ramos
Hospital de Cascais, Cascais, Portugal

Introduction

Influenza virus infection can have a range of presentations, from asymptomatic to life-threatening disease. Most commonly presented as malaise, myalgia, fever and upper airway symptoms, but it can also present as pneumonia, myocarditis, acute renal failure, liver failure and encephalitis. We report an influenza pneumonia and encephalitis case.

Case description

The authors report a case of a 57 year old woman with history of hypertension, obesity, type 2 diabetes and schizophrenia. Chronically medicated with clozapine 200 mg/day, biperiden 4 mg/day, simvastatin 20 mg/day, indapamide 1.5 mg/day and metformin 1000 mg/day. The patient presented with a week history of flu like symptoms with altered mental status (Glasgow coma score 10), fever (38°C) and dyspnea. Laboratory results showed an elevated C reactive protein (15.85 mg/dL), acute kidney injury (Creatinine 2.04 mg/dL) and positive rapid influenza antigen, arterial blood gas revealed type 2 respiratory failure, and urine and blood tests were negative for benzodiazepine, ethanol and tricyclic antidepressants. Chest X-ray was compatible with pneumonia and head computer tomography was normal. Initially admitted as pneumonia with altered mental status (sepsis) and medicated with oseltamivir and ceftriaxone. The patient's mental status deteriorated to a GCS 3 within 2 days and eventually transferred to the ICU where she was mechanically ventilated. During the ICU stay the patient developed a generalized tonic-clonic seizure after the suspension of propofol. EEG showed epileptiform activity and a lumbar puncture was performed: high opening pressure, glucose 131 mg/dl, white cell count 1/microl; protein 61 mg/dL. Search for inotropic viruses and head magnetic resonance were requested. Both CSF and blood Influenza RNA test were positive for Influenza A H3N1 and oseltamivir was continued for 15 days. Due to improving mental and cognitive status, the isolation of the influenza virus and seizure control with valproic acid and levetiracetam, the brain MRI request was cancelled. The patient made a full recovery by the 30th day of ICU and was transferred to the medicine ward.

Discussion

Although rare, influenza encephalitis should be considered in some specific settings, such as its seasonal epidemics (winter) or in some pandemic settings (H1N1 pandemic in 2009). Even though the symptoms may differ from patient to patient, this diagnosis should be considered when altered mental status or new neurologic symptoms appear in the settings described above.

#2172 - Case Report

FROM A “STROKE” TO AN OVERWHELMING DIAGNOSIS

Salomé Marques, Daniela Neto, Vitor Macedo Silva, Clarisse Neves, Emilia Lopes, Jorge Cotter
Hospital da Senhora da Oliveira, Guimarães, Portugal

Introduction

Glioblastomas are malignant brain tumors with poor prognosis. Its presentation usually occurs in the 70th decade of life and is characterized by symptoms associated with the mass effect of the fast-growing tumor. Some forms of presentation may arise as focal neurological symptoms or as seizures.

Case description

54-year-old male, with no known cardiovascular risk factors, presented with a 3-day history of intermittent paresthesia and paresis of the hemiface and upper limbs. During the hospitalization, some of these episodes were observed and there was also labial commissure deviation. A mild insular hypodensity and ipsilateral parietocorticossubcortical hypodensity were demonstrated in the CT-CE with suspicion of hyperdensifying focus in the M2 segment of the left middle cerebral artery. The analytical study, doppler US of neck vessels and transthoracic echocardiogram showed no significant alterations. However, transesophageal echocardiography revealed a FOP with right-to-left shunt. The patient was discharged from hospital without any neurological deficit, oriented to the Internal Medicine and Cardiology consultation and started hipocoagulation with a NOAC. At one month follow-up, he maintained episodes of paresthesia and paresis of right hemiface and upper limb. Ten days after, he was admitted to the ER due to convulsive crisis and a brain MRI was performed. It showed multiple corticosubcortical frontal-temporo-insular infiltrative lesions (with extension to the lenticular nucleus), parieto-temporal on the left side, with hyposignal at T1, hypersignal in the sequences with long RT and heterogenous enhancement after gadolinium. These lesions also comprised cystic/necrotic areas in frontal location and conditioned focal parenchymal expansion and mass effect with left lateral ventricle compression. These aspects suggested a high-grade multicenter glioma, likely glioblastoma multiforme. The patient was transferred to Neurosurgery care and was submitted to craniotomy with awake-asleep-awake anaesthetic technique. The affected tissue was only partially removed due to development of transient dysarthria. On the first postoperative day there was a sinking of the patient's state of consciousness due to intracerebral haemorrhage with deviation of the midline structures. Histological analysis of the tissue removed confirmed the diagnosis of high grade glioma

Discussion

High-grade gliomas are characterized by rapidly growing lesions and may be confused in an early stage with cerebral ischemic lesions.

#2213 - Case Report

DID COCAINE PLAYED A ROLE? - CASE REPORT

Rafaela Pereira, Ana Varela, André Florêncio, Motasem Shamasna, Conceição Viegas, Ana Paula Fidalgo
CHUA Faro, Faro, Portugal

Introduction

Drug consumption increase the risk of ischaemic and haemorrhagic stroke. Therefore, cerebrovascular disorders contribute to the morbidity and disability associated with illicit drug use.

The most commonly drugs associated with stroke are amphetamine and cocaine.

Cocaine use is associated with both intracerebral haemorrhage

and subarachnoid haemorrhage. As with ischaemic stroke the exact mechanism involved is not fully understood though may involve cocaine-induced haemodynamic changes in susceptible individuals. Potential causes include cerebral vasospasm, increased platelet aggregation, acute hypertension, dysrhythmias, embolization caused by infective endocarditis, vasculitis and exacerbation of pre-existing vascular disease.

Case description

A 56-year-old male patient, with a history of alcohol and tobacco abuse, was admitted to the hospital reporting blurred vision and gait disorder since he woke up. He mentioned that he had consumed cocaine the day before. On physical examination he had a blood pressure of 129/71 mmHg and the neurological exam revealed left homonymous hemianopsia. The brain Computed Tomography Scan (CT Scan) demonstrated an intracerebral hemorrhage in the right parietal lobe. Brain Magnetic Resonance Imaging (MRI) revealed a right parietal hemorrhage with 48 mm diameter and excluded subjacent lesions. The blood tests performed were unremarkable. The urinalysis exam, to determine the presence of toxic substances, revealed the presence of cocaine.

Discussion

We present a case of a hemorrhagic stroke possibly associated with cocaine use. Drugs use should always be considered as a possible cause of stroke, especially in young people and in patients who lack other vascular risk factors. However, it is impossible to prove that the cause was exclusively due to drugs.

Due to the short half-life of cocaine, high arterial blood pressure may no longer be found in the initial evaluation of the patient. Indeed, this patient presented normal blood pressure values.

The authors want to emphasize to always consider a toxicology screening for drugs in young patients with stroke and no obvious cause or if suggested by clinical history or examination.

#2238 - Case Report

A RARE TYPE OF STROKE, WHEN ONE-SIZE-FITS-ALL APPROACH DOESN'T WORK!

Rita Amorim Costa, Marta Gomes Rodrigues, Isabel Taveira, Raul Neto, Pedro Salvador

Centro Hospitalar de Vila Nova de Gaia / Espinho, Vila Nova De Gaia, Portugal

Introduction

Cerebral Venous Thrombosis (CVT) is rare (less than 1% of strokes) and is often underdiagnosed. It is more common in young adults and women, with an incidence of 7 cases/million. Acquired or hereditary thrombophilias, oral contraceptives, pregnancy, puerperium and neoplasias are highlighted as risk factors. The clinical presentation is variable and dependent on the occluded vessel. The diagnosis is based on brain CT and MRI with venographic study. We present the case of CVT in a young man with an inherited thrombophilia and discussion of therapeutic options.

Case description

A 42-year-old man, with obstructive sleep apnea and obesity, was brought to the ER after an inaugural tonic-clonic crisis, associated with headache and vomiting within the last 4 days. At admission he presented GCS 12 and motor aphasia. Cranial CT revealed left temporal parenchymal hematoma associated with hyperdensity of the lateral sinus. In the veno-CT, there was no filling of the lateral sinus and left jugular vein, compatible with CVT, and hypocoagulation was started. He evolved unfavorably, with depressed level of consciousness and motor deficits. A new CT confirmed the hematoma was conditioning compression of the brainstem and incipient hydrocephalus. Decompressive craniectomy was performed and he was admitted in the ICU where he kept therapy to control intracranial pressure (13 days). The etiological study identified Factor II mutation 20210A in heterozygosity and 4G variant at position -675 of the plasminogen activator inhibitor-1 (PAI-1) gene in homozygosity. After 40 days, the patient is oriented, with slight mixed aphasia, with no campymmetric deficit or oculomotor limitation, right central facial paresis and grade 4 right hemiparesis.

Discussion

Mutations in the Factor II and PAI-1 genes are associated with an increased risk of venous thrombosis. The cases describing both mutations are rare and may explain the etiology of the mentioned case. There are several therapeutic options in CVT such as hypocoagulation, reperfusion techniques (intravenous thrombolysis or mechanical thrombectomy) and decompressive craniectomy. Given the low incidence of CVT, the available clinical evidence is scarce. Mortality doubles in patients with associated hemorrhage and management of the risks/benefits of hypocoagulation can be hard. There are still no evidence whether the patient would have benefited from endovascular reperfusion therapy. Randomized trials are essential for better guidance and therapeutic standardization.

#2244 - Medical Image

DURAL ARTERIOVENOUS FISTULA MIMICKING A ISCHEMIC STROKE

Ivan Cadena, Sara Nicolau, Soraia Texeira, Joana Canadas, Manuela Grego

Hospital de Santarem, Santarém, Portugal

Clinical summary

A 74-year-old male with hypertension and dyslipidemia, was admitted due to the progressive appearance of transitory disorientation deficits that worsened in the last 24 hours with ataxia and aphasia of expression. At the psychical exam disartic language, facial asymmetry and hypoesthesia in the right upper extremity. CT-angiography head and neck revealed the existence of tortuous vessels in the left internal temporal region, which raised the suspicion of dural vascular malformation. Cerebral Angiography showed a complex multipedicular dural fistula

centered in the left lateral sinus / sigmoid, which is imprisoned with marked retrograde cortical and transcerebral venous flow. Embolization with Oxyx[®] obtained in the final closing of the fistula, without interurrences on an NIHSS1 scale.

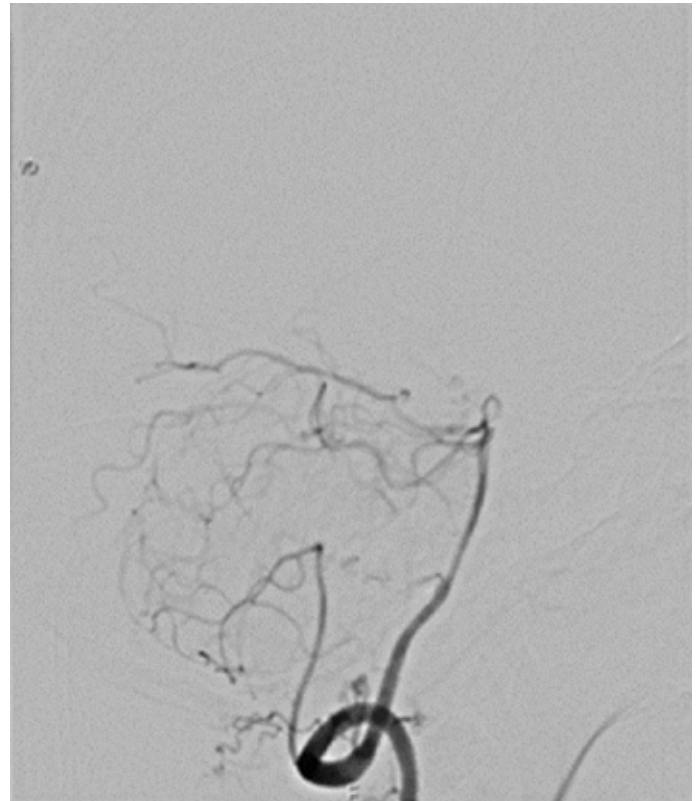

Figure #2244. Multipedicular complex dural fistula centered on the lateral / left sigmoid sinus.

#2249 - Abstract

A RETROSPECTIVE ANALYSIS OF ACUTE STROKE PATIENTS IN A GENERAL MEDICAL WARD

Rita Valente, Estefânia Turpin, Filipa Cardoso, André Rebelo Matos, Tiago Pacheco, Margarida Sá Pereira, Isabel Marcão
Central Lisbon University Hospital - S.José - Medicina ¹4, Lisbon, Portugal

Background

The acute cerebrovascular stroke is a major cause of hospital admissions, having multiple risk factors and several possible outcomes, from lack of neurological injuries to fatal events.

Methods

Retrospective analysis of clinical records from patients admitted in a general medical ward with diagnosis of acute stroke between January and December 2018.

Results

Among 922 patients, 123 acute strokes were identified: 98 ischaemic (18 transient ischaemic attacks and 80 ischaemic

strokes) and 25 hemorrhagic events. Both subgroups had similar mean age at onset (approximately 76 years old) and there was no substantial gender difference. The ischaemic subgroup presented a higher prevalence of cerebrovascular risk factors: 80% of patients had at least 2 risk factors vs 56% in the acute hemorrhagic stroke (AHS) subgroup. Regardless of the injury type, arterial hypertension and dyslipidemia were the most common (prevalence of 80% and 40%). Only two patients who suffered an AHS were taking an anticoagulant (warfarin), both due to a previous diagnosis of atrial fibrillation (AF). Considering the 98 patients with an ischaemic event: 37% had AF, 29% previously diagnosed, 50% (n=14) of these already medicated with an anticoagulant - 36% (n=5) warfarin and 64% (n=9) direct oral anticoagulant (DOAC); 7 patients eventually switched to another drug and, overall, 9 started anticoagulation (8 DOAC). Most underwent additional cardiovascular examination: 63% transcranial and/or carotid doppler ultrasound, 51% transthoracic echocardiogram and 29% 24h-Holter monitoring. Furthermore, 28% were submitted to endovascular procedures: fibrinolysis (n=15), thrombolysis (n=9) or both (n=1). Regarding the outcome after an ischaemic accident: 51% had none or minor neurological sequelae, while 13% became totally dependent and 7% died. This contrasts with AHS, which caused no impairment in only 24% and were fatal in 44% of situations. Altogether, 35% of patients were referred to a public rehabilitation center or another hospital.

Conclusion

Despite the existence of specialised stroke care units, cerebrovascular events are still a leading diagnosis in general medical wards and its approach is constantly evolving. Well-recognised risk factors, as AF, have several treatment possibilities and should be regularly assessed. A considerable amount of patients develop neurological injuries that might compromise their autonomy and/or have recovery potential, illustrating the crucial importance of a proper rehabilitation center network.



EMERGENCY AND ACUTE CARE MEDICINE

#138 - Abstract

TRANSFERS FROM SUBURBAN HOSPITALS: DO WE REDO TOO MUCH EXAMS? A RETROSPECTIVE STUDY

Jérôme Bertrand¹, Christophe Fehlmann¹, Olivier Groscurin^{1,2}, François Sarasin¹, Omar Kherad^{3,4}

¹ Emergency division, Department of Acute Medicine, Geneva University Hospitals, Geneva, Switzerland

² Division of internal and general medicine, Department of Medicine, Geneva University Hospitals, Geneva, Switzerland

³ Division of Internal Medicine, Hôpital de La Tour, Meyrin, Switzerland

⁴ Department of Medecine, University of Geneva, Geneva, Switzerland

Background

Patients' transfer from primary to tertiary care emergency departments (ED) is frequent, mainly because medical resources, technology and/or specialist consultations are lacking. Receiving hospital often repeat laboratory and/or radiographic tests despite receiving data from the sending structure. The aim of this study was to quantify the number of patients transferred to a tertiary care ED, and to estimate the frequency and inappropriateness of repeated procedures.

Methods

We conducted a retrospective chart review of all patients transferred from one primary care ED to a tertiary care ED from January 2016 to December 2016. We considered as redundant a procedure repeated during the 8 hours following the transfer despite the availability of the results. Two authors independently assess whether redundancy was appropriate or not. The inter-observer agreement was measured with a Kappa-coefficient. Factors predicting repetition of procedures were identified through a logistic regression analysis.

Results

During the year 2016, 432 patients were transferred from the primary emergency center to the tertiary center. Two-hundred and fifty-one procedures were repeated: 179 patients had a repeated laboratory tests, 34 a repeated radiological procedure and 19 both. The only risk factors for a repeated blood test was an advanced age (>65 years old) (aOR=1.8, 95%CI 1.2-2.7), and for a radiological procedure, a surgical (versus a medical) problem (aOR=1.9, 95%CI 1.0-3.7). Repeated procedures were judged

as partially or totally inappropriate for 197 (99.5%) laboratory tests (Kappa=0.57) and for 39 (73.6%) radiological procedures (Kappa=0.82).

Conclusion

Over half of the patients transferred from another emergency department have a repeated procedure. In most of the case (94%), these repeated procedures were considered as inappropriate.

#164 - Case Report

AN UNUSUAL BUT EMERGENT CAUSE OF CHEST PAIN

Cristina Martins, João Pina Cabral, Pedro Ribeiro, Armando Carvalho

Centro Hospitalar e Universitário de Coimbra - Hospital Geral, Coimbra, Portugal

Introduction

Chest pain is responsible for 5.5 to 5.8 million visits to emergency rooms (ER) each year. It has many possible causes: cardiac, respiratory, muscular-skeletal, esophageal/gastrointestinal, neurological, psychological, making it difficult to reach a definite diagnosis, when particular clinical settings are present. Chest pain related to esophageal disorders may be particularly difficult to diagnose and to distinguish from a cardiac origin pain.

Case description

A 67 years old man, with hypertension, dyslipidemia and obesity, presents to the ER complaining of anterior chest pain, irradiating to the back, with 2 hours of evolution, accompanied with nausea and vomiting (with no blood). On admission he was febrile, with a BP of 144/78 mmHg, a HR of 108 bpm and a SpO₂ of 90%, breathing air. He was conscient and oriented, with an innocent physical exam, except for a diminished respiratory sound in the inferior left pulmonary region. His blood gas analyses showed a type I respiratory failure (pO₂ 57.2 mmHg; pCO₂ 36.4 mmHg) and a rise in lactate level (3.24 mmol/L) with no acidemia. ECG was normal, except for a sinus tachycardia. Fluids, oxygen and analgesia were administered, with no improvement. Blood analysis revealed a discrete leukocytosis, a normal C-reactive protein, and normal levels of troponin and d-dimer. The chest X-ray, though, showed signs of pneumomediastinum (in the

posterior incidence: a tubular artery sign; in the lateral incidence: a continuous diaphragm sign), later confirmed with a chest CT, that related a pneumomediastinum, particularly important in its posterior region, next to the posterior-lateral section of the distal esophagus, suggesting an esophageal rupture. It also identified a left sided pleural effusion, with air within, suggestive of a hydropneumothorax. A Boerhaave Syndrome was assumed as the most probable cause of this pneumomediastinum and, therefore, of this chest pain. The case was discussed with general surgery, and the patient was submitted to a near total esophagectomy, and then admitted into the Intensive Care Unit.

Discussion

Pneumomediastinum is defined as free air or gas contained within the mediastinum. Although unusual (particularly in the setting of a spontaneous esophageal rupture - Boerhaave Syndrome), it may be an emergent cause of chest pain, so clinicians should always be aware of its possibility, specially since its diagnosis may be suspected after careful examination of a chest x-ray, as happened in our case.

#173 - Medical Image

AIRWAY MANAGEMENT IN AN ACUTE CASE OF ANGIOEDEMA

Adriana Bandeira, Joana Gonçalves, Luís Pereira
Centro Hospitalar de Leiria, Leiria, Portugal

Clinical summary

71 year old patient presenting in the ER with a rapid onset of dyspnoea and refractory angioedema of the face and neck, requiring immediate intubation with videolaryngoscopy support and ventilation.

CT scan less after intubation showed marked symmetrical edema involving the entire anterior facial and cervical region, as well as the perivisceral deep planes extending to both below the superficial aponeurosis of the neck and the posterior cervical compartment, suggesting a more generalized, systemic cause. The more probable cause was an allergic reaction as the episode occurred after eating octopus for the first time, and steroids and antihistamine treatment was started. Within 72 hours there was a clinically significant improvement leading to ventilatory weaning and extubation.

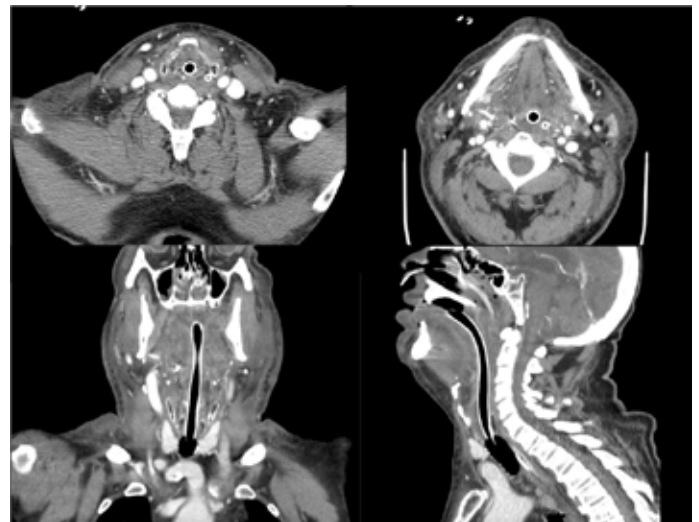


Figure #173. Head and neck CT scan showing patient with severe angioedema and a 6cm endotracheal tube. Axial, sagittal and coronal planes.

#206 - Abstract

THE INTENSITY OF PULMONARY EMBOLISM IN AN ICU - CLASSIFICATION AND MORTALITY

Sara Lopes Fernandes¹, Alexandre Fontoura², Nuno Sousa², Hélia Martins¹, Luísa Lopes²

¹ Leiria Hospital Center, Leiria, Portugal

² Local Health Unit of Guarda, Guarda, Portugal

Background

Pulmonary Embolism (PE) is an important cause of hospitalization and mortality, with an increasing incidence in Portugal. The clinical spectrum includes shock and cardiac arrest, requiring tight surveillance and control, including admission in an Intensive Care Unit (ICU).

Methods

Retrospective study of patients with PE admitted in a ICU, from January 2014 to November 2018. Evaluation and descriptive analysis of the classification and mortality of the PE.

Results

A total of 36 patients were admitted in the UCI with PE (66% bilateral or central), with a mean age of 66 ± 19 years and higher prevalence of men (58%). The main reason for admission was respiratory failure (58%), shock (11%) and cardiac arrest (8%). In the initial assessment, 9 patients had shock or hypotension (25%), 22 had positive cardiac biomarkers (61%) and echocardiogram showed dysfunction of the right ventricle (RV) in 18 cases (50%). The Severity Index of Pulmonary Embolism (PESI) was calculated, with an average of 136 ± 56 , most of them grade IV and V (75%). The short-term risk-of-death classification divided patients into low (6%), intermediate-low (33%), intermediate-high (36%) and high (25%) risk subjects. Comparing this groups, there was a significant

difference in the mean age ($p=0.005$), with a successive increase especially from the lowest to the highest risk group ($p=0.007$). Unlike the others, the high risk group had more female than male ($p=0.76$). The mean PESI score was significantly different ($p=0.000$), with increased values associated with increased risk. Total mortality was 19% ($n=7$), 6 of them in-hospital (17%), with 57% males and mean age of 82 years. Of those who died, 57% belonged to the high risk group, 29% to the intermediate-high and 14% to the intermediate-low risk group; 100% had PESI score V (mean 183 vs 127, $p=0.008$), 86% had positive cardiac biomarkers ($p = 0.069$) and 50% RV dysfunction.

Conclusion

PE is associated with a high morbidity and mortality rate. The results of this series show the importance of risk classification and stratification of patients with PE, as a form of early warning and a more timely and targeted approach.

#217 - Case Report

DRUG HYPERSENSITIVITY - THE IMPORTANCE OF DIAGNOSTIC SUSPICION

Marta Rafael Marques, Dolores Vazquez, Susana Marques Sousa, Vera Seara, Sónia Fernandes, Alexandre Mendonça

Centro Hospitalar Póvoa de Varzim/Vila do Conde, Vila Do Conde, Portugal

Introduction

The appearance of urticaria after a few hours of use of a new drug is easily recognized as possible drug hypersensitivity. However, many clinical presentations of drug hypersensitivity are more complex or occur in the context of disease and / or polytherapy.

Case description

An 84-year-old woman, hypertensive and dyslipidemic, came to the emergency room with generalized malaise, nausea and abdominal discomfort with 4 days of evolution, associated with a febrile peak (axillary temperature 38.5°C) and lipothymia on the previous day. She had been medicated for the previous 9 days with trimethoprim-sulfamethoxazole (TMP-SMX) 160/800 mg, orally, for uncomplicated acute cystitis. At admission, the patient was awake, glasgow coma scale 15, hypotensive (PA 87/45 mmHg), FC 87 bpm, without fever; she presented with generalized, symmetrical rash with maculopapular rosacea lesions, some discrete and small and others confluent, not pruritic, on the trunk, abdomen and more proximal extremities compatible with morbilliform exanthema and diffuse erythema on the back. Analysis revealed pancytopenia (normochromic normocytic anemia Hb 11.0 g/L, leucopenia 3790/L, absence of eosinophilia and thrombocytopenia 106,000/L), acute renal damage (Creatinine 2.3 mg/dL, Urea 81.1 mg/dL), hyponatremia, hepatic lesion (IGT 56 U/L, TGP 41 U/L, GGT 60 U/L, FA 114 U/L, normal bilirubin) and elevated inflammatory parameters (CRP 11.42 mg/dL, VS 26 mm/h). HBV, HCV, HIV, CMV and HBV were negative. Electrocardiogram and Chest X-ray were

normal. Because of suspicion of late hypersensitivity reaction to TMP-SMX with multiple organ dysfunction (cardiovascular, hematological, renal, hepatic and cutaneous), the antibiotic was discontinued and support measures were initiated. In the first 24 hours, there was also progression with erythema of the face and oral mucosa reaching, without erosions. However, after 72 hours, it evolved favorably with regression of rash and gradual normalization of the organic disfunctions.

Discussion

TMP-SMX is generally well tolerated in non-HIV infected patients, with adverse reactions occurring in about 6 to 8% of subjects. The most common side effects involve the gastrointestinal tract and the skin, with nephrotoxicity being uncommon. Potentially fatal effects, such as neutropenia, anaphylaxis and severe dermatological reactions, usually affect the elderly, so a high degree of clinical suspicion and early drug discontinuation are required.

#229 - Case Report

MIDDLE-AGED MALE PATIENT WITH RENAL INFRACTS DUE TO FIBROMUSCULAR DYSPLASIA PRESENTS WITH ACUTE ABDOMINAL PAIN

Dimitra Stathi, Konstantinos Kounouklas, Panagiotis Petrikos, Anna Mari, Eleni Karantoni, Nikolaos Symeonidis

General Airforce Hospital, Athens, Greece

Introduction

Acute abdominal pain due to renal infraction as result of fibromuscular dysplasia is rarely reported. The aim of our case report is to emphasize the importance of a broad differential diagnosis in patients presenting with acute abdomen.

Case description

A 47-year old male with no medical history or regular medical treatment was admitted due to acute upper abdominal pain. Physical examination revealed epigastric tenderness. Differential diagnosis included acute cholecystitis, choledocholithiasis, acute pancreatitis, acute pyelonephritis, ACS, gastric ulcer, mesenteric ischemia, renal infarcts and polyarteritis nodosa. Lab tests in the ER: SGOT: 63, SGPT: 79, LDH: 657, CRP: 75 (normal values < 10), no other significant findings. An abdominal U/S followed by a CT scan without contrast was performed and revealed a gallbladder polyp and fatty liver. Patient was admitted for further investigation. Gastroscopy, MRCP and echocardiogram were scheduled. Mild erosive gastritis, pancreas divisum and a mild pericardial effusion were correspondingly revealed from the above tests. However, due to progressively increasing pain and worsening of lab tests, a thorax-abdomen CT with IV contrast was performed and showed renal parenchymal defects on both kidneys, right renal artery stenosis as well as bilateral arterial wall thickening. Diagnosis was confirmed by renal angiography, which besides renal infarcts also revealed multiple bilateral renal arteries and the "string-of-beads" feature, characteristic of fibromuscular dysplasia.

Discussion

The significance of our case depends on the rare appearance of fibromuscular dysplasia in a male patient presenting with acute abdominal pain and increased LDH due to renal infarcts. The diagnostic value of CT scan with IV contrast should also be noted. Clinicians should include the case of acute renal infarcts in their differential diagnosis when acute abdominal pain and increased LDH are present.

#234 - Medical Image

CAN A URINARY RETENTION CAUSE BOWEL OBSTRUCTION?

Ana Isabel Andrade Oliveira, Joana Morais, Olga Pires, Inês Burmester, Isabel Agonia, Maria João João Regadas, Paulo Gouveia

Hospital de Braga, Braga, Portugal

Clinical summary

Mechanical or functional conditions can cause bowel obstruction. A woman in her 90's was brought to the emergency with depression of consciousness and confusion. Her daughter reported urinary incontinence, lack of bowel transit and a urinary tract infection. On examination, she had abdominal distension, tympanism and high frequency of metallic abdominal sounds. The x-ray showed air-fluid levels, consistent with obstruction. An enema was done without effect. After that, a CT revealed urinary retention and dilatation of the excretory systems. A urinary catheter was placed draining 1500 cc of urine. With bladder decompression the intestinal transit restarted and her cognitive status improved. This case represents an atypical and exuberant cause of intestinal occlusion that could have gone unnoticed.

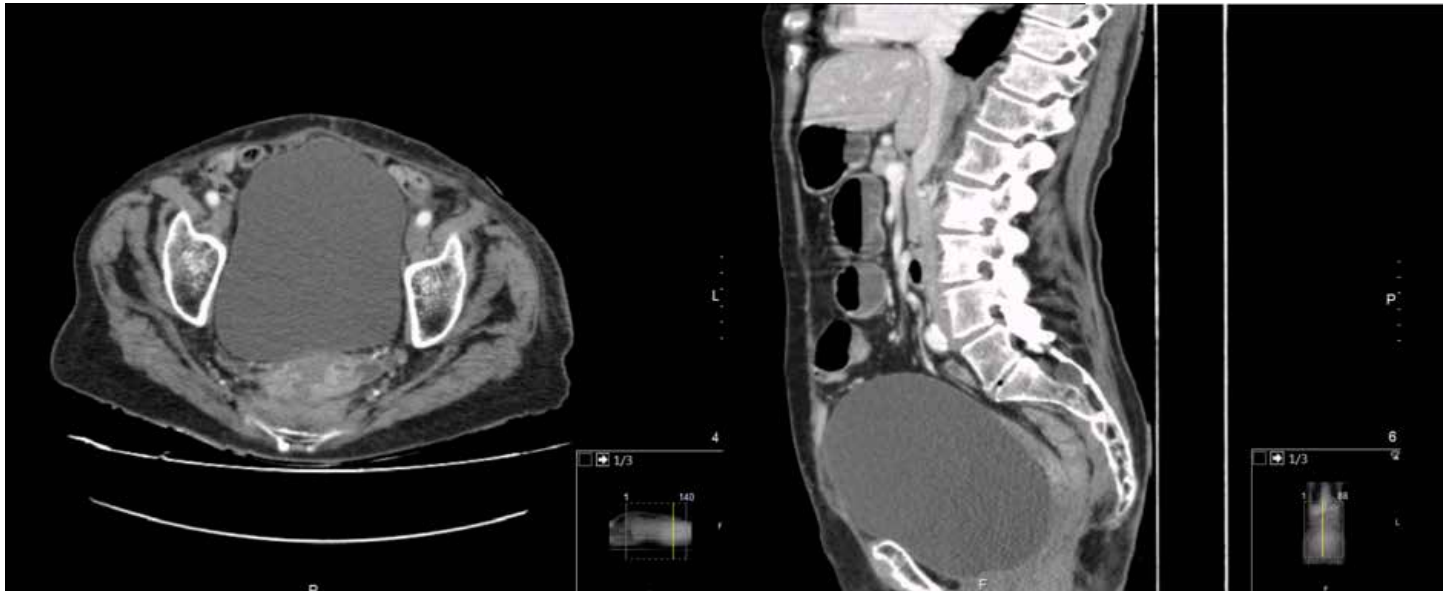


Figure #234.

#248 - Case Report

RARE AND UNDERDIAGNOSED COMPLICATION OF LONG-STANDING DIABETES: A CASE REPORT OF DIABETIC MYONECROSIS

Cristina Gavala, Loura Khallouf, Erik Holzwanger
UMassMemorial Hospital, Worcester, United States

Introduction

Diabetic myonecrosis, also termed diabetic muscle infarct, is a rare and severe complication of longstanding, poorly controlled Diabetes Mellitus. Angervall and Stener first described this condition in 1965 and less than 200 cases have been reported in the literature since. This disorder typically presents as a nontraumatic acute onset of pain and swelling of the affected muscle most frequently in the lower extremities and involving

the muscles of the thigh. Diabetic myonecrosis usually occurs in patients with an established longstanding history of diabetes in the setting of other associated microangiopathic changes such as retinopathy, neuropathy, and nephropathy. The main treatment involved with this disorder involves strict blood sugar regulation. We present an exceedingly rare case of diabetic myonecrosis in a 54-year-old woman with poorly controlled type II Diabetes Mellitus (DMII).

Case description

A 54-year-old woman with history of longstanding DMII, heart failure with reduced ejection fraction (EF 25%), and hyperlipidemia, presented with a four-week history of atraumatic left medial thigh swelling and pain. She had two courses of broad spectrum antibiotics during this time without improvement. Erythrocyte sedimentation rate and c-reactive protein were mildly elevated,

and she had a normal creatine phosphokinase and anti-nuclear antibody. Hemoglobin A1c done was 10.9%. X-ray of the left femur displayed mild osteoarthritis and soft tissue swelling, however no evidence of fracture or dislocation. Left lower extremity duplex was negative for deep vein thrombosis. MRI of the left thigh showed an area of high T2 signal and nonenhancement within the vastus medialis that measured 9.1 cm craniocaudally, 5.5 cm transversely, 2.3 cm posteriorly along with edema within the vastus medialis muscle both below and above the area of nonenhancement. The MRI findings were consistent with myonecrosis of vastus medialis. In the absence of infectious signs and symptoms along with no improvement in symptoms on broad spectrum antibiotics, she was diagnosed with diabetic myonecrosis. Muscle biopsy is not necessary to establish a diagnosis in such cases.

Discussion

We present an exceedingly rare case of diabetic myonecrosis. Being able to recognize the clinical presentation of this complication early in its course, avoiding unnecessary/invasive testing such as muscle biopsy and initiating treatment for the goal of pain/tighter glycemic control and is essential in prevention of further complications.

#381 - Abstract

ANALYSIS OF RADIOLOGY EXAMS REQUESTED BY AN EMERGENCY DEPARTMENT: DO PHYSICIANS PROVIDE ADEQUATE CLINICAL INFORMATION?

Rute Martins^{1,2}, Pedro Raimundo³, Pedro Alves^{1,2}, Rodrigo Monteiro^{4,2}, Luís Duarte Silva^{4,2}, André Gomes^{1,2}, Graça Afonso^{1,2}

¹ University Hospital Center of Algarve, Faro, Portugal

² Algarve Biomedical Center, Faro, Portugal

³ University of Algarve, Faro, Portugal

⁴ University Hospital Center of Algarve, Portimão, Portugal

Background

Although imaging exams are essential for diagnosis in the emergency context, many unnecessary imaging exams are still requested. The clinical information available is critical to assess the appropriateness of the exams but also to improve their interpretation. Therefore, we aimed to analyze the computed tomographies and ultrasounds requested by the Emergency Department in a district hospital.

Methods

We retrospectively analyzed the computed tomographies and ultrasounds requested by the Emergency Department to the Radiology Department at the University Hospital Center of Algarve during a 20-day period. The selected variables were: requested imaging exam, clinical information provided by the clinician, exam appropriateness and outcome of the exam (relevant findings and findings related to the clinical context). Variables were compared using Pearson's Chi-squared tests.

Results

Out of the 1427 requests analyzed, only 219 (15.3%) were considered to have complete clinical information. Nonetheless, 1075 (75.3%) requests were considered appropriate. Relevant findings were present in about one-third (n=453; 31.7%) of the exams and most of these findings were related to the clinical context (n=410; 90.5%). The presence of relevant clinical findings in the exam were found to be significantly related with the exams classified as appropriate (P<0.001). Moreover, a statistically significant association was observed between the relevant findings and the findings related to clinical context (P<0.001).

Conclusion

The fact that most requests did not provide complete clinical information obscures the radiologist task to understand the clinical usefulness and interpretation of an exam, implicating that each exam requires longer time of analysis, with impairment for both the patients and clinicians involved. Improvement of the communication between doctors, in the form of clinical information, should allow the optimization of the resources available by precluding unnecessary exams, enhancing its prioritization, reducing the time spent per exam and improving its diagnostic accuracy.

#395 - Case Report

SODIUM HYPOCHLORITE ACCIDENT DURING AN ENDODONTIC PROCEDURE - CASE REPORT

Joana Aguiéiras Cabrera, Margarida Mota, Diogo Ferreira

Centro Hospitalar Vila Nova de Gaia / Espinho, Vila Nova De Gaia, Portugal

Introduction

Cleaning and disinfection are mandatory for the success of endodontic treatments. There isn't any irrigation solution that has all the desirable functions. However, NaOCl seems to be the most suitable, since it covers more requirements than any other – it has the unique capacity of dissolving the necrotic tissue and destroying microorganisms organized in biofilms and located in the dentin tubes. Despite these advantages, accidents are reported every year using NaOCl in high concentrations during endodontic treatments: when the solution comes in contact with the organic periodontal and periapical tissues it creates severe necrotic changes with a dangerous organic destruction lesions associated.

Case description

The authors present a clinical case of a 47-year-old female that arrived at the ER with clinical information from her dentist describing the formation of an exuberant edema on the upper lip during a treatment with NaOCl. She showed an increased edema of the upper lip, maxillary region bilaterally with growing equimosis in the described area. There were no stridor or ADRS signs and the mimics of the upper floor of the face was preserved. In the evaluation of the

oral cavity, there were no visible lesion of the mucosa. Blood tests showed an increase in the inflammatory parameters. Treatment with corticosteroid, antihistaminic and antibiotic was administered immediately, but the edemas and the equimosis continued to grow and reached the right periorbital during the first 12 hours. In the following days, the edema was strongly improved and in day 3 equimosis were only seen in the lower right eyelid.

Discussion

In spite of all the advantages, NaOCl is a cytotoxic agent that causes hemolysis and ulceration, inhibits the migration of neutrophils and causes lesions on endothelial cells and fibroblasts.

The literature confirms the occurrence of serious accidents caused by the injection of NaOCl in periapical tissue, resulting in: severe pain, edema in adjacent tissues, bleeding into the root canal, discontinuation of the skin and mucous membrane (ecchymosis), tissue necrosis, secondary infection with formation of abscess and persistent paresthesias. When the NaOCl solution exudes into the peri-radicular tissues, the effect may ranging from a burn to localized or extensive tissue necrosis. Treatment with anti-inflammatories and antibiotics and sometimes a surgical drainage may also be required, depending on the extent of edema and tissue necrosis.

#408 - Abstract

CAN SPEECH-ENABLED PHRASELATORS IMPROVE HEALTHCARE ACCESSIBILITY? A CASE STUDY COMPARING BABELDR WITH MEDIBABBLE FOR ANAMNESIS IN EMERGENCY SETTINGS

Valerie Boujon¹, Antony Janakiram², Johanna Gerlach³, Pierrette Bouillon³, Herve Spechbach²

¹ Translator at AMPLEXOR, Toulouse, France

² University Hospitals of Geneva, Geneva, Switzerland

³ Faculty of Traduction and Interpreting, Geneva, Switzerland

Background

Language barriers are an important problem for healthcare services for minority groups like refugees or sign language users. Interpreters are not always available in emergency settings. Alternatives such as online machine translation are unsatisfactory in terms of languages covered, data confidentiality and translation reliability. Some Phraselators were developed in collaboration with medical staff to produce reliable translations, but they remain unsophisticated. To improve on this, the Geneva University Hospitals and the Faculty of Translation and Interpreting have developed BabelDr, a speech-enabled phraselator. When the doctor asks a question, the system uses speech recognition to recognize what was said and automatically maps this recognition result to the closest pre-translated core sentence.

Methods

The goal of this experiment is to compare two phraselators: BabelDr and MediBabble. We focused on two main criteria:

functional suitability (does speech help to provide the correct result?) and usability (does speech make the system more usable?). We used a crossover design: both systems were used twice by ten medical students in order to find precise information about the patient, based on two different scenarios.

Results

Both phraselators made it possible to collect most of the required information from the patients in the dedicated time. In the two sessions, participants collected 195/200 correct elements with MediBabble and 198/200 with BabelDr. This shows that both phraselators allowed doctors to obtain the correct answers to the medical questions. The two systems are thus closely matched in terms of functional suitability.

In both sessions users took less time to collect information with BabelDr, with an average time difference of 11 seconds (95%CI 4.6 à 17.3, $p < 0.001$) per question.

The average number of mouse clicks is always lower for BabelDr than for MediBabble, with an average difference of 2.7 clicks (95%CI 1.8 à 3.7, $p < 0.001$) per question.

Participants had to fill in a questionnaire after each task, rating statements on a Likert scale. Different questionnaires were used for the first and second session. The first contained 10 questions focussing on ergonomics; the second contained 9 questions with a focus on learnability.

Globally, we observe that BabelDr has more positive answers than MediBabble.

Conclusion

We find that objectively and subjectively the availability of speech in BabelDr makes this system more suitable than a standard phraselator.

#420 - Medical Image

WHEN THE LIGHT BURNS

Maria Vilela

Hospital Santa Maria Maior, Barcelos, Portugal

Clinical summary

A 57-year-old man, with no relevant medical history, presented himself to the Emergency Department in mid August with a painful and pruriginous erythematous edema of both forearms that begun in the previous hour. He reports that he was pruning a fig tree, which he regular does during winter, but had never done during summer.

Several plants, including the fig tree, contain furocoumarin compounds (psoralens) that cause a particular form of dermatitis. Phytophotodermatitis is a condition caused by sequential exposure to photosensitizing substances present in plants followed by ultraviolet (UV) light.

After corticoid administration, the edema reduced and the patient was discharged.

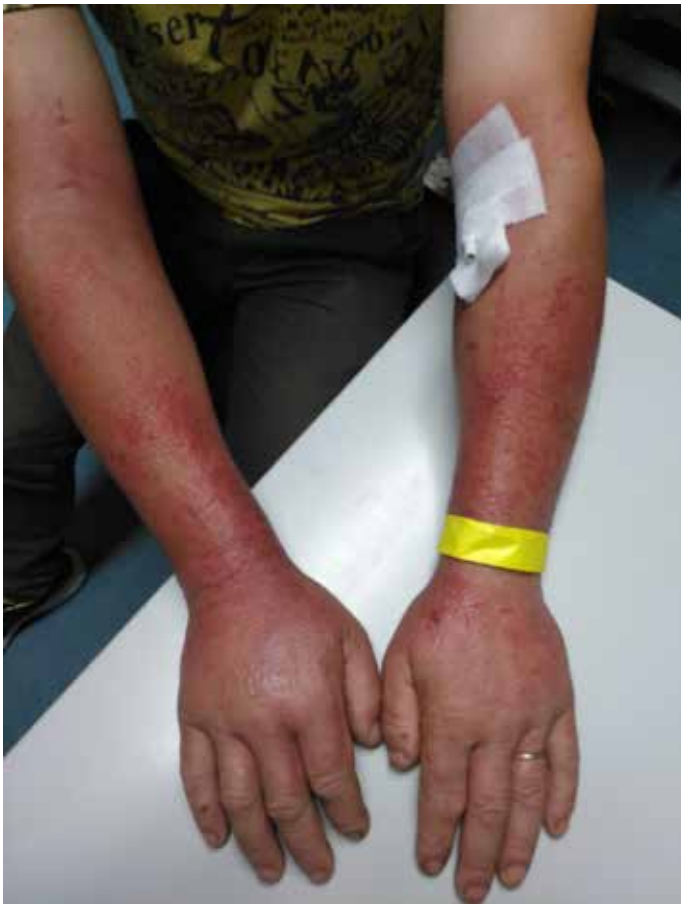

Figure #420.

#485 - Abstract

USE AND ABUSE OF ABDOMINAL RADIOGRAPHY IN EMERGENCY UNIT

María De Los Angeles Galindo-Andúgar, Inmaculada Espinosa-Monroy, Paula Miján-Caño, Jesús Monllor-Méndez, Clara Díaz-Parreño Quintanar, Antonio Martín-Castillo, Míriam Sánchez-López, Cristina Casado-Delgado, Dolores Macarena Lara-Doblas, Marina Cartas-Verdugo

Hospital General La Mancha Centro, Alcázar de San Juan, Spain

Background

The updating and use of New Technologies allow us to improve the medical assistance. However, in overloaded departments as Emergency can head to an abuse of some diagnosis test like the abdominal radiography (ARX). Our purpose is to evaluate the right indication for the ARX in the Emergency Department.

Methods

Descriptive study made in our hospital. We reviewed the patients who came to Emergency department in January, 7th of 2019, choosing those patients with ARX made that day. The correct indication of the ARX was evaluated according to 'Making the best use of a Department of Clinical Radiology: Guidelines for Doctors' from the Royal College of Radiologists of London.

Results

They were included 29 cases from 191 patients who came to Emergency Unit. 17 were males (58%). Median age was 49 years-old (range between 8 and 87), with 2 children below 14 years-old. The main diagnosis was abdominal pain in 12, followed by renal colic (6), diarrhea (3), respiratory infection (3), weight loss (2), urinary infection(2) and intestinal bleeding (1).

8 patients were admitted (27%) and 21 were discharged. A chest radiography was requested in 17 patients (58%) in addition to the ARX. Regarding the 8 inpatients, both radiographies (chest and abdominal) were requested from Emergency department in 7 of them.

There were 11 cases in which the indications were requested for one of the guidelines (38%), which are the followings: ureteral stones (6), acute abdominal pain (2), bowel obstruction (1), perforated viscus (1) and acute renal failure (1). The findings of the ARX were normal or unspecific in most of the patients (18 cases, 62%), followed by faeces (8), dilated bowel loops (2) and ureteral stone (1).

Conclusion

The number of ARX requested in the Emergency Department is bigger than guidelines. The correlation with the radiologist is moderated. It would be recommended a better knowledge of the guideline and the dosage radiation.

#500 - Abstract

PILOT-STUDY OF THE POINT-OF-CARE TEST FOR EVALUATION OF THE HEART TYPE FATTY ACIDS BINDING PROTEIN AND CARDIAC TROPONIN I EFFICACY IN SUSPECTED ACS

Valentin A. Kokorin ¹, Ivan G. Godeev ¹, Mikhail N. Arefiev ², Anna A. Yakovtsova ³, Anna Ya. Goncharova ³

¹ Pirogov Russian National research medical university, Moscow, Russia

² Minicipal clinical hospital #15 named after O.M. Filatov, Moscow, Russia

³ Alliance of Competences, Obninsk, Russia

Background

The simultaneous evaluation of different biomarkers of the myocardial injury (a multimarker strategy) may allow to confirm or exclude the diagnosis of acute myocardial infarction (AMI) more quickly and precise than the serial measurement of cardiac troponins. We aimed to assess the diagnostic efficacy of the new point-of-care express-test for the qualitative simultaneous evaluation of the heart type fatty acid binding protein (H-FABP) and cardiac troponin I (cTn I) concentrations in patients with suspected acute coronary syndrome (ACS).

Methods

One hundred eighteen patients, who were admitted to the clinic with the referral diagnosis of ACS, and had typical chest pain with duration of at least 20 min in the interval between 1 and 24

h before admission were enrolled in the study. The qualitative evaluation of H-FABP and cTn I concentrations was performed upon admission by the immunochromatographic point-of-care test "CARD-INFO 1+1" («CARDIO-Plus», Russia) in addition to the standard diagnostic procedures, including the serial measurement of the high-sensitive Tn I (hsTn I). Diagnostic threshold to H-FABP is 7 ng/ml, to cTn I - 1,5 ng/ml.

Results

AMI was diagnosed in 78 patients (66.1%), unstable angina - in 30 (25,4%), other reasons of chest pain - in 10 (8,5%). The sensitivity of "CARD-INFO 1+1" express-test was 85.9% (95% CI 77.7-91.8%), specificity - 77.5% (95% CI 64.4-87.3%), diagnostic accuracy - 83.1% (95% CI 76.0-88.6%), positive prognostic value - 88.2% (95% CI 80.3-93.5%), negative prognostic value - 73.8% (95% CI 60.5-84.3%). The diagnostic efficiency of the express-test in patients with ACS with and without ST-segment elevation had no significant difference ($p>0.05$). The sensitivity of the "CARD-INFO 1+1" express-test reached the maximum in the period between 3 and 6 hours from the chest pain onset. The application of the "CARD-INFO 1+1" test in addition to the first measurement of hsTn I performed at admission allowed to identify 17.5% more cases of AMI compared with hsTn I evaluation alone.

Conclusion

The pilot-study of the express-test "CARD-INFO 1+1" clinical application demonstrated its high efficiency in the diagnosis of AMI. We require further studies to confirm these compromising results and to clarify the possible implementation of such multimarker point-of-care tests in the diagnostic algorithms of suspected ACS.

#506 - Abstract

ROLE OF RADIOGRAPHY IN EMERGENCY DEPARTMENT. NICE AND CHEAP, BUT ALSO GOOD?

María De Los Angeles Galindo Andúgar, Clara Díaz-Parreño Quintanar, Inmaculada Espinosa-Monroy, Paula Miján Caño, Jesús Monllor-Méndez, Carmen Alarcón-Viejo, Laura Oriente-Frutos, Carolyn Itala Prieto-Espinoza, Luis Alonso González-Sánchez, Ruth Espinosa-Aunión

Hospital General La Mancha Centro, Alcázar de San Juan, Spain

Background

The Spanish Public Health System is universal, and it provides free assistance (cheap). The radiologic tests are widespread, especially in Emergency Unit because of their rapidity and usefulness (nice). However, in overloaded departments as Emergency can head to an abuse of some diagnostic tests. The need for a fast solution can increase the number of requests and therefore the radiation dose received by the patients (no good). The objective is to estimate the number of radiologic test requested in the Emergency Department and if it was related to a trauma in patients with osteomuscular pain.

Methods

Descriptive study made in our hospital. We reviewed the patients who came to Emergency department in January, 7th of 2019, choosing a winter day within the influenza epidemic. Depend on the pathology, the patients were distributed inside the Emergency Unit in four different areas: Pediatrics, Medical/Surgical area, Specialty (includes Ophthalmology, Psychiatry, Orthopedic etc.) and Critic area (provided for advanced cardiopulmonary resuscitation). The clinical reports were reviewed from 'Mambrino XXI' (the clinical informatics system used in our hospital), and the radiology was obtained from 'Ykonos' (all the radiologic test are digitalized and included in this database since the year 2002). Analysis with PASW Statistics 18.

Results

A total of 191 patients were included, 86 males and 105 females, with median age of 51 years-old (range between 3 months and 100 years-old), with 8 oncologic patients and 2 road accident. The distribution was the following: Pediatrics 21 cases (11%), Medical/surgical area 89 (47%), Specialty 70 (37%) and Critic Care 2 (1%). Most of the patients were discharged from Emergency (154 cases, 80%), 32 were admitted at the hospital (17%) and 5 left the unit without assistance. All they stayed between 1-30 hours (median 4 hours). When we reviewed the last year, it was the first time in Emergency only for 89 patients (47%), with 2 patients with 10 and 12 visits.

Radiography was request in 120 cases (63%). The most usual were chest radiography (72), abdominal radiography (29), limbs (15) and spinal column (14). There were 49 patients with osteomuscular pain. If we exclude 7 patients without radiography in this visit, we found more request for patients with traumatic pain than those cases without trauma (24 vs 18) with no statistical significance ($p=0.4$).

Conclusion

Radiologic test were request in two thirds of patients. A previous trauma increases the risk.

#512 - Case Report

MESENTERIC ISCHEMIA - A DIAGNOSTIC CHALLENGE

Catarina Sofia Martins Nóbrega, Ana Margarida De Abreu Temtem, Jéssica Chaves, Catarina Miriam Capelo Freitas, Filipe Pernetá, Maria Da Luz Reis Brazão

Hospital Central do Funchal, Funchal, Portugal

Introduction

Mesenteric Ischemia (MI) is a tissue lesion of ischemic nature that reflect an unbalance between vascular perfusion and metabolic needs. It has a reduced prevalence, affecting mostly the eldest, but when it occurs, it brings about significant morbimortality, mostly related with a difficult timely diagnosis, given its unspecific symptoms. The treatment, in its acute presentation, warrants immediate surgery

the restore abdominal blood flow, and is more prevalent in the female gender and associated with the occlusion by embolus of the superior mesenteric artery. Most patients will require surgical removal of necrotic bowel segments. The main risk factors associated are atrial fibrillation, atrial flutter, cardiac valve disease, ischemic cardiac disease and other structural heart abnormalities.

Case description

A 79-year-old female, with personal history of dyslipidaemia and arterial hypertension, already medicated. Presents herself to the A&E because of vomit and occasional liquid bowel discharges without blood or mucus, with one week of duration. The patient also referred diffuse abdominal pain and fever. Its physical exam the patient was prostrated, feverish, with low BP, with a diffuse abdominal discomfort upon palpation, but without peritoneal reaction. Her blood chemistry evidenced elevation of the Acute Phase Parameters (APP) (CRP 272.23 mg/L), acute kidney failure and a urinalysis with leucocyturia and bacteriuria. She was initially admitted with a presumptive diagnosis of pyelonephritis with gastroenteritis and dehydration and begun Cefuroxime empirically. On the 5th day of admission, although with a stable blood pressure, the patient maintained daily fever spikes, with a slight downfall in the APP. A surgical consult was requested and a subsequent Abdomen CT scan revealed pneumatosis and pneumoperitoneum. A laparotomy with subtotal colectomy and terminal ileostomy was performed, due to multiple colonic perforations. The patient was admitted in the ICU unit for post-operative care but developed multiple organ failure, passing away a few hours after her admission.

Discussion

The previous case reminds us the necessity of a timely diagnosis in IM, difficult in face of unspecific semiology which warrants an increased clinical suspicion. Only a diligent approach with early surgical intervention can be expected to improve prognosis and reduce mortality.

#518 - Medical Image

A RARE CAUSE OF SUBCAPSULAR HEMATOMA

Catarina Sofia Martins Nóbrega, Carolina Aguiar, Ana Marta Mota, Sofia Escórcio, José Júlio Nóbrega
Hospital Central do Funchal, Funchal, Portugal

Clinical summary

A 57-year old male with a past history of elevated BP was admitted in the resuscitation room after cardiac arrest following acute myocardial infarction. Subsequently, an angioplasty of the proximal anterior descending coronary artery was immediately performed. On the 2nd day of admission, the patient developed sudden epigastric pain with a fall in haemoglobin from 14.0 g/dL to 9.0 g/dL and increased transaminases although with decreasing values of the cardiac markers. An abdominal CT scan exposed

a large hepatic subcapsular hematoma (red dashed line in the images). Its origin was associated with a costal arch fracture. The trauma, coupled with abciximab therapy and the double antiaggregation, caused this rare complication. He doesn't need invasive procedures, with the hematoma absorbing.

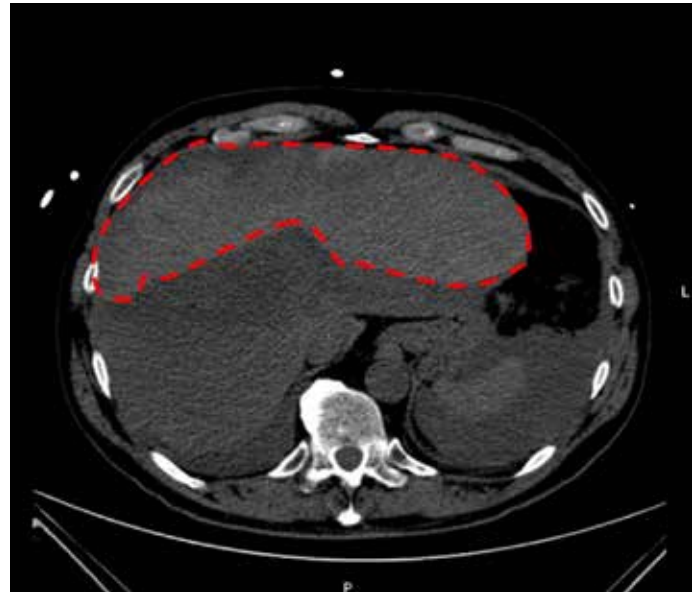


Figure #518. Abdominal CT scan with large hepatic subcapsular hematoma.

#528 - Abstract

PATIENTS WITH ACUTE CORONARY SYNDROME AND CONDUCTION DISTURBANCES IN REAL-LIFE CLINICAL PRACTICE

Yulia Venevtseva, Aleksandr Balko

Medical Institution of Tula State University, Tula, Russia

Background

Recent studies have shown that patients with bundle branch block (BBB) have worst outcome after an acute coronary syndrome (ACS), particularly with right BBB. Six comorbidities were predictive for risk stratification in elderly non-ST-segment elevation ACS patients: renal failure, anemia, diabetes, peripheral artery disease, cerebrovascular disease and chronic lung disease. The aim of the study was to determine clinical and functional characteristics in non-ST-segment elevation ACS patients with conduction disturbances.

Methods

From 188 consecutive patients admitted to the intensive care unit of cardiology department in Tula Emergency Hospital in autumn 2018 with nonfatal non-ST-segment elevation ACS, 50 patients (71.4±1.6 yrs) were selected: 19 patients (14 females (F) with left BBB, 18 (6 F) with right BBB and 13 (9 F) with I grade atrioventricular (AV) block.

Results

93% patients of all groups had history of hypertension; 42% of patients with left BBB, 27.8% of those with right BBB and 46.2% of AV-block - history of type II diabetes mellitus; 36.8; 27.8 and 38.5% of patients - renal disease. 33.3% of patients with right BBB had COPD.

Patients with left BBB were slightly older than those with right BBB and AV-block (74.2±2.4; 68.1±3.2 and 72.8±2.3 yrs; p=0.07). Body mass index in patients with right BBB was bigger than in patients with left BBB (31.4±1.3 vs 28.6 kg/m²; p=0.046). Patients with left BBB had more often pressing pain, patients with right BBB - chest pain and those with AV-block - burning pain. Permanent atrial fibrillation was more often seen in patients with right BBB (33.3%) whereas paroxysmal atrial fibrillation - in those with left BBB (36.8%).

Patients with left BBB demonstrated higher level of blood creatinine than patients with right BBB (132.8±14.0 vs 98.4±6.1 µmol/L; p=0.017) and lower thrombocytes count compared to patients having AV-block (155.9±12.3 vs 219.2±23.1 × 10⁹ /L). Patients with AV-block had more often digestive pathology (69% - cholecystitis, 31% - gastritis), lower hemoglobin level (119.8±15.4 g/l) and bigger left atrium size (44.4±4.4 mm). Lower left ventricular contractility (EF=56.4±2.9%) may be due to previous cardiac events: 38.5% of patients were suffered an AMI.

Conclusion

Patients with conduction abnormalities and clinical presentation of acute coronary syndrome have some clinical and functional features required more attention from the attending physician.

#574 - Case Report

ST-ELEVATION MYOCARDIAL INFARCTION (MI) IN A MAN WITH TRANSIENT ISCHEMIC ATTACK (TIA)

Catarina Vilaça Pereira, Fernando Nogueira, José Cunha Marques, Diana Ferrão, Pedro Ribeirinho Soares, Jorge Almeida
Centro Hospitalar São João, Porto, Portugal

Introduction

The speciality of Internal Medicine is characterized by the challenge that the diagnostic approach constitutes, in a multi-systemic approach, as the pathologies that concern the specialty so require.

Case description

We present the case of a 67-year-old man, a history of hypertension, obesity, type 2 diabetes mellitus and active smoker. One day, he uses the Emergency Department (ED) for complaints of hypersudoresis, decreased sensation in the left upper limb, dysarthria and deviation of the labial commissure, lasting 2-3 minutes. In the ED without other complaints, namely chest pain, dyspnea, asthenia or syncope. Physical examination was hemodynamically stable and normal neurological examination.

The transient ischemic attack (TIA) hypothesis was applied and a study was requested in this context (cerebral computerized axial tomography (CT), electrocardiogram (ECG), analytical study and chest X-ray). In this follow-up, ECG is performed with evidence of sinus rhythm and ST segment elevation in the leads corresponding to the inferior wall, with q waves. The patient is transferred to the emergency room for monitoring and is evaluated by cardiology, performing an echocardiogram that demonstrates "inferior-posterior acinesia with cicatricial aspect and lateral apical acinesia, moderate left ventricular dysfunction and preserved right ventricular systolic function." The CT reveals "carotid vascular degenerative pathology, mild cortical atrophy, however without recent vascular lesions". Analytically necrose markers with troponin I high sensitivity in ascending profile (763,6 -> 1680.1 -> 37360.8 ng/L). Given the clinical stability (sustained non-existence of chest pain or anginal equivalents), hemodynamics and electrocardiographic changes do not allow to accurately estimate the evolution time, it is understood that there are no criteria for the performance of emergent catheterization, performed on the day after admission.

Discussion

The present clinical case intends to alert to the importance of an exhaustive clinical history and a complete physical examination. However, and even in the absence of suggestive clinical history and objective examination, it culminated in the diagnosis of infarction in an asymptomatic patient from the cardiac point of view from admission to the hospital and that, during the etiological study of a cerebral vascular event is raised the hypothesis of acute myocardial infarction (later confirmed by enzymatic elevation).

#673 - Case Report

PNEUMOCYSTIS JIROVECII PNEUMONIA CASE IN A NON-HIV

Maria João Castro¹, Sara Raimundo², Márcia Souto², Andreia Rocha Costa², Anusca Paixão², Ricardo Amaral², Andreia Rei³, Ana Paula Dias², Francisco Esteves²

¹ ULSNE, Bragança, Portugal

² CHTMAD, Vila Real, Portugal

³ HESE, Évora, Portugal

Introduction

Pneumocystis Jirovecii Pneumonia (PJP) is a fungal infection that most commonly affects the immunocompromised and can be life-threatening. In general, patients at risk are those with any underlying disease states that alter host immunity such as those with cancer, the HIV, transplant recipients, or those taking immunosuppressive therapies and medications. Patients may show signs of fever, cough, dyspnea, and, in severe cases, respiratory failure.

Case description

We describe the case of a seventy-three, caucasian man with

history of Evan's Syndrome, taking a low dose of prednisolone (2.5 mg 3 times per week for 3 years). He was admitted at the Emergency department with fever, severe dyspnoea and bad general condition. He was febrile at 39.3°C, tachycardic at 95 bpm, tachypneic at 30 bpm and mean arterial pressure 55 mmHg. He had bilateral fine crackles on pulmonary examination. He presented with metabolic acidosis and severe hypoxemia, HIV test was negative. The chest radiograph revealed diffuse bilateral perihilar interstitial infiltrates. Computed tomography scan revealed "Extensive confluent densities in both lungs, demonstrating diffuse reticulodular pattern interstitial thickening."

Therefore, he was admitted in Intensive Care Unit (ICU) with de diagnostic of septic Shock owing to pneumonia and started on empiric antibiotic, endotracheal intubation was performed and vasopressor support was initiated after fluid challenge. Bronchoscopy was performed and bronchoalveolar lavage (BAL) revealed the presence of PJ. The antibiotherapy was changed to Trimethoprim-Sulfamethoxazole 1920 mg EV 6/6h per 14 days. The antibiotics were converted to oral dosing and he required decreasing amounts of oxygen. He spent a total of 10 days in the ICU and after gradual return to his baseline level of respiratory function; he was discharged on hospital day 18.

Discussion

This case reflects the importance of personal history in patient evaluation. It is crucial to identify immunosuppressed individuals at risk for developing PJP because several studies have shown that the morbidity and mortality in non-HIV patients is significantly worse than in patients with HIV. In this case PJP was suspected at the second day in the ICU because his clinical presentation and image pattern. Fortunately PJ was isolated earlier which allowed to initiate the adequate therapy. This case serves as an important reminder about how to approach similar patients.

#705 - Abstract

A "BRAIN COMPUTER INTERFACE" ON EEG SIGNAL FOR IMPROVING THE EMERGENCY DIAGNOSTIC PROCEDURE OF ACUTE ISCHEMIC STROKE.

Nicolò Casano¹, Giuseppe Placidi², Matteo Polsinelli², Carmine Marin³, Clara Balsano¹

¹ School of Emergency and Urgency Medicine, Department of Clinical Medicine, Life, Health & Environmental Sciences-MESVA, University of L'Aquila, L'Aquila, Italy

² University of L'Aquila, Computer Science laboratory, Department of Clinical Medicine, Life, Health & Environmental Sciences-MESVA, L'Aquila, Italy

³ University of L'Aquila, Stroke Unit, San Salvatore Hospital, L'Aquila, Italy

Background

Acute ischemic stroke is a time dependent disease, since the likelihood of a positive outcome of reperfusion therapies relies upon a timely intervention. Unfortunately, only a few patients are

eligible to be treated due to delays in the management of patients. In order to reduce the time door to needle or time door to decision, many efforts were done to develop new strategies in the pre-hospital management of acute ischemic stroke patients. Even if EEG, being associated with the cerebral blood flow, could be a reliable diagnostic tool in the differential diagnosis of ischemic, so far, there are few evidences on its application in emergency. Our purpose is to evaluate the effectiveness and reliability of EEG in early diagnosis of acute ischemic stroke. To this aim we started to validate the measurement of a "Brain Computer Interface" EEG in acute ischemic stroke patients, hospitalized in Stroke Unit.

Methods

We evaluated 10 ischemic stroke patients admitted to the Stroke Unit of San Salvatore Hospital in L'Aquila. The EEG measurements were performed with a Brain Computer Interface, Enobio 8 5G, a wireless electrophysiology sensor system for EEG recording.

Results

The EEG measurements were performed in the Stroke Unit, within 10 hours from symptoms, onset and after accomplishing the therapeutic procedures. The track recordings collected gave promising results on the possible use of this device to improve and to ease the diagnostic procedure of acute ischemic stroke.

Conclusion

In our opinion this device could be a valiant tool to support healthcare personnel in make the decision to activate the stroke code. Other studies need to be done to validate the EEG measurements during the transport of patients in the medical ambulance.

#714 - Abstract

"VIA VERDE CORONÁRIA" – A FAST APPROACH PROTOCOL FOR CHEST PAIN PATIENTS: WHAT HAVE WE LEARNED IN THE LAST 6 MONTHS?

Joana C F Lima¹, João Aguiar², Margarida Paixão Ferreira¹, Rita Calixto¹, Vera Cesário¹, José Vaz¹

¹ Hospital José Joaquim Fernandes, Beja, Portugal

² Instituto de Investigação do Medicamento (iMED.Ulisboa), Faculdade de Farmácia, Universidade de Lisboa, Lisboa, Portugal

Background

Coronary disease is one of the leading causes of death in Portugal and myocardial infarction accounts for 80% of all cardiovascular deaths. "Via Verde Coronária" (VVC), a fast approach protocol was developed few years ago to decrease the time between the first medical contact and the effective treatment. Our aim was to characterize the main diagnoses detected in VVC patients.

Methods

A cross-sectional study was undertaken in a Beja's hospital in the last 6 months. Upon admission, patients (aged 18 or older) were

included in the VVC if they presented an oppressive precordial pain that may irradiate to the left arm or neck, and may be associated with sweating, nausea and/or epigastric pain. Data was extracted from medical charts. Data analysis was performed using uni- and bivariate statistics (IBM SPSS v.20.0).

Results

A total of 181 patients were included (44% (n=79) female; mean age of 63.4±14.4 years old). The majority of diagnoses were from the circulatory system (64%, n=115), followed by musculoskeletal (19%, n=35), mental and behavioural disorders (12%, n=21), and other systems (6%, n=10). Anxiety and musculoskeletal pain were the non-cardiac causes most frequently identified. Uncontrolled hypertension was the leading cardiac cause apart from acute myocardial infarction (AMI), which accounts for 25% of the sample (73% NSTEMI vs 27% STEMI). There were no differences in time of symptom onset of patients with and without AMI (p=0.815). Obesity (aOR=3.64; 95%CI 1.43-9.27), smoking (aOR=1.82; 95%CI 0.77-4.30), hypertension (aOR=1.65; 95%CI 0.65-4.19), and type 2 diabetes mellitus (aOR=1.50; 95%CI 0.62-3.62) were possible risk factors for AMI, when compared with non-AMI; however, apart from obesity, there was no statistical significance on the other associations. In the AMI group, there may be no differences between the number of risk factors in patients with NSTEMI and STEMI (1.66±0.98 vs 1.69±1.02 risk factors per patient, respectively). The mean difference between maximum and at admission troponin I was 11.19±16.43 ng/ml. According to the Killip-Kimball classification, the majority of NSTEMI and STEMI were class I (88%, n=29; 92%, n=11, respectively). Only one of the two patients with class IV have died.

Conclusion

Data suggest that only 25% of all VVC cases were AMI. This finding corroborate that chest pain may not be sensitive enough to firstly include patients in VVC at admission. New screening technologies could be used to help triage patients with chest pain.

#756 - Medical Image

SUPERIOR VENA CAVA SYNDROME

Cátia Pereira, Joana Paixão, Sandra Santos, Joana Costa, Amílcar Silva

Centro Hospitalar Universitário de Coimbra, Coimbra, Portugal

Clinical summary

The superior vena cava syndrome (SVC) is characterized by a group of signs and symptoms caused by obstruction of the blood flow of SVC. Obstruction may be caused by extrinsic compression associated with malignancy. Treatment includes endoluminal stents, surgery, chemotherapy or radiation therapy. The image shows a 58-year-old woman who was admitted with facial and cervical oedema, flushing and thoracic collateral circulation with 3 weeks of evolution. History of Graves' disease. Smoker. Chest X-ray with one lesion superimposed on the projection of the clavicle. Computed tomography of the chest with a nodule of

41x22 mm in the right upper lobe. Evaluated by the interventional radiology that performed dilation of the filiform stenosis. Cytology compatible with pulmonary carcinoma metastasis.

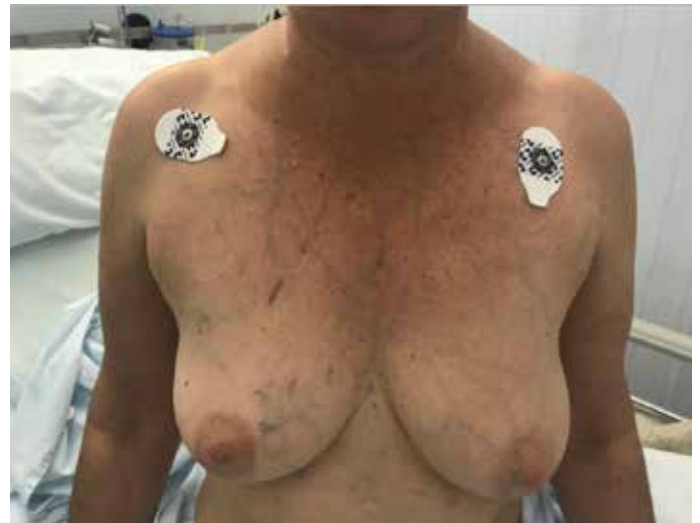

Figure #756. Obstruction of blood flow through the superior vena cava.

#768 - Case Report

SEVERE PAIN AFTER NSAID INGESTION – AN UNCOMMON PRESENTATION OF ANAPHYLAXIS.

Yuhei Mogi, Ivor Cammack

Teine Keijinkai Hospital, Sapporo, Japan

Introduction

Anaphylaxis commonly causes hypotension, rash, dyspnea and gastrointestinal symptoms. Crampy abdominal pain is common, but pain elsewhere is rare. We describe a patient who presented with lower back and bilateral leg pain 10 minutes after taking an over-the-counter NSAID.

Case description

A 62-year-old Japanese male presented to ER with back and leg pain and mild dyspnea. His symptoms began when he went to toilet, 10 minutes after ingesting Beneslon, a combination containing aspirin and hydrotalcite, an antacid.

Several years ago, he developed anaphylaxis to CT contrast dye which presented as severe generalized pain and dyspnea. He was otherwise in good health.

On examination, his blood pressure was 105/77 mmHg, heart rate 52 bpm, respiratory rate 28/min, SpO₂ 98% (Room Air), temperature 36.6°. There was no rash or perioral swelling. Cardiorespiratory exam was normal.

We diagnosed anaphylaxis based on the sudden onset of hypotension to 70% of his usual blood pressure and respiratory tract symptoms soon after ingestion of a new medication. He was treated with 0.3 mg intramuscular adrenaline, rapid intravenous fluid resuscitation, 5 mg chlorpheniramine maleate. His symptoms including the pain resolved within 10 minutes.

Discussion

In the literature, lower back pain in anaphylaxis has been reported as uterine cramping in women, but we couldn't find any published reports of this symptom in a male population.

During anaphylactic reactions, histamine release contracts smooth muscle.

Lower back pain is caused by contraction of ovary, which has been reported as a symptom of anaphylaxis in woman. Contraction of bladder and urethral smooth muscle are also known to cause lower back pain. Therefore, the pain in this case may be due to contraction of bladder smooth muscle.

This case highlights that lower back pain can be a symptom of anaphylaxis.

#798 - Abstract

ACUTE PANCREATITIS IN AN INTERMEDIATE CARE UNIT

Margarida Rodrigues Fonseca, Mariana Constante, Rita Ivo, Pedro Ribeiro Dos Santos, João Lopes Delgado, Isabel Madruga
Centro Hospitalar de Lisboa Ocidental, Lisboa, Portugal

Background

Acute pancreatitis (AP) is a potentially life-threatening disease with a wide spectrum of severity. Though most cases of AP are mild, the challenge remains in identifying and managing the severe cases and the associated complications. The present review aims to characterize all patients with AP admitted to an Intermediate Care Unit (IntCU).

Methods

Retrospective analysis of data concerning patients admitted to IntCU with the diagnosis of Acute Pancreatitis in 2017 and 2018 – demographic characteristics and clinical severity.

Results

Thirteen patients were admitted (5 in 2018 and 8 in 2017). One patient was excluded due to administrative reasons. Six were male and the median age was 57 years (24–81 years). Most patients (67%) were admitted from the Emergency Room. Two patients (17%) were transferred to the Intensive Care Unit. The median duration of stay was 5.5 days (0–13 days). Gallstones were identified in five patients. Nine patients had CT evaluation which revealed pancreatic necrosis in two. The initial APACHE II score was 9 (0–21) and the initial SAPS 2 score was 19 (6–46). The Ranson score at diagnosis was 1.6 (0–3) and the cumulative was 2.5 (0–4). The patients with APACHE II score higher than 10 (33%) had more acute renal injury and higher lipase at admission. Two of these patients needed vasopressor support due to haemodynamic instability.

Conclusion

Risk stratification plays a key role in identifying the best suitable candidates for IntCU admission in order to provide the best

management of complications. Acute renal injury and higher lipase at admission seem to be related with APACHE II scores higher than 10, and therefore with predicted mortality of more than 10%.

#918 - Case Report

MYOCARDIAL INFARCTION: THE CULPRIT IS NOT ALWAYS A CORONARY ARTERY

Ana Neto¹, Daniel Seabra¹, Diana Pissarra², Inês Oliveira¹, Mário Jorge Amorim², Aurora Andrade¹, Paula Pinto¹

¹ Tâmega e Sousa Hospital Center, Penafiel, Portugal

² São João Hospital Center, Porto, Portugal

Introduction

Embolic myocardial infarction (MI) is an uncommon complication of infective endocarditis (IE); diagnosing this complication requires high suspicion.

Case description

72-year-old obese male, with hypertension, dyslipidaemia and moderate aortic stenosis, presented at the emergency room with dyspnoea at rest after acute-onset chest pain during the night. He had weight loss history, night sweats and progressive shortness of breath in the past 3 weeks. On examination, he had respiratory distress and desaturation (90% with FiO₂ 60%), tachycardic but normotensive, no fever; bilateral pulmonary rales and no cardiac murmurs. Electrocardiogram (ECG) showed R wave poor progression in anterior leads, evolving with anterior QS waves and mild ST-T elevation. Laboratory data: mild anaemia, leucocytosis, mild C-reactive protein rise and elevated troponin I. Bedside echocardiography showed severe depression of left ventricular function with interventricular septum and anterolateral wall hypokinesia, moderate aortic stenosis, moderate to severe aortic regurgitation and an apparently flail valve with an hyperechogenic mass attached.

He was intubated in order to perform emergent cardiac catheterization that showed no significant coronary artery disease and a severe aortic regurgitation with no aortic dissection. Subsequent transoesophageal echocardiography confirmed severe regurgitation and a mobile image suggestive of vegetation (larger diameter ~3 cm), apparently attached to the 3 cusps of the aortic valve, conditioning dynamic obstruction of LV outflow tract. Thickening of the mitroaortic curtain suggestive of periaortic abscess was stated. He was transferred to cardiothoracic surgery referral centre and submitted to aortic valve replacement and abscess exclusion with pericardial patch. All sets of blood cultures and bacteriological examination of the valve were negative. Initial post-operative period was uneventful. Unfavourable clinical course with cardiac tamponade 10 days after with surgical reintervention, multiorgan dysfunction and death.

Discussion

IE can be associated with embolic phenomena carrying a high risk of morbimortality. Intracoronary septic embolization resulting in

MI is an uncommon complication of IE. Although no angiographic evidence of coronary emboli in our case, the probability of a MI secondary to coronary embolization is supported by the clinical presentation of chest pain, ECG findings and a significant rise in troponin. Management of MI in this setting remains controversial.

#929 - Medical Image

BILATERAL PNEUMOTHORAX AND PAZOPANIB

Marta Dalila Martins, André Paupério, Lindora Pires, Sofia Garcês Soares, Inês Ferreira, Mari Mesquita

Centro Hospitalar Tâmega e Sousa, Penafiel, Portugal

Clinical summary

A 77 year old man diagnosed with synovial sarcoma with pulmonary metastasis, presented to the emergency department with worsening dyspnea in the prior week. Examination revealed respiratory distress, high blood pressure (BP: 219/119 mmHg) and hypoxia (1). Pulmonary auscultation with prolonged expiratory time and scattered rhonchi and wheezing. Chest x-ray showed a bilateral pneumothorax (panel A), confirmed with computed tomography (panel B). The last exam displayed a pleural effusion on the left side (panel B). Two thoracic drains were placed with subsequent improvement of the dyspnea. The patient was being treated with pazopanib, which is described to be associated with pneumothorax in a small percentage of patients.

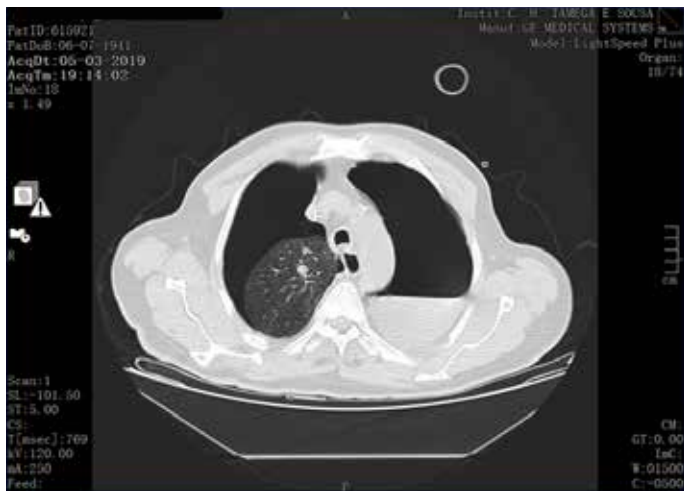

Figure #929.

#930 - Medical Image

BILATERAL OBSTRUCTIVE UROLITHIASIS - AN UNUSUAL AND CHALLENGING DIAGNOSIS IN THE ACUTE SETTING

Inês Albuquerque, Jorge Almeida

Centro Hospitalar de São João, Porto, Portugal

Clinical summary

A 57-year-old woman presented to the emergency room

complaining of hematuria and dysuria for four days. Two days earlier bilateral lumbar pain radiating to the lower abdominal quadrants and anuria settled. She was febrile, hypotensive and with a compensated metabolic acidosis. After correct placement of a urinary catheter, there was no urine output. Initial work-up showed acute kidney injury, leukocytosis and elevated C-reactive protein. Pancreatic enzymes were normal. We requested a contrast computed tomography of the abdomen, which confirmed the clinical suspicion of bilateral obstructive urolithiasis with massive hydronephrosis and markedly distorted kidneys. Emergency kidney stone removal surgery was performed.

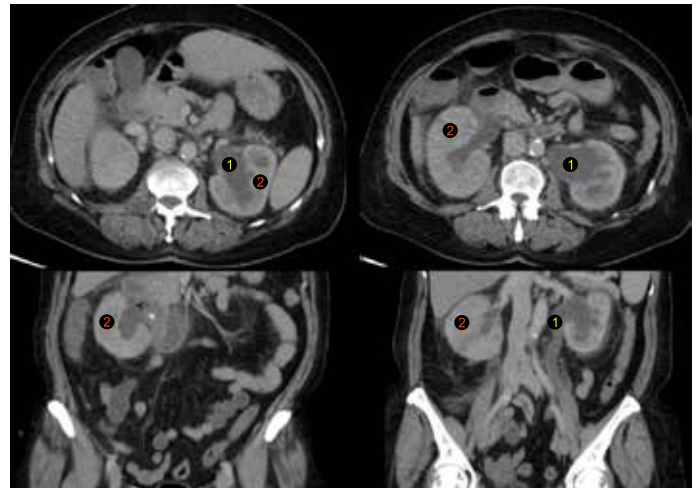


Figure #930. Contrast-enhanced computed tomography of the abdomen. Axial and coronal images showing (1) hydronephrosis and (2) distorted kidneys.

#932 - Case Report

AN INTERESTING CASE OF NON - CARDIOGENIC PULMONARY EDEMA DUE TO DELIBERATE CALCIUM CHANNEL BLOCKER OVERDOSE

Sofia Avgeri, Evaggelia Sergi, Aggeliki Tsifi, Stela Stefanova, Apostolos Voulgaridis, Maria Katsiari

Konstantopouleion - Patision General Hospital Of Nea Ionia, Athens, Greece

Introduction

Calcium channel blockers (CCBs) are widely used anti-hypertensive and anti-arrhythmic pharmaceutical agents, divided in two categories: dihydropyridines (such as amlodipine, nifedipine and felodipine) and non-dihydropyridines (verapamil and diltiazem). Overdose of these drugs can cause severe cardiovascular collapse and the potential complications include hyperglycemia, bowel ischemia and non-cardiogenic pulmonary edema.

Case description

We, hereby, present the case of a 58-year-old woman with a history of thyroid disease and obesity, who deliberately consumed 28 tablets (sustained release) of nifedipine 20 mg and 20 tablets

(sustained release) of verapamil 240 mg with suicidal intent. When she arrived in the emergency department she had a 9/15 in the Glasgow Coma Scale, hemodynamic instability, hypoxemia and hyperglycemia. She received gastric decontamination through a Levin tube and activated carbon was administered. She was also supported with oxygen, vasoconstrictive agents, insulin, iv Calcium gluconate and iv crystalloid fluids. Due to the consequent deterioration, presenting with lactic acidosis and respiratory failure, she was intubated and transferred to our Intensive Care Unit (ICU). Her X-rays revealed images compatible with Acute Respiratory Distress Syndrome (ARDS) and she was treated with high Positive End Expiratory Pressure (PEEP) mechanical ventilation. During this hospitalization, she suffered from fever due to central line infection which was treated with antibiotic agents. After being hemodynamically stabilized, iv furosemide was administered in order to maintain negative fluid balance. She gradually improved and she was extubated and monitored during spontaneous breathing. She was released from ICU after 15 days and she returned stable to the initial hospital ward.

Discussion

The mechanism of non-cardiogenic pulmonary edema in patients with CCB overdose is not exactly clarified. It is possible that selective precapillary vasodilatation leads to pulmonary capillary transudation causing an increase in transcapillary hydrostatic pressure and interstitial edema. Hyperglycemia – possibly due to decreased insulin release from the pancreatic cell, but also decreased insulin sensitivity and glucose uptake from the tissues, must also be treated. Cardiovascular complications – such as hypotension and reflex tachycardia – must be restored so as to maintain adequate circulation and breathing and oxygenation are of critical significance to be supported.

#955 - Case Report

DROWNING: PROMPT HIGH FLOW OXYGEN, PEEP AND HYPOTHERMIA - FOR A BETTER OUTCOME

Dulce Rita Correia, Carolina Alves Rodrigues, Catarina M Salgado, Manuel Morais, António Pais-De-Lacerda, Marco Ribeiro Narciso CHULN, Lisboa, Portugal

Introduction

Drowning is a serious public health problem with more than 500,000 deaths/year worldwide. Moreover around one-third of the survivors have severe neurological sequelae. Optimal pre-hospital and hospital care with rapid correction of hypoxemia and acidosis is determinant for a better outcome.

Case description

A 70-years-old housewife, with hypertension, dyslipidaemia and depression attempted suicide by drowning. The on-site emergency team (unconscious victim found in the irrigation tank) verified asystole in ECG monitoring, and started CPR

manoeuvres (adrenalin 1mg IV Q 3min X2, 200J shock for ventricular fibrillation), and performed orotracheal intubation. At hospital A&E admission (1h later) with Glasgow Coma Score (GCS) 3, non-dilated pupils but without corneal reflexes, she was hypertensive (158/115 mmHg) with tachycardia (123 pm), hypothermic (34.1°C) and hypoxemic - SpO₂ 93% (high flow mask FiO₂ = 80% with 15L O₂ p/M), with severe lactic acidosis (101 mmol/L). New onset atrial fibrillation developed. Chest x-ray revealed bilateral diffuse interstitial infiltrates, and brain CT-scan showed discrete decreased cortical gray matter attenuation with a loss of normal gray-white differentiation, bilateral basal ganglia attenuation and diffuse oedema with effacement of the CSF-containing spaces. With the resolution of acidosis, GCS increased to 6 with eye opening to pain, and present corneal reflexes. She was then admitted to the Intensive Care Unit (ICU) and remained mechanically ventilated (controlled mode) for 24h with Fi O₂ 80% and positive end-expiratory pressure (PEEP)=12cm H₂O. Targeted temperature between 34°C and 36°C was maintained for the first 3 days. Fiberoptic bronchoscopy revealed mucosal oedema; microbiological investigation was negative. Multiple bilateral, asymmetric patchy small nodular and reticulo-nodular opacities involving predominantly the lung bases, with bilateral pleural effusions were treated empirically for 7 days with Amoxicillin/clavulanic acid. Progressive neurological improvement (GCS 6->12) enabled her to be weaned from mechanical ventilation on day2 of ICU, and to be transferred to hospital ward (day3). She was discharged at day 15, without any neurological sequel, GCS 15.

Discussion

Rapid pre-hospital cares, and the prompt and effective correction of hypoxemia and acidosis, maintaining hypothermia for at least the initial 24 hours, are all essential measures to achieve a good prognosis in drowning.

#970 - Abstract

ARE D-DIMER DOSING BEING WELL PERFORMED FOR VENOUS THROMBOEMBOLISM DIAGNOSIS IN OUR EMERGENCY DEPARTMENT?

Bárbara Soeiro, Helena Greenfield, Carolina Guedes, Sílvia Sousa Hospital Pedro Hispano, ULSM, Matosinhos, Portugal

Background

Venous thromboembolism (VTE) refers to Deep vein thrombosis (DVT) and Pulmonary embolism (PE). Currently, there are 2 validated scores for pre-test probability of PE: Wells score and revised Geneva score, and 1 for DVT: two-level wells score.

D-dimer test has sensitivity of over 95% and high negative predictive value for the diagnosis of VTE. On the other hand, the specificity has lower values, and falsely positive results can be observed in cases of active infection, neoplasms and necrosis.

Our goal was to analyse every Emergency Department episode

in which d-dimer dosing was performed. The variables analysed were: presence or absence of clinical symptoms suggestive of VTE, the suitability of d-dimer request according to pre-test probability scores, performance of CT angiography if d-dimer elevation and number of confirmed VTE.

Methods

We performed a retrospectively analysis of all cases of patients over 18 years of age in whom D-Dimers test was performed in our Emergency Department from the 1st of July to the 31st of December of 2017.

Results

589 episodes were included in our analysis (565 patients). There was a light predominance of female gender, representing 61% (n=361). The median age was 62±19 years-old, minimum of 19 and maximum of 98.

The commonest presenting symptoms were dyspnea (29%, n=168), chest pain (28%, n=162), unilateral lower limb pain (14%, n=83) and syncope (13%, n=78). In 28% (n=165) no suggestive symptoms or signs were identified. The pre-test probability was calculated for each episode: for Wells Score, low level in 75% (n=441), intermediate level in 24% (n=144) and high level in 1% (n=4) with 6, 20 and 1 cases of confirmed VTE, respectively; for Revised Geneva Score, low level in 61% (n=361), intermediate level in 36% (n=214) and high level in 2% (n=3), with 4, 20 and 3 cases of confirmed VTE, respectively. For Two-Level Wells score, likely in 11% (n=62) and unlikely in 89% (n=527), with 12 and 3 cases of confirmed DVT.

D-dimers were elevated in 55,5% of all episodes (n=327). In only 27,8% (n=91) of these angio-TC was performed. VTE was confirmed in 4,6% (n=27) of all episodes, 2% (n=12) of PE and 2% (n=12) of DVT and overlap in 3 cases.

Conclusion

This analysis shows a substantial d-dimer dosing in patients without clinical likelihood and low-level pre-test probability. Consequently, a significant number of false positives were obtained. We intend to establish a VTE diagnosis protocol in our Emergency Department and reevaluate these results.

#983 - Case Report

ACUTE EOSINOPHILIC PNEUMONIA REQUIRING EXTRACORPOREAL MEMBRANE OXYGENATION

Verónica Botelho Guiomar, Carla Basílio, Nuno Príncipe, Roberto Jr Roncon-Albuquerque, Teresa Honrado
Centro Hospitalar e Universitário de São João, Porto, Portugal

Introduction

Acute eosinophilic pneumonia is a rare cause of hypoxemic respiratory failure that if not rapidly recognized can progress to refractory respiratory failure. The first case published of acute eosinophilic

pneumonia requiring Extracorporeal Membrane Oxygenation was in 2010 and there were only six cases described in the literature.

Case description

Case 1

An 18-years-old female was admitted in the emergency. Nine days before, she started with productive cough, fever and odynophagia that persisted despite 8 days of clarithromycin. On admission, she was febrile, tachypneic, with diffuse crackles on respiratory auscultation and hypoxemic respiratory failure. Blood tests showed elevated white cell count and chest X-Ray showed bilateral consolidation in inferior lobes. A diagnosis of community-acquired pneumonia was made and it was started an antibiotic. She was admitted in the Intensive Care Unit as she didn't present any signs of good evolution, extracorporeal membrane oxygenation was performed. We documented peripheral eosinophilia and bronchoalveolar lavage revealed eosinophilic alveolitis. The patient started glucocorticoids and she was successfully decannulated and extubated at day-13. Case II: a 55-years-old female was admitted in the emergency. Fifteen days before hospital admission, she started with productive cough, fever and dyspnoea after exposure to wood and plastic burnings. On admission, she was febrile, tachypneic, diffuse crackles and wheezing on respiratory auscultation and hypoxemic respiratory failure. Blood tests showed elevated white cell count and C-reactive protein. Chest X-ray showed bilateral consolidation. A diagnosis of community-acquired pneumonia was made and the patient started an antibiotic. In the following days, the respiratory failure worsened and the patient was transferred to Intensive Care Unit and in day-4 of admission Extracorporeal Membrane Oxygenation was started and a TAC-guided lung biopsy was made. The biopsy revealed signs of acute fibrinous and organizational pneumonia and eosinophilic infiltration, so the patient started glucocorticoids. She was successfully decannulated and extubated at day-15.

Discussion

The diagnosis of acute eosinophilic pneumonia depends on a high index of clinical suspicion and characteristic findings in bronchoalveolar lavage. Patients usually respond well to glucocorticoids but some require extracorporeal membrane oxygenation to have clinical improvement.

#995 - Abstract

METFORMIN-ASSOCIATED LACTIC ACIDOSIS: ANALYSIS OF 19 YEARS IN AN INTENSIVE CARE UNIT

Ana Pedroso¹, Inês Ferreira¹, Rita Santos¹, Vasco Costa², Carolina Paulino², Bernardino Valério², Luís Coelho², Vítor Mendes², Camila Tapadinhas², Pedro Póvoa²

¹ Internal Medicine Department, Hospital de São Francisco Xavier (CHLO), Lisboa, Portugal

² Polyvalent Intensive Care Unit, Hospital de São Francisco Xavier (CHLO), Lisboa, Portugal

Background

Metformin is the most commonly prescribed oral antihyperglycemic and the first line therapy for newly diagnosed type 2 diabetes. It is contraindicated in patients with renal or hepatic insufficiency, in very elderly patients, and in patients with conditions of circulatory dysfunction such as congestive heart failure, due to increased risk of lactic acidosis. Metformin-associated lactic acidosis (MALA) is an extremely rare condition (≤ 10 events per 100,000 patient-years of exposure) and are associated with mortality rates of 30-50%.

Methods

Retrospective analysis of the patients admitted with MALA in an Intensive Care Unit from 2000 to 2018.

Results

During this period 32 patients were admitted with MALA (age 73.8, 72% feminine, APACHE 30.6, SAPSII 61.8 and mortality in UCI 25%). The admission symptoms were gastrointestinal symptoms $n=23$ (71.9%), neurologic $n=7$ (21.9%) and respiratory $n=2$ (6.3%). Metformin doses were unknown in 6 patients, but 2109mg in average (median 2000mg) and 18 patients (56.3%) medicated also with diuretics and/or anti-hypertension drugs. On admission, every patient presented with acute kidney failure, needing continuous renal replacement technic in 93.8%. 68.8% presented in shock and needing mechanic ventilation 59.4%. The median creatinine at admission was 6.36 mg/dL [4.40-8.03], lactate 13.9 mmol/L [9.70-18.0], pH 6.980 [6.872-7.100] and bicarbonate 5.00 mmol/L [3.50-8.40].

Conclusion

Although metformin is largely used, attending this complication is rare, MALA is often non-recognized or late diagnosed. Patients and families should be aware of alarm symptoms (vomiting and nausea) and precipitant factors that should lead to metformin suspension and quick searching for medical evaluation. Doctors should be more conscious about contraindications and higher doses usage, because this complication is rare, but often fatal, without specific treatment.

#1003 - Medical Image

AN EXTREME ELECTROCARDIOGRAPHIC SINE WAVE PATTERN

Francisca Abecasis, Rita Homem, Mafalda Sequeira, Henrique Santos, Inês Pintassilgo

Hospital Garcia de Orta, Almada, Portugal

Clinical summary

A 57-year old woman with hypertension, chronic heart failure and end-stage renal disease on hemodialysis was admitted after progressive onset of weakness and altered consciousness. Her last dialysis session had been three days before. On examination she revealed slurred speech, generalized weakness and

tachypnea. The electrocardiogram (EKG) showed largely widened QRS complexes merging with T waves in a sine wave pattern (A). Potassium (K^+) measured on a blood gas sampling was 9.2mmol/L, with compensated metabolic acidosis.

Calcium gluconate and K^+ -wasting measures were emergently initiated. After 20 minutes, the only EKG changes were peaked T waves and ST-segment depression (B). Blood gas analysis now showed a K^+ of 7.4mmol/L. Emergent dialysis was started with clinical improvement.

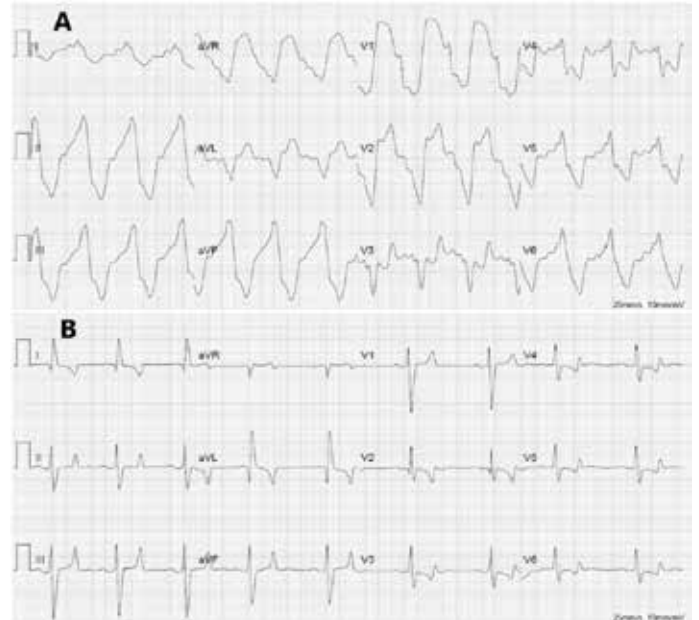


Figure #1003.

#1010 - Medical Image

EXTRAPLEURAL HEMATOMA: A RARE IMAGIOLOGIC FINDING

Carolina Nunes Coelho, Iuliana Cusnir, Diana Vital

Hospital de Santarém, Lisboa, Portugal

Clinical summary

A 74 year old man was admitted in Emergency Department after a fall with thoracic trauma. He was medicated with rivaroxaban. At admission he was clinically stable, normal arterial pressure, normocardic, peripheral saturation 93%, no pain. The chest radiograph showed a opacity in the superior part of right lung (Figure 1). Computed tomography revealed a extrapleural hematoma with 9x6x18 centimetres associated with fractured 4th to 7th costal arches. He was hospitalized, performed a thoracic drainage and then had a cirurgic approach.

Extrapleural hematomas are uncommon, and often associated with blunt chest trauma and rib fractures. Patients with anticoagulation medication has additional bleeding risk. The correct evaluation of initial chest radiograph is mandatory for early recognition.

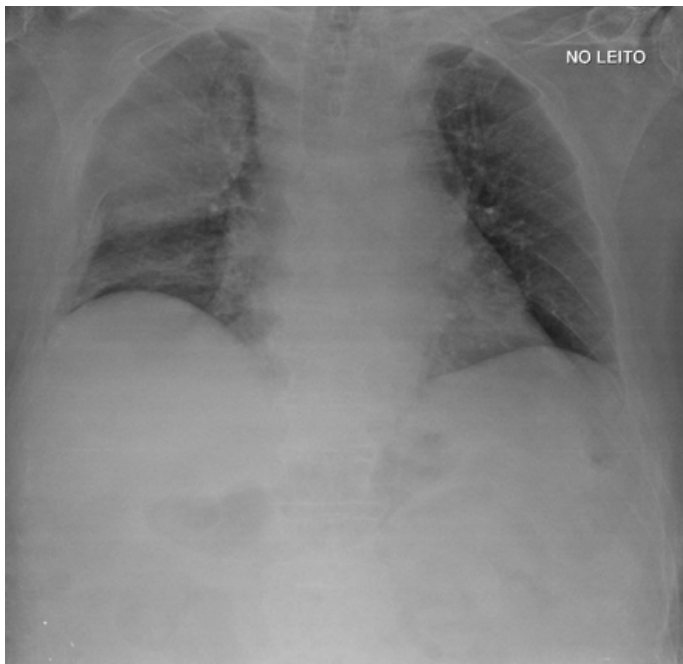

Figure #1010. Chest radiograph with extrapleural hematoma.

#1017 - Abstract

HYPOTHERMY AT THE INTERFACE BETWEEN SPECIALTIES

Nicoleta Dima¹, Elena Rezus¹, Roxana Ganceanu-Rusu¹, Elena-Daniela Onofras², Andreea Clim², Codruta Minerva Badescu¹, Minela Aida Maranduca¹, Ciprian Rezus¹

¹“Grigore T. Popa” University of Medicine and Pharmacy, Iasi, Romania

²“Sf. Spiridon” Clinical Emergency Hospital, Iasi, Romania

Background

Hypothermia is a thermoregulation imbalance characterized by alteration of the thermogenetic and thermolitic processes, with the appearance of a negative caloric balance, with the decrease of the body temperature. Many patients develop acute lower limb ischemia requiring amputation, with important functional and social consequences.

Methods

We conducted a prospective study on 100 patients admitted to hypothermia at the IIIrd Medical Clinic of the “Sf. Spiridon” Clinical Emergency Hospital, Iasi, between 1 January 2016 and 31 December 2018. The analyzed parameters included demographic data, presence of cardiovascular risk factors, clinical symptoms, associated co-morbidities and the impact of medical treatment on disease progression. For batch monitoring, we performed: bioumoral tests, electrocardiogram, ankle-brachial index (ABI) measurement, transthoracic echocardiography and vascular Doppler ultrasound.

Results

In the study group, the predominance of urban, male patients, aged 52-92 years, averaged 71.45 ± 10.15 years. Smoking was

the main cardiovascular risk factor. Associated comorbidities were high blood pressure, diabetes mellitus, dyslipidemia and alcohol consumption. Low adherence to treatment is a negative prognostic factor.

Conclusion

Serious hypothermia negatively influences the vital prognosis by the determined systemic pathophysiological phenomena. The most serious systemic complication of hypothermia is multiple organ failure syndrome. The major objective is to improve the quality of life of the patient by remission or alleviation of the algic syndrome, as well as preserving the viability of the affected member. Patient monitoring is extremely important and involves a multidisciplinary team.

#1031 - Abstract

EPIDEMIOLOGY OF INFECTIONS IN CRITICAL CARE

Pascual Valdez, Melina El Halli Obeid, Carla Huaman, Vanesa Segovia, Jonatan Bornia, Vanesa Vecchio, Soledad Galasso, Paula Ramos, Cintia Simón, María Del Rosario Bruno, Diego Yahni, Leonardo Vasta

Vélez Sarsfield Hospital. Government of the Autonomous City of Buenos Aires. Argentina

Background

Objectives: To determine the number of infectious events, establish mortality and factors associated with it.

Methods

Methods: Prospective, observational, longitudinal, analytical design. We analyzed patients from the ICU of the Velez Sarsfield Hospital in the months of February to July 2015. Sample: consecutive.

Results

Results: 52 cases, 58% males, medium: 61.50 ± 16.50 years, stay 14.00 ± 8.00 days, Apache II: 12.00 ± 4.50 , comorbidities: 2.00 ± 1.00 . Central route (CVC): 75%, median placements: 2.00 ± 1.00 /patient, permanence: 17.00 ± 12.00 days. Bladder catheter (SV): 82.69%, median permanence: 15.50 ± 11.50 days. Mechanical ventilation (VM): 46.15%, median permanence: 17.50 ± 12.50 days. Deceased: 30.76%, almost all linked to infections. Total infectious events: 86, per patient: 1.65. Cultures positivity: 44%-66%. Antibiotic adjustment was required in the first event: 46.66% (31.10% for failure, the rest for desquamation). Most frequent focus: lung (38.82%), second unknown (21.17%). Most common germs: Acinetobacter (21.94%), KPC (18.44%) and MRSA (10.67%). Most used drugs in decreasing order: vancomycin (19.10%), colistin (12.73%), piperacillin tazobactam (10.82%). Predictors of mortality in multivariate analysis: older ($p 0.002$), need adjustment of Atb? ($p 0.06$). Events linked to devices: 60.91 infections every 1000 days. Infection rate every 1000 patients day: 8.43 (CVC),

32.80 (VM) and 19.68 (SV). Infection rate for 1000 days of use: 9.34 (CVC), 56.36 (VM) and 21.78 (SV).

Conclusion

Population of moderate severity and few comorbidities, with 1.65 infectious events per patient, mainly respiratory. Mortality 31%, associated with age and tendency to a greater number of infectious events

#1048 - Case Report

TRANSIENT GLOBAL AMNESIA IN EMERGENCY ROOM: CASE REPORT

Mario Angelo Cenedesi Junior^{1,2}

¹ Sao Paulo University, Ribeirao Preto, Brazil

² Monte Alto Municipal Emergency, Monte Alto, Brazil

Introduction

Transient global amnesia (TGA) is a reversible condition characterized by acute and limited malfunction of episodic declarative memory, with no change in motor, sensory and perceptive function or lowering of consciousness level. Episodes of TGA are the reason for urgent visits, and the diagnoses can be as varied as possible, from strokes to dissociative disorders.

Case description

A 69-year-old woman was taken to the hospital by a family member with memory loss 30 minutes ago during breakfast. She could not remember what she was doing, what day it was-but she remembered the name of her husband and her children, her full name, her birthday, but she could not calculate her age. At physical examination, cooperative, without sensory-motor alterations, but he did not remember recent facts. Deny fever, allergies and traumas. He presented Transient Ischemic Accident episode three years ago, without sequels. Hypertensive and with hypothyroidism, without change of medication in the last months. He did not know where he was (even with the staff repeating), and could not record the doctor's name. Skull tomography performed without changes, as well as electrocardiogram and routine laboratory exams. Patient presented sudden recovery of memory 07h after the onset of the picture, was released (not knowing how she arrived at the hospital). Two days later, he performed brain resonance, which showed no morphological changes or evidence of acute ischemic injury. No residual symptoms or signs were noticed. Patient resumed his social and work activities without loss.

Discussion

The incidence of AGT among the population is 5.2 to 10 per 100,000 people per year, increasing over 50 years. It is a sudden and transient disorder of anterograde memory that usually lasts from four to 6h, and can last for up to 24h, with no alteration of consciousness level, sensory-motor examination, personality or other cognitive alterations. Acts such as writing, directing and looking at hours are preserved, as well as relating to other people

(the patient, despite repetitive questioning, remained cooperative and heeded the examiner's commands). The diagnosis is clinical, and it is necessary to perform imaging tests to rule out other pathologies. There is no consensus in the medical literature regarding the pathophysiology of TGA (the most accepted explanation was secondary to arterial ischemia and history of migraine). The differential diagnosis should include, in addition to transient ischemic attack, intoxication and others.

#1093 - Medical Image

AN UNUSUAL CASE OF ABDOMINAL AORTIC ANEURYSM RUPTURE

Jose Claro Rodriguez¹, Jose Ramon Seco Vasco¹, Juan Francisco Lopez Manchado²

¹ SCCU Sevilla Sur. Servicio Andaluz De Salud, Sevilla, Spain

² Har Moron De La Frontera. Asbg., Moron De La Frontera, Spain

Clinical summary

69 years old male, affected by multiple pathologies, beginning with a mild low back dull ache that stopped with oral intake of acetaminophen. On the next day, patient showed a confusing abdominal condition, with transient episodes of diarrhea and general discomfort, distended abdomen with mild rigidity, dullness, and downward blood pressure. This abdominal CT proved an infrarenal aneurysm, and early bleeding in retroperitoneum. Emergency endovascular surgery followed, with satisfactory results and prognosis.

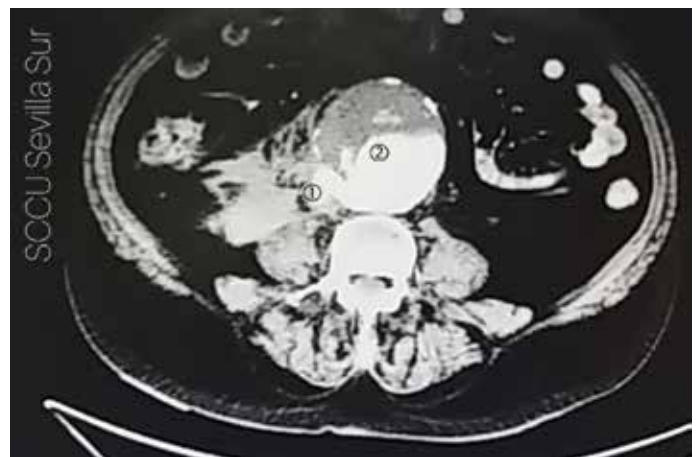

Figure #1093.

#1116 - Case Report

A CASE REPORT ON CAVERNOUS SINUS INFECTIOUS THROMBOPHLEBITIS IN A PATIENT WITH LOCALLY ADVANCED OROPHARYNGEAL CANCER.

Lara Cantero Del Olmo, Marta Del Palacio Tamarit, María José Díez Medrano, Blanca Rodríguez Alonso, Sandra Bello León, María Pavón Moreno

Fundación Jiménez Díaz, Madrid, Spain

Introduction

Septic thrombophlebitis of the cavernous sinus is a rare disease with high mortality rates. Before the availability of antimicrobial agents, mortality was near 100%, but since the onset of the antibiotic era, it has markedly decreased to approximately 20% to 30%.

Case description

A 74-year-old female patient presented to the emergency room with fever and asthenia that had progressed over the last four days, together with redness and swelling of the left eye. Her past medical records were remarkable for a T4aN2cM0 oropharyngeal epidermoid carcinoma that had been treated with palliative chemotherapy with paclitaxel and carboplatin.

On physical examination she had redness and oedema of the left eye, as well as conjunctival hyperemia, with bilateral asymmetrical paresis of extraocular muscles: partial ptosis of the right eye and complete ptosis of the left eye and obvious weakness of right superior rectus and lateral rectus muscle, together with a left "frozen eye", with weakness affecting all muscles.

Blood work showed leucocytosis, with neutrophilia and a high C-reactive protein level of 44 mg/dl (normal limits between 0-0.5 mg/dl).

A non-contrast brain CT scan showed enlargement of the left ophthalmic vein with periocular inflammatory changes as well as a partial filling defect in the left cavernous sinus.

A diagnosis of infectious thrombophlebitis affecting both cavernous sinuses as well as left orbital cellulitis was made.

Empiric antibiotic therapy with vancomycin 1 gr q 12hr, cefepime 1 gr q 8hr, ampicillin 1 gr q 6hr and metronidazole 500 mg q 6hr was started. Enoxaparin was prescribed as well at a dose of 60 mg q 12hr.

The patient was admitted to the Oncology Department.

Hypokalaemia was detected as a secondary effect of chemotherapy, and tubulopathy was diagnosed.

After receiving positive blood cultures for *Streptococcus anginosus*, antimicrobial treatment was adjusted, removing ampicillin from the treatment.

The main complication that arose during hospitalization was dysphagia, with the patient rejecting the option of a nasogastric tube. Finally, she was moved to a palliative care hospital.

Discussion

Nowadays, it is rare to observe the full clinical presentation of cavernous sinus thrombosis.

Oropharyngeal cancer patients are more vulnerable to complicated local infections, particularly after receiving local radiotherapy or cytotoxic chemotherapy.

Ophthalmic symptoms in the setting of fever and headache should always raise suspicion of cavernous sinus involvement.

#1121 - Medical Image

CARRYING THE ANSWER

Marta Fonseca, Mário Ferreira, Zélia Neves, João Machado

Hospital Prof. Doutor Fernando Fonseca, Amadora, Portugal

Clinical summary

50-year-old man, with previous hypertension history without medication, comes to emergency room with acute chest pain. While waiting for observation, the patient had a generalized tonic-clonic seizure. In the resuscitation room he was hypertensive and agitated. No tachycardia was observed. Symptoms were controlled with midazolam and isosorbide dinitrate. The patient suffered a vomit expelling plastic fragments.

Initial laboratory findings showed a total creatinine kinase of 6869 U/L, negative troponin, leucocytosis, urinary cocaine dosing with a maximum of 26,000 mg/dL. The abdomen and pelvic computerized tomography revealed signs of multiple packages along all digestive track.

The patient was submitted to a laparotomy surgery with the removal of 73 cocaine packages.

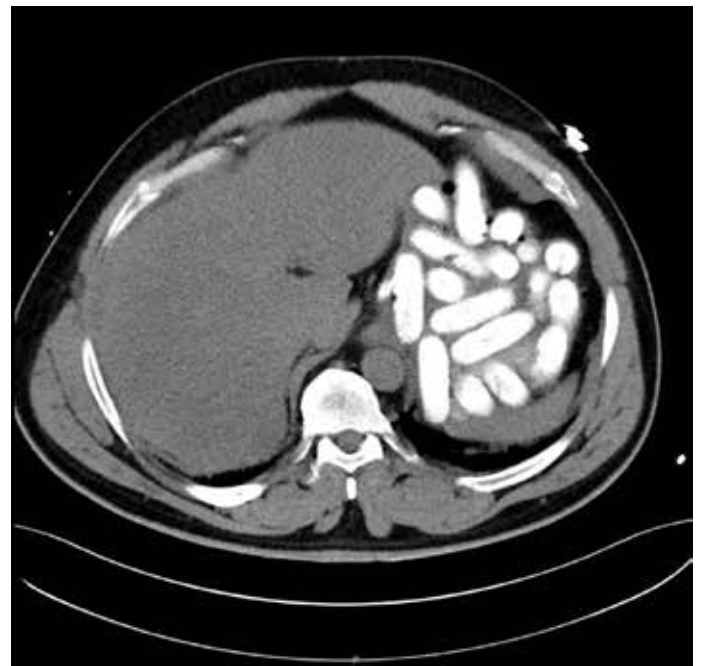

Figure #1121. Abdominal TC scan.

#1192 - Case Report

SUPERIOR VENA CAVA SYNDROME (SVCS): THE IMPORTANCE OF PHYSICAL EXAMINATION

Adriana Girão^{1,2}, Rui Pina^{1,2}, Isabel Fonseca^{3,2}

¹ Centro Hospitalar e Universitário de Coimbra, Serviço de Medicina Interna, Coimbra, Portugal

² Clínica Universitária de Medicina Interna, Faculdade de Medicina da Universidade de Coimbra, Coimbra, Portugal

³ Centro Hospitalar e Universitário de Coimbra, Serviço de Urgência A, Coimbra, Portugal

Introduction

Superior vena cava syndrome has a distinct clinical presentation, can be life threatening and is a rare oncologic emergency. A thorough history and physical examination are critical, focusing on the signs and symptoms of SVCS. Practitioners should specifically assess for dyspnea, upper extremity swelling, nonproductive cough, facial swelling and collateral veins on the neck or upper chest. Family members may note these signs to be more prevalent in the early morning.

Case description

A 65-year-old male was admitted in the emergency room (ER) with a month evolution of dyspnea with slight limitation of physical activity, swelling of the face, mostly around the eyes and in the morning and, non pruriginous purpuric lesions in the face and thorax with progressive worsening. He was previously medicated by his general practitioner with dexamethasone and desloratadin, without any improvement. His past medical history included a bladder carcinoma submitted to a transurethral resection and an 80-pack-year smoking history. As for the physical exam, he presented with edema of the face and neck with central cyanosis, evidence of collateral circulation – thoracic telangiectasis, jugular ingurgitation and digital clubbing. Bloodwork, gasometric analysis and EKG were normal. The X-ray revealed a right para-hilar hypotransparency and due to the raised suspicion of superior vena cava syndrome, a computerized tomography angiography was performed confirming the presence of SVCS by an occlusive mass with at least 7x5x8 cm, suggestive of tumoral invasion (small cell carcinoma of the lung). Interventional radiology decided on stenting the lesion and the patient was admitted to the ward for complementary study. A transthoracic biopsy was performed revealing a neuroendocrine small cell carcinoma and the patient started chemotherapy with Cisplatin and Etoposide. Despite the early diagnosis the patient died 3 months after diagnosis.

Discussion

SVCS is caused by cancer in 95% of the time being the other 5% mostly related to thrombosis from insertion of venous catheters or pacemaker wires. SVCS caused by cancer is a poor prognostic sign that is associated with high mortality.

#1241 - Case Report

DRESS SYNDROME: A RARE CASE BY VANCOMYCIN

Andreia Cinara Branco Diegues, Rita Silva, Elisa Tomé, Eugénia Madureira
ULSNE, Bragança, Portugal

Introduction

Drug rash with eosinophilia and systemic symptoms (DRESS) syndrome is a severe and idiosyncratic drug reaction characterised

by rash, fever, lymphadenopathy and internal organ involvement. The pathogenesis is not fully understood and many drugs have been associated with this disease, like antibiotics but in a rare cases. There are a high risk of morbidity and mortality.

Case description

A 75-year-old female was admitted to the orthopaedic department for revision of the prosthesis because of an infection. She had history of Alzheimer's disease and a right total hip prosthesis because of coxarthrosis. She was submitted to surgical debridement and antibiotic therapy with vancomycin and rifampicin, with good clinical evolution at the firsts days. However, 3 weeks later started with maculopapular morbilliform rash affecting the face, trunk and lower limbs and purpuric lesions on the limbs, which progressed to become exfoliative and was intensely pruritic and painful, associated with fever (38.5°C) and without lymphadenopathy or hepatosplenomegaly. Laboratory test results showed eosinophilia (7.7%), renal dysfunction (creatinine 2.1 mg/dL) and increase of transaminases (aspartate aminotransferase 130U/L, alanine aminotransferase 175U/L). Blood cultures, searching for CMV, EBV, hepatitis B, hepatitis C and HIV were negatives. Admitted Dress syndrome secondary to antibiotic therapy with vancomicina. Suspended vancomicina and initiation treatment with Co-trimoxazole, maintaining rifampicin. It was associated prednisolone and hydroxyzine. After 5 days, with clinical and analytical improvement. She was discharged with Co-trimoxazole and rifampicin for 3 months and corticoid therapy for 1 month. At the end of the first month, on the revaluation consult, with a normalisation of renal and liver function and without rash at the inspection.

Discussion

DRESS syndrome is of particular concern in patients with long courses of antibiotics. The findings at the history of our patient (skin eruption with eosinophilia in complete blood cell count and the involvement of the liver and kidney, that can be affected commonly) support the diagnosis. The rapid diagnosis was very important, allowing a prompt withdrawal of the antibiotic, which is the pillar to treat any drug hypersensitivity reaction. Also the supportive therapy with steroid and anti-histaminic allowed to reduce the symptoms.

#1259 - Case Report

WUNDERLICH SYNDROME AS A RARE CAUSE OF ABDOMINAL PAIN IN THE EMERGENCY ROOM

José Pedro Leite, João Pina Cabral, Diana Leite Gonçalves, António Pedro Pissarra, Joana Coelho, Fátima Silva
Centro Hospitalar e Universitário de Coimbra, Coimbra, Portugal

Introduction

Wunderlich syndrome (WS) is a rare condition in which spontaneous renal hemorrhage occurs into the subcapsular

and perirenal spaces. It can manifest with a life-threatening presentation of fulminant hypovolemic shock. We report the case of a woman with sudden onset of intense abdominal pain and shock whose final diagnosis was a WS of idiopathic cause.

Case description

A 59-year-old woman with prior history of resistant arterial hypertension, submitted to renal sympathectomy 8 years before, presented to the emergency room with a sudden onset of severe abdominal pain in the upper quadrants and left flank with associated symptoms that included nausea, vomiting and diaphoresis. Besides hypertension, she had no other relevant history, including trauma, anticoagulant or antiplatelet medication. At initial examination she was pale and sweaty, leaning forward in a sitting position. She had cold extremities, thin pulse, a blood pressure of 65/45 mmHg and a heart rate of 115 bpm. Hemodynamic stabilization was achieved with crystalloid fluid resuscitation. After that, she maintained severe left upper quadrant pain with ipsilateral costovertebral angle tenderness. Laboratory tests showed a hemoglobin of 11.9 g/dL (later 8.5 g/dL) and leukocytosis but normal creatinine, troponin, amylase and lipase. An abdominal computed tomography (CT) was performed revealing an anterior perirenal hematoma of 13x6 cm in the anterior face of the left kidney, compatible with WS. A subsequent angiography revealed no evidence of active bleeding and the patient was managed conservatively, being discharged asymptomatic after 5 days. At 3 month follow up, abdominal CT still showed an organized hematoma of 5cm contiguous to the left kidney anterior border. She had also a nonfunctioning left adrenal incidentaloma of 8x6cm and is awaiting elective adrenalectomy.

Discussion

WS is a rare entity with around 300 cases described in the literature. Classic presentation includes sudden or insidious onset flank pain, palpable flank mass and hypovolemic shock. Hematuria can be present. Neoplasms are the most common etiology, mainly angiomyolipoma and renal cell carcinoma. Vascular diseases like polyarteritis nodosa may also be the cause. WS management is mainly conservative, although endovascular or surgical interventions may be required in cases of massive hemorrhage or persistent hemodynamic instability. This case report is a good illustration of the main features of this syndrome.

#1285 - Abstract

EPIDEMIOLOGICAL ANALYSIS OF HYPEROSMOLAR HYPERGLYCAEMIC STATE (HHS): POPULATION-BASED INCIDENCE AND CLINICAL OUTCOMES

Francesco Medici^{1,2}, Ritwika Mallik¹, Shivani Gor¹

¹ Homerton University Hospital NHS Foundation Trust, London, United Kingdom

² Queen Mary, University of London, London, United Kingdom

Background

Epidemiological studies on Hyperosmolar Hyperglycaemic State (HHS) are scanty and the incidence of HHS is unknown. In addition, the evidence-base of current published guidelines is very limited. The objectives of our study were to ascertain the incidence of HHS in a European urban population and evaluate the clinical outcomes.

Methods

Retrospective survey focusing on hospital admissions with Hyperosmolar Hyperglycaemic State (HHS). Setting: Homerton University Hospital in London UK is the main provider of secondary care for City & Hackney Clinical Commissioning Group, with a total catchment population of 286,000. Measures: rate of misdiagnosis or miscoding, incidence, demographics, percentage of intravenous insulin therapy, complications and outcomes. Data source for identification of index cases: Electronic Patient Records (EPR) with systematic search for the HHS definitions used for clinical coding. Data source for analysis: paper notes and EPR (whichever applicable). Data set: patients' names, hospital numbers, dates of birth, gender, dates of admission, clinical outcomes, complications, insulin therapy. Survey period: five years from 1 July 2012 to 30 June 2017.

Results

The number of index cases identified was 127. Scrutiny of the clinical records identified 54 misdiagnosis (simple hyperglycaemia without hyper-osmolality, diabetic ketoacidosis or hyperglycaemia with ketosis) and 33 coding errors, leading to 40 confirmed cases of HHS. The incidence rate of HHS was 2.7/100,000/year, with a hospital caseload of 8.0 /year. The mean age was 67.8 years (SD 12.9). Twenty-four (60%) were males and 16 (40%) females. We observed 5 (12.8%) deaths, but the HHS-attributable deaths were only 2 (5%). Sixteen (40%) patients required transfer to the Intensive Care Unit. Twelve (30%) of HHS cases were on insulin therapy before the admission. In total 39 (97.5%) patients required intravenous insulin therapy. Only 2 (5%) experienced transient hypoglycaemia and none developed cerebral oedema or osmotic demyelination.

Conclusion

Our study provides the first available data about the population-based incidence of HHS and new data regarding outcomes. The observed mortality rate appears much lower than previously reported in the literature. Our data suggest that intravenous insulin therapy is safe and effective in the vast majority of cases of HHS, contrary to some current published recommendations. Our findings could be helpful to inform service planning and to modernise local and national guidelines.

#1294 - Abstract

GERIATRIC EMERGENCY UNIT: AN INNOVATIVE MODEL OF SENIOR CARE

Veronique Trombert, Katharine Di Silvestro, Fassier Thomas, Dina Zekry

Geneva University Hospitals, Thonex, Switzerland

Background

Elderly patients are more likely to consult in emergency services. In addition, after a visit to an emergency department, they are at high risk of adverse outcomes such as early readmission and functional decline. In the emergency department of Geneva University Hospital, 25% of the patients are older than 75 years old. Generally, elderly patients spend more time than younger in an emergency unit. This environment adds a supplementary stress increasing the risk of complications. Moreover, in Geneva, the following day, they must be routed to the geriatric hospital, 7 km distance, when a hospitalization is needed.

Methods

For all these reasons, a new model of care was proposed inside the Geneva Geriatric Hospital (292 beds: 180 acute care and 112 rehabilitation).

Results

This geriatric emergency unit (18 beds) was created on November 2016 for seniors older than 75 years old presenting no vital urgency. The interdisciplinary team was trained to geriatric syndromes and the environment was adapted for this population. In addition the lack of waiting time allows a less stressful stay for these patients.

After 2 years of experience, we will present results regarding the typology of patients, degree of urgency, hospitalization and readmission rates, length of stay, rate of discharge, mortality, diagnosis and compare the performance of this unit to the general hospital.

Conclusion

This new model improves the care of old patients in the emergency room.

#1295 - Case Report

PERICARDIOCENTESIS: A PALLIATIVE PROCEDURE?

Rodolfo Viríssimo Gomes, João Pacheco Pereira, Manuel De Sousa, António Messias

Hospital Beatriz Ângelo, Loures, Portugal

Introduction

Lung cancer is the most commonly related with pericardial involvement. Neoplastic cardiac tamponade usually has a subacute course, and may have floating symptoms.

Case description

A 78-years-old caucasian female with type-2 diabetes mellitus and systemic hypertension went to the Emergency Room (ER) because of a 2-week long progressive dyspnea with dry cough, with simultaneous 10.7% loss of total body weight. Ethiological studies revealed a stage 4 small-cell lung carcinoma with pleural, hepatic, bone and cerebral metastasis, having been discharged with scheduled holocranial RT and follow-up.

She came back to the ER the next day due to worsening dyspnea and signs of poor peripheral perfusion. ABG showed global respiratory insufficiency with compensated mild respiratory acidosis; blood tests had no significant changes. Thoracic ultrasound had no signs of pleural effusion, but transthoracic echocardiogram revealed signs of right ventricular diastolic collapse with anterior pericardial effusion (max diameter 33.6 mm) and 35% transmitral flow variation. So, she was admitted at the ICU for clinical stabilization.

She maintained progressive worsening of respiratory distress despite optimized medical therapy and non-invasive ventilation, so due to refractoriness to medical therapy after new respiratory exacerbation, delirium and Beck triad presence, cardiac ultrasound was repeated confirming cardiac tamponade. The patient was then submitted to echo-guided pericardiocentesis with drainage placement with total output of ~250 cc of slightly cloudy citrus yellow liquid, with almost immediate reversal of the symptoms and echographic reevaluation with vestigial effusion only; cytology was compatible with carcinoma cells.

Discussion

Neoplastic pericardial disease treatment depends on symptoms severity, primary neoplasia and its curative potential, and average life expectancy of each individual patient. Although it is an invasive and risky technique, in highly symptomatic patients with hemodynamic compromise, pericardial fluid removal is the only attitude that will allow symptom relief.

In this case, despite being a patient with plurimetastised lung neoplasia with a very poor short-term vital prognosis, pericardiocentesis was performed as a successful palliative attitude, what allowed to establish and fulfill personal and therapeutic plans.

#1296 - Abstract

EXTREME HEAT IN PORTUGAL: PATIENT OUTCOMES IN AN EMERGENCY DEPARTMENT

Daniela Marto, Salvador Morais Sarmiento, Ana Brito, Hugo Inácio, Miguel Sousa Leite, Sofia Mahomed Mateus, Andreia Amaral, Dina Rodriguez Pita, Paulo Barreto, Catarina Salvado

Centro Hospitalar Universitário de Lisboa Central, Lisbon, Portugal

Background

The deaths and comorbidities related to heat are potentially preventable, and with the current climate changes, this type of

extreme temperatures will become more frequent. We intend to evaluate the impact of extreme heat in our emergency department, including morbidity, mortality and emergency response capability.

Methods

Retrospective cohort study including all patients with medical conditions treated in a tertiary hospital emergency department, during a six days long heat wave (2nd to 6th August 2018) – exposed –, compared to a homologous non-heat wave period in 2017 - non-exposed. Outcome measures were: time in emergency department, inpatient ward admission, total hospital mortality.

Results

We registered a total of 3983 admissions at our emergency department on both periods, in which 2092 were patients with medical conditions: 1115 on those exposed to heat and 977 on non-exposed patients.

The exposed patients were slightly older (mean age of 56.4 years on those exposed to heat, and 52.7 years on those not exposed), and in both cases 55% were women.

Also, the exposed patients stayed a longer period in emergency department: median of 5.79 hours on exposed patients (interquartile range: 3.36-10.29) vs. 4.25 hours on non-exposed patients (interquartile range: 2.73-6.44) - $p < 0.001$.

In addition to that, the exposed patients tended to be more often admitted to inpatient ward (16.8% vs 13.4%) - risk ratio of 1.25 [confidence interval 95%: 1.02-1.54] - and had a greater likelihood of death, being admitted to reanimation room or intensive care units (4.3% vs 1.8%) - risk ratio of 2.34 [confidence interval 95%: 1.37-3.99].

Conclusion

During a period of extreme heat patients stayed longer in emergency department, with more admissions to inpatient ward, and higher mortality. These data support the importance of contingency plans in this situation.

#1347 - Abstract

UNDERGRADUATE ULTRASOUND CURRICULUM: INTRODUCING BASICS OF US IN AN ITALIAN UNIVERSITY AFFILIATED HOSPITAL

Ivan Silvestri, Daniela Torzillo, Francesco Casella, Marta Del Medico, Alessia Lo Surdo, Chiara Scaccabarozzi, Sara Di Gregorio, Chiara Cogliati

Department of Internal Medicine, L. Sacco Hospital, ASST-FBF-Sacco, University of Milan, Italy

Background

Point of care ultrasound (POCUS) has become a key step in clinical practice. This study concerns the introduction of a US curriculum in the third year of medical school and the evaluation of students' satisfaction and teaching efficacy.

Methods

Four 2.5 hours frontal lessons were planned: basics of physics, artefacts, cardiac, abdominal, vascular and thoracic US semeiotics were addressed. Then, students groups (6+tutor) underwent a 2,5 hours hands-on session practising by using each other as models and finally answered an anonymous satisfaction survey. During the second semester an elective US hands-on course (20 hours) was offered to 20 students/year (5 students+tutor groups). 4 tutored alternating with 4 self-practising sessions were held. In self-practising sessions students were asked to reproduce pre-defined scans and to load them on Google Plus for remote tutors review. An evaluation test (score 1-4, not sufficient, sufficient, good, optimal) aimed to evaluate competence in visualization of: lung sliding; lung curtain sign; parasternal long axis heart view; inferior vena cava (IVC) diameter and collapsability; suprahepatic veins; abdominal aorta; bladder volume estimation. Finally, a call for 'tutor training' was launched to increase faculty by creating a peer-tutoring system.

Results

185 students in 2 years completed the questionnaire. 98% thought that US was useful to recall anatomical and physiological correlates and 84% declared that US should be incorporated in Anatomy and Physiology course too. For 96% US introduction was useful for the comprehension of physical examination and 94% were interested in attending a hands-on course. 35 students completed the elective course. At least a sufficient grade (2-4) was obtained for: gliding scan 97%; lung curtain sign 97%; parasternal 94%; IVC 94%; suprahepatic veins 100%; aorta 100%; bladder 100%.

Finally, seven students joined the 'tutors program' and were involved in the hands-on sessions faculty for the on-going courses.

Conclusion

Introduction of US during physical examination teaching was really appreciated by students. Results from elective course test demonstrate that US basics competency can be obtained by third year students by alternating tutored and self-practising sessions. Finally, as previously shown, peer tutoring can be an effective way to increase faculty, one of the main limitation in US programs adoption. Efficacy of peer-tutoring teaching will be assessed in the continuation of the study.

#1361 - Case Report

IT WAS SUPPOSED TO BE AN ALLERGIC REACTION

Francisco Chambel Belém, Eduardo Carvalho, Maria Do Céu Evangelista, João Silva, Artur Costa, Juliana Sá, Margarida Ascensão, Leopoldina Vicente

Centro Hospitalar Universitário Cova da Beira, Covilhã, Portugal

Introduction

A pneumothorax is defined by the presence of air or gas in the pleural cavity. It can be caused by a blunt or penetrating

chest injury, medical procedures, underlying lung disease or spontaneously. Symptoms usually include sudden chest pain and shortness of breath.

If the released air gets into the tissues under the skin, we can stand before a subcutaneous emphysema. The most common and visible sign and symptom is swelling around the neck accompanied with pain in the chest. Other signs include cervical pain, difficulty in swallowing, breathlessness or wheezing.

Case description

We present a case of an 87-year-old male patient that went to the Emergency Department after waking up with facial and palpebral exuberant edema along with hoarseness immediately after starting Metamizol prescribed by the primary care doctor the day before due to chest pain caused by a fall from own height.

The patient presented edema from the face to neck region, slightly flushed, eyes exuberantly swollen, especially the upper eyelids. He has normal breathing, without neurological symptomatology and a slight hematoma in the right costal grate, due to the fall.

Thinking of an allergic reaction to metamizol, was immediately medicated with corticosteroids, antihistamine and adrenaline but without expected effectiveness in reduce symptoms.

Two hours later in the observation room, the patient becomes disoriented and agitated and developed subacute dyspnea.

In the X-ray of the thorax, we observed subcutaneous emphysema, an apparent fracture of the 4th right costal arch, with signs of pneumothorax on the right side.

We performed a thoracostomy with 30F thoracic drainage in the 5th right intercostal space.

The patient remained in the inpatient service for 5 days, with a drainage system, at rest and under analgesia, with good clinical evolution, need of supplemental oxygen at 2L/h and progressive improvement of disorientation and agitation.

At discharge, the patient had no pneumothorax on the x-ray, without subcutaneous emphysema, slight bruising on the right side of the costal grid, and normal breathing.

Discussion

Emergency requires thought processes that incorporate risk stratification, assessment of urgency and need for immediate treatment.

This case shows a changing clinical scenario in which a patient appears to have an obvious diagnosis but it turns into another completely different situation.

In the emergency medicine, behavioral flexibility is essential as doctors need to be able to adapt to a changing situation.

#1371 - Case Report

DECOMPRESSION SICKNESS AT LOW WATER DEPTH

Kristoffer K. Brockhattingen

The Department of Geriatrics, Odense University Hospital, Region of Southern Denmark, Odense C, Denmark

Introduction

Decompression sickness (DCS) is a rare but potentially fatal condition. In Denmark the occurrence is approximately 15 cases a year.

This case report describes that one cannot solely rely on water depth as an absolute parameter when it comes to DCS.

DCS is divided into two forms: a mild and a severe. Mild DCS can be constant, varying in intensity or with negative progression, with a change over the course of several hours.

Severe DCS manifests onset with potentially fatal neurological and/or cardio pulmonal manifestations due to gas embolisms.

Case description

A 38-year-old male arrived at the emergency department after having done an hour-long dive at 3 meters depth the previous day. He was cleaning the underside of a boat, as he underwent a rapid and sudden ascend due to a broken inflatable diving vest. When arriving at the surface he felt a tingling sensation in the right arm. The patient described a tingling/stabbing sensation in the thorax, diffuse muscle and joint pain, starting with a tingling/stabbing sensation in the right arm, intense pain in the loin and a tingling sensation in the back. There was no preceding fever, cough or flu like symptoms.

The patient was adipose with no history medical history. The neurological examination revealed subjective sensory paraesthesia in all four extremities and the back. The vital parameters were all normal, including blood gas analysis.

Due to suspicion of DCS oxygen therapy was started and the ward at the Department of Anaesthesiology at Rigshospitalet, Copenhagen, was contacted. It was recommended to continue oxygen therapy for a few hours and confer again. Subsequently most of the symptoms went into remission. However, the pain in the loin and the subjective sensory paraesthesia in the back persisted.

The patient was transferred to hyperbaric therapy at Rigshospitalet where after the symptoms went to total remission confirming the DCS diagnosis. The patient was given a four week long diving ban and was referred to control at the outpatient clinic six months later.

Discussion

The literature describes a significant connection between the formation of gas bubbles and body mass index, fat deposits, age and diving exposure, wherefore the mentioned state of nutrition of the patient and the diving time mentioned in the history is presumed to have been a factor in this case.

The treatment of DCS is oxygen with hyperbaric therapy as primary treatment and additional diagnostics must not delay this treatment.

#1376 - Medical Image

DIFFERENTIAL DIAGNOSIS OF HEMATEMESIS- THINKING ABOUT OTHER ETIOLOGIES

Carolina Carrilho Palma, Inês Costa Santos, Ricardo Pereira, Joana Patrício, João Tavares, Ana Catarina Emídio, Joana Carreira, Beatriz Navarro, Hugo Casimiro, Mário Parreira, Ermelinda Pedroso
Centro Hospitalar de Setúbal, Hospital de São Bernardo, Internal Medicine Department, Setúbal, Portugal

Clinical summary

Upper gastrointestinal bleeding highly contributes to morbidity and mortality constituting a medical emergency. It can present as

hematemesis, melena or hematochezia. Stomach and duodenal ulcers are the most common causes however, other diagnosis must be considered. 75 year old male, history of abdominal aortic aneurysm (under surveillance for 3 years), presented to the emergency room with acute, massive hematemesis. Nasogastric intubation immediately drained 300 cc of blood. Arterial pressure was 95/55 mmHg, lab work showed haemoglobin 9.30 g/dL (previously was 11.2 g/dL). CT angiography showed that the aneurysm had ruptured and an aortoenteric fistula had formed. This case reminds of the importance of the clinical history in a differential diagnosis, ensuring the best outcome for the patient.

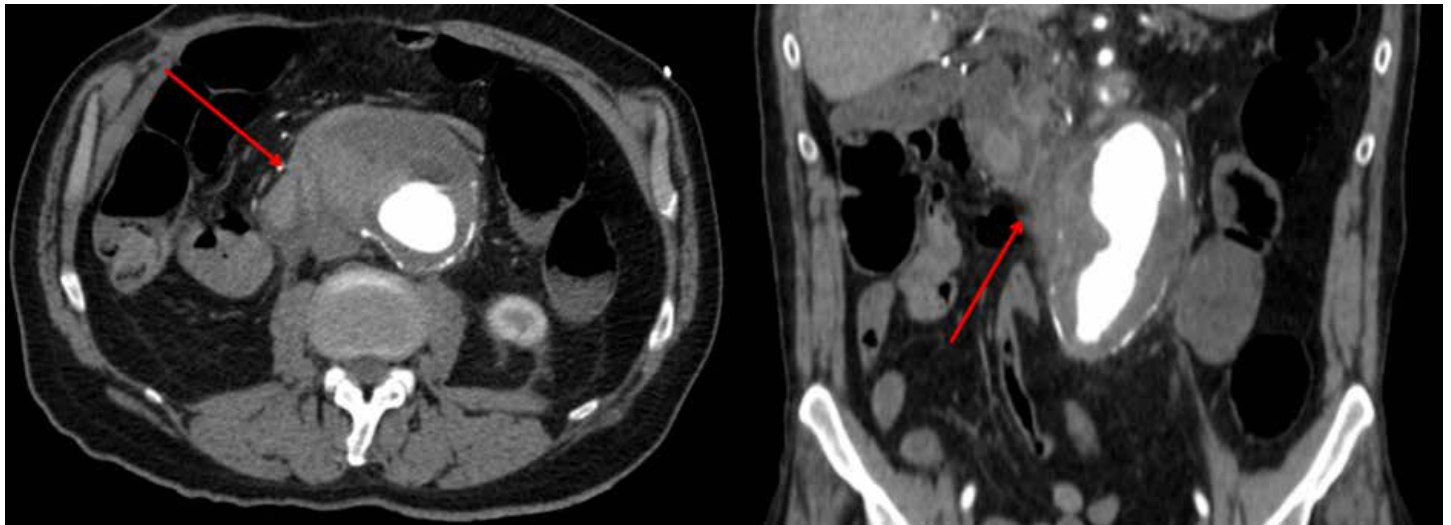


Figure #1376. CT angiography showing a ruptured abdominal aortic aneurysm together with an aortoenteric fistula.

#1387 - Case Report

CARDIAC ARREST IN THE ONCOLOGIC PATIENT: NEW CAUSES, NEW CHALLENGES

Ana Hipólito Reis, Daniela Coelho, Ernestina Gomes, Rui Araújo
Serviço de Medicina Intensiva, Hospital Pedro Hispano - Matosinhos Local Health Unit, Matosinhos, Portugal

Introduction

Successful outcome of an out-of-hospital cardiac arrest implies an interplay of the community, prehospital and intensive care medical teams. This interaction is crucial to ensure good care of critical patients, in order to deliver them again to the community.

Case description

A 57-year-old men with depression and a recently diagnosed colon carcinoma was referred to the local health centre to remove his chemotherapy infusion pump. He had had previous pelvic radiotherapy and colon surgery and had started the FOLFOX scheme 48 hours earlier, as well as haloperidol for his psychiatric disorder. While waiting for the procedure, he collapsed – cardiac arrest was promptly recognised, CPR with AED initiated and early defibrillation delivered with ROSC at 8 minutes. Prehospital

medical team assisted and transferred the patient to the hospital where reversible causes of cardiac arrest were excluded and post-resuscitation care was delivered. Interrogation of the AED identified a period of ventricular fibrillation and successful defibrillation. While in the intensive care unit, another episode of torsade de points degenerating in ventricular fibrillation was reverted. These episodes were filiated in cardiac dysrhythmia – primary or eventually secondary to FOLFOX and haloperidol, as described in the literature. The patient evolved well and was discharged without cardiac or neurological sequels, with a ICD and recommendation to not use these drugs again.

Discussion

Cardiovascular toxicity of many old and of new cancer therapies is one of the many dimensions of the growing field of cardio-oncology. Knowledge of potential toxicities is crucial for the approach of the ill cancer patient.

This case also reinforces the importance of the survival chain for the outcome of a cardiorespiratory arrest situation. Training of the medical community, structured AED program and the common and systematized emergency organization at the various sites of the healthcare network were determinants of success.

#1484 - Case Report

FATAL SEPTIC SHOCK DUE TO Fournier GANGRENE

Isabel De La Cal Caballero, Ana Patricia Gomes, Ricardo Gomes, Pedro Lito, José Proença, Leopoldina Vicente
Centro Hospitalar Universitario Cova da Beira, Covilhã, Portugal

Introduction

Fournier gangrene, is a rare (only 0.02% of hospital admissions) polymicrobial necrotising fasciitis of the perineal, perianal, or genital áreas.

This rapidly progressive synergistic infection can lead to multiple organ failure and death within hours of onset. Broad-spectrum antimicrobials, aggressive surgical debridement and septic shock resuscitation are the mainstay of treatment.

Case description

A 51-year-old tetraparetic man was admitted to emergency ward several hours after a wheelchair accident. The patient had a history of alcohol abuse and heart failure.

Upon physical examination, patient was oliguric and hypotensive (78/52 mmHg) with tachycardia (122/min), fever (38.1°C) and tachypnea. His scrotum was swollen and erythematous. There were multiple black gangrenous patches mainly on the right posterior side of the scrotum. He had concomitantly elevated white blood cell count, neutrophils, C-reactive protein (CRP) and respiratory alkalose and hyperlactacidemia as well.

It was hypothesized septic shock due to Fournier's Gangrene and was commenced initial resuscitation with crystalloid fluid, vasopressor infusion (norepinephrine) and broad-spectrum antimicrobials (meropenem and clindamycin); this was followed urgently by surgical exploration and debridement.

Discussion

Fournier Gangrene is an infrequent pathology, but its high mortality (7-40%) forces to perform an early diagnosis to avoid its progression and complications.

As shown in this case, Its high mortality rate it becomes a surgical emergency. It must also be associated with a postoperative on an intensive care unit by a multidisciplinary team.

#1510 - Case Report

SUCCESSFUL RECOVERY OF AN INTENTIONAL BARBITURATE POISONING - A CASE REPORT

Alexandra Esteves, Francisco Silva, Joana Abreu, Rogério Corga Da Silva, Tiago Veiga, Soraia Oliveira, Andriy Bal, Pedro Moura, José Caldeiro
Unidade Local de Saúde do Alto Minho, Viana Do Castelo, Portugal

Introduction

Pentobarbital was historically used for its anticonvulsant and hypnotic properties, later abandoned due to behavioural disorders and its physical dependence potential. Short-acting barbiturates

like pentobarbital have a narrow therapeutic margin, as shock and anoxia occur faster, and coma is more severe. Currently, it can be found both in medical and veterinary practice for anaesthesia and euthanasia, often cited by entities defending "painless death".

Case description

A 25-year-old veterinarian with a known history of depression, borderline personality disorder and previous self-mutilating episodes was found unresponsive in her clinic. Upon pre-hospital emergency care arrival, she was hypotensive, tachycardic, with a Glasgow Coma Scale of 3. A blood glucose level of 30 mg/dL was recorded. She had in her left forearm an intramuscular needle with a 20 cc syringe containing about 12 cc of a blue solution and near her was a bottle of pentobarbital for veterinary use (300 mg/mL) with 33 mL missing. Suspected self-administered dose was between 2.4 and 7.5 grams, well within lethal range. Glucose, naloxone and flumazenil and intravenous fluids were administered and she was intubated. On arrival to the Emergency Department there was an improvement on heart rate, blood pressure and glycemia, with no neurologic status change. Urine sample screened positive for barbiturates; serum acetaminophen, phenytoin and valproate concentrations were undetectable and blood biochemistry, brain computed tomography and electrocardiogram showed no significant changes. She was admitted to the Intensive Care Unit and remained in a comatose state for the first 48h. Vasopressor support was needed in the first 24 hours. Electroencephalogram performed during the drug washout period showed focal epileptic form, though no seizures were reported. On the 4th day, she had full recovery of awareness, with successful ventilatory weaning. Though psychiatric evaluation recommended admission on the Psychiatry ward, she was later discharged against medical advice without sequelae.

Discussion

Suicide and non-fatal suicidal behaviour in healthcare related professions are a growing concern. In patients presenting with shock, respiratory and central nervous system depression with an absence of brainstem reflexes the possibility of barbiturate intoxication should be considered, especially in patients with direct or indirect access. As no antidote is known, early supportive therapy grants the best chance of survival.

#1535 - Case Report

THE DIFFICULT CHALLENGE OF FLUID AND ACID-BASE BALANCE MANAGEMENT IN A COMPLICATED CASE OF ACUTE KIDNEY INJURY, SEPSIS AND GUT SUBOCCLUSION:ROLE OF US

Serena Melandri

Policlinico Umberto I - Sapienza University of Rome, Rome, Italy

Introduction

Fluids management is crucial in the care of critically ill patients. Hypovolemia results in decreased tissue perfusion and may lead to

MOF. Otherwise in an effort to reverse pre-renal oliguria, it is not uncommon, particularly when chronic kidney disease precedes sepsis, to exceed with resuscitation, leading to a dangerous overload. The focused Critical Care US has been adopted widely in the critical care hemodynamic monitoring because it allows a rapid volume-status assessment. Inferior Vena Cava diameter, its collapsibility and presence of B-lines in the lung are the “hot points” in the suspicion of a fluid overload.

Case description

A 73 years old man was admitted to Surgery Division for a toilette of a gouty lesion. In the ER he presented with acute on chronic renal insufficiency (creatinine 7.4 g/dl), due to a massive use of NSAIDs, and oliguria. Few days after surgery he developed severe constipation and biliary vomit. A CT-scan showed a pelvic faecaloma with bowel distension. He became anuric and pulmonary function got worsen, so he was transferred to Internal Medicine ward. At admission he was alert; BP 110/60, HR 78, SpO₂ 95% (FiO₂ 31%), tachypneic. Lab test showed hypocalcemia (5.8 mg/dl) and arterial blood gas (ABG) a mixed metabolic acidosis (pH 7,22; PCO₂ 33 mmHg; PO₂ 68; Lac 5 mmol/L, HCO₃⁻ 12). Calcium correction with 10 vials of calcium gluconate in 0.9% NaCl solution at 45 ml/h was started together with HCO₃⁻ bolus (50 mEq) followed by infusion of 100 mEq in 0.9% NaCl (20 ml/h); diuresis was forced by furosemide (10 mg/h). Despite a mild abdominal improvement due to evacuative enemas and correction of calcemia, the patient became hypotensive: BP 85/60 It's sensory got worse. In the suspicion of a septic shock (qSOFA 3) after blood, urine samples and empirical antibiotic, we used bedside US to assess volume status: IVC was normal but collapsed less than 50%; lung-US showed a mild “wet pattern”. We started an initial bolus of RL 500 ml and then a cautious “hydration”(80 ml/h). Vasopressor therapy with norepinephrine (0.2 mcg/kg/min) became necessary, together with a short cycle of NIV-Bi-Pap because of worsen ABG pH 7,10;PCO₂ 46; PO₂ 57; Lac 4 mmol/L; HCO₃⁻ 14. In 24 hours BP stabilized, metabolic acidosis reversed, CRP and procalcitonin were reduced and NIV interrupted. The ABG showed: pH 7.42; PCO₂ 33; PO₂ 87; Lac 2,8; HCO₃⁻ 21

Discussion

This case shows how a smart mix of clinical and US evaluation allows the right choice in fluid management of anuric septic patient

#1537 - Case Report

TETANY IN THE EMERGENCY ROOM – A SUDDEN MANIFESTATION OF HYPOCALCEMIA

Maria Margarida Pereira, Ana Vera Cruz, Marta Cerol, Petra Pego
Hospital Distrital de Santarém, Santarém, Portugal

Introduction

Hypocalcemia is a potentially fatal and often underdiagnosed electrolyte derangement. When it starts suddenly causes severe

and fast-onset symptoms such as seizures, cardiac arrhythmia, tetany or refractory hypotension, thus hospital admission and aggressive therapy are necessary. Despite this, the symptoms quickly regress with the normalization of calcemia values.

Case description

A 56-year-old female patient came to the emergency room with complaints of pain and generalized muscle stiffness starting an hour ago that made it impossible to walk, perioral paresthesias and of the hands and feet, nausea and an episode of vomiting. Her past medical history included arterial hypertension, noninsulin-treated type 2 diabetes mellitus, appendectomy, depressive disorder and cholecystectomy about one month ago. Of note, physical examination revealed the presence of tachycardia and tachypnea, profuse sweating, tetany with carpal spasm with extension of interphalangeal joints and adduction and flexion of the metacarpophalangeal joints and a positive Trousseau's sign. Blood samples were immediately collected for arterial blood gas analysis that revealed hypocalcemia (0.81 mmol/L) and the 12-lead ECG showed prolongation of the QT interval. The patient was given a calcium gluconate bolus followed by continuous perfusion with dramatic improvement of the mobility of the lower limbs and progressive recovery of the articular amplitudes of the fingers. The blood test also showed hypomagnesemia, hypophosphatemia, hypokalaemia and rhabdomyolysis parameters; no hypoalbuminemia, hepatic or renal impairment was detected. She was admitted to the intermediate care unit for rigorous surveillance and monitoring and was then discharged to an internal medicine outpatient clinic. The cause of electrolyte disorder is still being investigated.

Discussion

This case represents a classic presentation of sudden onset hypocalcaemia with mild symptoms of tetany that include circumoral numbness, muscle cramps, paresthesias of hands and feet and generalized muscle cramps. In severe cases, patients may present with laryngospasm, seizures or myocardial dysfunction. Early diagnosis with rapid institution of therapy is fundamental for the prognosis; electrocardiographic monitoring during ionic replacement is recommended because of the risk of cardiac arrhythmia. The causes of hypocalcemia are varied, the most common being vitamin D deficiency. The etiological study is essential to avoid recurrences and institute targeted therapy.

#1587 - Abstract

PROGNOSTIC VALUE OF CELL DEATH BIOMARKERS IN CARDIAC ARREST SURVIVORS

Beata Csiszar^{1,2}, Almos Nemeth¹, Zsolt Marton¹, Janos Riba¹, Peter Csecsei³, Tihamer Molnar⁴, Laszlo Deres^{1,2}, Kalman Toth^{1,2}, Peter Kenyeres^{1,2}

¹ 1st Department of Medicine, University of Pecs Medical school, Pecs, Hungary

² Szentagothai Research Centre, University of Pecs, Pecs, Hungary

³ Department of Neurology, University of Pecs, Pecs, Hungary

⁴ Department of Anaesthesiology and Intensive Care, University of Pecs, Pecs, Hungary

Background

Ischemia-reperfusion injury during and after resuscitation from cardiac arrest results in increased systemic cell death. Cytokeratin-18 (CK-18) is released into the blood during cell death, its caspase cleaved form (ccCK-18) is specific to apoptosis. This study evaluates their prognostic value for mortality, neurological outcome and their association with conventionally used clinical parameters after successful cardiopulmonary resuscitation (CPR).

Methods

Plasma samples of 40 resuscitated patients were collected 6, 24, and 72 hours after successful CPR to determine the CK-18, ccCK-18 concentrations by ELISA. The circumstances of the cardiac arrest and CPR, laboratory and physical parameters were recorded. Mortality within 30 days was considered end-point.

Results

The 6-hour troponin-T, GOT, GPT, INR, lactate levels and WBC count were significantly elevated among the 26 non-survivors. Significant negative correlations were found between the survived days and 6-hour GOT, GPT, troponin-T, INR values ($r=-0.551$, -0.443 ; -0.446 ; -0.462 ; $p<0.05$). Resuscitated patients had highly elevated CK-18, ccCK-18 levels and decreased ccCK-18/CK-18 ratio compared to healthy subjects, septic and postoperative patients (CK-18: 3842 vs. 242; 559; 1644 ng/L; ccCK-18/CK-18 ratio: 0.14 vs. 0.58; 0.22; 0.24)^[1]. Neither the values of CK-18 and ccCK-18 nor their kinetics showed difference between survivors and non-survivors and they did not show association with the length of the resuscitation, the initial rhythm, the neurological outcome or the number of the damaged organ systems either. CK-18 showed a declining kinetics in patients with good renal function in contrast to patients with renal failure. Significant negative correlation was observed between the 6-hour CK-18 and hemoglobin concentrations ($r=-0.400$, $p<0.01$).

Conclusion

This study was the first to investigate CK-18 and ccCK-18 levels among resuscitated patients. Surprisingly, the marker levels did not have prognostic value for mortality or neurological outcome in a general resuscitated population. The increased levels of

troponin-T, GOT, GPT, INR and WBC count in non-survivors indicate severe organ damage as expected.

Support: Supported by the ÚNKP-18-3-I New National Excellence Program of the Ministry of Human Capacities"

References

1. Stefan Hofer et al. Cell death serum biomarkers are early predictors for survival in severe septic patients with hepatic dysfunction; *Critical Care* 2009; 13:R93 <https://doi.org/10.1186/cc7923>

#1590 - Abstract

THE ROLE OF RIGHT VENTRICLE-ARTERIAL COUPLING IN ACUTE PULMONARY EMBOLISM WITH RIGHT VENTRICLE DYSFUNCTION: A RETROSPECTIVE COHORT STUDY

Lorenzo Falsetti¹, Alberto Marra², Mattia Sampaolesi¹, Francesca Ricconi¹, Marta Buzzo¹, Lorenzo Nobili¹, Vincenzo Zaccone¹, Annalisa Marchetti¹, Maria Novella Piersantelli¹, Tamira Gentili¹, Cinzia Nitti¹, Aldo Salvi¹

¹ Internal and Subintensive Medicine, Ospedali Riuniti, Ancona, Italy

² Center for Pulmonary Hypertension, Thoraxklinik at Heidelberg University Hospital, Heidelberg, Germany

Background

According to current guidelines, the presence of right ventricle dysfunction (RVD) in patients with pulmonary embolism (PE) is a turning point for clinical decision making. Right ventricle-arterial coupling (RVAC) is defined as the capability of the right ventricle to compensate the rise of pulmonary pressures by increasing its contractility. RVAC can easily and quickly be assessed with echocardiography through the ratio between the tricuspid anteroposterior systolic elevation (TAPSE) and the pulmonary arterial systolic pressure (PASp) (TAPSE/PASp). Aim of the current study was to investigate right ventricle-arterial coupling in patients admitted for PE.

Methods

Consecutive patients admitted in a large tertiary center for PE were retrospectively analyzed, enrolling all subjects with RVD. For each patient we obtained, at the admission: age, sex, body surface area, heart rate, systolic pressure, respiratory frequency and the main echocardiographic findings. We treated the TAPSE/PASp ratio both as continuous and dichotomous variable, adopting a cutoff of 0.32, derived from current literature on pulmonary arterial hypertension. BOVA score was treated as a dichotomous variable, subdividing patients in low-intermediate risk (BOVA \leq 4, stages I-II) and high risk (BOVA $>$ 4, stage III). Continuous variables were related with linear regression analysis and compared with t-test and ANOVA.

Results

we finally obtained a sample of 109 consecutive subjects. Patients

in BOVA stage III showed, when compared with the other subjects: a significant reduction of TAPSE, TAPSE/PASp, significantly lower telediastolic and telesystolic volumes in left ventricle and a significant reduction of stroke volume and VTILVOT. Patients with a TAPSE/PASp ratio ≤ 0.32 showed: a higher RV/LV ratio, a higher prevalence of paradoxical septum movement, a significant reduction of TAPSE, a significantly reduced telediastolic and telesystolic volumes and a significant reduction of stroke volume and VTILVOT.

Conclusion

Patients with PE and RVD with a low TAPSE/PASp ratio show significantly worse echocardiographic parameters, suggesting that an alteration of RVAC could have strong implications in the ventricular interdependency and could be suggestive of a worse haemodynamic status. Patients in stage BOVA III show a worse RVAC and, consequently, worse LV performances thus representing the group at highest risk of hemodynamic instabilisation.

#1675 - Case Report

POINT-OF-CARE ULTRASOUND IN ACUTE DYSPNEA – IT MAKES A DIFFERENCE

João Alexandre Tavares¹, José Mariz², Jorge Teixeira²

¹ Centro Hospitalar de Setúbal, Setúbal, Portugal

² Hospital de Braga, Braga, Portugal

Introduction

Pulmonary embolism (PE) is defined as an obstruction of the pulmonary artery or one of its branches, usually by a thrombus originated elsewhere in the vascular system. PE is a very serious form of venous embolism, being fatal sometimes. Despite being frequent, the diagnosis of PE is not always easy because signs and symptoms are usually non-specific and can range from asymptomatic to shock and cardiac arrest. The approach to the patient with suspected PE should be made on the basis of clinical probability in order to avoid unnecessary testing but also to ensure an early start of adequate treatment.

Case description

We describe a case of a 50-year-old woman with a history of hypertension, who came to the Emergency Department complaining of dyspnea that worsened with minimal physical effort (had to stop after 10 meters) for the past 2 days. Patient had no fever, cough, sputum, thoracic pain or pain in the legs. Had no history of recent immobilization, trips or surgery. On physical exam she was restless, tachypneic with 90% peripheral O₂ saturation without supplement oxygen. Lung sounds were maintained bilaterally. Patient had hemodynamic stability and no changes in the lower limbs. EKG had no changes. Arterial blood gases showed type I respiratory failure with hypocapnia (pH 7.48, pO₂ 57, pCO₂ 29, HCO₃ 21, Lactate 1.2, SaO₂ 89%). Blood was drawn and while waiting for X-ray, Point-of-care Ultrasound

(POCUS) was performed: preserved function of left ventricle, dilated right cavities with a right ventricle larger than the left; dilated inferior vena cava with decreased respiratory variability (<50%); Lungs with bilateral A-pattern without pleural effusion; compression of the venous system of the right lower limb was maintained; on the left lower limb hyperechoic material was seen inside the common femoral and popliteal veins and compression was not possible. Assuming a PE the patient was started on 1 mg/Kg of enoxaparin every 12 hours. Later the CT scan showed a massive bilateral PE and the inferior limb doppler scan confirmed an ileo-femoro-popliteal thrombus. Patient was admitted in the Intermediate Care Unit and 48 hours later transferred to the Internal Medicine ward for further studying.

Discussion

POCUS is becoming a reality in everyday clinical practice, with reports of its use since 1989 by Lichtenstein and co-workers. It has shown to improve diagnostic ability, allowing a swifter and assertive diagnosis and an early start of definitive treatment, just like the case presented.

#1706 - Case Report

CARDIAC TAMPONADE AFTER THROMBOLYSIS FOR ACUTE ISCHEMIC STROKE – A CASE WITH AN EXCELLENT OUTCOME

Ana Vera Cruz, Maria Margarida Pereira, Marta Cerol, José Ramalho, Gonçalo Ferrão, Juliana Mortágua, José Pedro Andrade
Hospital de Santarém, Santarém, Portugal

Introduction

Intravenous administration of IV recombinant tissue plasminogen activator (rt-PA) has been very effective in reducing the neurological deficit in patients with acute ischemic stroke (AIS). Serious adverse events are not uncommon, being hemorrhage the major complication.

We describe a case in which a patient with indistinct cardiac symptoms prior to thrombolysis in who haemopericardium and hemodynamically significant cardiac tamponade occurred after treatment with rt-PA.

Case description

A 59-year-old woman with history of epilepsy, dyslipidemia and hypothyroidism presented to the emergency department with dysarthria, left labial commissure deviation and right hemiparesis with 2:30 h of evolution. Her National Institutes of Health Stroke Scale (NIHSS) was 11.

There was no history of other symptomatology prior to the neurologic deficit. On examination blood pressure was 166/78 mm Hg, pulse was 140 beats per minute and the electrocardiogram with atrial fibrillation. The computed tomography (CT) of the brain showed a hyperdense left middle cerebral artery and intravenous thrombolysis with rt-PA (0.9 mg/kg) was started 2:50 hours after symptom onset.

The patient fell into a coma 30 minutes after starting thrombolysis. Repeat CT brain showed no hemorrhage.

Shortly afterward, she developed hypotension maintaining atrial fibrillation with rapid ventricular rate. Point-of-care ultrasonography found large amount of echodense material in the pericardium compatible with hemopericardium causing cardiac tamponade. Pericardiocentesis was promptly performed, draining 600 ml of serohematic fluid and followed by the resolution of the shock. The patient recovered the conscious state within a few minutes, presenting with NIHSS of 2.

Discussion

Acute ischemic stroke patients may have undetected cardiac disease that may pose a risk for hemopericardium and life-threatening tamponade after treatment with rt-PA.

Despite uncommon cardiac tamponade must be suspected in a patient presenting with shock after thrombolysis because for a successful outcome every minute counts.

#1708 - Case Report

GASTRIC ISCHEMIA IN SEPTIC SHOCK: A CASE REPORT

Nuno Pereira, Nuno Fernandes, Enrique Romero, Vasco Marques, Miguel Rodrigues, Rita Marçal

Hospital Particular do Algarve - Gambelas, Faro, Portugal

Introduction

Gastric ischemia is a rare condition, mainly because of the rich collaterals around the stomach. The etiologies for gastric ischemia include local vascular causes, systemic hypoperfusion and mechanical obstruction. On imaging studies air can be detected in the splanchnic circulation. It carries a bad prognosis, being associated with significant mortality.

Case description

The authors relate the case of a previously healthy 38 year old woman, medicated only with an anticonceptual pill and with iodine allergy. She visited the E&A Department of our hospital with complaints of right back pain and fever. Her bloodwork was unremarkable except for elevation of C reactive protein, and urine analysis was positive for leucocytes. A CT exam showed right hydronephrosis conditioned by a 6 mm calculi in the ureterovesical junction. She was admitted to the hospital, urinary and blood cultures were withdrawn, antibiotic was started, and she underwent a urinary tract catheterization. The procedure was uneventful, except for transitory hypotension, responsive to fluids. On the night of admission, she developed a sudden clinical picture of diffuse abdominal pain, refractory hypotension with need for vasopressors and transient loss of consciousness. A CT exam showed extensive air embolism: gas bubbles inside intra-thoracic veins; pneumatosis of the gastric wall with gas bubbles inside the splanchnic circulation; properly positioned right urinary catheter without any local complications. The patient was submitted to

bowel rest and nasogastric intubation, and high flow oxygen and broad-spectrum antibiotics were initiated. An upper endoscopy revealed a circumscribed area of congestive mucosa suggestive of ischemic phenomena. A head and whole-body CT exam showed reabsorption of almost all of the gas bubbles previously related. An *Escherichia coli* grew on blood and urinary cultures, sensitive to the antibiotic administered. The patient's clinical condition progressively improved and she was able to start feeding orally with good tolerance, being discharged ten days after admission.

Discussion

We emphasize this clinical case because of its rarity and the diagnostic challenge posed by its peculiar presentation. Here we postulate that the critical event for the gastric ischemia and the subsequent gaseous manifestations was the systemic hypoperfusion related to the urinary sepsis. Fortunately, the clinical evolution was favorable with the support measures instituted and the patient didn't need surgical treatment.

#1718 - Medical Image

LUDWIG'S ANGINA - AN EMERGENCY NOT TO FORGET

Isabel Ferreira, Sara Xavier Pires, Fábio Videira Santos, Lúcia Gonçalves, Gabriela Gonçalves, Cristina Pereira, Heloisa Castro
Centro Hospitalar Universitário do Porto, Porto, Portugal

Clinical summary

A 32 year-old female, previously healthy, was diagnosed with a dental abscess on the left inferior 3rd molar, initially treated with amoxicillin/clavulanate. She developed a painful left facial oedema and 2 days later, the inflammatory signs extended to the anterior cervical region with involvement of the upper airway, trismus and respiratory distress. Cervical CT-scan showed a diffuse thickening with phlegmon and emphysema of the soft tissues from the oral cavity to the anterior mediastinum with left internal jugular vein thrombosis and bulging of the walls of the upper airway at the base of the tongue.

Fibreoptic nasotracheal intubation and surgical drainage of the abscesses were performed, IV antibiotics started and she was admitted to the ICU.

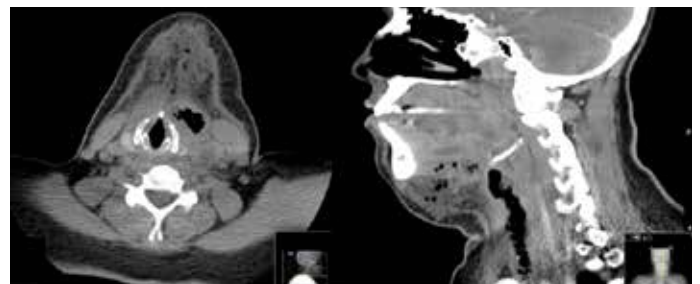


Figure #1718. Cervical CT scan with phlegmon and emphysema.

#1745 - Case Report

DISTRIBUTIVE SHOCK IS NOT ALWAYS A SEPTIC SHOCK – A CLINICAL CASE

João Alexandre Tavares, João Carvalho, Patrícia Carneiro, Catarina Emídio, Carolina Palma, Ricardo Pereira, Inês Costa Santos, Mário Parreira, Ermelinda Pedroso
Centro Hospitalar de Setúbal, Setúbal, Portugal

Introduction

Lyell Syndrome (LS) is a potentially fatal dermatologic disorder characterized by a widespread erythema, necrosis and bullous detachment of the epidermis and mucous membranes. Is usually a drug allergy, but can also be associated with infection, cancer and even vaccination. It has a mortality ranging from 25 to over 90% and is usually associated with sepsis, dehydration and multiple organ failure.

Case description

We describe a 47-year-old woman with no relevant history initially treated with acetaminophen and etoricoxib for tibiotarsus pain without arthritis. After 24 hours patient started to develop a pruriginous rash mainly in her back, and was treated with deflazacort and levocetirizine. The rash continue to worsen and she developed facial swelling and lethargy, being transported to the Emergency Department. At arrival she was confused, hypotensive, tachycardic and with cold extremities; had a disseminated rash of the entire body, mainly in the upper body not sparing palms and soles. Arterial blood gases showed: pH 7.45, pCO₂ 25, pO₂ 60, HCO₃ 17 and lactate 2. Labs showed increased markers of inflammation with multiple organ dysfunction. After fluid challenge patient was started on vasopressors in increasing doses. Blood was drawn for cultures and she was started on ceftriaxone and doxycycline (lived outside the city, had a cat and a typical rash). Echocardiogram showed hyperdynamic heart. She was admitted to the ICU with a Shock of undetermined etiology – septic vs other distributive type. Over the next 24 hours there was a worsening of the facial edema rash with multiple coalescent skin blisters and bullous detachment of the epidermis over 70% of her body, with positive Nikolsky sign. Lyell Syndrome was admitted. Skin biopsy later confirmed the diagnosis. She was transferred to a Burn Unit where she remained for several weeks, with various infectious complications. Patient had multiple skin grafts and intensive physical therapy, but remains with sequelae. She was referred to an allergy specialist.

Discussion

LS initial presentation as a distributive shock is very rare and not described in the literature. With a SCORTEN of 5 or more the mortality is around 90% but the patient ended up surviving. In emergency medicine is important to remember that there are other etiologies for distributive shock besides septic, specially when the cause is not immediately clear. Despite its cause, the basic principles of treatment are the same and should be known to every emergency physician.

#1747 - Case Report

A BIZARRE CASE OF REVERSIBLE HEART BLOCK - THEVETIA PERUVIANA INDUCED CARDIOTOXICITY

Anand Venugopal, Basavaprabhu Achappa
Kasturba Medical College, Mangalore, India

Introduction

Thevetia peruviana (yellow oleander) is a shrub found in the tropical and subtropical regions of the world belonging to the family Apocyanaceae. Consumption of the seeds are a very common method of suicide in South India and Sri Lanka. The toxic effects of the plant is similar to digitalis poisoning due to the presence of cardiac glycosides. The toxic effects usually begins within 24 hours of consumption which may lead to fatality if not identified in time and treated promptly.

Case description

57-year-old male complained of vomiting after accidental consumption of a seed. Seed was identified as 'Karaveera' (local name of yellow oleander seed) which was kept for plantation. On examination, he was conscious, oriented, pulse 74 beats/min, blood pressure 110/80 mmHg with systemic examination and ECG showing normal sinus rhythm. Gastric lavage was performed and admitted in the ICU for monitoring. Sodium, potassium magnesium and rest of the blood work up was normal, but after 10hrs of admission he developed giddiness with bradycardia (heart rate 40 beats/min) and hypotension (blood pressure 90/40 mmHg). Normal saline and atropine 0.6 mg IV was administered following which his BP improved but bradycardia persisted. Repeat ECG showed bradycardia with 2nd degree atrioventricular block – Mobitz type 2. This continued for next 3 hours in view of which electrophysiologist reference was obtained and patient was taken up for temporary pacemaker insertion (TPI). ECG returned to normal sinus rhythm and patient's condition improved.

Discussion

Yellow oleander (Thevetia peruviana) ornamental shrub grown widely in tropical and subtropical parts of the world. Leaves, flowers, seeds and fruits of plant are poisonous and are used as homicidal agents. Plant contains toxins thevetin A, thevetin B, nerifolin, thevetoxin, peruvoside and ruvoside. According to Eddleston et al. as little as two seeds lead to cardiac rhythmic abnormalities leading to fatality. Clinical symptoms of poisoning include nausea, vomiting, diarrhoea, giddiness and abdominal pain which often leads to cardiac arrhythmias. Since all parts of plant contains cardiac glycosides, toxicity mimics digitalis toxic toxicity. According to Eddleston et al. significant cardiotoxicity developed even 72 hours. Bradyarrhythmias are most common cause of mortality in yellow oleander poisoning which are treated with atropine, isoprenaline and temporary cardiac pacing. Learning point from this case is right identification of toxin and prompt treatment to prevent mortality.

#1755 - Abstract

EMERGENCY DEPARTMENT USE BY A GROUP OF PATIENT UNDER 55 YEARS OLD

Hugo Inácio, Ana Brito, Daniela Marto, Salvador Morais Sarmento, Miguel Sousa Leite, Sofia Mahomed Mateus, Dina Rodriguez Pita, Andreia Amaral, Paulo Barreto, Catarina Salvado

Centro Hospitalar Universitário de Lisboa Central, Lisbon, Portugal

Background

Currently, most inpatients with medical conditions are elderly and most of the Emergency Department (ED) studies address this population. However, little is known about the younger patients ED use. The aim of this study was to evaluate demographic characteristics of younger patients, their pattern in ED use, chief complaints (CC) and severity.

Methods

A retrospective observational study was performed, including all patients with medical conditions who visited the ED of a tertiary care hospital over a 12-month period. An exploratory data analysis showed that the median age divided the patients into 2 comparison groups: Group 1, 18-55, and Group 2 >55 years-old. We considered as CC the chosen flowchart using the Manchester Triage System (MTS). Patients were considered severe if they met at least one of the following criteria: admission to the resuscitation room and/or admission in an intensive care unit (ICU) and/or ED death.

Results

We observed 71469 patients (56% female), with an average age of 55 ± 22 (SD) years old. Group 1 (n=36,408 patients), mean age of 36 ± 11 and Group 2, (n=35061), mean age of 54 ± 11 .

Priority assigned by the MTS: 45% of patients was yellow or higher in Group 1 and 61% in group2; 56% of patients was green or lower in Group 1 and 39% in group2 ($p < .001$).

For the 10 most frequent CC, groups differ only in the frequency order. The most frequent CC in both groups was general disability (16% Group 1, 27% Group 2) followed by chest pain (10%) in group1; and dyspnea (17%) in Group 2; dyspnea was only the eighth most frequent in Group 1 (6%). Limb problems were the fourth most frequent CC in both.

Group 1 remained for 6 ± 8 hours in the ED and Group 2 for 10 ± 21 hours ($p < .001$).

Overall, 3% of the patients were considered severe in group1, and 12% in Group 2 ($p < .001$).

In total, 5% of group1 patients and 25% of group 2 were hospitalized ($p < .001$); and 0.03% of Group 1 patients and 0.08% of Group 2 were admitted in the ICU. Still, of the total patients admitted to the ICU, 25% were from group1.

Conclusion

The most frequent CC were similar in both groups, differing only in the frequency order. Group 1 seemed to be less severe than Group 2, remained almost half the time in the ED and was 5 times less likely

to be hospitalized. Nevertheless, it is crucial to note that while these results show that younger patients are less severe, 5% of inpatients and 25% ICU patients, admitted from the ED, were <55.

#1828 - Medical Image

AORTIC DISSECTION – A RACE AGAINST TIME

Ana Valada Marques, Miguel Falcão, Tânia Gaspar, Isabel Maldonado, Rosa Amorim

Centro Hospitalar do Oeste, Caldas Da Rainha, Portugal

Clinical summary

70 years old male, past history of type 2 diabetes, dyslipidemia, ischemic heart disease, admitted at the emergency room (ER) after sudden onset of severe chest pain and consciousness deterioration. Glasgow coma scale 7 (O1, V1, M5), horizontal nystagmus, symmetrical muscular strength. Blood pressure (BP) 121/98 mmHg, normocardial, peripheral oxygen 97%. Peripheral pulses absent. Normal electrocardiogram. BP dropped to 55/31 mmHg, no fluid challenge response, started vasopressor support and airway protection. Computed tomography angiography images showed an aortic dissection beginning at ascending aorta and ending after the emergence of left subclavian artery, extended to the left common carotid artery with rupture and hemopericardium. Patient was referred for surgical intervention.

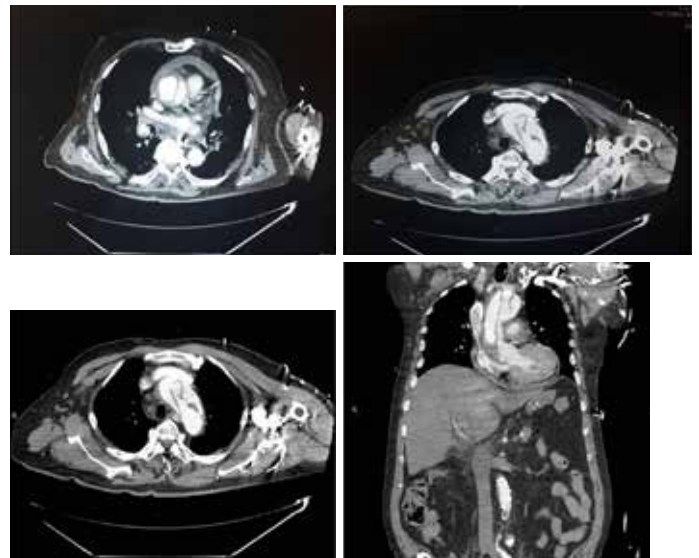


Figure #1828.

#1847 - Abstract

SUICIDE ATTEMPTS BY CHEMICAL INGESTION - A RETROSPECTIVE STUDY

Joao Gamito Lopes, Lucas Diaz, Jose Sousa E Costa

Hospital do Litoral Alentejano, Santiago Do Cacém, Portugal

Background

Suicide attempts and deliberate self-harm is a critical psychological issue worldwide with data suggesting an increasing trend.

Internists, as emergency doctors, are responsible for the acute management of the complications that result from these attempts. Each chemical type has its particularities and doctors need to be aware of those most frequently observed to best adequate their immediate response. The authors proposed to characterize the suicide attempts by chemical ingestion.

Methods

Cohort retrospective study over 4.5 years. Inclusion criteria was the need to hospitalization after a suicide attempt by chemical ingestion. Other methods of suicide attempt were excluded. Descriptive analysis on demographic variables, relevant medical history, ingested chemical characteristics, and outcome was done.

Results

101 hospitalizations episodes were included, corresponding to 96 patients. Women predominance (61,4%). Age varied between 18 and 91 years old, with a mean 55,7 years (SD: 19,1) and median of 55 years (IQR: 31). 32,7% were already on a Psychiatrist. Benzodiazepine was the most prevalent chemical used (33,7%), followed by organophosphate (16,8%) and antipsychotic drug (15,8%). More than a third of the patients used more than one type of drug, and 19,8% ingested three or more different types of drugs. 7,9% died. No seasonality was found.

Conclusion

The authors address the need to invest in physician's education on managing these drug complications. However, providing adequate follow-up care and address the problem as preventable should be a major concern.

#1901 - Case Report

WHEN A SIMPLE "FLU" HIDES SOMETHING ELSE: MEETINGS BETWEEN INTERNAL MEDICINE AND HAEMATOLOGY

Sandra D. Santos, David Lopes Sousa, Joana Paixão, Lídia Gomes, Ana Catarina Lucas

Serviço de Medicina Interna, Centro Hospitalar e Universitário de Coimbra, Coimbra, Portugal

Introduction

The triad cough, dyspnoea and fever can correlate with a myriad of differential diagnoses, among the most obvious the respiratory infections. However, these symptoms can mean more serious illness.

Case description

A 47-year-old woman, with no significant personal background and no usual medication, presented with a 3-day history of productive cough, dyspnoea and pleuritic pain, without fever. The patient denied any B symptoms and complained of recurrent skin infections in recent weeks. The week before, she had been medicated with amoxicillin/clavulanic acid for inguinal furunculosis.

She was hemodynamically (HD) stable, afebrile, and cardiopulmonary auscultation had no major changes. The chest X-ray showed diffuse bilateral cotton-like infiltrates, she had type 1 respiratory failure, and laboratory studies revealed severe acute pancytopenia [White blood cells = 3.56 k/ μ L (4-10 k/ μ L), Neutrophil = 1.9, with 6% immature cells), haemoglobin = 8.6 g/dL (12-16 g/dL) and platelets 17 k/ μ L (150-400 k/ μ L)]. The peripheral blood smear showed marked dysplasia of the myeloid line and erythrocyte morphology with moderate anisopoikilocytosis. An extended serological study was negative for syphilis, HBV, HCV, HIV, Chlamydia trachomatis, C. pneumoniae, Coxiella spp, S. pneumoniae and Legionella spp and revealed immunity for CMV, HSV-1, EBV and PpV-19. Blood, urine and sputum cultures were also negative. A thoracic CT-scan showed extensive areas of heterogeneous parenchymal densification in both lungs, especially in the upper lobes, with air bronchogram, which were admitted being of infectious nature. In addition, hilar adenomegalies were present, the largest on the right with 11 mm short axis. At this point, the patient was admitted to the Haematology ward and started on broad spectrum antibiotics. As soon as possible, a myelogram was performed, confirming the diagnostic suspicion of acute myeloid leukaemia, and chemotherapy was started.

Discussion

The authors present the case of a patient with a common presentation of acute cough, fever and dyspnoea leading to a diagnosis of acute myeloid leukaemia.

This case report demonstrates the importance of considering less obvious diagnoses even in cases that seem simple and highlights the importance of a good articulation between hospital specialties in the early resolution and early initiation of urgent treatments, namely chemotherapy.

#1931 - Case Report

ABDOMINAL HEMATOMA DUE TO ANTICOAGULANT THERAPY – A SERIES OF CASES

Cristina Moreira Marques, Márcia Ribeiro, Carolina Veiga, Carina Costa Silva, João Mota, Ana Ogando, Carlos Oliveira

Hospital Santa Maria Maior, Barcelos, Portugal

Introduction

Abdominal wall hematomas are uncommon, difficult to diagnose and are often associated with systemic anticoagulation. Studies report an incidence of 1.5 to 2% in hospitalized patients and overall, is more common in female than males. This series of uncommon cases reports 8 hospitalized patients that suffer from haemorrhagic shock due to abdominal wall haematoma in a period of 6 months in an internal medicine service, which were in therapy with LMWH. This paper intends to review all the factors that can have triggered this life-threatening, uncommon and abnormal situation in this hospital.

Case description

This series of 8 cases happened between October of 2018 and March of 2019, under LMWH during their stay in the hospital. All the patients were women with ages between 53 and 82. Four of our cases needed adjustment of the dosage of LMWH (age, kidney function, weight, previous treatments). From those under therapy with warfarin, two of them had therapeutic levels of INR, at the time of the start of the first administration of LMWH. One of the patients was under NOAC therapy, and at admission had coagulopathy. All the 8 patients suffer from haemorrhagic shock due to abdominal wall haematoma, which occurred 5 to 14 days after their hospitalization. The first case was approached surgically. Conservative treatment was decided in all the 7 of the other patients because of the high risk of a surgical approach; with the necessary support. Seven of patients recover completely, being discharged after 3 to 4 weeks from the hospital, with partial reabsorption of the haematoma. Death occurred in one of the cases. To all the patients the scores of CHA₂DS₂-VASc and HASBLED were calculated, having all scored higher than 5 and lower than 3, respectively.

Discussion

LMWH can cause bleeding complications and sometimes leads to major life-threatening complications. Even though 3 of the report cases could have been due to iatrogenic procedures; 5 of them happened in patients without any other triggers. It is important to be aware of all the factors that can influence anticoagulation (oral and systemic) therapy, the administration of these therapies and the relation with the drug itself. This series of cases pretends to alert to these serious and many times undiagnosed situations, the importance of early recognition and treatment and the extreme importance of the continuous revision of the anticoagulation's protocols in use.

#1954 - Abstract

EFFECT OF AGE IN THE INCREASED RISK OF MORTALITY OF SEPTIC PATIENT

André Simões¹, Sofia Durão², João Gonçalves Pereira¹

¹ Serviço de Medicina Intensiva - Hospital de Vila Franca de Xira, Lisboa, Portugal

² Serviço de Hematologia e Transplantação de Medula Óssea - Centro Hospitalar Lisboa Norte, Lisboa, Portugal

Background

Several studies have shown a close relationship between infection and mortality in critically ill patients. It is not known whether this effect is dependent of age.

Methods

Retrospective, observational, unicentric study to assess the impact of age and clinical severity on mortality of patients admitted to an Intensive Care Unit (ICU) with infection.

All patients admitted to the ICU between July 2016 and June 2017 were included. Patients were segregated in 6 different

groups, according to the presence of infection on admission to the ICU and according to their age (divided in 3 terciles).

We evaluated the mortality at hospital discharge and after 6 months.

Results

A total of 737 patients were included, (58.3% male, mean age of 66.6±16.3 years).

Infection on admission was noted in 216 patients. Its prevalence was similar in the 3 age groups (p=0.97). Respiratory was the most prevalent focus of infection (32.9%).

Infected patients had higher SAPS II (44.3±19.3 vs. 39.6±18.1, p=0.006) and hospital mortality (27.8% vs 20.4%, OR 1.5 [1.04-2.17]; p=0.033).

However, after 6 months, mortality was already similar in both groups (39.4% vs 34.9%, p = 0.274). Around 25% of the older patient's group, discharged alive from the hospital, died during the subsequent 6 months.

Conclusion

Patients with infection on admission to the ICU have higher mortality, largely explained by their higher severity at admission. This difference is transversal to all age groups and decrease significantly in the first 6 months after discharge.

#1987 - Case Report

TRASTUZUMAB, A LIFESAVER WITH A REMARKABLY AUGMENTED RISK FOR CARDIOVASCULAR EVENTS

Adriano Pacheco Mendes, André Gonçalves Mendes, Ruben Raimundo, Joana Cochicho, Sara Viana, Rita Parente, José Lessa, Ana Neves, Maxim Suleac, Isabel Lavadinho, Isabel Soles
Unidade Local de Saúde do Norte Alentejano, Portalegre, Portugal

Introduction

Trastuzumab is a life-extending therapy for breast cancer patients overexpressing the human epidermal growth factor receptor 2 (HER2+), but has known cardiotoxic risk and an increased risk for cardiovascular events.

Case description

We report a case of a 60-year-old woman, who was being treated with trastuzumab for breast infiltrating ductal carcinoma (HER2+), that has been admitted in the emergency department after a car crash coming off road. According to her medical history, she completed 6th cycles of chemotherapy for breast carcinoma and hypertension had been recently diagnosed. Although treatment with an ACE inhibitor plus calcium channel blockers, the blood pressure was poorly controlled. On physical examination she presented with left hemiplegia, an altered level of consciousness and elevated blood pressure. The CT scan revealed a right intracerebral hemorrhage with 7 cm of larger diameter and with a mass effect 4 mm to the left. After 10 days, with a good recovery

status and an optimization of antihypertensive therapy, she got discharged from hospital.

Discussion

More women are living with and surviving breast cancer because of improvements in breast cancer care. Despite the fact that trastuzumab has significantly improved outcomes for women with HER2-positive tumours, breast cancer patients are regarded as a population of high cardiovascular risk, risk that might be remarkably augmented under trastuzumab chemotherapy due to its known, but not that common, adverse effect such as hypertension. Since hypertension is a potent modifiable risk factor during breast cancer treatment, a stricter control of hypertension in these patients is desirable in order to avoid events such as hypertensive emergencies and their complications.

#2044 - Case Report

A CASE OF TAKOTSUBO SYNDROME IN THE IMMEDIATE POSTOPERATIVE PERIOD

Luciana Faria¹, Adriana Alves², Ana Mesquita²

¹ Centro Hospitalar Póvoa de Varzim/Vila do Conde, Vila Do Conde, Portugal

² Unidade Local de Saúde de Matosinhos, Matosinhos, Portugal

Introduction

Takotsubo syndrome (TS) is an increasingly recognized entity, but rarely described as an immediate complication after elective surgery.

Case description

A 59-year-old woman, active smoker, with hypercholesterolemia, depression with anxious distress and right hemithyroidectomy at age 44. Medicated with levothyroxine, escitalopram and alprazolam. Electively admitted for left hemithyroidectomy by follicular carcinoma. Preoperative study with ASA II, euthyroid and normal electrocardiogram (ECG). The surgery was performed under general anesthesia and no peri or intraoperative complications were reported. In the immediate postoperative period, after extubation, hypoxemic respiratory failure was identified, with desaturation up to 85%, without airway obstruction and not responsive to increase FiO₂. Noninvasive ventilation was started. ECG showed inversion of the T waves in DI, DII, DIII, aVF, V2 to V6 and prolongation of the QTc interval. Analysis with elevation of troponin I (maximum 1303 ng/L) and BNP (453.6 pg/mL). Thoracic angiography by computed tomography showed only bilateral opacities in the lower lobes and excluded pulmonary embolism. Echocardiogram (Day 1) showed a compromise of the left ventricle systolic function (Ejection Fraction = 30%), hyperkinesis of the basal segments with mid-apical segmental akinesia. Cardiac catheterization (Day 1) excluded significant coronary artery disease (40% stenosis at the beginning of the distal segment of the AD) and ventriculography documented severe depression of left ventricular systolic function

and segmental contractility suggestive of TS. Cardiac magnetic resonance imaging (MRI) (Day 8), showed “non-dilated ventricular cavities with normal biventricular systolic function, not apical bulging of the left ventricle, without evident areas of edema, fibrosis or myocardial necrosis and small pericardial effusion.” Considering the initial ECG, biomarkers (BNP), echocardiogram with absence of coronary disease, with subsequent normal study (MRI) the diagnosis of TS was made. The patient had discharge (Day 11), asymptomatic, with ECG with normal QTc but remaining inversions of Twaves and, medicated with aspirin, atorvastatin, levothyroxine, alprazolam, escitalopram.

Discussion

Since the surgery and extubation are considered a stressful events, this entity should be thinking as a differential diagnosis of acute respiratory failure/complication after a elective surgery.

#2059 - Abstract

SEPTIC SHOCK AS THE MAIN CAUSE OF ICU MORTALITY - 6 MONTHS IN REVIEW

Eduardo Cernadas¹, João Corrêa¹, Dália Estevão¹, Irene Aragão²

¹ Centro Hospitalar Cova da Beira, Covilhã, Portugal

² Centro Hospitalar do Porto, Porto, Portugal

Background

Shock is a life-threatening condition of circulatory failure. The effects of shock are initially reversible, but rapidly become irreversible, resulting in multiorgan failure (MOF) and death. Septic shock is a potentially fatal medical condition that occurs when sepsis, which is organ injury or damage in response to infection, leads to dangerously low blood pressure and abnormalities in cellular metabolism. The Third International Consensus Definitions for Sepsis and Septic Shock (Sepsis-3) defines septic shock as a subset of sepsis in which particularly profound circulatory, cellular, and metabolic abnormalities are associated with a greater risk of mortality than with sepsis alone.

Methods

Analysis and review of the main causes of mortality in an Intensive Care Unit (ICU) of a Central Hospital, between July 2018 and December 2018.

Results

The authors reviewed 6 months of clinical activity at an Intensive Care Unit, with a total of 230 patients (54% males; 46% females). The average time of internment at the unit was 6.7 days. Regarding mortality in the time object of the study, 46 (20%) have deceased being the shock (n=21), the main cause. From an etiologic point of view, the vast majority of these patients have died from Septic shock (n=14) being the respiratory and genito-urinary tract the main focus. Reference must be made to at least 7 patients, who died from distributive shock in the context of acute severe polytrauma and other causes of shock (like hemorrhagic or obstructive).

Conclusion

Septic shock is associated with significant mortality and is the leading non cardiac cause of death in intensive care units (ICUs). The results are in agreement with the clinical sense and international guidelines that efforts must be made to detect and treat shock as soon as possible, as septic shock still remains one of the main causes of mortality in ICU.

#2080 - Medical Image

THE GREAT DECEIVER

David Prescott, Ana Isabel Brochado, Margarida Pimentel Nunes, Inês Branco Carvalho, Isabel Montenegro Araújo, Beatriz Donato, Rita Sérgio, José Luís Ferraro, Vasco Evangelista, António Martins Baptista, José Lomelino Araújo

Hospital Beatriz Ângelo, Loures, Portugal

Clinical summary

We present the case of a sixty-one year old that calls the emergency services because of sudden lumbar pain, nausea, hyperhidrosis and referred hypotension. He mentioned an average systolic blood pressure greater than 200 mmHg the previous days, which he assumed was normal. On-site observation was unremarkable except for obtundation of consciousness and muffled heart sounds. His BP was 110/78 mmHg. ECG had no changes suggestive of ischemia. He was quickly transported to hospital where bedside echoscopy showed cardiac tamponade. The following Angio-CT images show a Stanford type A aortic dissection from the coronary arteries all the way to the left iliac artery. Extravasation of contrast material to the pericardial sac can be seen.

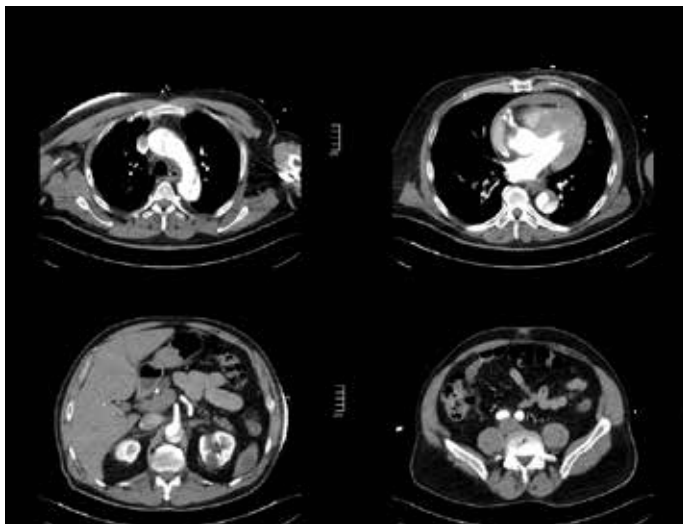


Figure #2080. Top Left: Aortic arch and Descending aorta dissection. Top Right: Contrast leak to pericardial sac and Thoracic Aorta dissection. Bottom Left: Abdominal Aorta dissection. Bottom Right: Common iliac arteries and Left common iliac artery dissection.

#2091 - Case Report

LUDWIG'S ANGINA – AN EMERGENCY

Cristina Silva, Sara Freitas, Jorge Cotter

Hospital da Senhora da Oliveira, Guimarães, Portugal

Introduction

Ludwig's Angina is a form of rapidly progressive cellulitis, which involves the sublingual and submandibular space. It can arise from an infection of the oral cavity or upper respiratory tract. Clinically, the patient may present with dysphagia, odynophagia, "hot potato" voice and fever. The most feared complication is airway obstruction, which is potentially fatal.

Case description

An 84 years old male was brought to the Emergency Department because of fever, mucopurulent sputum and right neck swelling of recent onset. He had prior medical history of hypertension, type 2 diabetes, atrial fibrillation, cerebrovascular disease, dementia and left sialadenitis. On physical examination, it was observed swelling in the right submandibular region, abundant secretions in the oral cavity, salivary stasis and elevation of the mouth's floor. The patient went into respiratory arrest, which was reverted by aspiration of secretions of the oropharynx. Computed tomography of the neck revealed "enlargement of the right submandibular gland with heterogeneous contrast uptake, compatible with sialadenitis". It also showed "reticulate densification of the ipsilateral superficial and deep fat plans of the neck, compatible with cellulitis/ phlegmon, extending to the floor of the oral cavity", inducing "flattening of the vallecula and right piriform sinus" as well as "thickening of the aryepiglottic fold, right ventricular band and vocal cord and infrahyoid muscles". These abnormalities were causing "moderate airway reduction in the oropharynx plan". It was requested an evaluation by Otolaryngology and it was decided to perform an emergent tracheostomy along with drainage of the purulent collections.

Discussion

Ludwig's Angina is an increasingly less frequent entity, in part because of the improvement of oral health. Nevertheless, because of the risk of airway obstruction, it may have a fulminating course and a fatal outcome. At an early stage, it can be treated with intravenous antibiotics but, in advanced stages, tracheostomy and surgical drainage can be necessary. This case intends to stress the importance of early diagnosis and immediate treatment of this condition.

#2117 - Abstract

OBSTETRIC ADMISSION TO INTENSIVE CARE UNIT – A FIVE YEAR REVIEW

Sofia Xavier Pires^{1,2}, Helena Gonçalves¹, Anusca Paixão¹, Sónia Canadas¹, Henrique Santos¹, Ricardo Amaral¹, Nelson Barros¹, Francisco Esteves¹

¹ Centro Hospitalar de Trás-os-Montes e Alto Douro, Vila Real, Portugal

² Hospital Senhora da Oliveira, Guimarães, Portugal

Background

Maternal mortality has declined since the 1960s as a consequence of improved health programs and is currently estimated at 7 per 100,000 births in 2015 (PorData). Obstetric pathology is a rare admission cause in Intensive Care, however, early admission improves prognosis of severe obstetric pathology. The objective of this study was to evaluate all medical records concerning pregnant and postpartum women who were admitted to ICU care, describing the characteristics of the mothers, their previous comorbidities, and identifying risk factors for maternal and neonatal mortality.

Methods

A descriptive retrospective study was carried out. All female patients admitted to the Intensive Care Service from 1 January of 2012 to 31 December of 2016 were included. Data was collected by clinical records reading. Data analysis was performed using descriptive statistics, and data was treated using SPSS software.

Results

Eight obstetric patients were admitted to the Intensive Care Unit during the study period, corresponding to 0.24% of all admissions. The mean age of the patients was 28 years. The most frequent cause for admission were complications related to hypertension, namely HELLP Syndrome in 38% of patients (n=3) and pre-eclampsia in 25% (n=2) of all admissions. The majority of complications occurred in the third trimester, with only one admission occurring in a second trimester pregnancy. In fifty per cent of cases an emergent cesarean was performed. The mean SOFA score at admission was 3 (minimum 2, maximum 5). On average, patients had 3 organ dysfunctions, with hepatic, respiratory and hematologic dysfunctions being the most frequent. The mean APACHE II on admission was 16.1, corresponding to an estimated mortality of 47.3%. The co-morbidity most frequently present was obesity in 63% of patients (n=8), followed by chronic hypertension in 38% (n=3) of all patients. The mean hospitalization time was 2.2 days. The maternal mortality rate was zero, and a fetal death was reported.

Conclusion

Admission in ICU care is rare due to obstetric complications with hypertensive complications leading the most frequent cause for admission.

#2118 - Abstract

NON-INTENSIVE CARE UNIT ACQUIRED PNEUMONIA: DATA FROM A TERTIARY CENTER

Andreia Margarida Margarida De Matos¹, André Filipe Goulart², Eduardo Santos³, Catarina Monteiro¹, Paulo Martins¹

¹ Coimbra Hospital and Univesity Center, Coimbra, Portugal

² Hospital de Santo Espírito Da Ilha Terceira, Açores, Portugal

³ Centro Hospitalar do Baixo Vouga, Aveiro, Portugal

Background

Hospital-acquired pneumonia (HAP) is a frequent cause of nosocomial infections, with great morbidity and mortality worldwide but most of the available data is in mechanically ventilated patients. Non-ICU acquired pneumonia (NIAP) has been described as a distinct clinical entity with few data as suggested in 2016 Marta Di Pasquale et al article review. The aim is to describe epidemiology and risk factors of NIAP in a tertiary center.

Methods

retrospective study of patients with NIAP admitted to a 29-bed tertiary care ICU from 2015 to 2017.

Results

From a total of 2904 patients admitted to ICU, 84 patients (4.0%) were admitted for NIAP: 76% men, with a mean age of 67,4±14,7 (26 to 90 years), APACHE-II 19.6, SAPS-II 49.7, SOFA-score at admission 9.9, and SOFA-score at discharge 3.2, 96.4% with mechanical ventilation (average 10 days). Fifty-five per cent had ≥3 comorbidities: 29% with recent malignant neoplasm, 26% with pulmonary disease or heart failure and 20% with alcohol or tobacco consumption. About 71.4% had ≥1 antibiotic multiresistance factor: previous 90-days antibiotic therapy (in 39%, mostly with ≥1 antibiotic group), immunosuppressive therapy (21%), and previous multiresistance bacteria (15%). A gastric content aspiration was described in 14.3%. Most patients (58.3%) were admitted to hospital for a surgical or neurological disease. Late-onset pneumonia was frequent (at average at 17-day admission), and ICU admission occurred before 36 hours. Combination therapy was made in 64.5%, with antibiotic step-up in 28.6% after monotherapy regimens versus 16% with combination. Bacterial agents from bronchial sputum were identified in 39 patients (46.4%): mostly *Staphylococcus aureus* (35.6% with 81% methicillin-resistant, followed by *Pseudomonas aeruginosa* (15.6%, mostly resistant to piperacillin-tazobactam) and 15.4% were polymicrobial. Sixty patients (41%) had bloodstream infection and 61.5% were multiresistant. Intra-hospital rate mortality was 39.2%. Hospital discharge occurred after 45 days (with an average 12 days in ICU). One year mortality rate was 27.1%, mostly 30 days after discharge.

Conclusion

NIAP seems to be an important cause of intra-hospital mortality, mostly late-onset acquired and with previous identified risk

factors. *Staphylococcus aureus* and *Pseudomonas aeruginosa* were the most frequent agents and multiresistance was high.

#2174 - Case Report

SYNCOPE IN A PREGNANT WOMAN - A SIGN OF CONCERN

Magda Ferreira Costa

Hospital Senhora da Oliveira, Guimarães, Portugal

Introduction

Syncope is defined as transient loss of consciousness due to cerebral hypoperfusion, characterized by a rapid onset, short duration, and spontaneous complete recovery. Can be subdivided in three main groups according with the underlying etiology: reflex, due to orthostatic hypotension and cardiac cause.

Case description

A 31-year-old woman, 8 weeks pregnant, with no prior relevant antecedent, was observed in our emergency service because of a colic abdominal pain in lower quadrants with one day of evolution, with vomiting and nausea. In the morning of admission she had a syncope when she went to the bathroom, with right frontal trauma. At the physical examination she was hypotensive, afebrile and presented a painful abdominal palpation, with no clinical recovery after fluidotherapy, paracetamol and metoclopramide. During the time the patient stayed at the observation room, became more symptomatic and hemodynamically unstable. In the complementary exams, we could observe a 2g/dL drop in hemoglobin in 2 weeks, with no elevation of inflammatory parameters. Electrocardiogram was normal, but the abdominal ultrasound described an empty uterine cavity, with gestational sac in an ectopic location and hematic liquid in intraperitoneal cavity. Internal medicine discussed the case with the obstetrician team and the patient was submitted to an emergent exploratory surgery and a gestational sac implantation in the left fallopian tube was confirmed. After the surgery, the patient presented a favorable evolution.

Discussion

Ectopic pregnancy is defined as a pregnancy that occurs outside of the uterine cavity. The fallopian tube is the most common location of ectopic implantation, accounting for more than 90% of cases. Treatment approaches include expectant, medical (methotrexate), or surgical. Can be complicated by rupture, in which case may present in shock from blood loss and with unusual patterns of referred pain from intraperitoneal blood. If undiagnosed or untreated, it may lead to maternal death due to rupture of the implantation site and intraperitoneal hemorrhage.

#2185 - Case Report

ANGIOTENSIN-CONVERTING ENZYME INHIBITOR-INDUCED ANGIOEDEMA: REPORT OF A CASE

Diogo Ramalho, Ana Canelas, Beatriz Samões, Ingrid Da Costa

Centro Hospitalar Vila Nova de Gaia / Espinho, Vila Nova De Gaia, Portugal

Introduction

Angiotensin-converting enzyme inhibitors (ACEi) are the main cause of pharmacological iatrogenic angioedema, due to their frequent use in patients with arterial hypertension and heart failure disease. Cough is the most common adverse reaction, but in rare occasions patients present angioedema.

The most important risk factors are: female gender, age above 65, African descent, aspirin and non-steroidal anti-inflammatory drugs (NSAIDs) use, previous history of angioedema, smoking and atopy.

Usually, the angioedema occurs in the first week (between the 2nd and 5th day) and involves non-dependent areas asymmetrically (e.g., face, tongue, lips and upper airways in 10% of the cases). Pruritus and urticarial reaction are typically absent.

Case description

A 73-year-old white male patient, with no relevant medical history, was admitted to the emergency department with marked edema affecting the lower lip and left hemiface, and odynophagia after taking perindopril for blood pressure control. Minutes after drug administration, the patient experienced a sudden onset of odynophagia. He took ibuprofen with clinical worsening of said symptom. 10 hours later, lower lip and left hemiface edema emerged. The patient denied pruritus, erythema, wheezing, abdominal pain, fever and known allergies. The physical examination was normal: afebrile, hemodynamic stability and normal cardiopulmonary auscultation. The patient was evaluated by Otorhinolaryngology that found tonsillar pillars, valleculae and aryepiglottic folds edema, sparing the tongue and other the structures of the oral cavity and oropharynx with preserved airway patency. Corticoid and antihistamine drugs were administered with clinical improvement. The patient was discharged with corticoid and antihistamine drugs and recommendations to stop taking ACEi, avoid NSAIDs and reinstate prior non-ACEi antihypertensive drugs.

Discussion

ACEi-induced angioedema is rare, but potentially life-threatening. The diagnosis is clinical-based and is confirmed by complete resolution after ACEi discontinuation.

This case report describes a white male patient with risk factors for ACEi-induced angioedema: advanced age and clinical worsening after NSAID intake.

When discharged, patients must be informed of the possible recurrence in the first months after discontinuation of the culprit drug.

#2191 - Case Report

METFORMIN POISONING - A TALE OF SEVERE LACTIC ACIDEMIA

Ana Hipólito Reis, Marta Pereira, Daniela Coelho, Rui Araújo
Serviço de Medicina Intensiva, Hospital Pedro Hispano - Matosinhos Local Health Unit, Matosinhos, Portugal

Introduction

Acute management of the patient with intentional drug overdose is challenging. As multiple drugs are frequently involved, with synergic and/or antagonical pharmacological profiles and effects, identification of a toxindrome is not always possible. Metformin is a drug of the biguanide family, widely prescribed and generally safe. Lactic acidosis is a well known and dangerous complication in acute and chronic settings, associated with renal insufficiency, critical illness or intentional overdose.

Case description

A 54 year-old woman with recently diagnosed breast carcinoma and depression was admitted in ICU after intentional overdose of high dosed multiple drugs: alprazolam, venlafaxine, propranolol, letrozole, vildagliptin and massive amount of metformin (50 g). She evolved with coma, hypotension, bradycardia with prolonged QT, hypoglycaemia and lactic acidemia (minimum pH of 7.13, maximum lactate 14 mmol/L). Management included airway protection with orotracheal intubation and mechanical ventilation, activated charcoal, dextrose, intravenous fluid and aminergic support. Continuous venovenous hemofiltration (CVVHF) was started. Initial pH and lactate improvement was followed by rebound deterioration. Other hyperlactacidemia causes were excluded, dialysis dosis was improved and CVVHF was maintained over 96 hours with sustained metabolic and renal function improvement. There was not resurgence of hyperlactacidemia after suspension of the technique.

Discussion

Acute management of this patient was challenging, due to severity of presentation and co-ingestion of high dosed multiple drugs. Metformin in particular was worrisome for the massive amount ingested and because its poisoning is a life-threatening condition. It presents with inespecific symptoms, severe lactic acidosis and cardiovascular collapse and is associated with a very high mortality rate (30-50%). Treatment options are limited to supportive care. Extracorporeal treatment is recommended and its benefits go beyond metformin removal, and include improvement of academia and lactate clearance. Intermittent hemodialysis is the preferred method for metformin clearance. In this case we chose a continuous modality as an alternative, due to patient hemodynamic status and UCI experience, with high dialysis dosis. A lactate rebound can occur during or after discontinuation of hemodialysis, due to redistribution of metformin into the intravascular space. As it is unpredictable, our patient acid-base status was monitored closed.

#2197 - Case Report

THE NEED TO REMEMBER: IS THE TREATMENT THE KEY FOR A NEW PROBLEM?

Diana Pires Fernandes¹, Sara Faria², Diana Mano³, Andrés Carrascal¹

¹ Unidade Local de Saúde do Nordeste, Bragança, Portugal

² Hospital Distrital Figueira da Foz, Figueira Da Foz, Portugal

³ Centro Hospitalar Universitário do Porto, Porto, Portugal

Introduction

There are several pathologies and risk factors that make hypocoagulation a fairly common treatment these days. Therefore, the need for this type of therapy should bring with it the search for the most appropriate drug for each patient in order to minimize the risk of hemorrhagic complications without, in this way, avoiding all inherent risks.

Case description

We present a 69-year-old truck driver with a history of hypertension, deep venous thrombosis and pulmonary thromboembolism, reason why he was hypocoagulated with warfarine about 6 months ago.

During one of his work trips, the patient went to the emergency department suffering from neck pain and paraesthesia in his left arm. With no other alterations in the physical exam and no history of traumatism, he was discharged on the same day after analgesia and anti-inflammatory prescription.

The next day, the patient woke up with urinary incontinence, a feeling of weight in the left arm and incapable to move the lower limbs so he returned to the emergency department. Clinical examination showed bradycardia and hypotension, as well as tetraparesis with upper limb folds, indifferent plantar reflexes and abolished osteotendinous reflexes.

In the diagnostic tests stands out a INR of 5 and the presence of a cervical hematoma in the region corresponding to C3-C7 with severespinal cord compression was verified by magnetic resonance imaging (MRI). After revert hypocoagulation and initiation of vasopressor support, the patient was sedated, ventilated and transferred to a central hospital for neurosurgical treatment. Performed laminectomy from C4 to C7 and hematoma removal in the same area. The patient was admitted to the intensive care unit and repeated MRI 5 days later with extensive hypersignal in T2/T2 STIR, from C2-C3 to C7-D1. The patient developed paraplegia of the lower limbs, distal paresis of the upper limbs and difficult ventilatory weaning, so he had to undergo for a tracheostomy before he was transferred to a rehabilitation center.

Discussion

Although, in the absence of trauma, hemorrhagic complications in hypocoagulated patients are not so common, this case showed the importance of not forgetting them at the time we considered the diagnosis. The urgency in the treatment of this type of complications is related with the fast reversal of hypocoagulation and the specific treatment of each problem to avoid permanent consequences, which was no longer possible in this situation.

#2234 - Abstract

ACUTE INTOXICATION IN THE EMERGENCY DEPARTMENT OF A GENERAL HOSPITAL

Gonçalo Mendes, Margarida Madeira, Mafalda Figueira, Ana Catarina Emídio, Daniela Brigas, Francisca Santos, Diana Neto, Eugénio Dias, Clara Rosa, Ermelinda Pedroso
Centro Hospitalar de Setúbal, Setúbal, Portugal

Background

Acute poisoning is a major medical emergency carrying significant morbidity and mortality in all age groups across the world. It may have highly variable clinical presentations depending on the substance involved and this variability can lead to delayed recognition with consequent increased morbidity and mortality.

Methods

With this study, authors aimed to describe the clinical and socio-demographic characteristics of patients admitted to an emergency department (ED) of a general hospital with a diagnosis of poisoning. A retrospective study analyzed patient admissions in the ED from January 1, 2017 to December 31, 2017.

Results

We found a total of 351 admissions, 314 (89.4%) cases were involved in non-deliberate poisoning, whereas 37 (10.6%) were involved in deliberate poisoning. 196 (55.8%) patients were female and 155 (44.2%) male. The mean age was 48.49 ± 19.93 . Analyzing the admission, 5.12% (18) of patients had more than one admission to the ED. 88 (25% of total) admissions were due to benzodiazepines, 27 (7.7%) due to pesticides and insecticides, including 1 case of paraquat and 133 cases (37.9%) were due to ethanol intoxication. Excluding ethanol intoxication, most admissions occurred in winter, January: 28 cases (7.9%); February with 26 cases (7.4%) and December with 29 cases (8.26%). From all the admissions only 5.12% (18 cases) needed to be admitted to the Intensive Care Unit and those patients had a mean stay of 10.8 ± 7.02 days. Total mortality was 1.42% (5 deaths, 4 in the ICU and 1 in the ED).

Conclusion

Most intoxication cases, except ethanol, occurred in the winter. The poisoning was more common in female than in males. Only a small number of cases needed ICU admission and the global mortality rate was low.

With this work authors tried to help physicians to understand the local data in order to promote early recognition and appropriate management, improving outcomes, reducing morbidity and mortality of poisoned patients.

#2250 - Case Report

ALTERED MENTAL STATUS IN A TOXICOPHILIC PATIENT: AN UNEXPECTED DIAGNOSIS

Inês Esteves Cruz¹, Ana Bento Silva¹, Gonçalo Cunha², Eduarda Carmo¹, Francisco Silva¹

¹ Hospital Egas Moniz, CHLO, Lisbon, Portugal

² Hospital Santa Cruz, CHLO, Lisbon, Portugal

Introduction

We present a case in which the unspecific symptoms masked the important diagnosis of a complicated myocardial infarction (MI) with cardiogenic shock and left ventricle (LV) thrombus. Thrombosis was a common complication before the advent of reperfusion, nowadays it occurs only in less than 8% of patients submitted to reperfusion therapy.

Case description

55-year-old Caucasian male, with a known history of epilepsy, dilated cardiomyopathy with low ejection fraction (EF), hepatitis B and C and a cardiorespiratory arrest secondary to opioid overdose a year ago. He had allegedly suspended both his IV drug use and alcoholic habits since then. Treated with levetiracetam 500 mg bid and olanzapine 10 mg id. He presented to the hospital with a 3-month history of fatigue and anorexia, worsened in the preceding 2 weeks leaving him bedridden. On physical examination he was conscious, pale, hypotensive with a normal heart rate (87/63 mmHg 85bpm) and hypoxemic (SpO_2 90% on room air), with a normal heart and lung examination, and hepatomegaly.

Laboratory findings revealed anemia 12.8g/dL, thrombocytopenia $125 \text{ mm}^3/\text{uL}$, hyponatremia 126 mmol/L, hyperkalemia 5.4 mmol/L, cytocholestatic pattern (total bilirubin 1.98 mg/dL, direct 1.13 mg/dL; AST 476 U/L, ALT 752 U/L, GGT 55U/L), acute kidney injury (urea 122 mg/dL, creatinine 1.27mg/dL), elevated inflammatory markers (leukocytosis $11100/\text{uL}$, CRP 6.2 mg/dL) and NTproBNP (8218 pg/mL). Abdominal ultrasound showed hepatic steatosis, moderate ascites and bilateral pleural effusion. Within 72h he developed an altered mental status, worsening hypotension and oliguria. ECG revealed a left bundle branch block, chest X-ray showed extensive bilateral pleural effusion, brain CT scan revealed no acute changes and blood tests demonstrated worsening liver and renal function tests, metabolic acidosis with raised lactate and troponin levels (hsTnT 680 ng/mL). He was transferred to the ICU with the diagnosis of MI with cardiogenic shock, starting ventilatory and inotropic support, and dialysis. The echocardiogram revealed an enlarged LV with reduced EF and a large apical thrombus; unfractionated heparin was started. Unfortunately, he ended up dead at 7 days after admission.

Discussion

This case should emphasize the importance of regular patients' follow-up, regardless of their social condition, toxicophilic and alcoholic dependence or therapeutic compliance, particularly in patients with severe pathology with a high probability of unfavorable progression.



ENDOCRINE AND METABOLIC DISEASES

#29 - Case Report

ADIPSIC DIABETES INSIPIDUS SECONDARY TO CRANIOPHARYNGIOMA RESECTION

María Alejandra Pérez Ardila, Juan David Zuluaga, Henry Augusto Millán, Andres Flórez, Fredy Andrés Luna Vela, Juliana Villa
Fundación Cardioinfantil, Bogotá, Colombia

Introduction

Central diabetes insipidus is characterised by decreased vasopressin secretion, with partial deficiency, or in more severe cases, complete deficiency, leading to a hyperosmolar state and increased serum sodium. The diagnosis is based on a diuresis greater than 2 mL/kg/hour or more than 2.5–3 L in 24 hours and a urinary density <1.005. Adipsic diabetes insipidus is a variant in which, following osmoreceptor damage in the circumventricular region, patients lose their thirst mechanism and have an increased risk of complications due to hypernatraemia. Approximately 100 case reports have been presented in the literature.

Case description

24-year-old woman with a history of delayed puberty and hypothyroidism, but no prior study reports. She consulted due to a headache with warning signs associated with altered visual acuity. Brain MRI was performed which showed signs of a non-adenomatous lesion with suprasellar and hypothalamic extension. Following transcranial surgery, she developed diabetes insipidus criteria, with absence of thirst documented during the hospitalisation (Using a visual analogue scale of thirst). The histopathological findings confirmed the diagnosis of craniopharyngioma. The patient was treated with desmopressin and received recommendations regarding rehydration according to the quantification of losses, with electrolyte stabilisation.

Discussion

After the resection of craniopharyngioma the deficit of antidiuretic hormone can occur in 70-90%, however the mechanism of thirst prevails in most of them. Adipsic diabetes insipidus is an infrequent but highly complex disease; complications associated with esta enfermedad include hypernatraemia, venous thromboembolism and obstructive sleep apnoea. Treatment includes desmopressin therapy and patient education in order to maintain an adequate fluid intake.

#41 - Case Report

THYROTOXIC PERIODIC PARALYSIS-A RARE CAUSE OF HYPOKALAEMIA IN PREGNANCY

Érica Barata, Eliseu Ekundi, Ernesto Ulica, Naima Andrade, Gilda Mariano
Clinica Sagrada Esperança, Luanda, Angola

Introduction

The manifestations of hypokalaemia are usually evident throughout the etiological investigation of patients with a history of previous episodes of vomiting, diarrhea or use of diuretics. However, in some cases, the cause of hypokalaemia may prove to be a real challenge when multifactoriality is present.

Case description

A 26-year-old woman, G3P2, previously healthy 16-week pregnant, admitted for hyperemesis. Severe hypokalaemia was identified refractory to correction, palpitations, tachycardia and paresis of the lower and upper limbs. After clinical and laboratorial evaluation, thyrotoxic periodic paralysis was diagnosed, and the therapy with Methimazole and B-blocker was initiated.

Discussion

thyrotoxic periodic paralysis is a rare manifestation of hyperthyroidism. It is a diagnosis to be considered in patients with a history of hyperthyroidism and should also be excluded in patients with severe hypokalaemia refractory to correction. Its identification in pregnant women is rare, however early intervention, correct surveillance and adequate monitoring of the treatment allowed the continuity of pregnancy safely.

#43 - Case Report

HYPOTHYROIDISM AS CAUSE OF HEART FAILURE IN WOMEN WHO HAVE JUST GIVEN BIRTH : A CASE REPORT

Taís Mendes De Lima, Andressa Braga Barros, Giulia Dal-Cin Zanquetto
Federal Hospital of Andaraí, Rio De Janeiro, Brazil

Introduction

Heart failure has the least prevalent causes of hormonal changes related to pregnancy and after given birth. Hypothyroidism

presents complications with pericardial effusion being the most common.

Case description

A 25-year-old woman was referred to the hospital because precordial burning pain seven days ago, ventilator-dependent, without irradiation, continuous. She had no fever or signs of infection and she had given birth five months ago. An electrocardiogram showed sinus bradycardia, PR-segment depression in lead AVR, diffuse ST-segment elevation and T-wave inversion in the precordial leads. A moderate-sized pericardial effusion was seen on echocardiography. In the emergency department, his cardiac-enzyme levels were found to be normal. On echocardiography was seen increased left chambers with left ventricle systolic deficit and increased pericardial fluid. MRI there was no myocardial fibrosis, and the myocarditis hypothesis was declined. A laboratory panel was obtained which was significant for a thyroid stimulating hormone level of 150 mIU/mL and free T4 0.28 ng/dL, confirming the diagnosis of primary hypothyroidism, prompting initiation of levothyroxine. The patient was temporarily treated with ibuprofen and colchicine for pericarditis.

Discussion

Pericardial effusion is reported to occur in 30% to 80% of subjects with hypothyroidism. Thyroid hormones influence homeostasis, altering cardiac output, contractility and blood pressure. Pleural effusion in myxedema leads to restriction of ventricular filling and bradycardia, observed in T3 deficiency, decreasing cardiac output. The screening of pregnant with risk factors and the effective management of cardiac abnormalities aims to improve prognosis and survival.

#47 - Abstract

MANAGEMENT OF TYPE 2 DIABETES IN ELDERLY PATIENTS – 6 MONTHS STUDY IN GERONTOLOGY INSTITUTE

Lazo Jordanovski, Dima Ilievski, Despina Milosevska Evrushoska, Jovanka Jakimovska

PHI Specialized hospital for geriatric and palliative care 13 November, Skopje, Macedonia, Former Yugoslav Republic of

Background

With increasing lifespan of patients, the prevalence of diabetes mellitus is also increasing. The treatment of diabetes in the elderly should be individualized. Glycemic values depend on the risk factors of the individual, and are based on his overall health as well as the planned survival period.

Methods

We created a study in order to see which dual therapy will lead to best reduction in HbA1C values in elderly patients.

Results

100 elderly patients in the study divided in 5 groups each within 20 patients. Average age of the patients was 70.26 years and patients were previous treated with diabetes for 150.4 months. Average HbA1C at the beginning level was 8.24 %. First group was treated with metformin and second generation sulfonylurea, second group metformin and DPP4 inhibitor, third group metformin and GLP-1 receptor agonist, fourth group only insulin and the last group metformin and insulin. After 6 months there was overall decreasing in HbA1C level in all groups (7.48%). In the first group decreasing was 0.34%, second 0.47%, third 0.66%, fourth 0.98% and last group 1.34%. 9 patients have hypoglycemic event, 13 patients have increased weight from the beginning, 28 patients have been hospitalized because of worsened health condition. Individually 13 patients after 6 months haven't decreases of HbA1C. These patients have several comorbidities.

Conclusion

Biggest reduction in HbA1C level is noticed when patients are using metformin and insulin therapy but care should be taken when titrating insulin therapy because hypoglycemia in elderly patients may be severe or unrecognized.

#72 - Abstract

RETROSPECTIVE ANALYSIS OF PATIENTS WITH GRAVES ORBITOPATHY TREATED BY PULSES OF METHYLPREDNISOLONE, WITH A FOCUS ON ADVERSE EVENTS

Jan Schovanek, Lubica Cibickova, Zdenek Frysak, David Karasek
Department of Internal Medicine III – Nephrology, Rheumatology, and Endocrinology, Faculty of Medicine and Dentistry, Palacky University Olomouc and University Hospital Olomouc, Olomouc, Czech Republic

Background

Graves orbitopathy (GO) is an extra-thyroidal manifestation of autoimmune thyroid disease. Early treatment with glucocorticoids in appropriately selected patients is recommended for active, moderate to severe, and sight-threatening disease. The recently published European Group on Graves Orbitopathy guidelines re-evaluated the recommended doses of intravenous methylprednisolone (ivMP) in response to the potential for adverse effects. We retrospectively reviewed our patient cohort treated with our ivMP protocol and analyzed the side effects of this treatment when given during hospitalization in our tertiary referral center.

Methods

Between May 2007 and May 2017, a total of 171 consecutive patients with active, moderate to severe, or sight-threatening GO were treated with ivMP in a cumulative dose of 7.5 grams, given monthly in three hospital sessions. Adverse events were reported using Version 4 of Common Terminology Criteria for Adverse Events.

Results

Ninety-two percent of patients who started the treatment were able to finish it; 5% did not finish the study due to adverse events, and 3% did not finish the treatment protocol because of noncompliance. The most common adverse events were asymptomatic changes in laboratory values (liver enzymes), psychiatric disorders, and infectious complications. None of the patients in the study died during the ivMP treatment, including those patients who experienced adverse effects or discontinued the protocol because of noncompliance.

Conclusion

High-dose ivMP for active, moderate to severe, and sight-threatening GO, when applied cautiously in carefully selected and monitored patients, is generally safe during the treatment period.

This study was supported by the Ministry of Health, Czech Republic—Conceptual Development of Research Organization (FNOL, 00098892).

#88 - Abstract

OUTCOMES OF HOSPITALIZED PATIENTS WITH GLUCOCORTICOID-INDUCED HYPERGLYCEMIA

Neele Delfs, Sandra Gafner, Thaddäus Muri, Ciril Bächli, Philipp Schütz, Claudine Blum

Medical University Clinic Kantonsspital Aarau, Aarau, Switzerland

Background

Glucocorticoid-induced hyperglycemia is a frequent side effect in hospitalized patients. Guidelines recommend treat-to-target treatment of glucocorticoid-induced hyperglycemia between 6–10 mmol/l with insulin, but patient-specific outcome has not been well-studied.

Methods

In this retrospective data analysis, all patient records of a Medical University Clinic from January 2014 to April 2018 were screened for glucocorticoid administration. We investigated the incidence of hyperglycemia in hospitalized patients after administration of at least 10 mg prednisolone equivalents daily for at least 3 days. Mortality, cardiovascular events, and infections until 30 days after discharge in patients with or without hyperglycemia were evaluated.

Results

2424 hospitalized patients received systemic glucocorticoids. 623 patients (26%) developed fasting hyperglycemia, and 656 (27%) postprandial hyperglycemia. Glucocorticoid-induced hyperglycemia therefore had an incidence of 34% (812 patients). 511 patients (21%) had a previous diabetes diagnosis. In-hospital hypoglycemia was documented in 45 (1.9%) patients. In-hospital mortality was 46 (2.9%) in patients without

hyperglycemia and 32 (3.9%) in patients with hyperglycemia (OR 1.37 (0.85–2.15), $p=0.18$). Mortality until 30 days after admission was 121 (7.5%) in patients without hyperglycemia, and 70 (8.6%) with hyperglycemia (OR 1.162 (0.85–1.58), $p=0.34$). Cardiovascular events during hospitalization occurred in 155 (9.6%) in patients without hyperglycemia, and 112 (13.8%) in patients with hyperglycemia (OR 1.5 (1.16–1.95), $p=0.002$).

The combined endpoint death, cardiovascular and infections event at day 30 after admission was reached in 584 (25%) patients without hyperglycemia and 372 (16%) with hyperglycemia (OR 0.57 (0.49–0.66), $p<0.0001$).

Infections during hospitalization occurred in 263 (16%) patients without hyperglycemia, and in 170 (21%) patients with hyperglycemia (OR 1.35 (1.09–1.68), $p=0.059$).

Conclusion

Mortality, cardiovascular events and rate of infections were higher in patients with glucocorticoid-induced hyperglycemia than in normoglycemic patients. Rate of in-hospital hypoglycemia rate was low. Whether the treatment of glucocorticoid-induced hyperglycemia has an effect on outcome remains to be shown.

#101 - Abstract

FOUR DECADES WITHOUT DIAGNOSIS: SHEEHAN'S SYNDROME, A RETROSPECTIVE ANALYSIS

Gulistan Alpagat¹, Deniz Gokalp²

¹ Inegol Country Hospital, Bursa, Turkey

² Acibadem University, Eskisehir, Turkey

Background

Sheehan's syndrome (SS) remains a frequent cause of hypopituitarism in undeveloped and developing countries, but due to improvements in obstetric care, it is rare in developed countries. We aimed to retrospectively evaluate the characteristic of SS patients who were diagnosed in our clinic.

Methods

The medical records of 124 patients with SS patients who were followed up in the Endocrinology Department of Dicle University between 1995 and 2015 were assessed retrospectively.

Results

The mean period of diagnostic delay was 20.37 ± 8.34 years on average. 5.7% of patients with SS were literate; 62% of patients delivered at home. Anemia was identified in 64.5% of SS patients. 25 (23.3%) had partially empty sella, and 1 patient had microadenoma and 2 had normal pituitary MRI urgently required to avoid the associated morbidity and mortality.

Mean blood sodium levels were 129.8 ± 11.3 mEq/L. The mean urine densities was 1013 ± 6.5 . Osteoporosis and osteopenia were found in 44 (35.4%) and 71 (57.2%) patients, respectively. According to pituitary MRI analyses, 92 (74.2%) patients with

SS had completely empty sella, (23.3 %) had partially empty sella, and 1 patient had microadenoma and 2 had normal pituitary MRI results.

Conclusion

Improved obstetric care and effective interventions for postpartum hemorrhage have limited the prevalence of SS in developed countries. However, in developing countries like Turkey, SS due to postpartum bleeding remains common. Thus, physician's awareness of the symptoms of SS is urgently required to avoid the associated morbidity and mortality.

#113 - Abstract

RELATIONSHIP OF LEFT VENTRICULAR HYPERTROPHY AND INFLAMMATION IN TYPE 2 DIABETES

Ergita Nelaj, Margarita Gjata, Irida Kecaj, Mihal Tase
University Hospital Center, Tirana, Albania

Background

Type 2 diabetes is associated with accelerated atherosclerosis and increased cardiovascular event rates. The association between diabetes and adverse cardiovascular outcome may be partially explained by the strong independent association of type 2 diabetes with cardiovascular target organ damage, such as left ventricular hypertrophy (LVH), a well-known predictor of cardiovascular events independent of coronary artery disease. We recently reported an independent association of LVH with an elevated fibrinogen level. Inflammation, and in particular elevated fibrinogen, is associated with the development of atherosclerosis and consequent vascular events.

The aim of the present study is to evaluate the relation of LVH to fibrinogen and C-reactive protein (CRP) as markers of inflammation and susceptibility to atherothrombosis.

Methods

We selected 50 adults with type 2 diabetes. 32 were women and 18 were men, mean age 51±14).

Left ventricular (LV) dilatation was determined as cavity volume > 90 ml/m². LV hypertrophy (LVH) was determined by mass index > 110 g/m² in females and > 131 g/m² in males. Concentric LVH (LVHc) has been determined as hypertrophy with normal cavity volume.

Eccentric LVH (LVHe) has been determined as hypertrophy with LV dilatation.

Participant's laboratory data were examined in the morning after an overnight fast 12 h. The levels of CRP and fibrinogen have been measured.

Results

From 50 participants, 22 (44%) presented LVH, which was associated with higher BMI and CRP, fibrinogen levels. Patients with concentric LVH had level of fibrinogen 444±100 mg/dl (P<0.001)

and CRP 15 ± 9 mg/dl (P=0.005), and patients with normal LV mass had fibrinogen 360 ± 66 mg/dl and CRP 6,5 ± 9.0 mg/dl.

Conclusion

The results of the ultrasound heart examinations show: 22 patients presented concentric LVH, 10 patients eccentric LVH, and 18 patients normal LV mass.

Concentric LVH was associated with elevated markers of systemic inflammation and susceptibility to atherothrombosis (CRP and fibrinogen levels) independently of clinically overt cardiovascular disease and traditional cardiovascular risk factors. No correlation was found between CRP and fibrinogen and eccentric LVH.

#139 - Case Report

WHAT A STORM!

Iolanda Oliveira, Sofia Calaça, Mariana Soares, Andreia Bernardino, Francisco Azevedo
Hospital Espírito Santo - Évora, Évora, Portugal

Introduction

Thyroid storm represents a state of thyrotoxicosis that is an endocrine emergency. It is rare, but it is associated with high mortality. It is manifested by the decompensation of various organs and the onset of fever is universal. It is important to investigate the precipitating cause and correct it. The treatment besides support, consists in the reduction of thyroid hormone synthesis and its peripheral effects.

Case description

Female, 84 years old, caucasian, with atrial fibrillation, hypertension, goiter with colloid nodule, and total bilateral knee prosthesis, medicated with diltiazem 60 mg tid, carvedilol 6.25mg bid, apixaban 2.5mg bid and pantoprazole 20mg qd, without known allergies, was admitted in emergency department for dyspnea for small efforts with 2 weeks of evolution, pain in the bilateral neck region with irradiation to the shoulders, intensity 5/10 without relieving or aggravating factors. On observation: BP 198/121 mmHg, HR 145 bpm. EKG: AF with rapid ventricular response. After amiodarone impregnation, she presented sudden dyspnea, exuberant bronchospasm, poor peripheral perfusion, hypertensive peak with SBP 200mmHg and fever of 39°C. Analyses: immeasurable TSH and fT4 1.887 ng/dL. Thyroid storm was admitted, medicated with Hydrocortisone, Propranolol and Propylthiouracil. During the hospital stay she underwent thyroid ultrasound: multiple nodules without suspicious characteristics. She was medicated with 7 day antibiotic course with Ceftriaxone for respiratory tract infection and was discharged 7 days later. Analysis: TSH 0.009 µUI/mL, fT4 3.691 ng/dL, fT3 2.8 pg/mL, medicated for outpatient with Propranolol 40mg qid, Thiamazol 15 mg tid, with scheduled Internal Medicine consultation.

Discussion

Thyroid storm can be precipitated by several factors, like infection,

pregnancy, myocardial infarction or, like in this case, with iodine drugs use such as amiodarone. Prompt recognition is crucial for the patient's therapeutic success and prognosis. In this case, symptomatic control was achieved by using drugs which inhibited hormone synthesis and its peripheral effects.

#148 - Abstract

CLINICAL PROFILE OF DIABETIC PATIENTS WITH HEART FAILURE IN A COUNTY HOSPITAL

Julio Osuna Sánchez¹, Antonio Ubiña Carbonero²

¹ Hospital Comarcal Melilla, Melilla, Spain

² Centro Salud San Andres-Torcal, Málaga, Spain

Background

Carry out a retrospective descriptive study of diabetic patients admitted for heart failure in the Internal Medicine service of our hospital during 2017.

Methods

This is a transversal descriptive analysis of patients admitted to internal medicine for heart failure in 2017 who were diabetic. A detailed study was carried out of all the risk factors presented by patients, the associated comorbidities, as well as personal history. We have analyzed the release reports of our service along with the review of medical records. A descriptive study of the characteristics of patients using frequency measurements has been carried out, analysing the type of sample to see whether or not they remained normal.

Results

There were a total of 120 patients admitted for heart failure, of which 45.8% were diabetics. The average age was 77.47±9.17 years. 9.1% of patients were institutionalized, 18.2% were dependent for all basic activities of daily life. 52.7% were Caucasians and 47.3% Berber. 83.6% had social security. Regarding personal history: 32.7% prior ischemic heart disease; 83.6% HBP; 34.5% A-fib; 9.1% COPD; 38.2% dyslipidemia; 10.9% sleep apnea; 12.7% anemia; prior stroke 10.9% and 10.9% neoplasia (active or not). The most frequent causes of admission were the ischemic cause with 42.9% and valvulopathy with 32.1%. As an important finding 9.1% of patients had cognitive impairment to some degree. 92.7% of patients had 2 or more pathologies at the time of admission. The most frequent medication prescribed was metformin with a DPP-4i (41.2%), followed by metformin (17.6%). 40% patients were treated with insulin. The average stay of the hospital admission was 9.38±7.043 days, being exitus 12.7% of the patients.

Conclusion

Heart failure (HF) is a problem for both public health and the doctor who must face it daily. Once diagnosed, the prognosis becomes ominous as approximately 50% of patients die within the next 5

years. Early diagnosis and treatment of HF is important to prevent its complications, slow its evolution, decrease its symptoms and avoid the need for hospitalizations once the diagnosis is confirmed. This situation gets worse when as a comorbidity we add DM, making it harder to manage and the morbidity and mortality is higher. Patients admitted for acute HF with diabetes mellitus have a pluripatological profile with multiple added diseases which makes them patients with more complicated management in the plant and to whom we should perform a closer follow-up due to higher mortality rate.

#160 - Case Report

AMIODARONE-INDUCED HYPERTHYROIDISM: THE ENDOCRINOLOGIST'S PERSPECTIVE OF A CLINICAL CASE

Patrícia Rosinha, Rosa Dantas, Teresa Azevedo, Isabel Inácio, Sara Esteves Ferreira, Joana Guimarães

Endocrinology Department, Baixo Vouga Hospital Center, Aveiro, Portugal

Introduction

The diagnosis, classification and follow-up of amiodarone-induced thyrotoxicosis (AIT) are challenging. The risk of cardiac injury imposes the need for rapid control of thyrotoxicosis, which might require not only pharmacological therapy but also an emergent thyroidectomy.

Case description

A 67-year-old male with history of hypertension and previous episode of atrial flutter with rapid ventricular response, submitted to electrical external cardioversion (EEC) in 2015, on treatment with rivaroxaban 20 mg/day and amiodarone 200 mg 5 days/week, presented to the Emergency Department on 16th August 2017 complaining of dyspnea for the last 3 weeks. At admission, the EKG showed atrial fibrillation (150-160 beats/min). He underwent chemical cardioversion with amiodarone, unsuccessful, and so EEC was performed and the patient was discharged. A few hours later, he returned with dyspnea, fever (38,8 degrees C), and was admitted with the diagnosis of pneumonia with pleural effusion. Diagnostic thoracocentesis revealed transudate, after which he was transferred to Cardiology. Initial evaluation revealed hyperthyroidism (TSH<0.01 mU/L; FT4 6.19 ng/dL), negative thyroid antibodies and a diffusely heterogeneous thyroid without nodules on ultrasound. Methimazole 5mg and prednisolone 40 mg were initiated with analytical improvement (FT3 3,0nmol/L; T4 4.92ng/dL). Two days later, a new episode of tachycardia and hypertension lead to the reintroduction of amiodarone, with repercussion on thyroid function (TSH <0.01 mU/L; FT4 6.65 ng/dL). Amiodarone was only temporarily withdrawn, due to the difficulty in controlling heart rate. The drug was definitely dropped on 28th August, in face of the worsening of the hyperthyroidism and unresponsiveness to the medical treatment with prednisolone 80 mg/day and methimazole 60 mg/day. Attending to the difficulty

in controlling heart rate (patient already under verapamil 240 mg, bisoprolol 20 mg, digoxin 250 µg daily) and the occurrence of life-threatening arrhythmias, the medical team decided for total thyroidectomy after EEC, performed on 29th September, with cardiac improvement and rapid control of thyroid function. He was discharged under levothyroxine 100 µg, bisoprolol 2.5mg and weaning doses of prednisolone.

Discussion

Due to the difficulty in classifying the type of thyrotoxicosis and deciding which patients should suspend amiodarone therapy, a successful treatment depends on a multidisciplinary approach for these patients.

#163 - Abstract

EFFICIENCY OF ASPIRATIVE CYTOLOGY OF THYROID IN A DISTRICT HOSPITAL: 2014-2017

Sócrates Vargas Naranjo, Rúben Raimundo, José Miguel Silva, Adriano Pacheco, Ana Bela Mateus, Isabel Soles
Hospital Dr. José Maria Grande, Portalegre, Portugal

Background

The thyroid nodules are common as 5% -10% of adult population. The aspiration cytology by fine needle (FNA), can identify 50% or more, of malignant nodules, having positive (VPP) and negative (VPN) values higher than 90%; However, around 35% do not present a definitive diagnosis, so that, we want to validate the effectiveness of FNA to identify malignant thyroid nodules.

Methods

We conducted a cross-section study, in which patients submitted to thyroidectomy were identified between 2014 and 2017. A subsequent observation of FNA and histological results was made. The variables analyzed were sex, age, ultrasound characteristics, cytological and histological diagnosis. SPSS 20.0 was used for statistical analysis. With statistical description, central and dispersion measures were calculated; by Bayes' theorem to identify Sensitivity (Se), Specificity (Sp), VPP and VPN and Efficiency (Ef) for the FNA; The statistical significance used was 0.05.

Results

Identification of 55 patients with thyroidectomy, but 71.0% (n=39) of them had FNA and biopsy results. We observed mostly women (n=37, 94.9%); the average age was 54.2 years (men 48.5 and women 54.5, alpha = 0.419), parameter 32-71 years. TI-RADS scale was not used, despite it, we observed that 66.7% of the ultrasounds had 2 or more nodules and 17.9% of adenopathies. The malignant samples were observed in 7.7% (n=3) with FNA and 10.3% (n=4) with histological samples. FNA showed Se=50.0%, Sp=96.7%, PPV = 66.7%, NPV=93.5% and Ef=91.2%.

Conclusion

In our hospital, the FNA results were within values from other studies, yet, although FNA shown good efficacy, the low VPP can be influenced by the little sample the was used. Is important that TI-RADS scale was not used, because it is a problem if we try to comparisons with others studies.

#196 - Case Report

A CASE OF B12 DEFICIENCY POLYNEUROPATHY IN A DIABETIC YOUNG ADULT

Adriana Bandeira, Diana Castro, Behnam Moradi, Alcina Ponte
Centro Hospitalar de Leiria, Leiria, Portugal

Introduction

Vitamin B12 is an essential dietary nutrient and plays a fundamental part in hematopoiesis and in the maintenance of the integrity of the nervous system. Below we report a case of B12 malabsorption due to intrinsic factor deficiency presenting as polyneuropathy and bicytopenia in a young adult with a diabetes diagnosis of unclear etiology.

Case description

A 44-year-old male patient, with recently diagnosed diabetes with poor metabolic control despite a daily cumulative dose of 40 U aspart insulin, is referred to the hospital due to a 2 months history of insidious onset paresthesias, starting at the soles of the feet ascending to the inguinal region. When questioned patient mentioned transient complaints of nocturnal paresthesias at the hand level, dysesthesia and proprioceptive changes in both feet. In addition, he describes episodes of spontaneous bladder incontinence and constipation. No complaints of dysphagia, no other relevant history. Physical exam revealed pale, mildly icteric and malnourished patient, grade 3 distal muscle strength, errors in the positioning of both hallux and ataxic gait, of right predominance. Initial blood work revealed bicytopenia with erythrocyte macrocytosis and anisopoikilocytosis, platelet anisocytosis, elevated LDH and bilirubin with a negative DAT and IAT. Of the tests conducted we highlight: severe vitamin B12 deficiency and positive IF antibodies suggesting pernicious anemia as well as positive GAD antibodies and so LADA was inferred. MRI showed T2 and STIR hypersignal extending from C1 to D11, with greater expression in the dorsal segment and no spinal expansion or signal enhancement after gadolinium; normal EMG. Upper endoscopy revealed an atrophic and micronodular gastric mucosa, histologically compatible with chronic gastritis with lymphocytic infiltrate, negative H.pylori. The patient was treated with a course of intramuscular injections of cyanocobalamin followed by oral supplementation and adjustment of the insulin therapy.

Discussion

In this case, the implementation of the B12 supplementation followed by clinical improvement excludes diabetic neuropathy

as a probable cause of patient symptoms. Pernicious anemia is estimated to be more frequent in patients with diabetes, whether due to the use of metformin in T2DM, or, in this case (LADA/T1DM) due to the common presence of IF antibodies in patients with positive GAD antibodies - the latter leading to an association of autoimmune conditions and development of autoimmune polyglandular syndromes.

#200 - Abstract

DEVELOPMENT AND MULTI-COHORT VALIDATION OF A CLINICAL SCORE FOR PREDICTING TYPE 2 DIABETES MELLITUS

Vanessa Kraege¹, Marie Mean¹, Stephen Sharp², Maite Vallejo³, Masoud Mirzaei⁴, Pedro Marques-Vidal¹

1. Department of Medicine, Internal Medicine, Lausanne University Hospital, Lausanne, Switzerland
2. MRC Epidemiology Unit, University of Cambridge School of Clinical Medicine, Box 285 Institute of Metabolic Science, Cambridge Biomedical Campus, Cambridge, United Kingdom
3. Tlalpan 2020 Study, Department of Socio-Medical Research, National Institute of Cardiology, Ignacio Chávez, Mexico City, Mexico
4. Shahid Sadoughi University of Medical Sciences, Yazd, Iran

Background

Many countries lack resources to identify people at risk of developing Type 2 diabetes mellitus (diabetes). We aimed to develop and validate a diabetes risk score based on easily accessible clinical data.

Methods

Prospective study including 5277 participants (55.0% women, 51.8±10.5 years) free of diabetes at baseline. The selection of the variables to be included in the score was performed using logistic regression, and scoring was based on the multivariable-adjusted odds ratio for each variable. To facilitate scoring, categories were preferred to continuous data. Comparison with two other published diabetes risk scores (the first with five and the second with eight clinical variables) and validation on three cohorts: Europe (n=61,595), Iran (n=9975) and Mexico (n=1203) was performed.

Results

After a mean follow-up of 10.9 years, 405 participants (7.7%) developed diabetes. Our score was based on age, gender, waist circumference, diabetes family history, hypertension and physical activity. The area under the curve (AUC) and corresponding 95% confidence interval (95% CI) was 0.772 (0.750-0.794) for our score, vs. 0.748 (0.726-0.770) (p<0.001) and 0.774 (0.753-0.796) (p=0.668) for the other two. Using a 13-point threshold, sensitivity, specificity, positive and negative predictive values (95% CI) of our score were 60.5 (55.5-65.3), 77.1 (75.8-78.2), 18.0 (16.0-20.1) and 95.9 (95.2-96.5) percent, respectively. The number needed to screen to detect one case of diabetes was 22 for our score vs. 129

for the first score and 20 for the second. Despite differences in the definition of some variables such as physical activity, our score performed equally well or better than the other two in the Iranian [AUC 0.542 vs. 0.564 (p=0.476) and 0.513 (p=0.300)] and Mexican [AUC 0.791 vs. 0.672 (p<0.001) and 0.778 (p=0.575)] cohorts. In the European cohort, it performed similarly to the first score but worse than the second [AUC 0.788 vs. 0.793 (p=0.091) and 0.816 (p<0.001)].

Conclusion

Our clinically-based score shows encouraging results compared to other scores and can be used in populations with differing diabetes prevalence.

#202 - Abstract

EVALUATION OF CARDIOVASCULAR RISK WITH ARTERIAL STIFFNESS IN PATIENTS WITH NON-FUNCTIONING PITUITARY ADENOMA

Yavuz Çağır¹, Mustafa Altay², Büsra Betül Çağır³, Erman Çakal⁴, Tolga Akkan⁵, Canan Yıldız⁵

1. Çankiri Çerkes State Hospital, Çankiri, Turkey
2. Sağlık Bilimleri Üniversitesi (University of Health Sciences) Keçiören SUAM, Department of Endocrinology and Metabolism, Ankara, Turkey
3. Sağlık Bilimleri Üniversitesi (University of Health Sciences) Diskapi Yildirim Beyazit SUAM, Department of Internal Medicine, Ankara, Turkey
4. Sağlık Bilimleri Üniversitesi (University of Health Sciences) Diskapi Yildirim Beyazit SUAM, Department of Endocrinology and Metabolism, Ankara, Turkey
5. Sağlık Bilimleri Üniversitesi (University of Health Sciences) Keçiören SUAM, Department of Internal Medicine, Ankara, Turkey

Background

Nonfunctioning pituitary adenoma (NFPA) accounts for 30% of all pituitary adenomas, and its incidence has been increasing compared to previous years. Increased risk of cardiovascular effects shown in recent studies is noteworthy in patients with NFPA diagnosis, but the number of studies on the subject is limited. In this study, we aimed to assess possible cardiovascular effects and risk via arterial stiffness measurements in patients diagnosed with NFPA.

Methods

We performed arterial stiffness measurements for 30 patients diagnosed with NFPA and 30 healthy volunteers and compared the results to explore the relationship between arterial stiffness parameters, hormone levels, and adenoma size.

Results

Systolic blood pressure (SBP), diastolic blood pressure (DBP), mean blood pressure (MBP), central SBP, central DBP, augmentation index corrected for a heart rate of 75 beats per minute (AIx@75),

and pulse wave velocity (PWV) values of the patients with NFPA diagnosis were significantly higher than the control group. PWV was found to have a significant and negative correlation with growth hormone and insulin-like growth factor 1 (IGF-1). A significant and positive correlation was found between adenoma median short-axis length and PWV. IGF-1 was found to have a significant and negative correlation with adenoma median long- and short-axis length. In multivariate linear regression analysis, we found that IGF-1 was an independent predictor of PWV.

Conclusion

Both arterial stiffness parameters such as Alx@75 and PWV and peripheral SBP, DBP, and MBP values were found to be high in NFPA patients with no cardiovascular risk factors. Our findings suggest increased cardiovascular effect and risk in patients with NFPA diagnosis, and therefore, we recommend that patients are monitored closely in this respect.

#212 - Abstract

VISCERAL FAT ACCUMULATION IN MALE PATIENTS WITH TYPE 2 DIABETES AND HEART FAILURE

Eva Hoskova, Jan Kopecky, Jiri Veleba, Katerina Velebova, Vojtech Melenovsky, Terezie Pelikanova

Institute for Clinical and Experimental Medicine, Prague, Czech Republic

Background

Metabolic effect of visceral fat accumulation is connected with insulin resistance and type 2 diabetes (T2D) with its complications. Specifically android type of body fat accumulation is associated with high cardio-metabolic risk. Our aim was to evaluate the associations between the location of fat accumulation, heart failure (HF) and T2D.

Methods

A cross-sectional comparative trial with 53 male subjects in 4 age and BMI matched groups - 10 patients with HF without diabetes (HF+T2D-), 11 patients with diabetes alone (HF-T2D+), 19 patients with type 2 diabetes or prediabetes and heart failure (HF+T2D+) and 13 healthy subjects without metabolic syndrome (HF-T2D-). The patients underwent number of laboratory tests including lipid profile, insulin sensitivity measured as metabolic clearance rate of glucose (MCG) during a hyperinsulinemic isoglycemic clamp, and dual-energy X-ray absorptiometry (DEXA) using a GE Lunar Prodigy.

Results

MCG was lower in the groups of patients with T2D compared to HF-T2D- ($p=0.01$), while HF did not affect MCG significantly (HF-T2D-: 5.79 ± 2.3 ; HF+T2D-: 5.99 ± 2.48 ; HF-T2D+: 3.4 ± 1.57 ; HF+T2D+: 3.73 ± 1.71 ml/kg.min). Despite there was the significant negative correlation between MCG and percentage of android fat in the whole group ($r=-0.49$; $p<0.001$), we did not found any

difference in android/gynoid fat percent ratio between the groups (HF-T2D-: 1.34 ± 0.11 ; HF+T2D-: 1.3 ± 0.15 ; HF-T2D+: 1.36 ± 0.15 ; HF+T2D+: 1.32 ± 0.2).

Conclusion

Insulin sensitivity was significantly affected by type 2 diabetes, but not by heart failure. Diabetes or heart failure did not significantly alter the body fat distribution in our carefully selected BMI and age matched groups.

Supported by AZV16-27496A

#277 - Abstract

STUDY OF CUTANEOUS SURROGATE OF VISCERAL ADIPOSITY AMONG INDIAN PHENOTYPE

Ananda Mohan Chakraborty, Soumitra Ghosh, Srabani Ghosh
IPGMR, Kolkata, India

Background

Appraisal of certain cutaneous markers may lead clinician to ascertain underlying pathology well before its clinical manifestation. Obesity and consequent insulin resistance and dyslipidaemia may lead to cutaneous manifestations like Acanthosis nigricans (AN) and xanthelasma. Visceral adiposity viz Hepatic steatosis, epicardial adipose tissue, are the major determinants of organ dysfunction. Objective of the present study is to study the association between AN, xanthelasma and cutaneous adiposity with visceral adiposity.

Methods

A cross-sectional observational study was conducted among overweight and obese patients determined by South East Asian BMI criteria. Visceral fat was determined by impedance body composition measurement, presence of hepatic steatosis, and Epicardial adipose tissue thickness (EAT). Acanthosis nigricans, xanthelasma, subcutaneous fat, and region-specific fat thickness was considered as cutaneous surrogate of adiposity.

Results

Among 149 patients studied, 28% had AN, 21% had Xanthelasma, 77% had hepatic steatosis and 78 % had excess visceral fat. Mean EAT was 6.12 mm (SD: 1.830). Subcutaneous fat had statistically significant relation with visceral fat (Chi-squared (trend) 12.460; $P=0.0004$) but not with EAT ($P=0.2172$) and presence of hepatic steatosis (Chi-squared (trend) 1.809; $P=0.1786$). Both the cutaneous surrogate had statistically significant association with Visceral fat percentage (two tailed t test, $P<0.0001$) and EAT (two tailed t test, $P<0.0001$). Among all the regional distribution of fat, only subscapular ($P=0.032$) and supra-iliac fat ($P=0.034$) had statistically significant relation with EAT.

Conclusion

Cutaneous surrogate like AN and Xanthelasma was a predictor of

visceral adiposity in this study. Among regional distribution of fat instead of waist circumference and waist hip ratio, subscapular and supra-iliac fat was related with EAT. Study of cutaneous surrogate like AN and xanthelasma, skinfold thickness can predict visceral adiposity early which is of immense importance in resource poor country like India.

#288 - Case Report

FAHR SYNDROME: CASE REPORT

Raquel Costa, João Costelha, Tiago Mendes, Joana Fontes, Marta Matos Pereira, Vitor Costa, Manuel Barbosa, Elsa Araújo, Joana Serôdio, Liliana Costa

ULSAM - Hospital Conde de Bertandos, Ponte De Lima, Portugal

Introduction

Fahr syndrome is a rare, chronic disease characterized by bilateral and extensive deposition of calcium in the basal ganglia, thalamus, cerebral cortex, cerebellum and hippocampus, and neuropsychiatric manifestations. The most common metabolic cause of Fahr syndrome is hypoparathyroidism.

Case description

66-year-old woman with history of hypertension and dyslipidemia. The patient presented to the Emergency Department (EM) because of intense holocranial headache and nausea. Referring also paresthesias of the hands and feet with several months of evolution, mnesic changes and periods of uninhibited behavior. In the EM, the patient had a generalized convulsive crisis, being medicated with levetiracetam (1000 mg/day). She performed a cranioencephalic tomography that showed "calcifications of the basal ganglia, cerebellum and frontal region, extensive and bilateral". In the analytical study, severe hypocalcemia was detected and electrocardiographic alterations were also observed, with prolongation of the QT interval. She began calcium replacement, and there was normalization of electrocardiographic changes.

During hospitalization, the patient was diagnosed with primary hypoparathyroidism as the cause of hypocalcemia. Electroencephalogram confirmed the diagnosis of epilepsy. Thyroid and parathyroid ultrasonography were normal. She was discharged for the consultation of Internal Medicine and Endocrinology for the etiological study of hypoparathyroidism. The patient had a favorable evolution and no new seizures in the last year.

Discussion

Fahr syndrome, although rare, should incorporate the list of differential diagnoses of neuropsychiatric disorders and epileptic seizures. The calcifications of the basal ganglia, despite being a suggestive finding of an evolved disease, may be an imaginative finding of enormous value since they can immediately guide the diagnosis and allow rapid treatment of hypocalcemia and hypoparathyroidism.

#292 - Case Report

A CASE OF AUTOIMMUNE ADDISON'S DISEASE: THE IMPORTANCE OF EARLY DIAGNOSIS.

Elisa Martinelli

AOU Careggi (University Hospital Careggi), Florence, Italy

Introduction

the most common form of adrenal insufficiency is autoimmune adrenalitis. It is, more often than not, associated with other autoimmune disorders, such as Hashimoto thyroiditis, Graves' disease or celiac disease.

The autoimmune destruction of the adrenal gland is usually a slow process that develops over many years and by the time the patient develops low serum cortisol levels (necessary for the diagnoses) adrenal destruction is essentially complete. Nevertheless several symptoms can occur early on in the disease and Addison's should always be taken in to consideration while working on the differential diagnosis in patients presenting fatigue, weight loss and gastrointestinal complaints, depression and electrolyte disorders (specifically hyperkalaemia and hyponatremia). A failure to recognize the disease can lead to devastating consequences, such as shock and coma, two possible outcomes of an adrenal crisis.

Case description

a 63 year old woman, with a history of Hashimoto disease, diabetes, psoriasis and asthma was admitted to the ER lamenting nausea, fatigue and anorexia. Her blood test showed severe hyperkalaemia, hyponatremia and metabolic acidosis. The patient had been admitted to the ER 4 times over the previous year, each time presenting the same signs and symptoms. Upon her arrival the patient was hypotensive. She manifested a lack of initiative and apathy and presented hyperpigmentation of the back and legs. Given that her clinical picture was highly suggestive of adrenal insufficiency her morning cortisol (76,2 nmol/L at 08:00 am) and ACTH (539,50 ng/L) were measured and tested for antiadrenal antibodies which resulted positive. To further confirm our diagnosis, once the patient started specific treatment with hydrocortisone not only was there a normalization of the vital parameters and electrolytes, but also an improvement of her mood and initiative. The patient was discharged with the diagnoses of Addison's disease over a year from the first appearance of the symptoms.

Discussion

because of the nonspecific early signs and symptoms, chronic adrenal insufficiency can often be overlooked. Taking into consideration that this disease can be easily diagnosed and treated, but can also be potentially lethal if unrecognized, a rapid and correct interpretation of the clinical manifestations is fundamental to achieve the best possible outcome for the patient, by improving quality of life and reducing hospitalization.

#296 - Case Report

HASHIMOTO'S THYROIDITIS: A RARE AND SEVERE CLINICAL PRESENTATION

Filipe J. Machado, Rita Maciel

Centro Hospitalar Entre Douro e Vouga, Santa Maria Da Feira, Portugal

Introduction

Hashimoto thyroiditis is a chronic autoimmune thyroiditis that constitutes a major cause of acquired primary hypothyroidism. The clinical onset usually develops insidiously however, very uncommonly, severe untreated hypothyroidism may present with a myriad of simultaneous characteristic signs and symptoms, some of them extremely rare that urge attempted diagnosis and treatment.

Case description

We reported a case of a 68-year-old woman that was conducted to the emergency department with decreased mental status and facial oedema with periorbital swelling. On physical examination she was bradycardic and hypothermic. Facial oedema was confirmed and other fans and skin changes noticed. An hemogram and metabolic panel reported a pancytopenia (with normocytic normochromic anemia), creatinine kinase elevation, hyponatremia and hypercholesterolemia. Thyroid function tests were consistent with primary hypothyroidism and it was presenting with myxedema and myxedema coma. Intravenous levothyroxine replacement therapy was started. Thyroid ultrasound performed revealed signs supporting a thyroiditis process, with diffuse parenchymal heterogeneity, and thyroid peroxidase antibodies analysis was 411.31 UI/mL. It was established the diagnosis of Hashimoto's thyroiditis, the most common cause of primary hypothyroidism, with a rare exuberant clinical presentation.

Discussion

Primary hypothyroidism accounts for more than 95% cases of hypothyroidism and Hashimoto's thyroiditis accounts for the most common cause. The clinical manifestations of hypothyroidism are highly variable, depending upon the age at onset, duration and severity of thyroid hormone deficiency but usually develops insidiously. Our case report presents a rare exuberant presentation of hypothyroidism, with a myriad of clinical pearls that are rare and severe, such as myxedema and myxedema coma. The authors pretended to raise attention to the clinical manifestations of hypothyroidism so that clinicians can diagnose it timely and initiate treatment immediately.

#302 - Case Report

FROM VERTIGO TO CONN'S SYNDROME: ABOUT A CLINICAL CASE

Ana Correia De Sá, Ana Cerqueira, Liliana Oliveira, Rui Fernandes, Jorge Cotter

Hospital da Senhora da Oliveira, Guimarães, Portugal

Introduction

Conn's syndrome, also known as primary aldosteronism (PA), has been reported in >5-10% of hypertensive patients, englobing a group of disorders in which aldosterone production is inappropriately high for sodium status. It is relatively autonomous from the major regulators of secretion and thus, non-suppressible by sodium loading. This causes hypertension, cardiovascular damage, sodium retention, suppression of plasma renin and increased potassium excretion. Only a minority of patients with PA presents with hypokalemia. Hypertension and spontaneous or diuretic-induced hypokalemia is one of the cases when it is recommended to measure the plasma aldosterone/renin ratio (ARR). Moreover, all patients with PA should undergo adrenal computed tomography to exclude carcinoma. Unilateral laparoscopic adrenalectomy is recommended for patients diagnosed with unilateral PA.

Case description

A 60-year-old male was admitted for dizziness and vertigo, with imagiologic documentation of stroke in the posterior cerebral fossa (Oxford Stroke Classification – POCI; TOAST Classification -Small-vessel occlusion). He had a medical history of poorly controlled arterial hypertension under antihypertensive therapy (a beta receptor antagonist, a angiotensin receptor blocker, a calcium channel blocker and mineralocorticoid receptor antagonist) and occurrence of stroke at the age of 51 years. During his hospitalization he maintained a poorly controlled blood pressure and hypokalemia (initially of 2.69 mEq/L) refractory to the endovenous and oral supplementation. Moreover, blood measurement showed a high ARR of 978.31, with a plasma aldosterone concentration of 81.2 ng/dL. The MRI performed highlighted a 10 mm nodule in the right adrenal gland, whose characteristics were suggestive of adenoma. Two confirmatory tests were performed, namely saline infusion and captopril challenge test. Results obtained in both tests were consistent with Conn's syndrome. As a result, he was referred to general surgery for unilateral adrenalectomy. Prior to surgery, both hypertension and hypokalemia should be well controlled, so verapamil and spironolactone were added as therapeutic.

Discussion

This case aims at drawing attention to the importance of the accurate cardiovascular risk evaluation of a patient with stroke. The revision of the patient's risk factors, and further assessment and investigation, led to the final diagnosis.

#311 - Abstract

GLUCOSE DYNAMICS IN DIABETIC PATIENTS TREATED WITH GLP-1 RECEPTOR AGONISTS: IMPROVING THE YIELD OF CGM ANALYSISAna Colás¹, M. Augusta Guillén-Sacoto², Carmen Rodríguez², Borja Vargas², Paula González², Manuel Varela², Luis Vigil²¹ Hospital 12 de Octubre, Madrid, Spain² Hospital Universitario de Móstoles, Móstoles, Spain

Background

The introduction of Continuous Glucose Monitoring (CGM) systems into clinical practice has allowed a deeper understanding of glycaemic dynamics. In the present work:

We explore the effects of long-acting GLP-1 receptor agonists (GLP-1RA) on glucose dynamics through the analysis of glycaemia time-series.

We evaluate the potential role of two CGM-derived variables (percentage of time under 110 mg/dL -TU110- and area over the threshold of 180 mg/dL -AO180-) to classify patients according to the predominance of primary failure of tonic glycaemic control or of postprandial glucose excursions management.

We search for basal variables that may predict which patients would have a better response to GLP-1RA.

Methods

Seventeen patients with type 2 diabetes and poor metabolic control were included. A CGM system was implanted at inclusion before a GLP-1RA was introduced and after 6 months follow-up. Glucose Management Indicator (GMI) was calculated for each registry as an HbA1c estimation based on CGM data. Two dynamical variables were defined, reflecting tonic control (TU110) or postprandial excursions (AO180).

Changes in quantitative variables were evaluated by paired Wilcoxon. Correlation among changes in dynamical variables and changes in GMI and search for predictive variables were performed through Spearman's correlation analysis.

Results

Significant improvement was observed after the addition of GLP-1RA in both conventional variables (fasting blood glucose (FBG): 155 vs. 139 mg/dL, $p < 0.01$ and HbA1c: 7.5 vs. 6.6%, $p < 0.01$) and CGM-derived metrics (GMI: 6.75 vs. 6.56, $p = 0.02$; mean CGM glycaemia: 143.9 vs 136, $p = 0.01$ and TU110: 0.08 vs 0.17, $p = 0.05$). Despite a trend towards a fall in AO180, no statistical significance was reached.

Changes in both phasic (AO180) and tonic control (TU110) showed good correlation with GMI decrease ($\rho = 0.804$ ($p < 0.01$) and $\rho = 0.559$ ($p = 0.02$), respectively).

Basal AO180 displayed the best correlation with the change in GMI ($\rho = 0.744$, $p < 0.001$). Patients with higher basal AO180 showed a more pronounced change in GMI after GLP-1RA treatment.

Conclusion

The addition of GLP-1RA induced a significant metabolic improvement. CGM-metrics seem to be a good tool for the measurement of this response in our cohort of patients.

TU110 and AO180 may have a role in identifying the relative contribution of tonic/phasic control failure in patients with diabetes.

CGM-derived variables (mainly AO180) may help to identify more suitable candidates for GLP-1RA treatment.

#340 - Case Report

CHRONIC DIARRHEA: NOT ALWAYS SO SIMPLE

Catarina Cascais Costa¹, Joana Paixão², Joana Costa²

¹ Centro Hospitalar Baixo Vouga, Aveiro, Portugal

² Centro Hospitalar Universitário de Coimbra, Coimbra, Portugal

Introduction

Neuroendocrine tumors are originated in secretor cells in the diffuse endocrine system and may include a variety of subtypes such as pancreatic, gastrointestinal or pulmonary. Neuroendocrine tumors of the pancreas are the second most common solid organ tumor in the pancreas, yet rare, occur in about 1-2% of all patients with pancreatic lesions. One of the most common manifestations of carcinoid syndrome, associated with hormonal hypersecretion, is diarrhea.

Case description

The authors describe the clinical case of a 70-year-old male patient who is referred to the Internal Medicine appointment with diarrhea complaints with about 1 year of evolution, daily rhythm, pasty stools and associated fecal urgency and incontinence.

It is a patient with no relevant medical history. On objective examination he did not present alterations except a discrete weight loss of approximately 3kg in the last year. He performed an analytical and stool study, only highlighting the presence of elevation of chromogranin (618.5 ng / mL (N <85)), colonoscopy was normal and abdominal-pelvic CT scan that showed a nodular lesion of 11 mm, with peripheral enhancement in the tail of the pancreas. In this context PET scan was also performed and identified a neuroendocrine neoplastic lesion with high expression of somatostatin receptors. It was proposed for surgical evaluation and the presence of neuroendocrine tumor of the tail of the pancreas was confirmed in histological analysis.

Discussion

Pancreatic neuroendocrine tumors may have a wide range of clinical and imaging manifestations. They are rare, sporadic and tendentially solitary tumors. The only treatment that offers a cure is surgery, which highlights the importance of an early diagnosis for that we need a high degree of suspicion in patients, often with nonspecific complaints.

#342 - Case Report

MUCORMYCOSIS: A RARE COMPLICATION OF DIABETES

Mafalda Ferreira, Mariana Lavrador, Luciano Almendra, Helder Esperto

Centro Hospitalar e Universitário de Coimbra, Coimbra, Portugal

Introduction

Mucormycosis is an invasive and uncommon fungal infection caused by a fungus of the order of Mucorales, with *Rhizopus* being

the most commonly associated. It is an invasive and almost always lethal disease, with a mortality rate of approximately 40% to 60%. It affects preferentially immunocompromised individuals and may also occur in poorly controlled diabetic patients. It can present as cutaneous, pulmonary, renal or rhino-orbitocerebral forms, the latter being the most commonly diagnosed, reaching the nasal mucosa and adjacent structures.

Rhino-orbitocerebral mucormycosis is an emergency that requires aggressive surgical treatment with local debridement, antifungal therapy with amphotericin B and control of the underlying diseases.

Case description

A 65-year-old male, type 2 diabetic, poorly controlled with oral medication, who started complaining of pain and facial edema on the right side. He was initially diagnosed with a dental abscess and completed 7 days of oral antibiotic therapy with amoxicillin and clavulanic acid. There was a progressive worsening of the complains which led to the observation in the emergency department. He presented proptosis and complete ophthalmoplegia of the right eye, retinal necrosis and blindness of the right eye. CT imaging showed right ocular proptosis, periorbital soft tissue and right malar region swelling, ethmoidal and right sphenoid-maxillary sinus inflammation. He initiated amphotericin B, ceftriaxone and metronidazole 10 days after symptoms onset. Biopsy of the nasal fossae cultured *Rhizopus* spp. Subsequently, in the first days of hospitalization, neurological signs worsened, with new focal neurological signs. At this moment it was identified a lesion in the right hemi-palate with a necrotic fundus and a moldy appearance. Cranioencephalic MRI identified multiple ischemic lesions in the territory of the right internal carotid artery, as well as a direct invasion of the artery. Despite the treatment the patient died after 61 days of hospitalization.

Discussion

This case includes many distinctive characteristics of this pathology. Our images illustrate clearly the typical palate lesion as well as a widespread angioinvasion.

The clinical evolution of these patients is usually poor. This leaves the alert for potentially fatal complications in populations at risk, which if identified in a timely manner may modify its prognosis.

#351 - Case Report

WHEN DIABETES HIDES THE REAL PROBLEM

Jéssica Chaves, Carolina Morna, Catarina Nóbrega, Luís Marote Correia, Augusto Barros, Maria Da Luz Brazão

Hospital Central do Funchal, Funchal, Portugal

Introduction

Diabetes mellitus (DM) is characterized by hyperglycemia (HG) and various degrees of deficiency and insulin resistance. The main ethiological factors are the dysregulation of the pancreatic-hepatic axis caused by pancreatic beta cell dysfunction due

to an immunological attack (type 1) or after compensatory hyperfunctioning state to an insulin resistance (type 2). However other factors, such as metabolic dysregulation caused by neoplasias, may disrupt this axis leading to HG.

Case description

We present two case reports reflecting this phenomenon. The first one, a 55-year-old male patient was admitted after being observed in our emergency department (E.R.) for complains of lower limb oedema, dyspnea, asthenia, anorexia and weight loss (about 8 kg in one month). He was a heavy smoker (25 packs-year). He was diagnosed with type 2 DM and was medicated with canaglifozin in the previous two months. The physical exam revealed bilateral crepitations in the pulmonary auscultation, painful hepatomegaly, ascitis, lower limb oedema and caquexia. The blood work found glucose 352 mg/dl, K⁺ 2.4 mEq/L, GPT/GOT 809/541 U/L, γ GT 821 U/L, FA 285 U/L, and the computed tomography (CT) showed an heterogeneous left mediastinal mass sizing 8x6cm and an enlarged liver filled in numerous lesions suggesting metastasis. After bronchofibroscopy, a biopsy identified a small cell lung carcinoma. The second patient, a 57-year-old female was referenced to the E.R. for poor diabetic control by her attending general practitioner. She was medicated with metformin and linagliptin. At the admission she was tachypneic, pale and dehydrated. The epigastric palpation revealed a mass of hard consistency. The blood analysis showed pH 7.28 glucose 572 mg/dL, and hemoglobin 5.0 g/dL. After stabilizing the diabetic ketoacidosis, a CT found a 9x9cm tumor originating from the gastric antrum, invading surrounding structures. The biopsy was showed a moderately differentiated adenocarcinoma. Both patients were guided by Oncology.

Discussion

It is intended to emphasize that the diagnosis of a common pathology can hide a cause with important clinical and therapeutic implications. The presented cases demonstrate that a new onset of DM or the aggravation of a known DM justifies a careful study of its ethiology.

#354 - Abstract

FACTORS ASSOCIATED WITH MICRO AND MACROVASCULAR COMPLICATIONS IN TYPE 2 DIABETES PATIENTS

Cristina Carvalho Gouveia, José Guia, Vanisa Do Rosário, Vanda Jorge, Irene Verdasca, Patrícia Vicente, Luís Campos

Hospital de São Francisco Xavier, Centro Hospitalar de Lisboa Ocidental, Lisbon, Portugal

Background

Type 2 Diabetes mellitus (T2DM) is widely recognized as an emerging epidemic that has a cumulative impact on almost every country, age group and economy across the world. It is associated with microvascular (retinopathy, neuropathy and nephropathy) and macrovascular (peripheral arterial disease, cardiovascular

and cerebrovascular) complications, which are responsible for significant morbidity and mortality. We aim to study the possible factors associated with increased incidence of complications in a group of outpatients being followed in a diabetes clinic.

Methods

Retrospective study of outpatients with T2DM who were consulted in a diabetes clinic between January and December 2018. The population was separated according to the presence of complications associated to diabetes in 2 groups: A – T2DM with complications and B – T2DM without complications.

Results

99 patients were included. 55.6% (n=55) of them had complications: 52.7% had nephropathy, 32.7% ischemic heart disease, 20% cerebrovascular disease, 16.4% retinopathy, 14.5% peripheral artery disease and 11% of patients had neuropathy. Group A was older (71.1 vs B: 67.4 years-old), had a higher percentage of male patients (54.5 vs B: 27.3%), higher time since the diagnosis of diabetes (14.2 vs B: 11.5 years) and higher percentage of patients taking insulin (36.4 vs B: 27.3%). Additionally, group A had a higher prevalence of other cardiovascular risk factors (98.2 vs B: 90.9%), namely: dyslipidemia (87.3%), high blood pressure (81.8%), overweight and obesity (25.5%), tobacco and alcohol use (25.4%) and sedentary lifestyle (12.7%). Glycated hemoglobin was 7.3% in group A and 7.1% in B.

Conclusion

In our study, we only included patients who were already being treated for T2DM and its associated complications. Despite this, the prevalence of complications is noteworthy. The older age, male gender, longer time of disease evolution and presence of other cardiovascular risk factors seemed to be associated with increased incidence of complications. The increased motivation for healthy behaviors might be an effective strategy to achieve better outcomes.

#358 - Medical Image

HYPERTRIGLYCERIDEMIA-INDUCED ACUTE PANCREATITIS IN A YOUNG MAN

Miguel Rodrigues Monteiro, Ana Catarina Brás, Filipa Gomes
Hospital Professor Doutor Fernando da Fonseca, Amadora, Portugal

Clinical summary

This picture depicts a blood sample collected from a 24 year-old man, who presented to the emergency department with persistent severe epigastric pain radiating to the back, nausea, vomiting, diarrhea and weight loss in the last month. A history of severe chronic alcohol abuse was reported. The diagnosis of acute pancreatitis was confirmed by abdominal ultrasonography, which revealed a volume increase of the head of the pancreas. The blood sample had a lactescent coloration due to hypertriglyceridemia of 2282 mg/dL. After centrifugation, three layers in the blood

sample can be observed, corresponding to triglycerides, serum and red blood cells. Despite the severity of the disease, the patient recovered with vigorous hydration with no need for therapeutic plasma exchange.

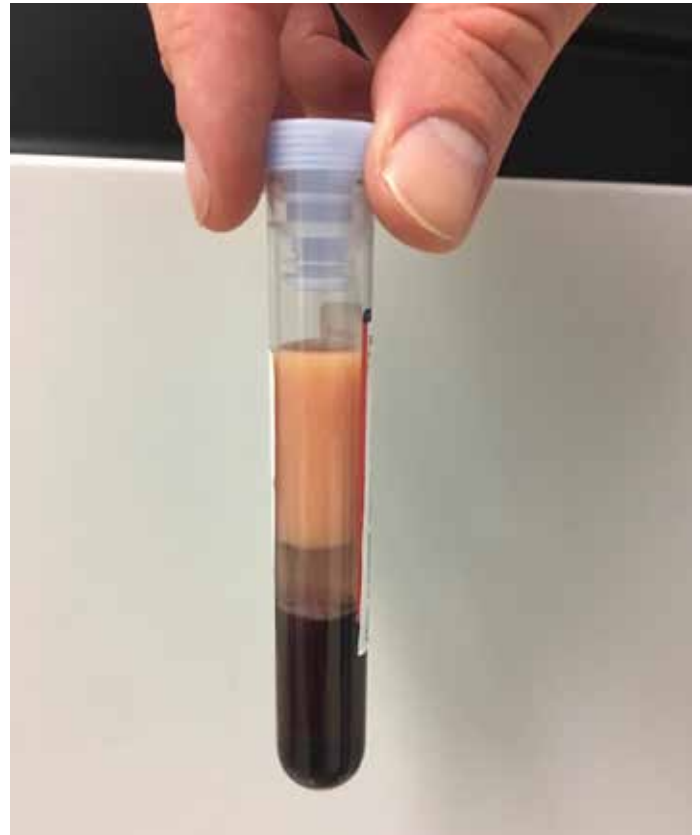


Figure #358.

#360 - Case Report

PHOSPHORUS, IRON AND FGF-23: THE GOOD, THE BAD AND THE UGLY

Ivo Cunha, Ana Oliveira, Sandra Silva

Hospital Pedro Hispano, Matosinhos, Portugal

Introduction

The association between hypophosphatemia and iron replacement, although without clinical relevance in the majority of the cases, has been recognized since the 1980s.

Case description

We report the case of a 39-year-old female submitted to total thyroidectomy due to a multinodular goiter. In the immediate post-operative period there was documentation of a severe hypocalcaemia and posteriorly, histological confirmation of one of the parathyroid glands removal. In the subsequent years she developed non-specific genicular pain and a mild depressive syndrome; laboratory results documented mild hypocalcaemia; there was no evaluation of the serum phosphorus and no specific treatment was done. At 2018, after discontinuation of a contraceptive pill, she started abundant menorrhagia

with anemia and iron and folic acid deficiency. She required intravenous replacement with 1g of ferric carboximaltose due to gastrointestinal intolerance. Thereafter she evolves with myalgias, joint pains, generalized paresthesias and cramps of nocturnal predominance. Analytically, she had a serum phosphorus value of 1mg/dL and an ionized calcium of 0.8mg/dL, and initiated IV and oral replacement, and vitamin D supplementation. Workup, including PTH, calcidiol, calcitriol, mioglobin, serum magnesium and alkaline phosphatase were normal; urine summary exam without alterations and a calculated fractional phosphorus excretion of 20%. Bone and parathyroid scintigraphy, as well as x-rays of the long bones, revealed no changes. She was discharged a week later, with compensated ionic values under oral supplementation.

Discussion

Phosphorus's renal excretion is mostly controlled by PTH and FGF-23. This last one, seems to play a crucial role in iron supplementation induced hypophosphatemia, which, in a simple way can be explained by its role as a "phosphatonin". FGF-23 also inhibits the conversion of calcidiol to calcitriol, which, in turn, has contributed to the worsening of chronic hypocalcaemia by decreasing intestinal absorption. Another concurrent mechanism seems to be the fact that iron deficiency will induce the production of FGF-23 by osteocytes which immediately convert it into an inactive form of FGF-23. Iron carboximaltose interrupts this cycle, thus leading to the increase of "active" FGF-23. This effect is not "class dependent" and does not appear to occur with other formulations. Therefore, iron-carboximaltose's induced hypophosphatemia should be taken into account prior to this type of treatment.

#377 - Abstract

HYPERCALCEMIA: A RETROSPECTIVE STUDY IN CENTRO HOSPITALAR UNIVERSITÁRIO COVA DA BEIRA

Clara Jorge¹, Sónia Coelho¹, Pedro Carlos¹, Catarina Chaves², Marlene Louro³, Leopoldina Vicente³

¹ Centro Hospitalar Universitário Cova da Beira, Covilhã, Portugal

² Centro Hospitalar Tâmega e Sousa, Penafiel, Portugal

³ Centro Hospitalar Universitário Cova da Beira,, Covilhã, Portugal

Background

Hypercalcemia (HC) is a common electrolyte disorder. It is closely regulated by PTH, vitamin D and calcitonin. Clinical symptoms are nonspecific, and there are a multitude of clinical manifestations (cardio-vascular, neurological, renal and gastro-intestinal).

Methods

Retrospective, observational and analytical study. Patients with severe hypercalcemia (SHC: ionized calcium > 5.6 mg / dl) were enrolled, in the period from 1 January 2017 to 31 December 2017. In order to study the underlying etiology, further study was made

using cervical ultrasound, parathyroid scintigraphy, vitamin D assay, serum and urinary phosphate and urinary calcium/24H assays, radiography of the skeleton, medullary/ bone biopsy and imaging of neoplasia.

Results

A total of 26 308 patients had HC, among which 50 had SHC. From these, only 31 patients exhibited SHC maintained over time. The mean age was 76.7 years, with a ratio female/male of 1.8 / 1. The main etiology was neoplastic (42%) (61.5% from solid tumors and 38.5% from multiple myeloma). The most frequent neoplasms were from ENL, esophagus, stomach, colon and bladder; must be highlighted that many of them already had bone metastases. Primary hyperparathyroidism (HPTH) due to parathyroid adenoma was diagnosed in 22.6% of cases. This is followed by 16.1% of patients with chronic renal disease in which the diagnosis of tertiary HPTH was admitted. In 3.2%, immobilization was the cause. In the remaining 16.1% the cause remained uncertain. Although they were not accounted, transient SHC was mainly due to an iatrogenic cause (hydrochlorothiazide, indapamide, calcitriol), and due to renal failure in a dehydration context.

Conclusion

HC is a common clinic finding in the hospital. Its study and treatment is crucial to prevent further complications. Primary HPTH and neoplasms represent the main causes of HC, as reported in the literature. In this study, the neoplastic etiology prevails 3.25 times, because SHC is more frequent than in primary HPTH, and it is also associated with a more hospital admissions since it is more symptomatic, and consequently more easily diagnosed.

#388 - Case Report

HUNGRY BONE SYNDROME

Joel Pinto, Paulo Almeida, Flávio Godinho, Daniela Meireles, Fani Ribeiro, Susana Cavadas

Centro Hospitalar do Baixo Vouga, Aveiro, Portugal

Introduction

Calcium homeostasis is regulated by the action of parathyroid hormone (PTH) and vitamin D at the renal, bony and intestinal levels. Hypocalcemia after parathyroidectomy or thyroidectomy is a common, though usually transient situation. However, in some cases, hypocalcemia may be severe and prolonged, especially in patients who have developed significant bone disease previously to surgery, due to prolonged exposure to elevated PTH levels. These cases are referred to as Hungry Bone Syndrome.

Case description

The authors present the case of a 69-year-old woman who went to the emergency department due to face and members paresthesia, nausea and vomiting with 15 days of evolution. She denied cough, dyspnea, dysphagia, dysarthria, diarrhea or urinary complaints. She had been submitted to parathyroidectomy 2 months before,

due to primary hyperparathyroidism. She had fever, but no other abnormalities were found in physical examination. Blood tests revealed hypocalcaemia (7.0 mg/dL), hypomagnesemia (1.10 mg/dL), hypokalemia (2.9 mEq/L), hypoalbuminemia (2.89g/dL), vitamin D deficiency (7.8 ng/mL) and C-reactive protein of 20.66 mg/dL. Viral serologies were negative, thyroid function markers and PTH were normal, and blood gas test showed a type 1 respiratory failure. An opacity in the left lung base was visible in the chest X-ray. Correction of hydroelectrolytic disorders and empirical antibiotic treatment was started, being admitted with the diagnosis of lobar pneumonia and Hungry Bone Syndrome. She presented a favorable evolution during hospitalization with regression of inflammatory parameters and normalization of the electrolytes. Septic screening was negative. She was then discharged medicated with calcium carbonate and calcitriol, maintaining previous follow-up in Endocrinology and Internal Medicine consultations.

Discussion

Hypocalcaemia may be responsible for a wide spectrum of clinical manifestations such as paresthesia, muscle spasm, tetany (Trousseau and Chvostek sign), seizures, QT prolongation or cardiac arrhythmias. It is more frequent after thyroid and parathyroid surgery and that's why its prevention and postoperative clinical and analytical surveillance is fundamental. It should be noted that the development of this syndrome can occur even with normal or increased PTH levels.

#413 - Abstract

DATA MINING ANALYSIS OF TYPE 2 DIABETES MELLITUS AND CARDIOVASCULAR DISEASE MORTALITY IN MEXICO

Sonia Citlali Juárez Comboní¹, Jorge Antonio Aldrete-Velasco², Salvador Durán-Coyote³, Scarlett Enríquez-Ramos²

¹ Los Ángeles Acoxa Hospital, Mexico City, Mexico

² Paracelsus S.A. de C.V., Mexico City, Mexico

³ Grupo ANLTYK, Mexico City, Mexico

Background

In Mexico, Diabetes Mellitus is the first cause of death in women and the second cause in men, after cardiovascular disease (CVD). Moreover, CVD is not only the first cause of death in the world, in Mexico also represents one of the most important causes of disability. For this reason, the National Health System considers these diseases as the principal health issues in the country. The principal objective of this study was to describe and analyze type 2 diabetes mellitus (T2DM) and CVD mortality in Mexico through data mining technique.

Methods

3 105 975 death certificates were consulted on the most updated registries of the health sector from January 2011 to December 2015. Death registries associated to T2DM and CVD were defined

as stated by the International Classification of Diseases (ICD-10). Age groups were analyzed according to its possible economic activity, mortality range per year and mortality by federal state.

Results

290 708 of the 3 105 705 death certificates were associated to T2DM and 132 148 to CVD, during January 2011 to December 2015. Population proportion was the measure used to obtain death frequency by T2DM, which had an increase from 8.38 to 10.24% during the analyzed lapse. Meanwhile, CVD proportion decline from 4.46 to 4.31%. Similarly, mortality range by T2DM showed a considerable annual increase compared to CVD deaths. Significant predominance by sex was not observed in any of the studied diseases. However, a comparing between economically active populations of 25 to 65 years old was performed, in which a significant difference (15.35 and 13.58% in 2011 and 2015, respectively) was reported when T2DM deaths were compared with CVD ones.

Eventually, T2DM and CVD distribution by federal states were studied, showing that states with higher mortality of both diseases were Mexico City, Mexico State and Veracruz.

Conclusion

Mortality by T2DM has been increasing in an exponential way and this affects to the economically active population importantly. Although CVD remains the first cause of death in Mexico, this condition had become more preventable and, therefore, mortality rate of CVD has decreased in last years.

These study results can orientate about the epidemiology of this conditions in Mexico. Due to the use of data mining, the impact of T2DM mortality in Mexico was highlighted. This analysis allows to see how important and urgent is to control and prevent T2DM.

#423 - Case Report

REFRACTORY HYPONATREMIA – A CASE OF AN EMPTY SELLA SYNDROME

Cláudia Isabel Góis Lemos, Sara Beatriz Santos Da Silva, Ana Carlota Policarpo Gouveia Vida, Sofia Patrícia Dinis Ferreira, António Manuel Rosa Oliveira, Ema Da Conceição Abreu Ferreira Teles Freitas, Maria Da Luz Reis Brazão
Hospital Central do Funchal, Funchal, Portugal

Introduction

Hyponatremia is the most common electrolytic disturb in clinical practice and is one of the manifestations of empty sella turcica syndrome, which is very rare and there is little clinical experience in the management of this pathology, as well as its complications.

Case description

Female, 77 years old, caucasian with personal history of hypertension, obesity, type 2 diabetes, stroke, medicated for her comorbidities. She went to the emergency services with a case of prostration, anorexia and vomiting with two weeks evolution.

Analytically, she presented severe hyponatremia, 110 mmol/L, so she was admitted in the enfermary of Internal Medicine. Since it was refractory to therapy, the team asked for an extensive study to discover possible causes, which revealed primary hypothyroidism and primary adrenal insufficiency. With the support of the Endocrinology team, the patient initiated treatment with levothyroxine and hydrocortisone. The CT scan of the pituitary gland showed invagination of the tank above-seal inside of the sella turcica, stipulating compression of the pituitary and erosion of the pavement seal, i.e., empty sella turcica. During the internment, analytically results were: low T4, T3 and TSH, ACTH and prolactin levels normal. Cortisol in the morning and afternoon were reduced. In the urine of 24h, increased urinary sodium (476 mEq/24h). The remaining parameters, such as, potassium, chlorine, osmolality, creatinine, and glucose levels were within the normal limits. The patient was discharged with total correction of natremia, medicated with letter and hydrocortone.

Discussion

The empty sella turcica Syndrome, congenital, primary or secondary etiology, is an uncommon entity that is characterized by filling of the sella turcica with cerebrospinal fluid due to herniation of the arachnoid, leading to compression of the pituitary tissues against the wall seal, which confers the radiological appearance of empty sella turcica. The typical patients affected are females, in the mid-fifties, multiparous, obese and hypertensive. Despite the vast majority of patients did not present alterations in the pituitary hormone levels, this entity is responsible for a non neglecting number of cases which may lead to a delay in diagnosis with serious consequences for the patient. In conclusion, the authors expose this case, evoking its rarity and its scarce literature.

#437 - Abstract

MAGNESEMIA VARIATIONS IN TYPE 2 DIABETES

Sabah Hanachi¹, Khalida Boudaoud², Karima Sifi³, Rayane Merlaoui⁴, Rayane Lecheheb⁴, Karima Benembarek⁵, Noureddine Abadi⁵

¹ Laboratory of Biology Aiaand Molecular Genetic, Faculty of Medicine, Constantine University, Constantine, Algeria

² Laboratory of Biology and Molecular Genetic, Faculty of Medicine, Constantine University, Department of Endocrinologie Constantine Hospital, Constantine, Algeria

³ Laboratory of Biology Aad Molecular Genetic, Faculty of Medicine, Constantine University, Biochemistry Laboratory, Constantine Hospital, Constantine, Algeria

⁴ Biochemistry Laboratory, Constantine Hospital, Constantine, Algeria

⁵ Laboratory Of Biology And Molecular Genetic, Faculty of Medicine Constantine University, Biochemistry Laboratory, Constantine Hospital, Constantine, Algeria

Background

Type 2 diabetes is a public health problem and is considered

today the evil of the century. It is characterized by a combination of deficiency and insulin resistance. Several mechanisms are envisaged to explain these concepts, an insufficient intake of magnesium, and consequently a deficit of magnesium within the cells would promote this insulin resistance.

The purpose of this study is to evaluate and compare magnesium levels in non-insulin-dependent diabetics with those of the control population.

Methods

-The study that we have undertaken is a control-case type. It involved 30 controls, 38 diabetics and 68 unbalanced diabetics.

- All our subjects have benefited from a biochemical report that counts a fasting glucose test, magnesium, calcium, albumin, phosphorus, urea, creatinine, triglycerides, total cholesterol, cholesterol HDL, LDL cholesterol and glycated hemoglobin.

Results

The mean serum magnesium level is lower in patients with unbalanced diabetes (21.69±3.47 mg / l) compared with controls (21.91±1.3 mg / l) and balanced patients (21.90±3.41 mg / l). But, this decrease is not significant.

We could not find any significance between mean serum magnesium levels versus diabetes seniority.

A positive correlation between magnesium plasma concentration and presence of hypertension, physical activity (in controls) and diet was found. Our results show that fasting blood glucose, glycated hemoglobin, calcium, albumin and triglycerides were significantly elevated in diabetics. Phosphorus, urea, creatinine, total cholesterol were low in patients.

Conclusion

Our results do not find a strong correlation between hypomagnesemia and type 2 diabetes (T2D). Larger scale studies will be needed to provide stronger evidence, and to elucidate the role of hypomagnesemia in Algerian type 2 diabetics, on the one hand and to support the possible inclusion of magnesium supplements in the guidelines for managing T2D. Especially in patients who are not able to achieve the desired glycemic standards.

#438 - Abstract

MUTATIONS IN FACTOR V LEIDEN AND FACTOR II AND COMPLICATED TYPE 2 DIABETES: CASE-CONTROL STUDY

Sabah Hanachi¹, Karima Sifi¹, Nacera Kerouaz², Khalida Boudaoud³, Salima Zekri⁴, Daoud Roula², Karima Benembarek⁴, Nouredine Abadi⁴

- ¹ Laboatory of Biology and Molecular Genetic, Medicine Faculty Constantine University 3, Constantine, Algeria
- ² Laboatory of Biology and Molecular Genetic, Medicine Faculty Constantine University, 3Departement Of Internal Medicine Constantine Hospital, Constantine, Algeria
- ³ Laboatory Of Biology And Molecular Genetic, Medicine Faculty Constantine University 3, Departement Of Endocrinology ,Constantine Hospital, Constantine, Algeria
- ⁴ Laboatory Of Biology And Molecular Genetic, Medicine Faculty Constantine University 3, Constantine, Algeria

Background

A synergistic effect of thrombophilia with several cardiovascular risk factors such as diabetes, obesity, and hyperlipidemia seems to have existed.

The purpose of the present study is to investigate a possible association between diabetes and Factor II and factor V Leiden mutations. The role of these two mutations in venous thromboses is well established, in contrast to that in arterial thromboses that remains controversial until then.

Methods

The study included 97 diabetics and 190 healthy controls. The DNA was extracted by the NaCl method. Both mutations were determined by real-time PCR.

Consent was obtained from all participants in the study.

Results

Genotype and allelic frequencies of the G20210A mutation of the prothrombin gene (factor II)

Our results show the predominance of the wild-type GG allele in the 2 groups, controls and patients with respective frequencies of 98.6% and 97.6%. While the heterozygous GA genotype is only found at 1.4% and 2.4% respectively. No homozygous mutated AA genotype was found in either group.

The G allele is predominant in both groups, 98.8% in patients and 99.32% in controls. The frequency of the mutated A allele is only 1.20% in patients and 0.68% in controls. Genotypic and allelic frequencies of the factor V gene mutation G1691A

Our patients are exclusively of wild GG genotype with a genotypic frequency of 100%, whereas in our controls this genotype predominates with a frequency of 97.4%, the heterozygote genotype GA with a frequency of 2.6%. No homozygous mutated genotype AA was found in our study population.

The G (wild) allele is predominant in our controls with a frequency of 98.68%; Allele A accounts for only 1.32% in this group. In our patients, only the wild allele is present (100%).

Conclusion

Our results found no significant association between the G20210A mutation of the prothrombin gene (factor II) and the G1691A mutation of the factor V gene and complicated type 2 diabetes

#453 - Case Report

PRIMARY HYPERPARATHYROIDISM

Ana Catarina Dionísio, Ana Branco, Dalia Estêvão, Artur Gama, Leopoldina Vicente
CHUCB, Covilhã, Portugal

Introduction

Primary hyperparathyroidism is in most situations caused by parathyroid adenomas (81%). They are more common in women and diagnosis is common in the 3rd and 4th decades of life. The symptoms are often non-specific (fatigue, depression, mental confusion, anorexia, nausea, constipation, renal tube defects, polyuria, a short QT interval and arrhythmias), so the high rate of suspicion is important.

Case description

A 79-year-old female patient has been referred to the Emergency Department for anorexia, nausea and vomiting for 1 month, weight loss of about 10% of habitual body weight, constipation and marked asthenia.

No changes were identified at the objective examination. Analytically, she presented severe hypercalcemia (18.8 mg/dL). Performed an electrocardiogram that showed no abnormalities.

She was hospitalized for etiological study and normalization of serum calcium values with electrocardiographic monitoring.

Analytically, had a high PTH value. The hypothesis of primary hyperparathyroidism was made and a thyroid ultrasonography showed a solid nodule, most likely a parathyroid adenoma.

After the institution of the therapy it presented good clinical and analytical evolution with resolution of anorexia and improvement of the remaining symptoms. After cervical computed tomography and parathyroid scintigraphy, left upper parathyroidectomy was performed.

Patient was medicated with cinacalcet 30mg twice daily until surgery.

Discussion

Severe hypercalcemia (>15mg/dL), can be a medical emergency, leading to coma and cardiac arrest. In the cases of adenomas of the parathyroids the definitive treatment passes through surgical intervention with great operative potential.

#481 - Case Report

AN ATYPICAL CASE OF ANASARCA IN A NEWLY DIAGNOSED TYPE 1 DIABETIC

Marc Hai Liang Wong, Tharmmambal Balakrishnan
Singhealth, Singapore, Singapore

Introduction

Lower limb swelling is a common occurrence in the acute medicine clinic. Here, we report a 40-year-old woman who was newly diagnosed with type 1 diabetes and commenced on insulin (Actrapid and Lantus) and subsequently developed lower limb swelling.

Case description

A 40-year-old woman was admitted for symptoms of polyuria and polydipsia and found to have hyperglycemia, fortunately not in crisis. She was previously well without any medical history and was subsequently found to have type 1 diabetes mellitus and was initiated on a basal-bolus regimen of insulin (Actrapid and Lantus). Tolerating her insulin therapy well, she was promptly discharged and planned for outpatient evaluation.

Two days after she was initiated on insulin therapy, she represented with bilateral lower limb swelling till the level of the mid shins and her edema progressed inpatient to anasarca. She gained more than 10 kgs within a short span of 2 weeks and subsequently had complications of acute pulmonary edema requiring high doses of intravenous furosemide for adequate dialysis.

Significant differentials of cardiac disease, liver disease, renal disease, and obstructive causes were evaluated requiring many investigative tests such as transthoracic ultrasound of the heart, a computed tomography scan of the abdomen and pelvis and a plethora of blood tests. Even after completing the initial investigations, the cause of the lower limb swelling remained a mystery leading to evaluation for a wider array of differentials which included autoimmune causes and drug causes.

Finally, after this thorough screen was negative, the rare complication of insulin usage resulting in edema was entertained. The doses of Actrapid and Lantus was titrated and finally switched to a combination of Apidra and Lantus. Fortunately, the massive fluid retention resolved thereafter and the patient was discharged well.

Discussion

The majority of reported cases of insulin edema have occurred in patients with Type 1 diabetes and patients have typically presented between 2 and 4 weeks following an initial presentation of DKA. Insulin is commonly known to cause weight gain and has been attributed to increased vascular permeability and altered renal sodium handling in addition to its anabolic action. However, the rare side effect of significant fluid retention is probably an underreported physical finding. We present this case of unusual lower limb swelling and a review of the literature and mechanisms surrounding insulin edema.

#548 - Abstract

EFFECTS OF SGLT2 INHIBITORS ON THE RENAL FUNCTION OF TYPE 2 DIABETICS: OUR EXPERIENCE AFTER ONE YEAR

Daniel Marín Dueñas¹, Juan Mora Delgado¹, Manuel Cayón Blanco², Patricia Rubio Marín¹, Ana Ruiz Arias¹, Alfredo Michan Doña¹

¹ Internal Medicine, General Hospital of Jerez de la Frontera, Jerez De La Frontera, Spain

² Endocrinology and Nutrition, General Hospital of Jerez de la Frontera, Jerez De La Frontera, Spain

Background

Type 2 diabetes mellitus 2 is already a worldwide epidemic, in addition, diabetic nephropathy has become the leading cause of end-stage renal failure.

Methods

The objective was to know the changes produced in HbA1c and impact on renal function after one year of treatment with iSGLT2. Observational and descriptive study, transversal. Patients with type 2 diabetes are selected in treatment with iSGLT2 for at least one year, excluding those with chronic kidney disease. Demographic characteristics, HbA1c and renal function are analyzed at the beginning of treatment and after one year of treatment

Results

The average age was 62.13 +/- 8.91, with 54.1% males. At the beginning they presented an Hb1Ac of 7.84 +/- 1.42 and after one year of treatment 6.9 +/- 1.17 (-0.93 +/- 1.19). Glomerular filtration increased by 62.2% in the treated patients (1.4 +/- 12.62). The albuminuria at the beginning was 19.6 +/- 35.7, and after one year it increased to 12.78 +/- 17.23 (-5.37 +/- 27.89). The albumin / creatinine ratio initially marked 32.38 +/- 31.68 with respect to 32.3 +/- 26.73 after one year of treatment (-0.08 +/- 27.97).

Conclusion

The use of iSGLT2 in patients without chronic kidney disease causes a decrease in HbA1c and could have benefits from the renal point of view. In our patients there is an increase in glomerular filtration and decrease in albuminuria.

#553 - Case Report

APPLICATION OF GLUCAGON-LIKE PEPTIDE-1 ANALOGUES: KIDNEY AND CARDIOVASCULAR RISK FACTORS

Juan Mora Delgado, Daniel Marín Dueñas, Patricia Rubio Marín, Ana María Ruiz Arias, Alfredo Michan Doña

Internal Medicine, General Hospital of Jerez de la Frontera, Jerez De La Frontera, Spain

Introduction

Glucagon-Like Peptide 1 analogues suggest having a protective

role in cardiovascular risk factors besides improving glycemic control, compared to placebo and to standard diabetes therapies, and have a positive impact on cardiovascular risk factors otherwise not addressed by most standard diabetes therapies.

Case description

A 66-year-old male smoker with a daily package (40 packages/year); with a history of high blood pressure; hypercholesterolemia; obesity type I. Diabetes type 2 of 15 years of evolution in treatment with oral antidiabetics. Stable chronic ischemic heart disease (stents more than 15 years ago). Chronic kidney disease stage 3A. Weight 91.3 kg; size 1.70 m; BMI 31,591. BP: 133/77 mmHg. Analysis: glucose 213 mg/dl; HbA1c 8.6%; total cholesterol 218 mg/dl, LDL-C 115 mg/dl, HDL-C 37 mg/dl and TGs 320 mg/dl; FGe 44 (CKD-EPI). His antidiabetic treatment was metformin 500 mg (every 12 hours) and sitagliptin 50 mg (daily).

We remove sitagliptin, initiating liraglutide, increasing weekly until the maintenance dose. At 3 months his HbA1c was 7.4% (-1.2%) and the weight of 86.7 kg (-4.6 kg). With this, we obtained the goal of glycemic control that we set ourselves. Six months later, he presented a new decrease in his HbA1c (-0.3%) and weight (-3.5 kg).

Discussion

This patient presents a moderate risk of hypoglycaemia due to CKD, a duration of T2DM between 10-20 years of evolution, microvascular and macrovascular complications and a patient's attitude that is not too active. Thus, a correct control of HbA1c would be between 7-7.5% (currently 8.6%), so we accept poor control.

When intensifying with a third drug, we look at the consensus document on the treatment of diabetes in patients with CKD: first choice is metformin and / or repaglinide and that associated with these could be used basal insulin, pioglitazone and aGLP1. These three options would be correct, but not all behave the same from a cardiovascular point of view. Pioglitazone did not find statistically significant benefits in its PROactive study and basal insulin glargine showed in the ORIGIN study its non-inferiority against placebo. In this sense, superiority is shown by liraglutide, which becomes the drug of choice according to the recommendations of the AACE in patients with CVD. We made the decision to start the treatment described based on the consensus of CKD in the patient with DM2, in the clinical practice guide of the AACE and in the LIRA-RENAL study.

#596 - Case Report

ADRENAL INSUFFICIENCY IN PATIENT WITH CEREBRAL METASTASES - CASE REPORT

Paulo Ferreira¹, Vanessa Machado¹, Cristina Ramalho¹, Hilda Freitas², Natalia Oliveira², Antonio Cabral²

¹ TrofaSaude Hospital Braga Centro, Braga, Portugal

² TrofaSaude Hospital Braga Sul, Braga, Portugal

Introduction

Adrenal insufficiency is a rare disorder, occurring in up to 144/1000000 of the population. Autoimmune adrenalitis is responsible for 70/90%, with the remainder being caused by other infectious diseases, replacement by metastatic cancer or lymphoma, adrenal hemorrhage or infarction, or drugs. Adrenal insufficiency can be caused by diseases of the adrenal gland (primary), interference with corticotropin (ACTH) secretion by the pituitary gland (secondary), or interference with corticotropin-releasing hormone (CRH) secretion by the hypothalamus (tertiary).

Case description

The authors describe a clinical case of 63 years old men, independent, with a history of Hypertension, Diabetes 2, Low Grade Papillary Urothelial Carcinoma and Melanoma (Oncology considered cured). He went do emergency room because confusion. He had Broca aphasia and dysmetria in the right finger test nose. Laboratory studies revealed hyponatremia. TAC CE sowed "multiple nodular, supra and infratentorial lesions, mostly hyperdense, some with central necrotic area. In the supratentorial compartment, they are mostly surrounded by a halo of vasogenic edema. Correspond to very likely brain metastases. He had axillary adenopathy of 2 cm. He was medicated with steroid therapy .Cortisol in the morning 1.5 and repeated: <1 (5.0-25.0); Cortisol in the afternoon 1.3 and repeated: 1.1 (1.7-14.1), before beginning of corticoids. Brain Cranial Resonance performed: "multiple expansive lesions suggestive of metastatic lesions". An aspiration biopsy was performed on axillary adenopathy. He improved mental confusion. Metastasis of melanoma confirmed in axillary ganglia cytology. According to decision of family members intended not to carry out any treatment directed to the disease, only being in treatment of symptoms.

Discussion

Tertiary adrenal insufficiency refers to causes that related to hypothalamic abnormalities that reduce corticotropin-releasing hormone (CRH) secretion. Any process that involves the hypothalamus and interferes with CRH secretion will result in tertiary adrenal insufficiency. Such processes include: tumors, infiltrative diseases such as sarcoidosis, and cranial radiation. In young adults, the presence of nonspecific and mild symptoms, besides laboratory studies at the threshold of normal, can let pass potentially treatable conditions that can improve survival and life-quality for these patients. In these cases, the Internist assumes a preponderant role.

#609 - Abstract

EFFECT OF METFORMIN ON BODY FAT DISTRIBUTION AND SERUM LIPID PROFILE IN PATIENTS WITH TYPE 2 DIABETES AND CHRONIC HEART FAILURE

Jan Kopecký, Eva Hošková, Jirí Veleba, Katerina Velebová, Vojtech Melenovský, Terezie Pelikánová

Institute for clinical and experimental medicine, Prague, Czech Republic

Background

Treatment with metformin (MET) in type 2 diabetic patients (T2D) with chronic heart failure (HF) is associated with better cardiovascular outcomes. Android type of body fat accumulation is associated with high cardio-metabolic risk factor profile. The aim of the study was to evaluate the effects of MET on body fat distribution and serum lipid profile during the meal test.

Methods

A randomized, double-blind, placebo-controlled, crossover study in a total time of six months testing the effect of 3-month usage of MET (2 g/day) vs placebo. A group of 40 treatment naive patients with T2D and HF were included. At the beginning and at the end of each intervention period body fat distribution was assessed by Dual Energy X-Ray Absorptiometry (DEXA; GE Lunar Prodigy) and serum lipid profile during meal test was measured. In addition, hyperinsulinemic-isoglycemic clamp was done and HbA1c was measured to assess the effect on glucose metabolism.

Results

MET did not significantly change android vs gynoid body fat composition as measured by DEXA. Fasting serum lipid profile (Tg, Chol, HDL, LDL, FFA) was also not altered. During a meal test, there was a trend to decrease area under curve of free fatty acids by metformin (statistically significant only vs baseline at $p < 0.05$, not vs placebo), triglyceride concentrations were not significantly altered.

MET significantly reduced HbA1c compared to placebo ($p < 0.01$). Insulin sensitivity, measured as a metabolic clearance rate of glucose (MCR) during the clamp, improved significantly with MET ($p < 0.001$) but also, although less significantly, with placebo ($p < 0.05$), difference between MET and placebo was not significant.

Conclusion

Our results on unique group of patients with heart failure and diabetes showed expected changes in glucose metabolism but did not find statistically significant changes in lipid metabolism and body composition.

Supported by AZV16-27496A

Registered as NCT 01690091

#678 - Case Report

GLIBENCLAMIDE-INDUCED THROMBOCYTOPENIA: A CASE REPORT

Yosra Cherif^{1,2}, Baya Chatti Amal^{1,2}, Maroua Mrouki^{1,2}, Fatma Ben Dahmen², Meya Abdallah^{1,2}

¹ Tunis El Manar University Faculty of Medicine of Tunis, Tunis, Tunisia

² Regional Hospital Ben Arous, Internal Medicine Department, Ben Arous, Tunisia

Introduction

Drug-induced thrombocytopenia is a common side-effect. Up to 25% of thrombocytopenia in critically patients are drug-induced. We report a glibenclamide-induced thrombocytopenia in an elderly woman.

Case description

A 75-year-old woman was admitted for headache. She had mellitus diabetes, high blood pressure and coronary insufficiency. She was treated with glibenclamide, metformine, aspirin, molsidomine and captopril. Physical examination showed global cardiac failure. She had no features of bleeding. Laboratory tests showed thrombocytopenia with a thrombocyte count at $42000/\text{mm}^3$, hemoglobin levels of 14 g/dL and leucocytes at $7910/\text{mm}^3$. Renal and liver function were within normal range. Abdominal ultrasound was normal. Hepatitis B and C and human immunodeficiency virus serologies were negative. Glibenclamide was withdrawn. Three days after the withdrawal of glibenclamide, platelets count increased with normal levels at $174000/\text{mm}^3$.

Discussion

The etiological analysis of glibenclamide-induced thrombocytopenia is not obvious. Different mechanisms were uncertain including auto-immune disease, bone marrow failure and impaired platelet production. Severe bleeding can occur. Therefore, platelet count should be monitored when patient are treated with glibenclamide.

#690 - Abstract

APPROACH AND TREATMENT OF HYPERGLYCAEMIA IN HOSPITALIZED PATIENTS (WITH NON-CRITICAL ILLNESS) - HOSPITAL CLINICAL ORIENTATION NORM AUDIT

Francisca Saraiva Santos, António Eliseu, Carolina Palma, Filipa Silva, Susana Marques, Julieta Sousa, Ermelinda Pedrosa
Centro Hospitalar de Setúbal, Setúbal, Portugal

Background

The joint recommendations of Portuguese Society of Diabetology and Portuguese Society of Internal Medicine about the Approach and Treatment of Hyperglycaemia in Hospitalized Patients (with non-critical illness), published in May 2015, were adapted into a Hospital Clinical Orientation Norm at the health institution where the authors are collaborators.

Methods

Three years after their publication, the authors present the results of a clinical audit of this norm implementation, in the form of a cross-sectional cohort, carried out at the various in-patient departments of the concerned health institution, involving non-critical patients, in order to verify the penetration of the aforementioned norm into clinical activity.

On January 29, 2019, an audit grid was applied to Medical and Surgical, excluding the Obstetric, Pediatric and Psychiatry ones, comprising a total of 275 patients, of whom 94 presented hyperglycemia during hospitalization. Of these, 89 were under insulin therapy.

The data were collected without prior notice in order to evaluate the usual clinical practice, following the entire circuit from its identification, therapeutic prescription and pharmacological administration.

Results

From the results analysis, it was concluded that: the use of oral antidiabetic medication is practically non-existent; most patients (85%) were under basal-bolus scheme; the review of insulin doses in cases of poor metabolic control is still deficient (and in only 47.1% of the cases the review was verified in the appropriate timing, constituting an important gap that need to be corrected). From the overall analysis, a positive compliance rate of 80.4% was obtained.

Conclusion

The analysis of results and their internal presentation will certainly allow us to correct deviations from the good practice and to involve all professionals, in order to better comply with the institutional norm, ensuring that patients receive the best possible approach during hospitalization, and in some cases, after hospital discharge.

#694 - Abstract

SEVERITY OF DIABETIC KETOACIDOSIS IN PATIENTS ADMITTED IN THE EMERGENCY DEPARTMENT OF A PORTUGUESE HOSPITAL: A CROSS-SECTIONAL STUDY

Joana C F Lima¹, João Aguiar², Margarida Paixão Ferreira¹, Rita Calixto¹, Vera Cesário¹, José Vaz¹

¹ Hospital José Joaquim Fernandes, Beja, Portugal

² Instituto de Investigação do Medicamento (iMED.Ulisboa), Faculdade de Farmácia, Universidade de Lisboa, Lisboa, Portugal

Background

Diabetic ketoacidosis (DKA) are one of the most serious acute metabolic complications of diabetes. The triad of uncontrolled hyperglycemia, metabolic acidosis, and increased total body ketone concentration characterizes DKA. Our aims were: a) to characterize the degree of severity of DKA episodes in a diabetic population from a Portuguese hospital; and b) to evaluate the correlation between HbA1c and the degree of severity of DKA episodes.

Methods

A cross-sectional study was undertaken in a Portuguese hospital in Beja from 2016-2017. Patients (aged 18 years or older) with DKA who were admitted in emergency room were included in the study. Data was extracted from medical charts, which included sociodemographic and clinical variables (e.g. serum ketones, arterial pH, serum bicarbonate, and anion gap). The degree of severity of DKA episodes was divided in three groups (mild, moderate, and severe), according to American Diabetes Association. Data analysis was performed using uni- and bivariate statistics (IBM SPSS v.20.0).

Results

A total of 20 patients were included, with a mean age of 54±18.9 years old and 75% (n=15) were female. From those, 55% (n=11) were type 1 diabetics and were firstly diagnosed in the last 16.9±7.9 years {0;37}. Microvascular complications were identified in 45% (n=9) of the sample, macrovascular complications in 5% (n=1), and 10% (n=2) presented both. Previous history of DKA episodes were identified in 20% (n=4) of the patients. A total of 43 DKA episodes were identified during the study period (mean of 2.2 episodes per patient {1;19}). Mild, moderate, and severe DKA episodes were present in 9% (n=4), 58% (n=25), and 33% (n=14), respectively. Ten patients (23%) were admitted to the intensive care unit. The mean HbA1c was 11.9±1.5 {5.5;17.3}. According to our data, there was no correlation between HbA1c and the degree of severity of DKA episodes (p=0.227).

Conclusion

Data suggest that one third of episodes were associated with severe DKA; however, only 2% of the overall patients followed-up annually in the diabetes department of the hospital experienced DKA episodes. Even though there was no correlation between HbA1c and the degree of severity of DKA episodes, this may be explained by the small sample size. Further studies would be necessary to evaluate possible correlations between severity of DKA episodes and metabolic control.

#698 - Abstract

THE ASSOCIATION BETWEEN HBA1C AND THE PRESENCE OF METABOLIC COMPLICATIONS IN DIABETIC PATIENTS: A STUDY IN A PORTUGUESE HOSPITAL

Joana C F Lima¹, João Aguiar², Margarida Paixão Ferreira¹, Rita Calixto¹, Vera Cesário¹, José Vaz¹

¹ Hospital José Joaquim Fernandes, Beja, Portugal

² Instituto de Investigação do Medicamento (iMED.Ulisboa), Faculdade de Farmácia, Universidade de Lisboa, Lisboa, Portugal

Background

Metabolic complications of diabetes mellitus (DM) are associated with a decrease in patients' quality of life and increased costs. Disease control is crucial to prevent those complications.

Therefore, our aim is to evaluate the association between HbA1c and the presence of metabolic complications.

Methods

A cross-sectional study was undertaken in a diabetes appointment of a Portuguese hospital from January to September of 2018. Patients (aged 18 years or older) with DM who are followed-up in this appointment were included in the study. Data was extracted from medical charts, which included sociodemographic and clinical variables (e.g. type of DM, disease duration, and HbA1c). Good glycemic control was defined as HbA1c \leq 7.0%. The strength of the association was estimated with logistic regression and expressed as adjusted odds ratio (aOR) with corresponding 95% confidence interval (95%CI) (IBM SPSS v.20.0).

Results

A total of 113 patients were included, where 55% (n=62) were female with a mean age of 59.4 \pm 15.5 years old {23;90}. From those, 39% (n=44) were type 1 diabetics, and 61% (n=69) type 2 diabetics. The prevalence of metabolic complications in type 1 diabetics was 68% (n=30), whereas in type 2 diabetics was 71% (n=49). Microvascular complications were identified in 67% (n=53) of the sample, macrovascular complications in 9% (n=7), and 24% (n=19) presented both. Macrovascular complications were more prevalent among type 2 diabetic patients. Patients who had poor glycemic control were associated with higher odds of metabolic complications (aOR=1.13; 95%CI 0.38-3.32) when compared to patients with good glycemic control. When analyzing by DM type, patients with type 1 DM and poor glycemic control had a 31% increased risk of having complications when compared to good glycemic control. In type 2 DM, this risk was slightly lower (aOR=1.11; 95%CI 0.31-3.96); however, none of these results were statistically significant.

Conclusion

Data suggest that may exist an association between HbA1c and metabolic complications in both types of DM analyzed. The high prevalence of macrovascular complications among type 2 diabetics may be explained by the presence of other cardiovascular risk factors. However, to confirm this association prospective studies and additional covariates are needed.

#712 - Abstract

OUTPATIENT MANAGEMENT OF TYPE 2 DIABETES MELLITUS - A 6 MONTH HOSPITALAR OUTPATIENT CLINIC REVIEW

Adriana Bandeira, Miguel Gonzalez Santos, Behnam Moradi, Alcina Ponte

Centro Hospitalar de Leiria, Leiria, Portugal

Background

Diabetes mellitus type 2 is a common disease with systemic impact. Though treatable with many available medications and

their multiple combinations, some patients remain a challenge to obtain glycemic control. Though indications for hospital referral and further in-hospital continuity of diabetes care may differ, the heavy burden of comorbidities, polymedication as well as uncontrolled diabetes are the main causes for this decision.

Methods

Retrospective study consisting of process review of all patients followed by one care team in the hospital's outpatient diabetes clinic during the second semester of 2018.

Results

Between July and December 2018, 224 consultations were carried out, of which 8% were family doctor referrals and the remaining 91% were follow-up appointments, corresponding to 131 patients.

Appointment intervals varied, though the majority of patients were re-evaluated within 8,2 weeks of latest appointment.

The majority of patients were male, with a medium age of 67,8 years (SD \pm 11.5) with an average of 13.5 years of disease evolution. The mean value of hemoglobin A1c in the patients referred to consultation was 8,97% and 7,08% at the time of discharge. 77% of patients were insulin-treated, of whom 69% were concomitantly medicated with at least one oral glucose-lowering agent. 87% of patients were prescribed statins and all patients over 65 years of age were taking low dose aspirin daily, 83% of them as primary prevention of cardiovascular events.

Approximately 61% of the patients had diabetes-related complications, namely diabetic nephropathy (32%), diabetic retinopathy (31%) and diabetic foot (19%). All patients received regular foot examination to identify high-risk foot conditions and if needed were forwarded to a specialized consultation. 36% of patients with diabetic foot were diagnosed with peripheral vascular disease and 28% with diabetic neuropathy as main cause of diabetic foot. During this 6 month period, 5 patients were admitted in order to do broad-spectrum antibiotics for active foot ulcer.

Conclusion

Despite all the limitations of an outpatient setting, we still find benefits of an in-hospital approach to diabetic patients mainly those without stable/controlled disease. A multidisciplinary approach, with the support of subspecialty physicians and nurses, facilitated in a hospital setting, may be especially beneficial to this patients.

#715 - Case Report

SYMPTOMATIC BISPHOSPHONATE-INDUCED HYPOCALCEMIA IN A PATIENT WITH PAGET DISEASE AND PRIMARY HYPOPARATHYROIDISM - A CASE REPORT

Roberto Calças Marques¹, Anabela Malho Guedes¹, Mafalda Aveiro², Ana Ribeiro³, António Veiga Moura³

¹ Nephrology Department, Centro Hospitalar e Universitário do Algarve, Faro, Portugal

² Family Medicine, USF Ossónoba, ACES Algarve Central, Faro, Portugal

³ Internal Medicine Department, Centro Hospitalar e Universitário do Algarve, Faro, Portugal

Introduction

Intravenous bisphosphonates are widely used in the management of metabolic bone diseases and appear to be safe in most cases. The rate of development of hypocalcemia is related to the potency and dose of bisphosphonate. If unrecognized or poorly treated, hypocalcemia can lead to a life-threatening state. We report a patient who exhibited profound symptomatic hypocalcemia after receiving intravenous zoledronic acid as treatment for Paget disease.

Case description

We present a case of an 88-year-old caucasian woman who had recently been diagnosed with active Paget disease. She also had a history of primary hypoparathyroidism of unknown cause for which she was taking vitamin D, calcitriol and calcium supplements. The patient was assessed for calcium status prior to intravenous zoledronic acid therapy and was within the normal range. She came to the emergency department one week post-intravenous bisphosphonate treatment with generalized body ache, perioral numbness and acral paresthesias. There was also a description of muscle spasms and cramps at home by a family member. Physical examination was negative for Chvostek's and Trousseau's signs. Her corrected calcium level was low at 5.1 mg/dL. Magnesium, phosphorus and renal function were within the normal range. Alkaline phosphatase was elevated at 1120 U/L, related with biochemical active Paget disease. She was acutely managed with intravenous calcium gluconate. Therapeutic doses of oral calcium and vitamin D therapy were also initiated. After two days, the corrected calcium levels increased to 9.0 mg/dL and her symptoms remarkably subsided. She was discharged from the hospital and advised to continue oral supplements of calcium, vitamin D and calcitriol and to follow-up with her endocrinologist on a monthly basis.

Discussion

Most patients who developed symptomatic hypocalcemia following intravenous bisphosphonate had one or more risk factors predisposing them to low calcium levels. Despite accurate monitoring of plasma calcium levels at the time of zoledronic acid therapy for management of Paget disease, she had an underlying condition that impaired the homeostatic response to

bisphosphonates and contributed to the severe hypocalcemia. We call attention to the possible increase in the number of cases reported, particularly after the recent approval for their management in more common diseases like osteoporosis.

#728 - Case Report

MARINE-LENHART SYNDROME - A RARE CAUSE OF HYPERTHYROIDISM

Joana Maurício, Marta Arriaga Rocha, Susana Heitor, Ricardo Fonseca

Hospital Prof. Doutor Fernando Fonseca, Amadora, Portugal

Introduction

Marine-Lenhart Syndrome, described in 1911, is characterized by the coexistence of Graves' Disease and a functioning autonomous nodule (Plummer's Disease) or toxic multinodular goiter. This is a rare cause of hyperthyroidism, with a reported prevalence of 0.8-2.7% in patients with Graves' Disease.

Case description

We describe the case of an 88 years old female, with shortness of breath, exertional dyspnea, nonproductive cough, and edema of the lower limbs, with one-week duration. She also complained of diarrhea, dysphonia and heat intolerance, with six weeks duration. At physical examination, she presented with high blood pressure and tachycardia, arrhythmic cardiac sounds, crackles at lung bases and symmetrical lower limbs edema. She also had a slightly enlarged thyroid gland, with bilateral nodules that were difficult to delimit, and no signs or symptoms of ophthalmopathy. The complementary diagnostic exams showed an elevated NT-proBNP (2932 pg/mL), suppressed TSH (<0.005 mUI/L), elevated fT4 (3.34 ng/dL) and fT3 (14.3 pg/mL); the electrocardiogram revealed new-onset atrial fibrillation (AF) with a heart rate of 122 bpm; the chest radiography revealed interstitial edema. It was assumed the diagnosis of acute heart failure, in a patient with de novo AF, in a context of hyperthyroidism. It was initiated diuretic, beta-blocker and anticoagulation, as well as thiamazole therapy. The anti-TSH receptor antibodies (TRAb) was positive (27.8 UI/L). Thyroid ultrasound showed an enlarged thyroid gland, with a substernal goiter component, with a diffusely heterogeneous, multinodular echostructure. Thyroid gland scintigraphy with technetium-99m showed multinodular goiter with hyper and hypofunctioning nodules in both lobes. The diagnosis of Marine-Lenhart Syndrome was thus assumed. Although the patient had a formal indication for cold nodule cytology and definitive treatment, due to age, comorbidities and low-risk malignancy thyroid nodules, it was decided to maintain conservative thiamazole therapy and vigilance.

Discussion

Marine-Lenhart Syndrome is still a controversial and underestimated etiology of hyperthyroidism. Its identification importance is the need for definitive therapy with radioactive

iodine or total thyroidectomy. Although autoimmune testing and thyroid ultrasound pattern confirms the etiology of the majority cases of Graves' disease, scintigraphy with technetium-99m may be useful in selected cases of coexistence of multinodular goiter.

#751 - Case Report

PERSISTING HYPONATREMIA IN AN ELDERLY WOMAN: A SHEEHAN'S SYNDROME CASE

Carla Falcão, Rita Grácio, Gaspar Pereira, Pedro Neves Tavares, Catarina Duarte Santos, João Coucelo, Diana Fernandes
Centro Hospitalar de Leiria, Leiria, Portugal

Introduction

Sheehan syndrome is a condition characterized by hypopituitarism due to necrosis of the pituitary gland caused by severe postpartum hemorrhage. Patients with this syndrome exhibit a variety of signs and symptoms that contemplate the varying degrees of anterior or, less commonly, posterior pituitary dysfunction resulting from the deficiency of multiple pituitary hormones. It may be manifested immediately postpartum, with a more severe presentation, or develop years after the delivery.

Case description

A 72-year-old woman, with a medical history of arterial hypertension, obesity and dyslipidemia, was admitted in the ER complaining of malaise, nausea, vomiting, anorexia, dizziness and fatigue for several months. She was being treated with aliskirene 300mg plus hydrochlorothiazide 12.5 mg, betahistine 24 mg and fenofibrate 145 mg, for arterial hypertension, dizziness and dyslipidemia.

Her blood panel was normal for glucose levels and renal function, but her sodium levels were low (125 mmol/L), as well as, the osmolality levels (266 mOsm/Kg), urine sodium and osmolality were high (64 mmol/L and 441 mOsm/Kg). She was treated with hyponatremia correction measures and referred to an internal medicine consultation. During follow-up, the patient admitted having had a past medical history of a severe hemorrhagic delivery of a stillborn child and research of hormone levels and brain MRI were performed. Her hormone levels were: TSH 2.66 µUI/mL, free T4 5.2 pmol/L, free T3 3.5 pmol/L, cortisol 6.2 µg/dL, ACTH 4.76 pg/mL, somatomedin C-IGF1 <25 µ7L and normal levels of renin e aldosterone and the brain MRI showed a reduced asymmetric pituitary parenchyma. She responded well to the hormone substitution treatment.

Discussion

Hyponatremia approach to the elderly remains a challenge considering the innumerable possible causes, especially in patients taking diuretics. Being an obstetric complication, Sheehan's syndrome is not usually considered as differential diagnosis in older patients and might be overlooked and untreated. The past medical history is of the utmost importance and even the smaller details might make the difference.

#771 - Case Report

A CASE REPORT OF A 70 YEARS OLD WOMAN WITH FAMILIAL CHYLOMICRONEMIA SYNDROME

Virginia Esteve Luque¹, Isabel Rodrigues Gonçalves², Bernat Villanueva Cutillas¹, Lluïsa Guillem Tió¹, Xavier Pintó Salas^{1,3,4}, Xavier Corbella Virós¹

¹ Hospital Universitari de Bellvitge, Barcelona, Spain

² ABS Roquetes-Canyelles, Barcelona, Spain

³ Ciber-OBN, Barcelona, Spain

⁴ IDIBELL, Barcelona, Spain

Introduction

Familial chylomicronemia syndrome (FCS), is a rare autosomal recessive monogenic disease caused by mutations in genes that encode for key molecules: LPL, ApoA5, GPIHBP1, ApoC2 and LMF1.

Patient should be considered possibly affected by FCS when we see fasting triglycerides (TG) levels >10mmol/L, a ratio of total triglycerides to total cholesterol >2,2 mmol/L and low levels of apoB. Symptom onset is usually during childhood. Physical findings are eruptive xanthomas, lipemia retinalis and hepatosplenomegaly. Recurrent pancreatitis is often present and is the most life-threatening complication.

The mainstay for management of FCS is a severely restricted in fat diet which has a negatively impact on patient quality of life.

Case description

We report a 70y/o woman followed in our cardiovascular risk unit. She had one miscarriage followed by a stillbirth. During her third she had her first episode of acute hypertriglyceridemic pancreatitis (TG >33 mmol/L) under no treatment.

Throughout her medical record she had many other episodes of recurrent hypertriglyceridemic pancreatitis.

In order to achieve further dietary compliance the patient was hospitalized. Recommendations of dietary fat restriction and use of medium chain fatty acid were prescribed. Treatment with plasmapheresis was required on a couple of occasions managing reductions of triglycerides values. Other medications such as fibrates and niacin were previously prescribed with poor results. Family history of hypertriglyceridemia were found in her mother, brother and daughter.

Physical examination indicated esplenomegaly and lipemia retinalis.

Earlier diagnosis of chylomicronemia was made by the determination of LPL activity in plasma after an intravenous administration of heparin (<8%). Currently we are awaiting genetic analysis.

Nowadays she is under medical treatment with beta-fibrate.

Discussion

Our patient had typical findings of FCS: severe hypertriglyceridemia and acute relapsing hypertriglyceridemic pancreatitis.

In our case genetic analysis will shed light on the cause of the disease, detecting the mutation responsible.

The main focus of current therapy is low fat diet. Up until now existent medication were quiet ineffective except for plasmapheresis. Future medications are expected to be an important improvement.

This report aims to underline the importance of recognising manifestations in these individuals and the necessity to refer the patient to a lipids expert for further assessment.

#780 - Case Report

TETANY - A SERIOUS AND RARE PRESENTATION OF PRIMARY HYPERALDOSTERONISM.

Micaela Manuel, Andreia Tavares, Luisa Salgueiro, Raquel Almeida, José Meireles

Centro Hospitalar de Entre Douro e Vouga, Santa Maria Da Feira, Portugal

Introduction

Primary hyperaldosteronism is a frequent cause of secondary hypertension. Usual manifestations are resistant hypertension, hypokalaemia and metabolic alkalosis. Rarely, atypical manifestations can occur, such as myalgia, tetany or muscle paralysis, mimetizing neuromuscular diseases and making the diagnosis more difficult.

Case description

A 64-year-old man, physician, with a history of poorly controlled hypertension since he was 45 years old; currently was on nebivolol + hydrochlorothiazide (5 mg + 25 mg once daily). He had previously studied by a Neurologist for transient episodes of myalgia and muscle weakness, whose study included electromyography, muscle biopsy and genetic test for SCN4A, but the results were inconclusive.

In August/2018, he presented to the emergency department for myoclonus; the positive remarks of the physical examination were tetany and generalized fasciculations, blood pressure 197/102 mmHg; laboratory data revealed increase in serum muscular enzymes (creatinine phosphokinase 2250 U/L and myoglobin 788.6 ng/mL), renal impairment (creatinine 1.8 mg/dL), severe hypokalaemia (potassium 1.6 mmol/L) and hypomagnesemia (magnesium <0.25 mmol/L) and low ionized calcium (0.76mmol/L). He was admitted for correction of ionic disorders and hypertension control. A possible primary aldosteronism was suspected with further study showing a positive result for plasma aldosterone/renin ratio (ARR 142) and abdominal computed axial tomography showing heterogeneous nodular capillary formations in both adrenal glands. The saline overload test was positive, confirming the diagnosis of primary aldosteronism.

The patient was started on spironolactone, magnesium and potassium supplementation, with subsequent control of muscular symptoms and with blood pressure control to date.

Discussion

This clinical case demonstrates an atypical and severe presentation of an endocrine disorder - primary aldosteronism - with predominantly neuromuscular symptoms. Knowing the pathophysiology of the disease and its broad clinical spectrum may contribute to a timely diagnosis and appropriate treatment.

#790 - Abstract

PREVALENCE OF MICROVASCULAR COMPLICATIONS AMONG PATIENTS WITH DIABETES MELLITUS TYPE 2 AT A RURAL HOSPITAL IN NORTH GREECE

Triada Exiara¹, Dimitrios Tsiolpidis¹, Christina Kotsiari¹, Palmyra Tsiftsi¹, Asimina Migdalia¹, Chasan Ali¹, Elisavet Makridou¹, Savvas Katsaridis², Berkay Mollagiousoufoglou¹, Vasilios Tsipizidis¹, Argyrios Tsatsakoulis¹, Paschalis Karagiozakis¹

¹ General Hospital of Komotini, Komotini, Greece

² Alexander Technological Educational Institution of Thessaloniki Department of Nutrition and Dietetics, Thessaloniki, Greece

Background

Microvascular complications are the major outcome of Diabetes Mellitus Type 2 (DM2) which reduce the quality of life and increase diabetic mortality. The aims of this study were to assess the prevalence of microvascular complications among patients with DM2 in our area and to identify the association between these complications and clinical characteristics.

Methods

993 outpatients with DM2 and treatment for at least one year, 584 (58.8%) female and 409 (41.2%) male, with mean age of 56±8.7 years, were included. All subjects underwent a standard evaluation to detect diabetic retinopathy (fundus photography), neuropathy (vibration pressure threshold), and nephropathy (microalbuminuria/macroalbuminuria). Demographical, clinical and laboratory characteristics of patients registered and analyzed. Statistically analysis was done using SPSS version 20.

Results

332 (33.4%) patients had at least one microvascular complication and of those 187(56.3%) were female and 145 (43.7%) male. The prevalence of neuropathy, nephropathy and ocular lesions were: 172 (17.3%), 137 (13.8%) and 152 (15.3%), respectively. Of the 137 subjects with nephropathy conditions, 92 (9.3%) had single microalbuminuria, 16 (1.6%) macroalbuminuria, 12 (1.2%) renal hypofunction and 27 (2.7%) renal failure. Of the 152 subjects with ocular complications, 118 (11.9%) had cataract and 83(8.4%) retinopathy. 207 (62.3%) of the patients with microvascular complications had poor glycaemic control (HbA1c>7). The overall prevalence of complications significantly increased with disease duration, increasing age, female gender and presence of hypertension (p<0.001, p<0.001, p=0.002 and p<0.001, respectively).

Conclusion

Nearly one third of our patients with DMT2 had at least one microvascular complication. Disease duration, poor glycaemic control, age, gender and hypertension were associated with the presence of microvascular complications.

#793 - Case Report

AN ODD CASE OF PANHYPOPITUITARISM

Rita Gamboa Cunha¹, Mariana Certal¹, Ana Rafael¹, Ana Saavedra², Sandra Tavares¹

¹ CHTMAD - Hospital de Chaves, Chaves, Portugal

² CHTMAD, Vila Real, Portugal

Introduction

Hypopituitarism is a deficiency of one or more of the hormones produced by the pituitary gland. It usually occurs congenitally but it may also be acquired through replacement by tumors, infarction, infiltrative disorders, autoimmune diseases, trauma, and infections.

Case description

60-year-old Caucasian male with history of cranial multinevritis in October 2018 with a starting point on an acute sphenoidal sinusitis subjected to a sphenoidectomy. Since then he referred weakness, anorexia, weight loss and adynamia being committed twice, the first in December 2018 where he developed a hypovolemic shock due to a pseudomembranous colitis that evolved favorably. He was admitted in the emergency room in February 2019 with a loss of consciousness due to hypoglycemia. At observation he was confused, with slurred speech and a blood sugar level of 14 mg/dL. The head CT revealed no acute endocranial injuries. He was admitted in the ward to investigate the cause of the hypoglycemia. The laboratory studies revealed a panhypopituitarism (free T3 1.76 pmol/L, free T4 2.9 pmol/L, TSH 1.23 mUI/L, total testosterone 0.23 ng/mL, FSH 2.70 mUI/mL, LH 3.44 mUI/mL, PRL 12.0 mUI/L, ACTH 2.7 ng/L, cortisol 9.4 nmol/L, glucose 68 mg/dL, insulin 0.4 mcU/mL, C-peptide 0.20 ng/mL). He began hormonal therapy with cortisol and levothyroxine with no more episodes of hypoglycemia. The magnetic resonance imaging (MRI) discovered a lesion in the anterior lobe of the pituitary gland with 1x0.6 cm, that could be related with the previous inflammatory process given that the MRI of October showed an enlarged pituitary gland with contiguity to the sphenoidal sinus. The patient developed hypernatremia of 157 mEq/L that resolved without intervention 6 hours later. This sodium levels fluctuated, so the patient performed a fluid deprivation test. He presented an elevated seric osmolarity of 353 mOsm/L (>298 mOsm/L) 2h after the beginning confirming a diabetes insipidus and was administered 4mcg of desmopressin. Then the urinary osmolarity elevated > 9%, diagnosing the patient with partial central diabetes insipidus. He began desmopressin and was discharged maintaining the hormonal therapy.

Discussion

In this patient, we have a panhypopituitarism that, although

symptomatic, remained undiagnosed for at least 4 months. It is important to increase awareness among physicians of the risks of sphenoidal sinus diseases related with endocrinopathies and the need for appropriate endocrinological testing and substitutive therapies.

#795 - Abstract

PREVALENCE OF MACROVASCULAR COMPLICATIONS AMONG PATIENTS WITH DIABETES MELLITUS TYPE 2 AT A RURAL HOSPITAL IN NORTH GREECE

Palmyra Tsiftsi¹, Dimitrios Tsiolpidis¹, Christina Kotsiari¹, Chasan Ali¹, Elisavet Makridou¹, Asimina Migdalia¹, Savvas Katsaridis², Theodoros Kostakis¹, Bilal Bilal¹, Vasilios Tsipizidis¹, Berkay Mollagiousoyoglou¹, Argyrios Tsatsakoulis¹, Paschalis Karagiozakis¹, Alexandros Kakaris¹, Triada Exiara¹

¹ General Hospital of Komotini, Komotini, Greece

² Alexander Technological Educational Institution of Thessaloniki Department of Nutrition and Dietetics, Thessaloniki, Greece

Background

Chronic complications are the major outcome of diabetes mellitus type 2 (DMT2). Macrovascular disease that includes Coronary Heart Disease (CHD), Cerebrovascular Disease (CVD) and Peripheral Vascular Disease (PVD) is the leading cause of mortality in people with DM2. The aim of this study was to determine the prevalence and risk factors of macrovascular complications among patients with DM2 in our area.

Methods

993 outpatients with DMT2 and treatment for at least one year, 584 (58.8%) female and 409 (41.2%) male, with mean age 54±9.2 years, were included in this cross-sectional study. Cases were screened for macrovascular complications as per ADA criteria. Interviews, sociodemographical data, clinical characteristics and laboratory findings of patients registered and analyzed. Statistically analysis was done using SPSS version 20.

Results

274 (27.6%) patients had at least one macrovascular complication. The prevalence of CHD, CVD and PVD were: 231 (23.3%), 106 (10.7%) and 62 (6.3%), respectively. 581 (58.5%) patients had poor glycaemic control ((HbA1c>7) and 623 (62.7%) had hypertension. The risk factors for CHD were: hypertension (p<0.001), female gender (p=0.04), disease duration (p=0.002) and increasing age (p=0.04). The predictive risk factors for PVD were: male gender (p<0.001), increasing age (p<0.001), duration of diabetes (p<0.001) and hypertension (p=0.01). The risk factors for CVD were: increasing age (p=0.02), hypertension (p=0.001) and poor glycaemic control (p<0.01).

Conclusion

Nearly one third of our patients with DM2 had at least one

macrovascular complication and the most common is CHD. Greater awareness and screening to the macrovascular complications in patients with DM2 in our area is needed.

#806 - Abstract

AUTOIMMUNE PATHOLOGY AND DIABETES MELLITUS

Leonor Pereira Amaral¹, João Alves Correia^{1,2}

¹ Faculty of Health Sciences, University of Beira Interior, Covilhã, Portugal

² Sousa Martins Hospital, Guarda, Portugal

Background

The term autoimmune diabetes refers to a group of chronic diseases resulting from the interaction between genetic and environmental factors that predispose an individual to an abnormal immune response, which destroys beta cells, causes insulin deficiency and hyperglycemia. The destruction of these cells may be sudden in young people resulting in a permanent need for insulin (type 1 diabetes mellitus, DMT1) or be slower in adults, resulting in requiring insulin for at least 6 months after diagnosis (diabetes latent autoimmune in adults, LADA). The autoimmune process of pancreatic cells can progress and affect other organs, developing other autoimmune pathologies. This research aims to characterize the most frequently associated autoimmune diseases and emphasize the importance of its early detection.

Methods

An observational retrospective study was performed through consulting clinical processes of diabetic patients of the Internal Medicine and Pediatrics Service of the Sousa Martins Hospital from May 2018 to April 2019. All patients with a diagnosis of DMT1 and LADA were included in the study. The sample had 74 patients with DMT1 and 24 patients with LADA. Relevant data of the process were collected, such as, age, sex, age of the onset of diabetes, antidiabetic therapy, HbA1c, BMI, presence of autoantibodies and associated autoimmune diseases. The statistical analysis was performed using SPSS Statistics version 24.

Results

Autoimmune diseases were found in 24.32% of patients with DMT1 and in 41.67% of patients with LADA, affecting a total of 28 patients. Comparing the two groups, no significant difference was found regarding the percentage of patients with autoimmune diseases. The most common disease in the sample studied was autoimmune thyroiditis, found in 17 patients. Other diseases have also been reported, such as vitiligo, ulcerative colitis, autoimmune hepatitis, autoimmune gastritis, Graves' disease, systemic lupus erythematosus, rheumatoid arthritis and celiac disease. GADA-65 was the most common autoantibody, being more frequent in the LADA group (94.12%).

Conclusion

This study showed a high proportion of autoimmune diseases in

patients with autoimmune diabetes. Regular screening of these patients for autoimmune diseases is needed. Only the combination of demographic, immunological and genetic characteristics makes possible to increase the ability to predict autoimmune diseases associated with diabetes, which will allow better treatment and better glycemic control.

#807 - Case Report

RAPIDLY PROGRESSIVE DEMENTIA AS A MANIFESTATION OF INSULINOMA

Marília Santos Silva, Cristina Rodrigues

Hospital Pedro Hispano - Matosinhos local Health Unit, Matosinhos, Portugal

Introduction

The occurrence of repeated or persistent episodes of hypoglycemia in a well-nourished non-diabetic patient is not a common finding and demands careful evaluation.

Case description

Here is presented the case of an 84-year-old male patient, with progressive cognitive impairment being investigated at Neurology Consult, who is admitted to the Emergency Department with the diagnosis of respiratory and urinary sepsis and with hypoglycemia only controlled with glucose infusion at 30%, between 21 and 42 ml/h. The family mentioned progressively more frequent episodes of irritability and aggressiveness, followed by apathy, over the previous years. Those episodes appeared to be most frequent in periods of longer fasting and improved with sweetened water. Increased eating habits were also noted, with consequent weight gain. In the previous four months, interpersonal relations were minimized.

Considering the high index of suspicion for endogenous hyperinsulinism, insulin and C peptide were measured after permission of hypoglycemia, both being raised. Considering these findings, the diagnosis of insulinoma was assumed, with greater glycemic decontrol in the context of sepsis that came to be fatal to this patient.

Discussion

This case reminds us of the need to keep a high index of suspicion for this kind of diagnosis, easily mistaken for dementia, especially in the elderly. The early diagnosis may have a great impact on prognosis.

#808 - Case Report

SCHIMIDT'S SYNDROME

Alejandra García García, Isabel Jimenez Hinarejos, John Molina Torres

Hospital General Universitario Gregorio Marañón, Madrid, Spain

Introduction

We present the case of a 39-year-old woman with hyperpigmentation, abdominal pain and hypothyroidism

Case description

We present a 39-year-old woman from Paraguay who was diagnosed 9 years ago with hypothyroidism and early menopause. She went to the emergency room due to a progressive clinical picture of nausea, vomiting and abdominal pain, associated with severe asthenia, loss of 11 kg of weight in the last 4 months.

On examination she has a blood pressure of 90/60 mmHg, mucosal hyperpigmentation at the gums, hard palate, peribuccal region and also on the back of both hands, feet, breast areoles and elbows.

Laboratory tests include sodium 126 mmol/L, potassium 5.7 mmol/L, standard high-dose ACTH stimulation test with basal and 60-minute after injection serum cortisol levels both <0.1 mcg/dL with baseline ACTH levels 397.7 ng/L confirming the diagnosis of primary adrenal insufficiency.

Other test included TSH levels 50.74mIU/L, free T4 0.7ng/dL, HbA1c 6.2%, Autoimmunity studies with anti-thyroglobulin antibodies > 4794 IU / mL, anti-TPO > 1542 IU / mL, anti-iodide peroxidase > 1130 IU / mL, anti-adrenal antibodies IFA positive 1/10 and study of celiac disease negative. The body CT-scan did not show adrenal or any other focal lesions.

Empirical treatment with hydrocortisone was started at a dose of adrenal crisis with symptom resolution.

Discussion

The autoimmune type 2 polyglandular syndrome, Schmidt's syndrome, is a disease with low prevalence that is characterized mandatory by the presence of primary adrenal insufficiency, thyroid autoimmune disease (usually chronic autoimmune thyroiditis but Grave's disease may also be present) and/or type 1 diabetes mellitus. As for the treatment, it is based on hormonal replacement therapy for each individual disorder.

#810 - Abstract

THE PREVALENCE OF SKIN DISORDERS IN TYPE- 2 DIABETIC PATIENTS IN A REGION OF NORTH GREECE

Christina Kotsiari¹, Dimitrios Tsiolpidis¹, Palmyra Tsiftsi¹, Vasilios Tspizidis¹, Argyrios Tsatsakoulis¹, Elisavet Makridou¹, Chasan Ali¹, Paschalis Karagiozakis¹, Asimina Migdalia¹, Berkay Mollagiousoufoglou¹, Theodoros Kostakis¹, Savvas Katsaridis², Triada Exiara¹

¹General Hospital of Komotini, Komotini, Greece

² Alexander Technological Educational Institution of Thessaloniki Department of Nutrition and Dietetics, Thessaloniki, Greece

Background

Patients with diabetes mellitus often show skin manifestations. The aim of this study was to evaluate the frequency of skin lesions in type-2 diabetic patients (DM2) in our area and their relationship with control of diabetes.

Methods

483 outpatients with DM2, 298 (61.7%) female and 185 (38.3%)

male with mean age of 57±13.6 years, during a three-year period, were included in this study. The mean duration of diabetes was 9±6.4 years. All patients underwent physical examination for detection of skin disorders with help of dermatologist and culture/biopsy of skin was performed when it was necessary. Hematological examinations and glycated hemoglobin were performed in all patients. Student's t-test was used for statistical analyses.

Results

332 (68.7%) patients had at least one skin disorder and 228 (68.7%) of them had poor glycaemic control (HbA1c>7.0). The lesions registered for the first time in 257 (77.4%) cases. 13 (64.2%) patients had a combination of skin lesions. The most frequent skin manifestations were: fungal infections in 187 (38.7%) cases, bacterial infections in 78 (16.1%), pruritus in 59 (12.2%), hyperkeratosis, skin xerosis, eczemas in 54 (11.2%) cases (mostly neurodermatitis), diabetic dermopathy in 92 (19.1%), acanthosis nigricans in 81 (16.8%) cases. Tinea pedis (82/187) was the commonest fungal skin infection followed by tinea unguium (63/187) and Candida albicans (42/187). Higher frequency of skin lesions was found to be associated to aging processes. Fungal infections were more common in patients with poor glycemic control.

Conclusion

Skin disorders are common with varied manifestations in patients with DM2. Systematic dermatological examination, frequent follow up and good glycemic control are the keys to confront the skin lesions in diabetics.

#832 - Case Report

CONN'S DISEASE WITH NORMAL ALDOSTERONE

Reem Musa, Loay Al Dhahir

Dr.Sulaiman Al Habib Medical Group, Riyadh, Saudi Arabia

Introduction

Primary hyperaldosteronism is a common cause of secondary hypertension and hypokalaemia, caused by aldosterone-producing adenomas or bilateral adrenal hyperplasias. It's an underdiagnosed cause of hypertension where diagnosis confirmed with elevated aldosterone to plasma renin ratio.

The authors present unusual case of hypokalemic hypertension but normal aldosterone despite frequent checking, finally diagnosis turns out to be Conn's syndrome as the patient cured with adrenalectomy and histopathology confirms Conn's.

Case description

41 years old Asian male, presents with recurrent symptomatic hypokalaemia required many hospital admissions for intravenous potassium despite being on oral supplement.

He reports no diuretic, laxative or alcohol abuse, no history of

chronic diarrhoea or vomiting. No family history of hypokalemic periodic paralysis and he is lifelong non-smoker.

Apart from hypertension normal physical examination, he started on Spironolactone with good blood pressure control and normal potassium level for 4 years.

The normal renin, cortisone along with normal examination and MRI put Cushing's, Liddle's and renal artery stenosis out of differential.

CT abdomen with contrast showed right adrenal lipid rich adenoma (1.7x1.23cm) with almost same size after 2 years, but again with normal aldosterone

Patient refused biopsy or adrenalectomy and prefers to continue on spironolactone. He responds well and after 4 years of conservative treatment agreed for surgical intervention although there was no guarantee that adrenalectomy will cure his condition. Laparoscopic Adrenalectomy done and histopathology reported as Adrenocortical adenoma, patient discharged home on no medications, follow up visits revealed normotension with normal potassium levels 6 months postoperatively.

Discussion

Conn's treated with adrenalectomy in those with unilateral disease. Bilateral adrenal hyperplasia or poor surgical candidates can be treated with mineralocorticoid antagonists and antihypertensive. Morbidity and mortality are related to hypertension leading to cardiovascular disease or hypokalemia induced arrhythmias.

We report that Conn's disease may presents with hypokalemic hypertension despite normal aldosterone and the standard management remains effective.

#870 - Case Report

SUNCT SYNDROME SECONDARY TO MACROPROLACTINOMA

Carolina Paiva, Paulo Carvalho Ferreira, Filipe Correia, Helena Greenfield, Raquel Santos, Rui Mõço
Hospital Pedro Hispano, Matosinhos Local Health Unit, Matosinhos, Portugal

Introduction

Short-lasting unilateral neuralgiform headache attacks with conjunctival injection and tearing (SUNCT) is usually a primary headache disorder. However, some cases are potentially secondary to intracranial lesions, mostly of them located in the posterior fossa or in the pituitary gland. Regarding this last one, it has been described in patients both with micro and macroadenomas, with attacks occurring on the side ipsilateral to the site of the tumor.

Case description

The authors present a case of a 48-year-old male, with no relevant pathological history, who presented to the emergency department with complaints of pain with about 2 months of evolution in the left wing of the nose with irradiation to the ipsilateral supraorbital region, with "saw-tooth" attacks of

continuous pain with multiple superimposed stabs. In association he reported nasal obstruction, rhinorrhea, and lacrimation of the left eye. At the objective examination, nothing to be highlighted. Cerebral magnetic resonance imaging was performed and showed an expansive lesion of larger diameters 29x39x45 mm with left parasellar extension, compatible with pituitary macroadenoma. The hormonal study revealed hyperprolactinemia of 13427.44 ng/mL with LH decreased 0.47 mUI/mL and without further changes (TSH: 1,029 uUI/mL, FT3: 2.25pg/mL, FSH: 1.55mUI/mL, PTH: 30.8pg/mL, ACTH: 26.17pg/mL). He was medicated with dopaminergic agonist in an increasing dose up to 1mg 2x/week. At three months of follow-up without new episodes of headache and runny nose; analytically with prolactin in descending profile 2482,83 ng/mL, and normalization of LH 1.61 mUI/mL; Brain imaging showing a reducing size prolactinoma 36x34x24mm.

Discussion

The diagnosis of SUNCT is based on clinical history and the semiology of the headache presented here is highly suggestive. Medical treatment of the prolactinoma led to a resolution in headache symptoms, that were ipsilateral to the lesion. This suggests that the prolactinoma was triggering the symptoms.

#901 - Abstract

PREVALENCE OF MICROVASCULAR COMPLICATIONS AMONG PATIENTS WITH NEWLY DIAGNOSED DIABETES MELLITUS TYPE 2 IN OUR AREA

Dimitrios Tsiolpidis¹, Palmyra Tsiftsi¹, Christina Kotsiari¹, Savvas Katsaridis², Berkay Mollagiousoufoglou¹, Asimina Migdalia¹, Elisavet Makridou¹, Vasilios Tsipizidis¹, Theodoros Kostakis¹, Paschalis Karagiozakis¹, Argyrios Tsatsakoulis¹, Bilal Bilal¹, Triada Exiara¹

¹ General Hospital of Komotini, Komotini, Greece

² Alexander Technological Educational Institution of Thessaloniki Department of Nutrition and Dietetics, Thessaloniki, Greece

Background

Diabetes Mellitus Type 2 (DM2) is associated with an increased risk for a number of serious macrovascular and microvascular complications which reduce the quality of life and increase diabetic mortality. The aim of this study was to determine the prevalence and clinical profile of microvascular complications in newly diagnosed DM2 patients in our area.

Methods

118 newly diagnosed DM2 patients according to ADA criteria, 67 (56.8%) female and 51 (43.2%) male with mean age of 52.7±9.4, during one-year period, were included in this cross-sectional study. All subjects underwent a standard evaluation to detect diabetic retinopathy (fundus photography), neuropathy (vibration pressure threshold), and nephropathy (microalbuminuria/macroalbuminuria). Demographical, clinical and laboratory data

of patients registered and analyzed. Statistically analysis was done using SPSS version 20.

Results

67 (56.8%) patients had at least one microvascular complication. The prevalence of neuropathy, nephropathy and retinopathy were: 19 (16.1%), 38 (32.2%) and 29 (24.6%) respectively ($p=0.358$, $p=0.003$ and $p=0.02$, respectively). Of the 38 subjects with nephropathy conditions, 33(28%) had single microalbuminuria, 5 (4.2%) macroalbuminuria and 3(2.5%) renal hypofunction. 27 (22.9%) cases had nonproliferative diabetic retinopathy and 2 (1.7%) cases had proliferative retinopathy. 89(75.4%) patients had poor glycaemic control ($HbA1c>7$). Incidence of retinopathy and nephropathy was significantly higher in patients who had $HbA1c>7\%$ than patients with $HbA1c\leq 7\%$ ($p<0.05$).

Conclusion

Nearly half of our patients with DM2 had at least one microvascular complication at diagnosis. There is high prevalence of nephropathy and retinopathy at diagnosis of DM2, which is statistically significant. Screening all newly diagnosed DM2 patients for complications is essential to identify them at an early reversible stage.

#952 - Case Report

LIFE-THREATENING ANTACID? A CASE OF EXTREME METABOLIC ALKALOSIS

Estela Ferrão, Francisca Pulido Valente, Rodrigo Pereira Andrade, Maria José Grade, Luísa Arez
Algarve University Hospital Center; Hospital de Portimao, Department of Internal Medicine, Portimão, Portugal

Introduction

Although metabolic alkalosis is a common electrolytic disturbance, its extreme form is not as common. A serum pH higher than 7.6 is associated with a mortality rate up to 80%.

There is a wide differential diagnosis concerning this condition. The diagnosis is particularly difficult in the absence of a reliable clinical history and if concurrent comorbidities act as potential confounding factors.

Case description

A hypertensive 50-year-old man was brought to the Emergency Room because of a 2 weeks history of vomiting, diarrhea, decreased oral intake, weight loss and general weakness. He had a generalized tonic-clonic seizure on admission.

The wife reported he had been intermittently taking an antacid (sodium bicarbonate) for the last 10 years, sometimes in a daily basis, to relieve pyrosis due to an alleged not treated peptic ulcer. On physical examination described as disoriented, confused. BMI 19. Sunken eyes, dry skin and mucous membranes. Anuric.

Laboratory results: urea 80 mg/dl, creatinine 4.2 mg/dl. ABG test (ambient air): pH 7.7 pCO_2 64 mmHg, pO_2 37 mmHg, K^+ 2.9 mmol/l HCO_3^- 82 mmol/l

Abdominal X-ray, ultrasound and CT: signs of gastric and duodenal distension.

ECG: Sinus rhythm, QT prolongation.

Head CT: no alterations.

He was transferred to the intensive care unit with severe volume depletion and hydroelectrolytic disturbance, and an acute oliguric kidney injury with acute tubular necrosis, requiring intravenous HCL and dialysis. After an extensive investigation a definitive diagnosis of metabolic alkalosis caused by sodium bicarbonate intake was made.

Discussion

This case highlights how challenging the differential diagnosis of metabolic alkalosis can be, and the importance of obtaining a reliable clinical history.

The difficulty obtaining the definitive diagnosis was worsened because the triad of hypertension, metabolic alkalosis and hypokalemia pointed to the possible presence of an aldosterone-producing tumor among other conditions.

The dyspepsia and past ulcer history suggested a pyloric stenosis. It also emphasizes the dangers of over-the-counter medicines, assumed as not having medical significance and that can be life threatening and culminate in death. Because of its availability without a prescription, the use of antacids is common and must be considered as a potential cause of metabolic alkalosis, especially if there is a history of dyspepsia or gastro esophageal reflux.

#959 - Abstract

DEVELOPMENT OF METABOLIC SYNDROME IS ASSOCIATED WITH BIOLOGICAL AGING PROCESS

Beom Jin Kim¹, Hyun Kang¹, Sang-Jung Kim²

¹ Chung-Ang University Hospital, Seoul, South Korea

² Bundang Jesaeng Hospital, Seongnam, South Korea

Background

Metabolic syndrome (MetS) is a cluster of metabolic abnormalities, which increase with age. Biological age (BA) determined by physiology reflects the functional state of the body. To date, no worldwide studies have been conducted to estimate the clinical utility of BA as a new indicator in MetS.

Therefore, the aim of the present study was to evaluate the development of MetS in terms of biological aging.

Methods

A consecutive series of asymptomatic subjects aged ≥ 30 years who underwent routine check-ups were enrolled. Clinical profiles such as physical, biochemical, and hormonal parameters for calculating BA were collected. BAs were calculated using the MEDIAGETM Biological Age Measurement System. Specially, body shape BA was calculated as following: $-137.388 + 224.964$ (Waist-hip ratio) $- 0.245$ (Height) $+ 0.631$ (Hip circumference) $- 0.2$ (Lean body mass%) $- 0.123$ (Waist circumference). This measurement system

has been used as an adjunctive measure for easily predicting individual differences in health and aging status with the use of clinical parameters that are commonly used at many health check-up centers in Korea.

Results

A total of 2,677 subjects were investigated. The mean chronological age (CA) was 46.0 years and the mean BA was 44.7 years. MetS was diagnosed in 216 subjects (8.1%). The prevalence of MetS increased with increasing BA ($P < .001$). Especially, the gradient of prevalence of MetS in BA was higher than that in CA. When the subjects were divided into two groups based on an age gap between BA and CA, Biologically older group ($BA-CA \geq 0$) and biologically younger group ($BA-CA < 0$), the incidence of MetS in the biologically older group was significantly higher than in the biologically younger group ($P < .001$). When the subjects were categorized into quartiles according to age gap between BA and CA, the prevalence of MetS increased with increasing quartiles of age gap between BA and CA ($P < .001$).

Conclusion

Development of MetS is affected by biological aging process. Therefore, measurement of BA may help to estimate the risk of MetS among the general population.

#971 - Case Report

AN UNUSUAL CAUSE OF DYSPNEA.

Sandra Piqueras Ruiz, Lucía Ordieres Ortega, Sergio De Santos Belinchón, Juan Carlos Cano Ballesteros
Hospital General Universitario Gregorio Marañón, Madrid, Spain

Introduction

Graves-Basedow disease (GBD) is an autoimmune disease, which is the most frequent cause of hyperthyroidism. We present a case with one of the less common symptoms, pulmonary hypertension, sometimes difficult to diagnose if thyroid symptoms are scarcely present.

Case description

A 74-year-old male with a medical history of gastroesophageal reflux disease (GRD) arrives at the Emergency Department with a main complaint of progressive dyspnea in the previous two weeks, chest pain (similar to his previous GRD episodes), odynophagia, dizziness and a constitutional syndrome with unquantified weight loss.

Upon physical examination, he presented an oxygen saturation of 91%, sinus tachycardia of 120 bpm and bibasal crackles. An electrocardiogram confirmed sinus tachycardia, a chest X-ray and blood test were normal (NT-proBNP 94 pg/ml).

The patient was admitted into the Internal Medicine ward to complete the study. A transthoracic echocardiogram showed the existence of pulmonary arterial hypertension (PAH), with a pulmonary artery pressure of 58 mmHg. A computerized

tomography (CT) of the pulmonary arteries relinquished the presence of pulmonary thromboembolism. A spirometry showed mild airflow obstruction (Tiffeneau Index 73%), with a negative bronchodilation test. A blood test exhibited primary hyperthyroidism (TSH < 0.01 ng/dl, T4 7.5 ng/dl), with positive antithyroid antibodies (Ac-anti-TPO 332.3 IU/ml, Ac-Anti-TSH 10.2 IU/L). A thyroid gammagraphy was thus performed, demonstrating diffuse hypercaptation compatible with GBD. The patient presented a good clinical and symptomatic evolution, after the initiation of antithyroid and beta-blockers treatment. He is currently asymptomatic.

Discussion

Although GBD is a common cause of hyperthyroidism, it may present with rare manifestations, including the one presented in this manuscript. An association between PAH and hyperthyroidism has been described, and PAH may be detected in up to 40% of patients with thyroid dysfunction. However, the treatment of thyroid disease can improve PAH, and for this reason, in patients with an unknown etiology of PAH, thyroid dysfunction should be ruled out.

#980 - Case Report

PITUITARY APOPLEXY AFTER ACUTE PULMONARY THROMBOEMBOLISM

Rute Sousa Martins, Sara M. Rocha, Fátima Farinha
centro hospitalar universitário do Porto, Porto, Portugal

Introduction

Pituitary apoplexy is a rare, life-threatening syndrome caused by acute pituitary hemorrhage or pituitary infarction, usually in an adenoma pituitary gland; it can occur acutely, with headache, neuro-ophthalmological symptoms and death, or subacute with evolution from days to weeks.

Case description

A 65-year-old woman with dyslipidemia, obesity, and degenerative osteoarticular disease, admitted to the emergency department for dyspnoea and chest pain; was diagnosed with a acute pulmonary thromboembolism at intermediate risk of mortality, having started hypocoagulation (low molecular weight enoxaparin). On the 5th day of hospitalization cephalic and paresis clinic of the third right pair, having EC MRI that revealed pituitary hemorrhage, apparently grafted previously unknown macroadenoma. It was evaluated by Neurosurgery, with indication for emergent surgery, but for suspension of hypocoagulation and insertion of vena cava filter. After serial evaluations and for maintaining stability of hemorrhagic lesion, returned to treatment with oral hypocoagulation. Evolution with hypopituitarism with anterior pituitary attainment and the need to initiate supplementation with levothyroxine and hydrocortisone (initiation of intravenous later orally). Table of polyuria-polydipsia of post-event onset, it was not possible to carry out the water restriction test (logistic question). Suspicious of central diabetes insipidus, and therefore

initiated desmopressin with improved symptomatic. She was highly oriented to ophthalmology reassessment consultation, neurosurgery and endocrinology.

Discussion

Pituitary apoplexy is a potentially fatal neuroendocrine emergency that requires immediate therapy. This entity must always be considered as a differential in a patient who presents with sudden, intense headache and neuro-ophthalmologic. A multidisciplinary approach, as described in the above case, is treatment and follow-up.

#981 - Case Report

A CASE OF KIKUCHI FUJIMOTO DISEASE AND QUERVAIN'S THYROIDITIS

Liliana Filipa Ribeiro Dos Santos, Ana Teresa Melo*, Ana Fúrao Rodrigues, Rita Pinto Medeiros, Ana Paula Vilas
Serviço de Medicina 2B- Hospital de Santa Maria - Centro Hospitalar Lisboa Norte, Lisboa, Portugal

Introduction

The association of weight loss, fever and enlarged lymph nodes may be due to several clinical conditions, mainly infectious diseases or lymphoproliferative and autoimmune disorders. Diagnosis is often difficult and a long term follow-up is warranted.

Case description

A 36-year-old Indian woman was referred to our Internal Medicine Department because of an one-month history of fatigue, weight loss, fever, sore throat and dry cough, along with multiple cervical painful lymphadenomegalies. An atypical upper respiratory infection had been suspected and azithromycin had been prescribed with no improvement. On examination, she had a painful stone-like mass on her central lower neck and some rubbery nodules in the left antero-lateral cervical lymph nodule chain. Her blood tests showed a persistent elevation of inflammatory markers (CRP 7.64 mg/dL and ESR 120mm/hr) and a new onset hyperthyroidism (TSH 0.017 uU/dL (RV 0.30-4.2); FT4 2.86 ng/dL (RV 0.93-1.7) with negative thyroid antibodies. On the prior year she had been diagnosed with lymph node tuberculosis (TB) and she had been treated with isoniazid, rifampicin, pyrazinamide and ethambutol with complete remission. TB recurrence and thyroid TB were therefore suspected. Investigation, however, ruled out tuberculosis. The neck ultrasound scan showed a heterogeneous and infiltrative thyroid and adenomegalies on the left antero-lateral cervical chain. The CT scan only showed another 2cm adenopathy on the celiac territory. The histological study of the fine-needle aspiration of the neck mass diagnosed a subacute thyroiditis (Quervain's thyroiditis) and immunophenotyping excluded a lymphoproliferative disorder. She was discharged but a couple of weeks later new tender lymph nodes appeared on the neck. An excisional biopsy of the largest nodule diagnosed necrotizing histiocytic lymphadenitis (Kikuchi Fujimoto's disease). Remission was achieved only with symptomatic treatment.

Discussion

Kikuchi-Fujimoto's disease (KFD) is a rare, benign and self-limited disease. The etiology and pathogenesis of KFD is still not completely understood. However, two hypothesis have been proposed: a viral infection hypothesis and an autoimmune hypothesis. In the presented case, a viral infection is the probable trigger for both diseases, KFD and Quervain's thyroiditis. Although there are several reports on the association of autoimmune thyroiditis and KFD, this is, as far as we know, the first case of KFD in a patient with QT.

#1020 - Abstract

IMPACT OF DEMOGRAPHIC AND CLINICAL CHARACTERISTICS ON DIABETIC NEUROPATHY

António José Santos Assunção¹, Dina Manuela Soeiro Marinho De Campos², Rui Marques³, César Matos⁴, Patrícia Santos⁵, Ana Teresa Bogalho Rebelo⁶, Inês Cunha³

¹ USF Viriato, Mundão, Portugal

² USF Viriato, Viseu, Portugal

³ Centro Hospitalar Tondela Viseu, Viseu, Portugal

⁴ UCSP Azeitão, Azeitão, Portugal

⁵ USF Sobreda, Almada, Portugal

⁶ USF Cidade Jardim, Viseu, Portugal

Background

Diabetic neuropathy is one of the most devastating complications of diabetes; however, unlike other countries, there aren't any studies to evaluate the impact of the demographic and clinical characteristics of this pathological entity in Portugal. The present study aimed at evaluating the impact of gender, age, metabolic control, and onset of disease with symptoms of neuropathic pain.

Methods

This study was conducted on a sample of 359 patients from several medical centers. Data was analyzed using a quantitative method, with the statistical software package Statistical Package for Social Science 24. The p value defined to consider a statistically significant result was $p < 0.05$. To determine the relationship between categorical variables, the Spearman correlation coefficient (r) was determined.

Results

There was no statistically significant difference in the prevalence of diabetic neuropathy between gender ($p=0.633$ and $r=0.025$). There was a statistically significant correlation between the value of HbA1c and diabetic neuropathy, with $p=0.010$ and $r=0.136$. There is a correlation between the age and symptoms of neuropathic pain, with a $p=0.034$ and $r=0.112$. Furthermore, there is a correlation between time since onset of disease and symptoms of neuropathic pain, with a $p=0.020$ and $r=0.112$.

Conclusion

The prevalence of neuropathic pain in diabetics is not negligible

and is associated with modifiable risk factors, thus being preventable. The correct approach of these patients implies screening and early treatment and contributes decisively to the improvement of functionality and life quality.

#1029 - Abstract

MULTICENTER STUDY: REGISTRATION OF HYPERGLYCEMIA IN INTERNATIONAL INTERNAL MEDICINE (REGLUMI)

Pascual Valdez¹, Darío Leff¹, Julio Wacker¹, Andrea Odzak¹, Luis Alberto Cámara², Mauricio Fiori², José Daher², Oscar Caravelo², Diana Fernandez², Adrian Cruciani², Carlos Perez², Cecilia Vanzetti², Martina Calvo², Pablo Kuschner², Cristian Panigadi², Paula Castro², Ana Cantillo²

¹ Research Council of the Argentine Society of Medicine (SAM), Caba, Argentina

² Research Council of the Argentine Society of Medicine (SAM), Buenos Aires, Argentina

Background

Objectives is to determine the prevalence of hyperglycemia in patients admitted to a medical clinic.

Methods

Prospective-observational-longitudinal-analytical study. Included are patients admitted to a medical clinic, multicenter study in 42 centers, with 2 years of recruitment. Consecutive sampling.

Results

Recruited 5925. Male gender 50.3%. Age 60.66 ± 0.25 years. Stay 12.61 ± 0.24 days, higher in surgery (15.45 ± 0.67 vs 11.76 ± 0.23, $p < 0.00001$). 23% received surgical treatment. Mortality 9.26%. BMI: 27.88 ± 0.65. 41.4% presented hyperglycemia more than once. Mean higher glycemia: 163.50 ± 1.23 (in DBT 2: 255.39 ± 3.04, in DBT 1: 199.81 ± 15.12). Mortality was higher with blood glucose higher than 110 ($p < 0.02$). Required Insulin: 31.37%. Corticosteroids use: 25.40%. Corticosteroids were associated with greater insulin use (35.34% vs 30.02%, $p < 0.0001$) and more infections (45.98% vs 42.01%, $p < 0.007$). Glycosylated Hb: 7.92 ± 0.08 (8.44 ± 0.09 in known diabetics and 9.63 ± 0.31 in unknown). 46% were categorized as normoglycemic, 4% as stress, 21% were not typified, 29% were diabetes. The use of insulin was associated with more symptomatic hypoglycemia (3.44% vs 0.44%, $p < 0.00001$) and asymptomatic hy

Conclusion

Conclusions: prevalence of hyperglycemia 54%, several new diagnoses of diabetes. Diabetes was not predictive of mortality in the multivariate analysis.

#1064 - Case Report

FROM HYPO TO HYPERTHYROIDISM - AN INCARCACTERISTIC EVOLUTION

Vanda Conceição, Alexandra Ávila, José Sousa, Nuno Vieira, Maria José Grade, Luisa Arez

Serviço de Medicina 3 - Unidade Hospitalar de Portimão do Centro Hospitalar Universitário do Algarve, Portimão, Portugal

Introduction

Toxic thyroid adenoma is one of the major etiologies of hyperthyroidism, as well as Graves' Disease and the Toxic Multinodular Goiter and it can be defined as a functioning autonomic nodule. Clinically and analytically similar to other forms of thyrotoxicosis. This diagnosis is confirmed by the presence of a warm nodule in thyroid scintigraphy. The timely treatment allows the avoidance of complications of hyperthyroidism, such as cardiac dysfunction, loss of bone mass or tracheal compression caused by large nodularities.

Case description

A 65-year-old woman, with comorbidities of Arterial Hypertension, Dyslipidemia and Depressive Syndrome, had a history of Hypothyroidism and Multinodular Goiter diagnosed 10 years ago and medicated daily with 200 µg of levothyroxine. In July 2018 she began to suffer from dyspnea, sensation of a foreign body and dysphagia, anxiety and palpitations. Analytically with evidence of de novo hyperthyroidism (TSH 0.01 µUI / mL, T4L 18.79 ng / dL), for which Levothyroxine was discontinued.

The thyroid ultrasonography revealed the right lobe mostly occupied with nodular lesion of a solid isoecogenic component with 36mm. Reassessment of thyroid function 3 months after suspension of levothyroxine revealed persistence of hyperthyroidism (TSH 0.02 µIU / mL, T4L 18.5 ng / dL and Negative antithyroid antibodies).

For better clarification it was used the Thyroid Scintigraphy that demonstrated a voluminous hot nodular formation to the right that slows the surrounding tissue (Autonomous Node), thus diagnosing the new appearance of a Toxic Adenoma with Hyperthyroidism in previously hypothyroid patient. It was initiated anti-thyroid therapy. With clinical and analytical improvement.

Discussion

Primary hyperthyroidism de novo in a previously hypothyroid patient, associated with the appearance of a toxic adenoma as occurred in this case, is an uncharacteristic and rare development in patients with chronic hypothyroidism. However, this case alerts us to the importance of the clinical and analytical monitoring of these patients, since a rapid investigation and its therapeutic adjustment will allow us to reach the euthyroid state more quickly, avoiding the complications associated with the thyroid dysfunction.

#1066 - Case Report

QUERVAIN'S THYROIDITIS MANIFESTED AS AN INDETERMINATED FEBRILE SYNDROME

Vanda Conceição, Alexandra Ávila, José Sousa, Nuno Vieira, Maria José Grade, Luísa Arez

Serviço de Medicina 3 - Unidade Hospitalar de Portimão do Centro Hospitalar Universitário do Algarve, Portimão, Portugal

Introduction

Thyroiditis of Quervain is an inflammatory condition of the thyroid, probably of viral etiology. This diagnosis is complicated, because of the great variability of presentation, which can range from hyper to hypothyroidism, associated with systemic symptoms and cervical pain. We present a case that stands out for its exuberant presentation as a persistent febrile syndrome with intense systemic repercussion.

Case description

A 52-year-old woman, with no comorbidities or any relevant previous medical history, started a high fever, predominantly in the evening, accompanied by profuse sweating, malaise, myalgias and migratory polyarthralgia without inflammatory signs. She also mentioned anterior cervical pain andodynophagia. The observation points out an increase in the cervical perimeter and palpable cervical adenomegalies.

In ambulatory, the blood analyses revealed clinical hyperthyroidism with anti-thyroid negative antibodies. Thyroid ultrasound showed an heterogeneous thyroid with thyroid nodules and cervical adenomegalies. The aspiration cytology revealed a follicular lesion of undetermined significance and a Thyroid Scintigraphy demonstrated generalized hypocaptation. The hypothesis of primary hyperthyroidism due to destructive thyroiditis was chosen and the patient started symptomatic treatment with nonsteroidal anti-inflammatory drugs.

There was an unfavorable evolution with persistent fever and a breakdown of the general condition of the patient that led to her hospitalization at the end of one month of fever to exclude other causes for the febrile syndrome. The study was negative for other causes. The fever subsided after about two and a half months coinciding with the improvement of complaints of cervical pain. Analytically, clinical hyperthyroidism evolved to clinical hypothyroidism and finally the patient became euthyroid, without the need for anti-thyroid or levothyroxine therapy.

Discussion

The present case is illustrative of Quervain Subacute Thyroiditis, which typically presents by the association of cervical pain, systemic symptoms and three - phase evolution of thyroid function (Hyper - Hypo - Euthyroidism). However, the intensity and persistence of fever and other systemic symptoms that justify the differential diagnosis with other conditions associated with a febrile syndrome of undetermined origin are emphasized.

#1082 - Case Report

DIABETIC KETOACIDOSIS, IN THE CONTEXT OF SGLT2 INHIBITORS - ABOUT A CLINICAL CASE

Rosana Maia, Marta Moreira, Pedro Pinto, Miguel Costa, Duarte Silva, Edgar Torre, Carmélia Rodrigues, Diana Guerra

ULS Alto Minho - Hospital de Santa Luzia - Viana do Castelo, Viana do Castelo, Portugal

Introduction

Inhibitors of SGLT2 (iSGLT2) lower serum glucose levels through urinary excretion, and are recommended for the treatment of Type 2 Diabetes Mellitus (DM). Diabetic ketoacidosis (CAD) in the context of these drugs is rare, with an incidence of 1/1000 people/year.

Case description

Female, 67 years old, with type 2 DM and dyslipidemia, treated with empaglifozine 25 mg and atorvastatin 20 mg, is referred to the Emergency Department for nausea, polydipsia, asthenia and malaise. At the precious day, vomiting, followed by dizziness, with a fall, without loss of consciousness. In addition, chest pain, palpitations, dyspnoea and hypersudoresis. In the prehospital evaluation by emergency medical team, Atrial fibrillation (AF) with rapid ventricular response (RVR) was identified, with frequency control after metoprolol. Physic examination: dehydrated and polypnea. Blood pressure 126/70 mmHg, oxygen saturation (SatO₂) 96% (FiO₂ 21%), glycemia 317 mg/dL. Cardiac Auscultation (A): S1 and S2 present, arrhythmic. Pulmonary A: normal. Analysis: Hgb 16.3 g/dL, Leukocytes 11.92x10⁹/L, Platelets 274x10⁹/L, Urea 49 mg/dL, Creatinine 1.18 mg/dL, Glucose 326 mg/dL, normal hepatic profile and myocardial necrosis markers. Venous gasometry: pH 6.97, pCO₂ 24 mmHg, HCO₃ 5.5 mmol/L, Lactates 4.4 mmol/L. Urinary sediment with ketone bodies and glucose. Abdominal ultrasound: possible focal steatosis. Admitted to the Intermediate Care Unit for CAD, in the context of empaglifozine intake, with the follow possible triggers - AF with RVR and dehydration. Fluidotherapy, insulin and sodium bicarbonate were initiated, with clinical and analytical improvement, and later transferred to Medicine Service on the 4th day of hospitalization. At the time of discharge, gasometry without acidemia (pH 7.52) and HgbA1C 8.3%. There were made teachings of insulin administration and dabigatran was initiated. Follow up: HgbA1C 7% without complaints. Metformin was initiated and discharged to follow up with the family doctor.

Discussion

CAD occurs more frequently in women, and is a potentially life-threatening disease. Given that iSGLT2 is a pharmacological class with clinical potential in the approach to type 2 DM and in the reduction of cardiovascular events, it is important not to forget the possibility of the occurrence of CAD as a rare adverse event, its non-hyperglycemic presentation, as well as the identification of possible triggering factors.

#1085 - Case Report

NEUROLOGICAL COMPLICATIONS OF DIABETES

Vera Seara, Juliana Chen Xu, Gonçalo R. Mesquita, Sónia Da Costa Fernandes, Lilian Maia, Teresa Pinto
CHPVVC, Vila Do Conde, Portugal

Introduction

Neuropathy is one of the most frequent and disabling complications of diabetes mellitus. Diabetic mononeuropathies can affect cranial, peripheral nerves or nerve roots.

Case description

A female aged 54 with a 10-year history of uncomplicated type 2 diabetes mellitus reported severe occipital headache of sudden onset and constant for 2 weeks. The squeezing pain was relieved after taking paracetamol. She also complained of blurred vision and polyuria, polydipsia and polyphagia. Her previously controlled glycemia had become uncontrolled for four months (HbA1c 7,9%). The neurologic assessment revealed horizontal rotary nystagmus on levoversion, horizontal diplopia on fatigue tests and right internuclear ophthalmoparesis, as well as right dysmetria in the finger-to-nose test and instability on the heel to toe and tandem gaits. The ophthalmic examination excluded diabetic retinopathy. The blood tests showed hyperglycemia (576 mg/dl) and glycosuria with no other abnormalities, namely normal immune and thyroid function test, negative HIV, HBV, HCV markers and VDRL. The cerebral CT scan, MRI and MR angiography were normal, as well as the thoracoabdominopelvic CT. Myasthenic syndromes were excluded with normal electromyography studies and negative anti-acetylcholine receptor and muscle-specific kinase antibodies. CSF excluded central nervous system infection and the oligoclonal bands were negative. Treatment with amitriptyline 10mg daily was started. Glycemic control was achieved by starting insulin. A progressive weaning was possible, and the patient was discharged on oral antidiabetic medication. On the one month follow up, there was total relieve of the headache and vision complains and optimal metabolic control. The exclusion of other causes led to the diagnosis of diabetes associated neuropathy.

Discussion

Diabetes causes a wide variety of acute, chronic, focal, and diffuse neuropathy syndromes that usually happen in older individuals with longer duration of diabetes and are related with bad metabolic control.

This case demonstrates that although uncommon, diabetic neuropathy should be considered in the presence of signs and symptoms of cranial nerve disturbance when other causes are excluded. It also shows that in acute presentations, a good glycemic control can reverse the nerve injury. Treatment of painful diabetic neuropathy includes tricyclic antidepressant drugs, such as Amitriptyline and has a therapeutic effect within 2-6 weeks.

#1086 - Case Report

ALLGROVE SYNDROME IN THE PRACTICE OF ENDOCRINOLOGIST

Natalya Volkova, Ilya Davidenko, Igor Reshetnikov, Snezhana Brovkina
Rostov State Medical University, Rostov-On-Don, Russia

Introduction

Allgrove syndrome (triple A syndrome) is a rare autosomal recessive multisystem disease characterized by adrenal insufficiency, alacrimia and achalasia. It is caused by a mutation in the AAAS gene (12q13) encoding the protein ALADIN. This syndrome is often associated with neurological dysfunction. Prevalence:<1/1000000. The first description was in 1978.

Case description

18 years old, appealed to the city endocrinological center with complaints of fatigue, weakness, darkening of the skin. Anamnesis of life: born from the first pregnancy without complications, weight 3200g. Parents often turned to the pediatrician with complaints: lethargy, frequent regurgitation, ARVI up to 6-7 times a year. Objectively he noted slow weight gain, dyspeptic syndrome (nausea, vomiting). At the age of 3, the boy entered the surgical department with acute abdomen, fever, vomiting. Achalasia was revealed, reconstructive surgery was carried out. In the diagnostic search for the causes of body weight loss he was directed to the endocrinologist. There were an increase in ACTH 470 pg/ml (0,0-46 pg/ml), cortisol 0.05 µg/DL. Diagnosis: primary chronic adrenal insufficiency; the dose of hydrocortisone 10 mg/day did not change with age. An in-depth anamnesis found: the patient never cried with tears.

Objectively: asthenic body type, BMI 16.5 kg/m², hyperpigmentation of the palms, armpits; weakness in the proximal muscles of the limbs. Laboratory studies: ACTH 95 PG/ml, cortisol 0.1 µg/DL (3.7-19.4 µg/DL), normal aldosterone-renin ratio. Optometrist: injected conjunctiva, sclera. Schirmer's test: mild alacrimia. It allowed to make the diagnosis: "Primary chronic adrenal insufficiency. Condition after surgery for achalasia (1997). Alacrimia. Allgrove Syndrome." The dose of hydrocortisone was increased to 17.5 mg/day.

In 2019, the patient complained of a sharp deterioration of health, darkening of the skin. The dose of hydrocortisone was increased to 25 mg/day (15 mg at 8.00, 10 mg in the afternoon). The optometrist noted an increase in the severity of alacrimia, artificial tear drops was recommended. The diagnosis was confirmed by pathogenic mutation c.43C>T of the AAAS gene.

Discussion

Despite the full clinical picture, the right diagnosis was made only after 14 years. We shown the difficulty of diagnosis is due to the lack of awareness of clinicians about the disease, the importance of interdisciplinary interaction, as well as the need for follow-up of such patients.

#1098 - Abstract

THE BODY MASS INDEX AS A MAIN TARGET FOR GLYCATED HEMOGLOBIN REDUCTION

Miguel Granado Seixal, Maria José Grade, Luísa Arez

Centro Hospitalar Universitário do Algarve - Unidade de Portimão, Portimão, Portugal

Background

Diabetes mellitus is considered the biggest pandemic disease of the 21st century, and glycated hemoglobin (HbA1c) is still the best method to measure metabolic control. In this study we intend to determine the predictors of HbA1c control in diabetic patients.

Methods

Retrospective study of a population of diabetic patients attending Diabetes consultation in a hospital unit during 2018. Data collected from a database, highlighting (i) sex, (ii) age, (iii) number of medical appointments, (iv) Body Mass Index (BMI), (v) years of Diabetes evolution, (vi) total cholesterol (TC), (vii) triglycerides (TG) and (viii) variation of HbA1c. Assessment of the relationship among the previously described factors in HbA1c variation through multivariate linear regression, using SPSS Software(v23), with statistical significance set for p-value <0.05.

Results

It was obtained data from 33 patients (mean age 64.1 years, 60.6% male). The model that better predicts HbA1c reduction considers (i) gender, (ii) age, (iii) BMI and (iv) TC (p =0.002, r²=0.613). The factors that most contribute for HbA1c reduction are BMI (p=0.006) and CT (p=0.007), and a reduction of BMI by 1 kg/m² is associated with a decrease in HbA1c by 0.3%.

Conclusion

The authors highlight the need to strengthen non-pharmacological therapeutic on metabolic control in Diabetes Mellitus, since weight loss only per se significantly reduces HbA1c. In addition to this effect, weight loss has synergistic effects in reducing other cardiovascular risk factors and, thus, in reducing cardiovascular morbimortality.

#1099 - Case Report

SECONDARY ADRENAL INSUFFICIENCY: AN OVERLOOKED EFFECT OF INHALED CORTICOSTEROIDS

Carla Pereira Fontes, Andreia M. Teixeira, José Moura Meireles

Centro Hospitalar de Entre o Douro e Vouga (CHEDV), Santa Maria Da Feira, Portugal

Introduction

Adrenal insufficiency (AI) is one of the most serious adverse effects of inhaled corticosteroids (IC). Despite the reduced risk, its occurrence is particularly associated with IC with higher lipophilicity, longer half-life or at high doses. The clinical

presentation spectrum varies widely, ranging from non-specific symptoms to acutely life-threatening adrenal crisis, requiring a high degree of suspicion for diagnosis.

Case description

A 74-year-old male with a history of controlled hypertension, dyslipidemia, and long course asthma under beclomethasone 1000 µg/day, presented with nausea and vomiting for 1 week, associated with acute alteration of consciousness and hypotension. A previous flu syndrome was mentioned. On examination, the patient was confused, afebrile, hypotensive and slightly tachycardic. The remainder exam was unremarkable. Laboratory investigations showed a serum sodium level of 116 mmol/L (135 to 145 mmol/L), with no other hydroelectrolytic disorders or associated renal injury. The urinary osmolality was reduced and serum osmolality was superior to 300 mOsm/L. The blood levels of total protein, glucose and thyroid function tests were all normal. In view of sustained hypotension and hypotonic hyponatremia, IRS hypothesis has been raised and intravenous hydrocortisone initiated with improvement of the hemodynamic profile, correction of natremia and restitution to patient's basal neurological state. Further investigations (without corticoid), pointed out a basal corticotrophin of 15,0 ng/L (7,2 to 63,3 ng/L), a low morning serum cortisol levels and an inadequate response to tetracosactide stimulation test, with a 60-minute peak cortisol of 297,5 nmol/L. Abdominal computed tomography revealed normal thickness of adrenal glands, with no nodules or calcifications, and brain magnetic resonance imaging was normal. Secondary AI due to suppressed hypothalamic-pituitary-adrenal axis by chronic IC administration has been enlightened in a context of infectious intercurrent. The patient was later discharged with daily prednisone in a weaning scheme; the IC was also changed to one of less systemic bioavailability

Discussion

IC, such as beclomethasone, are widely used in chronic lung diseases. Despite its favorable pharmacokinetic profile (less lipophilicity), if the clinical course is compatible, a differential diagnosis of secondary AI is required. The awareness to the potential risk for AI and its prompt diagnosis is imperative in clinical practice.

#1126 - Case Report

HYPOPITUITARISM: A FINDING IN THE HEART FAILURE APPROACH

Diana Isabel Dias, Ana Mafalda Silva

Entre Douro and Vouga Hospitalar Center, Santa Maria Da Feira, Portugal

Introduction

Hypopituitarism has an incidence of 4 per 100 000 populations and may be caused by hypothalamic or pituitary dysfunction with an insufficient pituitary hormones secretion and consequent endocrine peripheral glands dysfunction. Hypothyroidism

contributes to heart failure decompensation and thyroid function should be assessed in heart failure (HF) patient's approach. Central hypothyroidism detection must imply the assessment of the remaining hypophyseal function.

Case description

We report a 72-year-old female patient's with breast cancer many years ago and dyslipidemia. The only chronic medication was a statin. She complained of 1 week small exertion dyspnea, orthopnea, productive cough and 2-days vomiting. Additionally she had asthenia since a few weeks and cold intolerance. At admission she had fever (38°C), mild polypnea (26 cpm) and heart rate 55 bpm, crackles in both lung bases, peri-orbital edema and low extremities simmetrical non-pitting edema. From the initial study she had type 1 respiratory insufficiency, elevation of BNP and inflammatory parameters. It was assumed low respiratory infection and began empirical antibiotherapy, diagnosis and therapeutic approach to acute heart failure. From the complementary study was found low TSH (0.01 uUI/mL) and low free T4 (7.6 pmol/L) values, suggesting an central hypothyroidism. The thyroid ultrasonography had no alterations. Looking for a central cause for hypothyroidism, the remaining pituitary endocrine axes study was performed verifying low morning cortisol (30 nmol/L), low morning ACTH (6.49 pg/mL), LH (0.04 mUI/mL) and FSH (0.25 mUI/mL). Hypophyseal MRI was performed, revealing a Turkish saddle enlargement occupied with heterogenic material with an arachnocello suggestive aspect without compromise of the stem. Thus, the patient was hydrocortisone and levothyroxine supplemented and oriented to neurosurgical specialty for decision about invasive approach of the lesion.

Discussion

We highlight the thyroid function assessment importance in decompensated heart failure patients since thyroid dysfunction often competes for the difficulty of obtaining clinical stability in those patients and may be an etiology contributing in acute HF or still be a distinct edema and vomiting cause. In this case, we must also highlight how the early diagnosis of the pituitary dysfunction may have avoided importante systemic consequences.

#1141 - Case Report

MYXEDEMA COMA, A LATE POSTOPERATIVE COMPLICATION - THE ODDS OF RARITY

Marta Soares Carreira¹, Ana Cunha¹, Marta Couto¹, Paulo Ramalho²

¹ Centro Hospitalar Universitário do Porto, Porto, Portugal

² Hospital CUF, Porto, Portugal

Introduction

Acromegaly is a rare disease that results from hypersecretion of growth hormone, which in turn stimulates hepatic secretion of insulin-like growth-factor 1 (IGF-1), responsible for most of the clinical manifestations of acromegaly.

Clinical features are usually typical, and include macrognathia, enlargement of hands, feet, and face bones. The most common cause for acromegaly is a pituitary tumour. Transsphenoidal surgery (tumour resection) is the first line treatment, however, deficiency of one or more pituitary hormones may become apparent after surgery.

Case description

An 85-year-old male patient, with type 2 diabetes mellitus, a prior history of acromegaly treated with transsphenoidal surgery 20 years ago and and panhypopituitarism presented to the emergency department with coma (Glasgow Coma Scale = 9) and hypothermia. He was taking metformin 1g bid, bromocriptine 5mg id, hydrocortisone 15mg id, levothyroxine 50mcgid and octreotide 5mg/month. On presentation, his vital signs included a temperature of 35.1°C, blood pressure of 116/105 mmHg and heart rate of 25-30 bpm, which failed to respond to atropine or isoprenaline infusion. A temporary pacemaker was placed. Laboratory data revealed a low serum free thyroxine (T4) concentration (0,70ng/dL). The patient was diagnosed with myxedema coma and was started on intravenous hydrocortisone and levothyroxine. Over the next 24 hours, his neurological status and laboratory data improved (Glasgow Coma Scale= 12, T4 = 1,19ng/dL). However, the patient developed aspiration pneumonia with respiratory failure and died 4 days after admission.

Discussion

For the majority of patients with acromegaly, transsphenoidal surgery is recommended as the initial therapy with a very low rate of postoperative complications such as diabetes insipidus or pan hypopituitarism. Although rare, myxedema coma can occur as the culmination of severe longstanding hypothyroidism or be precipitated by an acute event in a poorly controlled patient. Careful assessment of risk and rapid action are essential for limiting morbidity and mortality. Older patients with cardiac complications, reduced consciousness or sepsis have a worse prognosis.

#1152 - Case Report

CONVULSIVE CRISIS IN PATIENT WITH DEPRESSIVE SYNDROME REACTIVE TO ONCOLOGICAL PATHOLOGY

Maria Manuel Costa, Joana Rodrigues

Hospital de São Sebastião, Oliveira De Azemeis, Portugal

Introduction

Vitamin D deficiency is currently very rare in developed countries, but its prevalence has been increasing globally due to a number of factors including the use of sunscreen, increased body mass index, decreased consumption of dairy products and population-ageing. This deficit can cause changes in the metabolism of calcium and phosphorus, with hypocalcemia, hypophosphatemia and an increase in the parathyroid hormone. It as many consequences,

among which osteoporosis with an increased risk of fractures is the most prevalent. Convulsive seizures associated with severe hypocalcemia may be an isolated presentation of the deficit, but this is a very rare occurrence. The treatment includes supplementation, as well as correction of eating habits and daily sun exposure.

Case description

We report the case of a 71-year-old woman with personal history of endometrial malignant tumor without evidence of metastasis, already submitted to surgical procedure and proposed for chemotherapy and radiotherapy, depressive syndrome related to the tumor, second degree obesity, and hypertension.

The patient enters the emergency room because of vomiting with 4 days of evolution, symptom not related to feeding or recent introduction of new drugs. She presented anorexia, since the diagnosis of the tumor associated to adynamism and diminution of the solar exposition.

During her stay in the emergency room she had a convulsive crisis, with about 1 min of duration and a spontaneous recovery. The study carried out showed hypocalcemia and severe hypophosphatemia with normal magnesium. During hospitalization severe vitamin D deficiency with elevated parathyroid hormone was noted. After supplementation with calcium, phosphorus and vitamin D, a normalization of the ionic deficits was observed. During the entire hospitalization period she had no further seizures. After a joint evaluation with the assistant oncologist, it was considered that the deficits had no relation to the oncological pathology of the patient, assuming changes in a probable context of nutritional deficit and reduction of sun exposure.

Discussion

With this case, the authors intend to present a rare cause of seizure in a patient with important cancerous disease and difficulty in dealing emotionally with it. This case is also intended to stress the importance of evaluating the patient as a whole, and physicians should never neglect the psychological component associated with the pathologies, namely, the oncological ones.

#1156 - Case Report

HEMYCHOREA-HEMIBALLIST ASSOCIATED WITH HYPERGLYCAEMIA

Maria Maia, Ana Gonçalves, Adriana Watts Soares, João Espírito Santo, Ismênia Oliveira, Rita Simões, José Lomelino Araújo

Hospital Beatriz Ângelo, Lisboa, Portugal

Introduction

Hyperosmolar hyperglycaemic non-ketotic (HHNK) syndrome is a clinical syndrome characterized by severe hyperglycaemia, hyperosmolarity without ketoacidosis. Fewer cases of the association of hyperglycaemia with chorea/ballism have been published, being the prevalence of this disorder less than 1/100,000. Major risk factors are female gender and older age.

Authors present two cases of hemychorea-hemiballist associated with hyperglycaemia (HHAH).

Case description

Case 1

91-year-old female, caucasian, history of type 2 diabetes (T2D) no insulin needed, auricular fibrillation under apixaban, that presented to the emergency department (ED) with a four-day history of involuntary movements of the left arm. Clinical exam: hemodynamic stability (HDS), neurological exam (NE) with GCS of 15, choreic movements of the left arm and some of the left leg, more proximal, giving pain and discomfort. Investigation: serum glucose (G) 460mg/dL (HbA1c 14%), ketone test negative, no acidosis.

CT-scan revealed no ischemic or haemorrhagic lesion, but a lenticular and right capsular hyperdensity, confirmed by the MRI with a change on the signal of the lenticular right nucleus, (hypersignal in T1 and hyposignal in T2 and FLAIR) characteristic of HHAH.

After hydration and insulin, risperidon 0,5mg was started. Progressively improvement of the symptoms, until they stop before discharge.

Case 2

60-year-old male, caucasian, history of arterial hypertension, dyslipidaemia, T2D insulin needed, presented to the ED due to involuntary movements of all the right part of the body with a month of progression. Clinical exam: HDS, NE with ballistic and choreiform movements of the right arm and leg. Investigation: G 350mg/dL (HbA1c 12.3%), ketone test negative, no acidosis. CT-SCAN with an hyperdensity on the left globus pallidus. No MRI was performed. Hydration and insulin were started and valproate, lorazepam and haloperidol. Little improvement of the symptoms was seen.

Discussion

HHAH is a rare syndrome characterized by lesions in the basal ganglia, contralateral to the affected side, secondary to hyperglycemia, physiopathologic process not yet clear. With the control of the glycemia the symptoms tend to get better as it could be seen in the first case. The second case, due to time of evolution and difficult control of glycemia, was more difficult to solve.

These two cases show us one more complication of the diabetes that can be confused with a stroke or other neurological entities, being essential the metabolic control.

#1168 - Case Report

HYPOTHYROIDISM AND ASSOCIATED ACUTE KIDNEY INJURY

Jovina Summer Goh, Chaozer Er, Clarissa Hui Wen Aw, Nicholas Cheong

Woodlands Health Campus, Singapore, Singapore

Introduction

Effects of the thyroid hormone throughout the body are pervasive. Hypothyroidism is commonly known to be associated

with multiple physiological manifestations such as lethargy, weakness, cold intolerance and poor appetite. Lesser known are its effects on kidney physiology and a resultant reduction in glomerular filtration. We present an uncommon case of severe hypothyroidism resulting in acute kidney injury.

Case description

A 54-year-old Chinese gentleman presented to the emergency department with generalised anasarca and weight gain of 4kg over the past 1 month. The patient had a significant past medical history of Graves' hyperthyroidism and underwent radioiodine ablation therapy 6 months prior to admission. He however defaulted subsequent appointments with the endocrinologist. Further history taking revealed that the patient had continued to take carbimazole post radioiodine ablation. Thyroid function tests revealed a TSH (Thyroid stimulating hormone) of 75.2 mIU/L (0.27 - 4.2 mIU/L) and a free thyroxine of 1pmol/L (12-22pmol/L). He was also noted to have mild acute kidney injury (AKI) - his creatinine was 121umol/L (67-112 umol/L), elevated from a previous baseline of 52-76 umol/L. Intravenous hydration over the next three days did not result in any significant improvement of his AKI - serum creatinine remained elevated at 129 umol/L.

Further investigation did not reveal any significant contributing cause of the AKI- the patient did not have any exposure to nephrotoxins; Urinalysis revealed a normal urine protein/creatinine ratio of 0.07 (normal range:< 0.2) and a normal urine albumin/creatinine ratio of < 30ug/mg; Urine microscopy examination was clear of any white, red or cast cells and ultrasonography of the kidneys and ureters were normal.

After being started on thyroxine 75 micrograms daily, his symptoms improved markedly and a repeat thyroid panel three weeks later showed significant improvement: TSH 22.6 mIU/L and free thyroxine 12.2pmol/L. A repeat serum creatinine showed a return to baseline - 85 umol/L.

Discussion

The exact mechanism of how hypothyroidism causes reduction in glomerular filtration has yet to be clearly understood but has been attributed partly to the effect of the thyroid hormone on sodium homeostasis, cardiac output and vascular resistance. The findings in this case study are best explained by the association of hypothyroidism and acute kidney injury. We thus hope to highlight hypothyroidism as a cause to be considered in cases with unexplained AKI.

#1171 - Abstract

UNFOLDING THE LINK BETWEEN DIABETES AND CANCER: A RETROSPECTIVE STUDY

Jorge Vaz Lourenço, João Pina Cabral, Joana Coelho

Centro Hospitalar Universitário de Coimbra, Coimbra, Portugal

Background

The link between cancer and diabetes mellitus (DM) is an emerging

and rapidly growing field of study. Accumulating molecular and clinical evidence supports this link and implicates cellular-based mechanisms at the interface of the two diseases. Hyperglycaemia and hyperinsulinaemia are both potential carcinogenic factors, by inducing DNA damage through increased oxidative stress and stimulation of insulin receptor and insulin-like growth factor-1, respectively.

Methods

We collected our data from electronic medical records of enlisting patients that were seen by an Oncologist for the first time during the first semester of 2017 and selected those with DM criteria (HbA1c >6.5% or fasting blood glucose level >126mg/dl). Then, we performed a retrospective study regarding age, gender, type of cancer diagnosed and their profile of DM (disease duration, HbA1c and vascular complications).

Results

We examined 1037 medical records and found a total of 127 patients with type 2 diabetes, 57,5% males (n=73) and 42,5% females (n=54) with a mean age of 67,9 years. The mean duration of DM was 3,9 years and mean HbA1c was 7,05%. There were 13 patients with vascular complications, namely retinopathy (n=8), nephropathy (n=12), neuropathy (n=2), myocardial infarction (n=9) and stroke (n=4). According to the organ systems affected by primary tumors, we found that 29,1% of patients had a GI tract tumor - esophagus (n=5), stomach (n=9), colon (n=20) and liver (n=3); 20,5% had gynecologic tumors - breast (n=20), uterus (n=4), ovary (n=2); 18,9% had hematologic tumors - lymphoma (n=14), myeloma (n=10); 14,2% had urinary tract tumors - bladder (n=8), kidney (n=4), prostate (n=6); finally, 3,9% (n=5) were diagnosed with malignant melanoma.

Conclusion

The GI tract tumors and gynecologic tumors were the most prevalent in diabetic patients and the majority had no vascular complications at the time of tumor diagnosis. Whether DM confers the same excess risk of cancer, overall and by site, in women and men is still unknown. Further studies are needed to clarify the mechanisms underlying the sex differences in the diabetes-cancer mutual influence.

#1221 - Abstract

ANALYSIS OF PATIENTS HOSPITALIZED FOR HYPOGLYCEMIA AT TWO TERTIARY CARE HOSPITALS

Marina Fayos¹, Tania Ramos², David García¹, Luis Gibert¹, Nuria Puente¹, Pablo González¹, Gonzalo Martínez De Las Cuevas¹

¹ Hospital Universitario Marqués de Valdecilla, Santander, Spain

² Complejo Asistencial Universitario de León, León, Spain

Background

Hypoglycemia is one of the main reasons for admission due to

acute complications of diabetes. The aim of this study is to analyze and compare patients hospitalized due to hypoglycemia at two tertiary care hospitals in Spain.

Methods

This is a descriptive retrospective study of patients admitted for hypoglycemia at Marqués de Valdecilla University Hospital of Santander (HUMV) and at Complejo Asistencial Universitario of León (CAULE), between January 2013 and December 2015. Clinical characteristics, hypoglycemic treatment, and readmissions in the first three months were analyzed.

Results

We analyzed 116 patients: 48 in León and 68 in Santander. At CAULE, 59% were women, with a mean age of 71 (SD 19) and an average stay of 7 days (SD 5). At HUMV 54% were men, with a mean age of 77 (SD 12) and an average stay of 14 days (SD 12). At CAULE, 92% were admitted to Internal Medicine Service, compared to 94% at HUMV. At CAULE, 63% of patients were TP2DM, while at HUMV they were 93%.

At CAULE, the average Charlson score was 4.8 (SD2.4), and the mean HbA1c 7.7% (SD 1.4). At HUMV, the average Charlson score was 6.7 (SD 3.2) and the mean HbA1c was 7.5% (SD 1.5).

Regarding treatment, at CAULE 50% of patients were on insulin, mainly mixtures; while 65% were on insulin at HUMV, mainly mixtures and glargine. At CAULE, 25% took OAD, mostly sulfonylureas. 25% used insulin combination with OAD. At HUMV, 22% used OAD, mainly biguanides, and 13% used a combined treatment.

After discharge, at CAULE the hypoglycemic drug was modified to 50%, to 16% the dose was reduced, to 16% the medication was withdrawn and there was no change in 18%. At HUMV, the drug was changed to 35%, it was reduced to 38%, to 6% was removed, and there was no changes in 22%.

At CAULE, 31% of patients were readmitted after 3 months, 3% due to hypoglycemia. At HUMV, 34% were readmitted, 26% due to hypoglycemia.

Conclusion

- Patient's profile admitted to CAULE was a younger woman, with less comorbidity and fewer days of stay, while HUMV's profile was an older man, with higher comorbidity and longer income.
- At CAULE, ADOs were more used than at HUMV, both in monotherapy and combined.
- At CAULE, the tendency was to modify the hypoglycemic treatment, since it was more frequent the use of mixtures and sulfonylureas.
- At HUMV, the dose tended to be decreased, as most of patients were on glargine.
- There were more readmissions for hypoglycemia at HUMV than at CAULE, being that the profile was a more fragile and older patient.

#1224 - Abstract

EVALUATION OF PATIENTS ADMITTED FOR HYPOGLYCEMIA AT A TERTIARY CARE HOSPITAL

Marina Fayos, Nuria Puente, Pablo González, Luis Gibert, David García, Gonzalo Martínez De Las Cuevas

Hospital Universitario Marqués de Valdecilla, Santander, Spain

Background

Hypoglycemia is one of the main reasons for hospitalization due to acute complications of diabetes. The aim of our study is to analyze the causes of admission due to hypoglycemia and the clinical characteristics of the patient.

Methods

This was a descriptive retrospective study of hospitalized patients with hypoglycemia, at Marqués de Valdecilla University Hospital between January 2013 and December 2017. We analyzed: the cause of admission, clinical characteristics, functional status (Profound Index and functionality scale of the red cross), treatment at discharge and evolution.

Results

Among 116 patients analyzed, 54% were women, mean age 78 (SD 12). The median length of hospitalization was 13 days (SD 12). 96% were admitted to Internal Medicine Service and the rest to Endocrine, Oncology and Hematology Services. 93% of patients were T2DM and 7% T1DM.

Comorbidity was high, with an average Charlson score of 7 (SD 3), Profound score of 7 (SD 5) and an average Red Cross disability score of 2 (SD 1). The average HbA1c was 7.6% (SD 1.7).

Most frequently recorded underlying diseases were: renal insufficiency (47%), heart failure (42%), and peripheral artery disease (28%). The main reasons for admission were: hypoglycaemia (44%), respiratory infection (18%), heart failure (12%) and diarrhea (6%).

79% of patients were on insulin as a diabetes treatment regime, mainly glargine (26%) and mixtures (24%). 41% used OAD, mostly biguanides (19%) and inhibitors of DPP4 (15%). 23% used a combination of insulin with OAD. At discharge, the treatment dose was reduced to 37%, the hypoglycemic drug was changed to 29%, the medication was completely withdrawn to 10%, and there was no change in the rest of the patients.

The overall in-hospital mortality was 24%, and 37% were readmitted in the next 3 months, after an average of 29 days (SD 21). 14% of readmissions were due to hypoglycemia.

Conclusion

- T2DM is the main cause of diabetes in patients admitted for hypoglycemia in our hospital.
- The profile of the patient admitted for hypoglycemia was a woman around 78, with high comorbidity and functional disability.
- The main treatments associated with hypoglycemia were

glargine and mixtures.

- At discharge, the treatment tended to be decreased instead of being modified.
- There was a high rate of readmissions and mortality in patients hospitalized for hypoglycemia, due to the fragility and high comorbidity of these patients.

#1250 - Abstract

CORRELATIONS OF GLYCEMIC CONTROL, PHYSICAL FUNCTION, MOOD AND PERSONALITY TRAIT IN TYPE 2 DIABETIC WOMEN

Raziye Nesrin Demirtas¹, Nur Kebapci², Belgin Efe²

¹ Eskisehir Osmangazi University Medical School, Department of Physical Medicine and Rehabilitation, Eskisehir, Turkey

² Eskisehir Osmangazi University Medical School, Department of Endocrinology, Eskisehir, Turkey

Background

The aim of the study was to investigate the correlations of glycemic control, physical function, mood and personality trait in type 2 diabetic women (T2DW).

Methods

The demographic and medical data of 25 T2DW were recorded. They completed the self reported physical function (PF) and mental health (MH) components of the Short Form-36 Health Survey (SF-36), Beck Depression Inventory (BDI) and Hacettepe Personality Inventory (HPI) which included Personal Cohesion (PC), Social Cohesion (SC), General Cohesion (GC) subscales. The glycated hemoglobin (HbA1c) as an index of glycemic control was measured.

Results

In T2DW whose HbA1c level >7% indicating poorer control of blood glucose levels: PF score of SF-36 was less ($p=.018$) than those whose HbA1c level <7%, but there weren't differences for MH of SF-36, BDI scores and personality trait ($p>0.05$). In T2DW whose BDI scores >17: MH ($p=.000$), PF ($p=.042$) scores of SF-36 and PC, SC, GC scores ($p=.000$) of HPI were less than those whose BDI scores <17. There weren't associations between BDI score, age, body mass index and diabetes duration ($p>.05$).

Conclusion

The results of this study suggested that glycemic control was correlated to PF and mood were especially affected with personality trait and PF in T2DW.

#1258 - Case Report

PRIMARY LOCALIZED AMYLOIDOSIS OF THE RENAL PELVIS AND URETER PRESENTING AS ACUTE PYELONEPHRITIS AND MIMICKING UROTHELIAL CARCINOMA

Rita J. Rodrigues, Paula Gonçalves Costa, Marta Costa Gonçalves, Ricardo Macau, Alcina Ponte

Hospital of Santo André - Hospital Center of Leiria, Leiria, Portugal

Introduction

Amyloidosis encompasses several conditions characterized by amyloid deposition in different tissues and organs and it can either be systemic or localized. Localized amyloidosis of the urinary tract is uncommon and the involvement of the renal pelvis and ureter is rare.

Case description

A 56-year-old man with an history of symptomatic nephrolithiasis was referred to the Emergency Department due to severe left back pain and haematuria for the last 3 days. On physical examination, he was febrile and had left costovertebral angle tenderness. Laboratory examination showed an increase in inflammatory markers – leucocytosis ($21 \times 10^9/L$), neutrophilia and C-reactive protein of 144 mg/dL. Ultrasonographic examination revealed foci of calyceal lithiasis and left renal pelvis dilation with an echogenic content without evident cone shadow. He was then submitted to an urographic tomography that described: a diffuse and irregular parietal thickening of the left renal calyces and pelvis which continued along the ureter; numerous irregular and thick calcifications; and a discrete dilation of the ureter. The patient was admitted to the Urology Department considering the possibility of urothelial carcinoma, where he was treated with antibiotic therapy for acute pyelonephritis with clinical and analytical improvement and underwent diagnostic ureterorenoscopy that revealed a bulky mass with multiple surface calcifications that occupied the lumen of the left renal pelvis. The renal pelvis lavage cytology excluded the presence of neoplastic cells. The anatomopathological study of the mass's biopsies revealed apple-green birefringence of Congo red stained amyloid deposits. The patient was then referred to Internal Medicine consultation where systemic amyloidosis was excluded after several exams done without any signs of other organs' involvement, concluding that he had primary localized amyloidosis. He currently maintains surveillance in Nephrology consultation, with normal renal function and without proteinuria.

Discussion

Although the cause of localized amyloidosis of the urinary tract is unknown, local monoclonal plasma cell infiltrates and local amyloid synthesis have been suggested as causes. It may present as renal calculi as focal lesions calcify; in the ureter, it may mimic a malignant tumour in its clinical presentation and imaging aspect, sometimes leading to nephroureterectomy. Therefore, it should be considered and confirmed by biopsy and histological examination thus avoiding unnecessary surgery.

#1288 - Abstract

THE FATIGUE AND ITS RELATIONS WITH GLUCOSE CONTROL, PHYSICAL ACTIVITY AND QUALITY OF LIFE IN TYPE 2 DIABETIC WOMENRaziye Nesrin Demirtas¹, Nur Kebapci², Belgin Efe²¹ Eskisehir Osmangazi University Medical School, Department of Physical Medicine and Rehabilitation, Eskisehir, Turkey² Eskisehir Osmangazi University Medical School, Department of Endocrinology, Eskisehir, Turkey**Background**

The fatigue is a common symptom of diabetes mellitus. The aim of this study was investigated the fatigue and its relations with glucose control, physical activity and quality of life in women with Type 2 Diabetes Mellitus (T2DM).

Methods

A total of 55 consequent women with T2DM aged 42 to 78 years (mean age 60.43±8.62) were eligible to participate in this cross-sectional study. Their clinical and laboratory data were recorded. The glucose control was established by HgA1c level. The fatigue was assessed with energy/fatigue (E/F) component of the Short Form-36 Health Survey (SF-36). The Nottingham Health Profile (NHP) for quality of life and 2-minute walking test (2MWT) and timed Up and Go Test (TUG) for physical activity were applied.

Results

The E/F score of SF-36 were negatively correlated to diabetes duration ($p < 0.01$), HgA1c ($p < 0.05$), comorbidity number ($p < 0.05$), TUG ($p < 0.01$) scores, all components of NHP ($p < 0.001$ - $p < 0.000$) and positively correlated with 2MWT ($p < 0.000$).

Conclusion

The findings suggested that fatigue were related to glucose control, physical activity and quality of life in women with T2DM. The effective interventions such as providing glucose control and improving physical activity and quality of life can help to reduce the fatigue in women with T2DM.

#1343 - Case Report

THE FAULT IS NOT OF THE HEART

Ana Figueiredo Albuquerque, Flávia Santos, Maria João Palavras, Juliana Silva, Helena Carrondo, Célio Fernandes

Centro Hospitalar de Leiria, Leiria, Portugal

Introduction

Hypothyroidism is a common endocrine disorder resulting from deficiency of thyroid hormone. Normally, thyroid hormones prevent overexpression of glycosaminoglycans, so, the lack of the thyroid hormone could cause accumulation of matrix glycosaminoglycan's in the interstitial spaces of many tissues provoking myxedema.

Case description

We present a case of an 85-years-old male with past medical history of heart failure, chronic obstructive pulmonary disease, diabetes mellitus, hypertension and obesity. He was medicated with metformin, lorazepam, olmesartan, allopurinol, furosemide and amiodarone.

The patient presented in the Emergency Room with dyspnea, productive cough and easy fatigability. The clinical examination revealed apathy, pulmonary rales on auscultation, and an edema the periorbital region and lower limbs.

The blood analysis showed an elevation of the inflammatory parameters, macrocytic anemia (Hb 8.7 g/dL; VCM 108.0 fL; HCM 38.7 pg), an elevation of both creatinine (3.26 mg/dL) and creatine kinase 612 U/L as well as a discrete hyponatremia (131 mmol/L). In the blood gas analysis presented with partial respiratory failure. The chest X-Ray revealed bilateral pleural effusion. He was admitted to regular ward of Internal Medicine with the diagnosis of respiratory infection and acute heart failure.

The echocardiogram revealed a normal systolic function, with a ventricular ejection fraction of 72%. The thyroid study revealed marked elevation of thyroid-stimulating hormone (TSH) concentration 89.1 yUI/mL and decrease of T4 concentration 2.5 pmol/L. The thyroid echography was normal.

Amiodarone was discontinued and it was started replacement therapy with thyroid hormone, with clinical improvement.

Discussion

The symptoms of hypothyroidism, that may range from mild to severe, include cold intolerance, decreased sweating, weight gain, fatigue, obstructive sleep apnea, congestive heart failure symptoms and decreased mental function. By this means, differential diagnosis and clinical management of hypothyroidism can be challenging. Amiodarone is associated with thyroid dysfunction (both hypo- and hyperthyroidism), which is due to its high iodine content and its direct toxic effect on the thyroid.

The authors intend to demonstrate the importance of the physicians to considerate this disease as a hypothesis when observing patients with a nonspecific or atypical course.

#1358 - Medical Image

BEHIND THE SCARF

Álvaro Alejandro De Oña, Victor Mato Jimeno, Cristina Ausín García, Noemí Brox Torrecilla, Carmen Cuenca Carvajal, María Victoria Villalba García

Hospital General Universitario Gregorio Marañón, Madrid, Spain

Clinical summary

We present the case of a 62 years old female who reported asthenia and a goiter, presented at least since 2003 (Figure 1). We performed laboratory analysis which showed severe macrocytic regenerative anemia (Hb of 5,3 g/dL), bilirrubina of 3,2 mg/dL, GGT of 89 U/L, LDH of 1119 U/L and suppressed TSH. Chest radiography demonstrated multiple masses in both lungs. We performed a CT

showing hepatic metastasis, and a ultrasonography followed by a fine-needle aspiration (FNA) which was compatible with papillary thyroid cancer. We performed a hepatic FNA which confirmed metastasis.

Due to clinical worsening of patient and after tumor board meeting, palliative management was decided.

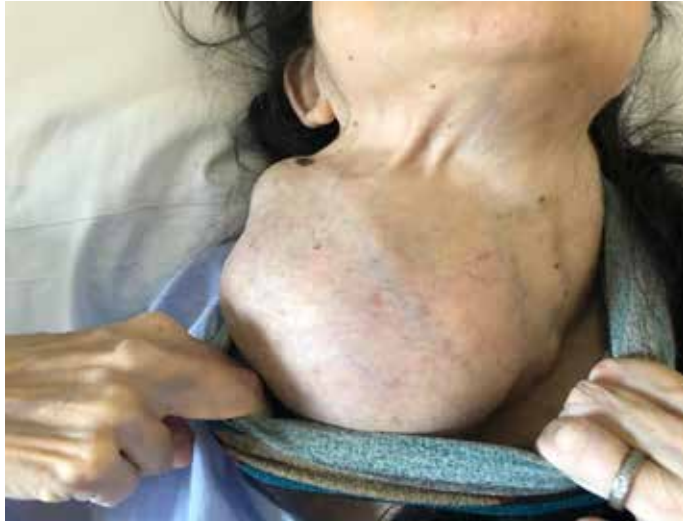

Figure #1358.

#1360 - Medical Image

AN UNNOTICED MANIFESTATION OF PITUITARY ADENOMA

Mónica Silva, Miguel Barbosa, João Gramaça, Fernanda Martins, Filomena Carneiro, Fátima Campante
Centro Hospitalar Barreiro Montijo, Barreiro, Portugal

Clinical summary

A 84 year-old-woman presented with nausea, vomiting and acute diarrhoea evolving for two weeks. Initial evaluation showed unspecific discomfort at abdominal palpation. Laboratory studies showed a normal level of myoglobin, hepatic enzymes, cholestasis markers, TSH and FT4. However, levels of morning cortisol and ACTH were both low (1.1 ug/dL and <5.0 pg/mL respectively) and increased serum levels of prolactin (57.34 ng/mL). Brain MRI revealed an expansive inner and suprasellar lesion compressing the hypothalamus and the optic chiasm. No signs of visual loss were found. A diagnosis of pituitary macroadenoma with secondary adrenal insufficiency was made, and the patient underwent hydrocortisone treatment, normalizing cortisol and ACTH levels, and reverting the gastrointestinal symptoms.

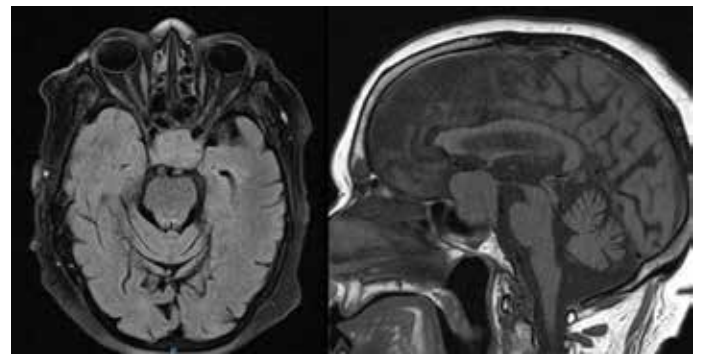


Figure #1360. Pituitary macroadenoma.

#1362 - Case Report

HYPERPROCALCINEMIA AND SEVERE KETOACIDOSIS IN A CHILD WITH TYPE 1 DIABETES MELLITUS IN TREATMENT WITH INSULIN PUMP

Ignacio Iniesta-Pino Alcázar, Elena Del Carmen Martínez Cánovas, Lia Ferraro, Maria Del Carmen Hernández Murciano, Carlos Báguena Pérez-Crespo, Gabriel Puche Palao, Vicente David De La Rosa Valero, Ana Martín Cascón, Francisco Javier Hernández Felices, Mónica Martínez Martínez, Isabel Pellicer Espinosa, María Del Carmen Gutiérrez Sánchez
Hospital General Universitario Reina Sofía, Murcia, Spain

Introduction

Procalcitonin (PCT) is a helpful marker of systemic inflammatory response to an infection. It is strongly indicative for sepsis of bacterial aetiology. Mild PCT elevations are also detected in many other diseases.

Case description

14-year-old child diagnosed with mellitus diabetes type I, carrier of insulin bomb, Hashimoto's chronic thyroiditis in the hypothyroid phase, with family history of diabetes and thyroiditis. Chronic treatment with levothyroxine 25 and insulin pump.

He presents a poor metabolic control (glycosylated hemoglobin: 8.4%), although his diabetological training is good (autonomous management of the insulin pump, self-performing catheter replacements, dietary knowledge and control of carbohydrate intake by the rations method).

The patient has nausea, vomiting and malaise. He only refers insulin pump catheter replacement the previous day.

The physical examination (cardiac and pulmonary auscultation, abdomen and extremities) and the vital signs were anodyne (apyretic, blood pressure of 90/40 mm Hg, 95 beats/minute, 16 breaths/minute, oxygen saturation of 99%). Only the oropharyngeal exploration shows tongue with erosion zones and discrete hyperemia and he does not present adenopathies.

In the blood analysis, the following was detected: glucose 581 mg/dl, urea 62 mg/dl, creatinine 1.66 mg/dl, sodium 133 mmol/L, potassium 5.1 mmol/L, procalcitonin 20.41 ng/mL, leukocytes 39,000 ul (neutrophils 84%), platelets 394,000. In the venous

gasometry it was observed: pH 7.11, pO₂ 30 mmHg, pCO₂ 42 mmHg, HCO₃ 12.8 mmol/l, excess of bases -16 mmol/L and lactic acid of 7.6 mmol/L. The rest was normal (Hemoglobin, coagulation and chest X-ray). In urine glucose and positive ketone bodies.

Diabetic ketoacidosis (DKA) management was administered. The patient evolved favorably and remained asymptomatic. Although the blood analysis suggested an infection as trigger, he didn't have an infectious focus or other suggestive data.

Discussion

PCT is a helpful marker indicative for sepsis of bacterial etiology. Mild PCT elevations are also detected in other diseases such as viral infections, myocardial infarction, burns and multiple trauma. Although DKA is not described as a major cause of procalcitonin elevation or false positive test, there are scientific papers that describe this association. During severe DKA there is a secretion of proinflammatory cytokines capable of releasing PCT independently of endotoxine.

#1380 - Case Report

A RARE MALIGNANT CAUSE OF HYPOGLYCAEMIA

Daniela Meireles¹, Diana Carvalho¹, Paulo Almeida¹, Joel Pinto¹, Maria João Amaral², Ana Rafaela Araújo¹

¹ CHBV - Aveiro, Aveiro, Portugal

² CHUC - Coimbra, Coimbra, Portugal

Introduction

Neuroendocrine neoplasms of the pancreas are uncommon and represent 1–2% of all clinically apparent pancreatic neoplasms. Neuroendocrine carcinomas (NECs), or high-grade, poorly-differentiated NETs, are the most aggressive subtype. Tumors arising from neuroendocrine cells are rare and can cause typical symptoms of carcinoid syndrome. Only those patients in whom Whipple's triade is documented require evaluation of hypoglycemia.

Case description

An 80-year-old woman was admitted in the Emergency Department (ED) with a two-months history of morning episodes of temporo-spatial disorientation, aggressive behaviour, asthenia, polyphagia and nocturnal diaphoresis. These symptoms occurred mainly in the fasting state relieved with food ingestion. The patient had a history of atrial fibrillation, toxic multinodular goiter, hypertension and dyslipidemia. In ED, the blood glucose level was 38 mg/dl, with a normal brain computed tomography (CT). Hypertonic glucose (30%) was administered and a 5% glucose infusion was maintained thereafter. The patient was hospitalized for etiological study. Glucose infusion withdrawal resulted in an episode of symptomatic hypoglycaemia (37 mg/dL), with elevated levels of insulin (26.9 mUI/L) and normal levels of C-peptide (6.08 ng/mL). Chromogranin A was 225 ng/mL. FSH, LH estradiol, cortisol, prolactin and ACTH were within normal values.

Thoracoabdominopelvic CT revealed an enlarged body and tail of the pancreas with oval formation of 80 mm with heterogeneous enhancement extended to the splenic cord with involvement of the respective hilar vessels and to the splenic parenchyma, without any other distant metastasis. A ⁶⁸Ga-DOTA-NOC positron-emission tomography CT was highly suggestive of neuroendocrine tumor of the pancreas. A left pancreatectomy, splenectomy and atypical block resection of the gastric fundus was performed. The anatomopathological results was compatible with three large cell neuroendocrine carcinomas of the pancreas (NEC). There was complete remission of the hypoglycemic episodes.

Discussion

What, in the beginning, seemed like an insulinoma, turned out to be a functional insulin producing high-grade NEC of the pancreas, presenting with symptoms of hypoglycemia. For NEC, the overall 5-year survival of the patients is 17%. Our patient did not have any further episodes of hypoglycaemia after surgery. The rarity of this case is even greater because nearly all grade 3 NET are nonsecretory.

#1394 - Case Report

TACHYCARDIA - CONSIDER ME

Virginia Visconti, Andre Fernandes, Adriana Watts, Ismenia Oliveira, Fernando Goncalves, Jose Lomelino Araujo, Maria Maia Hospital Beatriz Angelo, Loures, Portugal

Introduction

Atrial fibrillation is the most frequent chronic arrhythmia, affecting 1-2% of the population. Often, due to its paroxysmal potential, it may be underdiagnosed and undertreated.

Case description

The authors present the case of a 50-year-old patient with a history of essential hypertension, type 2 diabetes and anxiety. Several episodes of palpitations and atypical anterior thoracalgia over the past years, without diagnosis to date.

Admitted to the emergency room for palpitations, fatigue after moderate exertion and anterior thoracalgia (located with one finger and increased with digital pressure), without irradiation, nausea, vomiting, lipothymia. Without orthopnea, cough, fever, urinary or intestinal complaints. Reference to episodes of agoraphobia. The patient was anxious, uncooperative, dehydrated, with discrete crackling at the right base. Apyretic, hypertensive, with a heart rate of 140 beats per minute, with arrhythmic heart sounds.

Electrocardiogram showed atrial fibrillation with a rapid ventricular response of 138 beats per minute, which was controlled with 5 mg of bisoprolol. Analytically, microcytic, hypochromic anemia, without elevation of acute phase parameters and negative cardiac biomarkers. Thyroid stimulating hormone (TSH) <0.01 mU/L, with free thyroxine level (fT4) of 43.8 ng/dl.

She began methimazole, with good tolerance and results. After

one month, the patient was asymptomatic, calmer and more cooperative, with TSH <0.01, FT4 19, Free Triiodothyronine (FT3) 5.6, microsomal anti-peroxidase antibody 609 and anti-TSH receptor antibody 4.53, confirming the presumptive diagnosis of Graves disease.

Discussion

Patients with hyperthyroidism may suffer from a wide range of symptoms, including anxiety, palpitations, irritability, heat intolerance, muscle weakness, among others. Patients often resort to emergency services with similar symptoms, so we mustn't forget this etiology during the diagnostic process.

#1401 - Abstract

MYOPATHY AND PCSK9 INHIBITORS THERAPY

Marta Carmen Esles Bolado, [Cristina Limia Vita](#), Lucia Paz Fajardo, Andrea Gonzalez Pascual, Marta Minguez Picasso
Hospital Sierrallana, Torrelavega, Spain

Background

The adverse effect more frequent with statin use are muscular symptoms (SAMS) to a greater or lesser degree, being rhabdomyolysis the most unusual and serious one¹. Its appearance entails one of the indications of PCSK9 inhibitors therapy² (iPCSK9). A recent meta-analysis confirms its safety in patients diagnosed of HFH (Heterozygotic familiar hypercholesterolemia) and SAMS³ and, also, in patients with primary myopathies^{4,5}. For that reason, we decided to examine this aspect in our patients.

Objective

Verifying the evolution of symptoms and CPK concentration in patients diagnosed of primary myopathy who are under iPCSK9 treatment.

Methods

We looked over patients diagnosed of primary myopathy who are receiving iPCSK9 in our hospital (where 165.000 patients are attended to and 260 beds are available). We establish that a patient presents primary myopathy when plasmatic concentration of CPK are higher than 180 u/L before starting treatment with lipid-lowering drugs and if another cause of secondary myopathy were excluded.

We collected demographic and clinical variables and LDLc concentration as well as CPK concentration before and after beginning iPCSK9 therapy.

Results

Of a total of 49 patients under iPCSK9 treatment, 5 meet criteria for primary myopathy. 60% of them are women and average age is 71 years. All of them are diagnosed of ischemic cardiopathy, one patient was diagnosed of muscular dystrophy and another one of inflammatory myopathy by muscular biopsy. This whole group

of patients were given evolocumab, 140 mg every 14 days, as treatment.

Average LDLc presented by our patients at the beginning of the treatment was 165 mg/dl and 59 mg/dl afterwards (meaning 68% of reduction). Prior to iPCSK9 treatment, CPK average was 3006 u/L, being 810 u/L subsequent to it.

Conclusion

Myopathy associated to statins use (SAMS) is an usual complication, being described in 7-29% of patients. An added problem consists in unmasking a primary myopathy, metabolic or congenital, because of the use of statins. In different published consensus about management of SAMS, the attitude in patients with primary myopathy remains unclear. With the introduction of PCSK9 inhibitors as therapy, several cases of this type of patient treated safely have been described. Our data confirm this aspect about iPCSK9 safety as well as their efficacy.

#1404 - Case Report

ADDISON'S DISEASE IN SCHMIDT SYNDROME

[Maria João Guerra Lopes Palavras](#), Ana Luísa Albuquerque, Catia Santos, Maria João Vieira, João Santos, Filipa Alçada
Hospital de Santo André, Leiria, Portugal

Introduction

Autoimmune polyendocrine syndromes comprise a diverse group of clinical entities involving functional impairment of multiple endocrine glands due to loss of immune tolerance.

Autoimmune polyendocrine syndrome type II (AIPS-II), also known as Schmidt syndrome, is a rare autoimmune disorder in which there is a steep drop in production of several essential hormones by the glands that secrete them. When first described, this disorder was thought to manifest by adrenal insufficiency (Addison's disease) and thyroid insufficiency (Hashimoto's thyroiditis) alone. However, as more patients were studied, the scope of the syndrome was expanded to include other disorders as type 1 diabetes mellitus and parathyroid gland disease. Dysfunction of the endocrine glands is usually accompanied by signs of malnutrition due to a dramatic decrease in intestinal absorption of nutrients.

Case description

The authors present the case of a 26 year-old male who was admitted by asthenia and palpitations. He was diagnosed with type 1 diabetes mellitus at age 12 and celiac disease at age 16. There was a hyperpigmentation on his lips and neck. In the emergency department, blood tests revealed hyperkalemia and hyponatremia. In a more extensive work up a decreased secretion of cortisol and aldosterone was found, as well as an increase in renin production. 21-hydroxylase antibody was negative. Corticosteroid treatment was started, considering the hypothesis of Addison's disease, which contributed to persistent, but eventually controlled, hyperglycemia.

Discussion

The etiology of AIPS-II is not fully known, but it is thought to result from abnormal immune responses. This syndrome, unlike AIPS-I, occurs in adults, with a peak incidence at age 30, and it tends to be more frequent in women than in men.

#1414 - Medical Image

DEXAMETHASONE ON DEMAND... LOOK AT THE CONSEQUENCES!

Carolina Carrilho Palma, Joana Patrício, Ricardo Pereira, Inês Costa Santos, João Tavares, Ana Catarina Emídio, Beatriz Navarro, Hugo Casimiro, Joana Carreira, Mário Parreira, Ermelinda Pedroso
Centro Hospitalar de Setúbal, Hospital de São Bernardo, Internal Medicine Department, Setúbal, Portugal

Clinical summary

Iatrogenic Cushing's syndrome is rarely seen nowadays, as physicians are aware of the multiple consequences of chronic systemic glucocorticoid therapy. However, it is believed to remain underestimated. A 42 year old male with bronchial asthma was treated with dexamethasone for an acute exacerbation and kept the treatment chronically. He was admitted for general weakness, uncontrollable pain in his right hip joint. He presented a moon face, together with dorsocervical fat pad, abdominal purple striae and bruises. Abdominal CT scanning confirmed atrophy of adrenal cortex, compatible with Iatrogenic Cushing's syndrome and CT scanning of the hip joint showed lytic lesions and cortical rupture of the right femoral head suggesting avascular necrosis, known as a major complication of this disease.

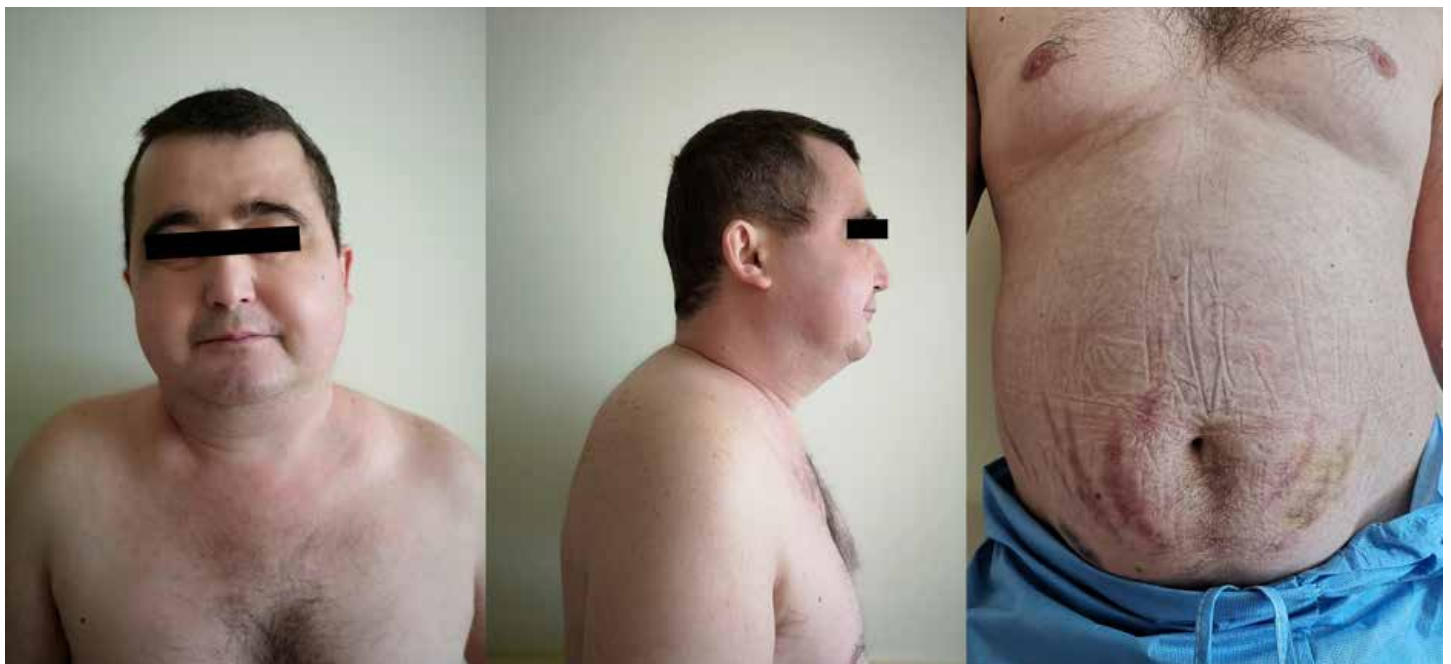

Figure #1414. Iatrogenic Cushing showing a moon face, a dorsocervical fatpad and purple abdominal stria.

#1422 - Case Report

ADDISONIAN CRISIS – A RARE DISEASE ENTITY

Ana Isabel Rodrigues, Rita Martins Fernandes, Domingos Sousa, Hugo Calderon, Cristina Granja
Centro Hospitalar e Universitário do Algarve - Hospital de Faro, Faro, Portugal

Introduction

Addison's disease is a rare disease with a prevalence of 110-140 cases/1,000,000 people in Western Europe, in which there is an inadequate secretion of the adrenocortical hormones - cortisol, aldosterone and androgens.

Case description

A 40-year-old man presented to the emergency department with a 3-day history of dizziness and confusion. He denied any past

medical history or regular medical treatment and reported a flu-like illness in the last week, with fever and productive cough.

On physical exam he was confused, feverish, dehydrated, pale, asthenic, with hyperpigmentation of the oral mucosa. He was hypotensive (mean arterial pressure <65 mmHg), refractory to fluid resuscitation. All other systems were essentially normal.

Laboratory results showed hyponatremia (114 mmol/l), hyperkalemia (5.3 mmol/l) and hypoglycemia (62 mg/dl).

Brain computerized tomography scan showed no ischemic or hemorrhagic changes.

After consulting hospital records it was verified that the patient was diagnosed with Addison's disease 5 years ago, daily medicated with hydrocortisone 17.5 mg id and fludrocortisone 0.075mg id. Asking the patient, he said that he had self-suspended the medication at the onset of the flu-like illness. The most likely hypothesis was Addisonian crisis triggered by the flu.

He started treatment with hydrocortisone 100 mg 3 id, fludrocortisone 0.1mg id and ionic correction. Due to cardiovascular dysfunction that required aminergic support, he was admitted to the Intermediate Care Unit, with progressive weaning of corticosteroid therapy and a favourable evolution.

Discussion

Acute adrenal insufficiency or Addisonian crisis is a rare endocrine emergency in which the prognosis depends on suspicion and timely intervention. In this clinical case, the delay in treatment was due to the difficulty in collecting the clinical history due to the patient's state of consciousness, which made the diagnosis difficult. The goal of treatment is to achieve glucocorticoid and mineralocorticoid levels in healthy individuals, in similar circumstances, as well as symptomatic support

#1438 - Case Report

A RARE CASE OF A THYROID RUNNING OUT OF BATTERIES

Rui Files Flores, Joana Rita Lopes, Maurício Peixoto, Guilherme Alpedrinha, Sofia Caridade
Hospital of Braga, Braga, Portugal

Introduction

Myxedema coma is one of many possible causes for acute changes in consciousness and is described as a serious life-threatening hypothyroidism that slows the body metabolism and can culminate in death. The most frequent clinical presentations involve neurological manifestations, such as lethargy and coma. Other clinical findings include extreme bradycardia and hypothermia that require early diagnosis and treatment.

Case description

An 80-year-old woman, independent, was brought to the emergency department after being found unconscious. Past medical history is noted for hypertension, dyslipidaemia and sleep disorder. She had an accidental fall less than a month previous to this episode, which resulted in a fracture of the orbit and lamina papyracea. Usually medicated with esomeprazol, simvastatine, lisinopril and bromazepam. At admission, she was conscious but with slowed speech and movements. Physical examination was noted for hypothermia, poorly perfused extremities, bradycardia and discrete peripheral edema. ECG confirmed bradycardia with Osbourne waves and T wave inversion in all precordial leads, except for V1. Arterial blood gas showed lactate levels of 3.8 mmol/L. Blood analysis showed elevated myoglobin and creatine kinase; thyroid stimulating hormone level of 69 U/mL and free T4 level of 0.42 ng/dL. Brain CT scan excluded vascular lesions. Diagnosis of Mixedema Coma was assumed and the patient received hydrocortisone followed by levothyroxine. During the first days of hospitalization, corticosteroid and thyroid supplementation were both maintained (100mg three times a day and 50µg od, respectively). After exclusion of adrenal insufficiency, hydrocortisone was withdrawn. Clinical

evolution was favorable and levothyroxine was titrated according to TSH levels taken weekly. During hospitalization, seizures were noted and confirmed by EEG. Levetiracetam 500 mg twice daily was initiated with good response.

Discussion

Myxedema Coma is a rare manifestation of severe hypothyroidism that is associated with high mortality rate if left untreated. Some of its diagnostic criteria combine acute changes in consciousness and hypothermia, alongside elevation of TSH and suppressed T4 levels. Other clinical findings are bradycardia, rhabdomyolysis, hyponatremia, hypoglycaemia and hypoventilation. Initial treatment with steroids and thyroid hormone should begin as soon as possible. Support treatment for managing systemic complications should not be underestimated.

#1444 - Medical Image

ENLARGING NECK MASS IN THE ELDERLY

Diogo Drummond Borges, Filipa Lourenço, Heidi Gruner, António Panarra

Serviço de Medicina Interna⁷², Hospital Curry Cabral, Centro Hospitalar Universitário Lisboa Central, Lisboa, Portugal

Clinical summary

87-year-old male went to the ER with complaints of headache, dysphagia, weight loss and cervical swelling. He denied dyspnea, dysphonia or nocturnal sweating. Physical examination revealed a heterogeneous hard elastic nodule on the right thyroid lobe over 4cm, and a smaller one on the left lobe with the same characteristics, with fixed right jugular adenopathy. Known medical history of type 2 diabetes, hypertension, chronic gastritis with Dieulafoy's lesion. Thyroid ultrasound revealed a large solid nodule, probable adenopathy with invasion and thrombosis of the left jugular vein. He underwent fine needle aspiration compatible with anaplastic thyroid carcinoma. Full body CT scan revealed loco regional invasion with vascular, lymphatic compromise and pulmonary metastasis, staged as T4N1bM1.

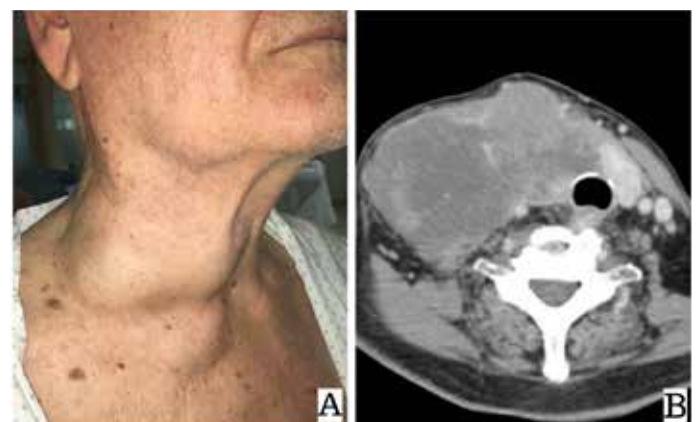


Figure #1444. A - Neck mass; B - Computed tomography (CT) findings of anaplastic thyroid carcinoma, with loco regional invasion, vascular and lymphatic compromise.

#1449 - Abstract

NONALCOHOLIC FATTY LIVER DISEASE AND THE CARDIOVASCULAR RISK IN DIABETIC PATIENTS

Elena Cristina Rezi

Lucian Blaga University, Medical Faculty, Sibiu, Romania

Background

Non-alcoholic fatty liver disease (NAFLD) can be considered a feature of metabolic syndrome. Some studies suggest that the metabolic syndrome predicts incident cardiovascular disease (CVD), so it is possible to hypothesize that NAFLD patients might have a greater CVD risk.

Methods

We have performed a retrospective observational study in order to see if there is any significant difference between the risks of CVD (assessed by using the UKPDS risk engine) at the type 2 diabetic patients with NAFLD, comparing with those without NAFLD. We have studied a group of 80 type 2 diabetic patients who were hospitalized in the Diabetes and Nutrition disease Department of the Clinical County Hospital from Sibiu, Romania, during a period of three months.

Results

From the whole group, 23 patients (28.75%) were diagnosed with NAFLD. The average age of the patients with NAFLD was higher than of those without NAFLD (66.91 ± 7.59 years, comparing with 60.29 ± 9.15 , with $p=0.0015$). The risks of developing CVD at those without NAFLD comparing with those with NAFLD were: for coronary heart disease 21.3% comparing with 33.02% ($p=0.0071$), for fatal coronary heart disease 15.3% comparing with 26.81% ($p=0.0031$), for stroke 7.6% comparing with 15.91% ($p=0.0001$) and for fatal stroke 1.3% comparing with 2.86% ($p=0.0004$). A linear correlation was found between the Forns index of liver fibrosis and the risk of developing CVD ($r=0.21$ for coronary heart disease, $r=0.199$ for fatal coronary heart disease, $r=0.334$ for stroke and $r=0.325$ for fatal stroke). The level of liver cytolysis did not correlate with the risk of CVD, in the NAFLD group.

Conclusion

The diabetic patients with non-alcoholic fatty liver disease have a higher risk of developing cardiovascular diseases than those without the liver pathology. There is a linear correlation between the degree of liver fibrosis and the risk of cardiovascular diseases. Our findings support the hypothesis that non-alcoholic fatty liver disease is associated with a moderately increased risk for future cardiovascular events among type 2 diabetic individuals, independent of the degree of liver cytolysis.

#1482 - Abstract

DYSTHYROIDISM AND SYSTEMIC LUPUS ERYTHEMATOSUS (SLE)

Wafa Baya, Imen Ben Hassine, Jihed Anoun, Fatma Ben Fredj Ismail, Monia Karmani, Amel Rezgui, Chedia Laouani Kechrid
Internal Medicine Department, Sahloul University Department, Sousse, Tunisia

Background

Thyroid dysfunction is more common in lupus patients than in general population. The aim of our study is to evaluate the frequency of dysthyroidism in lupus patients.

Methods

This is a retrospective descriptive study carried out in the Internal Medicine Department of Sahloul University Hospital in Sousse, based on the records of lupus patients.

Results

Among the 127 lupus patients hospitalized at least once in the department, thyroid dysfunction was observed in 11 patients. They were all women. The mean age was 53 years [26 - 79 years]. The mean duration of SLE was 11.5 years. Articular, cutaneous and hematological involvements were mostly observed. Our patients have been treated with synthetic antimalarials associated with corticosteroids in the majority of cases.

All cases of thyroid dysfunction were hypothyroidism. Hypothyroidism was subclinical in 4 cases. Asthenia and weight gain were the most frequent manifestations. A goiter was found in two patients. Hashimoto's thyroiditis was diagnosed in four cases. Hypothyroidism was discovered after SLE diagnosis in one case. Among these patients, only one case of Schmidt syndrome was found.

The patients were on substitution treatment when indicated, with good evolution.

Conclusion

Any lupus patient must benefit from thyroid exploration given the frequency of subclinical hypothyroidism association and Hashimoto's thyroiditis.

#1496 - Case Report

UREA IN THE TREATMENT OF SIADH

Marta Arriaga Rocha, Joana Maurício, Martim Trovão Bastos, Susana Bastos Heitor
Hospital Prof.Doutor Fernando Fonseca, Amadora, Portugal

Introduction

Syndrome of inappropriate antidiuretic hormone secretion (SIADH) results from the non-osmotic release of vasopressin. The secretion of this hormone induces water retention with maintenance of normal total sodium levels, which results in the

dilution of solutes and consequent euvoletic hyponatremia and hypoosmolality. Although SIADH is associated with multiple conditions, one-third is idiopathic. Therapy involves water restriction and an increase in solute intake (0.25-0.50 g/kg/day of urea) or a combination of loop diuretics and sodium chloride may be considered.

Case description

An 83-year-old man diagnosed with hypertension, dyslipidemia and smoking 45 pack-years, treated with losartan and atorvastatin, was hospitalized due to altered state of consciousness. At admission he presented with hyponatremia of 126 mmol/L. Objective examination had no signs of dehydration or water overload. Among the aetiological investigations during hospitalization were: creatinine 0.58 mg/dL, urea 0.58 mg/dL, uric acid 2.2 mg/dL, plasma osmolality 258 mEq/L, urinary osmolality 499 mOsmol/kg, urinary sodium 125 mmol/L. Euvoletic hypotonic hyponatremia was admitted and treatment with 0.9% sodium chloride (NaCl), water restriction and furosemide 40 mg oral was initiated. Assuming SIADH or endocrinological pathology as a diagnostic hypothesis, he performed thyroid function tests with normal values, serum cortisol dosage with borderline value (4.43mcg/dL), ACTH 29.57 pg/ml, still performing synacthen test with cortisol 0': 5; 30': 18.5; 60': 20mcg/dL. Thoracic, abdominal, pelvic and brain CT scan did not show alterations. Analytical profile was within reference value. In the absence of response to the established measures, with worsening hyponatremia (119 mmol/L), 40 mL of 20% NaCl was added to the 500 mL of 0.9% NaCl, with improvement of serum sodium levels (133 mmol/L). However, after interrupting fluid therapy, the hyponatraemia worsened. The implementation of therapy with 30 g/day of Urea restored the ionic balance and maintenance of serum sodium values in the order of 134 mmol/L. The patient was discharged keeping urea therapy until further evaluation in the outpatient clinic.

Discussion

SIADH causes high morbidity and its main therapeutics have varying efficacy and tolerability. Urea appears as an effective, safe and relatively well-tolerated alternative for the treatment of euvoletic hypotonic hyponatremia, which can be used on an outpatient basis and with lower costs when compared to vasopressin antagonists.

#1522 - Case Report

GAIT DISORDERS- DIFICULT DIAGNOSIS IN A DIABETIC PATIENT

Rita Dos Santos Marques

Centro Hospitalar do Oeste, Torres Vedras, Portugal

Introduction

The diabetic neuropathy is a frequent complication of Diabetes mellitus. In Diabetes mellitus type 1, the distal polyneuropathy usually becomes symptomatic, after years of prolonged

hyperglycemia. In majority it manifests with sensitive and motor symptoms, such as ataxia. Ataxia is an incapacity to maintain a normal posture and a coordinated movement.

Case description

Male, 65 years old, with diagnosed diabetes mellitus type 1 (30 years ago), dyslipidemia, essential hypertension and urinary incontinence. Chronically medicated with Insuline and Ramipril. He comes to emergency room with headache, vomits and hyperglycemia. Physical exam: prostrate but responsive to verbal stimulus with ocular opening, pale e dehydrated, acetone breath. Arterial sample: pH 7.16, bicarbonate 12 mmol/L; lactate 1.6 mmol/L; glucose 320 mg/dl; anion gap 20.1 mmol/L; ketone bodies 7.8 mg/dL.

Hospitalized with diabetic ketoacidosis, without sign of infection. During hospitalization there is maintenance of confusion, bilateral muscular weakness of lower limbs and ataxic gait. Brain CT: "supratentorial ventricular dilation, with reduce sulcal permeability, some degree of hydrocephalus with Evan's ration of 0.42. EEG: chronic loss of motor units of the distal muscles, related to sensitive and motor polyneuropathy in patient with chronic diabetes mellitus, without signs of demyelinating disease such as amyotrophic lateral sclerosis. There was improvement in metabolic status and mental confusion. Neurologist's examination: " oriented in person and space but not in time; Without dysarthria, neither diplopia or nystagmus; fast and irregular postural tremor. Hypopalesthesia from feet to ankles; Proprioception errors fin feet and hand fingers. Nose-finger test: dysmetria with closed eyes. Positive Romberg test. Irregular gait mostly with closed eyes". He was discharged with booked Neurology's consultation, for follow-up.

Discussion

This case report highlights the difficulty to have a definitive diagnosis in a diabetic patient, with bad metabolic control and a long-term evolution. The clinical features (ataxic gait, urinary incontinence, cognitive disorders), and brain CT findings, may suggest normal pressure hydrocephalus. Spontaneous resolution of the mental confusion status, exclude that diagnosis, and assume that gait disorder may be related to diabetic neuropathy. A definitive conclusion just be possible with natural disease progression and a good follow-up of the patient.

#1547 - Case Report

GABA (IN) THE GUT

Maria João Palavras, Ana Albuquerque, Flávia Santos, Filipa Alçada

933613792, Leiria, Portugal

Introduction

Pregabalin, a gamma-aminobutyric acid (GABA) analogue used to treat neuropathic pain and fibromyalgia, is mostly used for the treatment of pain related to nerve injury or inflammation, but it has also been used as an adjunctive therapy for partial onset seizures.

Case description

The authors describe the case of a 61 year-old woman with severe demyelinating sensorimotor polyneuropathy, admitted to the hospital following acute exacerbation of chronic obstructive pulmonary disease. Two days later, she suffered three episodes of generalized tonic-clonic seizure. The cause for these seizures was not identified. The electroencephalogram suggested a grade 3 metabolic encephalopathy with no epileptogenic activity. After speaking with the patient's sisters, an abuse of pregabalin ingestion at home was identified, at least 800mg per day. Since this medication was not administered during the hospital stay and the patient never complained about uncontrolled pain, the most probable cause for the seizure was assumed to be pregabalin withdrawal.

Discussion

The case focused on a patient who developed seizures after a sudden discontinuation of a relatively large dose of pregabalin, which is very uncommon in a patient with no previous history of epilepsy. The reason for the overuse of pregabalin in this patient is unknown, since she denied any additional benefits, as well as the abuse itself. The authors believe a thorough psychological examination should take place before starting chronic pain relief medications, since further studies are needed to clarify which ones will cause withdrawal seizures or addiction psychosis.

#1566 - Case Report

COR PULMONALE SECONDARY TO SEVERE PULMONARY HYPERTENSION AS THE FIRST MANIFESTATION OF GRAVES' DISEASE

Sandra D. Santos¹, Ana Guiomar, Ana Cristina Martins¹, João Rua¹, Pedro Ribeiro¹, Armando Carvalho^{1,2}

¹ Serviço de Medicina Interna, Centro Hospitalar e Universitário de Coimbra, Coimbra, Portugal

² Clínica Universitária de Medicina Interna, FMUC, Coimbra, Portugal

Introduction

Pulmonary hypertension (PH) is a severe, multifactorial, multi-causal clinical syndrome that compromises physical capacity and causes great morbidity. It consists of an increase in pulmonary arterial pressure by a progressive increase in pulmonary vascular resistance, which tends to evolve with right ventricular failure and premature death of the patient.

Case description

A 88-year-old woman, with history of CKD stage IIIa, atrial fibrillation, heart failure and hypertension, was evaluated at the Hospital because of dyspnea and edema of the lower limbs. She was hemodynamically (HD) stable, afebrile, with absence of murmur in both pulmonary bases, with hepatomegaly, ascites and marked inferior limbs edema. She had type 1 respiratory insufficiency, atrial fibrillation with rapid ventricular rate, and increased Nt-proBNP (20,000 pg/ml). The patient was diagnosed with severe heart failure and was hospitalized. There was a history of 2 similar hospitalizations

that year, with rapid re-admission after discharge and loss of walking ability. Three days later, she presented acute pulmonary edema and, underwent a transthoracic echocardiogram (ETT), which showed severe PH (PSAP 75 mmHg), right ventricular dysfunction without left structural or functional dysfunction. An AngioCT excluded pulmonary thromboembolism. The PH investigation was initiated, although the right catheterization was refused, including a CT-CTAP that excluded relevant pulmonary pathology and an extended, also negative, autoimmune study. Thyroid function evaluation [TSH <0.008 IU/ml, T4L 3.2 ng/dl (0.8-1.6), T3L 3.7 pg/ml (1.8-4.2), TRABS 1,6 IU/ml (<1.0)] revealed a Graves' disease with thyrotoxicosis. Treatment with propylthiouracil, 100 mg 3id, was started and later replaced with thiamazol due to an allergic reaction. There was a rapid improvement in the clinical and hemodynamic status of the patient, stabilization of the right HF and resolution of the volume overload. A new ETT showed improvement with mild PH (PSAP 50 mmHg). At discharge, the patient was HD stable, with no need for oxygen therapy or relevant limitation of physical activity (NYHA I) and was able to walk autonomously. At one month reevaluation appointment the patient remained stable.

Discussion

The patient had a clear clinical course of right HF due to severe PH, but few clinical signs of hyperthyroidism (increased cardiac output, decreased vascular resistance). Therefore, we assumed that PH was due to stimulation and proliferation of the pulmonary artery vasculature.

#1570 - Case Report

ALKAPTONURIA

Ana Simas, Ricardo Veloso, Maria Menezes, Ana Silveira, Juvenal Morais, Mariela Rodrigues, Joana Mota, Sandra Brum, Fátima Pinto, António Goulart

Hospital da Horta, E.P.E., Horta, Portugal

Introduction

Alkaptonuria is a rare autosomal recessive error in phenylalanine and tyrosine metabolism (affecting 0.0004 to 0.001% of the world's population) that causes an accumulation of homogentisic acid, consequently, increasing urinary excretion. The first signs appear in childhood but the patients only become symptomatic in the fourth decade of life. This disease is characterized by ochronosis arthropathy, cardiovascular, cutaneous and ocular ochronosis, renal lithiasis and black urine. Ochronosis arthropathy is the most disabling manifestation and it can initially affect the large joints and vertebral column.

The authors consider that this case report should be exposed by its rarity, contributing in this way for a better knowledge and characterization of this disease.

Case description

A 72-years-old female with personal antecedents of type 2 diabetes, arterial hypertension, dyslipidemia, incapacitating left

gonartrosis and chronic kidney disease, with multiple references in follow-up visits to “blue disease” in order to justify the “blue” dermic coloration, diagnosed at the age of 50.

The patient arrived to the emergency department with nausea, vomiting and prostration. The physical examination revealed crackles in both lung bases, edema of the lower limbs, cyanosed lips, gray skin color with dark spots on the hands and ears. The urine collection bag presented dark-colored urine.

The clinical picture worsened and the patient died a few hours later due to heart failure.

Given the atypical findings, direct relatives were contacted, confirming similar dermic dark spots in other family members.

A clinical autopsy was performed to clarify a possible hereditary disease. The macroscopic observation revealed dark spots on the eyelids, ears, areas of limb flexion, pleats of hands palms and soles of the feet, ribs with dark color mainly at the cut surface, heart with dark insertion of aortic and mitral valves, and brown shade of aorta. The histology revealed irregular deposits of brown/ochre pigment in the dark areas previously cited and in areas where macroscopic observations looked normal. These features are compatible with ochronosis (alkaptonuria).

Discussion

In this case report the signs and symptoms were typical, however the diagnosis was post-mortem due to the rarity of the disease. This case shows the importance and necessity of a high level of suspicion.

#1603 - Abstract

GESTATIONAL DIABETES OF A MEDIAN PORTUGUESE COMMUNITY HOSPITAL

Juliana Chen Xu, Angela Coelho, Pedro Carvalho E Marques, Sónia Da Costa Fernandes, Teresa Pinto, Ana Maria Maia
CHPVVC, Póvoa De Varzim, Portugal

Background

Gestational diabetes (GD) has lately grown in number (nr), not only because of underdiagnosed cases in the past, today's characteristics of our society (overeating and non-exercising) but also the recent lower cut-off (92 mg/dL of fasting glucose).

In order to analyze the effect that GD has in the community that attends our hospital, we decided to collect GD cases for one year.

Methods

Data was collected during GD consultations since the diagnosis until post-partum evaluation of all the births occurring from 2018 January 1st to December 31st. Therefore, the database is based on those registrations and examined retrospectively. The information gathered was: citizenship, age, academic qualifications, familial history of diabetes, body mass index (BMI), history of previous GD, previous macrosomia, diagnosis with fasting glycemia or oral glucose tolerance test (OGTT), gestational week of diagnosis/1st consultation, nr of waiting weeks, weight

before pregnancy/diagnosis/end of pregnancy, use of insulin or metformin, pregnancy complications, delivery information, newborn information and reevaluation post-partum with OGTT. IBM SPSS Statistics 25 was used for statistical analysis.

Results

We had 84 cases of GD in 2018 from a total of 1055 births, with mean age of 33.93 years.

15.5% had higher education and 8.3% completed high school. 69% had familial history of diabetes. 32.1% were already obese before pregnancy, 33.3% were overweight and 32.1% had normal BMI. 16.7% had previous pregnancies with GD and 4.8% had previous macrosomia. The median delay from diagnosis until the 1st consultation was 8 weeks, with minimum 1week and maximum 30 weeks of waiting. 61.9% of the pregnant were controlled with diet and exercise, 15.5% had only insulin therapy, 10.7% had just metformin and 11.9% had both insulin and metformin during pregnancy. Only 6% of the newborns weighted ≥ 4000 g from which 40% were from mothers controlled only by diet. On post-partum reevaluation, we had one case of diabetes, 2 impaired glucose tolerance and a case of impaired fasting glucose.

Conclusion

The familial history of diabetes and previous BMI are great risk factors for the development of GD. However, it is possible to control glycemia only with appropriate diet and exercise.

It has come to our attention that our latency period is too long. The reasons for such are still under evaluation and it may be due to delay in referral/scheduling consultations, so measures have been taken to speed up the patients follow up.

#1617 - Abstract

THE RELATIONSHIP BETWEEN STRESS LEVELS AND METABOLIC RISK FACTORS IN NORMAL AND PROFESSIONAL MUSICIAN POPULATIONS

Yavuz Masrabacı, Melisa Askim Paker
Güven Cayyolu Healthy Living Campus, Ankara, Turkey

Background

The aim was to reveal the relation between different stress levels and metabolic abnormalities in normal population, and to compare this relation in normal and musicians populations.

Methods

Samples were consisted of 46 professional musicians and 21 participants from normal population. Recent Life Events Scale was applied to participants who attended to Güven Cayyolu Healthy Living Campus-Checkup Program. Mann-Whitney U Test, χ^2 Test and independent samples t-tests (Bootstrapping run) were run to reveal differences in fasting blood glucose, insulin resistance and TOTAL/HDL cholesterol among gender and different stress levels in normal population, and one-way between subjects ANOVA

tests (Bootstrapping run) were run to compare these variables among normal and musicians.

Results

In normal population, males had significantly higher TOTAL/HDL cholesterol ratio than females, same as musicians whilst in musicians, different stress levels were founded to significantly differ for fasting blood glucose level. Male musicians had found to have significantly lower TOTAL/HDL cholesterol ratio and fasting blood glucose than males in normal population. There was no significant difference in metabolic abnormalities among stress levels in normal population.

Conclusion

In normal and musician populations, males had higher cardiovascular disease risks since TOTAL/HDL cholesterol ratio was higher. Performing musical instruments could be thought as a protective factor for TOTAL/HDL cholesterol ratio and fasting blood glucose.

#1625 - Case Report

PREGNANCY-RELATED OSTEOPOROSIS

Ana Chora Sousa, Francisco Dias Claudio, Rita Ribeirinho, Tiago Tribolet Abreu

Hospital do Espírito Santo de Évora, Évora, Portugal

Introduction

Pregnancy-related osteoporosis is a very rare condition characterized by the occurrence of fracture during pregnancy or the puerperium. Its etiology and pathogenesis are unknown. Throughout the last period of pregnancy, calcium mobilization and bone resorption are increased and lactation imposes a further increase. These changes could lead to osteoporosis and fracture in young women.

Case description

A 32-year-old pregnant woman, primiparous, at 32 weeks of pregnancy, was sent to the emergency room after a small-energy fall with trauma of the lower limb. She had no relevant past medical or family history. The radiological evaluation showed a subcapital femur fracture. The patient was submitted to a percutaneous osteosynthesis, without post-op complications. The blood panel showed a vitamin D of 15 ng/mL, with normal serum calcium and phosphorus. At discharge, she was given bisphosphonates, calcium and cholecalciferol. Four weeks later, she delivered the baby by caesarean. The bone mineral density (BMD) T-scores, 3 months after the delivery were -1.6 at femur total and -0.9 at lumbar. The therapy was maintained for 6 months. The BMD T-scores 15 months after the delivery and after 6 months without therapy were -0.8 at femur total and -0.7 at lumbar. After a 2-year follow up there were no new fractures.

Discussion

Our aim is to report this unusual case of pregnancy-related

osteoporosis with a pathological femur fracture during the third trimester of a primiparous woman. The underlying pathological factor is still not clear. However, there are certain risk factors such poor nutrition, low calcium intake, family history, smoking and corticosteroid intake which strongly increase the risk. Our patient did not have any of these risk factors. Antiresorptives are the first line of management in pregnancy-related osteoporosis with fractures. Calcium and vitamin D supplementation increase the levels of calcium in body and calcium absorption, respectively. The optimal duration of bisphosphonate in pregnancy-related osteoporosis remains unsolved. Following the delivery and the above-described therapy, the bone mineral density improved and she did not experience any recurrence.

#1633 - Abstract

THREE YEARS OF MANAGEMENT OF GESTATIONAL DIABETES IN A PORTUGUESE HOSPITAL CENTRE

Giovana Clare Sousa Ennis, Diana Pinho Santos, Cristina Andrade, Adelino Carragoso, Isabel Torres, António Correia Tondela-Viseu, Hospital Centre, Portugal, Viseu, Portugal

Background

Gestational diabetes (GDM) is prevalent and is associated with adverse maternal and foetal outcomes. The authors report the results of a three-year follow-up study of pregnant women with GDM.

Methods

A retrospective study was performed based on medical records of women with gestational diabetes followed in a Portuguese hospital centre with childbirth from 2015 to 2017.

Results

501 pregnant women with GDM were included. Women's ages ranged from 16 to 44 years (mean 32.75). Most were in the 30 to 35 year age group and nearly a third were over 35. In 2017, there was a considerable reduction of overweighted or obese women (51.3%), however more than half still had a body mass index above normal values. The third trimester glycated haemoglobin value was stable throughout these three years, with a mean of 5.15% (± 0.40). Average gestational age at childbirth was 38.58 weeks (± 1.42), and 92.3% of women carried their pregnancy to term. Average new-born's weight was 3,192.88g (± 490.55). The proportion of new-borns weighing more than 4,000kg at birth averaged 4.2%, ranging from 1.8% in 2015 to 4.9% in 2016. The percentage of low birth weight (less than 2,500 g) has been more stable, averaging 8.0%. More than 80% of the women included in our study were reclassified. At the reclassification appointment, more than 90% presented a normal glucose tolerance test. There was a progressive increase in fasting glucose abnormality diagnoses (0.64%, 1.76% and 2.08% in 2015, 2016 and 2017, respectively), whereas diminished glucose tolerance declined

over the period (3.87%, 2.35% and 2.08% in 2015, 2016 and 2017, respectively). 2017 saw the largest proportion of diabetes diagnoses in reclassification appointments (2.58%).

Conclusion

The number of women who delay pregnancy has been growing over the years, as is shown by our study in which almost third of the sample were over 35 years of age. There is a surprising number of young women overweighted or obese, accentuating the increased cardiovascular risk associated with GDM. Nonetheless, pregnancy outcomes were quite satisfactory, as more than 90% of these women carried their pregnancy to term, and the average rate of macrosomia was less than 5%. Post-partum reclassification of the state of tolerance to carbohydrates is essential, as a history of GDM is a risk factor for GDM in a subsequent pregnancy, as well type-2 diabetes and cardiovascular disease.

#1656 - Case Report

HYPERCALCEMIA IN A 75-YEAR-OLD PRESENTING WITH PANCREATITIS AND ITS CONFOUNDING FACTORS

Catarina Ribeiro Pereira

Hospital Prof. Doutor Fernando de Fonseca, EPE, Lisboa, Portugal

Introduction

In the presence of pancreatitis, finding an aetiology can be challenging and has important prognostic implications.

Hypercalcemia is an uncommon yet recognized cause of acute pancreatitis with a reported prevalence between 1,5-8%. In its presence, particularly in the elderly, secondary malignancy should be excluded.

Case description

A 75-year-old male with previous medical history of hypertension, renal lithiasis, hyperuricemia, benign prostatic hyperplasia submitted to parcial prostatectomy in the past and chronic constipation was admitted with vomits and abdominal pain with epigastric location radiating to both flanks. Concomitantly, he referred unquantified weight loss as well as bilateral hip pain with mechanical features in the 6-months previous to admission.

Initial investigation presented an elevation of inflammatory parameters, hyperamylasaemia 1087 U/L and hypercalcemia of 12.9 mg/dL. The abdominal ultrasound documented a distended gall bladder without evident of biliary lithiasis or biliary tract distention. Abdominal CT-scan demonstrated pancreatic inflammation and additionally three bone lesions with lithic features in the pelvic region.

Additional studies directed to hypercalcaemia revealed an elevated parathormone level of 357pg/mL and thyroid ultrasound identified a nodule with mixed features.

Bone scintigraphy presented six additional bone lesions of osteoblastic nature, further supporting the neoplasm hypothesis. Given past medical history, a free prostatic antigen was solicited

25 ng/mL and the patient underwent prostatic biopsy with no identification of tumour cells.

The patient underwent PET tomography that identified FDG avidity in the pancreatic head and further characterized bone lesions as possible implants. No tumor was found on an eco-guided biopsy performed later. Two hip lesions were biopsied surgically and pathology identified "brown tumour" with extensive osteoclastic activity and no evidence of tumour cells. Furthermore, an adenoma was found and confirmed on parathyroid scintigraphy, confirming the diagnosis of primary hyperparathyroidism. The patient awaits surgery on support therapy with bisphosphonates.

Discussion

This case demonstrates the interdisciplinarity that defines, and norms, Internal Medicine, and the importance of the classical syndromic presentations. Therefore, in an era where cancer diagnosis is more frequent and actively sought in medical wards, an unbiased knowledge of the classic metabolic multisystemic syndromes should remain present.

#1669 - Abstract

EFFECTS OF PRE-PREGNANCY BODY MASS INDEX AND GESTATIONAL WEIGHT GAIN ON RISK OF MACROSOMIA IN WOMEN WITH GESTATIONAL DIABETES MELLITUS

Diana Pinho Santos, Giovana Ennis, Adelino Carragoso, Cristina Andrade, Isabel Torres, António Correia

Centro Hospitalar Tondela-Viseu, Viseu, Portugal

Background

Gestational Diabetes (GD) is associated with numerous complications for both mother and fetus. Pre-pregnancy Body Mass Index (BMI) and Gestational Weight Gain (GWG) have been associated with newborn's weight. We proposed to investigate: (1) associations between pre-pregnancy BMI, total GWG and excessive GWG with macrosomia; (2) differences between excessive and no excessive GWG groups in pre-pregnancy BMI variable.

Methods

This observational retrospective study included 459 pregnant women with GD followed in a Portuguese Hospital with childbirth from 2015 to 2017. BMI was categorized according to WHO criteria. Total GWG was calculated using the weight at the last appointment before delivery and the pre-pregnancy weight. GWG was categorized according to Institute of Medicine recommendations. Macrosomia was defined as birth weight ≥ 4000 g. Association between pre-pregnancy BMI, total GWG and excessive GWG with macrosomia were computed using a Chi-square (X^2) test. Differences between excessive and no excessive GWG groups in pre-pregnancy BMI variable was computed using student's t-test. Statistics were performed in IBM-SPSS 23 and the level of significance was established in 5%.

Results

Pre-pregnancy BMI mean was $27.0 \pm 6.0 \text{ kg/m}^2$; 2.6% of women were underweight, 42.9% had normal weight, 27.7% were overweight and 26.8% were obese. The mean birth weight was $3216.5 \pm 478.7 \text{ g}$ and macrosomia occurred in 4.1% of newborn. 4.4% of overweight and obese women delivered a macrosomic infant, and 4.1% of women with normal weight had a macrosomic infant. Significant association was found between pre-pregnancy BMI and macrosomia ($X^2=9.054$, $p<0.05$). The mean total GWG was $8.5 \pm 5.7 \text{ kg}$ in the whole population. No significant associations were found between total GWG ($X^2=50.420$, $p>0.05$) and macrosomia. Only 32.0% of women had an adequate GWG and 17.2% had an excessive GWG. Women with excessive GWG had more macrosomic infants compared with women with no excessive GWG (7.5% vs 3.4%), but no significant association was found between excessive GWG ($X^2=2.757$, $p>0.05$) and macrosomia. Women with excessive GWG had a higher mean pre-pregnancy BMI ($28.8 \pm 4.6 \text{ kg/m}^2$) than women without excessive GWG ($26.7 \pm 6.2 \text{ kg/m}^2$) ($t=-3.474$, $p<0.05$).

Conclusion

Pre-pregnancy BMI is predictive of the risk of macrosomia and women with excessive GWG had a higher pre-pregnancy BMI. This information should be considered when designing more efficient strategies to control weight before the women's pregnancy.

#1679 - Case Report

(A RARE CASE OF) METHADONE-INDUCED HYPOGLYCEMIA

Maria Inês Vicente^{1,2}, Alexandre N. Fernandes¹, Tânia Strecht¹, Ana Paula Antunes¹, Carolina Sequeira¹, Marta Custódio¹, Ana Gorgulho¹, Jana Zelinová¹

¹ Hospital de Cascais, Cascais, Portugal

² IPO Lisboa, Lisboa, Portugal

Introduction

Methadone is the main pharmacologic agent used in the treatment of opioid addiction. Although uncommon, hypoglycemia has been observed in patients receiving this drug and the effect is believed to be dose-related. Some studies point out that the risk is increased for doses exceeding 40 mg orally per day. Several authors recommend blood glucose monitoring during methadone use and titration.

Case description

We present the case of a 48-year-old woman with medical history of HIV1/HCV coinfection for 20 years and irregular antiretroviral therapy use, alcoholic and viral chronic hepatic disease (CHD), current smoker and previous IV drug user, on methadone 80 mg daily and recently under cotrimoxazole prophylaxis (CD4 count 2 cells/ μL). She was admitted to the emergency room for symptomatic hypoglycemia (35 mg/dL), which became partially refractory to dietary measures and glucose infusion. Serum insulin

was normal (14 $\mu\text{UI/mL}$), as were serum peptide-C (6.4 ng/mL), β -hydroxybutyrate (0.03 mmol/L), ACTH (20.5 pg/mL) and morning cortisol (18.2 mcg/dL). She also had anemia, thrombocytopenia, mild hyponatremia, prolonged INR, hypoalbuminemia and altered hepatic enzymes, all presumed to be related to CHD. Abdominal CT showed features of CHD. Episodes of hypoglycemia started before she initiated cotrimoxazole (1 month earlier). Based on rare cases of hypoglycemia associated with this drug it was suspended, but hypoglycemia persisted. It only ceased after methadone dose reduction to 70 mg/day. The patient was discharged home and so far (8 months later) hypoglycemia never recurred.

Discussion

Methadone-induced hypoglycemia has been mainly described in association with rapid dose escalation. Our patient was already on methadone for several years, however, hypoglycemia only resolved after dose reduction and no other apparent explanation was found. This case reminds us about the clinical importance of knowing drug side-effects in our daily practice and that methadone use should be included in the differential diagnosis of new onset hypoglycemia.

#1695 - Case Report

ANTIBODY-INDUCED GRAVES' ORBITOPATHY

Fabiana Gouveia¹, Isabel Taveira², Hipólito Nzwalo²

¹ Hospital Central do Funchal, Funchal, Portugal

² Unidade Local de Saúde do Litoral Alentejano, Funchal, Portugal

Introduction

Ocular manifestations, in particular, exophthalmos, are a frequent complication of Graves' Disease (GD). The occurrence of ophthalmopathy preceding the clinical manifestations of the DG is rare.

Case description

Woman, 49 years old, with a history of hypertension, type 2 diabetes mellitus, obesity, and dyslipidemia, with a history of progressive onset in one week of holocranial headache and monocular blurred vision on the right. At the emergency department, hemorrhagic exudate and conjunctival hyperemia of the right eye were present. The initial investigation (ocular fluorescein angiography, angio-resonance, cerebral and ocular Magnetic Resonance Imaging (MRI)) was negative. He did not present systemic symptoms or constitutional complaints. Repetitive study for systemic, autoimmune diseases including anti-thyroid antibodies was negative. During three years, the clinical condition remained stable, until the onset of aggravation, with asymmetrical involvement, with evident proptosis, hyperemia and slight pain to the ocular mobilization. Orbital MRI showed exophthalmos and dimensional increase of the extrinsic muscles of the eye (inferior rectus, medial and superior rectus bilaterally). With the exception of holocranial headache, there were no additional complaints.

The analytical study revealed the presence of low TSH (0.14 uIU/mL), T4 (11.55 ug/dl), slightly increased anti-thyroid peroxidase antibodies consistent with GD diagnosis.

Discussion

This case highlights the diagnostic difficulties arising from an atypical manifestation of a well-described disease. The isolated attainment of the eye in the GD is due to the particular affinity of the GD antibodies to the ocular tissues, probably in a phase of reduced activity of the disease.

#1696 - Abstract

THE EFFECT OF DAILY VERSUS WEEKLY LEVOTHYROXINE - REPLACEMENT ON THYROID FUNCTION TEST IN HYPOTHYROID PATIENTS AT A TERTIARY CARE CENTRE

Pratibha Singh^{1,2}, Avinash Chandra Srivastava^{1,2}

¹ Dr. Ram Manohar Lohiya Institute of Medical Sciences, Lucknow, India

² Dr. Ram Manohar Lohiya Hospital, Lucknow, India

Background

Hypothyroidism is the most common thyroid disorder and affects women more frequently than men, and incidence increases with age. Its clinical presentation ranges from asymptomatic to severe, with myxedema coma as a severe complication.

In spite of being easily treatable using a daily dose of levothyroxine (LT4),

many patients remain hypothyroid due to malabsorption syndromes, pancreatic and liver disorders, drug interactions, autoimmune gastritis, polymorphisms in type 2 deiodinase, high fiber diet and, more frequently, noncompliance to LT4 therapy.

Noncompliance is attributed to the limitations and inconveniences imposed by therapy:

1. the need to take the medication while fasting;
2. the need to wait approximately 30 minutes for the next meal;
3. the need to take the medication on a daily basis.
4. the need to avoid other medications that may interfere with absorption.

Methods

The mean treatment dose of oral thyroxine is 1.6 µg/kg/day. The results achieved with this dose are adequate and reproducible. This will be a randomised crossover experimental study in which 100 hypothyroid patients on a stable LT4 dose will be divided into 2 groups of 50 each.

In group I, patients will given daily therapy for 8 weeks and then shifted to weekly therapy for the next 8 weeks. In group II, patients will be given LT4 once a week for 8 weeks and then switched to daily therapy for the next 8 weeks.

Inclusion Criteria:

1. All patients will be bio-chemically euthyroid on stable doses of LT4 for at least 3 months before recruitment into the study.

2. AGE GROUP: 25 - 55 years
3. Both males and females but in a fixed proportion of 1:9
4. Purely voluntary participation

Exclusion Criteria:

1. Population not under euthyroid conditions.
2. Pregnant women and Postpartum females
3. Population with comorbidities like IHD, DM, CAD, immunodeficiency state, chronic illness.
4. BMI > 30 kg/m²
5. Population > 60 years
6. Secondary and Tertiary Hypothyroidism

Ethical considerations

1. Transparency on goals and methods of experiment to be shared with patient
2. No additional cost to participating patients
3. Participants' information will be processed in confidence

Results

1. TFT ((euthyroid level) (0.5-4.0 mU/L)
2. quality of life (QoL) with SF-36
3. Hyperthyroidism symptom scale (HSS) score will be compared in each group at 0, 8, and 16 weeks.

Conclusion

Demonstrate that a weekly dose of levothyroxine is sufficient to manage hypothyroidism and show improved TFT, QoL (using SF-36 as a generic measure) and HSS.

#1701 - Abstract

GESTATIONAL DIABETES IN A PORTUGUESE HOSPITAL CENTRE IN 2017

Giovana Clare Sousa Ennis, Diana Pinho Santos, Cristina Andrade, Adelino Carragoso, Isabel Torres, António Correia
Tondela-Viseu Hospital Centre, Viseu, Portugal

Background

Gestational diabetes mellitus (GDM) is prevalent and is associated with a high risk of perinatal morbidity and mortality.

Methods

A retrospective study was performed, based on medical records of women attending gestational diabetes appointments in a Portuguese hospital centre with childbirth in 2017, compared to the national data.

Results

A total of 185 pregnant women with GDM were included, with ages ranging from 16 to 44 (average 33 years). 29.2% were over 35 years old, lower than national average (45%). 18.4% had a previous history of GDM. More GDM women were diagnosed in the first trimester (51.9%) than in the second trimester (42.2%); the

inverse occurred at national level (36.0% and 56% respectively). 1.1% were diagnosed only in the third trimester. Most women (58.4%) waited 3 to 6 weeks for their first appointment, and only 10.3% had their first appointment in less than 3 weeks. These results are inferior to national data (27.4% with first appointment in less than 3 weeks). More women achieved glycaemic control without pharmacological therapy than in the national whole (67% vs. 64.4%). Only 13.6% of women who needed pharmacological therapy were medicated with metformin, compared to 22% nationally, while 15.7% were treated with insulin and 3.7% with both, compared to 17.9% and 6.9% respectively in the national data. There was a similar rate of complications in our sample compared to the national whole: chronic hypertension 4.9% vs 5%; gestational hypertension 3.8 vs. 4%; pre-eclampsia 2.7% vs. 3%; hydramnios 0.5% vs. 1.9%; foetal death 0.5% vs. 0.37%. Average gestational age at birth was 38,57 weeks, and 88.1% of women carried their pregnancy to term. 4.9% of new-borns weighed more than 4,000 g, compared to the national average (3.8%), and 7.03% weighed less than 2,500 g (9.2% at national level). 83.8% of women were reclassified, more than nationally (65%). Most (92.9%) presented a normal glucose tolerance test, 2.6% were diagnosed with diabetes, 0.6% had a fasting glucose anomaly, and 3.9% displayed a lower glucose tolerance, differently from the national whole (91%, 1%, 2% and 6%, respectively).

Conclusion

The hospital centre compares very well with the whole national. However, it needs to shorten the time between the diagnosis of GDM and the first appointment, as studies have shown that appropriate management of gestational diabetes reduces complications such as macrosomia and pre-eclampsia.

#1714 - Abstract

EVALUATION OF THE INFERENCE OF PERIODONTAL DISEASE TREATMENT ON HEALTH UTILIZATION AND DISEASE PROGRESS IN DIABETIC PATIENTS

Chi-Jeng Hsieh¹, Wender Lin²

¹ Oriental Institute of Technology, New Taipei City, Taiwan

² Chang Jung Christian University, Tainan City, Taiwan

Background

Diabetes and periodontal disease (PD) are common diseases in health care services. Previous studies showed diabetic patients with periodontal treatment have lower blood glucose. Few studies explored health care expenditure associated with diabetes after periodontal treatment. Besides, few studies used total population database to explore this topic. This study aimed at evaluating the impact of scaling and PD treatment on the consequent health care expenditure associated with diabetic care.

Methods

We used NHI claims data to identify diabetic patients in 2014

and 2015. NHI claims data contained diagnostic codes, procedure codes such as examination, treatment, operation, medication, and expenditure information. Diabetic patients who had PD diagnosis in 2014 were assigned to three groups. The PD group was those who had PD treatment in 2014 or 2015. The scaling group was those who had scaling treatment and didn't have PD treatment in 2014 or 2015. The non-treatment group was those who did not have PD or scaling treatment utilization in 2014 and 2015. We used propensity score matching method to select the control cases. Health expenditure associated with diabetes was defined as ambulatory care and inpatient expenditure incurred by patients with diabetes in primary or secondary diagnostic codes. Multivariate regression was conducted to compare the differences of diabetes-associated health expenditure between these three groups. Logistic regression was used to evaluate the probability of dialysis treatment of these three groups in three years period.

Results

After propensity score matching, every groups had 4,460 cases. The diabetes-associated health expenditures of non-treatment, scaling and PD groups in 2015 were 37,627, 32,646 and 31,332 New Taiwan Dollar (1 U.S. D=30.46 NTD), respectively. After adjusted for demographic characteristics, Diabetes Complications Severity Index, and hospital region and level, the diabetes-associated health expenditures of scaling group was lower than those of non-treatment group by 4,914 NTD, and this expenditures of PD group was lower than those of non-treatment group by 6,245 NTD. The probability of dialysis treatment of these three groups in three years period had no significant difference.

Conclusion

We found that scaling and PD program could reduce the diabetes-associated health expenditure. The health authorities should consider to providing more incentives to increase scaling or PD treatment when physicians treat patients with diabetes.

#1730 - Abstract

ENDOCRINOPATHIES AND SYSTEMIC LUPUS ERYTHEMATOSUS

Wafa Baya, Imen Ben Hassine, Jihed Anoun, Fatma Ben Fredj Ismail, Monia Karmani, Amel Rezgui, Chedia Laouani Kechrid
Internal Medicine Department, Sahloul University Hospital, Sousse, Tunisia

Background

Systemic Lupus Erythematosus (SLE) is an autoimmune connective tissue pathology. Its association with an endocrinopathy is frequent. This endocrinopathy may be secondary to an autoimmune process or an adverse effect of corticosteroid therapy.

Methods

This is a descriptive retrospective study carried out in the Internal Medicine Department including lupus patients.

Results

We collected 21 out of 127 lupus patients (16.5%). The average age was 51.3 years old. The average duration of disease evolution was 11 years. Articular, cutaneous and hematological involvements were mostly observed. Our patients were treated with synthetic anti-malarials in all cases associated in some cases with corticosteroids, immunosuppressive therapy.

Dysthyroidism was the most common endocrinopathy. We found 11 cases of hypothyroidism and no case of hyperthyroidism. It was Hashimoto's thyroiditis in 4 cases. Hypothyroidism was discovered after one year of SLE evolution in one case.

Eight cases of diabetes were noted including 7 cases of cortisone-induced diabetes which occurred in less than one year.

Adrenal insufficiency was found in 4 patients. It was secondary to the corticosteroids abrupt stoppage in 3 cases and post-tuberculosis in 2 cases. Only one case of Schmidt syndrome was found.

Patients received substitution therapies and /or oral anti-diabetic drugs.

Conclusion

The association of an endocrinopathy with an SLE is not rare, in particular a hypothyroidism imposing its systematic screening.

#1732 - Case Report

A CASE OF HYPERPARATHYROIDISM

Ivo Castro, Adelaide Figueiredo, Maria Cristina Esteves

Hospital Distrital de Santarém, Santarém, Portugal

Introduction

Primary hyperparathyroidism is an uncommon disorder and occurs when the parathyroid hormone is secreted excessively, resulting in high levels of calcium.

Case description

We report a case of an 80-year-old woman with a history of hypertension and type 2 diabetes mellitus that was admitted to the hospital with loss of appetite, nausea, polydipsia, polyuria, confusion, muscle weakness and hypercalcemia (16 mg/dL). A more completed analytical serum study was conducted and revealed severe vitamin D deficiency (8.80 ng/mL) and elevated parathyroid hormone (736.80 pg/mL). During the time that patient was hospitalized we did several reevaluations of calcium level and perform image studies, specifically neck and thyroid ultrasonography and Technetium-99m scintigraphy. The results were compatible with the presence of parathyroid tissue hyperfunctional projected to the left lobe of the thyroid gland. While the surgery was programmed the patient need to be hospitalized twice to control symptoms due to the high levels of calcium that was corrected with diuretics and bisphosphonates. After the parathyroidectomy performed, the histology result of hyperplasia of the left superior parathyroid was established and the levels of calcium and parathormone return to normal ranges.

Discussion

This is a rare case of severe hypercalcemia duo to primary hyperparathyroidism.

#1794 - Case Report

YOU ARE JUST ANXIOUS...

Carolina Reis Ferreira, Cláudia Costa, Dora Gomes, Inês Batista Mesquita, José Borges Martins, António Correia

Centro Hospitalar Tondela-Viseu, Viseu, Portugal

Introduction

The prevalence of hyperthyroidism ranges from 0.2% to 1.3% in iodine-sufficient countries. The prevalence of thyroid disease in Portugal is high. Graves' disease is the most common cause of hyperthyroidism, mostly in young women. Symptoms of this condition are anxiety, insomnia, emotional lability, muscle weakness, tremor, palpitations, heat intolerance, increased perspiration and weight loss, despite a normal or increased appetite. Some patient's diseases can lead to a misdiagnosis, namely psychiatric or neurologic conditions. It is also known that some stress life-events can trigger Grave's disease development.

Case description

A 34-year-old woman, with major depression, under mirtazapine and diazepam, visited her primary care physician because of palpitations, chest pain episodes, easy fatigue, insomnia, and tremor of the upper limbs, for several months. She also presented weight loss (25 kg in 10 months) and increased number of daily dejections. The clinical condition was presumed to be an exacerbation of her depression, so the psychiatric medication was adjusted. There was no improvement; the patient remained anxious, with upper limb tremor and complained about dysphagia. Her blood pressure was 130/95mmHg and her heart-rate was 119bpm. On physical examination a goiter was noticed. Because of this, she was sent to an internal medicine outpatient clinic. Analytic study: TSH=0.005µIU/mL (normal range 0.350-5.500µIU/mL) and free T4>100ng/dL (normal range 0.90-1.80ng/dL); anti-thyroglobulin (AT) >4000U/mL (positive if >100U/mL), anti-thyroid peroxidase (TPO)=204U/mL (positive if >60U/mL) and anti-TSH receptor antibody (TRABs) >30IU/L (positive if >1.5IU/L). Thyroid ultrasonography: exuberantly enlarged thyroid (right lobe 18x24x65 and left lobe 15x16x57) with heterogeneous echo-structure, without nodules. At this point she was started on tiamazol 5mg 3 times daily and propranolol 20mg 3 times daily with adjustments in each clinical evaluation. In her last visit, the patient was not euthyroid yet.

Discussion

This case report illustrates the delay in the diagnosis of hyperthyroidism that may occur when the patient presents co-morbidities with similar symptoms. The patient remained hyperthyroid for almost then months, because her clinical picture was thought to be a depression worsening with anxiety.

#1798 - Medical Image

MADELUNG'S DISEASE

Maria Inês Santos, Marisa Brochado, Helena Vieira Dias
Hospital Distrital de Santarém, Santarém, Portugal

Clinical summary

Madelung's disease is a rare disorder of the lipid metabolism, of unknown cause, characterized by massive deposits of fatty tumors (lipoma) located symmetrically around the neck, and on

the shoulders, upper arms and upper trunk. These abnormal fat deposits may grow rapidly over the course of months or more slowly over a period of years. The rest of the body may be lean in contrast to the affected parts. The fatty deposits do not indicate malignancy but may cause deformities, loss of mobility and pain due to peripheral nerve compression (peripheral neuropathy). Prevalence is highest in men, of Mediterranean ancestry, with ages between 30 to 70 years old and 60 to 90% of the cases have an history of alcohol abuse.

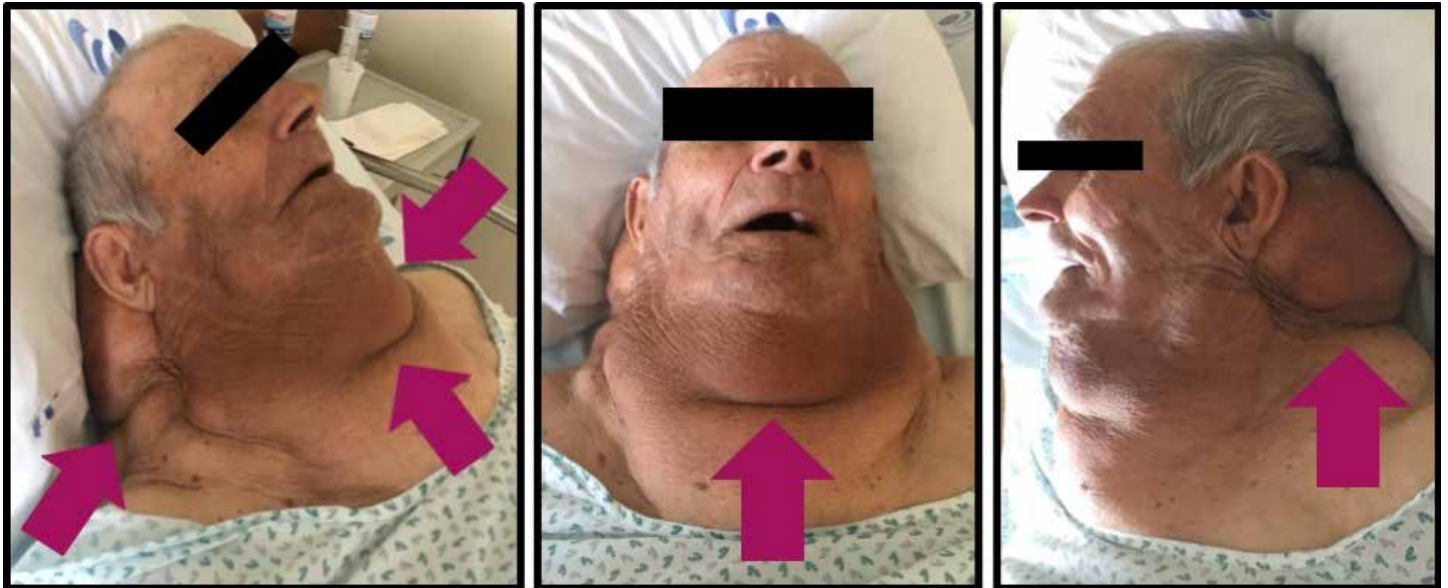

Figure #1798. Madelung's disease - 79 year-old male with long term developing lipomas around the neck and shoulders.

#1844 - Case Report

HYPERFERRITINEMIA: DO WE ALWAYS GET THE DIAGNOSIS?

Carlos Báguena Pérez-Crespo, Francisco Javier Hernández Felices, Gabriel Puche Palao, María Del Carmen Hernández Murciano, Ignacio Iniesta-Pino Alcázar, Elena Del Carmen Martínez Cánovas, Vicente David De La Rosa Valero, Ana Martín Cascón, Lia Ferraro, Mónica Martínez Martínez
Hospital General Universitario Reina Sofía, Murcia, Spain

Introduction

Patients with elevated levels of ferritin are a diagnostic problem, given that hyperferritinemia, in addition to iron overload, can be the presence of a variety of disease such as anemia, liver diseases or inflammatory syndromes.

Case description

A 61-year-old man with metabolic syndrome (hypertension, diabetes and dyslipidemia together with obesity) remitted from Endocrinology due to elevated ferritin levels. The patient was totally asymptomatic, and in the anamnesis he denied alcohol consumption as well as other toxins. The analyte only preserved elevated levels of ferritin (821) with normal levels of transferrin. Hepatic, renal and hemogram function were normal, and markers of inflammation were

negative. An abdominal ultrasound showed a completely normal liver, and a genetic test of hemochromatosis was performed, which was negative for the HFE C282Y gene, so finally it was diagnosed with hyperferritinemia secondary to metabolic syndrome.

Discussion

For years the association between metabolic syndrome and hyperferritinemia has been described as the main cause of it in the western world. It is a diagnosis of discarding, to which it is necessary to arrive after having rejected the rest of possible secondary causes.

#1850 - Case Report

DIAGNOSTIC CHALLENGES IN THYROTOTOXIC PERIODIC PARALYSIS: A CASE REPORT

Lazaros Sideras, Vasiliki Tsoutsouli, Georgios Christantonou, Christina Chrysanthi Theocharidou, Dimitrios Kampranis, Armonia Chatzigeorgiou, Konstantinos Gkogkos
Internal Medicine Clinic of G.Papanikolaou General Hospital, Thessaloniki, Greece

Introduction

Thyrototoxic Periodic Paralysis (TPP) is a rare endocrine disorder

occurring predominantly in men of Asian origin but it has also been reported increasingly in western countries mainly due to immigration. TPP is a potentially life-threatening complication of hyperthyroidism, characterized by muscle paralysis and hypokalemia resulted from massive intracellular shift of potassium. We describe the following case to call attention to an important cause of acute paralysis of endocrine origin.

Case description

A 42-year-old Iraqi female immigrant was admitted from a rural hospital to the emergency neurology department as potential acute stroke. The patient complained of sudden onset weakness of proximal and distant limb muscles manifested as complete inability to walk. Brain Computed Tomography scan was normal. The patient had history of hyperthyroidism treated with carbimazole 10mg and reported weight loss, palpitations, tremors and heat intolerance. Neurological examination revealed diminished deep tendon reflexes with decreased muscle power in both lower limbs, no sensory deficit and intact cranial nerves. Systemic examination was normal. Laboratory studies revealed hypokalemia ($K^+=2,9$ mmol/L) with low urinary potassium excretion and electrocardiographic alternations. The patient was admitted to the neurology department and further evaluation revealed symmetrical low amplitude electrical compound muscle action potential on electromyography. Immediate therapy with potassium chloride supplementation improved the symptoms within 4 hours, without rebound hyperkalemia. Thyroid function tests revealed $TSH < 0,001$ U/mL with $FT3$ 8,64 pg/mL and $FT4$ 3,04 ng/dL. Thyroid ultrasound was consistent with Graves' disease. Treatment was initiated with carbimazole 40mg and propranolol 80 mg. The patient was discharged after 8 days with complete recovery of muscle strength.

Discussion

It is important to consider the diagnosis of TPP in patients of Asian origin presenting with acute paralysis. The inability to evaluate thyroid function on the emergency department led to a misdiagnosis of stroke. Thyroid function should be tested on a routine basis. Emergency therapy with potassium chloride supplements, nonselective β -blockers and antithyroid drugs can prevent life threatening complications.

#1852 - Case Report

CONFUSED? TAKE A LITTLE SODIUM

Joana Rita Lopes, Maurício Peixoto, Rui Files Flores, Sofia Caridade, Guilherme Alpedrinha
Hospital of Braga, Braga, Portugal

Introduction

Hyponatremia may manifest with neurological symptoms, such as the acute confusional state. It may be associated with hypovolemia, euvolemia or hypervolemia, so a good clinical history and physical examination are needed to make this distinction, since the etiology of hyponatremia varies according to the category.

Case description

A 57-year-old female, with a history of hyperthyroidism due to multinodular goiter and dyslipidemia, underwent total thyroidectomy and was discharged one week later with 100 mcg of levothyroxine, calcium, and calcitriol. She presented dysphonia as the only complication which was treated with corticotherapy during hospitalization still.

She came to the ER 3 days after discharging due to confusion and incoherent speech with no other symptoms. The physical examination was normal except for high blood pressure and neurological examination was normal except for temporal disorientation and occasional incoherent speech. She was submitted to brain CT, brain MRI, electroencephalography and lumbar puncture that excluded central nervous system disease. Analytically with hyponatremia (124 mEq) and elevated TSH (7.7 mU/L). She was admitted to the Internal Medicine service to study the presented confusional state associated with hyponatremia. During hospitalization tests revealed normal free T4, elevated TSH (peak 13.7 mU/L), normal aldosterone, cortisol and ACTH levels, decreased serum osmolarity. Urinary sodium was 154 mmol/L. Hyponatremia was progressively corrected with saline solution during hospitalization associated with decreasing of the number and duration of confusional episodes. She was discharged with sustained and symptom-free eunatremia, medicated with levothyroxine 137 mcg daily.

Discussion

In the presented case, the patient has an altered state of consciousness due to acute hyponatremia. Thus, it was necessary to find the cause for this hyponatremia. Since the metabolic study was normal, apart from increased TSH, we can contextualize hyponatremia in a post-surgical setting accompanied, eventually, by hypothyroidism.

#1871 - Abstract

POLYMORPHISM ID OF ANGIOTENSIN CONVERTING ENZYME, ARTERIAL HYPERTENSION AND LOSS OF BONE MASS

Joana Ferreira^{1,2}, Alda Pereira Da Silva¹, Cristina Monteiro³, Ana Paula Barbosa^{4,5}, Mário Rui Mascarenhas^{4,5}, Manuel Bicho^{1,2}

¹ ISAMB, Genetic Laboratory, FMUL, Lisboa, Portugal

² Institute for Scientific Research Bento Rocha Cabral, Lisboa, Portugal

³ CIPER, FMH-UL, Lisboa, Portugal

⁴ Service of Endocrinology, Diabetes and Metabolism, H.S.Maria - CHLN, Lisboa, Portugal

⁵ Endocrinology, Diabetes and Metabolism, Lisbon Clinic, Lda, Lisboa, Portugal

Background

The association of bone mass loss and hypertension is a controversial subject. There are few studies on the influence of the renin angiotensin system on blood pressure regulation in osteoporosis. The objective of the study was to study the

association of the ACE functional polymorphism of the angiotensin converting enzyme (ACE) and its serum activity with arterial hypertension (HBP) in individuals with normal or reduced bone mineral density (osteopenia and osteoporosis).

Methods

A sample of 650 individuals both genders (90.6% Fem) was studied, with a mean age of 55.2±13.3 years old and BMI = 28.5 ± 4.9 kg/m². Of these, 218 were hypertensive according to the guidelines (www.sphta.org.pt/). Bone mineral density (BMD-g/cm²) was assessed by DEXA (DualEnergy X-ray Absorptiometry) at the lumbar spine, femoral neck, and distal end of the radius, with 400 individuals with reduced BMD (osteoporosis or osteopenia) and 250 with normal BMD. The enzymatic activity of ACE (IU / ml) was determined in serum by spectrophotometry in 389 individuals (15.63±10.36). The genetic polymorphism ACE I/D by PCR in 562 individuals. The three possible genotypes for ECA I/D (II, ID and DD), the dominant model (II + ID vs DD) and the recessive model (II vs ID + DD) were considered. The program SPSS 24.0 for Windows was used. Statistical significance was considered for p < 0.05.

Results

There was an increase in the frequency of genotype II and ID in patients with reduced BMD and hypertension. Individuals with reduced BMD and I allele (II and ID) have a risk of 1,885-fold for the development of hypertension in relation to DD, OR = 1.885; 95% CI [1.177-3.018] p = 0.008. There was a decrease in the enzymatic activity of ACE in individuals with reduced BMD and hypertension, median [min-max] (n): without HBP - 14.8 [2.1-64.3] (188); with HBP -11.1 [3.7-47.7] (70), p = 0.006. The ACE polymorphism was related to its enzymatic activity, presenting the lowest activity, the genotypes II and ID (median [min-max] (n)) regardless of BMD: normal BMD ECA II vs ID vs DD - 6.8 [4.4-12.6] (8) vs 9.9 [1.1-32.6] (57) vs 12.1 [1.5-72.8] (39) p = 0.002; reduced BMD ECA II vs ID vs DD - 8.5 [4.6-47.7] (25) vs 13.2 [3.7-42.7] (73) vs 17.3 [3.7-64.3] (99) p = 0.005.

Conclusion

In individuals with reduced bone mass, the ACE I/D polymorphism and the lower activity of this enzyme may confer susceptibility to hypertension. Future studies may assess the association of BMD with antihypertensive therapy based on ACE inhibitors.

#1893 - Case Report

WHEN A RARE DIAGNOSIS IS IN FRONT OF YOUR EYES

Andreia Vanessa Novais Teixeira^{1,2}, Mariana Matos Pinto¹, Paulo Maia¹, Fernando Rua¹

¹ Centro Hospitalar Universitário do Porto, Porto, Portugal

² Hospital Santa Luzia de Elvas, Elvas, Portugal

Introduction

Altered state of consciousness is a common cause of medical emergency and the most frequent etiologies are cardio and

cerebrovascular diseases. Coma induced by metabolic alterations must be considered in differential diagnosis.

Case description

59-year-old man, found unconscious at home and had known pathological history of schizophrenia, chronic respiratory disease, gastritis, smoking and obesity.

At the arrival of the emergency team at his home, the patient presented a Glasgow score of 3/15, myotic, isoreactive and isochoric pupils, bradipneic, hypotensive and hypoxic. Patient needed orotracheal intubation and presented great amount of secretions and enteric content that was aspirated. His relatives referred labial commissure deviation the day before.

At the emergency room was mechanically ventilated with FiO₂ 100% with saturation of 91%, hypotensive, sinus bradycardia, sedated (RASS-5), hypothermic, and presented severe edemas and scaly skin. The more relevant in the complementary diagnosis exams included: arterial gasometry with respiratory acidosis and hyperlactacidemia (4.1mmol/L); CT CE normal; CT thorax: bilateral pleural effusion with chronicity signs, without pericardial effusion; Echocardiogram: right heart and inferior vena cava dilatation, and severe biventricular systolic dysfunction; pleural fluid thoracentesis compatible with exudative effusion.

After excluding frequent causes of coma compatible with clinical findings such as stroke, alterations of acid-base, myocardial infarction, the most probable diagnosis hypothesis was myxedema coma. The myxedema coma score was 120 points (> 60 points its very suggestive of the diagnosis). Analytical study was completed with thyroidal function: TSH 87,9 uIU/mL (N 0,3-3,18); T4L < 0,039 ng/dL (N 1,01-1,65); T3L 0,43 pg/mL (N 2,66-4,33). The cause of the hypothyroidism was Hashimoto's disease (Antiperoxidase antibodies: 154,9 UI/mL (> 34 positive), and the trigger factor was respiratory infection.

The patient started treatment with levothyroxine and hydrocortisone with clinical and analytical favorable evolution.

Discussion

Myxedema coma is a rare disorder and if not promptly diagnosed and treated, the mortality rate can be more than 50%, and even with immediate recognition and medical intervention the mortality rate could be as high as 25%. In this case report the medical history and clinical findings were primordial to the successful diagnosis and treatment of myxedema coma.

#1897 - Case Report

MONOFOCAL PAGET'S DISEASE OF BONE IN THE HIP: A LONG JOURNEY TO DIAGNOSIS

Lídia Caley, Telma Elias, Cristina Lopes, Fátima Pimenta
Hospital Center of Médio Tejo, Abrantes, Portugal

Introduction

Paget's disease of bone is a metabolic disorder, in which there is an increased and disorganized bone remodelling. Although radiological imaging can be straightforward for diagnostic,

monofocal involvement of a bone may raise doubts that sometimes require invasive procedures, such as bone biopsy.

Case description

We present the case of a 78-year-old Caucasian woman who was admitted to the emergency department for falling, which resulted in a severe pain in her right hip and motor impairment of the limb. She referred having hip pain for 3 months, along with episodes of diarrhea and weight loss.

On examination, she was underweight, presented bilateral protruding eyeballs and bilateral foot drop. She complained with pain on the right hip with mobilization, but did not present any bruising or swelling of the limb.

Laboratory tests revealed normocytic normochromic anemia. Hip X-ray showed bone resorption in the head of the femur and the acetabulum. CT revealed an enhanced image of the femoral head, with bone destruction and lesion of soft tissue, involving the surface of the acetabulum. MRI evidenced the presence of bulky liquid collection in the trochanteric region of the femur, with suspicious of an infection or inflammatory process. PET-scan showed a musculoskeletal mass suggestive of malignancy. Due to the uncertainty of the diagnosis, it was decided to perform a biopsy. The result excluded malignancy and was consistent with non-specific inflammation.

All these findings, along with subsequent elevation of alkaline phosphatase and the presence of elevated urinary hydroxyprolin, established the diagnosis of Paget's Disease of Bone as a final diagnostic. Treatment with zoledronic acid resulted in a clinical and laboratory improvement.

Discussion

The fact that the patient fell, had chronic diarrhea and weight loss, along with the presence of a focal x-ray image of bone rarefaction of the hip, made considerate several diagnostic hypotheses. This led to the patient being observed by several specialists who took time to execute many exams performed such as imaging, ultrasound, endoscopy and laboratory tests that did not clarify the case. The bone biopsy was essential to exclude malignancy or infectious etiology, allowing to establish of monofocal Paget's disease of bone as final diagnostic.

In the presented case the fact that there was a previous trauma and the suspicion of neoplasm lesion, as a result of some tests, made the journey to diagnosis difficult and lengthy.

#1910 - Case Report

MULTIPLE ENDOCRINE NEOPLASIA TYPE 1 MASQUERADING AS REFRACTORY EPILEPSY: A CASE REPORT

Vasiliki Tsoutsouli, Lazaros Sideras, Dimos Foutsitsakis, Georgios Papadimos, Georgios Christantoniou, Dimitrios Kazineris, Zacharo Sachla

Internal Medicine Clinic of G.Papanikolaou General Hospital, Thessaloniki, Greece

Introduction

Multiple Endocrine Neoplasia type 1 (MEN1) is a rare endocrine tumor syndrome characterized by tumors of the parathyroid glands, endocrine gastroenteropancreatic tract and anterior pituitary. Hypercalcaemia due to parathyroid tumors is usually the first manifestation. Pancreatic islet tumors occur less frequently, among them gastrinomas and insulinomas are the most prevalent. We report a sporadic case of insulinoma in MEN1 presented as refractory epilepsy.

Case description

A 23 year old male patient under antiepileptic medication was admitted to the emergency department for refractory epilepsy. Electroencephalography revealed temporal lobe epileptiform discharges. Following meticulous observation recurrent hypoglycemia was detected during the seizures. Laboratory investigation revealed hypoglycemia and hypercalcemia. Fasting C-peptide levels were inappropriately normal. Although serum glucose reached remarkably low levels, the patient did not manifest any symptoms of hypoglycemia, other than, eventually, seizures. Thus, there was a strong suspicion of multiple endocrinopathy. Abdominal magnetic resonance imaging (MRI) showed rapidly enhancing tumor in the pancreatic body. Somatostatin receptor scintigraphy results were normal. Cervical ultrasound and sestamibi parathyroid scintigraphy revealed a single parathyroid adenoma. The pituitary gland appeared normal in MRI. Consequently, the diagnosis of MEN-1 with pancreatic insulinoma and primary hyperparathyroidism was established. The patient was immediately referred to a specialized surgical department for surgical resection of the insulinoma. Insulin and glucose levels remained normal for 6 months of follow-up postoperatively. He reported no episodes of seizures while the antiepileptic medication was discontinued. The patient is under surveillance for the parathyroid adenoma in a specialized oncology department.

Discussion

MEN1 can pose a diagnostic challenge even to the experienced clinician. Misdiagnosis of insulinoma as psychiatric illness or epilepsy is common and might lead to disastrous consequences.

#1915 - Case Report

A NOT SO SUBCLINICAL CASE OF SUBCLINICAL HYPOTHYROIDISM

Isabel Vilas-Boas¹, Marta Vilaça², Elaine Aires², Denise Magalhães², Helena Greenfield², Filipe Teixeira Andrade²

¹ Instituto Português de Oncologia do Porto, Porto, Portugal

² Hospital Pedro Hispano, Matosinhos, Portugal

Introduction

Hypothyroidism is a prevalent condition and is an important cause of pericardial effusion. More rarely, it may also be associated with large-volume pericardial effusions and pericarditis. Although

controversial, subclinical hypothyroidism (SH) is also reported to be associated with some of the manifestations observed in hypothyroidism, such as increased cardiovascular risk and there are also reported cases of pericardial effusion in patients with SH.

Case description

The authors present the case of a 67-year-old man who was admitted to the emergency department with complaints of pleuritic chest pain, fever, anorexia and dyspnea. Chemistry laboratory tests revealed increased inflammatory parameters and hypoxemic respiratory failure. An electrocardiogram revealed sinus tachycardia and an ST elevation of 1-2mm ST in the inferior leads. Thoracic computed tomography and transthoracic echocardiography showed a large pericardial effusion (28 mm). A diagnosis of acute pericarditis with associated pleural effusion was assumed and ibuprofen and colchicine were started. Due to hemodynamic instability, a new echocardiogram was performed and showed a partial collapse of the right atrium and ventricle. Pericardiocentesis was performed with a 70 mL outlet and subsequent clinical improvement. The effusion was an exudate with polymorphonuclear cell predominance. Microbiological studies were negative for bacteria, viruses, fungi and mycobacteria, and there was no evidence of malignant cells. The etiological study performed revealed subclinical hypothyroidism (TSH of 15.7 uIU/mL and free T4 of 0.92 ng/dL) and positivity for anti-TPO and anti-thyroglobulin antibodies. Thyroid echography was compatible with thyroiditis and Hashimoto's thyroiditis was diagnosed. The patient started thyroid hormone supplementation with 50 ug levothyroxine and, to date, 4 months after the onset of symptoms, there was no recurrence of the condition. Despite normal T4 and T3 levels, it was assumed that the subclinical hypothyroidism was the cause of the pericardial effusion and pericarditis in this patient.

Discussion

The effects of subclinical hypothyroidism are variable and depend on the degree of TSH elevation and on the duration of hypothyroidism. This case intends to demonstrate that, although defined as "subclinical", SH may be a cause of large pericardial effusions and that it is important to initiate levothyroxine supplementation to control the endocrine dysfunction.

#1936 - Abstract

NUTRITIONAL STATUS AND CLINICAL OUTCOME

Ana Filipa Batista, Joana Antunes, Filipa Domingues, Margarida Gaudêncio, Sónia Campelo Pereira, Amélia Pereira
Hospital Distrital da Figueira da Foz, Coimbra, Portugal

Background

In the setting of the acute hospital care, malnutrition or the risk of malnutrition are very frequent, with an estimate incidence of up to 60%. Although they are established independent predictors of prolonged hospitalization and increased mortality, the practice of individualized nutritional assessment is rarely if ever

addressed. We conducted a study to assess the prevalence of malnutrition and nutritional risk at hospital admission and its association with clinical outcome.

Methods

This is a prospective study of hospitalized patients evaluated within the first 48 hours of admission, by NRS (Nutritional Risk Screening), MNA (Mini Nutritional Assessment) and Charlson Comorbidity Index questionnaires. The variables recorded included demographic, anthropometric, hospitalization and clinical data. Patients were separated based on their homogeneous diagnostic groups and subgroups of severity and mortality. We excluded patients receiving enteric or parenteral feeding.

Results

Out of 403 patients hospitalized during the study period (January to April of 2018), a total of 121 patients were included (30%); 52% were women, with a mean age of 76.91±13.03 years. The mean Charlson Comorbidity Index was 5.97±2.36. According to mean body mass index (BMI) classification for people aged 65 years and older, 17.9% of the patients were underweight. The MNA classified 21% of the patients as malnourished and 57% at risk of malnutrition. The patients aged over 85 years were at most risk of malnutrition (NRS≥3) and had the lowest scores in the MNA. There were no differences between BMI and nutritional risk, but there was a positive correlation between the first and better nutritional status. The main reason for hospitalization was infection (42%). The length of stay, with a median of 10.96 days, had no significant difference between the estimate time determined by the severity and mortality rates in the corresponding diagnostic group and did not correlate either with the risk of malnutrition or the nutritional status. Among the patients that died, 60% were malnourished.

Conclusion

In our study, a combined percentage of 77.68% of patients were either malnourished or at risk of malnutrition. Even though the nutritional status did not influence the length of stay, it was associated with a higher mortality rate. Malnutrition and poor food intake, unlike age or comorbidities, are both modifiable risk factors, so it even more accentuates the importance of implementing a nutrition care process.

#1979 - Case Report

PLASMA EXCHANGE IN THYROID STORM – A CASE OF AGRANULOCYTOSIS

Leonor Boavida¹, Joana Carvalho¹, Afonso Santos¹, Fabiana Pimentel¹, Micaela Caixeiro¹, João Mendes¹, Isabel Serra¹, Teresa Brandão¹, Paulo Freitas²

¹ Professor Doutor Fernando Fonseca Hospital, Lisbon, Portugal

² Professor Doutor Fernando Fonseca Hospital, Lisboa, Portugal

Introduction

Hyperthyroidism, in particular, Graves' disease, can be associated with various hematologic abnormalities. Agranulocytosis

contraindicates the use of thionamides, therefore, in a severe presentation, as in thyroid storm, plasma exchange therapy can become the only therapeutic option.

Case description

A 45-year-old woman with past history of Graves' Disease diagnosed at 14 treated with anti-thyroid drugs with remission, presented with gradual onset of asthenia, weight loss and high pyrexia over 3 months. On physical examination she was febrile, tachycardic, with thyroid gland enlargement. Laboratory findings included a high free triiodothyronine (FT3) level of 22 pg/dL (2.3–4.4 pg/dL), free thyroxine (FT4) level over 7.7 ng/dL (0.9–1.7 ng/dL), and a low thyroid stimulation hormone (TSH) concentration of less than 0.005 μ IU/mL (0.27–4.2.0 μ IU/mL, with serum TRAb positivity at a concentration of 36.5 IU/L (under 1.75 IU/L). In addition, complete blood count showed pancytopenia, in particular leukopenia of $0.7 \times 10^3/\mu$ L ($4.0\text{--}11.0 \times 10^3/\mu$ L). The patient was diagnosed with a thyroid storm associated with Graves' Disease recurrence, with a Burch-Wartofsky score of 45 out of 140, and severe hematologic abnormalities contraindicating thionamides given their potential of leukopenia worsening. She was admitted to the Intensive Care Unit and therapeutic plasma exchange was started. The patient underwent four exchanges in addition to steroids, propranolol and cholestyramine with partial correction of thyroid function but marked improvement in blood cell counts and neutrophil count recuperation. Thiamazole and potassium iodide-iodine were then started with thyroid hormones' normalization and without further hematologic deterioration, thus enabling radical surgical treatment after 2 weeks. The patient is currently asymptomatic.

Discussion

Thyroid storm has an excessively high mortality rate of 30% making its prompt recognition and treatment of utmost importance. Plasma exchange therapy is a relatively safe option that can and should be used, especially if conventional medical treatments are ineffective or contraindicated as is the case with agranulocytosis. Rapid blood cell count improvement with plasma exchange therapy corroborates the potential humoral autoimmune mechanisms behind hematologic abnormalities associated with hyperthyroidism, particularly in Graves' Disease.

#1982 - Case Report

SEVERE HYPOCALCEMIA INDUCED BY ZOLEDRONIC ACID - CASE REPORT

Sofia Calaça, Iolanda Oliveira, Francisco Rebocho, Diogo Canudo Diogo Canudo, Diana Coutinho
Hospital Espírito Santo de Évora, Evora, Portugal

Introduction

Intravenous bisphosphonate are usually safe and are used in the management of metastatic and metabolic bone diseases, hypocalcemia cancer-related, osteoporosis and Paget's bone disease.

Although infrequently, hypocalcemia may occur and is usually asymptomatic, however could lead if untreated to life-threatening situations.

Case description

A 79-year-old male, still employed came to the emergency department with a 3 week course of fatigue, loss of appetite, lethargy, gait difficulty and desorientation for a few hours. One week before the onset of symptoms he was treated with zoledronic acid 5 mg/100 ml due to Paget's bone disease.

At hospital admission the patient presented with altered level of consciousness and progressive mental deterioration. Chvostek's and Trousseau's signs were not tested. Laboratory tests revealed a serum creatinine of 2.39 mg/dl (for a baseline of 0.68 mg/dl) and an ionized calcium of 0.54 mmol/L. On electrocardiography, corrected QT interval was prolonged (521 msec). Later, serum 25-hydroxyvitamin D showed immeasurable levels and parathyroid hormone level was 270 pmol/L. Three months earlier he presented a serum calcium value at the lower limit of normality and a PTH within the normal range. Vitamin D was not measured. The patient was diagnosed with severe hypocalcemia induced by zoledronic acid, severe vitamin D deficiency and secondary hyperparathyroidism.

In spite of vigorous and continuous supplying of intravenous and oral calcium and vitamin D, ionized calcium concentration had a very slow improvement with a level of 0.95 mmol/L in 7 weeks after hospital admission. The patient presented a slow and almost insignificant clinical improvement with several nosocomial infectious interurrences, namely pneumonia (in the context of vomit aspiration), urinary infection and clostridium difficile-induced diarrhea.

Unfortunately, he never recovered his prior status and was discharged after 49 days to a convalescence unit with significant neurological compromise and loss of autonomy.

Discussion

This case emphasizes the importance of evaluating renal dysfunction, vitamin D, calcium and PTH levels, prior bisphosphonate treatment. Although vitamin D and calcium supply it's not mandatory it's highly recommended.

#1986 - Case Report

EMPTY SELLA SYNDROME- A RARE CAUSE OF HYPONATREMIA

Maria Inês Ribeiro, Melanie Ferreira
Hospital Garcia de Orta, Almada, Portugal

Introduction

Hyponatremia is a frequent diagnosis found in the internal medicine ward. Determining the etiology of hyponatremia is fundamental to guide treatment and prognosis. The differential diagnosis is wide-ranging, often complicated by overlapping causes of hyponatremia. Secondary hyperthyroidism due to

hypopituitarism is a rare cause of hyponatremia. Empty sella syndrome is a rare cause of hypopituitarism. It is a radiological finding characterized by enlargement of sella turcica, that is not entirely filled with pituitary tissue, but with cerebrospinal fluid. It can be diagnosed by Magnetic Resonance Imaging (MRI) or computed tomography. Treatment is warranted in the presence of hormone deficiency and directed to affected hormones.

Case description

We present a case of a 59 years old woman, with a known history of arterial hypertension and ischemic cardiomyopathy, submitted to coronary artery bypass 1 month before, was admitted with new onset of altered mental status. On evaluation, she had a symptomatic hypotonic hyponatremia, with serum sodium levels 114 mmol/L, serum osmolarity 233 mOsm/L (excluded pseudohyponatremia), and right-side pleural effusion. Initially, we attributed the hyponatremia to a hypervolemic status due to recent cardiac surgery. However, with the maintenance of severe hyponatremia, even with water restriction and diuretic therapy, further investigation was ordered. It revealed a normal thyroid stimulating hormone, low total thyroxine and low free triiodothyronine, suggesting secondary hypothyroidism. Other hormonal analysis and the synacthen test were normal. Finally, an MRI was performed, which was compatible with empty sella. Hormone replacement therapy with levothyroxine was initiated, with resolution of hyponatremia and symptoms.

Discussion

Empty sella after coronary artery bypass has been reported in the literature previously. It is a rare complication, but can be fatal or cause permanent neurological or endocrine damage in absence of proper treatment. The physician should be aware of hyponatremia, altered mental status or visual changes after cardiac surgery as presenting features. Early diagnosis and treatment minimize morbidity and mortality from this complication.

#2013 - Case Report

HYPERGLYCEMIC HYPEROSMOLAR SYNDROME WITH NEUROLOGICAL MANIFESTATIONS - INAUGURAL EVENT OF DIABETES MELLITUS TYPE 2

Tatiana Gonçalves, Jorge Leitão, Lélita Santos, Armando Carvalho
Internal Medicine Department A - Centro Hospitalar e Universitário de Coimbra, Coimbra, Portugal

Introduction

Hyperglycemic Hyperosmolar Syndrome (HHS) is a entity with high mortality and exact incidence is not known. Most cases occur in patients diagnosed with Type 2 Diabetes Mellitus, with their initial presentation being 30-40%. HHS can be associated with neurological involvement ranging from seizures, involuntary movements to irreversible focal neurological deficits.

Case description

We report the case of a 78-year-old patient, with no relevant personal history. He entered the emergency department of the hospital, ventilated and intubated, with a history of seizures and myoclonus on the left with 1 day of evolution. Patient was dehydrated and the study showed high glycemia (900 mg/dl), hyperosmolarity, acute renal failure and hyperkalemia. Cranioencephalic Computed Tomography (CT-EC) was normal. Electroencephalogram (EEG) was compatible with metabolic encephalopathy and lumbar puncture (PL) presented hyperglycorrhachia. It was concluded that SHH was associated with urinary tract infection by *Klebsiella pneumoniae*. It progressed initially with neurological improvement and glycemic profile, but on the 5th day of hospitalization, the myoclonus was restored to the left and the EEG was compatible with the right focal stage, interpreted as hemichorea-hemiballismu. She was treated with fluid replacement, targeted antibiotics and anticonvulsants. There was progressive degradation of the state of consciousness, without neurological recovery and evolution to total dependence.

Discussion

This case reports HHS with neurological sequelae. Hemichorea-hemiballismus is a rare but dramatic complication of nonketotic hyperglycemia in patients with uncontrolled diabetes. The authors believe that this case report is relevant because of its rarity and the exuberance of the clinical presentation.

#2014 - Case Report

UNDERCOVER HYPOTHYROIDISM

Eduarda Carias, Roberto Marques, Rosario Blanco Saez, Rafaela Pereira, André Fragoso, Ana Paula Silva, Pedro Leão Neves
Centro Hospitalar Universitário do Algarve - Hospital de Faro, Faro, Portugal

Introduction

Some causes of nephrotic syndrome and intrinsic kidney diseases are associated with autoimmune thyroid disease. Although there is no data, it's reasonable to test thyroid function when in presence of kidney injury or nephrotic syndrome.

Case description

A 69-year-old man with past medical history of a tracheostomy due to neoplasm in larynx, treated with chemo and radiotherapy (RT) in 2010, hypertension, medicated with an ACEi and hemorrhagic stroke. In the last 2 weeks he has had an history of myalgia limited to lower limbs, paresthesia in fingers and diarrhea 3 times per day for 4 days. He wasn't aware of decreased urine output. After blood tests his attending physician sent him to emergency department (ED) with serum creatinine levels of 7 mg/dl and BUN 101 mg/dl (6 months before SCreat 1 mg/dl).

In ED general physical examination: temp 36.5°C, cardiac frequency 72 bpm, blood pressure 95/60 mmHg. He was conscious, calm and capable of presenting medical history, had no periorbital

or peripheric edema and cardiopulmonary auscultation had no alterations. Ultrasound showed normal kidneys and no signs of chronicity, urine summary test: blood 3+ and proteins 2+ and 20% dysmorphic red cells. He was admitted in nephrology department to study for a rapid progressive glomerulonephritis.

Remaining study showed normocytic anemia, CRP 127 mg/l, albumin 2.4 g/dl, 4.7 g/24hour proteinuria, PR3-ANCA 148 UA/ml (<15), normal C3 and C4 levels. We also evaluated thyroid function: TSH>100 uIU/mL (0.35-4.94), T4<0,40 ng/dl (0.52-3.88) and Thyroid peroxidase 85 UI/ml (<50). After evaluation by an Endocrinologist he started low doses of levothyroxin. We questioned patient and his family about other symptoms of hypothyroidism: lethargy, irritability, bradycardia, obesity and edema, which were all denied.

At last we admitted ANCA PR3 renal limited vasculitis, started metilprednisolone pulses, then cyclophosphamide cycle. He didn't recover renal function. Nowadays he is integrated in hospital day care of hemodialysis where he does regular sessions.

Discussion

The association between thyroid disease and ANCA vasculitis may reflect a propensity for autoimmune disease. It was remarkable that in this case the patient had no symptoms, however thyroid function levels were extremely altered with serum T4 levels very low, that could lead to severe hypothyroidism.

In this case the patient had history of previous thyroid injury with radiation therapy, so we admitted insidious hypothyroidism on account of RT.

#2062 - Case Report

PRIMARY HYPERPARATHYROIDISM - A CASE REPORT

Isabel Borges, Madalena Meneses, Bernardo Pereira, Luis Dias

Hospital do Divino Espírito Santo, Ponta Delgada EPE, Ponta Delgada, Portugal

Introduction

Hypercalcemia (HyperCa) affects 0.5% to 1% of the general population. Primary hyperparathyroidism (PHPT) causes 70% of outpatient and 20% of inpatient cases of HyperCA. It's prevalence is highest in women (3:1).

Case description

We report a 61 year-old woman, with chronic hepatic disease, coronary artery disease and hypertension, medicated with thiazid diuretic (TD), without personal history of cervical irradiation or family history of thyroid cancer. She was admitted at the Emergency Department (ED), because of multiple episodes of downfalls preceded by dizziness without loss of consciousness or convulsion. She also referred lethargy, weakness, confusion and limb paresthesias. Clinically, there wasn't fever or focal neurological deficits. Laboratory tests (LabT) revealed elevation of creatine kinase and liver enzymes, hyperamonemia, HyperCa,

hypophosphatemia and hypomagnesaemia. Cardiovascular and neurological ethiology was excluded. We admitted the following diagnosis: Rhabdomyolysis and Electrolyte Disturbance (ED), for investigation. At Internal Medicine (IM) ward, we started the study of HyperCa and its differential diagnosis, like neoplastic disease and HPT. LabT revealed persistency of HyperCa, hypophosphatemia, 25(OH)vitD insufficiency, elevated iPTH without renal impairment and 24h urinalysis with polyuria and slight hypercalciuria. After correction of 25(OH)vitD, we verified persistency of electrolyte disturbance and the ratio Cl-/PO4-: >33. We admitted PHPT and she underwent cervical ultrasonography (US) that show a nodular thyroid. She was discharged to ambulatory for follow up. Two weeks later, she was readmitted in the ED, because of obnubilation, dehydration and severe HyperCa. At IM ward, we started calcium mimetic. However it was suspended, due to gastrointestinal side effects and switched to zoledronic acid with good response. Parathyroid four-dimensional computed tomography (CT) and US revealed a nodule at the left lobule of the thyroid gland. A parathyroid sestamibi scan was performed, with findings suggestive of parathyroid adenoma. In accordance with clinical findings, serum calcium and bone densitometry, she was proposed for surgery.

Discussion

The triad consisting of HyperCA, elevated iPTH and hypophosphatemia makes the diagnosis of PHPT likely. A single parathyroid adenoma (85%) is the most frequent cause, followed by four-gland hyperplasia (10%) and parathyroid carcinomas (5%). The only definitive therapy for PHPT is parathyroidectomy.

#2090 - Case Report

INSULIN OVERDOSE - RARE CAUSE OF SUICIDE ATTEMPT

Joana Alves Duarte, Sofia Gomes Brazão, Sara Leitão, Rui Santos, Armando Carvalho

Centro Hospitalar e Universitário de Coimbra, Coimbra, Portugal

Introduction

The use of insulin with suicidal ideation is rare. It is usually associated with the administration of high doses, it can be difficult to identify and is often fatal. More frequent in diabetics, it also appears in non-diabetics. The hypoglycemic effect of insulin depends on the dose, individual susceptibility, absorption factors and coadministration of other substances. The speed of diagnosis and the intensive treatment are fundamental for a complete recovery of the patient.

Case description

A 54-year-old female was admitted to the emergency department in coma, with hypoglycaemia maintained even after administration of 12 g of glucose. Without a history of diabetes, with major depression (followed in Psychiatry appointment) and a history of abdominal surgery complicated by abdominal lip dystrophy, with

altered sensitivity. Already had several suicide attempts with oral antidiabetics and insulin – her husband’s usual therapy. It was found in coma, with evidence of multiple pricks in the abdomen and several Insuman Comb 25® empty pens (± 2400 IU). At admission in the hospital GCS 12, sweating, cold extremities and cyanosed lips, BP 109/70 mmHg, HR 108bpm and SpO₂ 90%. Blood glucose 33 mg/dL, kalemia 2.75 mmol/L, blood alcohol concentration 1,12 g/L and positive urinary benzodiazepines. Arterial gasimetry with pO₂ 66mmHg, pCO₂ 36mmHg and lactates 5.5 mmol/L. Under continuous monitoring, she was treated with hypertonic glucose in perfusion, glucagon in bolus and correction of hydroelectrolytic imbalance. After 6 days, the blood glucose values normalized and the patient recovered, being able to be transferred to the psychiatric hospital.

Discussion

Although rare, insulin poisoning with suicidal ideation was easy to establish because of the circumstances in which it was found. The use of premixed insulin and the use of other substances (alcohol and benzodiazepines) combined with abdominal lip dystrophy may have contributed to the administration of such a high dose and the need for such long-term surveillance. In the absence of an action protocol, continuous monitoring and administration of glucose and glucagon are the key to optimizing treatment and prognosis.

#2101 - Case Report

PLEURAL EFFUSION IN A YOUNG PATIENT - BEYOND THE MAJOR CAUSES: CASE REPORT

Marta Quaresma, Patricia Varela Ramos, Ana Isabel Oliveira, Sofia Cruz, Zara Soares, Jose Barata

Hospital Vila Franca Xira, Vila Franca Xira, Portugal

Introduction

Pleural effusion (PE) is common finding in daily practice and can be a diagnostic challenge since it may occur in pleuropulmonary or systemic diseases. The cause of a PE may remain unclear after initial research in up to 25 percent of patients.

Case description

The authors report the case of a 28-year-old male referred to the Emergency Department due to persistent PE. He complained of increased fatigue in the last few weeks. No other symptoms were referred and the patient’s personal history, usual medication or epidemiologic context were not relevant. Physical examination was normal apart from bilaterally decreased pulmonary murmur. Additional study was conducted revealing leukocytosis 10000/ UI, with 30% lymphocytosis, c-reactive protein of 1.88 mg/dl, increased D-dimers 2024 ng/mL and Erythrocyte sedimentation rate 31. Highlighting negative autoimmunity markers. Echocardiogram, Thoracic CT angiography, thoracoabdominal CT with no relevant changes, besides persistent PE.

Pleural fluid analysis revealed exudate characteristics, ANA

negative; Cytological examination and pleural biopsies were negative for neoplastic cells. Bacteriological examination was negative.

Three months after the first evaluation, the clinical, analytical and radiological manifestations persisted. An additional PET-CT showed no evidence of pathological hypermetabolic images.

With no etiological diagnosis after the initial study of the most frequent causes of PE, and taking into consideration the patient’s age and associated symptomatology, a further analytical study was performed with neuroendocrine markers revealing a marked increase in somatostatin (> 400 pmol / L) and increased 5-hydroxyindoleacetic acid (5-HIAA) in urine.

At this point, considering the possibility of a somatostatinoma, abdominal MRI followed by a Dotanoc PET study were performed. These did not detect any abnormal tissue or abnormal expression of somatostatin receptors suggestive of metabolically active neoplastic tissue.

Knowing that somatostatinoma is a neuroendocrine tumor of indolent growth, with 5 to 10 years between analytical alterations and identification of the tumoral location, the patient was referred to be followed by Endocrinology.

Discussion

This case illustrates the challenges of the etiological diagnosis of PE, particularly in young patients, highlighting the importance of detailed research towards persistent PE, and the fundamental role of Internal Medicine in integrating every detail in the absence of evident etiology.

#2104 - Case Report

PAGET’S DISEASE - CASE REPORT

David Paiva, Sandra Barbosa, Jorge Cotter

Hospital Senhora da Oliveira, Guimaraes, Portugal

Introduction

Paget’s disease (PD), also called osteitis deformante, is characterized by an osteoclastic hyperactivity with consequent bone resorption, accompanied by a compensatory osteoblastic response. This disease rarely has a symptomatic clinic (5%), which can affect one or several bones, the pelvis and sacrum are the most prevalent. Diagnosis is essentially radiological, but some laboratory alterations help the accomplishment of the same.

Case description

Man 72 years old, smoker with history of multiple bone fractures. Painful complaints, with 1 month of evolution, in the lumbar region, with irradiation to the lower limbs and decrease of the associated muscular strength. Assistant physician treated with deflazacorte witch resulted in clinical improvement. Computed tomography (CT) of the lumbar spine was performed, which revealed areas of lytic lesions and/or greater bone resorption in the posterior iliac region suggesting Paget’s disease. All of the study that was done, thyroid ultrasound, upper and lower digestive endoscopy and

abdominopelvic CT without any changes of relief. Analytically, increased alkaline phosphatase (160 U/L) and hydroxyproline 42 mg/24h (normal value:<42). Calcium, phosphorus and parathyroid hormone without alterations. Calcium in urine 24h was normal. Bone scintigraphy: outbreaks of abnormal osteoclastic hyperactivity in L4-L5 in the left iliac, sacral and pubic bone. The patient initiated infusion of zoledronic acid and had hospital discharge with calcium, vitamin D and supplemented with B vitamins. Oriented for internal medicine consultation, and three months later he presented significant clinical improvement, without pain and return to his normal life.

Discussion

It is important to exclude secondary causes (neoplasias, multiple myeloma) for bone lytic lesions. Treatment is indicated for symptomatic control, reduction of hypercalciuria, reduction of the number of complications and suppress high levels of bone resorption. Bisphosphonates are the agents approved for treatment of PD.

#2121 - Case Report

DELIRIUM SECONDARY TO HYPOTHYROIDISM

José Abreu Fernandes, João Borges Rosa, Nelson Pedro, Lèlita Santos, Armando Carvalho

Centro Hospitalar e Universitário de Coimbra, Coimbra, Portugal

Introduction

Confusional state and delirium are common neurologic dysfunctions in elderly patients specially those who have multiple morbidities and it may complicate their evaluation and management. Besides the attention and cognitive impairment, delirium can be accompanied by psychomotor and autonomic overactivity.

Although its pathophysiology is not well explained it is established to be associated with an underlying organic condition.

Case description

An 80 years-old male, autonomous for daily life activities (Katz functional scale of 6), antecedents of hypothyroidism due to thyroidectomy, essential arterial hypertension, and glaucoma was admitted to the emergency room for behavioral alterations and complex visual hallucinations for the past 2 weeks. The physical examination did not have any alterations, but the neurological examination showed dysarthria. Head CT revealed no recent vascular or expansive lesion. Lumbar puncture did not show any bacterial growth in the direct or cultural exam, biochemistry showed mild proteinorachia with normal glucose and without pleocytosis, and the multiple test for viruses and bacteria were all negative. HIV and screening for sifilis were negative. Thyroid function test revealed thyroid dysfunction, thyreo-stimulating hormone of 80 uUI/mL and free T4 was <0,4 mg/dL, while in previous study the patient had had normal values.

The patient was admitted to the Internal Medicine ward with thyroid hormone reposition and supportive care, and when asked he mentioned to have withdrawn all medication for the past few weeks.

Two days later, the patient resumed his past cognitive status without hallucinations. Hyperactive delirium secondary to hypothyroidism due to lack of medication compliance was assumed and the patient was reevaluated 1 month later with normal thyroid function.

Discussion

We report a case of a behavioral alteration and complex visual hallucinations potentially secondary to a hypothyroidism due to lack of medication compliance. Although cognitive impairment is common in overt hypothyroidism it is uncommon to see neuropsychologic symptoms like disorientation or psychosis.

It is emphasized the relevance of thyroid testing in elderly patients with neurologic dysfunction as well as the importance of pharmacology compliance vigilance in risk patients.

#2125 - Case Report

HYPOPITUITARISM ASSOCIATED WITH HYPOGLYCEMIA: CASE REPORT

Mario Angelo Cenedesi Junior^{1,2}, Fabiana Santos Felipe³

¹ Senhor Bom Jesus Hospital, Monte Azul Paulista, Brazil

² University of Sao Paulo, Ribeirao Preto, Brazil

³ Central Family Health Unit, Pitangueiras, Brazil

Introduction

The occurrence of hypoglycemia associated with hypopituitarism is a rare event in adult patients and a little more frequent in children with similar pituitary dysfunction. In patients with adrenal insufficiency, hypoglycemia is more prevalent in those whose cortisol deficiency is secondary to ACTH deficiency than in those with primary adrenal disease. This is probably due to the fact that, in the first condition, there are simultaneous deficiencies of GH and cortisol.

Case description

A 27-year-old man with a history of recurrent episodes of loss of consciousness. Attendance at all times, with superficial coma, with capillary glycemia less than 50 mg/dL, with improvement of the condition to hypertonic glucose correction. It refers to nocturnal enuresis for more than 5 years, daily. Bearer of short stature (1,60 cm), without beard, face and voice infantilizados, with appearance of characters secondary to the 17 years. Patient presenting daily nocturnal enuresis. The physical examination evidences genitalia with grade IV piloting (Tanner scale), elongated penis, with evident balanopreputial groove, with topical testes, of about 02cm each. Absence of postural hypotension and others. Laboratory tests: blood count, electrolytes and renal function without abnormalities. Endocrinological evaluation: ACTH: less than 5 pg/mL (NV <60pg/mL); Cortisol: <1 ug/dL (NV 7-31 ug/dL); Insulin: <1 uUI/mL (NV

2.6-24.9 uIU/mL); GH: <1ng/dL (NV 55-25 2ng/dL); TSH: 9.03 uIU/mL (NV 0.4-4.3 uIU/mL); Free T4: 0.5ng/dL (VN 0.6-1.5ng/dL LH: 8.5UI/L (NV 1.4-9.2 UI/L); FSH: 6.8IU/L (NV 1-12 IU/L); Cortisol suppression test after dexamethasone: 0.31ug/dL (NV <2 ug/dL); Total testosterone 1046ng/dL (NV 241-627ng/dL); Prolactin/DHEA/Androstenedione: not performed due to lack of laboratory possibility. Computed tomography (CT) of the abdomen and skull does not show any changes.

Discussion

Hypoglycaemia caused by deficiency of counterregulatory hormones is not a common clinical condition in adults with hypopituitarism, except when hypopituitarism is associated with diabetes treated with insulin or oral hypoglycemic agents (which is not the case with this patient). Hypoglycemia episodes disappeared after treatment with glucocorticoids. This demonstrated a cause and effect relationship between hypocortisolism and hypoglycemia.

Excluding other causes, after studying the hormones and axes, we assume that pituitary function impairment was caused by an autoimmune process, causing hypophysitis.

The patient is still being followed up.

#2128 - Case Report

PRIMARY HYPERALDOSTERONISM PRESENTING WITH HAEMORRHAGIC STROKE IN A YOUNG ADULT

Rita J. Rodrigues, Paula Gonçalves Costa, Marta Costa Gonçalves, Patrícia Gomes Pereira, Alcina Ponte

Hospital of Santo André - Hospital Center of Leiria, Leiria, Portugal

Introduction

There is an increased risk of cerebrovascular events in primary hyperaldosteronism (PH). Nevertheless, acute neurologic event as presenting feature of PH is uncommon. We present a case of stroke in young adult to highlight the need for secondary hypertension management workup in these patients.

Case description

A 39-year-old female presented to the emergency department with left hemiplegia, minor facial paralysis, left extinction and a blood pressure of 205/105 mmHg. She had previous history of unstudied uncontrolled hypertension since her first pregnancy at 29-years-old and was under antihypertensive therapy. Computed tomography (CT) scan of the brain showed an acute right lenticulo-capsular 5cm-long hematoma with involvement of the corona radiata, which had no surgical indication. She was admitted with diagnosis of haemorrhagic stroke. Laboratory exams revealed hypokalaemia (2.8mmol/L), normal thyroid stimulating hormone and raised T4, raised parathyroid hormone, normal serum calcium, low vitamin D and high cholesterol levels. During inpatient care, her clinical evolution was favourable. Etiologic study of stroke was negative except for uncontrolled hypertension. Further

investigation revealed normal catecholamines, high aldosterone (>20ng/dL) and increased aldosterone-to-renin ratio confirmed by sodium-loading test results. Abdominal CT scan showed a right suprarenal hypodense nodule suggesting adrenal adenoma. Parathyroid scintigraphy excluded adenoma. The patient was diagnosed with primary hyperaldosteronism caused by a functioning unilateral adrenal adenoma and is now waiting for surgical intervention while under medical treatment that includes a mineralocorticoid receptor antagonist. Hyperparathyroidism was considered secondary to vitamin D deficiency.

Discussion

In this case, the patient had secondary hypertension for 10 years without a known cause. The diagnostic approach to resistant hypertension should include screening for a secondary cause, including PH because it is one of the most common causes with a prevalence of 5-15%. An early diagnosis and subsequent treatment not only improves blood pressure control, but also acts to diminish cardiovascular morbidity and mortality.

#2133 - Case Report

HYPERPARATHYROIDISM - JAW TUMOR SYNDROME - CDC73 GERMLINE MUTATION

Isabel Borges, Bernardo Pereira, Rui Cesar

Hospital Do Divino Espírito Santo, Ponta Delgada EPE, Ponta Delgada, Portugal

Introduction

Primary hyperparathyroidism (pHTP), the main finding of hyperparathyroidism-jaw tumor (HPT-JT) syndrome, occurs in up to 95% of affected individuals. It is a rare autosomal dominant syndrome, linked to germline inactivating mutations in the tumour suppressor gene CDC73 (1q31.2 chromosome). Onset is typically in late adolescence or early adulthood.

Case description

We report a 59-year-old woman, with history of complicated and symptomatic nephrolithiasis during youth, with the need of extracorporeal shock wave lithotripsy and double-J stent implantation, benign uterine tumor and jaw tumor, intervened in 1999 and 2002. In the last three years, she was investigated at hospital's appointment, because of renal impairment stage 3. Hypertension and recurrent nephrolithiasis were the two major risk factors identified. Laboratory tests (LabT), during its investigation revealed mild hypercalcemia, elevation of parathyroid hormone, 25(OH)vitD deficiency, normal serum phosphorus levels, urinary calcium/creatinine >0.02 and no evidence of lithogenic risk profile on 24hour urinalysis. Clinical findings and LabT was suggestive of HTP. There weren't cervical compressive symptoms, palpable nodules and family history of HTP or neoplastic disease. According to the findings, HPT-JT syndrome was a plausible diagnosis. Indeed, the patient underwent cervical ultrasonography (US), without evidence of suspected

parathyroid nodules. A parathyroid sestamibi scan was performed and was negative. However, cervical CT-scan combined with "second-look" US examination evidenced a hypoechoic nodular formation at the inferior lobe of the right gland, suggestive of parathyroid adenoma.

Because of pHTP renal complications, a successfully parathyroidectomy of the two right glands was performed. Histologic diagnosis confirmed an adenoma. HPT-JT syndrome diagnosis was made by a positive genetic testing for CDC73 mutation (exon 14).

Discussion

The diagnosis of hereditary pHTP should be confirmed by a genetic testing preceded by the appropriate genetic counselling. CDC73 germline mutation may offer a predisposition to neoplastic progression with parathyroid carcinoma found in 21.6%. The optimal surgical approach has not yet been established and remains controversial. Because of the risk of recurrent or new disease, a regular lifelong serum testing for biochemical evidence of pHTP is recommended.

#2142 - Case Report

A RARE CASE OF ACQUIRED CHOREA

Guilherme Assis¹, Daniela Viana¹, Joana Rua¹, Luís Marques Loureiro², Romeu Pires¹, Paula Vaz Marques¹

¹ Hospital São Pedro de Vila Real, Vila Real, Portugal

² Hospital Distrital de Chaves, Chaves, Portugal

Introduction

Chorea is defined as an involuntary, non-stereotyped, random and continuous flow of movements that most commonly affects distal limbs and face. The classification comprises primary (idiopathic, hereditary) and secondary (acquired) etiologies. Causes for acquired chorea include metabolic/endocrine, infectious, drugs, toxins, neurologic, vascular and malignancy. The differential diagnosis relies on age, mode of onset, and other accompanying features.

Case description

A 60 years-old man presented in the emergency room with psychomotor agitation and hypersalivation. Physical examination revealed tachycardia, generalized chorea and previously known tetraparesis with crural predominance, anterocollis and dystonic posture of the left lower limb. No new-onset motor deficit was noted. No recent history of fever, neuroleptic administration or tonic-clonic seizures was documented. Relevant background included congenital cognitive deficit and epilepsy with ongoing treatment with valproic acid (800 mg per day). Family history included multiple stillborn siblings and a sister with identical intellectual phenotype. Initial blood and urinary analysis displayed no significant results. Valproic acid levels were normal. Cerebral CT showed no relevant findings. EKG revealed sinus tachycardia. Haloperidol and heart rate control drugs merely had partial

response. He later conducted extended tests: syphilis and HIV were negative, ANA testing was negative, but endocrine testing revealed free T4 58.60 pmol/L (normal level, 8.24 - 21) and TSH <0,01 mIU/L (normal level, 0.27 - 4.20). We assumed the diagnosis of thyrotoxicosis and instituted treatment with beta-blocker and methimazole. After normalization of the thyroid function tests, the neurological condition of the patient returned to its previous basal state.

Discussion

Although the patient has relevant neurological background, hereditary chorea usually develops insidiously, whilst acute onset is characteristic of acquired etiology. In this case, recognizing a secondary or reversible cause was relevant, as some conditions might be reversed. This patient manifested chorea in the context of hyperthyroidism. The effective correction of the level of thyroid hormones and concomitant abolishment of the neurological condition, while other causes were excluded, is sufficient to establish the diagnosis of hyperthyroidism-induced chorea.

#2145 - Case Report

AN ATYPICAL CASE OF POLYGLANDULAR AUTOIMMUNE SYNDROME TYPE III

Pedro Martins Dos Santos, Pedro Gomes Santos, Lucy Alves, Pedro Mendonça, Sérgio Gonçalves, António Veiga E Moura
Centro Hospitalar Universitário do Algarve - Faro, Faro, Portugal

Introduction

Polyglandular autoimmune syndrome (PAS) is defined as the functional disorder of at least two abnormal endocrine glands based on autoimmune mechanisms, that can also be associated with nonendocrine Autoimmune Diseases. PAS type III is one of the four types of PAS, and includes autoimmune thyroid disorders associated with other Autoimmune Diseases (ADs) and is not accompanied by Addison disease or Hypoparathyroidism. The authors describe the case of a middle-aged woman with a rare presentation of a PAS type III.

Case description

A 53-year-old woman is referenced to an Internal Medicine appointment after a short hospitalization due to a macrocytic anemia with vitamin B12 (vB12) deficiency. The patient had history of Hypothyroidism and Anemia irregularly medicated with vB12 and folate. There were no significant alterations in the physical examination, except for xanthelasmas in the upper eyelids. Laboratory results presented positive anti-gastric parietal cell antibodies (Ab) and negative anti-intrinsic factor Ab, which associated with vB12 deficiency were suggestive of Pernicious Anemia (PA). Immunology tests were also suggestive of Autoimmune Thyroiditis (AT) (Anti-Thyroglobulin Ab >3000 IU/mL and anti-thyroid peroxidase Ab 951 IU / mL). The findings of positive anti-mitochondrial Ab and anti-nuclear Ab with anti-SP100 Ab and anti-gp210 Ab, associated with the xanthelasmas in

the upper eyelids and absence of laboratory alterations of hepatic enzymes, revealed a subclinical Primary Biliary Cholangitis (PBC). About 11 months after discharge, the patient presented ptosis of the right eye and periods of dysarthria and dysphagia. Based on a suspected diagnosis of Myasthenia Gravis (MG), she underwent electromyography that revealed dysfunction of the post-synaptic membrane of the motor plate and is now awaiting the detection of specific MG Ab to confirm the diagnosis.

Discussion

Patients with ADs have a higher risk of developing other ADs, which makes it important to be alert to the possible sequential development of other autoimmune events in patients with PAS. In this case, a woman with PA and AT, developed a subclinical PBC and is in the early stages of a possible MG. As there is a possibility of developing other ADs, a strict follow-up is needed. An early detection of newer ADs in patients with PAS by screening for autoantibodies is a controversial issue but may help in introducing early treatment of other AD that may arise, before irreversible changes develop.

#2148 - Case Report

HEREDITARY HEMOCHROMATOSIS: AN INCIDENTAL DIAGNOSIS

Marta Mendes Lopes, Catarina Lameiras, Afonso Santos, Énia Ornelas, Maria Do Céu Dória

Professor Doutor Fernando Fonseca Hospital, Amadora, Portugal

Introduction

Hereditary hemochromatosis is the most frequent autosomal recessive genetic disease in the Caucasian population. It consists of excess iron deposition in tissues due to increased intestinal iron absorption, resulting in multiorgan dysfunction (liver, heart and endocrine glands). In 80% of cases it is caused by mutations in the HFE gene (H63D and C282Y being the most frequent), however, in some rarer cases it can be due to mutations in other genes involved in the regulation of iron metabolism – HFE-negative hemochromatosis.

Case description

We present a 76-year-old Caucasian male, with arterial hypertension and a recent hospital admission due to an ischemic stroke caused by ipsilateral carotid stenosis. During his hospital stay, due to a haemoglobin level of 12,5 g/dl, an iron study was requested, revealing an serum iron of 123 µg/dl, transferrin saturation of 60% and hyperferritinemia of 7949 ng/ml, hence making the diagnosis of hereditary hemochromatosis. The genetic testing proved to be negative for HFE gene most frequent mutations, therefore being most likely a HFE-negative hemochromatosis with the results from the remaining genetic study still in course.

The patient has been asymptomatic since the diagnosis. Due to a slight increase in liver enzymes (AST 42 U/L e ALT 70 U/L) and

although the abdominal ultrasound was normal, an abdominal MRI was ordered which revealed severe iron overload in the liver (232 µmol/g) as well as mild overload in the spleen (64 µmol/g). Moreover, the patient has no signs or symptoms of congestive heart failure and has a normal transthoracic echocardiogram. His thyroid function is normal, his fasting blood sugar levels are also under normal values and he has no signs of arthropathy or skin lesions. He is currently undergoing regular phlebotomies in the Day Hospital and is being followed-up in conjunction with the Immunotherapy Department.

Discussion

This case illustrates an incidental diagnosis of a rarer form of hemochromatosis. Although the patient is asymptomatic, he already presents signs of end-organ damage, namely, liver iron overload, being therefore at a greater risk of developing cirrhosis and hepatocellular carcinoma. We can thus conclude that early detection of this disorder and treatment initiation can delay and prevent end-organ damage, leading to lower morbidity and mortality.

#2155 - Case Report

WHEN BEHAVIOR CHANGE AND CARDIOVASCULAR RISK HAVE THE SAME CAUSE

Raquel Bastos Plácido¹, Ana Rafaela Araújo², Daniela Meireles², Diana Carvalho²

¹ USF Beira Ria - ACeS do Baixo Vouga, Gafanha Da Nazaré, Portugal

² Centro Hospitalar do Baixo Vouga, Aveiro, Portugal

Introduction

The Symptomatology of the Cushing's Syndrome is related to the exposure to high corticoid levels, bearing in mind that the severity is directly related to the intensity and duration of the Hypercortisolism. There's a wide spectrum of non-pathognomonic manifestations, some of them being common among the population, as for example glucose intolerance, obesity and arterial hypertension.

Case description

The authors present the case of a male patient, 57 years old, with a history of bipolar disorder, admitted to the emergency department in November 2018 for behavior change, showing alternation between periods of agitation and prostration. He had resumed therapy with lithium a few months before because of mood swings. Observed by Psychiatry he was being admitted for intoxication by lithium, in patient with concomitant hypernatremia.

However, clinical features remained the same despite the normalization of lithium levels, and a computerized cranioencephalic CT scan was requested that raised suspicion of pituitary lesion.

He was hospitalized for a study, with symptoms and signs

reviewed: food refusal and muscle weakness, despite weight gain, with recent diagnosis of hypertension and diabetes mellitus. The objective examination included obesity of the trunk and neck, full moon and bitemporal hemianopia.

Hypothesized state of hypercortisolism, confirmed in the analytical study (significant elevation of serum and urinary cortisol levels and serum ACTH levels). Had also reduced levels of TSH and thyroid hormones, with no other changes in the pituitary base.

EC magnetic resonance imaging confirmed that it was an invasive pituitary macroadenoma, with involvement of adjacent structures. Was submitted to transsphenoidal removal, with normalization of urinary and serum cortisol levels in a post-surgical study.

In this patient the behavioral changes were the cardinal manifestation, initially attributed to the underlying psychiatric illness and drug iatrogeny.

CS is associated with a significant increase in cardiovascular risk, as happened in this case, which made us suspect that hypercortisolism was confirmed.

Discussion

HBP, DM and obesity may improve after treatment, but often do not normalize. This suggests that they continue to be at increased risk, even after the disease being controlled, thereby benefiting from targeted and intensive therapy.

We reinforce the need for integration of signs and symptoms in the management of the differential diagnosis of confusional syndrome.

#2157 - Case Report

POLYURIA: A CASE OF CENTRAL DIABETES INSIPIDUS

Ana Luís Ferreira, Gabriela Pereira, Laura Castro, Magda Fernandes, Jorge Cotter

Hospital da Senhora da Oliveira - Guimarães, Guimarães, Portugal

Introduction

Central diabetes insipidus is a rare disorder caused by absent or reduced concentrations of antidiuretic hormone (ADH). Approximately thirty to fifty percent of cases are idiopathic. Differential diagnosis includes nephrogenic diabetes insipidus and primary polydipsia.

Case description

Healthy, forty-nine year-old woman complains of polyuria and polydipsia with one month of evolution and a daily water input of six liters. No history of trauma or neurosurgery. Abdominal ecography without evidence of urinary obstruction. MRI imaging showed a slight thickening of the pituitary stalk, with no evidence of space occupying lesions. Intravenous desmopressin was administered after water restriction with a one hundred and sixty percent increase in urine osmolarity, consistent with central diabetes insipidus. Oral treatment with desmopressin tablets, 0.1 mg twice daily, was introduced and the patient achieved clinical stability by the time of discharge.

Discussion

Water balance relies on a precise and flexible regulation, allowing adaptation to various circumstances of deprivation or abundance. The thirst mechanism is essential to achieve homeostasis. This is a rare case that highlights the importance of the hypothalamic-pituitary system and its interaction with multiple organs, particularly the kidney.

#2171 - Abstract

EVALUATING HOW THE WEEKENDS AND WARM SEASONS AFFECT THE INCIDENCE OF SEVERE HYPOGLYCEMIA AND DIABETIC KETOACIDOSIS IN A PORTUGUESE HOSPITAL

Liliana R Santos, Carlos Lemos, Rita Medeiros, Ana Paula Vilas

CHLN, Lisboa, Portugal

Background

Severe hypoglycemia (SH) and diabetic ketoacidosis (DKA) are among the main endocrinological disorders that cause Emergency Department (ED) visits. Although diabetes management has improved significantly over the years, this has not led to a decline in SH and DKA incidence. The primary outcome is to assess the effects of environmental factors, such as seasonality and weekends/weekdays, on SH and DKA incidence. This effect has never been studied in the Portuguese population.

Methods

Retrospective population observational study capturing all episodes of SH and KD between 2014 and 2018 in a tertiary care University Hospital. SH was defined as a symptomatic low glucose blood level (<60 mg/dL) that required intravenous glucose. DKA was defined as the association of hyperglycaemia (>250 mg/dL), acidosis and ketonaemia/Ketonaemia.

Results

Between 2014 and 2018, 48157 glucose blood levels were determined at the ED. A total of 474 episodes of SH were registered, 345 on weekdays and 129 on weekends. When the data was stratified per year, there was an increase in the admissions on the weekends versus weekdays. In 2014, the frequency of weekend SH admissions was 10.9% per day (15.6%/day in the week group), compared to 17.4% per day in 2018. Regarding seasons distribution, warm seasons were associated with an increased incidence of SH.

During the same period of time, 4622 patients presented with glucose higher than 250 mg/dL and 344 fulfilled DKA criteria. There were 108 DKA admissions on weekends (15.7%/day) and 236 admissions on week days (13.7%/day). Unlike SH, in the DKA group the lowest incidence happened in the summer (19.1% versus 38,0% during the winter).

Conclusion

For the risk and prognosis of SH and DKA, temporal and season

factors appear to contribute substantially. The enhanced frequency of SH in patients during weekends, in particular in warm seasons, is probably caused by short-term changes in behavior such as increased physical activity or higher alcohol consumption. Supporting these data, some international studies have documented that hemoglobin A1c levels are lower in the warm seasons. Concerning prognosis, a recent North American study concluded that patients admitted to hospital with DKA during weekends had a higher mortality rate than those admitted on weekdays. In conclusion, temporal and season factors may affect diabetes and awareness of this fact may help improve its' management.

#2186 - Abstract

PREVALENCE OF GLYCEMIC CONTROL IN TWO RANDOM DAYS OF AN INTERNAL MEDICINE SERVICE

Sérgio Antunes Da Silva, Domingos Sousa, Catarina Jorge, Margarida Viana, Elena Rios, Sara Aleixo, Diana Reis, Armindo Figueiredo

CHUA - Hospital de Faro, Faro, Portugal

Background

The prevalence of diabetes mellitus (DM) has been steadily increasing over the past few decades, promoted by the global rise in the prevalence of obesity and unhealthy lifestyles. The latest report from the World Health Organization (WHO) estimates a global prevalence of 422 million people living with diabetes in 2014. Patients with diabetes mellitus have highest rates of hospitalization and increased risk of adverse outcomes and mortality.

Objectives

To characterize the population of patients with diabetes mellitus admitted to an Internal Medicine service of a central hospital on two random days in 2019 (6 of March and 3 April 2019) and study the prevalence of glycemic variability.

Methods

Cross-sectional study based on consultation of the clinical files of patients admitted to the Internal Medicine of a Central Hospital. Hyperglycemia in hospitalized patients was defined as blood glucose levels > 180 mg/dL and hypoglycaemia as <80mg/dL.

Results

A total population of 280 patients with a mean age of 79.8 years was considered. The prevalence of diabetes was of 31.4%. Patient included to data collection need to be admitted less than 14 days ago and should be assigned to internal medicine specialist.

So we finally had 51 patients. Blood glucose (mg/dL) <80 1%, 81-180 46.9%; 181-240 26.2%; 241-300 15.8%, >301 9.8%. Only 25% of patients with oral antidiabetic agents persisted during hospital stay. 90% of the patients was under insulin during the hospital stay. A sliding-scale regimen was present on 65.3%.

Conclusion

It has been proved that both hyperglycemia and hypoglycemia are associated with adverse outcomes, including death. A sliding-scale regimen is strongly discouraged.

In the hospital setting, a basal insulin plus premeal short- or rapid-acting insulin (basal-bolus) coverage has been associated with improved glycemic control and lower rates complications compared with the traditional sliding scale regimen

Lastly our study reinforces that the internist should be able to control diabetes at the hospitalized patients accordingly with the standards of diabetes care.



GASTROINTESTINAL AND LIVER DISEASES

#35 - Abstract

SIRS CRITERIA VERSUS QSOFA IN SEVERE ALCOHOLIC HEPATITIS

Paula Reyes Suárez, Onán Pérez Hernández, Emilio González Reimers, María José Sánchez Pérez, Camino Fernández Rodríguez, María Candelaria Martín González, Víctor Vera Delgado
Complejo Hospitalario Universitario de Canarias, San Cristóbal De La Laguna, Spain

Background

Severe alcoholic hepatitis (sAH) is a serious complication in patients with alcoholism and was associated with high mortality. Bacterial translocation is a fundamental pathogenic factor and its intensity is related to severity and prognosis. In a recent study, SIRS criteria were related to LPS levels and surveillance. On the other hand, qSOFA has displaced these criteria in the definition of sepsis. The purpose of this study is to determine if qSOFA has greater clinical utility than SIRS criteria in patients with sAH.

Methods

Sixty-two patients with sAH (Maddrey ≥ 32) were included. We recorded these variables used in usual clinical practice, such as age, sex, liver and renal function parameters. We also determined SIRS criteria and qSOFA components.

Results

Mean age was 52.5 ± 10.7 years. During this period, 24 patients died (38.7%). SIRS criteria ≥ 3 and qSOFA ≥ 2 were related with mortality at 180 days (LR=12.09; $p=0.001$; LR=4.81, $p=0.028$, respectively). Other parameters who had related with surveillance were: male sex (LR=5.73; $p=0.017$), high serum bilirubin (LR=7.62; $p=0.006$), high serum creatinine (LR=5.43; $p=0.020$) and hyponatremia (LR=5.75; $p=0.018$). Cox regression was made and only bilirubin and SIRS criteria were independent prognostic factor.

Conclusion

SIRS criteria appear to have prognostic value in sAH, unlike qSOFA. We found that altered Glasgow (component of qSOFA) was related with delirium tremens, frequent in alcoholics and with almost non-existent mortality relation. Likewise, cirrhotic patients have lower blood pressure (other component), without this implying a worse prognosis. These facts could justify that the qSOFA does not have an independent relation with mortality in sAH.

#36 - Abstract

MALONDIALDEHYDE ASSOCIATED TO MELD IN SEVERE ALCOHOLIC HEPATITIS

Emilio González Reimers, Onán Pérez Hernández, Paula Reyes Suárez, María José Sánchez Pérez, Selena Gala Aguilera García, Lucía Romero Acevedo, Daniel Martínez Martínez
Complejo Hospitalario Universitario de Canarias, San Cristobal De La Laguna, Spain

Background

Severe alcoholic hepatitis (sAH) is a serious complication in patients with alcoholism and was associated with high mortality. Oxidative stress and lipid peroxidation are increased in sAH. In previous study, we found that malondialdehyde (MDA, as lipid peroxidation marker) could be independent prognostic factor. The aim of this research is to demonstrate the utility of MDA in clinical practice. For this, we decided to associate MDA to MELD, a previously validated prognostic score.

Methods

Sixty-two patients with sAH (Maddrey ≥ 32) were included. Serum MDA was determined at admission. In the cited study, MDA was related with 180 days-mortality. We built a new score with MDA and MELD, both corrected by Hazard ratio obtained in this work. The formula was $2 \times \text{MDA} + \text{MELD}$. Kaplan Meier curves and ROC curves was made for new score and its components.

Results

Mean age was 52.5 ± 10.7 years. During this period, 24 patients died (38.7%). High MDA levels were related with mortality (LR=7.89; $p=0.005$), just like MELD (LR=7.17; $p=0.007$). The association of both also had prognostic value (LR=7.89 ; $p=0.005$). ROC curves were constructed. MDA and MELD had a smaller area separately (AUROC=0.79 and 0.72, respectively) than the association of both (AUROC=0.83).

Conclusion

MDA could be useful in clinical valoration of sAH. The association of MDA with the MELD score could improve its predictive value, although it is necessary to perform a confirmatory work with an external cohort.

#42 - Case Report

WHAT IS HIDING BENEATH A LOWER LIMB NODULAR LESION?

Irina Tica¹, Zizi Niculescu¹, Liliana Mocanu², Mihaela-Maria Ghinea¹, Costin Niculescu¹

¹ Faculty of Medicine, Constanta, Romania

² County Clinical Emergency Hospital, Constanta, Romania

Introduction

Pancreatic panniculitis represents a dermatological manifestation mainly due to a pancreatic disorder, but other etiologies are possible. Usually it occurs prior to the clinical manifestation of the underlying disease, and its presence must orientate the investigations especially towards pancreas, liver and neuroendocrine system.

Case description

We report the case of a 47-years-old male patient who presented to emergency unit complaining for 2 weeks persistent pain in the upper abdomen and biliary vomiting. He recognized alcohol abuse. Several days prior to the onset of these symptoms, the patient noticed the occurrence of a nodular inflammatory lesion of 5/3 cm in the anterior middle third of the right calf. Based on clinical aspect and high levels of pancreatic enzymes, acute pancreatitis was diagnosed. Contrast enhanced abdominal CT examination revealed a cystic pancreatic mass and dilated intrahepatic biliary ducts, MRI being recommended. Abdominal MRI revealed a cystic tumor of the pancreatic head and thrombosis of portal vein, rising the suspicion of pancreatic adenocarcinoma. Biopsy was performed from the calf nodular lesion, with the diagnosis of panniculitis.

Discussion

Discussions over the differential diagnosis of the etiology of calf panniculitis, of the cystic pancreatic mass and of patient's evolution are performed, along with a review of the medical literature.

#48 - Abstract

NON ALCOHOLIC FATTY LIVER DISEASE (NAFLD) AND METABOLIC ASSOCIATED DISTURBANCES: THE IMPORTANCE OF DIET AND SPORT

Elena Gologan

University of Medicine and Pharmacy, Iasi, Romania

Background

A prospective study on obese patients with NAFLD, in an outpatient service, (06/2016 - 07/2017), with associated metabolic and tensional disturbances to find if an one year diet would improve the liver function.

Methods

A lot of 47 patients with NAFLD, obese (mean BMI=33.1), mean age 47.8 years, with diabetes mellitus (24), hypertriglyceridemia

(39), hypertension (36) were studied for liver function before and after one year a restrictive diet and sport.

Results

Initially the patients had mean values of: ALT=191.5 IU/l, AST=235.7 IU/l, serum albumin=3.5 g/dl, serum bilirubin=2.1 mg/dl, glycemia=159 mg/dl, triglyceridemia=370 mg/dl, INR=1.2 and a mean value of arterial pressure 165/96 mmHg. The patients were treated only by diet (low calories, low carbohydrates, low saturated fat, rich fibers, moderate rich in low glycemic index carbohydrates, no alcohol) and 7 hours per week sport. After one year the mean values of BMI=25.1, ALT=45.7 IU/l, AST=56.3 IU/l, serum albumin=3.7 g/dl, serum bilirubin=1.1mg/dl, glycemia=109 mg/dl, triglyceridemia=197 mg/dl, INR=1.07 and mean arterial pressure 135/83 mmHg.

Conclusion

The role of diet and sport in NAFLD in order to decrease the BMI is also essential for the improvement of liver function and regulation of associated metabolic disturbances and arterial pressure.

#51 - Case Report

WATERMELON STOMACH - AN UNCOMMON CAUSE OF ANEMIA IN THE ELDERLY

Rahul Unnikrishnan

Rashid Hospital, Dubai, United Arab Emirates

Introduction

Gastric Antral Vascular Ectasia(GAVE), also referred to as 'watermelon stomach' is an uncommon, under reported, yet significant cause of acute or chronic gastrointestinal blood loss in the elderly. It accounts for about 4% of non variceal upper GI bleed and diagnosis is established by demonstration of characteristic watermelon stripes on upper GI endoscopy.

Case description

65-year-old lady, with no known comorbid illnesses, presented with complains of generalised fatigue, loss of appetite, unquantified loss of weight for the last 4 months, She was evaluated locally 2 months ago and was found to be anemic with a Hemoglobin of 10g% and was started on oral iron supplementation, as her iron stores were found to be low, with no significant symptomatic improvement since then. Over the next two months, she had persistent complaints of generalised edema and occasional bouts of diarrhea. She did not have any associated overt bleeding manifestations. Routine evaluation revealed iron deficiency anemia and stool occult blood was positive. This warranted the second line of anemia evaluation. Upper GI Endoscopy thus done revealed Gastric Antral Vascular Ectasia (GAVE). Argon Plasma Coagulation was done, and her occult blood loss ceased. On followup, her hemoglobin levels gradually improved and she continued to be asymptomatic, as her earlier symptoms had largely resolved.

Discussion

GAVE is an uncommon but significant cause of acute or chronic GI blood loss in the elderly. It was first described in 1954 by Rider as “fiery red changes with marked hypertrophic mucosal changes, and scattered profuse bleeding.

#60 - Case Report

DIARRHEA IN YOUNG PEOPLE

Cristina Lojo, M. Angeles Gallardo, Isabel Melguizo, Jose Antonio Mira

Hospital de Valme, Sevilla, Spain

Introduction

Diarrheal diseases are a leading cause of morbidity and mortality worldwide

Case description

A 15-year-old woman with chronic normocytic-normochromic anemia since 2015 was admitted due to asthenia, intermittent hematuria, lower limbs edema and diarrhea with blood of 15 days of evolution. The examination revealed skin pallor, bilateral malleolar edema and low weight with no pubic or axillary hair (Tanner I) with slightly developed breasts (Tanner II). Blood count shows Hb 7.8 g/dl (normo-normo), white series and normal platelets; smear with red series with tendency to rouleaux, hypochromia and poikilocytosis. He presents iron deficiency and folic deficit. In the coagulation study no clot is detected, so fresh plasma and vitamin K are administered. In the biochemistry, total proteins of 3.5 g/dl stand out. Normal immunoglobulins. In urine sediment presence of red blood cells. Stool culture with normal flora and normal abdominal ultrasound.

Therefore silent episode of severe malnutrition with coagulopathy and delayed growth and maturation, until the moment of admission. Given the diagnostic suspicion, Ac antigliadina is requested (these being > 80), a gluten-free diet is initiated and an oral endoscopy is performed, with duodenal second folds and nodular mucosa of a biopsy pattern being observed, all compatible with celiac disease. Excellent evolution with gluten-free diet, staying asymptomatic.

Discussion

Celiac Disease is an immune-mediated systemic disease caused by gluten and related prolamins in genetically susceptible individuals and is characterized by: gluten-dependent clinical manifestations, EC-specific antibodies, HLA haplotypes DQ2 or DQ8 and enteropathy. The prevalence in Europe is 1%, more frequent in women. Symptoms may be atypical or absent and 75% of patients are undiagnosed.

For certainty diagnosis, intestinal biopsy is essential without removing gluten from the diet.

#69 - Case Report

A RARE COLITIS IN A YOUNG GIRL

Ana Beatriz Amaral, Pedro Duarte, Cláudia Rodrigues, Luís Dias

Hospital do Divino Espírito Santo de Ponta Delgada, Ponta Delgada, Portugal

Introduction

Ischemic colitis is the most common form of intestinal ischemia, with heterogeneous presentation, more frequent in the elderly and rare in young people.

Case description

A 22-year-old woman was referred to the emergency department for abdominal colic, more intense in the left lower quadrant, without irradiation, with diarrhoea and haematochezia, after 10 hours of evolution. She denied associated fever, vomiting and urinary symptoms. She had a history of anxiety disorder, migraine and irritable bowel syndrome and was taking an oral contraceptive. On examination she had a blood pressure of 96/67 mmHg, a heart rate of 97 bpm, an abdomen without guarding but painful in the epigastrium and left quadrant, with no signs of peritoneal irritation. Rectal examination showed abundant mucus and blood. She had leucocytosis (12,280/μl) and neutrophilia (81.3%), low CRP, with no change in coagulation, renal or hepatic function. X-ray of the abdomen without changes of relief. A flexible rectosigmoidoscopy revealed a vascular erythema and edema, with mucous desquamation with haemorrhagic suffusions, without ulcers, suggestive of ischemic colitis. An abdomino-pelvic CT showed parietal thickening of the colon, from the splenic angle to the beginning of the sigmoid colon, compatible with colitis of the descending colon. No signs suggestive of obstructive vascular disease. Ciprofloxacin was prescribed, and the patient was hospitalized for study and monitoring. Coprocultures and study of thrombophilias were negative. The histological result confirmed ischemic colitis. Two months later and after suspended oral contraceptive intake the patient was asymptomatic and had normal colonoscopy.

Discussion

Among young people, ischemic colitis is a rare but not impossible condition, which may be idiopathic and occur insidiously. However, in most cases ischemia is self-limiting and leaves no sequelae.

#70 - Case Report

LIFE THREATENING IDIOPATHIC ACUTE LIVER FAILURE IN POSTPARTUM FEMALE: A RARE PRESENTATION OF ACUTE FATTY LIVER OF PREGNANCY

Chavely Valdes Sanchez, Nitasa Sahu, Rohit Jain

Hershey Medical Center, Hershey, United States

Introduction

Acute fatty liver of pregnancy (AFLP) is a rare life-threatening acute liver failure (ALF) (5/100,000 pregnancies), primarily

diagnosed in the late third trimester than in post-partum. This case describes idiopathic AFLP in postpartum period and its diagnosis by Swansea criteria.

Case description

A 26-year-old female, G1P1 presented to ED on postpartum day 5, with complains of epigastric pain, nausea, yellowing of skin and eyes, and diffuse rash of two day duration. Her physical exam demonstrated soft, non-tender, distended abdomen, bilateral 1+ pedal edema, diffuse jaundice and skin rash. Patient was hemodynamically stable. Laboratory workup revealed albumin 2.2, Alk phos 269, ALT 153, AST 132, total bilirubin 12.2, direct bilirubin 9.7, uric acid 8.1, INR 2.1, PTT 21.3, glucose 56, BUN 26, Cr 1.74, Fibrinogen 92, hemoglobin 11.4, WBC 17 000, platelets 171 000, and LDH 661. Abdominal ultrasound (US) showed tiny polypoid extrusion of the liver from the inferior liver margin, normal portal vein and gallbladder. Retroperitoneal US showed increased echogenicity of the liver. Abdominal venous duplex showed no abnormality. Skin biopsy confirmed perivascular and interstitial lymphocytic infiltrate of the dermis, indicative of urticaria. Work up for viral serology and screening for long-chain-3-hydroxyacyl-coenzyme-A dehydrogenase (LCHAD) were negative. Her AFLP improved with no complications due to early diagnosis and optimal management.

Discussion

This case highlights importance of Swansea criteria to exclude other causes of ALF, which mimic AFLD. Physicians should be aware of Swansea criteria, for early diagnosis of AFLD, prevention of complications, and educating patients to avoid recurrence.

#92 - Abstract

CLINICAL AND INVESTIGATIVE PROFILE OF ACUTE VIRAL HEPATITIS: A PROSPECTIVE OBSERVATIONAL STUDY FROM NORTHERN INDIA

Biswadeep Roy, P K Bansal, Vinod Kumar, Veenu Gupta
St. Stephen's Hospital, New Delhi, India

Background

Viral hepatitis, an acute infectious disease of liver with systemic involvement, is a cause for major health care burden in India. It is now equated as a threat comparable to the "big three" communicable diseases – HIV/AIDS, malaria and tuberculosis and may occur in both sporadic form as well as in the form of epidemic outbreaks. The present study was aimed to study clinical and investigative profile of acute viral hepatitis (AVH) and to determine relative frequency of different viral etiologies in AVH. Observations were also made on different types of complications, clinical outcome and certain risk factors that determine the severity of hepatitis.

Methods

A prospective, observational study was conducted in the Department of Medicine St. Stephens Hospital, New Delhi from July 2016 to December 2017. A total of 100 patients aged more than 12 years of either sex with indoor and outdoor patients were included. Based on history, physical examination and results of various investigations, patients of acute viral hepatitis were evaluated with regard to relative frequency of various viral hepatitis markers and prevalence of various complications among them. Prevalence of common risk factors for hepatitis and/or its severity such as alcohol intake, diabetes mellitus, low socio-economic status and older age of patients was determined.

Results

Among 62 males and 38 females patients, mean age was 32.3 years. Mean values of laboratory investigations of haemoglobin (11.89±1.74), total count (6650±3931), platelet count (1.94±0.75 lakhs), total bilirubin (5.23±2.84), direct bilirubin (4.49±2.35), SGOT (1354±1120), SGPT (1451±1040), alkaline phosphatase (303±194.66) and INR (1.43±0.79). Hepatitis E (62%) was the most common etiology followed by Hepatitis A (25%).

Conclusion

Patients with AVH often present not only with well known symptoms, signs and laboratory manifestation of disease but at times can have a variety of complications. Feco-oral mode of transmission together with types of hepatitis such as E and A are much more common than parenteral route like B and C types. By and large clinical and laboratory features of feco-oral and parenteral AVH are similar and majority of AVH patients have good outcome. Diabetes, alcohol intake and increased age of patients are more often associated with severe form of hepatitis. Patients who develop hypoalbuminemia, ascites, shock or AKI have poorer outcome.

#93 - Case Report

ACUTE PANCREATITIS AS AN UNUSUAL PRESENTATION OF BURKITT'S LYMPHOMA

Natália Bystrianska

HEGITO (Division of Hepatology, Banská Bystrica, Slovakia)

Introduction

Burkitt's lymphoma is a highly aggressive B-cell non-Hodgkin lymphoma (B-NHL) accounting to less than 2% of all adult NHL cases. There are three clinical variants, of which the sporadic form is the most common in our area.

Burkitt's lymphoma usually presents as a tumorous mass in the abdominal region (ileocecal region, retroperitoneum). Acute pancreatitis is a very rare initial presentation of BL rarely described in case reports.

Case description

In our case report, we present a patient – a middle-aged man

without any previous severe diseases – admitted on the basis of acute edematous pancreatitis, followed by a progressive deterioration of his health state within a short time frame during a period of hospitalization, manifested by various clinical findings ranging from focal liver lesions, sudden onset of dysphagia to paraplegia of the lower limbs with associated neurological complications. After a thorough examination, it was the bone marrow biopsy that revealed the diagnosis responsible for everything – Burkitt's lymphoma.

Discussion

This case report, therefore, contributes to the conclusion that NHL belongs to the differential diagnosis of pancreatitis and in the case of Burkitt's lymphoma, the early diagnosis with immediate intervention is essential.

#103 - Case Report

OLMESARTAN INDUCED ENTEROPATHY – A CAUSE FOR DIARRHEA AND MALABSORPTION

Miguel Trindade, Leonor Boavida, Joana Carvalho, João Serôdio, Catarina Favas, José Delgado Alves
Hospital Professor Fernando Fonseca, Lisboa, Portugal

Introduction

Drug-induced enteropathy has been described with azathioprine, methotrexate, colchicine and mycophenolate mofetil. Since 2012 it has recently garnered more attention with its association with olmesartan, a commonly prescribed antihypertensive medication. We describe two cases in which olmesartan was accountable for a sprue-like enteropathy.

Case description

Case 1

59 years-old-female presenting with abdominal pain, diarrhea and vomits while on olmesartan treatment for hypertension. Workup for celiac and inflammatory intestinal disease were negative. The colonoscopy showed no macroscopic lesions and the histology revealed focal loss of goblet cells, intraepithelial lymphocytosis, and mixed inflammatory infiltrate. Olmesartan as a precipitant agent was suspected and withdrawn. Follow-up at one year shows clinical remission.

Case 2

84 years-old-male presenting with diarrhea and weight loss while on olmesartan plus amlodipine and olmesartan plus hydrochlorothiazide. No evidence for celiac disease was found. Gastrointestinal endoscopy showed extensive erosive duodenopathy. Gastrin levels were normal. The histology revealed villous atrophy with intraepithelial lymphocytosis and mixed inflammatory infiltrate. Both olmesartan associations were suspended and the patient was discharged with clinical improvement. The patient mistakenly resumed his former antihypertensive medication and diarrhea recurred. Olmesartan

was permanently removed and follow-up at four months shows complete clinical remission.

Discussion

Olmesartan-induced enteropathy causes diarrhea and malabsorption. It features intestinal villous atrophy, particularly in the duodenum, intraepithelial lymphocytosis and subepithelial collagen deposition. There is no specific macroscopic finding or serology. Therefore, the diagnosis is based on clinical and/or histologic improvement after drug suspension. Since being a commonly prescribed drug in the hospital setting, this is a significant differential diagnosis in cases presenting with diarrhea, weight loss, and villous atrophy.

#107 - Medical Image

RIGHT PLEURAL EFFUSION AND ABDOMINAL PAIN

María Elena Mansilla Rodríguez, Joaquín González Cantón, Blanca Hidalgo Armayones, Eva Nadejda Gutierrez Cortizo, Manuel Jesús Romero Jiménez
Hospital Infanta Elena, Huelva, Spain

Clinical summary

A 75-year-old man who went to the Emergency Department for abdominal pain and dyspnea. In hepatic MRI (A) and (B) CT images of the abdomen, we can see a subcapsular hematoma coming from a bleeding metastasis as a first possibility and / or primary hepatic tumor. (C) Fine needle aspiration of one nodular lesion established the diagnosis of neuroendocrine tumor. After the autopsy, the pathological anatomy of the hepatic lesions showed abundant necrosis (D, E), evident nucleolus and abundant mitotic figures (C) and, in the stomach (F), we discovered an excretion which confirmed a gastrinoma with hepatic metastasis. Neuroendocrine tumors are presented as radiological syndromes in which the diagnosis and anatomical location of the primary tumor influences its clinical presentation and treatment.

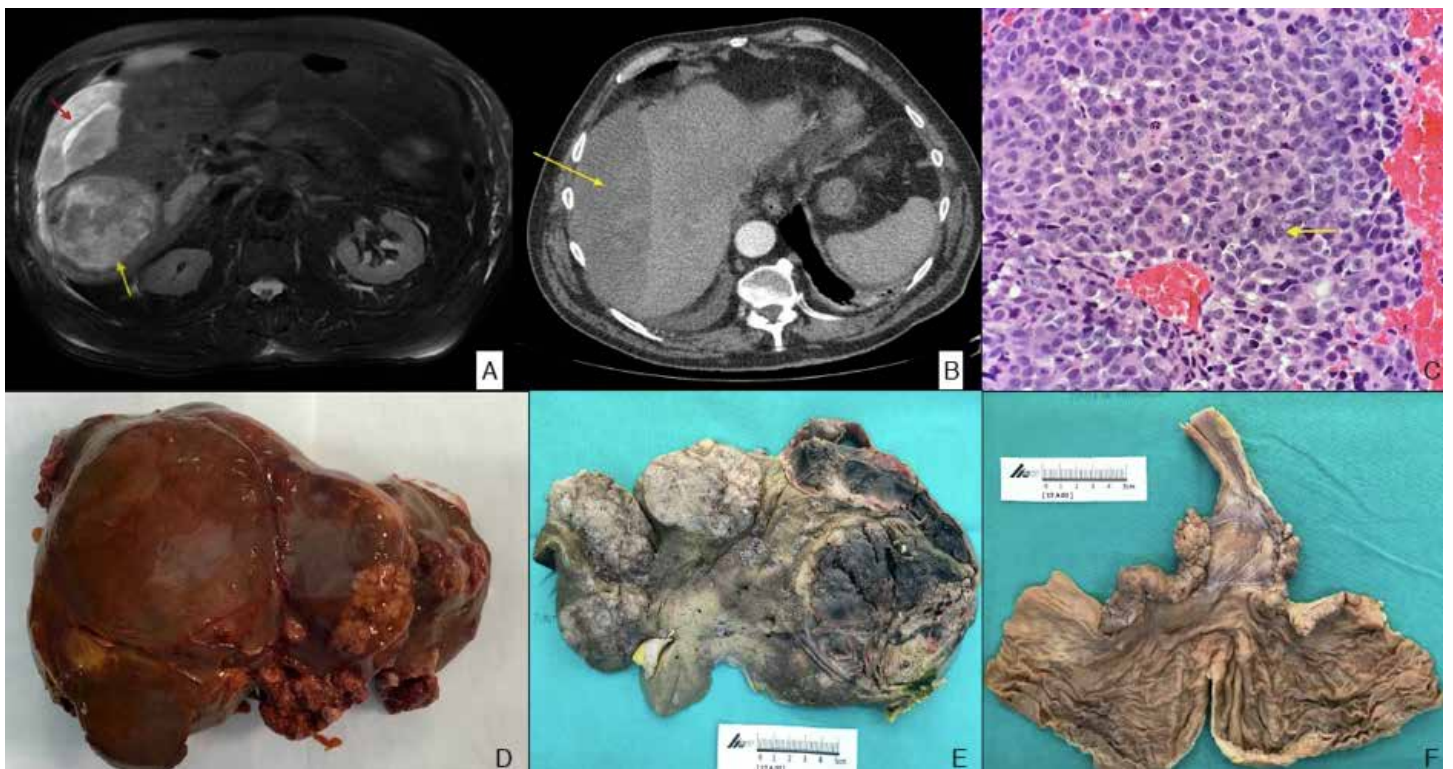


Figure #107. Autopsy neuroendocrine tumor.

#112 - Abstract

AUTOIMMUNE HEPATITIS (AIH): THE IMPACT OF AGEING ON SEVERITY, TREATMENT RESPONSE AND OUTCOME OF AUTOIMMUNE HEPATITIS (AIH)

Kalliopi Azariadis¹, Nikolaos K. Gatselis^{1,2}, Pinelopi Arvaniti¹, Vasiliki Lygoura¹, Stella Gampeta¹, Kalliopi Zachou^{1,2}, George N. Dalekos^{1,2}

¹ Department of Medicine and Research Laboratory of Internal Medicine, University Hospital of Larissa, Larissa, Greece

² Institute of Internal Medicine and Hepatology, Larissa, Greece

Background

AIH affects both sexes and all age groups. However, few studies have focused on the potential particular characteristics of AIH in older patients in terms of disease severity, response to treatment and outcome. Therefore, we investigated the baseline characteristics, treatment response and prognosis of AIH patients of ≥ 70 years

Methods

234 patients with well-established AIH prospectively followed in our center were evaluated. Treatment response was assessed in a subgroup of 202 patients.

Results

25/234 patients (10.7%) were ≥ 70 years at the time of disease onset (median 73 years) while the rest (89.3%) had a median of 47 years. The disease presentation was mainly subclinical or

insidious, similarly to the younger group (19/25, 76% vs 134/209, 64.1%, respectively, $p=0.313$). Older patients had higher levels of ALT at the time of diagnosis [199(441) vs 101(433) IU/L, $p=0.045$], but no differences were found regarding the presence of hypergammaglobulinemia and autoantibodies. Older patients were more frequently cirrhotic at diagnosis (12/25, 48% vs. 57/209, 27.3%, $p=0.032$). Importantly, similar rates of response to treatment (11/18, 61% vs. 81/184, 44%, $p=0.171$) and corticosteroid withdrawal (11/18, 61% vs 123/184, 67%, $p=0.612$) were achieved in both groups. Treatment-related adverse events were observed at the same rate between groups (6/18, 33% in older vs. 54/184, 29% in younger patients, $p=0.724$). Among treated patients ($n=202$), the age ≥ 70 -years was related only with the overall mortality [HR 11.3 (95%CI: 2.6-48.6), $p=0.001$], while liver-related mortality was similar between age-groups [HR 3.4 (95%CI: 0.4-30.0), $p=0.268$].

Conclusion

AIH should be seriously considered in older patients with unexplained impaired liver function tests as the disease is not rare in this patient group and seems to carry an increased risk for advanced disease at diagnosis. However, if immunosuppression therapy is started promptly, seems as effective and safe.

#126 - Abstract

THE CHANGING EPIDEMIOLOGY OF HEPATITIS B IN GREECE

Vasiliki Lygoura¹, Nikolaos K. Gatselis^{1,2}, Konstantinos Galanis¹, George Giannoulis¹, Stella Gabeta¹, Kalliopi Zachou^{1,2}, Eirini I. Rigopoulou^{1,2}, George N. Dalekos^{1,2}

¹ Department of Medicine and Research Laboratory of Internal Medicine, University Hospital of Larissa, Larissa, Greece

² Institute of Internal Medicine and Hepatology, Larissa, Greece

Background

Chronic hepatitis B (CHB) virus infection remains an important public health problem worldwide. However, during the last decades its epidemiology is changing due to various competing factors, such as the application of expanded vaccination programs in all newborns but also the migration of population from moderate/high to low endemicity countries. The aim of the present study was to assess trends in epidemiological and clinical characteristics of the disease during the last 20 years in the region of Thessaly, Central Greece.

Methods

1910 consecutive CHB patients (males 60.8%, mean age 42.2±15.8 years), followed in our centre during 1999-2017 were included in the analysis. At initial evaluation, 1314 (68.8%) had chronic infection (inactive carriers), 415 (21.7%) CHB, 116 (6.1%) CHB-related cirrhosis and 65 (3.4%) CHB-related hepatocellular carcinoma (HCC).

Results

1601 CHB patients were initially evaluated during the first period of 1999-2010, while the rest 309 patients evaluated for the first time during the second period (2011-2017). Patients with baseline visit at our centre during 2011-2017 were significantly older (55.1±16.1 vs 49.2±15.6 years, $p<0.001$), had longer disease duration (47±16.5 vs 41.3±15.6 years, $p<0.001$), lower BMI (26.3±3.6 vs 26.7±3.4 kg/m², $p<0.05$) and were immigrants in a significantly higher proportion (16.2% vs 8.1%, $p<0.001$) compared to those diagnosed in the previous period. Patients of the second period tended to diagnose at more advanced disease stage namely cirrhosis and/or HCC (12.3% vs 8.9%, $p=0.085$) although they characterized by lower rates of virological breakthrough (9.5% vs 45.5%, $p<0.001$), biochemical relapse during treatment (9.5% vs 43.3%, $p<0.001$), progression to cirrhosis (1.8% vs 14%, $p<0.02$) and development of HCC (5.1% vs 13.2%, $p<0.04$) compared to the patients of the first period.

Conclusion

Despite the implementation of prevention and early detection strategies during the 1999-2010 period, the proportion of CHB patients presenting at diagnosis with already established cirrhosis continues to rise. However, during the current decade the rates of relapse and disease progression to cirrhosis and HCC development in treated CHB patients seem to decline probably

because of the use of the newer potent antiviral agents which bear high barrier of resistance.

#152 - Case Report

A CASE OF MESENTERIC PANNICULITIS: WHAT YOU NEED TO KNOW ABOUT IT.

Chaozer Er¹, Navin Kuthiah¹, Vanessa Hwee Ting Tey²

¹ Woodlands Health Campus, Singapore, Singapore

² Ministry of Health Holdings, Singapore, Singapore

Introduction

Mesenteric panniculitis (MP) is the inflammation of the adipose tissue of the intestinal mesentery. It is associated with abdominal trauma, surgery, infection and malignancy. Its prevalence was reported to be 0.16-2.5%. We present a case of MP associated with pancreatitis.

Case description

A 66-year-old Chinese gentleman with past medical history of diabetes mellitus, hypertension, previous pancreatitis and epilepsy, presented to us with an episode of near syncope due to hypoglycaemia. As there was raised alkaline phosphatase, he underwent an ultrasonography (US) of the abdomen. The US showed a hypoechoic lesion at the right hepatic lobe which could represent early infection. He therefore underwent a computed tomography of abdomen and pelvis (CTAP) for further evaluation. The CTAP showed no abnormality in the liver but there was incidental finding of small bowel mesenteric panniculitis (MP). Our radiologist reviewed our patient's old CTAP which was done 4 years ago. The small bowel mesenteric stranding was already present in the old scan and appeared stable in the current scan. As MP is associated with malignancy, our patient underwent upper and lower gastrointestinal endoscopy to look for neoplastic lesion. The endoscopy findings were negative of malignancy. He also underwent CT thorax which was negative of malignancy. The MP was attributed to his previous pancreatitis. He is currently on follow up with our gastroenterologist.

Discussion

MP can present as abdominal pain, fever, weight loss, diarrhoea or constipation. 10% of the patients may be asymptomatic. It is usually an incidental finding on CTAP that was done for other purposes. As it is associated with malignancy, a thorough check for malignancy should be carried out upon diagnosis of MP. Treatment options for symptomatic cases include steroid, non-steroidal anti-inflammatory drugs (NSAIDs) and immunosuppressants.

#177 - Case Report

ANABOLIC STEROID-INDUCED HEPATITIS – A HIDDEN DANGER AT THE GYM

Joana Liz Pimenta, Patrícia Chow Liu, Paula Vaz Marques, Sandra Alves Morais

Centro Hospitalar de Trás-os-Montes e Alto Douro, Vila Real, Portugal

Introduction

Anabolic steroids (AS) are a cause of drug-induced hepatitis and in most cases these substances are not approved by regulatory agencies. The clinical presentation varies from mild liver enzyme elevations to fulminant hepatitis, usually within the first 3 months after consumption of AS. The medical approach is based on the suspension of the drug and supportive medical care, sometimes requiring early referral to liver transplantation.

Case description

We present a case of a 32-year-old male with no relevant past medical history, who attends the gym frequently. The patient went to the emergency department complaining of conjunctival icterus, dark yellow urine and generalized pruritus with 3 weeks of evolution. He had a history of self-administration of artificial testosterone (2,3-epithio-17 α -methyl-17 β -hydroxy-5 α -androstane) in the previous 2 months. On physical examination the patient had jaundice and blood tests showed liver dysfunction with conjugated hyperbilirubinemia [total bilirubin (BT) of 9.4 mg/dL and direct bilirubin (DB) of 9 mg/dL] and mixed dyslipidemia. Abdominal CT showed hepatomegaly, without focal lesions or biliary ducts dilatation. HBV, HCV, HAV, HEV, HIV, CMV, EBV, Herpes simplex, Syphilis and Rickettsioses were excluded. ANA, AMA, SMA, SLA, LC1, anti-actin Ab, ceruloplasmin and copper were negative. It was assumed anabolic steroid-induced hepatitis. Supportive medical care and 40mg of prednisolone daily was provided. At first, the patient presented worsening of the hepatic parameters (TB of 26 mg/dL and DB of 21 mg/dL), without neurological consequences or hemodynamic instability. A pretransplantation study was carried out concomitantly. Liver biopsy revealed discrete lesions of canalicular cholestasis, compatible with hepatitis in resolution. Given the clinical stability, close patient monitoring and symptomatic control were decided. The patient presented progressive clinical and analytical improvements until a complete resolution.

Discussion

AS are often misused by professional and amateur athletes as a way to improve physical performance and muscle mass. The presence of the 17 α -alkylated group showed an increased risk of hepatotoxicity, since the substitution of the 17 α -alkyl group was shown to delay the hepatic metabolism of AS. Cholestatic hepatitis, hepatocellular carcinoma or hepatic adenoma are some of the adverse effects related to this group. Information about the risks of these drugs becomes urgent and their use should be discouraged by health professionals.

#184 - Case Report

A DIVIDED PANCREAS

Cristina Martins, Pedro Ribeiro, Armando Carvalho

Centro Hospitalar e Universitário de Coimbra - Hospital Geral, Coimbra, Portugal

Introduction

Acute pancreatitis (AP) is one of the most common pathologies of the digestive tract. It has several causes, being biliary lithiasis the most frequent. Even though there has been a decrease in the associated morbidity and mortality, there are still various cases of severe AP, which reflect the need for a correct initial assessment of its severity.

Case description

A 76 years old woman, previously cholecystectomised in the setting of lithiasis, presents to the Emergency Room complaining of abdominal pain, dyspnea and vomiting, with 24 hours evolution. Abdominal pain was constant, severe, localized to the upper abdominal quadrant and irradiating to the back. On admission she was anicteric, her abdomen was painful on the upper quadrant but without signs of peritoneal irritation, and she showed signs of shock and SIRS. Blood tests showed a conjugated hyperbilirubinemia and elevated liver enzymes, amylase and lipase (4763 UI/L). Ultrasonography (US) identified a dilated common bile duct and extrahepatic ducts. A diagnosis of AP was assumed and an abdominal CT performed, showing a normal pancreas but with a thickening of the adjacent duodenal loop, and dilated intra and extrahepatic ducts, with a common bile duct of 1.3 cm of higher caliber. The patient was admitted for treatment and etiological study of this AP, since the exams were suggestive of an obstructive cause, being the patients already cholecystectomised. A MRCP was performed revealing no alterations except for signs of a classic pancreas divisum, with a main pancreatic duct draining to the minor duodenal papilla. A final diagnosis of AP caused by microlithiasis (non-visible on the US and CT, and responsible for the biliary ducts distention), that was deeply aggravated by the presence of a pancreas divisum, was finally assumed. After 9 days of hospitalization, the patient was discharged, with normal blood tests, and oriented to a Gastroenterology consult.

Discussion

Pancreas divisum is an anatomical variant in which the usual fusion of the dorsal and ventral pancreatic ducts with formation of Wirsung doesn't occur, there being instead two independent channels, a condition that predisposes to the development of AP, since pancreatic drainage happens to occur mostly by the minor papilla. It is estimated that 10% of the world population have this variant. The described case is interesting since, even though microlithiasis is the primary cause of the AP, the presence of a pancreas divisum certainly contributed to its greater severity.

#186 - Case Report

HORSE CHESTNUT DIETARY SUPPLEMENT INDUCED LIVER INJURY

Diogo Costa Santos, Graça Lérias, Isabel Madruga

Hospital de Egas Moniz - Centro Hospitalar Lisboa Ocidental, Lisbon, Portugal

Introduction

Natural dietary supplements widely available to the general population have increased in popularity throughout the last years. Few case reports associate these products with liver injury. Horse Chestnut supplements are commercialized for usage in peripheral vein disease.

Case description

A 70 year old male with hypertension and allergic rhinitis, medicated with irbesartan+hydrochlorothiazide and desloratadine, recently started an echinacea based dietary supplement. One week before admission the patient reported flu symptoms resolved with paracetamol 500 mg 8/8h taken for 2 days, prompting suspension of his dietary supplement. The patient was admitted for conjunctival icterus, white stool and choluria developed over 3 days. There was no history of adverse effects. Upon examination: icteric skin and sclera; no lymphadenopathies and abdominal palpation with no pain or palpable masses; AST 275 U/L; ALT 550 U/L; ALP 348 U/L; GGT 1451 U/L; total bilirubin 11.2 mg/dL; direct bilirubin 8.23 mg/dL; Lipase 37 U/L; no findings on abdominal ultrasound. Hepatic and cholestatic enzymes continued to rise with total bilirubin reaching 22 mg/dL. A self-limited generalized erythematous and punctiform rash including palms and soles developed. Metabolic, auto-immune and infectious causes were discarded by additional testing, including magnetic resonance cholangiopancreatography and upper endoscopic ultrasound. Due to the absence of hepatotoxicity reports regarding previously known medication, including echinacea, both the patient and his family were extensively inquired on several occasions about additional drug history, until the patient's wife remembered that other than the echinacea based supplement, an horse chestnut supplement was started one month prior and suspended a week before admission. After reviewing compatible literature, a diagnosis of drug induced liver injury due to horse chestnut dietary supplement was established. Soon after hepatic and cholestatic enzymes values progressively decreased with icterus, stool and urine resolution. Laboratory values reached normal values several weeks after the patient was discharged, during follow-up.

Discussion

Drug induced liver injury due to a horse chestnut dietary supplement is a benign self-limited rare idiosyncratic drug reaction apparent between 4 to 8 weeks after taking a single dose. A suspicion of drug induced hepatotoxicity caused requires an accurate drug history, including dietary supplements, considering their increasing popularity.

#194 - Case Report

SEVERE AND UNEXPECTED SILENT COAGULOPATHYLuis Ramos Santos¹, Vítor Magno Pereira², Manuela Lélis¹, Maria Da Luz Brazão¹¹ Internal Medicine Department, Hospital Central do Funchal, Funchal, Portugal² Gastroenterology Department, Hospital Central do Funchal, Funchal, Portugal**Introduction**

Abnormal coagulation test results with or without symptoms warrant investigation for underlying acquired or congenital bleeding disorder. Personal and family history and thorough physical examination are crucial. With increasing age, acquired and systemic diseases are the most likely etiologies.

Case description

62 year-old man observed in the emergency room with complaints of loose stools for a week, with no blood or fever. He recalled unspecified weight loss. Physical examination was normal. Prior history was unremarkable. He denied easy bruising or visible blood losses. Blood tests: leukocyte count of 6.1×10^3 , hemoglobin of 13 g/dL, a severely prolonged PT of 149.5s (double checked on different samples), sodium 138 mEq/L, potassium 3.2 mEq/L, normal renal and liver tests and C-reactive protein of 100 mg/dL. Ciprofloxacin was started and patient was admitted with provisional diagnosis of acute enteritis and prolonged PT for study. On admission: patient reported four floating loose stools a day for a month, and loss of 3kg with no fever. He reported having a "weak bowel" for years but did not value or correlate with any particular ingestions. Patient's parents were first-degree cousins and patient was married to a first-degree cousin as well. He had a sister and two first degree cousins with Celiac Disease (CD). With clinical suspicion of malabsorption syndrome further studies were ordered: albumin 21.5 g/dL, corrected calcium 8.8 mg/dL, phosphorus 1.88 mg/dL, normal thyroid function, ferritin 210 ng/mL, folic acid 0.82 ng/mL, cyanocobalamin 248 pg/mL, parathyroid hormone (PTH) 84.8 pg/mL, total vitamin D 9 ng/mL. This supported the diagnosis of malabsorption of liposoluble vitamins and proximally absorbed elements. Replacement was initiated including vitamin K with normalization of PT. Anti-tissue transglutaminase IgA tested positive. Upper endoscopy had no macroscopic changes. Duodenal biopsies showed partial villous atrophy, without increased intraepithelial lymphocytes and mild inflammatory infiltrate of the corion. Gluten-free diet was started. Follow-up visit at 1 month showed symptom and weight improvement, normal PT and almost complete resolution of PTH.

Discussion

Malabsorption can cause vitamin-K deficiency, and in this patient led to severe silent coagulopathy. This case illustrates the multitude of clinical and analytic findings of CD. Most atypical cases occur with increasing age so a high level of suspicion must be maintained to ascertain the diagnosis.

#197 - Medical Image

GIANT MESENTERIC CYST - THE DIAGNOSTIC CHALLENGE

Inês Soler Bargiela, Maria João Gomes, Ana Sofia Ventura
Hospital Prof. Doutor Fernando Fonseca, Lisboa, Portugal

Clinical summary

We present a case of a 70-year-old female patient, who was admitted for abdominal volume increase, corresponding to exuberant ascites, having performed paracentesis with increased serum albumin gradient and positive malignant cell. CT scans revealed a significant abdominal mass of about 100x100 mm suggestive of mesenteric cyst, located at the mesenteric root, and peritoneal secondary implants. After an extensive etiological investigation that culminated in diagnostic laparotomy, a high-grade serous carcinoma was diagnosed in the uterine isthmus, with invasion of the left ovary and mesenteric cyst, which histologically corresponded to hemorrhagic cyst with associated peritoneal carcinomatosis. Mesenteric cysts are rare abdominal tumors, with malignant degeneration occurring in 3% of cases.

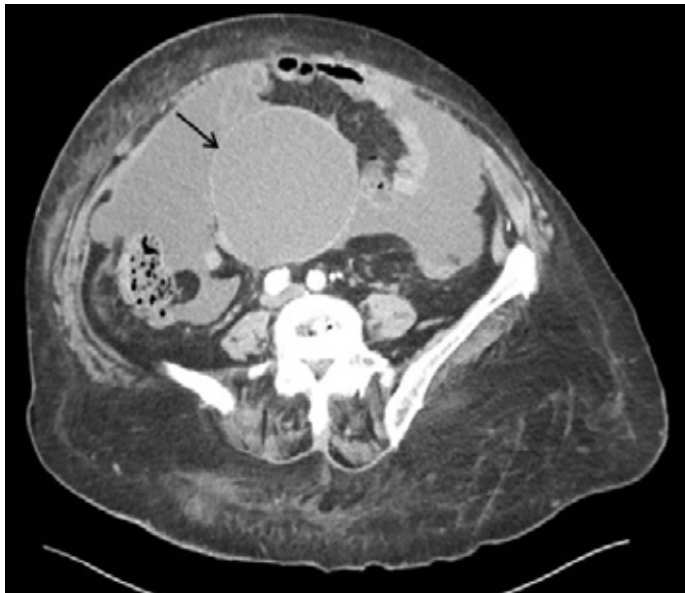


Figure #197.

#211 - Abstract

THE EFFICACY OF ANTI-TNFA THERAPY IS BETTER FOR STEROIDS NAÏVE PATIENTS WITH ULCERATIVE COLITIS

Tatsuya Toyokawa, Isao Fujita, Joichiro Horii
National Hospital Organization Fukuyama Medical Center, Fukuyama, Japan

Background

Although anti-TNF α therapy is known to be effective in the treatment of ulcerative colitis, there are few reports on who would benefit most from the therapy, when they should be prescribed and how anti-TNF α drugs should be used.

Methods

We enrolled 51 patients with ulcerative colitis undergoing treatment with anti-TNF α for over 6 months. We analysed efficacy, clinical backgrounds, therapeutic histories and laboratory data of the patients.

Results

We examined 51 patients included (30 males and 21 females) with the median age of 42 (range, 13-88) years. There were 25 total-colitis-type patients, 21 left-sided-colitis-type and 5 proctitis-type. 5-aminosalicylic acid drugs were prescribed for all patients, 32 patients received steroids, 9 had previous steroids therapy and 10 never had steroids therapy. Immuno-modulator agents were prescribed for 26 patients, calcineurin inhibitors for one and granulocyte apheresis therapy for 9. Regarding severity, 39 patients were moderate and 12 were severe. Infliximab was prescribed for 26 patients and adalimumab for 25 cases as the first anti-TNF α drug. The mean duration time from onset of disease to the prescription of anti-TNF α drug was 70 (range, 2-296) months. The mean white blood count was 9000 μ /ml, mean hemoglobin 11.6 g/dl, mean albumin 3.5 g/dl and mean C-reacting protein 1.75 mg/dl. With regard to endoscopic Mayo score, 18 patients were grade 2 and 33 were grade 3. Treatment was complete effective in 24 patients, effective (not complete) in 11 and not effective in 16. Four received surgery after anti-TNF α treatment because of disease progression.

Thereafter, we classified the patients into two groups: SN group (steroids naïve patients) and S group (patients with current or past steroids therapy). The frequencies of completely effective or effective in the SN group were significantly higher than in S group (SN group: complete effective, 8 patients, effective, 0 and not effective, 2; S group: complete effective, 16 patients, effective, 11 and not effective, 14; $p = 0.048$). There were significant differences in disease type and duration time from onset to the prescription of anti-TNF α drug; however, there were no differences in other factors, including disease activity and endoscopic findings between the two groups.

Conclusion

The efficacy of anti-TNF α therapy is better for steroids naïve patients with ulcerative colitis. This findings of this study can help in the development of an efficient therapeutic strategy against ulcerative colitis.

#224 - Case Report

CROHN'S DISEASE PRESENTING AS ACUTE ABDOMEN: CASE REPORT

Martim Baltazar Alçada¹, Guilherme Violante Cunha¹, Marina Boticario¹, Rita Aranha², Aluixa Lozada¹, Catarina Ivanova¹, Maria Filomena Roque¹

¹ Hospital de Santarém EPE, Santarém, Portugal

² Faculdade de Medicina Lisboa, Lisboa, Portugal

Introduction

Crohn's disease (CD) is an immune-mediated disease characterized by transmural inflammation of the bowel wall, and is often complicated by fistula formation, bowel perforation and abscess. Abdominopelvic (AP) abscess occurs in 10–30% of the patients with CD in the Western countries and can affect the peritoneum (including the pelvis) and retroperitoneum such as psoas abscesses

Case description

A 18-year-old female was admitted in our hospital with a history of pain in the right lower abdominal quadrant, distension, fever and vomiting for the last 2 days. She had no past history of weakness, anorexia, or diarrhea. Abdominal examination revealed the features of acute abdomen. A abdominal ultrasound was suggestive of ileal inflammatory disease. She was admitted and antibiotic was performed. A CT scan showed non-specific terminal ileal transmural thickening and an adjacent 4 cm mesenteric mass.

Discussion

Intra-abdominal abscess formation affects up to one third of patient's with CD. A mixture of aerobic and anaerobic organisms can be found in these abscesses. Treatment involves bowel rest, analgesia, antibiotics, percutaneous and/ or surgical drainage. Immuno suppressants should be held until the abscess is completely drained and infection controlled. Although symptoms of CD mimic many other abdominal conditions but it should be kept in back of mind as one of the causes of acute abdomen. A colonoscopy with biopsy confirmed CD. She had a successful management after 21 days of therapy with metronidazol plus piperacilin/tazobactam. She was discharged to the outpatient inflammatory bowel disease.

#232 - Abstract

ANALYSIS OF HSD17B13: TA ALLELIC VARIANT AS A PUTATIVE PROTECTIVE FACTOR TOWARDS HCC IN PATIENTS WITH AND WITHOUT CHRONIC HEPATITIS C

Martina Fazio¹, Carla De Benedittis¹, Michela Emma Burlone², Matteo Nazzareno Barbaglia¹, Rosalba Minisini¹, Mario Pirisi¹

¹ Università del Piemonte Orientale, Translational Medicine, Novara, Italy

² AOU Maggiore della Carità, Medicina Interna, Novara, Italy

Background

The PNPLA3 single nucleotide polymorphism rs738409 (C > G) is a major genetic factor for steatosis, fibrosis progression and hepatocellular carcinoma (HCC). In fact, carriers of the G allele with chronic liver disease are more likely to progress to cirrhosis and HCC, especially when affected by alcoholic or non-alcoholic fatty liver disease (NAFLD). However, these same patients have been shown to be relatively protected against developing cirrhosis

by carriage of the HSD17B13:TA variant (rs72613567)(Abul-Husn NS et al. N Engl J Med. 2018;378:1096-106). Since cirrhosis is by far the strongest risk factor for HCC, it is conceivable that such protection might extend to HCC. We aimed to verify this hypothesis.

Methods

The study population included N=728 patients, among whom N=246 had a diagnosis of HCC (Group 1; 135 with hepatitis C virus infection, HCV, 55%); N=180 HCV infected patients (Group 2) and 302 NAFLD (Group 3) patients had chronic liver disease with and without advanced fibrosis/cirrhosis, not complicated by HCC. Restriction fragment length polymorphism analysis was performed to determine the allelic variants frequency of PNPLA3 and HSD17B13.

Results

The PNPLA3:G frequencies were 0.40, 0.31 and 0.32 for Group 1, Group 2 and Group 3, respectively (p=0.004). The HSD17B13:TA frequencies were 0.21, 0.28 and 0.16 for Group 1, Group 2 and Group 3, respectively (p<0.001). The figure shows the distribution of PNPLA3 genotype frequencies, according to the presence or absence of HCC and HSD17B13 status. By considering only the subgroup of patients negative for HCV (N=416/728, 57%), similar results were observed: based on PNPLA3 genotype, patients with HCC were 22/118 (19%) vs. 10/55 (18%) (C/C), 35/131 (27%) vs. 21/55 (38%) (C/G), and 20/45 (44%) vs. 6/12 (50%) (G/G), among HSD17B13 wild-type (p=0.002) vs. HSD17B13 variant carriers (p=0.006), respectively.

Conclusion

The HSD17B13:TA allelic variant does not appear to decrease appreciably the risk of developing HCC conferred by carriage of the PNPLA3:G allele, neither among HCV positive nor among HCV-negative patients.

#261 - Case Report

MANAGEMENT OF A MASSIVE PLEURAL EFFUSION FOLLOWING ACUTE PANCREATITIS

Florence Dutertre, Nicolas Garin, Domenico Galasso, Riadh Ksontini

HRC Monthey, Monthey, Switzerland

Introduction

Peripancreatic collections are common following acute pancreatitis. Pleural effusions are a less frequent but potentially life-threatening complication of the disease.

Case description

A 57-years old man was referred for dyspnea. Past medical history was notable for acute pancreatitis two months ago, complicated by a left-sided pleural effusion, which resolved after temporary chest tube drainage.

At admission, the patient was afebrile, hemodynamically unstable, and in respiratory distress. There were dullness on percussion on the left hemithorax. Ultrasonography confirmed a massive pleural effusion. After chest tube insertion, 2000 ml of a fluid rich in lipase (140,000 U/L) were evacuated. A cholangio-MRI showed a fluid collection of the pancreatic tail, extending in the left pleura. Endoscopic ultrasonography confirmed the presence of a 13x4 cm fluid collection with partially solid content, characteristic of a walled-off necrosis (WON). During the procedure, a lumen-apposing metal stent was inserted through the stomach wall and allowed for rapid evacuation of the collection. A percutaneous gastrostomy was placed to facilitate drainage of the collection, and a nasoduodenal tube was inserted, allowing feeding of the patient while avoiding penetration of nutrients in the cavity. The patient was discharged home after 14 days. Three months later, he was in good clinical condition, with a weight gain of 3 kgs. A repeat cholangio-MRI confirmed the resolution of the WON. The stent and percutaneous gastrostomy were removed.

Discussion

Peripancreatic collections require drainage when they exert local compression or become infected. When feasible, endoscopic management is preferred over surgery.

Pancreaticopleural fistula is a rare complication following disruption of the main pancreatic duct. It manifests as a recurrent, mainly left-sided, pleural effusion, secondary to a retroperitoneal fistula tract extending through the diaphragmatic hiatus into the pleural space.

Endoscopic management requires evacuation of necrosis and exocrine secretion in the digestive tract through implantation of transmural stents under endoscopic and fluoroscopic guidance. A physiologic drainage of pancreatic secretions can also be restored through transpapillary stenting of the main pancreatic duct.

Finally, patients with acute or chronic pancreatitis have associated multifactorial malnutrition and need specialized nutritional support, preferably via the enteral route.

#267 - Case Report

CHRONIC HEPATIC DISEASE WITH SHORT TIME OF DEVELOPMENT

Rodrigo Rufino¹, Catarina Carvalho¹, Alexandra Albuquerque¹, Fátima Campante²

¹ Centro Hospitalar Barreiro-Montijo, Barreiro, Portugal

² Centro Hospitalar Barreiro Montijo, Barreiro, Portugal

Introduction

Autoimmune Hepatic Disease is a chronic inflammatory disease of the liver characterized by circulating autoantibodies, the most common are Anti-Nuclear antibodies (ANA), and elevated serum globulins. This disease is prevalent in women of any age and ethnicity. Clinical manifestations vary from asymptomatic to jaundice, ascites and splenomegaly, signals suggestive of cirrhosis or hepatic failure.

Case description

A 73 year old woman with a personal history of Gastroesophageal Reflux and Cholecystectomy due to Vesicular Lithiasis, was referred to an Internal Medicine Consultation due to dyspepsia and cutaneous pruritus, without jaundice, nausea or vomiting. She had elevation of aspartate aminotransferase (AST) 109, alanine aminotransferase (ALT) 95, gammaglutamyltranspeptidase (GGT) 95 and alkaline phosphatase (AF) 120. Total (BT) and direct (BD) bilirubin, serologies and abdominal ultrasound (ABUS) were normal. An analytical reevaluation with autoimmunity markers was requested and a follow-up consultation scheduled. The analyzes showed similar changes, with alpha-fetoprotein (AFP) 5.7, positive ANA and negative anti-mitochondrial antibodies.

After 3 months (before her next appointment), the patient is sent to the Emergency Department by her Family Doctor due to jaundice, associated with several months of anorexia and weight loss. Analytically with BT 15.1, BD 10.7, AST 695 and FA 669. Abdominal and pelvic computed tomography showed a small liver with bossy contours and a grossly structure and mild pelvic and peri-hepatic ascites. In this context, the patient was hospitalized and started treatment with ursodeoxycholic acid.

During hospitalization studies showed AFP 11.1, ANA 3.2, protein electrophoresis with gama elevation 21.5% and ABUS with liver of cirrhotic conformation with right lobe atrophy, bosselated contours, heterogeneous ecostructure by diffuse nodularity and peri-hepatic and peri-splenic ascites. Given these findings and the patients' worsening condition, a liver biopsy was attempted without success, opting to perform an evacuating paracentesis, with ascitic fluid without analytic changes. At this point, corticotherapy was initiated with improvement on discharge date. Currently, the patient is performing corticosteroid withdrawal and continues etiologic study in Hepatology Consultation.

Discussion

This case shows how a similar clinical phenotype can have different etiologies and evolution times, therefore it's important to be alert to not so frequent differential diagnosis.

#276 - Abstract

CORRELATIONS BETWEEN SERUM CREATININE, COCKROFT FORMULA AND DIRECT MEASUREMENT OF GLOMERULAR FILTRATION RATE TO LIVER TRANSPLANTATION

Marilena Stoian

Carol Davila University Of Medicine Bucharest, Bucharest, Romania

Background

Frequent impaired renal functions have a significant impact on early mortality risk, to patients with end-stage cirrhosis. Serum creatinine is one of 3 components of MELD score; however, patients with end stage cirrhosis frequently have muscular atrophy and water retention, which represent significant bias for

the interpretation of indirect markers of renal function. GFR is likely to be under or overestimated by these indirect markers.

Aims

To compare indirect markers of renal functions (SCr, Cockcroft formula and MDRD formula) to direct measurement of GFR in a population of cirrhotic patients listed for liver transplantation (LT).

Methods

91 candidates for LT (67 males, 24 females; mean age: 52 years) were studied. The cause of cirrhosis was alcohol in 48%, HBV in 11%, HCV in 27% and miscellaneous in 14%; 29% had hepatocellular carcinoma (HCC). All patients had direct measurement of GFR; mean MELD score in those without HCC was 17.

Results

SCr and calculated creatinine clearance according to Cockcroft formula were poorly correlated to measured GFR (R² of 0.3 and 0.4, respectively). Cockcroft formula overestimated creatinine clearance compared to direct measurement with a mean difference of 29±37 mL/min ($p < 0.001$). In 47% patients, there was a 30% or more overestimation of GFR with Cockcroft formula. Multivariate analysis showed that independent predictive factors for a 30% or more overestimation of GFR were low prothrombin index, young age and ascites ($p < 0.05$ for all). There was also a relatively poor correlation between calculated GFR using MDRD formula and direct measurement (R² of 0.5). In 24% patients there was a 30

Conclusion

SCr and calculated clearance using Cockcroft or MDRD formula are inaccurate markers of GFR in cirrhotic patients waiting for age, low prothrombin index (or increased INR) and ascites are significant risk factors for overestimation. Since renal function is crucial prognostic factor in cirrhotic patients, prognostic studies using measured GFR as a reference rather than SCr might help improve the performance of MELD score.

#315 - Abstract

CLINICAL PARTICULARITIES OF PORTAL VEIN THROMBOSIS IN ELDERLY PATIENTS

Doina Georgescu, Norina Basa, Mihaela Muntean, Oana Elena Ancusa, Daniel Lighezan

V Babes University of Medicine and Pharmacy, Timisoara, Romania

Background

Portal vein thrombosis (PVT) due to its diverse etiology and various clinical forms of presentation could sometimes be challenging even for experienced clinicians.

Methods

We conducted an observational study in 50 consecutive patients diagnosed with PVT, assigned into two groups, as matched pairs: 25 equally or over 65 years and 25 under 65 years. Clinical

examination, laboratory works - up, upper and lower digestive endoscopies, abdominal Duplex ultrasound, as well as CT and MRI were performed

Results

Older patients displayed significant differences concerning lower albumin level, liver malignancies and longer hospitalization, whereas comparison group showed significant differences related to admission as emergencies, digestive bleeding, abdominal pain, anticoagulant treatment (ACT) and underlying hematological diseases. No significant differences were recorded with regard to PVT severity, outcome and in hospital death. In older group we noted no correlation of outcome vs. age ($r = 0,0772$) and hospitalization length ($r = 0,03$), low correlation to albumin ($r = -0,1744$), digestive bleeding ($r = 0,1676$), ACT ($r = 0,2159$), PVT severity ($r = 0,2295$) and medium correlations to total bilirubinemia ($r = 0,2996$), emergency status at admission ($r = 0,3121$) and abdominal pain ($r = 0,3343$).

Conclusion

PVT in elderly was generally non occlusive, with good short-term outcome, mitigated symptoms, main causes being end stage liver conditions and liver malignancies. Short-term outcome in elderly was not related to age over 65 years per se, PVT severity or longer hospitalization, but more to emergency status at admission, abdominal pain and plasma total bilirubin. Causes of inpatient death in both groups were not associated to PVT severity, but to fatal cardio-vascular events.

#383 - Case Report

WHEN ALCOHOL IS NOT THE ONLY GUILTY

Joel Pinto, Paulo Almeida, Fani Ribeiro, Flávio Godinho, Daniela Meireles, Susana Cavadas

Centro Hospitalar do Baixo Vouga, Aveiro, Portugal

Introduction

The primary biliary cholangitis (PBC) is a rare autoimmune disease characterized by the destruction of the intralobular bile ducts. It manifests itself by signs of cholestasis, progressing to liver failure. Its cause is unknown, having genetic and environmental factors involved.

Case description

A 48-year-old man, with a history of chronic alcoholism, chronic liver disease (CLD), and chronic pancreatitis (CP), submitted to an endoscopic retrograde cholangiopancreatography (CP) 6 years before with placement of a temporary biliary prosthesis (BP), subsequently abandoning follow-up.

He was referred to the emergency department for uncontrollable vomiting and epigastric pain since the day before. He presented himself with icteric skin, soft abdomen, without fever or other changes in the physical examination. Blood tests revealed macrocytosis, thrombocytopenia (platelets $73 \times 10^9/L$),

international normalized ratio of 2.6, Aspartate transaminase 136 U/L, Alanine transaminase 31 U/L, Gamma-glutamyltransferase 318 U/L, Alkaline phosphatase 280 U/L, Total, Direct and Indirect bilirubin of 11.68, 6.07 and 5.61 mg/dL, respectively and without elevation of inflammatory markers. Abdominal ultrasound revealed diffuse hepatic steatosis, heterogeneous echo texture compatible with CLD, intrahepatic and extrahepatic bile ducts dilatation, without peritoneal effusion. He was presumed to have alcoholic hepatitis, with Maddrey score 71.9, being hospitalized under steroid therapy.

He presented a progressive reduction of cholestasis markers. The etiological study of CLD was extended, showing an increase in immunoglobulins M (282 mg/dL) and G (2600 mg/dL). Serologies for human immunodeficiency virus, A, B, C and E hepatitis were negative, as well as for Cytomegalovirus, Epstein-Barr virus, Herpes simplex 1 and 2. Antibody tests, including anti-mitochondrial antibodies (AMA) were all negative with exception for anti-Sp100 and anti-Ro52, which were positive. A magnetic resonance CP revealed changes compatible with CP and dilatation of intrahepatic biliary ducts. Previous implanted BP wasn't found. Liver biopsy was done and histological evaluation revealed chronic cholestatic syndrome compatible with PBC in cirrhotic stage. He was discharged medicated with ursodeoxycholic acid.

Discussion

With this case, authors emphasize the need of excluding other etiologies for CLD that can overlap with alcohol abuse. Absence of positive AMA does not exclude the diagnosis of PBC, since these may be absent in up to 5% of cases.

#386 - Case Report

A CURIOUS LIVER ABSCESS

Filipa Coroado Ferreira, João Paulo Vilas-Boas, Ines Pinheiro, Érica Ferreira, Clarinda Neves, Rosa Jorge
Centro Hospitalar do Baixo-Vouga, Aveiro, Portugal

Introduction

Liver abscesses are the most common type of visceral abscesses. Risk factors include diabetes mellitus, underlying hepatobiliary or pancreatic disease, liver transplant and regular use of proton-pump inhibitors. *K. pneumoniae* is a frequent pathogen and several studies have suggested an association with underlying colorectal cancer. It relates to portal vein pyemia, direct spread from biliary infection, surgical or penetrating wounds or from hematogenous seeding. Treatment usually includes drainage and antibiotic therapy.

Case description

A 78-year-old man recurred to the Emergency Department due to head injury, non-preferential gait imbalance and disorientation over the previous 2 days. He had dementia nevertheless, treated with donepezilo 10 mg od. He was feverish, tachycardic, hypotensive – severe sepsis. He had normocytic, normochromic

anemia, lymphopenia and thrombocytopenia, acute kidney injury, hepatic citolysis and elevated reactive C protein and procalcitonin. Cranioencephalic CT showed no traumatic or vascular lesions. Cerebrospinal fluid, urinalysis and chest X-ray had no suggestion of infection. Two blood cultures were performed and antibiotic therapy was started empirically with ceftriaxone 1g 12/12h. Abdominal ultrasound showed echogenic nodular lesion of 57mm diameter, requiring CT study. Because of maintenance of daily fever and elevation of inflammatory parameters, antibiotic therapy was altered to piperacillin/tazobactam 6/6h. The thoracoabdominopelvic CT was made and revealed an heterogeneous oval formation of the right hepatic lobe, with heterogeneous enhancement after IV contrast, with several liquid hypodense loci, surrounded by a capillary wall, with 80x68mm dimension, admitting the diagnosis of multiloculated hepatic abscess. No agent was identified on blood cultures. He evolved with clinical and analytical improvement with antibiotic therapy and no drainage was performed. After 4 weeks on piperacillin/tazobactam, antibiotherapy was altered to amoxicillin + clavulanic acid per os. A colonoscopy was performed, he had no alterations.

Discussion

The authors highlight this case for the unusual diagnosis and the lack of risk factors described by the literature for this pathology. There are few cases described with good resolution only with medical treatment, so the presentation of this case becomes relevant.

#394 - Abstract

CHRONIC LIVER DISEASE AND DIRECT ORAL ANTICOAGULANTS

Joana Arana Ribeiro, Andreia Póvoa Vicente, Tiago Silva, David Rabiço Costa, Lurie Pantazi, Rita Gomes
Unidade Local de Saúde da Guarda, Guarda, Portugal

Background

The management of anticoagulation therapy in Chronic Liver Disease (CLD) is challenging. The haemostasis and fibrinolysis are changed, due to alterations in production of anti/procoagulation factors, predisposing to haemorrhagic and thrombotic events. Furthermore, the liver metabolism of anticoagulants is modified, leading it to unpredictable levels.

The Direct Oral Anticoagulants (DOAC) are attractive in CLD, although phase 3 trials excluded CLD patients. The current usage is based on small studies.

The aim of this study is report the experience of an hospital with CLD patient taking DOAC, including haemorrhagic events and predictor of bleeding.

Methods

We reviewed clinical processes of Consultations in Liver Diseases and we identified and followed up the ones taking DOAC. CLD was defined based on history and/or evidence of

Chronic Liver Dysfunction visible through ultrasound providing by hepatomegaly and/or persistent abnormalities in liver test for more than 6 months. We registered age, sex, Charlson Index, CLD aetiology, haemorrhagic events, esophageal varices, INR, platelet count and antiaggregation therapy.

To test association between independent variables and haemorrhagic events, Cox regression analysis was performed.

Results

Of the 18 patients identified, the mean age was 68 year (SD 10.3), 13 (72.2%) were males and the Charlson Index mean was 5.5 (SD 2.1), corresponding 26% estimate 10 years survival. The most prevalent CLD aetiology was alcohol (15, 83.3%), followed by nonalcoholic steatohepatitis (1, 5.6%) and primary biliary cholangitis (1, 5.6%). they were taking dabigatran (6, 33.3%), apixaban (6, 33.3%), rivaroxaban (4, 22.2%) and edoxaban (2, 11.1%). The indications for DOAC were atrial fibrillation (11, 61.1%), portal vein thrombosis (2, 11.1%), pulmonary thrombosis (2, 11.1%) and renal artery thrombosis (1, 5.6%).

33.3% (n 6) of the patient had 1 or more bleeding episode that motivated a medical assist, at mean 20.8 (SD 20.8) months of DOACs. 2 of them were clinically relevant, both gastrointestinal with need for transfusions. We didn't register major bleedings.

There's no significant statistical predictors to bleeding events, namely DOAC type, time of anticoagulation, Charlson Index, esophageal varices, INR, platelet count and antiaggregation.

Conclusion

The current utilization of DOACs in CLD must be careful due to the unpredictability of these drugs in those patients, even if the major bleeding events seems to be low. Larger and robust studies are still needed.

#398 - Medical Image

DIGITAL CLUBBING

Joana Arana Ribeiro, David Rabiço Costa, Iurie Pantazi, Rita Gomes
Unidade Local de Saúde da Guarda, Guarda, Portugal

Clinical summary

The digital clubbing is one of the oldest clinical signs in medicine. It's characterized by enlargement of terminal fingers/toes segments and loss of normal 160° angle between nail and nail bed, caused by the proliferation of connective tissues between nail matrix and distal phalange.

The pathogenesis is unclear, but it's acceptable that platelet clusters in digital vasculature, enhanced by hypoxia, release PDGF and VEGF that induce angiogenesis and proliferation of fibroblasts and osteoblasts.

This sign often reflects a serious condition. Most commonly pulmonary diseases (90%), although it may be present in cardiac, gastrointestinal or endocrine disease.

These feet belong to a 51-year-old man with history of alcoholic cirrhosis hospitalized with diagnosis of portal vein thrombosis.

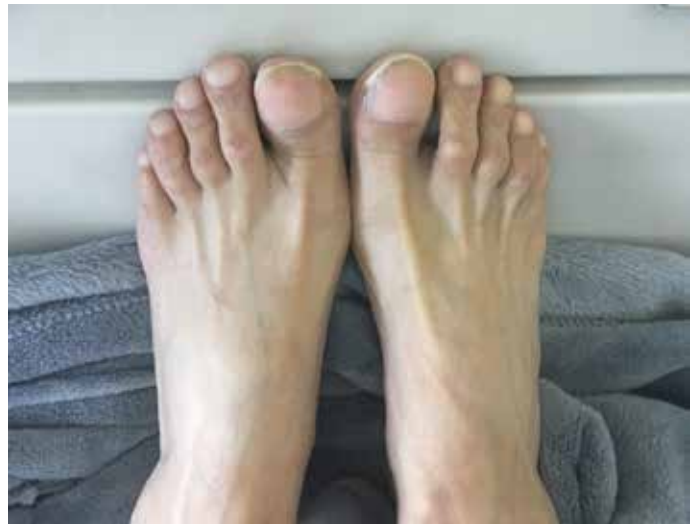

Figure #398.

#416 - Case Report

ACUTE HEPATITIS AT YOUNG AGES, A DIFFERENTIAL DIAGNOSIS

Joana Sousa Morais, Ana Andrade Oliveira, Olga Pires, Inês Burmester, Maria João Regadas, Paulo Gouveia
Hospital de Braga, Braga, Portugal

Introduction

Hepatitis is a disease that can manifest in several ways, the most common being jaundice and abdominal pain. The most common causes are infectious, however, especially in young patients, toxicity and immune diseases should also be taken into account. Some drugs can lead to the development of immune disease, called idiosyncratic reactions, especially when they are episodes of acute repeat disease.

Case description

A 30-year-old woman with a history of autoimmune thyroiditis and hospitalization 7 years ago, due to acute hepatitis, whose etiological study was inconclusive. Was referred to the emergency department for jaundice with two days of evolution, with no other complaints. She said she had been taking minocycline for a month, but stopped a week ago. In the complementary diagnostic exams, an increase in transaminases (alaninotransferase (ALT) - 1756U / L and aminotransferase (AST) - 1421 U/I), bilirubin at the direct cost (Total Bilirubin - 7.68 mg/dL), Alkaline Phosphatase - 208 U/L) and LDH (424 U/L). During hospitalization, the patient remained clinically stable, with jaundice at the objective examination, but no other alterations, and analytically with increase of bilirubin values reaching maximum values of 10 mg/dL, but stability of transaminases, AF and LDH in similar, without hepatic dysfunction or thrombocytopenia. From the rest study request to point out, serology and immunological study negative and normal imaging studies. However, at the end of one week of hospitalization, due to maintaining clinical picture and analytical aggravation, it was opted to initiate acetylsysteine (600 mg, 2x/day) and since then

with clinical and analytical improvement. With bilirubin values below 5 mg/dl, hepatic biopsy was performed and the patient was discharged for reassessment in consultation. In consultation, patient without jaundice, analytically bilirubin and transaminases values normalized and provided result of liver biopsy that has been shown to treat of toxic hepatitis.

Discussion

This is a case of a young patient with a second episode of acute hepatitis with an immune disease, who was medicated with minocycline, one of the drugs with the highest association with idiosyncratic reactions leading immunological liver disease and whose resolution of the clinical picture was quite time consuming. Therefore, exclusion of a non-toxic etiology is fundamental.

#421 - Abstract

ALTERED EXPRESSION OF DNA METHYLATION/HYDROXYMETHYLATION ENZYMES IN PATIENTS WITH AUTOIMMUNE HEPATITIS (AIH).

Pinelopi Arvaniti¹, Kalliopi Zachou¹, Aggeliki Lympelopoulou¹, Eirini Sevdali², Matthaios Speletas², Yves Renaudineau³, George N Dalekos¹

¹ Department of Medicine and Research Laboratory of Internal Medicine, University Hospital of Larissa, Larissa, Greece

² Department of Immunology and Histocompatibility, Faculty of Medicine, School of Health Sciences, University of Thessaly, Larissa, Greece

³ Laboratory of Immunology and Immunotherapy, INSERM UMR 1227, CHU de Brest, Brest, France

Background

AIH is a chronic liver disease of unknown aetiology, characterized by hypergammaglobulinemia, circulating autoantibodies, interface hepatitis on liver histology and favourable response to immunosuppression. Little is known about the impact of epigenetics on disease pathogenesis. The aim of our study was to assess potential epigenetic modifications in peripheral blood mononuclear cells (PBMCs) from patients with AIH through an altered expression of DNA methylation/hydroxymethylation enzymes.

Methods

PBMCs were isolated from 10 patients with AIH at diagnosis, 8 AIH patients at remission, 9 primary biliary cholangitis (PBC) patients followed at the Department of Medicine and Research Laboratory of Internal Medicine of Larissa University Hospital and 6 healthy controls (HC). CD19(+) B and CD4(+) T lymphocytes were isolated with positive and negative selection respectively, by ROBOSEP platform. The mRNA levels of DNA methyl-transferases (DNMT1, DNMT3A, DNMT3B) and Ten-Eleven Translocation (TET) enzymes (TET1, TET2, TET3) were determined by quantitative real-time PCR.

Results

Regarding CD4(+) T cells, AIH patients at diagnosis (n=10) were characterized by increased DNMT3A expression (p=0.007 and p=0.001) and reduced TET1 expression (p=0.03 and p=0.02) compared to HC and PBC patients respectively. The same significant findings were observed in CD19(+) B cells concerning DNMT3A and TET1 expression. No differences in DNMT1, TET2 and TET3 levels were observed between AIH patients and HC, while DNMT3B levels were beyond the detection threshold so no further analysis was made. DNMT3A and TET1 levels in CD4(+) T cells were correlated with circulating IgG levels (r=-0.673, p=0.05; and r=0.715, p=0.03, respectively), and a trend was observed for DNMT3A in CD19(+) B cells (r=-0.600, p=0.08). In contrast no association with other clinical, biochemical and serological parameters was observed. Interestingly, the increased DNMT3A expression was reversed after treatment administration in PBMCs of the 8 AIH patients at remission in both cell populations (p=0.025 for both CD19(+) and CD4(+) cells).

Conclusion

Altered expression of DNMT3A and TET1 characterizes immune cells from patients with AIH. The abnormal expression of DNMT3A is reversible after achieving complete remission a fact that could be amenable to novel therapeutic interventions.

#432 - Case Report

NON-CIRRHOTIC PORTAL HYPERTENSION

Catarina Parente, António Cardoso, Fátima Campante
Centro Hospitalar Barreiro Montijo, Barreiro, Portugal

Introduction

Liver cirrhosis is the most common cause of portal hypertension, but there are other etiologies collectively termed non-cirrhotic portal hypertension, including, primary biliary cholangitis or Budd-Chiari syndrome.

Idiopathic non-cirrhotic portal hypertension occurs when there is no attributable cause identified, and may be secondary to autoimmune diseases, infectious, drug, genetic or thrombophilic causes.

Case description

A 53-year-old male patient, with no relevant personal history, presented to the Emergency Department for hematemesis with 2 isolated episodes of bright red blood vomit with clots. He also reported black stools for a week-long and the taking of anti-inflammatories due to lumbar pain.

The complementary study detected anemia requiring transfusional support and the endoscopic study revealed ulcerated gastric variceal cord. Posteriorly, abdomino-pelvic computed tomography (CT) showed dilatation of the suprahepatic veins, enlargement of portal and splenic vein caliber, and extensive collateral circulation - aspects compatible with portal hypertension - liver with regular contours and conserved dimensions. Thrombosis of

the portal venous system was excluded by abdominal Doppler ultrasonography. There were no changes in liver function laboratory parameters.

After discharge, the patient continued investigation, with serologies, autoimmunity, parasitological examination of feces, ferritin and ceruloplasmin assays, hepatic magnetic resonance imaging and angiography, which did not reveal alterations beyond those already identified in CT.

Hepatic biopsy was proposed and the patient refused.

Discussion

Idiopathic portal hypertension is established by diagnosis of exclusion, implying the identification of unequivocal signs of portal hypertension, absence of hepatic veins and portal vein thrombosis, and absence of cirrhosis or advanced fibrosis confirmed by biopsy. This case report demonstrates the diagnostic challenge with a patient who refuses an invasive approach, emphasizing, however, the absence of significant implications in the therapeutic management and allowing the discussion of alternative diagnostic methods with a greater degree of acceptability for patients as in transient hepatic elastography.

Idiopathic non-cirrhotic portal hypertension is a rare cause of portal hypertension requiring a high degree of clinical suspicion for the early identification of the pathology and institution of therapy in order to avoid potentially serious complications of the disease.

#433 - Case Report

CHRONIC HEPATITIS B INFECTION AND HEPATOCELLULAR CARCINOMA IN A NON-CIRRHOTIC LIVER

Catarina Parente, António Cardoso, Fátima Campante
Centro Hospitalar Barreiro Montijo, Barreiro, Portugal

Introduction

Chronic hepatitis B virus (HBV) infection is an important cause of hepatocellular carcinoma (HCC) associated with either a process of integrating viral genetic material into the host cell genome or a sustained inflammatory state with necrosis and high rate of cell regeneration that promotes chronic changes of the organ itself with accumulation of mutations that ultimately cause neoplastic lesions.

Case description

A 45-year-old male, a native of Guinea-Bissau, with a history of moderate ethanolic habits that had ceased about 6 months prior to admission, presented to the emergency department for abdominal pain located in the upper quadrants with two weeks of evolution. The physical examination showed only sensitivity to palpation of the right hypochondrium and the abdominal ultrasound revealed two nodular lesions described as non-draining abscesses, in a normodimensional liver without other alterations.

The patient was admitted for intravenous antibiotic therapy.

Serological tests for HBV antigens (HBs, HBc and Hbe) were requested with a positive result, with subsequent assay of HBV viral load, which was greater than 2,000 IU/mL.

Magnetic resonance imaging was performed for evolutionary control and for better characterization of the hepatic lesions that showed solid nodular lesions with enhancement characteristics suggestive of HCC.

The patient was then referred to Hepato-Biliary Surgery, having been oriented for chemoembolization.

Discussion

The present case report is illustrative of the importance of complementary diagnostic tests in current clinical practice and in therapeutic orientation, as well as the particularity of a case of multifocal HCC in a non-cirrhotic liver, highlighting the direct oncogenic effects of hepatitis B virus independent of its pathogenic effects closely related to chronic inflammatory changes and repeated cellular regeneration leading to cirrhosis and carcinogenesis.

#458 - Case Report

ACUTE ALITIASIC CHOLECYSTITIS AS UNUSUAL PRESENTATION OF HEPATIC SARCOIDOSIS ASSOCIATED TO SJÖGREN SYNDROME

Alessandro Croce, Alice Pirovano, Erika Zecca, Mattia Bellan, Mario Pirisi, Rachele Rapetti
Ospedale Maggiore della Carità, Novara, Italy

Introduction

Sarcoidosis (SS) is a multisystemic disease characterized by the presence of noncaseating granulomas usually non necrotizing, but sometimes described necrotizing too. It can affect any organ, with prevalence of lungs and lymph nodes. Hepatic SS is reported in 50-65% of cases, mostly asymptomatic. SS can occur together with Sjögren's Syndrome (SjS), an autoimmune disorder characterized by reduction of gland excretion.

Case description

A 55-year-old woman with a history of hypothyroidism, mild xerostomia and xerophthalmia, and fatigue since 9 months, developed acute onset of fever during a holiday in Corsica, with alteration of liver biochemistry tests (LBTs) and abdominal bulkiness. She was then transferred to an Italian surgery for suspected acute cholecystitis. Abdominal ultrasonography and computed tomography (CT) were performed: enlarged liver, some enlarged hepatic hilar lymph nodes, a mild splenomegaly and pericholecystic effusion were found. After starting antibiotic therapy LBTs improved, but a liver biopsy showed necrotizing granulomas made up by giant multinucleated cells with eosinophilic infiltration. Infectious diseases were excluded since serologies for HIV, HAV, HBV, HCV resulted negative; screening for autoimmune diseases revealed ANA 1:320, granular pattern; anti-

Ro60>27496 CU and anti-Ro52 417,3 CU; ANCA, anti-β2GP1, anti-cardiolipin negative; Shirmer test was positive; respiratory function tests and echocardiogram were normal. After 1 month, at a new CT scan and a PET non homogeneous pathological tissue at the hepatic hilum, wrapped around vena cava and also near small gastric curvature was seen, and was consistent with colligated adenopathies. Also EGDS and laparoscopy with multiple biopsies from liver and ilar lymph nodes were performed, and confirmed results of necrotizing granulomas. A diagnosis of SS was finally made and steroids were started.

Discussion

Acalculous cholecystitis is typically seen in patients who are hospitalized and critically ill, but it is also possible in outpatient setting in cases of risk factors or several underlying chronic diseases, such as immune-mediated disorders. SS should be suspected in patients with lymphadenopathy, manifestations of SjS and acalculous cholecystitis, once other diseases have been excluded. The decision to treat gastrointestinal SS is based upon the activity and extent of disease. For symptomatic patients steroids are the treatment of choice.

#462 - Abstract

VONOPRAZAN VERSUS PROTON PUMP INHIBITORS FOR THE MANAGEMENT OF GASTRIC ENDOSCOPIC SUBMUCOSAL DISSECTION-INDUCED ARTIFICIAL ULCER: A SYSTEMATIC REVIEW

Beom Jin Kim, Hyun Kang, Jae Gyu Kim

Chung-Ang University Hospital, Seoul, South Korea

Background

There is a growing number of reports comparing the effectiveness of a novel potassium-competitive acid blocking agent called vonoprazan with that of PPIs in treating ESD-induced ulcers. However, the findings have been variable, and reported outcomes are conflicting. Furthermore, no previous systematic review and meta-analysis has been published regarding this issue. Therefore, we have performed a systematic review and meta-analysis to assess and compare the effects of vonoprazan and PPI in the treatment of ESD-induced artificial ulcers and prevention of delayed bleeding in randomized clinical trials (RCT) and cohort studies.

Methods

We searched OVID-MEDLINE, EMBASE, Cochrane Central Register of Controlled Trials (CENTRAL), Google Scholar, and clinical trial registries in April 2018 to identify all studies that assess and compare the effects of vonoprazan and PPI in treating ESD-induced artificial ulcers and preventing delayed bleeding. Primary outcome of ulcer healing rate and secondary outcomes of shrinkage rate, ulcer size, and delayed bleeding were studied.

Results

A total of 1265 patients from 12 studies was included in the final analysis. Healing rate at 4 weeks post-ESD was significantly higher in the vonoprazan group than in the PPI group (RR 1.20 (1.03–1.40)). However, healing rate at 8 weeks post-ESD was significantly higher in the PPI group than in the vonoprazan group (RR 0.68 (0.48–0.97)).

There was no evidence of significant difference between groups in shrinkage rate at 4 weeks post-ESD, shrinkage rate at 8 weeks post-ESD, delayed bleeding, ulcer size at 0 weeks post-ESD, and ulcer size at 8 weeks post-ESD.

Conclusion

There was no substantial difference in ulcer healing and post-ESD bleeding between vonoprazan and PPIs. However, vonoprazan more rapidly and effectively treated artificial ulcers after ESD than did PPIs.

#469 - Case Report

COEXISTENCE OF H63D HETEROZYGOSITY AND ALPHA-1 ANTITRYPSIN DEFICIENCY IN A PATIENT WITH IRON OVERLOAD

Carolina Teles¹, Carlos Dias Da Silva¹, Teresa Vaio^{1,2}, Armando Carvalho^{1,2}

¹ Centro Hospitalar e Universitário de Coimbra, Coimbra, Portugal

² Faculdade de Medicina da Universidade de Coimbra, Coimbra, Portugal

Introduction

Multiple etiologies are responsible for liver iron overload. Hereditary hemochromatosis, an autosomal recessive condition predominantly caused by mutations in the HFE gene (C282Y and H63D), stands out as the most frequent one. H63D heterozygous patients rarely have clinical manifestations. Coexistence of alpha-1 antitrypsin deficiency is uncommon and may contribute to the development of liver siderosis in these cases.

Case description

43-year-old male patient referred for an Internal Medicine consultation due to hyperferritinemia (1458 ng/mL). Asymptomatic. Plethoric face and malar telangiectasia were visible on physical examination. He had a personal history of hepatic steatosis, chronic alcoholism, arterial hypertension, dyslipidemia and infertility. Laboratory studies showed normal hepatic enzymes and function, decreased alpha-1 antitrypsin, ferritinemia of 699 ng/mL, transferrin saturation at the normal upper limit, as well as negative serologies for hepatotropic viruses and liver autoimmune disease. Genetic testing revealed H63D heterozygous mutation and homozygosity for the PI*S allele of the alpha-1 antitrypsin gene. Abdominal ultrasound showed hepatic steatosis, with F0-F1 fibrosis and S2 steatosis on Fibroscan. Hepatic Magnetic Resonance Imaging confirmed liver iron overload with an iron concentration of 128 (± 20) μmol/g. Respiratory function tests were normal. Thoracic Computed Tomography showed a

tracheal diverticulum and small subsegmental atelectasis, without panlobular emphysema. Treatment with monthly phlebotomies was initiated, normalizing ferritinemia after 12 months, without anemia.

Discussion

This is a patient with H63D heterozygosity and alpha-1 antitrypsin deficiency with confirmed liver iron overload, suggesting the potential relevance of this coexistence. In addition, fatty liver disease likely had a contributory role in the development of hyperferritinemia and liver siderosis. Therefore, this case highlights the importance of the etiological association in liver disease, which may potentiate the expression or exacerbation of clinical manifestations.

#471 - Case Report

THE IMPORTANCE OF BEING WARY LEADING TO THE DIAGNOSIS OF PRIMARY SCLEROSING CHOLANGITIS

Maria João Correia, Catarina Mateus, Renato Guerreiro, Cândida Fonseca, Luís Campos

Hospital São Francisco Xavier - CHLO, Lisboa, Portugal

Introduction

Primary sclerosing cholangitis (PSC) is a chronic cholestatic disease characterized by inflammation, fibrosis, and stenosis of intra and extrahepatic bile ducts, leading to terminal liver disease. Two thirds of patients with PSC have concomitant inflammatory bowel disease (IBD), most often ulcerative colitis (UC).

The clinical presentation of PSC is heterogenous - from totally asymptomatic, only analytical alterations of the liver tests, to exuberant symptoms related to hepatic cholestasis. Magnetic resonance cholangiopancreatography (MRCP) is the preferred diagnostic method, with high sensibility and specificity.

There are multiple PSC complications, highlighting the high incidence of neoplasia (mainly hepatic, gallbladder and colon). Liver transplantation is the only effective therapy.

Case description

A 79-year old man with personal history of hypertension, UC, chronic obstructive pulmonary disease and bronchiectasis. He was admitted at the hospital for watery diarrhea, nausea and fever, associated with gait imbalance in the previous 2 days. No major alterations to the physical examination. The laboratory work showed elevation of inflammatory parameters (leukocytosis, CRP of 24.9 mg/dL, ferritin of 2705 ng/mL), and hepatic cholestasis with normal bilirubin. Abdominal ultrasound was normal. An aggravation of UC was excluded. Given the resolution of diarrhea and no clear signs of infection there was no need to start antibiotic therapy. He underwent thoraco-abdominal-pelvic CT, in which hepatosplenomegaly stands out, with microcysts compatible with irregularities of the caliber of intrahepatic bile ducts. Since there was clinical improvement

and resolution of inflammatory parameters with symptomatic therapy, it was decided to complement an outpatient study to clarify the suspicion of PSC. The MRCP revealed a pattern suggestive of PSC, with irregularities of the left main intrahepatic biliary branch, characterized by segmental ectasias, and zones of annular stenosis. After confirming the diagnosis he was referred to gastroenterology consultation for follow-up interventions.

Discussion

This is a case of fever with no clear focus, since the patient presented to us with nonspecific clinic and alteration of liver tests, reason why a high level of suspicion was necessary for the diagnosis. Given the association of IBD and PSC, it was possible to timely diagnose a rare pathology, which will modify the patient's prognosis requiring a closer clinical surveillance.

#476 - Case Report

FROM INFECTION TO CROHN DISEASE

Francisco Lopes Morgado, Bárbara Saraiva, João Costa, Celestina Blanco Torres, João Correia

ULS Guarda, Guarda, Portugal

Introduction

The internist is in a privileged position for the best approach to systemic pictures. We present the case of a patient whose acute event served as the starting point for the diagnostic march of a chronic disease, which, being relatively common and well-known, is sometimes forgotten due to its clinical variability.

Case description

A 25-year-old man admitted in the Emergency Department (ER) with generalized arthralgia, anorexia and fever. There is a previous history of recurrences to the ER due to diarrhea, abdominal pain and fever during the last month, as well as recent contact with rural animals and a tick bite 2 weeks before the admission. No known personal history other than multiple episodes of diarrhea throughout adolescence as well as frequent episodes of arthralgia. Examination showed painful complaints in the lumbosacral spine and wrists, with functional impotence and aggravation with mobilization, without any other relevant findings. Complementary study revealed a significant increase of inflammatory parameters as well as a Weil-Felix positive test.

Taking these findings into account, the patient was hospitalized with the presumed diagnosis of Mediterranean Spotted Fever and treatment started accordingly.

During hospitalization, the patient presented a rapid resolution of the febrile condition accompanied by a gradual descent of the inflammatory parameters, but with persistent arthralgia, as well as episodes of bloody diarrhea. By this time serologic studies confirmed the diagnosis of admission. Bacteriological and parasitological study of faeces was negative and fecal calprotectin was greatly increased; endoscopic gastrointestinal exams only revealed nonspecific ileal changes suggestive of ileitis.

These findings allowed the diagnosis of enteropathic arthropathy related to a probable underlying Crohn disease. Induction therapy was successfully performed the patient was discharged for ambulatory follow-up under maintenance therapy.

At the follow-up consultation the rest of the autoimmune study was compatible with Crohn Disease as well as the associated presence of Sjogren's syndrome.

Discussion

Crohn disease is one of the major intestinal inflammatory conditions with the particularity of being able to involve any portion of the digestive tract. In spite of this, there are frequent extra-intestinal manifestations. For this reason, its diagnosis should not only be based on complementary tests, but also in a detailed clinical history, especially during its initial course.

#480 - Abstract

PATIENTS WITH CIRRHOSIS PRESENT A VERY LOW ADHERENCE TO NUTRITIONAL RECOMMENDATIONS: RESULTS FROM A PROSPECTIVE OBSERVATIONAL STUDY

Francesco Palmese¹, Ilaria Bolondi¹, Ferdinando Antonino Giannone², Maurizio Baldassarre³, Giacomo Zaccherini¹, Manuel Tufoni¹, Silvia Boffelli¹, Sonia Berardi⁴, Franco Trevisani¹, Paolo Caraceni¹

¹ Department of Medical and Surgical Sciences, Alma Mater Studiorum University of Bologna, Bologna, Italy

² Support Services and People Care, General Direction, S.Orsola-Malpighi University Hospital, Bologna, Italy

³ Center for Applied Biomedical Research (C.R.B.A.), Alma Mater Studiorum University of Bologna, Bologna, Italy

⁴ Department of Care of Organ Failures and Transplants, Internal Medicine for the Treatment of Severe Organ Failures, Sant'Orsola-Malpighi University Hospital, Bologna, Italy

Background

Malnutrition is a frequent complication in patients with cirrhosis but still remains underestimated and often untreated, affecting the global prognosis of patients.

Patients with cirrhosis represent a very heterogeneous population in terms of nutritional requirements, which can be determined only through a personalized assessment of the complex interaction between their nutritional status and clinical condition.

The aim of the study was to evaluate the level of patients' adherence to the current international nutritional recommendations adapted to the individual clinical status.

Methods

192 outpatients with cirrhosis were prospectively evaluated. 161 were considered at risk of impaired nutrition as they present at least one of the following factors: altered body mass index score, non-volitional body weight changes, ascites, peripheral edema, hepatic encephalopathy, or diabetes. Patients at risk were offered

a nutritional assessment by a certified specialist, including a 3-days food diary and hand-grip strength (HGS) test. Only 78 patients returned the diaries properly filled in.

Results

The analysis of food diaries showed a low-level adherence to the nutritional recommendations: caloric intake was insufficient, in excess and adequate in 75%, 13% and 12% of cases, respectively. An appropriate consumption of carbohydrates, protein and fibers was found only in 10-15% of cases, while the intake of simple sugars, lipids, and water resulted adequate in up to 55%. The protein intake was more frequently insufficient in patients with more advanced disease. HGS test was altered in 49% of patients, without significant correlations with macronutrient intakes. Twenty-seven subjects (17%) refused the nutritional assessment: these patients presented a significantly less severe disease and a lower number of risk factors.

Conclusion

This observational study shows that patients with cirrhosis present a very low adherence to the nutritional recommendations. This can be explained both by the limited knowledge on foods and by the lack of an educational program on nutrition. These results highlight the importance of a nutritional intervention tailored to the needs of the individual patient as part of a multidisciplinary approach. Finally, this nutritional intervention should start from the initial stage of the disease, when lower is the awareness of patients and higher the probability of success in positively influencing patient's prognosis and quality of life.

#484 - Abstract

DECOMPENSATED ALCOHOLIC LIVER CIRRHOSIS IN AN INTERNAL MEDICINE DEPARTMENT

Ana Teresa Goes

Hospital Litoral Alentejano, Santiago Do Cacém, Portugal

Background

Alcoholic liver cirrhosis is an important public health problem in Portugal. Recent studies have revealed that in 15 years more than 80 000 patients with cirrhosis of the liver have been hospitalized, of which 85% with alcoholic cirrhosis, with long hospitalizations and high mortality. Liver disease is the fifth leading cause of death, according to data from Direção Geral de Saúde (DGS).

With this study the author aims to characterize the hospital admissions for decompensated alcoholic liver cirrhosis in an Internal Medicine Service (IMS) during a three-year period.

Methods

A retrospective observational study with a reference period from January 2014 to December 2016, through consultation of clinical processes of the hospitalized patients with the main diagnosis of alcoholic liver cirrhosis in an IMS.

Results

A total of 47 cases were analyzed, covering 31 patients (93.62% men), with a mean age of 62.23 years (minimum 44, maximum 84). The mean length of hospital stay was 12.11 days (minimum 3, maximum 46). The most prevalent cause of alcoholic liver cirrhosis decompensation was hepatic encephalopathy (42.55%), followed by ascites (21.28%) and spontaneous bacterial peritonitis (14.89%). It should be noted that in most cases alcohol consumption remained active (59.57%). There were nine deaths, most in the context of progression of the underlying disease (55.56%).

Conclusion

The complications resulting from alcoholic cirrhosis require important health care and consume many economic resources, with great emphasis in Portugal, registered as the eleventh country with the largest consumption of alcohol worldwide. Alcoholic liver disease has a great impact on hospital admissions, with high complexity and mortality, as confirmed by the data analyzed, also reflecting the need for a multidisciplinary and constant approach, before, during and after hospitalization.

#491 - Medical Image

SCLEROSING MESENTERITIS AS CAUSE OF ABDOMINAL PAIN

Nina Jancar, Filipa Gonçalves, Mariana Simões, Patricio Aguiar, José Luís Ducla Soares

Hospital de Santa Maria, CHLN, Lisbon, Portugal

Clinical summary

A 67 year old patient, with a history of rectal adenocarcinoma (T3N2M0, stage IIIb), submitted to anterior resection of the rectum with ileostomy in 2018, admitted to the hospital due to periumbilical pain (without any trigger or aggravating factors), post-prandial vomiting, within the three previous days, acute kidney injury (AKIN II) of pre-renal etiology and a rise in inflammatory parameters. An abdominal and pelvic CT scan was performed and it showed: "densification of mesenteric fatty tissue and small mesenteric ganglia (sclerosing mesenteritis), densification of pre-sacral fatty tissue and a small herniation of mesenteric fatty tissue", thus confirming the diagnosis of sclerosing mesenteritis in the context of recent surgical intervention as cause of abdominal pain.

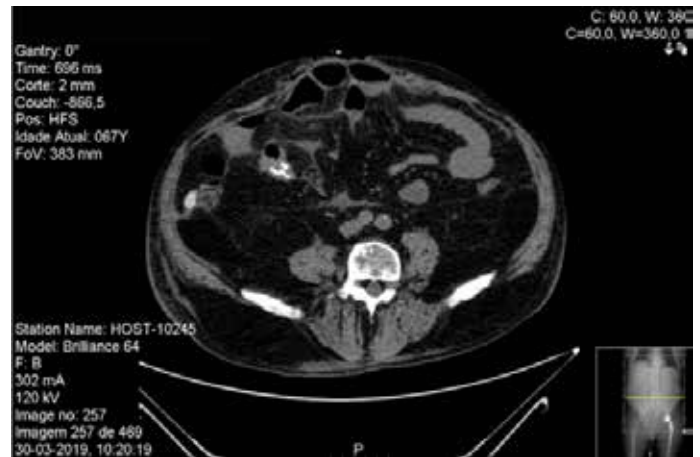

Figure #491. Sclerosing mesenteritis as cause of abdominal pain.

#514 - Medical Image

MORGAGNI HERNIA - AN INCIDENTAL DIAGNOSIS.

Gonçalo Mesquita, Vera Seara, Sónia Fernandes, Luciana Faria, Catarina Patronillo, Juliana Xu, Luísa Guimarães
Centro Hospitalar Póvoa de Varzim - Vila do Conde, Vila Do Conde, Portugal

Clinical summary

An 85-year-old woman presents herself to the emergency department after an episode of syncope with amnesia for the event. The postero-anterior chest X-ray (Figure 1) shows bowel loops in the right hemithorax, retrosternal located by the right lateral radiograph (Figure 2). A CT scan of the thorax revealed a Morgagni hernia to the right, with the hepatic angle of the colon in the hernial sac. After a period of surveillance, the patient was asymptomatic. Conservative treatment and surveillance were decided. Morgagni hernia is very rare, comprising about 3% to 5% of all types of congenital diaphragmatic hernias. It is usually diagnosed during childhood but, may remain asymptomatic until adulthood. Its diagnosis may be incidental to unrelated events when a chest X-ray is performed.

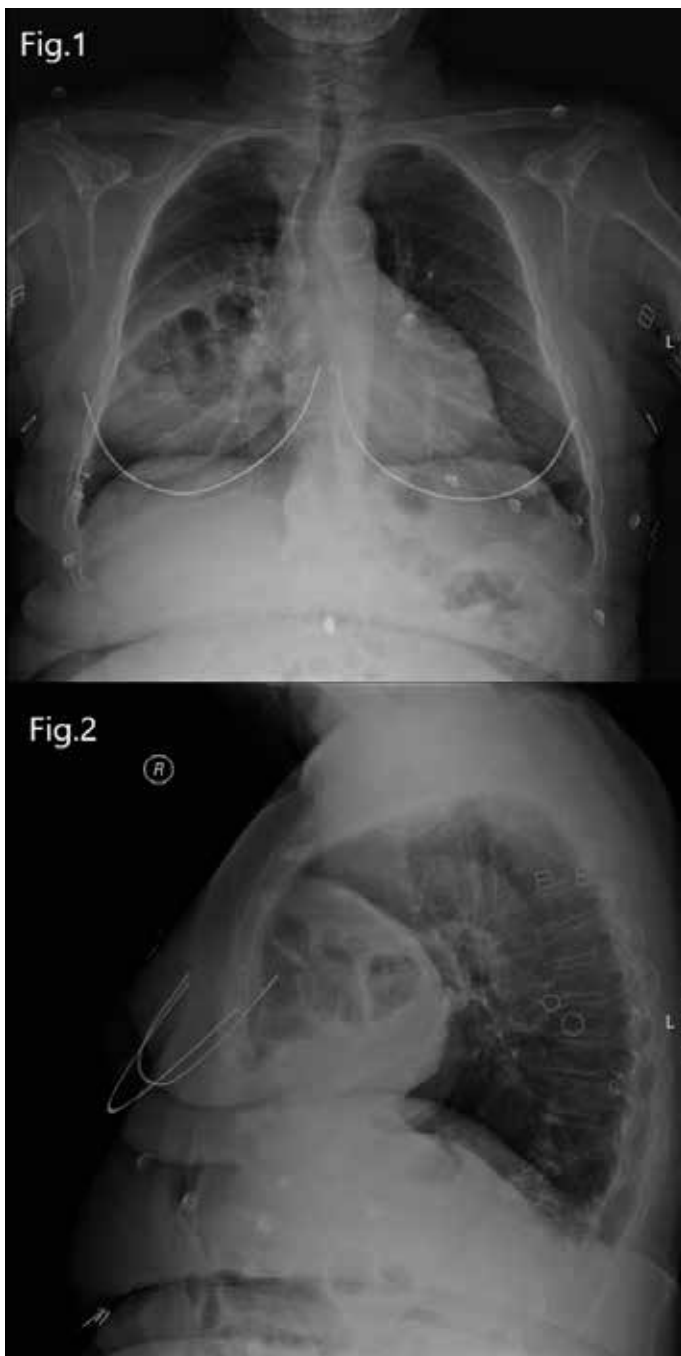


Figure #514.

#519 - Abstract

CARDIOVASCULAR STUDY AND EVALUATION OF SUBCLINICAL ARTERIOSCLEROSIS IN PATIENTS WITH NON-ALCOHOLIC FATTY LIVER DISEASE

Mario Salcedo^{1,2}, Sergio Palacios-Fernández^{3,2}, Natalia García Morales¹, María Sahuquillo Serrano¹, Jon Ortiz Carrera¹, Ángela Zaragoza¹, Cristina Campo¹, Carmen Morata¹

¹ Hospital Universitario y Politécnico La Fe, Valencia, Spain

² Universidad de Valencia, Valencia, Spain

³ Hospital Clínico Universitario San Juan de Alicante, San Juan De Alicante, Spain

Background

NAFLD represents the most common chronic liver disease. A relationship with CVD has been described. NASH is currently considered the liver manifestation of the metabolic syndrome; however, it is emerging as a possible independent risk factor for CVD. Objective is to describe the epidemiology of the various cardiovascular risk factors (CRFs) in nonalcoholic fatty liver disease (NAFLD) and to assess their relationship with subclinical atherosclerosis.

Methods

We prospectively studied 68 adult patients diagnosed with NAFLD through liver biopsy. The histological findings were classified according to the FLIP (fatty liver inhibition of progression) Pathology Consortium algorithm based on the SAF score (Steatosis, Activity, Fibrosis).

We studied the prevalence of the following CRFs: hypertension, dyslipemia, diabetes, metabolic syndrome and hyperuricemia.

The study of subclinical atherosclerosis was based on three noninvasive tests and following the 2013 guidelines on hypertension of the European Society of Hypertension:

- Doppler ultrasonography of the supra-aortic trunk (SAT) through mode B ultrasonography of the arterial wall in both carotid arteries, assessing the intima media complex thickness (IMT) following the recommendations of European Guide of Hypertension 2013 (pathological if >0.9 mm and atheromatous plaques are present)
- Study of arterial stiffness through tonometry by flattening using a pressure transducer connected to a SphygmoCor® device measuring the pulse wave velocity (PWV) (pathological if >10 m/s)
- Ankle brachial index (ABI) using a double-digit oscillometer (considered pathological if <0.9)

Results

78.4% of the study patients were diagnosed with nonalcoholic steatohepatitis (NASH) and 21.6% were diagnosed with steatosis. 64.9% of the patients had metabolic syndrome, 64.9% dyslipemia, 59.5% hypertension, 45.9% diabetes and 10.89% hyperuricemia. 16.2% were smokers.

There were atheromatous plaques in 24.3% of the patients and abnormalities in the intima-media complex in 35.1%. 35.1% of the patients had an increase in the PWV, and 5.4% had a pathological ABI.

Conclusion

As conclusion, our study shows patients with NAFLD had high prevalence of CVF and a moderate-high rate of subclinical atherosclerosis, supporting the current evidence of a close relationship among the NAFLD and the CVD.

#540 - Case Report

VON MEYENBURG COMPLEXES. CASE REPORT

Juan Francisco Barrios, Luis Benjamin Godínez, Gabriel Antonio Ríos

Instituto Guatemalteco de Seguridad Social, Guatemala, Guatemala

Introduction

The bile duct hamartoma or Von Meyenburg complex is a rare hepatic lesion consisting of a deformation and disorganization of the bile ducts, forming cystic structures that vary in size. These cysts come from the biliary tract, but the cysts do not communicate with them.

Case description

A 51-year-old female patient with no medical history consulted with a 6-month history of abdominal distension associated with pain located in the right hypochondrium, sensation of gastric fullness, which is associated with respiratory distress. Imaging studies were performed in which the enlarged liver was observed, at the expense of the right hepatic lobe dominated by a hypodense image with thin lobed walls and fine fine septa with an estimated volume of 1,405 cc, data in relation to hepatic polycystosis. She was taken to the operating room for hepatic cyst resection that includes segments 4, 5 and 8, with serobiliary fluid of approximately 1,300 cc inside, thickened walls adhered to vascular structures and bile ducts inside. Pathologically the cyst wall lined with cuboidal simple epithelium, multiple small bile ducts with benign epithelium were observed, on a fibrous background and with a small zone of normal hepatic parenchyma. Compatible with a Biliary Hamartoma (von Meyenburg complex).

Discussion

The majority of von Meyenburg complexes are discovered incidentally, this condition is incidentally detected in from 0.5 to 5.6% of autopsies and is generally asymptomatic. In contrast our patient presented with abdominal distension and pain located in the right hypochondrium. These complexes do not require treatment, but a long-term follow-up is indicated due to the possibility of more frequent cholangiocarcinoma in patients with von Meyenburg complexes. Currently the patient is clinically stable and with adequate evolution with radiographic follow-up. This is probably the first case report of the von Meyenburg complexes described in Guatemala.

#541 - Case Report

A DRINK OF ASPIRIN

Filipa Rodrigues, Carmen Valdivieso, Eugénia Madureira, Pedro Verão, Maria Castro, Andreia Diegues

ULSNE, Bragança, Portugal

Introduction

Esophageal varices and Mallory Weiss syndrome are two major esophageal bleeding disorders and the management of both these

conditions remains a challenge. Mallory Weiss in particular is responsible for up to 15% of upper GI bleeds and it was initially described in association with vomiting following an alcoholic binge. On the other hand, acute bleeding of esophageal varices occurs in 25% to 40% of cirrhotic patients and carries a high mortality.

Case description

37-year-old female, with a past medical history of alcohol, that following a fall, which resulted in the right malleolus fracture that she self-medicated with aspirin, was admitted in the ER with a massive upper gastrointestinal bleeding, caused by a Mallory Weiss tear with bleeding of grade II esophageal varices newly diagnosed.

She developed hemorrhagic shock and was admitted in the ICU where she stayed for approximately 8 days with severe organ dysfunction, encephalopathy and severe hepatic dysfunction.

The patient had a good clinical and laboratory evolution, being able to discharge the ICU and being transferred to the ward, to further control and evaluation and was then discharged from the hospital, and has since been followed in an outpatient regimen.

Discussion

The connection between Mallory Weiss and cirrhosis is poorly studied but there are some studies that say the severity of bleeding from this syndrome is related to the status of the liver function and therefore develop mainly in patients with chronic alcoholism. An important risk factor is, of course, the concomitant use of aspirin, reported in about 30% of patients, highlighting recent findings that even low dose aspirin use increases major GI bleeding risk by 58% in healthy adults which raises concerns with the wide-use of aspirin in the present medical practice, and of course, the harm of self-medication with apparent innocuous pills.

#565 - Case Report

DIEULAFOY'S LESION AND ACUTE KIDNEY INJURY: THE SAME ETIOLOGY?

Ana Sá, Paulo Medeiros, Narciso Oliveira, Teresa Pimentel

Hospital de Braga, Braga, Portugal

Introduction

Dieulafoy's lesion, also termed "caliber persistent artery", is a rare and potentially life-threatening cause of acute gastrointestinal (GI) bleeding, accounting for up to 2% of total episodes. Typically presents with severe, active GI bleeding, without prior symptoms. The stomach is the most common site for Dieulafoy's lesion. Approximately one-third of lesions are extra-gastric, most frequently in the duodenum followed by the colon. Although its etiology remains unknown, it is often associated with alcohol and non-steroidal anti-inflammatory drugs (NSAIDs).

Case description

An 83-year-old man, with hypertension and alcoholism, went to the emergency room due to asthenia, peripheral edema and

decreased urine output. He had been medicated 7 days before with non-steroidal anti-inflammatory drugs for right knee pain after falling. He had oliguric acute kidney injury (creatinine 5.2 mg/dL), hyperkalemia and hyperlactacidemia. Renal ultrasound had no pathological changes. Multiple sessions of hemodialysis were performed without clinical renal recovery. During hospitalization, he had acute onset of hematemesis, melena, hypotension, acute drop in the hemoglobin value (11,1 g/dL to 6,2 g/dL) and hypotension, requiring transfusion of multiple units of packed erythrocyte and high volume fluid administration. Esophagogastroduodenoscopy showed GI bleeding secondary to Dieulafoy's lesion, treated with local epinephrine injection. Despite all therapeutic measures, the patient eventually died.

Discussion

Unlike normal vessels of the gastrointestinal tract which become progressively smaller in caliber peripherally, Dieulafoy's lesions maintain a large caliber despite their peripheral, submucosal, location within gastrointestinal wall. Dieulafoy's lesion is an important cause of acute GI bleeding. Although etiology still uncertain, it is more common in males hospitalised, with cardiopulmonary dysfunction or renal failure. Dieulafoy's lesion is often associated with alcoholism and NSAIDs. This patient has been hospitalized with acute kidney injury and Dieulafoy lesion, probably by non-steroidal anti-inflammatory drugs. Endoscopy is the first diagnostic test and endoscopic therapy (including clips, sclerotherapy, argon plasma coagulation, thermocoagulation, or electrocoagulation) is the recommended initial therapy. Dual endoscopic therapy of epinephrine injection followed by ablative or mechanical therapy appears to be effective.

#611 - Abstract

NEW INTERFERON FREE ANTIVIRAL THERAPY AND INCIDENCE OF AUTOIMMUNE MANIFESTATIONS IN PATIENTS WITH VIRAL HEPATITIS C

Anca Belu, Mihaela-Maria Ghinea, Daniela Belu, Traian Tache, Zizi Niculescu, Eduard Circo

Constanta County Emergency Hospital, Ovidius University Constanta, Constanta, Romania

Background

The interferon free treatment in viral chronic hepatitis C is a great chance for this patients and the beginning of a new era for the fight against the hepatic virus C.

The treatment can also be applied to patients with liver cirrhosis - this was not possible with previous and is shorter but a median of 12 weeks. Moreover, there is no age limit for treatment and the side effects are much less than with interferon.

But, what about the autoimmune reaction?

There have been numerous studies that demonstrated that autoimmune side effects in these patients were due both to interferon therapy but also to replication of the virus in various

organs- extrahepatic reservoir of viral replication (eg thyroid, kidney) or autoantibody development due to the existence of a common sequence present in both the structure virus, and also in self structures of the human body.

Can the new treatment solve the autoimmune implications of hepatitis C virus infection? Our objective is to have an answer at this question.

Methods

We studied a group of 157 patients diagnosed with chronic type C viral hepatitis, (69 patients- liver cirrhosis stage). They were treated with VIEKIRAX (ombitasvir, paritaprevir and ritonavir) in combination with EXVIERA (dasabuvir).

All patients had undetectable viremia at the end of treatment, and none discontinued treatment due to side effects.

Results

Among these patients, 52,8% (83 patients) had previously received Interferon treatment without a favorable therapeutic response. At the beginning of treatment, we had the following situation: 33,7% (53 patients) had autoimmune thyroiditis, 12,1% (19 patients) mixed cryoglobulinemia, 6,4% (10 patients)- membranoproliferative glomerulonephritis and 5% (8 patients) with secondary autoimmune hepatitis.

6 months after the end of the treatment - 12,7% (20 patients) still had autoimmune thyroiditis, only 5% (8 patients) of the mixed cryoglobulinemia were biological reconfirmed, the clinical manifestations and the paraclinical determinations denies the secondary autoimmune reactions in the kidney and liver.

Conclusion

The introduction of new interferon free therapies in the treatment of viral hepatitis C represents a major benefit for these patients in terms of fighting the virus itself as well as all autoimmune associated manifestations.

We consider this study as a prove of new infinite opportunities for the internal medicine.

#612 - Abstract

NON ALCOHOLIC FATTY LIVER DISEASE IN AUTOIMMUNE HEPATITIS: IMPORTANT PLAYER OR INNOCENT BYSTANDER? AN INTERNATIONAL MULTICENTER STUDY OF THE IAIHG

Kalliopi Zachou^{1,2}, Kalliopi Azariadis², Ellina Lytvyak³, Nikolaos K Gatselis^{1,2}, Atsushi Takahashi⁴, Mercedes Robles⁵, Raul J Andrade⁵, Christoph Schramm⁶, Ansgar W Lohse⁶, Atshushi Tanaka⁷, Eirini Rigopoulou^{1,2}, Aldo J Montano-Loza³, George N Dalekos^{1,2} on behalf of the IAIHG

¹ Institute of Internal Medicine and Hepatology, Larissa, Greece

² Department of Medicine and Research Laboratory of Internal Medicine, University Hospital of Larissa, Larissa, Greece

³ Division of Gastroenterology & Liver Unit, University of Alberta Hospital, Edmonton Alberta, Canada

⁴ Department of Gastroenterology, Fukushima Medical University School of Medicine, Fukushima, Japan

⁵ Unidad de Gestión Clínica del Aparato Digestivo, Servicio de Farmacología Clínica, Instituto de Investigación Biomédica de Málaga-IBIMA, Hospital Universitario Virgen de la Victoria, Universidad de Málaga, CIBERehd, Malaga, Spain

⁶ Department of Medicine and Martin Zeitz Centre for Rare Diseases, University Medical Centre Hamburg-Eppendorf, Hamburg, Germany

⁷ Department of Medicine, Teikyo University School of Medicine, Itabashiku, Tokyo, Japan

Background

Non-alcoholic fatty liver disease (NAFLD) and steatohepatitis (NASH) affect 17-46% of western countries population, making the coexistence with other liver diseases inevitable. Our aim was to investigate the prevalence and clinical significance of NAFLD/NASH in patients with autoimmune hepatitis (AIH), in a multicentric large cohort.

Methods

Prospectively collected data from patients with well-established AIH from 6 academic centers (Greece, Canada, Japan, Germany and Spain) were evaluated retrospectively. The presence of NAFLD and NASH in liver biopsy reports was recorded in detail in order to compare the clinical and laboratory data as well as the outcome between AIH patients with and without NAFLD/NASH.

Results

580 patients (433 females, 74.7%; age at AIH diagnosis 46+/-18 years; 175 from Greece, 309 from Canada, 44 from Japan, 29 from Germany, 13 from Spain; follow-up 103+/-86 months) were included. NAFLD was present in 123/580 (21.2%) baseline biopsies. In more detail, 107/580 (18.4%) had NAFLD (64/107 steatosis only; 43/107 steatosis and lobular inflammation) and 16/580 (2.7%) NASH. Patients with AIH-NAFLD/NASH were older at AIH diagnosis ($p=0.004$), had higher BMI ($p<0.001$), lower AST, ALT, ALP and bilirubin ($p<0.05$ for each), but higher albumin ($p<0.001$), triglycerides ($p=0.05$) and lower simplified score ($p=0.02$)

compared to those without NAFLD/NASH. AIH-NAFLD/NASH patients suffered more frequently from hypertension, diabetes and obesity ($p<0.001$ for each). AIH-NAFLD/NASH patients were less likely to be anti-SLA/LP positive ($p=0.005$), but more likely to be anti-LKM positive ($p=0.02$). Although progression to cirrhosis was not associated with NAFLD/NASH presence, AIH-NAFLD/NASH cirrhotic patients (39/197) were more likely to decompensate during follow-up ($p=0.01$). The presence of NAFLD/NASH did not affect response to treatment or overall prognosis (liver related death or liver transplantation).

Conclusion

Despite the high prevalence of NAFLD/NASH in one fifth of AIH patients, there is no evidence that NAFLD/NASH acts as an aggravating factor since response to treatment and the overall prognosis of AIH patients were not affected. However, the low number of patients with AIH and NASH could be responsible for these findings. Nevertheless, special attention might be needed for those with established AIH-related cirrhosis and concurrence NAFLD/NASH.

#613 - Case Report

A CASE OF EXTREME CACHEXIA

Sandra Celeste Dias Rebelo, Ana Tornada, Tiago Marques

Centro Hospitalar Lisboa Norte - Hospital de Santa Maria, Lisboa, Portugal

Introduction

Indeterminate colitis (IC) or idiopathic chronic colitis (ICC) is characterized by a presentation comparable to Ulcerative Colitis (UC), although with a more extensive and severe presentation, often with extraintestinal manifestations such as in Crohn's disease (CD). It is an overlapping of clinical, histological and serological characteristics of both UC and CD, compelling for a diagnosis of exclusion.

Case description

We report a case of a 55-year-old Cape Verdean man, hospitalized for dysphagia for solids, weight loss over 10% of the body mass index (BMI), diarrhea with hematochezia, vomiting, anorexia and asthenia with insidious onset in the previous 6 months. At admission, the patient presented extreme cachexia (BMI of 13.8 kg/m²), jaundice and deep dehydration with severe hyposmolar hyponatremia (Na 95 mmol/L), acute kidney injury, liver dysfunction and hypergammaglobulinemia. Several opportunistic infections (esophageal candidiasis, pseudomembranous colitis and Cytomegalovirus (CMV) colitis and latent tuberculosis) were diagnosed. With elevation of fecal calprotectin, positive Antineutrophil cytoplasmic antibody (PR3) and Anti-Saccharomyces cerevisiae Antibody (ASCA) the differential diagnosis of the etiology of pancolitis which was documented in computed tomography and magnetic resonance imaging was a challenge. Serial endoscopic examinations confirmed findings consistent with the infections above mentioned and macroscopic

and histopathological findings suggested both UC and CD, difficult to distinguish because of the mucosal ulceration due to CMV over infection. The duodenal biopsies, revealed aspects of celiac disease, with HLA DQA1 and DQB1 associated with DQ2 heterodimer and trans configuration DQ7.5, despite not having Anti-transglutaminase, antiendomysium and antigliadin antibodies. By exclusion criteria we defined the final diagnostic suggestive of ICC and celiac-like disease. Parenteral nutrition, mesalazine and systemic corticotherapy were introduced with a subsequent switch to infliximab and azathioprine to control inflammatory activity, with a notable improvement. He had a portal vein thrombosis as an extraintestinal manifestation.

Discussion

The occurrence of pancolitis and malabsorption syndrome may lead to the occurrence of opportunistic diseases, which difficult the differential diagnosis. The rare association among ICC and celiac-like disease raise a dilemma on the early institution of biological immunosuppressant therapy, given the opportunistic infection.

#618 - Medical Image

CAMERON LESIONS – A STILL OVERLOOKED DIAGNOSIS

Magda Sofia Silva, Francelino Ferreira, Rúben Reis, Laurinda Pereira, Anneke Joosten, Ana Paula Pona, Fátima Campante
Centro Hospitalar Barreiro Montijo, Barreiro, Portugal

Clinical summary

We report the case of a 76-year-old woman admitted for asthenia and fatigue. At the observation she was pale, tachycardic and polypneic. The analytical evaluation revealed iron deficiency anemia with hemoglobin of 5.7 g/dL and serum iron of 10 µg/dL. Upper gastrointestinal endoscopy identified a large hiatus hernia with Cameron lesions. She started treatment with proton pump inhibitor and oral iron supplementation.

This case illustrate an uncommon and still overlooked diagnosis of indolent digestive hemorrhage and consequent iron deficiency anemia. These lesions are identified in only about 5% of patients with hiatal hernia.

#634 - Abstract

LEAKY COLONIC BARRIER IN OBESE PATIENTS. AN OPEN GATE TO LIVER STEATOSIS

Emilio Molina-Molina¹, Domenica Maria Di Palo¹, Agostino Di Ciaula², Harshitha Shanmugam¹, Leonilde Bonfrate¹, Eric Mossel³, Piero Portincasa¹

¹ Clinica Medica “A. Murri”, Department of Biomedical Sciences and Human Oncology, University of Bari “Aldo Moro” Medical School, Bari, Italy

² Division of Internal Medicine, Hospital of Bisceglie, Bisceglie, Italy

³ AB Analitica, Padua, Italy

Background

The role of intestinal permeability (IP) in the pathogenesis of fatty liver is poorly explored.

Methods

113 subjects (74F) underwent the study of IP by measurement of urinary recovery of selectively absorbed sugar probes, i.e. sucrose [SO] 20g (stomach-duodenum), lactulose [LA] 5g + mannitol [MA] 1g (small intestine), sucralose [SA] 1g (colon) dissolved in 200 mL water. Urines were collected for 6-hr and sugar concentrations were measured by triple quadrupole mass spectrometry and HPLC (AB Analitica, Padua, Italy). Liver steatosis was scored semiquantitatively (absent, mild, severe) by ultrasonography (Hitachi Noblus 3.5MHz equipment). Adherence to Mediterranean diet (M-diet) was assessed by questionnaire.

Results

While urinary recovery of all sugars was similar in males and females, MA and SA recovery correlated inversely with age. Urinary recovery of SO, LA, MA were comparable, while SA recovery was higher in obese (BMI ≥ 30 Kg/m²) than in overweight (BMI 25-29.9 Kg/m²) and lean subjects (mean ± SE 1.6 ± 0.1%, vs. 1.0 ± 0.1% vs. 1.0 ± 0.06%, respectively, P = 0.0006, ANOVA). This finding was independent from age, which was similar in the three subgroups (P = NS, ANOVA). SA recovery increased with BMI (P = 0.001) and degree of fatty liver (1.0 ± 0.06% vs. 1.2 ± 0.1% vs. 1.5 ± 0.1% in absent, mild and severe steatosis, respectively, P = 0.005 ANOVA). Subjects following a “sufficiently adequate” M-diet (n = 89) had lower SA recovery (1.0 ± 0.04%) than subjects following a “scarcely adequate” M-diet (1.4 ± 0.2%, P = 0.03), although mean BMI was similar in these two subgroups (P = NS).

Conclusion

Obese display a leaky colonic barrier, independently from age and sex; the highest value of colonic permeability was recorded when the highest degree of fatty liver was present; adherence to M-diet could have beneficial effects on colonic permeability, the role of which needs to be further defined.

#655 - Case Report

OGILVIE’S SYNDROME: A CASE REPORT

Cátia Pereira, Sandra Santos, Joana Paixão, Joana Costa, Amílcar Silva

Centro Hospitalar Universitário de Coimbra, Coimbra, Portugal

Introduction

Ogilvie’s syndrome was first described by William Ogilvie in 1948 and is also known as pseudo-obstruction syndrome.

Clinically it is characterized by dilation of the blind and right colon in the absence of colonic obstruction in relation to a dysfunction of the autonomic nervous system. The diagnosis is confirmed by radiological studies.

This syndrome can be treated in most of the times with food

interruption, insertion of a rectal and nasogastric tube. The infection treatment and the correction of possible metabolic disorders are extremely important.

Diagnosis failure can increase the risk viscera perforation, which is rare but significantly increases patient mortality.

Case description

The authors presents a case of a 36-year-old man totally dependent for life activities with a history of hemophilia (factor VIII deficit) and a hemorrhagic cerebral vascular disease at age 11. He contacts a medical appointment for abdominal distension with abdominal pain and fecaloid vomit with about 24 hours of evolution, later aggravated by dyspnea, acute respiratory distress syndrome, wheezing and reflex tachycardia. Constipation with 4 days of evolution. At the emergency service he was prostrate, with abdominal distension, tachypnea, pulmonary auscultation with wheezing and low saturations (91% with oxygen at 5L/min). Started therapy with fluid therapy and bronchodilator for stabilization. Due to a suspicion of acute intestinal obstruction he presented a new episode of vomiting of dark stasis vomit and one anti-emetic agent was administered after the insertion of one nasogastric tube. Two enemas were performed with two episodes of pasty stools.

Prophylactic antibiotic therapy with piperacillin-tazobactam was started and was admitted in the internal medicine department.

Discussion

This case allows to warn that despite being a rare syndrome, most often manifests as a medical urgency whose rapid approach to significantly reduce the morbimortality of patients.

#659 - Case Report

GASTROINTESTINAL BLEEDING FROM AN UNEXPECTED SOURCE

Claudia Janeiro, Pedro Mesquita, Rosario Eça, João Teixeira, Ines Santos, Raquel Mesquita

Hospital Santo António dos Capuchos - CHULC, Lisboa, Portugal

Introduction

Lower gastrointestinal bleeding (LGIB) is a frequent cause of hospital admission and is a factor in hospital morbidity and mortality, particularly among elderly patients. It accounts for approximately 20-33% of episodes of gastrointestinal (GI) hemorrhage.

The etiology of lower gastrointestinal bleeding is essential for patient management and outcome. Colorectal polyps/neoplasms, Dieulafoy lesion, inflammatory bowel disease, and anorectal conditions are the most common etiologies of acute severe LGIB. Effective management with less invasive modalities has also reduced healthcare costs and, more importantly, patient morbidity and mortality.

Case description

The authors describe a case of 75 years-old woman with past

medical history of hypertension and atrial fibrillation, taking anti-hypertensive and anti-coagulant therapy with ACE inhibitors and novel oral anticoagulants.

The patient comes to the emergency room with history of lower GI bleeding, that started 2 months ago. At the beginning, the patient was on medical ward for studying the source of blood loss, so a colonoscopy was performed and the diagnosis of diverticular disease was made (but without identification of bleeding source). She was discharged assuming bleeding from diverticular disease and once the bleeding remained, doctors decided to stop anticoagulant therapy and further evaluation in outpatient clinic. The patient remained anemic, with almost daily episodes of hematochesia, with need of frequent blood transfusions so that the doctors decided to admit patient in medical ward for further examination. During her second stay in ward she needed blood transfusions frequently and all initial exams were inconclusive: angio abdominal CT scan, rectosigmoidoscopy and colonoscopy (always with active bleeding and no identification of source). She made a last left colonoscopy and was finally found 25 cm from anal margin a 'strange body' with metallic consistency with approximately 4 cm long, with active hemorrhage adjacent to that site. After that the hemoglobin remained stable and no more episodes of GI bleeding happened.

Discussion

Lower GI bleeding in elderly is frequently associated with diverticular disease. In this particular case it was really difficult to imagine another etiology for the GI bleeding, but once the signs and symptoms persisted, further examination had to be performed and luckily we found this (strange) bleeding source.

And the question remains: How did this strange body reached colon?

#669 - Case Report

ESOPHAGEAL RUPTURE AND LUNG EMPYEMA IN A PATIENT WITH ESOPHAGEAL CANCER, AFTER PALLIATIVE TREATMENT WITH ESOPHAGEAL STENT PLACEMENT

Dimitris Tsilivarakis, Vasiliki Papanikolaou, Antonios Gikopoulos, Dimitra Karadima, Afroditi Roumpou, Ioanna Papaioannou, Christos E Lampropoulos

Panarcadian General Hospital, Tripoli, Greece

Introduction

Esophageal cancer is a devastating disease with poor prognosis (5-year survival rate <20%). Most of patients have inoperable disease at time of diagnosis. Symptoms include anorexia, dysphagia, weight loss or hoarseness (recurrent laryngeal nerve paralysis). Infiltration of surrounding tissues may cause esophageal perforation, hydro-pneumothorax, empyema, mediastinitis and sepsis with high mortality. Treatment consists of chemoradiotherapy (with or without surgery) or/and endoscopic self-expanding metal stent (SEMS) placement for esophageal dilation, as palliative therapy for dysphagia.

Case description

A 71-year old male presented right chest pain extending to the abdomen. Medical history included esophageal cancer with SEMS 3 months ago. Clinical examination revealed low blood pressure, rales of right lung fields and diffuse abdominal tenderness with borderline rebound tenderness. Thoracic X-ray showed infiltrates and pleural effusion of right lung. Laboratory investigation showed leukocytosis, high ESR, anemia, renal failure and malnutrition (protein=5.2g/dL). Empirical antibiotic treatment was applied (piperacillin/tazobactam, moxifloxacin). The third day the patient developed septic shock with hemodynamic compromise (BP=75/55mmHg), respiratory deficiency and pain deterioration. New x-ray showed air-fluid level at right lung apex and mediastinal expansion. Thoracic CT (IV contrast, gastrografin meal) revealed esophageal rupture with gastrografin and air leakage into the pleural fluid and mediastinum. The patient was operated with excision of the ruptured area and drainage of the empyema. He remained in the Intensive Care Unit for 15 days, where he unfortunately died, despite being alert, mainly because of his cancerous cachexia.

Discussion

The newer SEMS are safer than the previous conventional ones, regarding aspiration pneumonia, bleeding, stent migration or reintervention due to stent dysfunction. Nevertheless, major complications still occur in 20-30% of patients. Esophageal rupture is a rare complication of esophageal cancer with high mortality (>35%). Risk factors for perforation include age younger than 60 years, extracapsular lymph nodes involving the esophagus, T4 stage of disease and repeated courses of radiotherapy. The risk is lower after SEMS placement for palliative esophageal dilation. Perforation may occur immediately during stent procedure or a few months later. Despite surgical intervention, mortality is high because of mediastinitis, empyema and septic shock.

#684 - Case Report

FULMINANT HEPATIC FAILURE

María De Los Ángeles Gallardo, Cristina Lojo

Hospital Universitario Virgen de Valme, Sevilla, Spain

Introduction

A 42-year-old male with active smoking and drinking habits; history of myocarditis and positivity for markers of chronic hepatitis B virus (precore mutant).

Case description

He was admitted at the hospital due to right hypochondrium pain, low-grade fever and increased abdominal perimeter with malleolar edemas of 24 hours of evolution. The analytics showed leukocytosis, prothrombin time of 49% and bilirubin 2.59 mg/dl. Abdominal ultrasound shows poorly defined area in right hepatic lobe, splenomegaly and abundant ascitic fluid. During

the admission he presents arterial hypotension, tachypnea, tachycardia, jaundice and worsening of ascites. Paracentesis was performed with cloudy peritoneal fluid, with 340 leukocytes with 80% mononuclear, 1100 red blood cells and 3.7 proteins.

He enters ICU with poor clinical evolution, hypothermic, maintained hypotension and tachycardic. The analytics shows severe metabolic acidosis (pH 6.9, EB-26), leukocytosis of 56,000, hemoglobin 17g/l, INR up to 7.15, bilirubin up to 2.86mg / dl with transaminases of 7110 and creatinine 4.5. Abdominal CT shows left basal condensation, hepatic steatosis with permeable portal vein, splenomegaly and ascites. Normal echocardiography, negative coombs test, smear normal, with PMN leukocytosis, lactate 27, blood cultures, rose bengal and negative serology. Antibiotic therapy with cefotaxime and metronidazole was initiated and hemodiafiltration. Finally, presents fulminant hepatic failure with multiorgan failure and he died.

Necropsy is compatible with severe hemorrhagic centrilobular necrosis liver associated with thrombosis of suprahepatic and intrahepatic efferent veins, all compatible with Budd-Chiari syndrome.

Discussion

Budd-Chiari syndrome is defined as an obstruction of the hepatic venous outlet tract. Patients may present acute fulminant hepatic failure. Symptoms may include fever, abdominal pain, ascites, edema, jaundice, gastrointestinal bleeding (due to varicose veins or hypertensive portal gastropathy) and / or hepatic encephalopathy. The diagnosis can be established with Doppler ultrasound. Coagulopathy, encephalopathy and hepatorenal syndrome are indicative of a poor prognosis. If thrombolytic therapy and angioplasty fails, liver transplantation should be considered. Without treatment, the prognosis is poor.

#688 - Case Report

PORTO-SINUSOIDAL VASCULAR DISEASE: RAISING AWARENESS FOR AN OLD NEW ENTITY

Adriana Soares, Sofia Monteiro, Alda Tavares, Elia Cipriano, Filipe Andrade, Artur Silva, Fernanda Estevinho, Carlos Sottomayor

Hospital Pedro Hispano, Porto, Portugal

Introduction

Porto-sinusoidal vascular liver disease (PSVD) occurs in the presence of portal hypertension in the absence of portal vein thrombosis, without cirrhosis and with mild or moderate alterations of liver histology. This new entity encompasses a heterogeneous group of vascular liver diseases previously described, namely idiopathic non-cirrhotic portal hypertension or nodular regenerative hyperplasia.

PSVD has multiple etiologies such as immunologic, blood and genetic diseases, prothrombotic conditions and drugs. Oxaliplatin is one of the most common associated chemotherapy agents, described in until 15% of patients.

Case description

We present a case of a 60-year old man, without previous history of liver disease, submitted in April 2012 to a total gastrectomy due to a signet-ring cell gastric cancer (pT1N1M0), followed by a total of 6 cycles of adjuvant chemotherapy with EOX regimen (epirubicin, oxaliplatin and capecitabine) and surveillance.

Patient was asymptomatic until January 2017 when he was admitted with acute esophageal variceal bleeding. Abdominal CT scan showed patency of portal vein, perihepatic ascites and nodular configuration of segment III. Tumor markers were normal and common causes of cirrhosis were excluded. Median liver elastography was 10.1 kPa and hepatic venous pressure gradient was 4 mmHg. A liver biopsy of segment III and of the right lobe was performed which excluded cirrhosis or neoplastic involvement. Diagnosis of PSVD due to oxaliplatin was made.

Discussion

In patients treated with oxaliplatin in the presence of clinical signs of portal hypertension, the diagnosis of vascular liver disease should be suspected. Findings can mimic liver neoplastic involvement as described in our case report. In this population biopsy should be pursued to exclude the diagnosis of malignancy and avoid overtreatment. The natural history of PSVD is not yet fully known but patients require screening for portal vein thrombosis and management of portal hypertension complications.

#749 - Case Report

SOLID PSEUDOPAPILLARY TUMOR: A RARE PANCREATIC NEOPLASM

Lucía Pérez, Ana Blanco, Ana Barreiro

Complejo Hospitalario Universitario Ourense, Ourense, Spain

Introduction

The solid pseudopapillary tumor (SPT) of pancreas is a rare neoplasm with low potential of malignancy, more common in women. It represents between 0.2% and 2.7% of the exocrine pancreas neoplasm, even though some authors maintain that in recent years this percentage has increased to 6% due to a better diagnosis.

Case description

A 27-year-old woman with familiar hyperlipidemia and mild smoking as the only relevant personal medical history. In a routine revision, a solid mass in the tail of the pancreas was carried out by an abdominal echography. The patient was asymptomatic and the physical examination was anodyne, as well as the analytical data. In view of the ultrasound finding, abdominal CT was performed, which revealed a tumor dependent on the tail of the pancreas suggestive of a macrocystic adenoma or cystic mucinous neoplasm. It was decided then to make a laparotomy, in which a cystic tumor of the tail of the pancreas of 6 cm of diameter was found. A corporo-caudal splenopancreatectomy was performed, without complications. The anatomic-pathological study of the

surgical specimen revealed a SPT of the pancreas, without criteria of malignancy, of 6.5 cm. The surgical margins were free and the extracted nodes did not have significant alterations, neither did the spleen. The patient has remained asymptomatic since then and without evidence of recurrence on CT, PET-CT and ultrasound, after a 9 years follow-up.

Discussion

The SPT predominates in women between 20 and 30 years old. The most common location is the tail of the pancreas. The embryological origin of SPT is not clear although it has been postulated that they could be derived from female genital tissue. Clinical presentation is nonspecific, with abdominal pain occurring in 58-72% of cases, although up to 30% of patients are asymptomatic. Routine analytics and tumor markers are not useful in the diagnosis of SPT. Imaging techniques typically show a heterogeneous mass with a solid and cystic component, well defined by a peripheral capsule, with occasional calcifications. Most SPTs have a benign course, although in a small percentage of the cases it has caused a distant disease, being the liver the most frequently affected organ. The chosen treatment is the complete tumor resection, regardless of stage, and incomplete resections should be avoided, given the risk of complications such as tumor dissemination and a higher rate of recurrence. The overall mortality of SPT is estimated at 2%, and recurrence after resection is calculated at 10-15%.

#772 - Case Report

MIGRATED FISH BONE CAUSED LIVER ABSCESS PRESENTED AS A GASTRIC SUBEPITHELIAL LESION (MASS) IN CLINICAL PRACTICE DIAGNOSED BY ECHOENDOSCOPY

Metin Basaranoglu

Bezmialem Vakif University, Istanbul, Turkey

Introduction

A 63-year-old man presented with a one-month history of abdominal pain. The final diagnosis was a fish bone caused liver and gastric wall abscesses presented as a gastrointestinal stromal tumor diagnosed by echoendoscopy (EUS).

Case description

A 63-year-old man presented with a one-month history of abdominal pain. Esophagogastroduodenoscopy revealed a 40 mm subepithelial lesion located at gastric antrum. Gastrointestinal stromal tumor (GIST) was suspected. Then, an endosonographic (EUS) evaluation was performed.

A curvilinear echoendoscope (EG-530UT; Fujinon, Japan) was used. Endosonographic (EUS) evaluation was performed and showed that a 23x27 mm hypoechoic mass arising from gastric wall and producing pus by the pressure of the tip of the EUS (Figure 1). Additionally, there was a linear hyperechoic tract that was located between the gastric antrum and 3rd segment of the left liver lobe (Figure 2).

Apex of the subepitelial lesion producing pus by the pressure of EUS device. Inferior part of the gastric lesion did spread to the left lobe of the liver. On this liver segment, there was a hypo-echoic mass lesion.

Discussion

Suppurative gastritis may develop secondary to pancreatitis, cholecystitis, appendicitis, and diverticulitis (1-5). It may also arise from foreign body ingestion.

Patient-related risk factors for the development of suppurative gastritis include alcoholism, older age, diabetes mellitus, hypochlorhydria or achlorhydria, and immunosuppression. Abdominal pain and nausea usually dominate the clinical picture in these cases.

The most common appearance of a gastric wall abscess is a submucosal tumor. Both radial and curved linear array endoscopic ultrasound provides a unique imaging modality for evaluating the gastric wall with an excellent visualization of the layers of the gastric wall. EUS features include a heterogeneous mass often with solid and cystic components. Suppurative gastritis may progress to peritonitis and death from sepsis with delayed diagnosis and treatment. Surgery is definitive therapy.

Cases of hepatic abscess due to fish bone penetration are rare and may be fatal with delayed diagnosis and treatment (6,7).

In summary;

EUS may provide an additional diagnostic tool in the evaluation of patients with suspected gastric wall abscess. EUS is fundamental on the diagnosis of suspect foreign bodies and their complication.

#773 - Case Report

AN OLD MALE WITH CROHN'S DISEASE PRESENTED BY SUBILEUS CLINIC AND DIAGNOSED BY DOUBLE BALLOON ENTEROSCOPY AND HISTOLOGIC EXAMINATIONS

Metin Basaranoglu, Gokcen Basaranoglu
Bezmialem Vakif University, Istanbul, Turkey

Introduction

Crohn's disease (CD) is a disease that causes inflammation or swelling of any part of the gastrointestinal (GI) tract. The part most commonly affected is the end part of the small intestine, called the ileum. We, here, presented a case with CD diagnosed by taken specimens during the double balloon enteroscopy and enteroscopy findings.

Case description

A 60-year-old male was admitted to the clinic with abdominal pain and vomiting. His medical history includes diabetes and hypertension, besides cholecystectomy and inguinal hernia operation. He was an ex-smoker. Laboratory examination showed nothing. Abdominal tomography showed that the wall of the jejunum and ileum were thickened. Small bowel contrast

examination revealed thickened wall in the ileum with ulceration and nodularity. Colonoscopy showed no abnormality in the colon and 15 cm of the distal part of the ileum. Oral double balloon enteroscopy first performed and showed multiple xantomas in the jejunum and proximal ileum segments. Then, double balloon enteroscopy performed by anal route and showed semicircular ulcers and narrowing in the ileum, approximately 100 cm far from the ileocecal region. Multiple biopsies performed and specimens showed ulceration with active inflammation. Quantiferon was positive as PCR-tuberculosis of the specimens from the ileum was negative. Chest examination was normal. Crohn's disease was diagnosed in this elderly patient.

Discussion

Crohn's disease affects men and women equally and seems to run in some families. Crohn's disease occurs in people of all ages, but it most commonly starts in people between the ages of 13 and 30. Men and women who smoke are more likely than nonsmokers to develop Crohn's disease. People of Jewish heritage have an increased risk of developing Crohn's disease, and African Americans have a decreased risk. The most common symptoms of Crohn's disease are abdominal pain, often in the lower right area, and diarrhea. In our presented case, suspected radiological findings confirmed by double balloon enteroscopy with histologic examination. Tuberculosis should be carefully excluded in patients with ileum ulcers and positive blood quantiferon test results, particularly in developing countries which tuberculosis still is endemic.

#774 - Medical Image

ACHALASIA

Margarida Gonçalves Coelho, Lília Castelo Branco, Cátia Pereira, Elisabete Pinelo, Eugénia Madureira

Serviço de Medicina Interna, Unidade Hospitalar de Bragança, Unidade Local de Saúde do Nordeste, Bragança, Portugal

Clinical summary

Achalasia is a rare disease with loss of ganglion cells in the esophagus myenteric plexus, characterized by insufficient lower esophageal sphincter (LES) relaxation and loss of esophageal peristalsis. Manifestations include dysphagia, regurgitation, chest pain and weight loss. Diagnostic confirmation needs radiograph of barium swallowing and/or esophageal manometry. We report the case of a 72-year-old woman with psoriatic arthritis and complaints of solids and liquids dysphagia and regurgitation, chest pain and weight loss (15 kg). Barium esophagram showed diffuse spasm and uncoordinated tertiary waves that lead to segmentation of the lower 2/3 of the esophagus and dilation of the upper third. The manometry demonstrated type 2 achalasia. She was oriented to LES endoscopic balloon dilation.

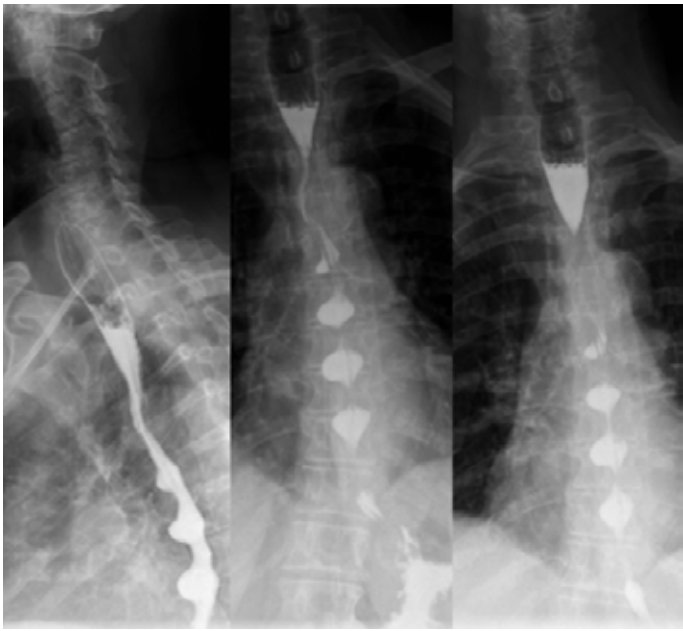

Figure #774. Dilatation of the esophagus with incomplete emptying, hydroaerial level and tapering in the LES region, resulting in the appearance similar to that of a bird-beak.

#834 - Abstract

INCIDENCE OF CHOLANGIOCARCINOMA AND RISK FACTORS IN NORTHERN ITALY: AN ANALYSIS OF 403295 CONSECUTIVE PATIENTS.

Francesca Colapietro¹, Vincenzo Craviotto¹, Monia Aloise², Roberto Ceriani², Guido Torzilli¹, Salvatore Badalamenti², Antonio Voza², Alessio Aghemo¹, Ana Lleo¹

¹ Humanitas University, Milano, Italy

² Humanitas Clinical and Research Hospital, Milano, Italy

Background

Cholangiocarcinomas (CCAs) are a heterogeneous group of tumors that arise from the biliary tract epithelia, and account for nearly 3% of all gastrointestinal tumors. Although CCA is on the rise in most countries, the epidemiology of these cancers has been poorly understood. We therefore aim to assess the prevalence, demographics and risk factors of patients with new diagnosis of CCA presenting in the Emergency Room (ER) of an Academic Italian Hospital

Methods

We retrospectively analyzed all ER cases between January 2010 and December 2017 at Humanitas Research Hospital in Milano Italy.

Results

From January 2010 to December 2017 403295 patients entered the ER, in 203 (0.05%) of them the diagnosis was CCA. CCA cases increased from 38 in the 2010-2011 period (38/102103: 0.03%) to 66 in the 2016-2017 period (66/101337: 0.07%) (p=0.007).

The most frequent reasons for hospitalization in patients with CCA were jaundice (n=106, 52%), abdominal pain (n=30, 15%) and abnormal liver function tests (n=13, 6%). During the study period 1224 patients (0.3%) entered the ER for jaundice, CCA accounted for 9% of those cases. Out of the 203 patients with CCA, 109 were male (53.7%), the mean age was 68 years (24-88). No patient had PSC, only 6 (2.9%) had cirrhosis, while 32 had diabetes (15.7%). The anatomical location of the identified CCA was intrahepatic in 21.6% of the cases, perihilar in 29%, distal in 26.6%, and gallbladder in 21%. Tumor staging was 1 in 27 (13.3%), 2 in 57 (28.1%), 3 in 29 (14.3%) and 4 in 90 patients (44.3%). Treatment of CCA could be analyzed in 135 patients, 51 patients (38%) received best supportive care, 43 received Chemotherapy (32%), while 41 underwent surgery (30%). The rates of surgery increased during the enrolment period however without reaching significant differences (19.7% in 2010-2011 vs 32.5% in 2016-2017, p=0.3).

Conclusion

CCA is a rare presentation in the ER, however with increasing incidence. CCA was found in 9% of all cases presenting with jaundice. Importantly, none of the identified CCA patients had PSC. Further, the low rate of patients with coexisting liver disease (2.9%), the high prevalence of advanced cancer stage (47%) as well as the low rate of surgical treatment (30%) reported by our study highlights the need for research in the field.

#837 - Abstract

DIRECTLY ACTING ANTIVIRALS ARE SAFE AND EFFECTIVE IN HCV ELDERLY PATIENTS

Maria Corina Plaz Torres¹, Francesca Colapietro², Rossella Meli¹, Massimo Colombo¹, Alessio Aghemo², Ana Lleo²

¹ Humanitas Clinical and Research Hospital, Milano, Italy

² Humanitas University, Milano, Italy

Background

Treatment of chronic Hepatitis C (HCV) with directly acting antivirals (DAAs) can lead to sustained virological response (SVR) in nearly 95% of patients. Treatment efficacy and safety in elderly patients has not been extensively studied.

Methods

We retrospectively analyzed treatment efficacy and safety in HCV patients ≥ 80 years of age who consecutively received DAAs at the Humanitas Research Hospital between 2015 and 2018. DAAs were given following the EASL recommendations.

Results

During the study period 976 patients received DAA treatment in our center, 40 patients (4%) were ≥ 80 years old and were included in the study. Their mean age was 81.8 years (80-88), 25 patients were female (62.5%), HCV genotype 1b (29) and 2 (10) were the most prevalent HCV genotypes. Advanced fibrosis (F3-F4) defined by transient elastography was present in 21 (52.5%), six patients

had CPT score >A5 and 8 (20%) had previously failed IFN based treatment. Sofosbuvir based therapies (SOF/LDV, SOF/VEL and SOF + RBV) were given to 21 patients, Paritaprevir/Ombitasvir/Dasabuvir was used in 3, G/P in 7 and Grazoprevir/Elbasvir in 9. Concomitant medications were common in our cohort with 39 (97%) patients taking at least 1 drug and 23 (57,5%) taking 4 or more concomitant drugs. In 3 cases concomitant therapy had to be modified to start DAA treatment for potential significant Drug-Drug interactions. Five patients reported side effects during treatment, side effects were always mild, and no serious adverse events were reported, no patient discontinued treatment prematurely. Seven patients are still completing the follow-up and could not be assessed for SVR. In the remaining 33 patients a SVR was achieved in 32 (97%). The only treatment failure was a patient lost to follow-up after the End of treatment visit.

Conclusion

Our study shows that DAA treatment in HCV Patients older than 80 years of age is safe and effective. Due to high rate of comorbidities DDI need to be carefully assessed before starting treatment.

#871 - Abstract

AUTOIMMUNITY AGAINST TYPE I COLLAGEN IN ULCERATIVE COLITIS

Diliara Mukhametova¹, Diana Abdulganieva¹, Oleg Zinkevich², Nellya Saphina², Marina Koporulina², Alfiya Odintsova³

¹ Kazan State Medical University, Kazan, Russia

² Kazan State Medical Academy, Kazan, Russia

³ Republican Clinical Hospital, Kazan, Russia

Background

Immunological disorders play an important role in the pathogenesis of ulcerative colitis (UC). Collagen is the main component of the intercellular matrix of connective tissue. It can be assumed that the immune disorders leading to the production of autoantibodies to collagen play a role in the pathogenesis of UC.

The aim is to study the level of IgM and IgG to type I collagen (COL1) in UC.

Methods

We prospectively included 61 patients with UC and 30 healthy controls. Mean age in UC was 37±1,5 years and in control group – 30±1,5. Severity of UC was assessed by Mayo score: remission – 5, mild – 25, moderate – 26, severe – 5. Extraintestinal manifestations of UC were in 24 patients (39%). Level of serum IgM and IgG to COL1 was assessed by enzyme immunoassay.

Results

In active UC levels of IgM to COL1 was increased (0,17 [0,10; 0,20] mkg/ml) compared with healthy (0,09 [0,07; 0,12] mkg/ml; p<0,01). The difference between remission (0,1 [0,09; 0,19] mkg/ml) and exacerbation, remission and control group was not

detected (p>0,05). In patients with severe UC IgM to COL1 was 0,19 [0,18; 0,25] mkg/ml, which was higher than in moderate UC – 0,12 [0,08; 0,17] mkg/ml (p<0,05) and mild – 0,18 [0,11; 0,20] mkg/ml (p>0,05). There was a tendency to increase of IgM to COL1 in patients with extraintestinal manifestations (0,17 [0,10; 0,22] mkg/ml) than without them (0,12 [0,09; 0,18] mkg/ml).

The level of IgG to COL1 in active UC (24,69 [16,36; 99,12] mkg/ml) was higher than in the control group 11,36 [6,93; 19,83] (p<0,05) and remission – 13,15 [8,88; 26,21] (p>0,05). There was not revealed the difference of IgG levels depending on the severity of disease. There was a tendency to increase of IgG to COL1 in patients with extraintestinal manifestations (16,18 [9,46; 26,21] mkg/ml), than without them (12,78 [8,81; 28,31] mkg/ml).

There was increasing of ESR (r=0,36; p<0,05) and leukocytosis (r=0,32; p<0,05) with increase of IgM level to COL1.

Conclusion

In active UC the level of serum antibodies of class IgM and IgG to COL1 increased compared with healthy. The maximum increase was found in the group of patients with severe relapse and in the presence of extraintestinal manifestations.

#876 - Case Report

AUTOIMMUNE HEPATITIS - AN UNEXPECTED RECURRENCE

Paula Marques Ferreira¹, Marli Cruz², Sofia Ferreira³, Judit Gandara³, Helena Pessegueiro³, Jorge Daniel³, Vitor Lopes³

¹ Centro Hospitalar Vila Nova de Gaia / Espinho, Vila Nova De Gaia, Portugal

² Hospital da Luz Arrábida, Vila Nova De Gaia, Portugal

³ Centro Hospitalar Universitário do Porto, Porto, Portugal

Introduction

Autoimmune hepatitis (AIH) is a pathology caused by an immune disorder, that

may lead to liver fibrosis and cirrhosis. Despite timely and correct immunosuppressive therapy, AIH can progress unfavorably to decompensated cirrhosis with a worrying short-term mortality. In these situations, liver transplantation may be an effective treatment, with an expected survival rate of 75% at 10 years. The recurrence of AIH after transplantation may occur, and its frequency is variable and apparently independent of the immunosuppressive treatment used in the context of transplantation.

Case description

The authors present the case of a 30-year-old woman diagnosed with autoimmune liver cirrhosis (elevation of IgG and IgM Immunoglobulins, ANA 1/160 with mottled pattern and anti-gp210 positive) with 9 years of evolution. In 2013 she was hospitalized for decompensation of liver cirrhosis with no identified factor. She had ascites and was Child C and MELD 21. She was submitted to liver transplantation in the same year, without surgical complications.

In the first month she had cell rejection, according to graft dysfunction and hepatic histology. She presented normalization of the analytical profile after adjustment of therapeutic use of prednisolone, mycophenolate mofetil and tacrolimus. The patient maintained medication compliance (tacrolimus with adequate and stable levels and 2.5 mg prednisolone / day) and an always normal graft until October 2017, when she presented unexpected graft dysfunction with contemporary hepatic histology showing portal inflammatory infiltrate with hepatitis interface as well as portal fibrosis with some septa, results compatible with relapse of AIH. The dose increase of prednisolone to 60 mg / day was insufficient, so azathioprine was added, which also allowed a reduction in the dose of prednisolone and normalization of the graft at the end of 3 months.

Discussion

We are faced with an autoimmune disease prior to transplantation with evidence of relapse in the graft, which must be conformed by histology. Immunosuppressive treatment requires reintroduction of other immunosuppressants in addition to calcineurin inhibitors.

#880 - Case Report

PANCREATITIS DUE TO AN INTRA-GASTRIC BALLOON

Marine Pierson, Frederique-Estelle Etogo-Asse, Fazia Mana
Clinique Saint-Jean, Brussels, Belgium

Introduction

Obesity is an important world-wide problem which took epidemical proportions. Intra-gastric Balloons (IGB) are space-occupying devices in the stomach and one of many treatments for obesity. The advantage of IGB over surgery is the fact that they preserve the anatomy of the stomach and that it is reversible and safe. We report a case of pancreatitis due to an IGB.

Case description

A 20-years-old obese girl presented to the emergency with acute abdominal pain which started several hours before presentation, associated with nausea and vomiting. She used no medication, did not smoke and not drink alcohol. Her medical history was negative except for the placement of an IGB 5 months earlier. A blood test including calcium, triglycerides and autoimmune markers was unremarkable besides the isolated elevation of lipase. The CT-scan demonstrated a compression of the pancreatic body by the IGB, associated with a moderate acute pancreatitis of the tail of the pancreas. The IGB was removed by endoscopy the same day of admission. She recovered quickly and left the hospital pain free 2 days afterwards.

Discussion

IGB placement for the treatment of obesity is frequently used in spite of the moderate results on long term weight loss and this because of several advantages: it can be placed and removed

easily, it is reversible, no major surgery is necessary and it can often be done in patient who are not fit for surgery. Furthermore it is considered safe with a mortality of 0.05%. The most frequent side effect occur in the first hours/days of the placement with nausea, dyspepsia, pyrosis, vomiting and abdominal pain, usually responsive to supportive treatment and resolving spontaneously (up to 30 % of patients). However early removal can be necessary in persisting symptoms. Major side effects are rare and consists of gastric ulceration, intestinal perforation and balloon deflation with migration and bowel obstruction (<1%). Pancreatitis is rare and mostly described in case reports and case series and not always reported in review articles (Laing P, 2017). Most cases are mild and resolve quickly after removal of the IGB. However, removal does not always seem to be necessary (Alsohaibani FI,2019). Although it is thought that acute pancreatitis from IGB use is due to the mass effect from the balloon on the pancreas, it can occur at any time point after placement and can also occur in balloons filled with gas. In our patient a pressure of the balloon on the body of the pancreas could be seen on the CT-scan.

#897 - Case Report

SEVERE POLYNEUROPATHY DUE TO VITAMIN B12 DEFICIENCY

Vera Seara, Sónia Da Costa Fernandes, Gonçalo R. Mesquita, Lilian Maia, Teresa Pinto
CHPVVC, Vila Do Conde, Portugal

Introduction

Polyneuropathy is associated with a wide range of causes, which can vary from the common diabetes mellitus and alcohol abuse, to the rare hereditary forms. It is often a manifestation of a systemic disease, so its presence should lead to a prompt investigation.

Case description

The authors describe the case of a 44-year-old male, with insidious onset of paresthesia in the feet and hands, bilateral and symmetrical, progressing for a year. He presented hypoesthesia with stocking-glove distribution and distal hyporeflexia, with no other neurological changes. The electromyographic study was compatible with severe sensory-motor polyneuropathy. Blood test showed serum cyanocobalamin (Cb) levels of 178 pg/ml, hemoglobin (Hb) 12.1 g/dl, MGV 106 fl, with hyper-segmented neutrophils on peripheral blood smear and positive anti-parietal cell antibodies.

The upper endoscopy performed revealed the presence of atrophic gastritis and an ulcerated pulp formation, which was biopsied. The anatomopathological exam enabled the diagnosis of a well differentiated neuroendocrine tumor (NET), type 1.

Treatment with parenteral Cb was started, with a marked improvement in neurological symptoms and an Hb of 14.8 g/dl and MGV of 86.5fl, after a month. Complete excision of the gastric lesion was crucial, with no signs of recurrence on endoscopic follow up at 6 months. The patient maintains follow up in endocrinology and neurology outpatient clinic.

Discussion

This case emphasizes the importance of increased suspicion in patients presenting with peripheral neuropathic symptoms. The thorough investigation led to the recognition of pernicious anemia and later to the rare diagnosis of a well differentiated gastric NET. Pernicious anemia is a rare form of anemia caused by Cb deficiency. It often presents with megaloblastic anemia and neurological disorders, the last often as the presenting symptom.

Cb deficiency neuropathy is a rare, debilitating disease, and an early identification and correction of Cb deficiency is essential in preventing long term complications that can account for significant morbidity. Delayed treatment permits progression of the anemia and neurologic complications; therefore, a timely diagnosis is pivotal in the prognosis.

Cb supplementation, however, does not cure the atrophic gastritis, which can progress to gastric cancer.

Type 1 NET are associated with chronic atrophic gastritis and frequently with pernicious anemia (65%). They account for 70-80% of all gastric NET.

#898 - Case Report

IN SEARCH OF THE PRIMARY ABSCESS: A CLINICAL CASE OF CHRONIC APPENDICITIS

Yolanda De Sá Pereira¹, João Roque¹, Nuno Vieira Brito², Jorge Silova Ferreira², Maira Joao Gomes², Vitor Ramalhinho²

¹ Centro Hospitalar Universitário Lisboa Norte, Lisbon, Portugal

² Centro Hospitalar Universitario Lisboa Norte, Lisboa, Portugal

Introduction

Chronic appendicitis corresponds to 1% of all cases of appendicitis and has an atypical clinical presentation, being its diagnosis usually late and already in the presence of complications.

Case description

A 60 year old male recently released from prison without any previous diagnosis or chronic medication, and with past smoking and alcohol consumption, presented with complaints of asthenia and weight loss (15 kg in 4 months), associated with a 2-week history of constipation. At clinical examination the patient was emaciated, afebrile, with hepatomegaly, and a painless mass in the lower right abdominal quadrant. His laboratory finding showed, Hb 8.5g / L, ESR 62 mm, INR 1.33, Alkaline phosphatase 168 U/L, Gamma glutamyl transferase 68 U/L, Albumin 2.9 g/dL, Reactive Protein C 22.3 mg/dL, with no further changes. A Thoraco-Abdomino-Pelvic CT scan was performed, which identified 2 liver abscessed collections (17 cm of greatest diameter) and multiple fistulous trajectories with a starting point in the cecum region, and no thickening of the intestinal wall. Aspiration of the lesions were performed and empirical antibiotic therapy was initiated. Multisensitive *Escherichia coli* and Meticillin-resistant *Staphylococcus aureus* were isolated. Serologies of HIV, HBV and HCV were negative. Colonoscopy did not identify changes in the intestinal mucosa. Blood cultures, coproculture, eggs, cysts and

parasites in the faeces, the IGRA test, and assays of ANCA, AMA and alpha-fetoprotein were all negative. Fecal Calprotectin was elevated (2064 µg/g, reference <200). At the 30th day of antibiotic therapy, clinical improvement and favorable analytical response were observed. Comparative imaging was performed by CT scans that showed residual hepatic lesions without evidence of fistulas. Taking into account the clinical presentation and the findings of extensive fistulation of the vermiform appendix that resolved with antibiotic therapy, we established the diagnosis of Chronic Appendicitis.

Discussion

This case demonstrates how the diagnosis of Chronic Appendicitis can be complex, alerting to the need to include this entity in the differential diagnosis of nonspecific abdominal complaints, in order to avoid the complications that are frequently associated with it. It is also evident the need for a systematic review of the topic, in order to clearly define strategies for diagnosis and treatment.

#902 - Abstract

INTRAHEPATIC CHOLANGIOCARCINOMA WITH RADIOLOGIC ENHANCEMENT PATTERN MIMICKING HEPATOCELLULAR CARCINOMA

Luca Viganò^{1,2}, Ana Lleo^{1,2}, Riccardo Muglia¹, Nicolò Gennaro¹, Francesca Colapietro¹, Massimo Roncalli^{1,2}, Alessio Aghemo^{1,2}, Arturo Chitti^{1,2}, Luca Di Tommaso^{1,2}, Luigi Solbiati^{1,2}, Massimo Colombo², Guido Torzilli^{1,2}

¹ Humanitas University, Milano, Italy

² Humanitas Clinical and Research Hospital, Milano, Italy

Background

Non-invasive diagnosis of hepatocellular carcinoma (HCC) in cirrhotic patients requires demonstration of wash-in and wash-out on contrast-enhanced imaging. Recent studies have reported misclassification of mass-forming intrahepatic cholangiocarcinoma (MFCCC) as HCC. We aimed to analyze the contrast enhancement patterns of MFCCC and their association with prognosis, focusing especially on lesions mimicking HCC.

Methods

We retrospectively evaluated all consecutive patients with MFCCC who underwent surgery between 2007 and 2017. Patients with mixed HCC-MFCCC were excluded. Two expert radiologists reviewed preoperative CT and MRI. Full-nodule hyperenhancement in the arterial phase in conjunction with hypoenhancement in the portal/late phase was classified as an "HCC-like pattern". Imaging of MFCCCs with an HCC-like pattern was reviewed by an additional radiologist blinded to clinical data.

Results

The imaging studies of 92 patients were reviewed (18%

cirrhotics). All patients were investigated with multiphase CT and 85 with MRI. Twelve tumors (13%) showed full-nodule arterial hyperenhancement. Of these, four were hypoenhancing in the portal/late phase. Overall, 4/92 (4%) MFCCCs (4/45 in patients with cirrhosis/hepatitis, 9%) showed an HCC-like pattern accounting for misclassification as HCC on imaging review. HCC-like MFCCCs accounted for 9% of single tumors ≤ 50 mm. All HCC-like MFCCCs occurred in patients with cirrhosis or hepatitis, whereas only 47% of non-HCC-like MFCCCs did so ($p=0.053$). After a median follow-up of 29 months, 3-year survival was 62%. All patients with HCC-like MFCCCs are alive and disease-free (median 64 months).

Conclusion

MFCCC was misdiagnosed as typical HCC in 4% of all cases and in 9% of patients with single tumors ≤ 50 mm or with cirrhosis/hepatitis. Patients with HCC-like MFCCCs show a favorable survival. The risk of misdiagnosis should be considered prior to treatment planning.

#921 - Case Report

ATYPICAL EPSTEIN-BARR PRESENTATION - CASE REPORT

Pedro Carlos¹, Ana Dionísio¹, Clara Jorge¹, Sónia Coelho¹, Catarina Chaves², Artur Gama¹, Leopoldina Vicente¹

¹ Centro Hospitalar Universitário Cova da Beira, Covilhã, Portugal

² Centro Hospitalar Tâmega e Sousa, Penafiel, Portugal

Introduction

Epstein-Barr virus (EBV) is a widely disseminated member of the herpesvirus family, infecting up to 90% of the general population by the second decade of life. Infectious mononucleosis (IM) is the more frequent and recognizable presentation, with a triad of fever, generalized lymphadenopathy and pharyngitis. Mild liver involvement is common (80-90%), although clinical evident manifestations of hepatitis are infrequent and even more rarely, its sole presentation.

Case description

Woman, 66 years old, admitted to inpatient care with a 6-day duration clinical presentation characterized by asthenia, anorexia, postprandial vomit, right hypochondrial discomfort and intermittent fever with late-afternoon predominance. No mention of odynophagia, dysphagia or respiratory, genitourinary or other symptoms.

Previous relevant history of a probable unregistered episode of viral hepatitis 44 years prior and multiple hepatic cavernous haemangiomas with routine follow-up. No history of previous or recent usage of intravenous drugs or known hepatotoxic ingestion. No reference to known risk exposure.

On admission, mild hepatic involvement with cytolysis and cholestatic findings (AST 207, ALT 310, ALP 255, GGT 101, Total Bilirubin 0.8) and discrete elevation of c-reactive protein, abnormal

coagulation tests and thrombocytopenia. Clinical examination with no findings besides a mild hepatomegaly, anicteric without evidence of pharyngitis or lymphadenopathy.

Abdominal echography reveals only the cavernous haemangiomas previously found, no signs of splenomegaly. Further study concludes negative autoimmune markers, viral serology with positive EBV IgM and IgG antibody and HVA IgG antibody.

During hospital care, gradual remission of original symptoms with symptomatic treatment and supportive care. No complications besides mild transient increase of cytolysis and cholestatic pattern during the first week of stay and maintenance of intermittent fever until 48h before discharge (after 11 days).

Discussion

EBV primary infection frequently assumes a typical IM presentation, although its frequent liver involvement as a mild, self-limited and predominantly cholestatic pattern injury makes this an entity to be considered in the differential diagnosis of febrile anicteric cholestatic illness in immunocompetent adults, even in the rare cases with an atypical presentation such as described here. Therefore, an early investigation for EBV in these patients can promote a more expedite diagnosis and treatment in such cases.

#926 - Case Report

AMINOPHYLLINE SIDE EFFECT AS A RARE CAUSE OF CHRONIC DIARRHOEA: THE IMPORTANCE OF A CAREFUL HISTORY

Bruno Mendes^{1,2}, Carlos Figueiredo^{1,2}, Jose Sousa^{3,2}, Mariana Cabral^{3,2}, Catarina Pires^{3,2}, Tiago Pack^{3,2}, Afonso Rodrigues³, Teresa Garcia^{3,2}, Alexandra Mineiro^{1,2}, António Guerreiro^{3,2}, João Cardoso^{1,2}

¹ Pulmonology Department - Hospital Santa Marta, CHLC, Lisboa, Portugal

² Faculdade de Ciências Médicas, Universidade NOVA, Lisboa, Portugal

³ Internal Medicine Department - Hospital Santa Marta, CHLC, Lisboa, Portugal

Introduction

Chronic diarrhoea could be defined as persistent alteration of stool consistency and increased frequency greater than 4 weeks duration. Aminophylline is rarely associated with diarrhoea. We present a clinical case of difficult control chronic diarrhoea, where complementary diagnostic exams were inconclusive, and only a methodical review of clinical history allowed diagnosis.

Case description

81 year-old female, medicated with valsartan, furosemide, indacaterol/glicopyrronium and aminophylline. Known history of arterial hypertension, chronic obstructive pulmonary disease and heart failure. The patient went to emergency room because of 2 months weakness and diarrhoea, described as 3 to 4 defecations day of watery stool, with no blood or mucus. She lost 4 kilograms during this period. The patient didn't realize any change in diet or

medication. At examination she was hypotensive and dehydrated with no fever or abdominal pain during palpation. Abdominal radiography was clear. Laboratory exams revealed hypokalaemia and acute kidney lesion due to dehydration. During 2 weeks stay in internal medicine department she was medicated with valsartan, inhaled bronchodilators and intravenous fluid replacement. No diarrhoea or fever was ever recorded. Thoracic abdominopelvic computed tomography and colonoscopy were innocent. Biopsies of cecum mucosa showed the possibility of a microscopic colitis. The patient started rifaximin and mesalazine and was discharged with the same medication previous to admittance. She returned after three weeks of persistent symptoms, with new hypokalaemia. A detailed clinical history and records consultation was done. We found that aminophylline 225 mg oral was started, after a pulmonology consultation, two months before first admittance to hospital. This period was coincident with the beginning of diarrhoea. The fact was never mentioned by the patient. Aminophylline was never given during hospital stay. Aminophylline, rifaximin and mesalazine were suspended. Since one year no further diarrhoea was recorded.

Discussion

Diarrhoea as aminophylline's side effect was described in less than 1% of patients. The wide range of conditions that may lead to diarrhoea make it difficult to establish an investigation pathway. Nevertheless, clinical history is always the first and most important step in the diagnostic approach. Often patients are not able to give a detailed clinical history and a meticulous study of the clinical records is needed.

#982 - Abstract

PERIOSTIN ROLE IN LIVER CARCINOGENESIS

Carla De Benedittis, Mattia Bellan, Mauro Grandi, Violante Mulas, Martina Crevola, Rosalba Minisini, Martina Costanzo, Matteo Nazzareno Barbaglia, Venkata Ramana Mallela, Mario Pirisi
Università del Piemonte Orientale UPO, Novara, Italy

Background

Human Hepatocellular Carcinoma (HCC) represents a growing threat in developed countries, being the second leading cause of cancer-related death. The majority of HCC cases (90%) develops in the context of a chronic liver disease (CLD). Periostin is an extracellular matrix protein, which has been recently proposed as a promising determinant of liver disease progression from CLD.

Aim of the present study was to investigate the possible role of periostin plasma levels as an early marker of HCC development in patients with CLD and to evaluate the impact of three periostin gene (POSTN) single nucleotide polymorphisms (SNPs) on CLD and circulating Periostin levels.

Methods

A total of N.=399 cases (N.=247 HCC, N.=74 HCV and N.=78 NAFLD patients) and N.=104 healthy controls were genotyped for

POSTN gene SNPs with restriction fragment length polymorphisms technique and a haplotype analysis was performed. An ELISA assay was performed on available serum samples in all the 4 groups to determine circulating Periostin concentrations. Clinical data were collected for the whole population.

Results

The genotype and haplotype analysis found 7 haplotypes, of which haplotype 2 was the most prevalent. A dominant model for haplotype 2 was built and analysed in the different groups: in patients with CLD haplotype 2 was more prevalent than in those with HCC, nearly touching statistical significance (84.% vs 76.1%; p=0.053).

The median circulating periostin was 31.9 ng/ml (21 – 50.1) in HCC group, 11.4 ng/ml (9.1–16.5) in the HCV group, 10.1 ng/ml (7.1–13.8) in the NAFLD group being, therefore significantly higher in patients with HCC than in case of CLD alone (p<0.001). The carriers of haplotype 2, according to a dominant model, showed a lower periostin plasma levels (14.5 [9.6-21.4] ng/ml vs. 18.8 [10.7-30.4] ng/ml for 2/*+2/2 vs. */* respectively; p=0.02).

Conclusion

Periostin is a promising marker of HCC among CLD patients; moreover, the presence of POSTN haplotype 2, in a dominant model, might confer protection from progression to HCC, being associated to a lower periostin plasma concentration.

#1006 - Case Report

A CASE OF MULTIPLE KLEBSIELLA LIVER ABSCESES: A HISTORY TO BE CONTINUED?

Mariana Brandão, Telmo Borges Coelho, Maria Alves, Paula Ferreira, Manuela Sequeira, Vítor Paixão Dias
Centro Hospitalar Vila Nova de Gaia/Espinho, Vila Nova De Gaia, Portugal

Introduction

Liver abscess (LA) is usually caused by enteric gram-negative bacilli. LA typically occur in the presence of predisposing factors, such as biliary tract disease, surgery or peritonitis. An association between Klebsiella LA (KLA) and gastrointestinal (GI) malignancy was suggested in retrospective studies, mainly in Asia.

Case description

A previously asymptomatic 63-year-old man, with prior smoking and alcoholism, presented to the emergency room with a 2-day-history of fever, shivering, anorexia and abdominal pain in the right upper quadrant. He denied other GI symptoms, choloria or pruritus. He also denied previous abdominal surgery, contact with cattle or contaminated water, recent travel or risky sexual behavior. On examination, he had tenderness in the right hypochondrium and a palpable liver edge. Laboratory testing revealed normocytic normochromic anemia (Hb 11.6 g/dl) and elevated C reactive protein (10.5 mg/dl), without liver cytolysis or cholestasis. Abdominal tomography (CT) showed periportal

edema and countless millimetric hypocoaptant thin-walled hepatic lesions (Figure 1), suggestive of microabscesses, without evidence of biliary disease (BD). Empirical therapy with Ceftriaxone and Metronidazole was initiated. Blood cultures (BC) were positive for *Klebsiella oxytoca*. Additional serologic tests and viral markers were negative. Transthoracic echocardiogram was negative for vegetations. The patient gradually improved, and BC became negative. Upon discharge, 2 weeks after, multiple lesions without halo persisted on CT. Hence, he was referred to our Day Hospital Unit for clinical and imaging reevaluation and endoscopic screening for colorectal disease (CRD) [results pending]. Cefuroxime was prescribed to complete 6 weeks of antimicrobial therapy.

Discussion

In this case, LA presents without an apparent causal mechanism, with an unusually reported agent in European countries. Still, the patient had a history of alcoholism, a risk factor for *Klebsiella* infection. CT was remarkable for typical findings in KLA, such as thin-walled lesions without halo. However, KLA are usually solitary, and countless lesions were observed here. Given the absence of hepatobiliary disease, the possibility of concurrent CRD was considered, and the patient was referred for endoscopy. In previous studies, patients with LA caused by *Klebsiella pneumoniae* had a stronger association with subsequent colorectal cancer. Therefore, in patients with KLA without underlying BD, wary screening for CRD is encouraged.

#1009 - Case Report

AUTOIMMUNE ATROPHIC GASTRITIS: A CASE REPORT

Carolina Nunes Coelho, Iuliana Cusnir, Diana Vital
Hospital de Santarém, Lisboa, Portugal

Introduction

Autoimmune Metaplastic Atrophic Gastritis (AMAG) is a form of chronic gastritis associated with autoantibodies against parietal cells, which can lead to vitamin B12 malabsorption. It is a rare condition, generally asymptomatic, and therefore a challenging diagnosis to the clinicians.

Case description

The authors presents a case of a 71 years old man with type 2 diabetes, arterial hypertension and dyslipidemia. At admission in the emergency department he presented with symptom of fatigue with several weeks long, and routine blood analysis with anaemia. Therefore he was hospitalised in our Internal Medicine ward to further investigation. Laboratory testing reveal low valor of hemoglobin (9.2 g/dL, with high valor of VGM), leucopenia ($25 \times 10^9/L$ with 35.6% of neutrophils) and trombocitopenia ($78 \times 10^9/L$). Reticulocyte were above the normal range. Other laboratory findings disclose a very low level of vitamin B12 <83 pg/ml (normal range 187-883 pg/ml), with normal folates and iron metabolism. He was positive for antiparietal cell antibodies but

negative anti-intrinsic factor antibodies. The patient underwent endoscopy examination which revealed diffuse atrophy of the gastric mucosa, with no suspicious lesions. Biopsy samples were endoscopically taken from antrum and gastric body and showed chronic gastritis with severe atrophy and intestinal metaplasia, consistent with AMAG findings. *Helicobacter pylori* testing was negative. Thyroid function was normal and there was no signs of vitiligo. It was initiated vitamina B12 correction and the patient was discharged with oral cyanocobalamin supplements. About 3 months later, the patient was reassessed in hospital consultation with no symptoms and new laboratory results showed normal level of hemoglobin, white cells and plaquets.

Discussion

This case report show the workup from unespecif symptom (fatigue) and anaemia to the diagnosis of a rare autoimmune disease. The diagnostic criteria have not yet been established, moreover the diagnosis of AMAG is made on laboratory testing, endoscopic examination, and biopsy results. AMAG is frequently associated with others autoimmune pathologies, but not presented in this case. The patient is still ongoing being monitored because of associated risk with gastric cancer.

#1013 - Abstract

UPPER GASTROINTESTINAL BLEEDING: ARE PATIENTS WITH LOW LEVEL HEMOGLOBIN ANY DIFFERENT?

Carolina Nunes Coelho, Bruna Nascimento, Ana Garrido Gomes, Iuliana Cusnir, Bruno David Freitas, Marta Guisado Orantos, Maryna Telychko, Diana Vital, Stela Calugareanu, Sandra António
Hospital de Santarém, Santarém, Portugal

Background

Upper Gastrointestinal Bleeding (UGB) is defined as mucosal bleeding from the proximal portion of the esophagus to the ligament of Treitz, with a high global mortality rate. Level of hemoglobin at admission is a valuable contribution to the risk stratification of clinical outcome. Objective: We aim to analyse the group of patients with an hemoglobin level at admission <8g/dL, within all cases diagnosis of UGB hospitalized in an Internal Medicine (IM) ward.

Methods

The authors consider all patients with the diagnosis of UGB hospitalized in a IM ward between january and december 2018. Through revision of clinical electronic data, we evaluated the following variables in both groups: age, sex, comorbidities, ambulatory medication, endoscopic findings, medical intervention, hospitalization length.

Results

There were a total of 38 cases with UGB hospitalized in our IM ward in 2018. The median age of the patients was 75.1 years, and

the majority were men (68.4%). Twenty cases (52.6%) presented to the emergency department with a hemoglobin level lower than 8g/dL. Average age was equal in both groups, however patients which presented with lower hemoglobin were more frequently women (45.0% vs 16.7%). The clinical presentation was also different between both groups, melenas were present in 70% of the patients who was admitted with Hb <8g/dL, and only in 44.4% of the remain. In this group of patients there was a higher history of anticoagulant therapy (35% vs 16.7%). However, the antiplatelet agents were used by 50% of the patients with higher hemoglobin level at admission, in comparison with 20% of the rest. The average Glasgow Blatchford Score (GBS) in the group with <8 g/dl of hemoglobin was 14.0 and 10.2 in the group with higher level of hemoglobin. The endoscopic examination was more frequently done in patients with lower hemoglobin (90%) than with cases with >8g/dl of hemoglobin (77.8%) Patients with a lower hemoglobin level had a prolonged length of hospital stay (13.2 days in opposition to 8.7 days). There was only one death in-hospital and it was a patient who presented a 5.7 g/dL level of hemoglobin at admission.

Conclusion

The studied group of patients with the diagnosis of UGB with hemoglobin <8g/dl at admission were more frequently women, presented more often with melenas, and taking anticoagulant therapy. Also, the GBS score was higher and had a longer hospital stay.

#1015 - Abstract

ONE YEAR HISTORY OF UPPER GASTROINTESTINAL BLEEDING

Ana Garrido Gomes, Carolina Nunes Coelho, Bruna Nascimento, Bruno David Freitas, Iuliana Cusnir, Marta Guisado Orantos, Maryna Telychko, Diana Vital, Stela Calugareanu, Sandra António Hospital de Santarém, Santarém, Portugal

Background

Upper Gastrointestinal Bleeding (UGB) is a common medical emergency, with a high global mortality rate. The correct initial evaluation of these patients and therapeutic management still a clinical challenge.

The objective is to evaluate the cases with the diagnosis of UGB hospitalized in an Internal Medicine (IM) ward.

Methods

The authors consider all patients with the diagnosis of UGB hospitalized in a IM ward between January and December 2018. Through revision of clinical electronic data, we evaluated the following variables: age, sex, comorbidities, ambulatory medication, endoscopic findings, medical intervention, hospitalization length and outcome. The Glasgow-Blatchford scoring (GBS) system was calculated with clinical and laboratory data in the emergency department (ED).

Results

There were a total of 38 cases with UGB hospitalized in our IM ward in 2018. The median age of the patients was 75.1 years, and the majority were men (68.4%). Ten patients were previously anticoagulant users and n=13 patients were taking anti-platelet drugs. Five patients were described as having a prolonged history of NSAIDs intake. Six patients had a history of previous admissions with UGB and four had chronic hepatic disease diagnosed at an early stage. At the ED, 57.9% of the patients had melena and 36.8% had hematemesis. The mean value of hemoglobin was 8.39 g/dL. The average GBS score at admission was 12.2, with a minimum value of 5 and maximum of 16. In regard to medical treatment, 89.5% were prescribed a perfusion of proton-pump inhibitor. The majority of the patients (71.1%) required blood transfusion and 23.7% underwent plasma transfusion. Endoscopy is the primary tool for diagnosis and treatment. Only 26.3% of the endoscopic exams were performed in the first 24 hours since admission. The most common endoscopic findings were gastric (n=11) and duodenal ulcer (n=9), with two patients having esophageal varices. The endoscopy did not reveal the specific site of hemorrhage in 23.7% of the cases. None of the patients were submitted to surgical treatment. We obtained a medium in-hospital stay of 11.0 days. The in-hospital mortality was 2.6% (n=1).

Conclusion

The studied population showed increased age, major medical conditions, previous antithrombotic therapy and high clinical risk at presentation. It is necessary to improve management of these patients with early therapeutic endoscopy medical treatment to reduce the risk of life threatening bleeding and decrease mortality.

#1074 - Abstract

INTRAMUSCULAR DICLOFENAC AS PROPHYLAXIS FOR POST-ERCP PANCREATITIS

Luis Fernando Sandoval, Gerson Emir Avila, Abel Sánchez Hospital Roosevelt, Guatemala, Guatemala

Background

Post-ERCP pancreatitis (PEP) is one of the potentially serious complications of this procedure; in general population it occurs in approximately 1% to 10% of patients, but most cases are mild or moderate. Several studies have demonstrated the safety and efficacy of NSAIDs in the prevention of PEP. However, most of these trials have used the rectal route and it is not clear whether the parenteral route of administration is as effective as the rectal route.

Methods

We proceeded to take the data of all patients scheduled for ERCP in the Gastroenterology Unit of Hospital Roosevelt, during the months of March and April of 2019. After the procedure they were followed up for 24 hours looking for signs of acute pancreatitis. If suspected, it was confirmed and the complication was managed.

Results

A total of 42 patients were included, which were randomized in the study group - 18 (diclofenac 75 mg) and control group - 24 (0.9% saline). Two patients presented PEP, which is equivalent to 4.76% of the sample. The use of intramuscular diclofenac was not statistically significant among the patients studied. The only value that showed difference was the white blood cell count.

Conclusion

There is no difference between the events of acute pancreatitis in patients undergoing ERCP with the use of diclofenac 75mg intramuscularly.

#1080 - Case Report

SEVERE HYPOMAGNESEMIA INDUCED BY CHRONIC USE OF PPI

Antonio Eliseu, Teresa Furtado, Paula Lopes, Filipa Silva, Lucia Gil, Rita Silverio, Ermelinda Pedroso

Centro Hospitalar de Setúbal, Setúbal, Portugal

Introduction

Proton pump inhibitors are a pivotal therapy for all gastric acid-related diseases. The chronic use of PPI (> 1 year) have been described in small numbers of case reports to induce hypomagnesemia. The presumed mechanism is impaired absorption of magnesium by intestinal epithelial cells. Severe hypomagnesemia is rare, being generally asymptomatic until reaching serum levels < 1.25 mg/dL. Symptomatic magnesium depletion is usually associated with biochemical abnormalities such as hypocalcemia and hypokalemia. The major clinical manifestations are neuromuscular, cardiovascular and abnormalities of calcium metabolism. Very low levels of magnesium lead to a hypoparathyroidism state and parathyroid hormone resistance.

Case description

Male, 64 years old

Past medical history: Hypertension, DM type 2 and GERD.

Medication history: ARB+Thiazide, Beta Blocker, PPI (> 1 year), Aspirin and metformin.

The patient was admitted in the emergency room with altered level of consciousness associated with tonic clonic seizures. He also complained of thoracic pain, hemisensory loss in the left arm, nausea and vomiting and had history of muscle cramps for the last 6 months. His laboratory evaluation revealed a hypocalcemia (6.2 mg/dL), hypokalemia (2.6 mmol/L) and a severe hypomagnesemia (<0.7 mg/dL). The ECG had a Long-QT and Head-CT had no pathological features. It was initiated electrolyte replacement therapy (Magnesium Sulphate, Calcium Gluconate and Potassium Chloride) and the patient was moved to Internal Medicine ward. More laboratory studies were done showing a serum PTH low-normal level and a 24h urine sample with low urinary magnesium level. After a couple of days of magnesium repletion, the PTH levels

showed a rapid rise and magnesium, calcium and potassium levels reached normal values. It was admitted a severe hypomagnesemia induced by the chronic use of PPI. The use of PPI was suspended and initiated ranitidine in substitution. The patient was discharged and reevaluated being asymptomatic and with normal levels of magnesium.

Discussion

We should suspect of hypomagnesemia when patients present with hypocalcemia and hypokalemia of unknown etiology, especially if they are being refractory to electrolyte replacement. In patients with chronic use of PPI measurement of magnesium serum levels is recommended before treatment initiation and periodically. Hypomagnesemia resolves with cessation of PPI therapy.

#1101 - Medical Image

PANCREATIC LIPOMA, AN UNUSUAL FINDING

Carla Pereira Fontes, José Moura Meireles

Centro Hospitalar de Entre o Douro e Vouga (CHEDV), Santa Maria Da Feira, Portugal

Clinical summary

A 45-year-old man, with no significant comorbidities, presented with epigastric discomfort and vomiting of 2-hour duration. Beyond epigastric tenderness, physical examination was unremarkable. Laboratory evaluation, including liver function tests and pancreatic enzymes, was normal. Considering his persistent complaints, an abdominal computed tomography was performed and a 15 mm fat containing lesion in the pancreatic body was noted.

Pancreatic lipoma is a rare and benign mesenchymal tumor, consisting of adipocytes. It's commonly asymptomatic appearing as an incidental mass during screening, and usually managed in a conservative way with radiologic monitoring; surgery treatment is only offered when it's causing symptoms, compressing on vital structures, or if any malignant changes occur.

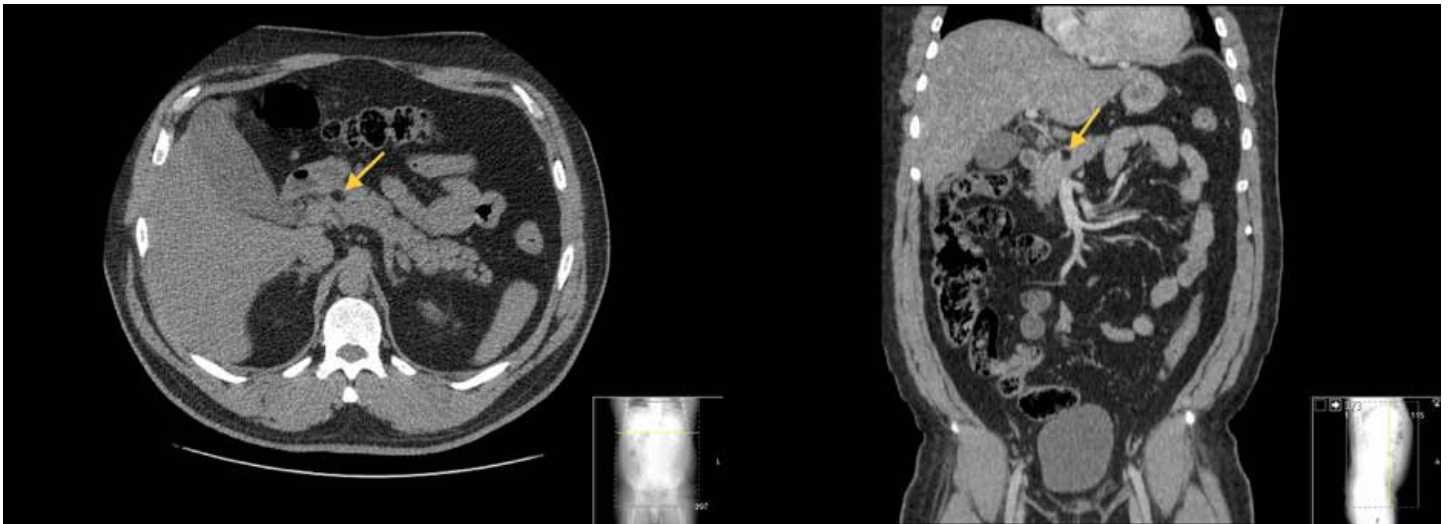


Figure #1101. Lipoma of the pancreatic body on the transverse (left) and coronal (right) contrast-enhanced computed tomography scan: a 15-mm, round, fatty, nonenhancing mass circumscribed by normal parenchyma (arrows).

#1107 - Case Report

MACROCYTIC ANEMIA DUE TO VITAMIN B12 DEFICIENCY: DO NOT OVERLOOK CELIAC DISEASE

Annelies Meuwissen¹, Gil Verschelden¹, Shaira Sahebali², Sabine D. Allard¹, Rembert Mertens¹, Patrick Lacor¹

¹ UZ Brussel, Department of Internal Medicine, Brussels, Belgium

² UZ Brussel, Department of Anatomopathology, Brussels, Belgium

Introduction

The causes of Vitamin B12 deficiency include disorders affecting absorption in the small bowel. Among these is celiac disease. The mechanism is not completely understood and probably multifactorial. It is hypothesized that decreased pancreatic protease production resulting in inhibition of binding of intrinsic factor to vitamin B12 might be involved.

Case description

A 45-year-old male was admitted to the hospital because of general weakness, lowered exercise tolerance and vague epigastric pain. On physical examination, he appeared pale and slightly icteric. Blood analysis revealed a macrocytic anemia (hemoglobin 7 g/dl, MCV 116 fl), with a normal white blood cell count and differential, and a slight thrombocytopenia ($149.000/\text{mm}^3$). There were signs of hemolysis (serum unconjugated bilirubin 2.14 mg/dl, LDH 5510 IU/l, haptoglobin <0.10 g/l) with a negative direct antiglobulin test. Vitamin B12 serum level was unmeasurably low (<0.1 $\mu\text{g/l}$), folic acid in serum and red blood cells was normal, as well as serum ferritin (181 $\mu\text{g/l}$). Auto-antibodies to intrinsic factor and parietal cells were negative. Measurement of immunoglobulin levels showed selective IgA deficiency. Serum tissue-transglutaminase IgA antibodies were absent, serum anti-deamidated gliadin peptide-IgG was positive. Gastric endoscopy showed signs of duodenitis with duodenal villous atrophy Marsh-Oberhuber type 3b on biopsy, leading to a diagnosis of celiac disease.

Discussion

Although iron deficiency anemia is the most common extra-intestinal sign of celiac disease, vitamin B12 deficiency can also be involved in the pathogenesis of anemia in these patients. In our patient, it appeared to be the sole mechanism. This finding illustrates the importance of including celiac disease in the differential diagnosis of macrocytic anemia, even in the absence of iron deficiency.

#1122 - Abstract

CHANGES IN SERUM LEVEL OF KERATIN-18 (TPS) IN PATIENTS WITH CHRONIC HEPATITIS C WHO RECEIVED DIRECT-ACTING ANTIVIRAL THERAPY

Cristina Macía-Rodríguez¹, Emilio Paez-Guillán², Alba García-Villafranca², Ana Teresa Afonso², Esteban Otero², Santiago Tomé², Arturo González-Quintela²

¹ POVISA, Vigo, Spain

² Complejo Hospitalario Universitario Santiago de Compostela, Santiago De Compostela, Spain

Background

Hepatocytes apoptosis plays an important role in the pathogenesis of chronic hepatitis C and in the development of liver fibrosis. Keratin-18 is a major component of hepatocyte cytoskeleton. During the apoptosis is cleaved by caspases and its fragments (TPS) are released to the blood stream.

Methods

The study included patients with chronic hepatitis C treated with direct-acting antiviral therapy in the Internal Medicine Department of the Santiago de Compostela University Teaching Hospital (NW Spain) between 1 February 2015 and 1 February 2016. Serum K-18 (TPS) was measured before and after the treatment.

Results

We included a total of 149 patients, 68.5% men and median age 53.0 years (IQR: 46.0-58.0 years). 98.0% of the patients achieved sustained virological response 12 weeks after treatment. After treatment, we observed a significant reduction of serum TPS levels. 12 weeks after treatment, 51.7% of the patients presented an elevated TPS and 66.0% of them presented another cause of TPS alteration: 13 metabolic syndrome with mellitus diabetes or obesity, 11 were alcohol-consuming, 3 had a pharmacological hepatotoxicity, 2 presented a hepatocellular carcinoma, 4 had a carcinoma different than hepatocellular, 1 presented a recurrence of hepatitis C virus and 1 an autoimmune hepatitis.

Conclusion

After treatment we observed an improvement of K-18 fragments levels. A persistent elevation of K-18 fragments after treatment can indicate the coexistence of another liver damage.

#1166 - Medical Image

AN UNEXPECTED FINDING

Ana Filipa Pinho, Isabel Silva

Hospital de Braga, Braga, Portugal

Clinical summary

Klatskin tumors are cholangiocarcinoma of the hepatic hilar duct bifurcation, that have distinct biological behavior, natural history and therapeutic strategy from distal cholangiocarcinoma. Risk factors are primary sclerosing cholangitis, biliary calculi and parasitic liver disease. The absence of early symptoms explains the advanced stages at diagnosis. An 86-year-old woman performed a thoracic CT scan to rule out pulmonary thromboembolism. Incidentally it was found a dilated intrahepatic bile duct with an hyperdense area in the biliary duct bifurcation of 15 mm (CT scan - images 1-2, MR cholangiopancreatography 3-4). Diagnosis: Bismuth-Corlette type II Klatskin Tumor. The advanced age and multiple comorbidities determined that the patient was not a candidate for surgery.

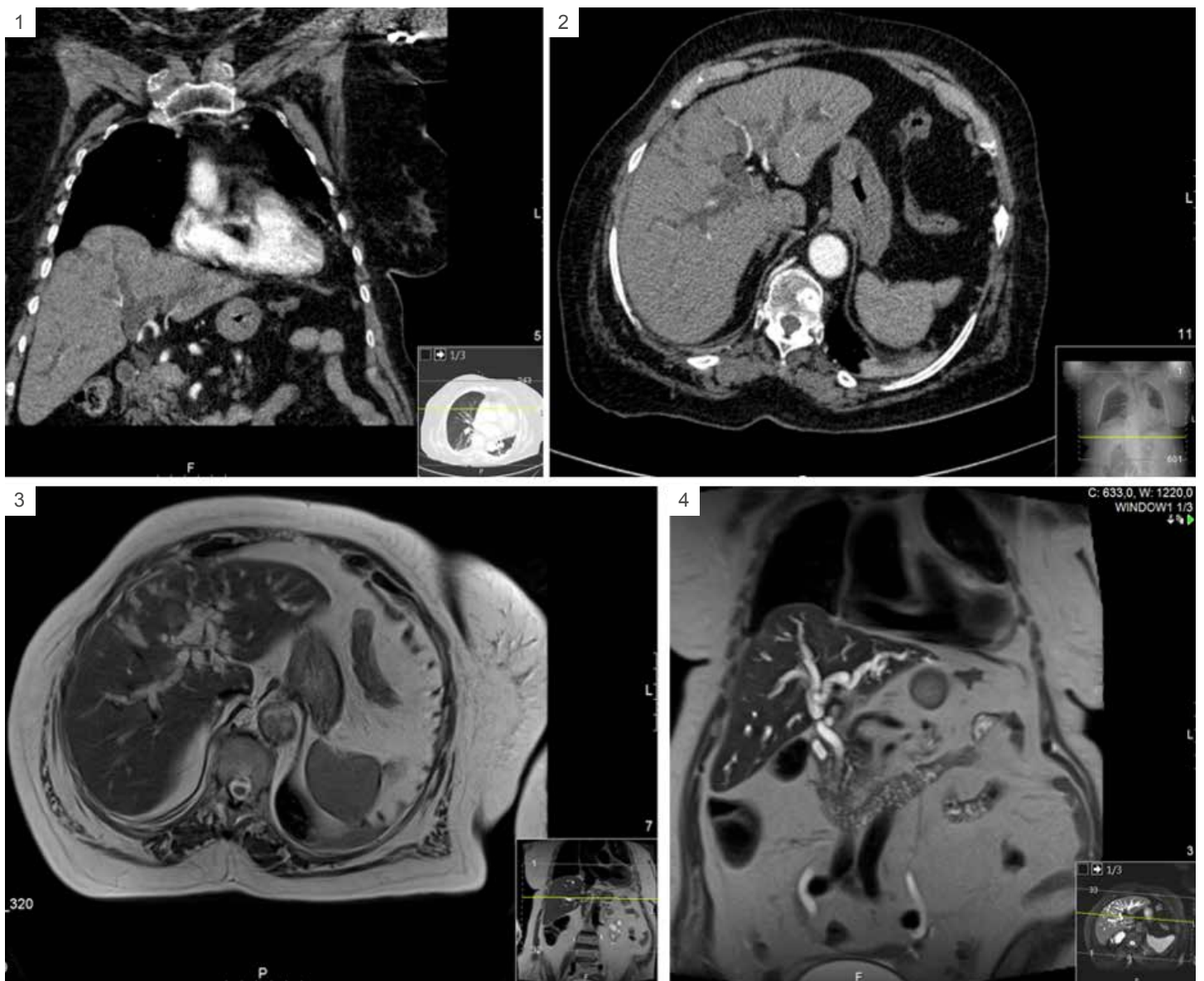


Figure #1166. Above - 1 and 2 - CT scan. Below - 3 and 4 - RM cholangiopancreatography.

#1174 - Abstract

SERUM KERATIN 18 FRAGMENTS (TPS) ARE RELATED TO LIVER FIBROSIS IN PATIENTS WITH CHRONIC HEPATITIS C

Cristina Macía-Rodríguez¹, Emilio Paez-Guillán², Alba García-Villafranca², Ana Teresa Afonso², Esteban Otero Anton², Santiago Tomé Martínez De Rituerto², Arturo González-Quintela²

¹ POVISA, Vigo, Spain

² Complejo Hospitalario Universitario de Santiago de Compostela, Santiago De Compostela, Spain

Background

Hepatocytes apoptosis plays an important role in the pathogenesis of the disease and in the development of liver fibrosis. Keratin-18 is a major component of hepatocyte cytoskeleton. During the apoptosis keratin-18 is cleaved by caspases and its fragments (TPS) are released to the blood stream.

Methods

We included patients with chronic hepatitis C. We measured serum TPS and performed a transient elastography and we calculated the fibrosis biomarkers score APRI and FIB-4. We used Spearman's rank test (for bivariate correlation) to analyze the relation between the variables, and COR curves were used to evaluate the capability of TPS and biomarkers score to predict liver stillness. We considered $p < 0.05$ to be statistically significant.

Results

We included a total of 111 patients, 67.6% men and median age 52.0 years (IQR: 46.0-57.0 years).

Serum TPS levels were significant correlated with liver stillness ($\rho = 0.47$). We plotted ROC curves to evaluate if TPS or biomarkers score could predict liver stillness. The area under the ROC curve (AUC) for discriminating severe fibrosis (more than grade 3 using transient elastography, $F \geq 3$) was 0.75 (CI 95% 0.65-0.84) with TPS, 0.77 (CI 95% 0.69-0.87) with Fib-4 and 0.80 (CI 95% 0.72-0.89) with APRI. The cut-off point at 140 U/l of TPS predicted $F \geq 3$ with a sensibility of 80.6 % and a specificity of 54.5%. The cut-off point at 1.5 of APRI predicted $F \geq 3$ with a sensibility of 45.5% and a specificity of 92.9%. The cut-off point at 3.25 of Fib-4 predicted $F \geq 3$ with a sensibility of 42.4% and a specificity of 85.7%

Conclusion

In conclusion, serum levels of K-18 fragments can be used to estimate liver fibrosis.

#1182 - Case Report

CROH'S FULMINANT DISEASE IN A VIH-1 PATIENT

Domingos Sousa^{1,2}, Sérgio Antunes Silva¹, Catarina Jorge¹, Rita Martins Fernandes¹, Ana Isabel Rodrigues¹, Margarida Viana Coelho¹, Rui Osório¹, Amparo Mingo¹, Elena Rios¹, Armindo Figueiredo¹

¹ Centro Hospitalar Universitário do Algarve, Faro, Portugal

² Faculdade de Ciências da Saúde - Universidade da Beira Interior, Covilhã, Portugal

Introduction

Crohn's disease (CD) is a chronic inflammatory disease of unknown cause, characterized by discontinuously affected areas with transmural granulomatous inflammation and/or fistula. CD can affect any region in the digestive tract from the mouth to the anus but is more likely to involve the small and large intestines (especially the ileocecum) and the perianal region. The inflammation is initiated and perpetuated by an overly aggressive T-cell-mediated immune response to an unknown environmental antigen in a genetically susceptible host. In the rare cases where CD and HIV infection coexist, it has been speculated that a progressive decline in CD4+ count, caused by HIV, might remit CD disease activity.

Case description

A 51-year-old woman with a past medical history of HIV-1 with a good immunological state (T-cell CD4+ 634 cells/mm³) and virologic suppression, diabetes mellitus type 2, former iv-drug user and active smoker was admitted with a 3-month history of weakness, intermittent diarrhoea and anorexia. Laboratory studies revealed elevation of inflammation markers and a microcytic hypochromic anaemia (6.0 g/dL) with evidence of iron deficiency. Colonoscopy revealed small ulcerations at the cecum and ascending colon. Biopsy of colonic mucosa described acute inflammation with cryptitis and cryptic abscess and was negative for helicobacter pilori. Coprocultures, Clostridium difficile and tissue transglutaminase (IgA and IgG) antibody were negative. Faecal calprotectin was elevated (6421 µg/g).

Patient's evolution was unfavourable with development of a septic shock with multiorgan failure being transferred to an intensive care unit and eventually dying.

Discussion

CD cardinal symptoms are chronic diarrhoea with abdominal pain that was present on our case. In addition, the histopathological findings and elevated faecal calprotectin further support the diagnosis of CD.

Our case highlights that HIV patients with a good immunological state can present with more aggressive CD because T-cell CD4+ play a major role on the pathophysiology of immune response in CD. CD is a result of a dysregulation of mucosal immune system with activation of mucosal T-lymphocytes and production of proinflammatory cytokines which leads to extensive mucosal or transmural injury which caused the patient's to develop a septic shock.

#1195 - Case Report

ANTI-HU SYNDROME - A TRULY RARE ENTITYFilipa Lucas¹, Miguel Alve², Tatiana Oliveira¹¹ Hospital de Cascais, Cascais, Portugal² ULS Nordeste, Bragança, Portugal**Introduction**

Chronic intestinal pseudo-obstruction (POIC) is a rare disorder characterized by partial/total absence of gastrointestinal propulsion.

This entity may be idiopathic or secondary to infections, drugs, paraneoplastic syndromes, etc. Of these, we highlight the anti-Hu syndrome, which almost always appears in a paraneoplastic context, and is mediated by autoantibodies, which react against neuronal proteins. Anti-Hu antibodies correspond to an antineuronal antibody that recognizes a protein expressed in the nuclei of the neuron (ANNA-1) and neoplastic cells.

In POIC these autoantibodies attack the intestinal nervous plexuses. The common genesis seems to be an immune disorder that conditions injury of the intestinal nerve plexuses with alteration of motor plaque transmission and subsequent aganglionosis.

Case description

Two clinical cases with early postprandial constipation and vomiting are presented, in which serology revealed anti-neuronal antibody anti-HU positivity.

The study of one case revealed a thymoma as an etiology. The other remains idiopathic, so screening for an underlying neoplasm remains an imperative, since there may be a 8 years delay between symptoms and tumor.

Discussion

Paraneoplastic CIPO is a very rare entity and is highly difficult to treat. Advances in functional studies and histological analysis have enabled a better understanding of the pathogenesis of this syndrome, which is defined as an enteric neuromuscular disorder that frequently involves various segments of the digestive tract. Screening for Anti-HU antibodies is recommended for diagnosing intestinal dysmotility associated with enteric ganglionitis.

The treatment of this entity is based on a symptomatic approach, using cholinergic, immunomodulatory, and prokinetic therapy, plasmapheresis, but without significant benefits.

We highlight these two highly rare and complex cases (about 30 cases reported in the literature), that pose several diagnostic and therapeutic challenges.

#1198 - Case Report

APPROACH OF ASCITES – THE IMPORTANCE OF MEDICAL HISTORY

Luciana Silva, Catarina Almeida, Ana Mondragão, Joana Cochicho, Luís Andrade, Vitor Paixão Dias

Centro Hospitalar de Vila Nova de Gaia e Espinho, Vila Nova De Gaia, Portugal

Introduction

Ascites is a frequent complication of cirrhosis but up to 20% of the cases are related to other conditions such as heart failure, nephrotic syndrome, malignant conditions, granulomatous diseases or infections.

Case description

A 42-year-old woman born in Angola, living in Portugal since 2002, presented to the emergency department with nonbloody diarrhea preceded by abdominal colic pain. The symptoms began 6 days before and were associated with vomiting. On the 3rd day, fever started and she noticed a gradual increase in abdominal girth. She mentioned asthenia and anorexia, without weight loss or night sweats. Her medical history was relevant to sickle cell trait and asthma.

At presentation, she was febrile with a swollen painful abdomen compatible with large ascites. The blood analyses revealed hemoglobin of 10,5 g/dl, no leukocytosis or thrombocytopenia, Na⁺ 130 mmol/L, LDH 426 U/L and C-reactive protein of 19,21 mg/dl. The abdominal US and abdominal CT showed ascites and increased density in mesenteric root's resembling peritoneal carcinomatosis.

She was admitted to the Internal Medicine ward for further evaluation. The peritoneal fluid (PF) analysis revealed 1528 leukocytes/uL 28% polymorphonuclear and 72% mononuclear, LDH 642 U/L, proteins 6.1 g/dl, ADA 255 U/L and serum-ascites albumin gradient was <1,1. Microbiological analysis of PF and Ziehl-Neelson (ZN) stain were negative. PET-CT reported hypermetabolic focus suggesting adenopathies, peritoneal lesions suggesting malignant infiltration and hypermetabolic focuses between the hepatic hilus, head of the pancreas and spleen. The peritoneal implants biopsy's revealed chronic inflammatory infiltrate that included epithelioid histiocytes with granuloma formation without necrosis.

Three weeks later the culture for mycobacteria came positive for Mycobacterium tuberculosis complex, leading to the diagnosis of peritoneal tuberculosis (TB). At this time, the patient revealed that she had pulmonary TB when she was in Angola. She started antituberculous treatment.

Discussion

TB is characterized by generic symptoms and involvement of a range of organs. The peritoneum is one of the extrapulmonary sites more frequently affected. The ADA elevation and the prevalence of mononuclear cells in PF led us to consider this diagnosis. However the negativity of ZN stain and the radiological suggestion of malignancy led to further evaluation.

Despite the effective treatment, there is still a social stigma associated with TB, hindering its control.

#1199 - Abstract

CORRELATION BETWEEN SYSTEMIC AND LOCAL INFLAMMATION IN INTESTINAL TRANSIT DISORDERSCristina Voicu¹, Sorin Rugina²¹ Sfântul Apostol Andrei, Constanta, Romania² Ovidius, Constanta, Romania**Background**

Chronic diarrhea is a challenge for the clinician as it has a significant impact on the overall health and quality of life. Statistically, an adult has at least five episodes of diarrhea per year.

Methods

81 patients were included in the Medical Clinic I and the Gastroenterology Department of Constanta Emergency County Hospital between October 2014 and October 2017 and had fulfilled the required criteria, respectively manifested transit disorders of the type diarrhea or alternating diarrhea/constipation of at least four weeks duration, excluding the infectious pathology. Out of the 64 patients 39 are men and 42 women aged 19 to 89 years. The batch of tests included biological investigations in the blood (blood count, inflammatory syndrome represented by the reactive C protein, velocity of sedimentation of red blood cells and fibrinogen, serum proteins), in faeces (coprocitogram, coproparasitologic, coproculture, calprotectin) and endoscopic investigations, respectively superior digestive endoscopy and endoscopic colonoscopy (biopsy where applicable).

Results

The average age was 54 years. A total of 31 patients with Crohn's disease, 7 patients with microscopic colitis, 7 patients with ulcerative haemorrhage colitis, 4 patients with celiac disease, 14 patients with colorectal neoplasms and 18 patients with irritable bowel have been diagnosed.

Depending on the complications, three stenosis forms, a stenosis-shaped form, and a complicated Crohn's disease with two fistulas (entero-enteral and entero-bladder) were diagnosed. Systemic inflammation is not correlated with intestinal inflammation, since in patients without systemic inflammatory syndrome, faecal calprotectin ranges from 79 mg/kg to 3,635 mg/kg, a value comparable to that of patients in whom the inflammatory syndrome is represented by the four measured components (leukocyte count, VSR, RCP and fibrinogen).

Conclusion

A correct assessment of intestinal inflammation can be diagnosed with pathologies with a high impact on health and quality of life at an early stage. It has been shown that systemic inflammation markers do not reflect intestinal inflammation and can not be used in quantification of inflammation. Using faecal calprotectin in diagnostic test batches for transit disorders, in particular chronic diarrhea, morbidity and mortality can be reduced by organic intestinal disorders, proving a high accuracy marker in assessing inflammation in the intestine.

#1203 - Medical Image

BOWEL DYSFUNCTION IN MULTIPLE SCLEROSIS

Beatriz Porteiro, Mariana Costa, Rodrigo Moraes, Filipa Nunes, Whine Pedro, Marinela Major

Hospital Professor Doutor Fernando da Fonseca, Lisboa, Portugal

Clinical summary

Multiple sclerosis (MS) is a chronic inflammatory disease of the central nervous system in which loss of neurological functions occurs due to an autoimmune demyelination. Often it leads to slowed bowel activity. We present a case of a 51-year old male with a MS diagnosis, that shows significant physical disability, presented with a subacute painful abdominal distention with a firm and mobile abdominal mass. There was no history of irregular bowel transit. Imagiological investigation revealed a giant fecaloma condition redistribution of mesenteric vascular structures and stomach collapse. After unsuccessful conservative measures the management plan was to proceed to surgery. A timely surgical intervention in fecal impactions may prevent perforation that is associated with high mortality.

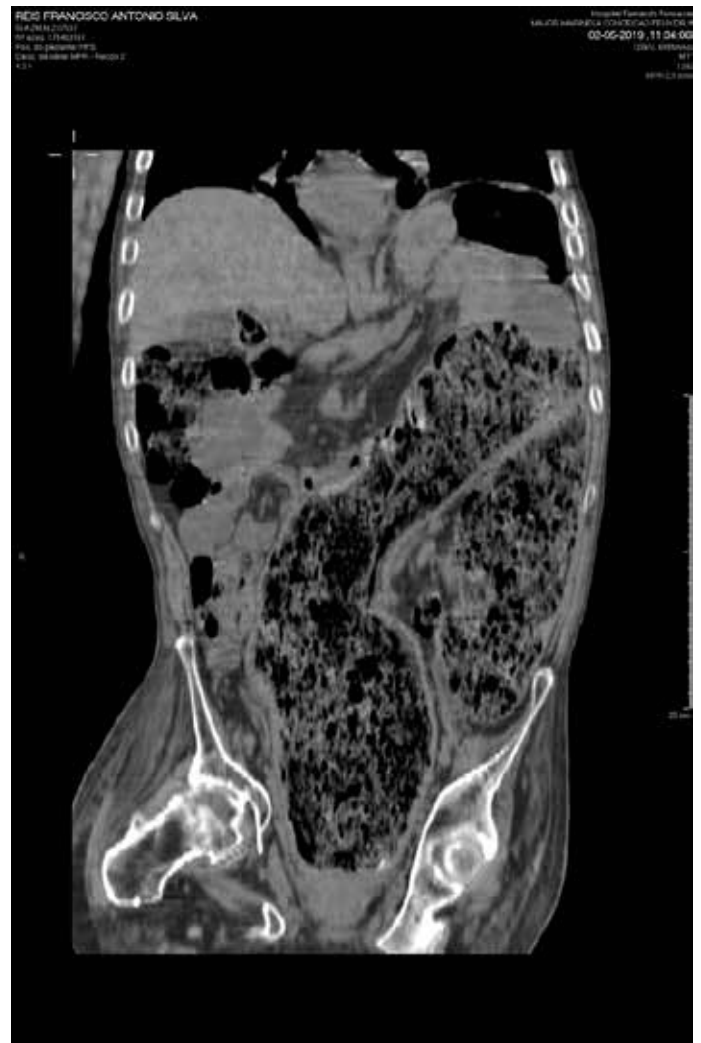

Figure #1203. Computed tomography revealed the presence of a giant fecaloma condition redistribution of mesenteric vascular structures and stomach collapse.

#1215 - Abstract

ALCOHOL WITHDRAWAL SYNDROME AND CHRONIC LIVER DISEASE IN A THIRD LEVEL HOSPITAL

Néstor Vázquez Agra, Ana Teresa Marques Afonso, Martiño Vidal Vázquez, Jonathan Geovany Montoya Valdés, Lucía Barrera López, Hadrian Pernas Pardavila, María López Ródriguez, Ariadna Helena Andrade Piña, Ignacio Novo Veleiro, Lara Maria Mateo Mosquera

Clinical Hospital Of Santiago De Compostela, Santiago De Compostela, Spain

Background

Alcohol withdrawal syndrome (AWS) is a common alcohol-related diagnosis which consists of a set of signs and symptoms ranging from autonomic hyperactivation (nausea, vomiting and tachycardia), tremors and nervousness to more serious ones such as disturbances of perception, psychomotor agitation and convulsions. It represents a major cause for inpatient and ICU admission.

It is well known that alcohol dependence and consumption pattern are related to AWS and liver injury; and there is at least a clinical conviction that patients with chronic liver disease (CLD) suffer from less AWS. The aim of this study is to investigate the possible relationship between CLD and AWS.

Methods

We conducted an observational and retrospective study of patients with an alcohol related diagnosis admitted to a internal medicine service (Hospital of Santiago de Compostela, Galicia. Spain). They were included older than 18, non-diabetic, non-complex and non-polymedicated patients who were divided into 2 groups: with and without AWS (AWS/No AWS). Demographic, clinical, laboratory and image variables were collected. We performed a descriptive, univariate and multivariate data analysis with SPSS.

Results

Sample n=81 patients, median age (years): 54.0 (SD 10.5), women: 19 (23.5%), CLD: 25 (30.9%).

Comparisons between the two groups (AWS / No AWS) are shown below:

Univariate analysis:

Nominal variables [n (%): Age (<50): 24(46.2)/3(10.3) p = 0.001, gender (Female): 16(30.8)/3(10.3)

p=0.032, CLD: 9 (17.3) / 16 (55.2) p=0.001.

Quantitative variables [Mean (SD)]: Age (years): 52.2 (9.4) / 62.5 (9.1) p <0.001, Alanine amino transferase (ALT, mg/dl): 82.3 (87.4) / 44,2 (25.3) p = 0.008, direct bilirubin(mg/dl): 2.9 (3.3) / 1.7 (0.56) p = 0.037. Glucose(mg/dl) 124 (5.5) / 105.3 (25.3) p = 0.022.

Multivariate analysis: there was association between AWS and: Age (B= -1.28 OR = 0.880, 95% CI 0.81-0.95 p=0.001), gender (female) (B= 4.13 OR = 62.14, 95% CI 2.23-1725.66; p=0.015), CLD (B= -3.77 OR = 0.023, 95% CI 0.002-0.222, p=0.001), Total bilirubin (B=1,93 OR 6,94 95%IC 1,03-46,90 p=0,047) mean corpuscular volume (MCV) (B=0,116 OR = 1.12, 95% CI 1.03-1.24, p=0.005)

Conclusion

Our study suggests that patients with AWS may have less CLD than patients with another alcohol-related diagnosis. Being younger than fifty and woman could be an added risk factor for development of AWS. Higher MCV and total bilirubin were associated with more AWS. Further evidence is needed.

#1279 - Abstract

THE ROLE OF SPLEEN STIFFNESS IN PREDICTING ESOPHAGEAL VARICES IN PATIENTS WITH VIRUS-RELATED CIRRHOSIS

Razvan Peagu, Sararu Roxana, Carmen Fierbinteanu

University Emergency Hospital Bucharest, Bucharest, Romania

Background

Current guidelines recommend that all patients with cirrhosis undergo upper gastrointestinal endoscopy (UGE) screening for esophageal varices (EV). Unfortunately, UGE is an expensive, time consuming method that is not well tolerated by patients. We evaluated if spleen stiffness measured using Acoustic Radiation Force Impulse (ARFI) is a viable technique in diagnosing EV.

Methods

We recruited 178 patients with virus-related cirrhosis who underwent biochemical tests, abdominal ultrasound, UGE, liver stiffness (LS) and spleen stiffness (SS) measurements using ARFI elastography.

Results

Patients with EV had lower platelets (p=0.005), higher values for spleen diameter (p=0.001), portal vein (p=0.003), LS (p=0.006) and SS (p<0.001). However, ARFI SS was the only non-invasive parameter associated with the presence of EV (2.7±0.30 vs. 3.4±0.52, p<0.001) after multivariate logistic regression (p<0.001). ARFI SS for predicting EV showed an AUROC of 0.872 (CI 95%: 0.799-0.944).

Conclusion

SS is a good method for predicting EV in patients with virus-related cirrhosis.

#1287 - Case Report

THE ONCOLOGIC DISEASE THAT WAS, AFTER ALL, A ZENKER DIVERTICULUM

Marisa Brochado¹, Maria Ines Santos², Helena Dias²

¹ Internal Medicine Department - Hospital Distrital de Santarém, E.P.E., Fafe, Portugal

² Internal Medicine Department - Hospital Distrital de Santarém, E.P.E., Santarém, Portugal

Introduction

The Zenker Diverticulum is a rare finding of the upper digestive tract. The dysfunction of the hypopharyngeal muscle associated

with the reduction of muscle tone, when the pressure is increased, may be the origin of the formation of this pharyngeal pouch. Thus, it is characterized by a higher prevalence in the countries of northern Europe and has an incidence in more advanced age groups, especially above 60 years, and in males.

Case description

Male patient, 86 years old, with no relevant personal history. He was recruited to the Emergency Department for a clinical picture, with an evolution of approximately 12 months, characterized by weight loss of 20 kg, dyspepsia, halitosis and nocturnal predominance of food regurgitation.

Discussion

Of the complementary diagnostic tests: analytically with normochromic normocytic anemia; Chest X-ray normal; Thoraco-abdomino-pelvic CT "...a large diverticular image originating from the paramedian pharyngo-esophageal transition and posterior to the esophagus trajectory in the lower cervical region and the beginning of the upper mediastinum, with around 7X4cm, a voluminous Zenker diverticulum being probable." During the hospitalization, prokinetics were initiated with a clear improvement in nocturnal regurgitation. The patient had high medication and with referral for external consultation of Gastroenterology and Cardiothoracic Surgery.

Conclusion: This clinical case alerts us to the fact that not all elderly patients with a history of constitutional syndrome are based on an oncological etiology. Thus, studies comparing the surgical and endoscopic treatment of Zenker's diverticulum do not show significant differences in efficacy in the approach.

#1303 - Abstract

INFLAMMATORY BOWEL DISEASE (IBD) – CAN WE FORESEE A WORSE OUTCOME IN HOSPITALIZED PATIENTS?

Marta Andrade Moreira, Rosana Maia, Francisca Silva Cardoso, Miguel Romano, Ana Sofia Costa Matos, Edgar Torre, Luís Lopes, Diana Guerra

ULSAM-Hospital Santa Luzia, Viana Do Castelo, Portugal

Background

In recent years the management of the Inflammatory Bowel Disease (IBD) has undergone important modifications. The vast majority of patients are now followed in an ambulatory setting. However, there is a subset of patients requiring hospital admissions. These inpatients' prognosis is heterogeneous and appears to depend on several factors. In Portugal, there are few studies addressing this topic. We aim to assess the predictors of a worse outcome during hospitalization.

Methods

We conducted an observational cohort retrospective study, between 2012 and 2018, at Hospital Santa Luzia, ULS Alto Minho.

All patients with IBD (n=337), followed in the IBD clinic were included, and patients with at least one admission (n=54) during the study period were selected for analysis. The main indications for admission were categorized in two groups: flare (included diarrhoea and sub-occlusion) and fistulae/abscesses. The main outcome evaluated was admission prognosis defined as a binary variable, according to three dimensions: length of stay, need for biologics and surgery. A qualitative response regression analysis with a logit model was performed using multiple clinical and laboratory predictors.

Results

44 patients (81%) had Cronh's disease (CD) and 10 patients (19%) had Ulcerative Colitis (UC). 44 patients (81%) were admitted with flares and 10 patients (19%) with fistulae/abscesses. An unfavourable outcome was observed in 24 patients (54.5%) and 7 patients (70%), in the flare and fistulae subgroups respectively. In the severe cases the mean haemoglobin level was lower than the non-severe cases (11.5 g/dL vs 13.0 g/dL, $t=3.25$; $p=0.0027$). In the regression analysis, the only predictor of a worse outcome was the haemoglobin value at admission. For each 1 g/dL decrease of haemoglobin at admission, the probability of having a less favourable hospital stay increases by 9.8% ($p=0.0033$), all other predictors constant.

Conclusion

The value of haemoglobin at admission is a key predictor of the prognosis of the admitted IBD patients. Further studies are needed with larger samples to confirm our findings.

#1331 - Medical Image

AEROPORTIA AS AN INDIRECT SIGN OF MESENTERIC ISCHEMIA

Luís Monteiro Dias, Marta Braga, Rosa Carvalho, Vânia Gomes, Céu Rodrigues, António Oliveira E Silva
Hospital de Braga, Braga, Portugal

Clinical summary

A 66-year-old male, with type 2 diabetes mellitus, arterial hypertension and stage 5 chronic kidney disease, presented to the Emergency Room (ER) with a 2 day history of abdominal pain, asthenia and nausea with onset after a hemodialysis session. The day he came to the ER, the hemodialysis session was interrupted due to hypotension. At physical examination he had low blood pressure, abdominal discomfort and fecaloid vomit. Abdominal CT revealed gastric and jejunoileal distension, associated with intestinal pneumatosis (Image). There were visible marked signs of intra-hepatic aeroportia and gas across the superior mesenteric blood vessels, suggesting mesenteric ischemia. A segmental bowel resection of nearly 30 centimeters was performed, with a good outcome.

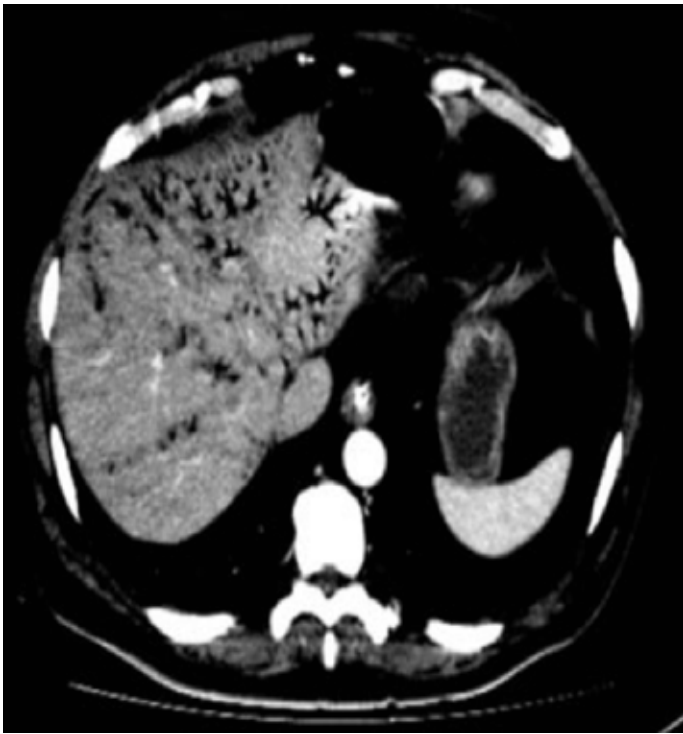

Figure #1331. Marked signs of intra-hepatic airoportia.

#1339 - Abstract

DIET AND NON-ALCOHOLIC FATTY LIVER DISEASE (NAFLD): IMPACT ON CLINICAL PRESENTATION AND VASCULAR DISEASE IN LEAN AND OVERWEIGHT PATIENTS

Federica Iuculano, Rosa Lombardi, Giuseppina Pisano, Sibilla Maria Spreafico, Silvia Tiraboschi, Erika Fatta, Silvia Fargion, Anna Ludovica Fracanzani

Ca' Granda IRCCS Foundation, Policlinico Hospital, University of Milan; Department of Pathophysiology and Transplantation, Milan, Italy

Background

Dietary macronutrient composition plays a key role in the onset of NAFLD and an inverse correlation between Mediterranean diet and cardiovascular events has been shown. Aim: To evaluate the role of diet on clinical presentation and cardiovascular alterations in patients with non-alcoholic fatty liver disease (NAFLD).

Methods

We enrolled 154 newly diagnosed, consecutive untreated NAFLD patients (M/F 112/42 mean age 49±12 ys), who were administered with a semi-quantitative food-frequency questionnaire (dietary record including 118 food items covering seven days) to calculate energy and nutrients intake. Steatosis, carotid intima-media thickness (IMT) and plaques were evaluated by ultrasonography; diastolic dysfunction (E/A), left ventricular mass, and epicardial adipose thickness (EAT) by echocardiography.

Results

Mean BMI and waist circumference were 28.8±5.2 and 103±11

cm; prevalence of hypertension 45%, dyslipidemia 49%, obesity 34%, diabetes 10% and metabolic syndrome 35%. Twenty-three (15%) patients had "lean" NAFLD (BMI <25 kg/m²). Moderate to severe steatosis was present in 61%, IMT >0.9 mm in 13%, carotid plaques in 28%, and E/A <1 in 39%; mean EAT was 5.8±4 mm. Three patients (2%) had a history of cardiovascular events. Total calories and macro-nutrient intake (g/day) were: 1705±5 750 kcal; proteins 98±46, fat 65±32 (saturated 23±14; PUFA 10±5; monounsaturated 25±12), carbohydrates 164±75 (simple sugar 64±35), fiber 23±14. No difference in nutrient daily dietary composition and total Kcal between lean and overweight patients was observed, despite a higher prevalence of metabolic comorbidities and moderate-severe steatosis in the latter. Among nutrients, fructose was significantly higher in patients with plaques (p=0.03) and vitamin E lower in those with E/A<1 (p=0.01). At multivariate analysis adjusted for age, sex and BMI, diet fat content was significantly associated with dyslipidemia (OR 1.2, 95% CI 1-1.4, p= 0.04), fat and carbohydrate with moderate-severe US steatosis (OR 1.2, 95% CI 1.03-1.5, p=0.01). No independent association was found between nutrients and carotid IMT, plaques and E/A.

Conclusion

Nutritional intake does not differ between lean and overweight NAFLD suggesting a genetic predisposition to NAFLD in lean subjects. Different diet composition may influence the onset of metabolic alterations and the severity of liver steatosis, while the role on cardiovascular damage remains to be defined.

#1348 - Case Report

EOSINOPHILIC GASTROENTERITIS: ABOUT A CASE

Miguel Alexandre Alves¹, Sergio Alves¹, Rafael Velho², José Mariz², Elsa Gonçalves², Jorge Teixeira²

¹ ULSN, Bragança, Portugal

² Hospital de Braga, Braga, Portugal

Introduction

Eosinophilic gastroenteritis (EG) is a rare and heterogeneous disorder, with a variable clinical spectrum ranging between the presence of common gastrointestinal symptoms and occlusive pyloric or intestinal disease. The symptomatology is relatively unspecific, dependent on the eosinophil infiltration of different sections within the gastro-intestinal tract. Little is known about its etiology despite this it seems multifactorial. Chronic inflammation of the digestive mucosa is triggered by exposure to potential food allergens and inhalant allergens in previously predisposed individuals.

Case description

A 36-year-old female, no pathological history. Went to emergency department (ED) complaint of diarrhea with 15 days of evolution, without blood or mucus, with general malaise and an increase

in the abdominal perimeter and reduction in food intake with weight loss. Negative epidemiological environment. No history of consumption of foods other than usual. She was hemodynamically stable, apyrética, with a soft, globular, depressible abdomen with sign of the ascitic wave. Analytically with leukocytosis, neutrophilia and a 45% eosinophilia (7000 μ l) and discrete hepatic cytolysis with high C-reactive protein. Abdominal ultrasound with "moderate volume ascites. Some enteric loops with a discrete and diffusely thickened wall are observed". Performed TC Toraco Abdomino Pelvic, confirming "moderate volume ascites and diffuse parietal thickening of the distal esophagus. Diffuse parietal thickening of jejuno-ileal loops". Paracentesis was performed with Eosinophils 89% (8337) no other alterations. Probable eosinophilic gastroenteritis. Patient started corticotherapy, initially methylprednisolone 30mg / day being changed to prednisolone 40mg / day with favorable evolution. From the extended analytical study, negative serologies, negative autoimmune study, increased IgE. Performed High Endoscopy and Colonoscopy with biopsy, revealed inflammatory infiltrate in the lamina propria, with some eosinophils.

Discussion

EG presents great clinical diversity. The response to treatment of the disease in general is good. The diagnosis is suspected by the presence of gastrointestinal symptoms, peripheral eosinophilia present in 50 to 100% of cases, and exclusion of other pathologies that occur with eosinophilia. Confirmation is made by the histopathology of the compromised intestinal wall whose eosinophilic infiltration is pathognomonic.

#1372 - Medical Image

RECTORRHAGIES AND DIARRHOEA: UN UNUSUAL PRESENTATION OF CLOSTRIDIUM DIFFICILE-ASSOCIATED PSEUDOMEMBRANOUS COLITIS.

Olga Cristina Pires, Joana Morais, Ana Isabel Andrade Oliveira, Inês Burmester, Paulo Gouveia, Maria João Regadas, António Oliveira Silva

Hospital de Braga, Braga, Portugal

Clinical summary

A 72-year-old man, presented to the emergency department with complaints of rectorrhagies, anorexia and diarrhoea. He denied antibiotic use in the last months. Presented elevated inflammatory parameters and a severe anaemia, requiring transfusion with two unities of red blood cells. A high digestive endoscopy was performed, that revealed a duodenal ulcer, with no signs of bleeding. Low digestive endoscopy revealed an endoscopic pattern of numerous small, yellowish or whitish plaques diffusely distributed, which compromises the rectum extending to proximal colon, typically compatible with pseudomembranous colitis. Results of *C. difficile* testing were positive. He fulfilled 14 days of oral Vancomycin and intravenous Metronidazole with a good clinical response.

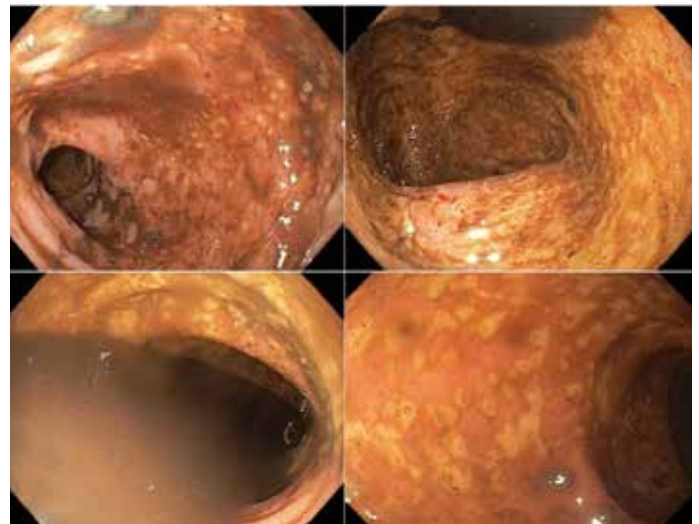


Figure #1372. Pseudomembranous colitis.

#1375 - Case Report

ACUTE PANCREATITIS WITH NEGATIVE AMYLASE AND LIPASE: A CASE REPORT

Sofia Guerreiro Cruz, Bruno Ferreira, Ana Rita Gomes, Ana Isabel Oliveira, Patrícia Ramos, Marta Quaresma, José Barata
Hospital Vila Franca de Xira, Vila Franca De Xira, Portugal

Introduction

Acute pancreatitis (AP) is caused by intracellular activation of proteolytic enzymes (PE) with destruction of pancreatic parenchyma and peripheral tissues. Biliary lithiasis and alcoholism are the most common etiological factors (80%), followed by hypertriglyceridemia, hypercalcemia and drugs. Almost all patients have abdominal pain at presentation and nausea/vomiting are also frequent. Diagnosis is made when two of the following three criteria are met: suggestive abdominal pain; characteristic imaging findings; and increased PE serum level (serum amylase [SA] and lipase [SL]), at least three times the normal level. Although normal AL levels have been reported, AP with normal SL is rare because of its negative predictive value of 94-100%. Treatment usually consists in intravenous fluid hydration, analgesia and oral feeding restriction. Without major complications, prognosis is often good, but 10-20% of cases are severe, with a mortality rate of 30%, that worsens with age.

Case description

The authors report a case of a 92-year-old female, with a good performance status and no relevant medical history, presenting with a 3-day history of abdominal pain, nausea and vomiting, without fever or other systemic symptoms. She denied history of alcohol consumption, lithiasis or introduction of new drugs. On admission, vital signs were normal and in the observation stood out diffuse abdominal pain, without peritoneal signs. Laboratory findings showed: leukocytes 28x10⁹/L; neutrophils 92,4%; C-reactive protein 49.81 mg/dL; normal liver-associated enzymes; SA 123 U/L and SL 116 U/L. Abdominal ultrasound and first

abdominal computed tomography (CT) indicated no significant anomalies. There was a clinical worsening during the first days of hospitalization, with elevation of inflammatory markers (despite negative PE values) and a reevaluation CT revealed densification of the peripancreatic fat planes and mesentery root, suggesting an edematous pancreatitis. Despite the supportive treatment, we witnessed a clinical deterioration and the patient died suddenly.

Discussion

This case intends to highlight the importance of clinical and imaging evaluation when AP is highly suspected, despite a non-significant elevation of PE (specially SL, which is rare) and how that early recognition and treatment can impact both prognosis and outcome.

#1381 - Abstract

ELASTOGRAPHY VARIATIONS IN CIRROHTIC PATIENTS OF VARIOUS HEPATIC ETIOLOGIES PRE AND POST TREATMENTS.

Obinna Kevin Kenechukwu Onwuteaka

Ternopil National medical university, Ternopil, Ukraine

Background

To evaluate elastographic variations of liver cirrohtic patients of different etiology at the ternopil regional hospital before treatment and dynamic comparison of the effects of the therapeutic regimes to the disease progression after treatment using transient elastography.

Methods

102 patients from a 2 year period was included in this study with (33) had HCV infection, (15) chronic HBV infection, (37) liver cirrohsis with alcohol etiology, (11) autoimmune hepatitis, (6) chronic idiopathic hepatitis with transformation to cirrhosis,consideration of various bias such as age, with mean age of 53.8 +/- 7.6 years, sex, (59 males, 43 females),therapeutic modalities EASL etiotropic guidelines;

GT1a, treatment experienced viral copies more than 100,000, Fibrosis grade >F3, LDV\SOF 400 mg daily PO\12 weeks.

GT1a,treatment naive, viral copy < 100,000, subcompensated F2-F3, LDV\SOF 400 mg\dailyPO\8 weeks.

GT1a,treatment naive,decompensated (child-pugh B-C) + thrombocytopenia and resistant ascities, F3-F4, LDV\SOF400mg +RBV\daily PO\ 16 weeks.

GT1b,treatment naive,decompensated (child-pugh B-C) + thrombocytopenia and resistant ascities, varices F3-F4, LDV\SOF400 mg +RBV\daily PO\ 24 weeks.

GT2, treatment experienced, decompensated with portal hypertension F4, LDV\SOF400mg +RBV\daily PO\ 12 weeks.

Prednisolone 15 mg tapered by 0.2mg every week for 8 weeks +USDA weight adjusted at 75kg for autoimmune hepatis F3.

Prednisolone 30 mg\5 days\alcoholic hepatitis. Pathogenic treatment included glutargine, hepatoprotectors,

L-glutathione,antioxidant and detoxification therapies, ursodeoxycholic acid,Proton pump inhibitors,diuretics,vitamin B complex. Liver fibrosis degree was estimated using elastography before comencement of treatment and was reevaluated after 3 months and liver enzymes assay after 1 month for assesment of organ response.

Results

At 3 months all patients had follow up investigations. The range shear wave elastography values were 7.14-16.7 kPa (F2- F4). With respect to fibrosis, shear wave elastography did not change significantly in patients F4 (0.327); a significant difference was observed between the F2-F3 and F3-F4 groups (P-0.002). Corrolation between ALT levels (Rs=0.287,p=0.804). Patients with resistant ascites had to undergo TIPS before elastographic measurements was recorded.

Conclusion

Positive dynamics is seen in F2-F3 stages in response to therapy than F3-F4 stages. With significant improvements with clinical syndromes but slow response on organ level.

#1407 - Case Report

AN UNUSUAL CAUSE OF ABDOMINAL PAIN

Joana Rua, Daniela Viana, Guilherme Assis, Nuno Silva, Cristiana Pinto, Paula Vaz Marques

CHTMAD, Vila Real, Portugal

Introduction

Splenic infarct is a rare cause of acute abdominal pain and it is associated with several diseases, including hematologic or embolic disorders, autoimmune diseases, infections and others. It can be asymptomatic but the most common clinical presentation is left upper quadrant abdominal pain, with fever, nausea, vomiting and left shoulder pain. Complications include bleeding, abscess and fistula. Treatment is mostly symptomatic and preventive.

Case description

A 73-years-old women with chronic kidney disease and non-anticoagulated paroxysmal atrial fibrillation presented to the emergency service with acute pain on the epigastric region and upper left quadrant. The pain started six days before, after dinner, associated with vomiting and nausea, with no other symptoms nor history of previous trauma. She had already been medicated with pain killers with no clinical improvement. Physical examination showed abdominal tenderness on the epigastric region and upper left quadrant. The analytic study revealed elevated LDH, myoglobin and CRP. CT scan showed severe abdominal atherosclerotic disease, structural liver changes suggesting chronic liver disease and splenomegaly with a bulky area of splenic acute infarct. Treatment with enoxaparin was initiated and she was admitted for symptom control and investigate the etiology of the splenic infarct. The autoimmune and pro-thrombotic studies,

blood cultures and infectious serology's were all negative. The echocardiogram showed no vegetation or thrombus, and ECG monitoring showed sinus rhythm. During hospital stay the patient had an episode of lower gastrointestinal bleeding, requiring transfusional support and interruption of the anticoagulation therapy. Endoscopic study of the gastrointestinal tract was performed and several polyps were biopsied. After careful restart of anticoagulation and successful pain control, the patient was discharged completely asymptomatic.

Discussion

We cannot yet exclude a paraneoplastic cause but the described patient has several risk factors to a thromboembolic etiology to the splenic infarct, including the paroxysmal atrial fibrillation, atherosclerotic disease of the aorta and the chronic liver disease. High suspicion levels are needed for diagnosis but should always be part of the differential diagnosis of abdominal pain, especially when risk factors are present. Treatment and preventive measures are very important to avoid complications.

#1412 - Case Report

PLANNING A PREGNANCY IN AGGRESSIVE AUTOIMMUNE HEPATITIS

Francisca Silva Cardoso, Miguel Romano, Francisco Teixeira Silva, Rogério Corga Silva, João Andrade, Alfredo Pinto
ULSAM - Hospital Santa Luzia, Viana Do Castelo, Portugal

Introduction

Autoimmune hepatitis (AIH) is a chronic inflammatory disease characterized by increased transaminases, hypergammaglobulinemia, presence of autoantibodies and classical histological findings. It is a rare and heterogeneous entity with a highly variable antibody pattern that makes diagnosis difficult but permits severity prediction. Pregnancy in these patients should ideally be preceded by an accurate diagnosis and effective therapy.

Case description

A 36-year-old woman, with no previous personal and family history, on oral contraceptives was referred to the Internal Medicine consultation for sustained elevation of AST and ALT, without other analytical changes. The patient presented with a one-year history of abdominal discomfort and distension, without any stigmas of chronic liver disease on physical examination and expressed a desire to conceive.

For the patient's best interest, pregnancy was delayed until a study of liver disease was performed. Serum tests showed, ALT and AST elevation (10x UNL) (ALT > AST), normal IgA and IgM, increased IgG, ANA, anti SLA/LP and Anti-Ro52 positive. ANCA (p and c), AMA, Anti Sm, Anti LKM were negative. Serologies (HIV, HCV, HBV) were also negative. Hepatic biopsy was performed with a result compatible with moderate chronic hepatitis with hepatic interphase lesions. The diagnosis of Autoimmune Hepatitis (previously designated type

3) was made. Considering the desire to become pregnant, a plan was prepared together with the obstetric physician, and the patient was put on immunosuppressive therapy with azathioprine, with full response. Term pregnancy was achieved without intercurrents but a slight increase in post-pregnancy transaminases. Patient keeps follow up in consultation and maintains disease remission.

Discussion

Subclassification of AIH has been a subject of debate. However, some authors consider AIH-3 to be a more aggressive disease, with recurrent exacerbations and requiring lifelong immunosuppression.

Effective immunosuppression allows safe pregnancy in young women with AIH, and it should be maintained during pregnancy, usually with good clinical outcomes, as seen in the case presented. Nevertheless there are non-negligible risks such as disease flares and prematurity.

If diagnosis is performed during pregnancy, AIH is more difficult to manage, this is why the disease must be pre-emptively monitored and controlled.

#1415 - Case Report

THE TOXIC LEMONGRASS

Ruben Guerreiro Raimundo, Ana Catarina Rodrigues, André Mendes, Joana Cochicho, Ana Neves, Maxim Suleac, Adriano Pacheco Mendes, José Silva, Sócrates Vargas Naranjo, Augusto Mendonça, Isabel Lavadinho, Isabel Soles
Unidade Local de Saúde do Norte Alentejano, Portalegre, Portugal

Introduction

Nowadays there are a lot of different teas and homemade remedies and its use by population is increasing. Although they are natural products, they are able to cause a metabolic imbalance in the human body, especially when they are uncontrolled and its origin is dubious.

Case description

We present a 41-year-old woman with gastritis and medicated with sucralfate that comes to the emergency department with acute right hypochondrium pain, without fever, nausea, jaundice, choluria or acholic stool.

After investigation we found high cytolysis enzymes (AST 1768 and ALT 1328) and a slight bilirubin increase (total bilirubin 1.92 and conjugated bilirubin 1.70). Abdominal CT scan revealed a regular size liver with heterogeneous uptake of iodinated contrast. Routine questioning showed that she didn't try any new drugs, drank water from wells or had any contact with animals but she planted lemongrass in her yard and drank lemongrass tea the previous week.

Discussion

She was hospitalized for hydration and diary surveillance in order to evaluate liver enzymes, bilirubin, lactate and pH. Other

investigation excluded autoimmune disease, viral infection (HIV, HAV, HBV and HCV), zoonosis (leptospirosis) and hemocromatosis.

The patient improved and the analytical parameters evolved positively. She was discharged without any signs or symptoms, with the diagnosis of toxic hepatitis caused by regular consumption of homemade planted lemongrass tea. This clinical case shows the risk of planting and consuming food of unknown origin and the importance of buying and purchasing packaged and controlled products.

#1417 - Case Report

PRIMARY BILIARY CHOLANGITIS: THE CHALLENGE OF DIAGNOSIS AND THERAPY

Francisca Silva Cardoso, Miguel Romano, Francisco Teixeira Silva, Rogério Corga Silva, João Andrade, Alfredo Pinto
ULSAM - Hospital Santa Luzia, Viana Do Castelo, Portugal

Introduction

Primary Biliary Cholangitis (PBC) is a rare disorder that predominantly affects women over the age of 40. It is a chronic cholestatic autoimmune liver disease characterized by progressive destruction of the intrahepatic bile ducts, which in the absence of effective therapy, progresses with fibrosis, cirrhosis and liver failure.

Case description

A 36-year-old woman, with a previous known history of difficult-to-control dyslipidemia, treated with oral contraceptive, was referred to the Internal Medicine consultation for elevation of transaminases (AST 88 UI/L, ALT 321 UI/L), cholestasis parameters (GGT 224 UI/L) and an alterations in abdominal ultrasound showing hepatomegaly and 2 hyperechoic images (probable hepatic hemangiomas). The patient had no relevant family history presents with scattered hyperpigmented skin lesions at physical examination. She complained of lower limbs pruritus for the 4 previous months. Serum tests highlighted positive values of ANA, AMA, Anti M2 and AntiGp210. Abdominal CT revealed an enlarged liver and 2 nodular images in segment VII and V/VI of the liver. MRI showed a heterogeneous hepatomegaly and nodularities that may correspond to hepatic hemangiomas, without an aggressive appearance. A liver biopsy was performed which did not rule out the diagnosis of CBP at an incipient stage. Once the diagnosis of CBP was established, ursodeoxycholic acid therapy was initiated. After 1 year of therapy, hepatic markers continued worsening and due to difficult control of the disease (corroborated with a GLOBE Score of 2.42), confirmed indication to start the patient on obeticholic acid. Patient keeps follow up in consultation.

Discussion

Early identification of CBP is crucial in initiating treatment and slowing the progression of the disease. In responding patients,

Ursodeoxycholic acid offers a life expectancy similar to the general population and cirrhosis development is rare. Patients who don't respond to this therapy have new options available. The approval of the expensive obeticholic acid is a current validated alternative, but it requires the use of validated risk assessment tools, able to accurately stratify PBC patients to high and low risk, after one year of conventional therapy. It is argued that in more severe cases (more aggressive, refractory and in young people) we should wait less time. Data on CBP in Portugal are scarce, but its impact isn't ignoble.

#1432 - Case Report

NON-ALCOHOLIC STEATOHEPATITIS AFTER LONG-TERM CORTICOSTEROID THERAPY

Andrea Silva, Carina De Sousa, João Madaleno, Catarina Canha, Adélia Simão, Armando Carvalho
Coimbra Hospital and University Centre, Coimbra, Portugal

Introduction

Corticosteroids may have major effects on the liver, particularly when given long term and in higher than physiologic doses. Glucocorticoid use can result in hepatic enlargement and steatosis or glycogenosis. Hepatic complications of corticosteroids usually represent the worsening or triggering the hepatic disease like non-alcoholic steatohepatitis (NASH), and rarely are the result of drug hepatotoxicity.

Case description

We present a case of a 56-year-old man with sarcoidosis with neurological involvement, hypertension, dyslipidemia, obesity and alcohol consumption of 15g/day, who was admitted for asymptomatic elevation of liver enzymes (aspartate transaminase 435U/L, alanine transaminase 540U/L, alkaline phosphatase 688U/L, gamma-glutamyltransferase 6792U/L), without liver failure. He was chronically medicated with prednisolone 8mg/day for 3 years, azathioprine, atorvastatin and metoprolol. Before initiating treatment for sarcoidosis the liver enzymes were normal. He denied consumption of illicit or over-the-counter drugs. He was asymptomatic and had no stigmata of chronic liver disease or alcohol abuse. Blood tests revealed total cholesterol of 457 mg/dL and triglycerides of 362 mg/dL. Serology for hepatotropic viruses and immunological markers for immune-mediated liver disease were negative. Abdominal ultrasound and computed tomography revealed steatosis. Non-alcoholic fatty liver disease fibrosis score was 2. Liver biopsy was compatible with steatohepatitis. Dietary alterations were made and the patient remained asymptomatic with progressive regression of analytical alterations.

Discussion

This is an early, but well documented report of NASH arising during corticosteroid therapy. The increased of serum aminotransferase and exclusion of other causes led to a hospital admission and liver biopsy. An issue is whether the liver disease was due to

corticosteroid therapy directly or was the result of weight gain and insulin resistance caused by the therapy.

#1442 - Abstract

ALCOHOL INTAKE AMONG PATIENTS WITH VIRAL C HEPATITIS

Elena Cristina Rezi

Lucian Blaga University, Medical Faculty, Sibiu, Romania

Background

Ethanol intake is an independent predictor of liver cirrhosis in subjects with chronic hepatitis C virus (HCV) infection. Viral infections favor the development of alcoholic liver diseases; these two factors, alcohol and virus, potent themselves. Our aim was to study the prevalence and some consequences of alcohol consumption among patients chronically infected with HCV.

Methods

We have considered all the patients who were hospitalized in the medical departments of the County Hospitals from three major cities from Transylvania during ten weeks, and who were ultrasonographically examined. We have studied the prevalence of HCV and the association of these diseases with alcohol consumption.

Results

A total number of 1377 patients were examined. The prevalence of the infection with HCV was of 7.5% (104 patients). 13.88% of them were also alcohol consumers. There were analyzed the patients with HCV who did not consume alcohol, as compared with those who are also consuming alcohol. At the last ones, there were found significantly higher values of the next parameters: the degree of liver steatosis ($p=0.02$), the spleen diameter ($p=0.05$), TGO ($p=0.00037$), TGP ($p=0.0062$), GGT ($p=0.00016$), total bilirubine level ($p=0.027$). The patients with viral C hepatitis who are also alcohol consumers, are, generally younger than those with viral C hepatitis who do not consume alcohol (54.42 years, compared with 57 years, $p=0.02$). Also, the Forns index of liver fibrosis was higher in patients with HCV who were also alcohol consumers, as compared with those with HCV who do not consume alcohol (5.56, as compared with 5.11, $p=0.22$).

Conclusion

The alcohol consumption among patients chronically infected with HCV is pretty high, this fact being also involved in the response to the antiviral treatment. The patients who are infected with HCV and also consume alcohol have a higher steatosis grade and a higher degree of cytolysis and cholestasis.

#1477 - Case Report

GASTRIC MALIGNANCY PRESENTING AS INTERNAL JUGULAR VENOUS THROMBOSIS

Ana Inês Ponciano, Joana Raquel Monteiro, Sónia Santos, Fernanda Pinhal, José Leite, Célio Fernandes

Centro Hospitalar de Leiria, Leiria, Portugal

Introduction

Jugular venous thrombosis is unusual and usually associated with central venous catheterisation, intravenous drug abuse and head and neck sepsis. However, is seldomly associated with malignancy. Gastric carcinoma is the second most common cause of cancer-related death worldwide. Advanced gastric carcinoma commonly presents with outlet obstruction, dyspeptic symptoms, and features of metastasis. Jugular vein thrombosis is an uncommon presentation.

Case description

A 31-year-old female presented to the emergency department with pain and swelling of the left side of her neck of four days duration, in association with a sore throat and chest tightness. There was no history of fever, night sweats or weight loss. She had no cough, and no relevant past medical or surgical history and was not taking any medications. On examination, there was diffuse tender swelling on the left side of neck with marked engorgement of the superficial veins over this area. The remainder of clinical examination was normal.

Ultrasound examination of the neck which demonstrated extensive thrombosis of the left internal jugular and subclavian veins. The patient was admitted for further study and started anticoagulation with low molecular weight heparin. She underwent body computed tomography (CT) which confirmed venous thrombosis. Coagulation tests were normal. CT also showed multiple lymphadenopathies especially on the celiac trunk and an incisional biopsy was performed. The histology was diagnostic of carcinoma. In order to find out the primary site she underwent upper endoscopy revealing an ulcer of the gastric body and biopsy confirmed the final diagnosis of gastric adenocarcinoma. She started chemotherapy but showed rapid progression of disease and died after 6 months.

Discussion

Venous thrombosis usually affects the legs. The veins in the head and neck are less susceptible to thrombosis as they are mostly valveless and their drainage is aided by gravity in the upright position.

Jugular venous thrombosis may be first manifestation of an occult malignancy and may be due to the hyper coagulated state of the patient secondary to a metastatic malignancy. In the absence of an obvious head and neck pathology or haematological disorder, disseminated malignancy should be suspected and further investigations initiated.

#1491 - Case Report

HEPATOCELLULAR-CHOLANGIOCARCINOMA AND NON-CIRRHOTIC PORTAL HYPERTENSION: WHICH CAME FIRST?

Carolina Teles¹, Carlos Dias Da Silva¹, Teresa Vaio^{1,2}, Rui Santos^{1,2}, Armando Carvalho^{1,2}

¹ Centro Hospitalar e Universitário de Coimbra, Coimbra, Portugal

² Faculdade de Medicina da Universidade de Coimbra, Coimbra, Portugal

Introduction

Combined hepatocellular-cholangiocarcinoma (CHC) is a rare and aggressive primary liver cancer, sharing unequivocal elements of both hepatocellular carcinoma (HCC) and intrahepatic cholangiocarcinoma (ICC). The etiologic factors behind CHC development are still poorly understood but its presence in a normal liver is uncommon. On the other hand, it has been suggested an association between liver cancer and non-cirrhotic portal hypertension, a condition of unclear natural history.

Case description

A 51-year-old female patient with a two-month history of epigastric discomfort, nausea, asthenia, and unexplained weight loss (14%). Physical examination showed epigastric tenderness and hepatomegaly, with no other changes. She had no personal history of diabetes, dyslipidemia or hypertension, and denied chronic medication use. No smoking or alcohol habits. No family history of liver neoplasms. Laboratory studies revealed hypochromic microcytic anemia, thrombocytopenia and liver enzymes elevation (AST 63 U/L, ALT 40 U/L, ALP 259 U/L, GGT 206 U/L), with normal bilirubin, alpha-fetoprotein, ferritin, alpha-1 antitrypsin and ceruloplasmin levels, and negative serologies for hepatotropic viruses and liver autoimmune disease. Abdominal ultrasound showed a hypoechoic nodule with 10 cm of greater axis, with no evidence of liver steatosis or cirrhosis. This finding was confirmed by Thoracoabdominal Computed Tomography and liver Magnetic Resonance Imaging, which also identified 5 liver nodules compatible with metastases, abdominal and mediastinal adenopathies, as well as signs of portal hypertension (splenomegaly, perisplenic collateral circulation and peritoneal effusion). Liver biopsy revealed a carcinoma with morphology and phenotype consistent with hepatocellular origin but immunohistochemical overlap with cholangiocarcinoma. Upper Gastrointestinal Endoscopy demonstrated esophageal varices and hypertensive gastropathy.

Discussion

This case reports the coexistence of CHC and non-cirrhotic portal hypertension, in a patient with no risk factors, supporting the possible relevance of this association, not yet completely understood. Given its mixed characteristics and lack of specific manifestations, CHC represents a real diagnostic challenge, resulting in delayed diagnosis and worse prognosis, emphasizing the importance of a high index of suspicion for CHC in the case of liver nodule detection.

#1497 - Case Report

CODEINE-INDUCED ACUTE PANCREATITIS: A CASE REPORT

Ricardo Ambrosio Rodrigues¹, Inês Farinha², Ana Rita M. Gomes³, Telma Alves¹, Mariana Guerra¹, João Pina Cabral¹, João Rocha Gonçalves¹, Armando Carvalho¹, Ana Figueiredo¹

¹ Department of Internal Medicine, Coimbra Hospital and University Center, Coimbra, Portugal

² Department of Pulmonology, Coimbra Hospital and University Center, Coimbra, Portugal

³ Department of Cardiology, Coimbra Hospital and University Center, Coimbra, Portugal

Introduction

Acute pancreatitis is a sudden inflammation of the pancreas that can vary from a mild to a life threatening condition. The most common causes are gallstones, representing 40-70% of cases, followed by alcohol (25-35%), hypertriglyceridemia and others. Medication induced pancreatitis is rare, representing less than 5% of cases.

Case description

A 78-year-old woman presented to the Emergency Room with coffee ground vomiting that started during the night, accompanied by epigastric pain and abdominal distention. The patient mentioned having started acetaminophen/codeine association the previous day. Physical examination showed abdominal defense, more pronounced in the epigastric region, with no other significant findings. Blood work showed an increase, more than 3 times the upper limit, of both amylase and lipase. Abdominal ultrasound was shown to be completely normal, with no gallstones or any other changes to report.

Diagnosis of acute pancreatitis was assumed (Ranson criteria of 2 and BISAP of 1) and the patient was admitted to the Internal Medicine infirmary for conservative therapy.

During the period of hospitalization all other causes were ruled out, including alcohol abuse, hypertriglyceridemia and others (including auto-immune). Abdominal CT scan was also performed and revealed no changes as well.

Codeine-induced acute pancreatitis was assumed as the diagnosis and the patient had a complete recovery after a few days of fasting and supportive therapy only.

Discussion

Codeine has already been associated with acute pancreatitis in published cases, most of them in patients that have undergone cholecystectomy.

This case highlights the importance of carefully monitoring and being aware of possible drug side effects, particularly when they are first prescribed.

#1514 - Case Report

THE OTHER CAUSE

Ana Cláudia Antunes, Ana João Carvalho, Cátia Santos, Adélia Miragaia

Centro Hospitalar de Leiria, Leiria, Portugal

Introduction

One of the possible consequences of gastrectomy is anemia, either due to vitamin B12 deficiency (VB12D) caused by the resection of the parietal cells or iron deficiency, due to increased gastric pH. Autoimmune gastritis (AIG) is a chronic inflammatory disease that affects the gastric parietal cells so, VB12D with pernicious anemia is a known consequence of this entity. These patients are usually asymptomatic but may present dyspepsia with late gastric emptying, intestinal infections, weight loss, muscle weakness, diarrhoea or neurological manifestations such as paresthesia.

Case description

80-year-old male, with history of psoriasis, psoriatic arthritis, arterial hypertension, splenectomy, partial gastrectomy due to ulcers of the great curvature of the stomach, who was referred to the internal medicine consultation due to weight loss of approximately 10 Kg in two months and dyspepsia with delayed gastric emptying. Thoracic, abdominal and pelvic computed tomography were normal. The pathological anatomy study of gastric biopsies by upper digestive endoscopy (UDE) revealed mild grade chronic gastritis, severe atrophy with extensive pseudopyloric metaplasia suggestive of autoimmune aetiology and were negative for *Helicobacter pylori*. Blood tests showed anemia 12.9 g/dL, with MCV 103.7 fL and MCH 34.1 g/dL, decreased ferritin 15.2 ng/mL, without iron deficiency 15.2 µmol/L, VB12D 64 pg/mL, Hb A1c 5.3%, elevated IgG and IgA of 1752 and 570 mg/dL respectively, intrinsic factor antibody and gastric parietal cells antibody were positive. Thyroid, renal and hepatic function without alterations.

Discussion

This case emphasises the importance of a thorough diagnosis approach even when in the presence of an already known potential cause for anemia, as multifactorial causes may be present, and the discovery of other factors may lead to different patient management. The gold standard for the diagnosis of AIG is the UDE with fundus and gastric body biopsy that reveals typical findings such as presence of polyps, endocrine cell hyperplasia in early stages and, with the progression of the disease, intestinal metaplasia with marked glandular atrophy. An additional importance of this diagnosis is the risk of developing gastric adenocarcinoma.

#1554 - Medical Image

THE COFFEE-BEAN SIGN

Mafalda Miranda Baleiras, Cristina Gouveia, Inês Ferreira, Carolina Gouveia, Patrícia Vicente, Luis Campos

Hospital São Francisco Xavier, Lisbon, Portugal

Clinical summary

Sigmoid volvus is the fourth leading cause of large bowel obstruction. The diagnostic accuracy of plain-X rays ranges from 30-90%. If left untreated, it may result in bowel ischemia, gangrene and perforation.

A 90-year-old woman presented to the emergency department with a 1-week history of abdominal pain and constipation. She had no record of abdominal surgery. Her vital signals were normal. Physical examination revealed diffuse abdominal tenderness and distension. Abdominal radiograph showed a distended sigmoid loop with an inverted U-shape, the classic “coffee-bean sign”, suggestive of sigmoid volvulus. The patient underwent a successful transrectal endoscopic decompression.

Awareness of the coffee-bean sign helps to prevent life-threatening complications from sigmoid volvulus.

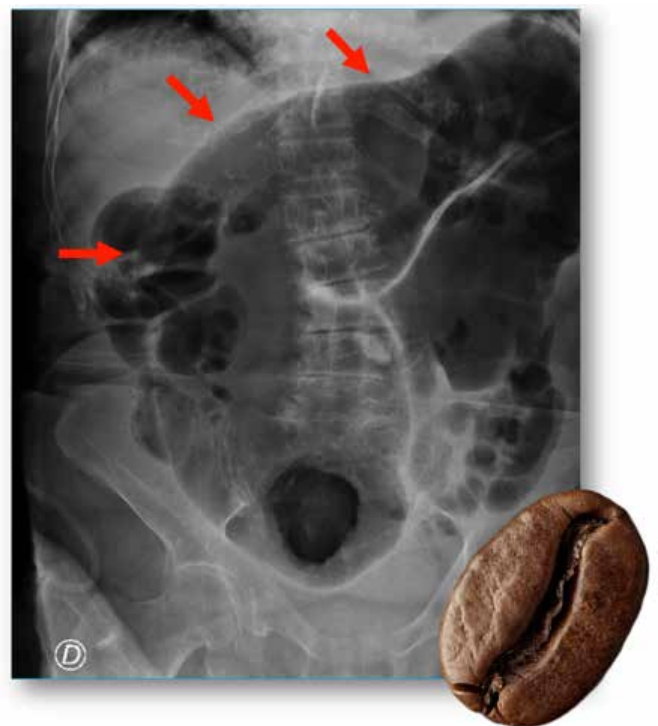

Figure #1554. Abdominal radiograph showing dilated sigmoid loop (arrows) with an inverted U-shaped appearance (coffee-bean sign).

#1615 - Case Report

COLIC HAEMOLACRIA IN MICROSCOPIC COLITIS, A RARE CONDITION THAT MAKES MUCOSA CRY BLOOD

Elena Creanga¹, Sebastian Dobos², Monica Nechita Ferreira³

¹ CHU Brugmann, Gastroenterology Department, Bruxelles, Belgium

² CHU Brugmann, Surgery Department, Bruxelles, Belgium

³ CHU Brugmann, Internal Medicine Department, Bruxelles, Belgium

Introduction

Patients with microscopic colitis present chronic watery diarrhea, normal endoscopy and inflammatory abnormalities of the

colorectal mucosa detected on biopsies. The diagnosis is based on histological findings, exclusion of other causes of diarrhea and analyses of effects of all treatments used over a 6-month period. Because of the inflammatory abnormality, the diagnostic assessment is frequently associated with increased iatrogenic complications at a higher rate than one encountered during screening colonoscopy.

Case description

An 89-year-old female patient was referred for total colonoscopy due to chronic diarrhea without rectorragias or fever. Weight loss was reported but not quantified. The patient had a medical history of hypothyroidism and hypertension and her medication include l-thyroxine, ramipril and aspirin. During the colonoscopy the mucosa of transverse and right colon presented edema, erythema, high friability and tore easily- all of these characteristics of colic haemolacria. Two tears in the right colon were closed by endoscopic clips. For developing progressive abdominal pain, she realized an abdominal scanner which showed pneumoperitoneum. A colic perforation after colonoscopy was diagnosed and the patient underwent a right hemicolectomy extended to the transverse colon with ileocolic anastomosis. Diarrhea disappeared progressively with a complete and permanent remission of symptoms during the follow-up period. The anatomopathologic exam confirmed the presence of collagen colitis with thickening of the subepithelial collagen band and infiltration of the lamina propria by lymphocyte-containing plasma.

Discussion

The authors discuss the therapies generally adopted in microscopic colitis: avoidance of drugs that might induce symptoms, symptomatic treatment or surgical treatment if resistance to medical treatment, iatrogenic complications or associated malignancy. Surgery involves excision procedures from ileostomy to proctocolectomy.

This case illustrate the importance of considering the diagnosis of microscopic colitis in patients with watery diarrhea. Early recognition of endoscopy findings, like the presence of mucosal erythema, edema, linear colonic mucosal defects or mucosal scarring could suggest the diagnosis and impose a more careful approach during and after endoscopy.

We draw attention that in the presented case the surgical act undertaken to resolve the complication of colonoscopy was therapeutic.

#1616 - Case Report

NON-HODGKIN LYMPHOMA IN A PATIENT WITH CELIAC DISEASE

Pablo Segovia-Alonso¹, Julio Dávila¹, Sara Hernández², Antonio Gracia¹, José Hernández¹, María Antonia Gonzalo¹

¹ Complejo Asistencial de Ávila, Ávila, Spain

² Complejo Asistencial de Salamanca, Salamanca, Spain

Introduction

Celiac disease (CD) is characterized by a T-cell-mediated response to gluten intake. This immune response leads to a chronic inflammation of the small intestinal mucosa that results in malabsorption, diarrhea, abdominal distension and pain, malnutrition and weight loss. Since 1937, it has been recognized that CD is associated with an increased risk of developing T-cell non-Hodgkin lymphoma (T-cell NHL), defined as enteropathy-associated T-cell lymphoma (EATL). We present a case of EATL in a 61-year-old man with celiac disease.

Case description

A 61-year-old man with celiac disease was admitted at the emergency department. He was diagnosed seventeen years ago of his pathology, but he does not conduct gluten free-diet although he regularly attended to schedule check-ups. At present, he referred fever up to 38.5°C, asthenia and weight loss during the last three weeks. He came from a rural area with consumption of unpasteurized dairy products and he referred occasional tick bites. Baseline laboratory evaluation with inflammatory markers was normal. Liver function tests showed mild elevation of transaminases and mild cholestasis with an elevated value of lactic dehydrogenase (more than three times over the upper limit of normality). Brucella microagglutination test and serologic test for Rickettsia, Coxiella and Borrelia spp were performed and the results were negative. A full body CT revealed a gastric neoplasia with multiple liver metastases. Upper endoscopy with biopsy was conducted compatible with high-grade enteropathy-associated Non-Hodgkin's T lymphoma. Ki-67 index showed high proliferation rate (95%). Hematology consultants evaluated the patient and started CHOP chemotherapy with poor response, then switched to IVE-MTX achieving partial response.

Discussion

EATL is a rare tumor that involves less than 5% of all gastrointestinal lymphomas and less than 1% of all non-Hodgkin lymphomas. Several studies verify that the risk of T-cell NHL is considerably greater in patients with CD than in the unaffected population. The T-cell-mediated immune response induced by the ingestion of gluten it is thought to be the main cause of the lymphomagenesis among CD patients. Management of celiac disease with a gluten-free diet effectively prevents the development of EATL. Consequently, it is important to reassure the compliance to the strict gluten-free diet for life.

#1620 - Case Report

SINUSOIDAL OBSTRUCTION SYNDROME INDUCED BY MEDICINAL HERBS

Pablo Segovia-Alonso¹, Sara Hernández², Francisco Díaz¹, María Pilar Delgado¹, Rosana Villanueva¹, Juan Manuel Blanco¹, Antonio Gracia¹, José Hernández¹, María Antonia Gonzalo¹, Raquel Tur¹, Beatriz Segovia¹

¹ Complejo Asistencial de Ávila, Ávila, Spain

² Complejo Asistencial de Salamanca, Salamanca, Spain

Introduction

The sinusoidal obstruction syndrome (SOS) is a disease secondary to a blockage of the venous drainage of the liver. This disorder is produced by the damage caused in the hepatic sinusoidal endothelium by the intermediate metabolites of different toxic substances inducing rapidly progressive ascites, painful hepatomegaly and jaundice. Typically, SOS is a serious complication of hematopoietic cell transplantation (HCT) but hepatotoxic effects of pyrrolizidine alkaloids found in herbal medicines have also been described as cause of this syndrome.

Case description

A 56-year-old woman was admitted at the emergency department. She was diagnosed one year ago with low risk essential thrombocythemia but she did not require medical treatment. At the present time, she referred abdominal pain, hyporexia and weight increase for two weeks. One month ago, she started a therapy with medicinal herbs for acid reflux by her naturopath. Baseline laboratory evaluation showed a normal serum aminotransferase levels with mild cholestasis, slight direct hyperbilirubinemia (1,7mg/dL, normal < 0,5 mg/dL), prothrombin activity curtailment (61%, normal 70-115%) and slight thrombocytosis ($475 \times 10^3/\text{mm}^3$, normal < $450 \times 10^3/\text{mm}^3$). A full body CT was performed ruling out hepatic vein thrombosis or neoplastic disease but revealing the presence of important ascites. Liver biopsy was performed illustrating sinusoidal congestion and endovenular fibrosis. Those findings were suggestive of SOS. The patient was treated with an adequate management of water retention but a week later she referred worsening of its basal state with increasing ascites. A new CT was conducted revealing thrombosis of the suprahepatic veins (Budd-Chiari syndrome). Haematology consultants evaluated the patient and started low molecular weight heparin and hydroxycarbamide with clinical improvement but with frequent evacuation paracentesis needed. Four months after the diagnosis, a new CT was executed proving partial permeability of the suprahepatic veins. The patient underwent porto-systemic shunt with no further needs of paracentesis.

Discussion

SOS is frequent among patients underwent HCT but there is a long list of drugs and toxic agents related to this syndrome. The increasingly use of natural remedies, including those derived from pyrrolizidine alkaloids, could lead to major drug-induced liver toxicity and SOS. Due to the severity of the disease and the lack of an effective treatment, a prompt and accurate diagnosis is essential.

#1626 - Case Report

INFLAMMATORY BOWEL DISEASE IN A PATIENT WITH PSORIATIC ARTHRITIS TREATED WITH SECUKINUMAB

Pablo Segovia-Alonso¹, Carmen Torres¹, Marta Lumbreras¹, Sara Hernández², Juan Manuel Blanco¹, José Manuel Hernández¹, María Antonio Gonzalo¹

¹ Complejo Asistencial de Ávila, Ávila, Spain

² Complejo Asistencial de Salamanca, Salamanca, Spain

Introduction

Psoriatic arthritis (PsA) is a chronic immune-mediated inflammatory disease that shows significant correlation with inflammatory bowel disease (IBD). Patients with PsA are two to four times more likely to develop IBD. Secukinumab is a human monoclonal antibody that inhibits IL-17A, showing significant efficacy in the treatment of PsA but has not shown effectiveness in the treatment of IBD. Moreover, detection of IBD has been reported in patients being treated with IL-17 inhibition. We present a case of IBD-unclassified (IBDU) following treatment with secukinumab in a 56-year-old woman with PsA.

Case description

A 56-year-old woman with PsA was referred from Rheumatology for diarrhea. He was diagnosed of PsA twenty years ago and she has performed multiple treatments with partial response (methotrexate, leflunomide, infliximab, etanercept, adalimumab, golimumab, ustekinumab and ciclosporine). Two months ago her rheumatologist started secukinumab 300 mg subcutaneous with usual initial dosing, followed by monthly maintenance dosing. She described bloody diarrhea (three-four times per day), abdominal pain and intermittent mild fever with no other signs of infection or extraintestinal manifestations. Baseline laboratory evaluation included normal values of renal and liver functions with mild C-reactive protein elevation and sedimentation rate four times its normal rank (with significant increase since the beginning of secukinumab where it was twice times its normal value). Stool cultures were negative for both bacteria and viruses. Colonoscopy with biopsy was conducted revealing pancolitis with chronic colitis and mild inflammatory activity compatible with idiopathic inflammatory bowel disease. Secukinumab was discontinued and salazopyrin was started with cessation of the diarrhea and normalisation of the inflammatory markers.

Discussion

While the association between PsA and IBD is well recognized, IBD pathogenesis is still under study. Dysregulation of mucosal cytokines, including interleukins and tumour necrosis factor alpha, seems to promote IBD pathogenesis. Nevertheless, IL-17A inhibition appears to increase the risk of IBD in some patients. Murine studies implicate that IL-17A is an important contributor to the gastrointestinal homeostasis and tissue repair, rather than enhance pathogenic inflammation. Patients treated with secukinumab should be assessed for IBD during treatment with withdrawal of the drug if specified.

#1646 - Abstract

NAFLD AND HEPATIC FIBROSIS BY TRANSIENT ELASTOGRAPHY ARE HIGHLY PREVALENT IN DIABETIC PATIENTS: NEED FOR A SYSTEMATIC SCREENING OF LIVER DISEASE

Annalisa Cespiati¹, Rosa Lombardi¹, Lorena Airaghi¹, Giovanni Targher², Giovanni Serviddio³, Gabriele Maffi¹, Cristina Bertelli¹, Giuseppina Pisano¹, Erika Fatta¹, Federica Iuculano¹, Luca Rinaldi⁴, Emanuela Orsi⁵, Silvia Fargion¹, Anna Ludovica Fracanzani¹

¹ Department of Pathophysiology and Transplantation, Ca' Granda IRCCS Foundation, Policlinico Hospital University of Milan, Milan, Italy, Milano, Italy

² Division of Endocrinology, Diabetes and Metabolism, Department of Medicine, University Hospital of Verona, Verona, Italy, Verona, Italy

³ Centro C.U.R.E., Dept. of Medical and Surgical Sciences, University of Foggia, Foggia, Italy

⁴ Department of Medical, Surgical, Neurological, Metabolic and Aging Sciences, University of Campania Luigi Vanvitelli, Naples, Italy, Napoli, Italy

⁵ Department of Medical Science, Endocrinology and Diabetes Unit, Ca' Granda IRCCS Foundation, Policlinico Hospital, University of Milan Italy, Milano, Italy

Background

Type 2 diabetes mellitus (T2DM) is a risk factor for the onset and progression of non-alcoholic fatty liver disease (NAFLD) to liver fibrosis, but this issue is often neglected. Liver biopsy is the gold standard for staging NAFLD, but it is not routinely applicable to wide cohorts of T2DM patients. We aimed at estimating non-invasively prevalence and predictors of NAFLD and liver fibrosis in a multi-center cohort of T2DM patients.

Methods

Three-hundred nineteen T2DM patients attending the diabetes outpatient clinic in five Italian centres were enrolled. Secondary causes of liver disease were excluded. All patients underwent liver ultrasound (steatosis grading 1-3) and FibroScan®. Controlled attenuation parameter (CAP) ≥ 248 Db/m and liver stiffness measurement (LSM) ≥ 8.7 kPa for M probe and ≥ 7.2 kPa for XL probe defined steatosis and advanced fibrosis, respectively.

Results

Among the 319 T2DM patients included (mean age 69 ± 9 years; 49% males) hypertension was present in 78%, dyslipidemia in 84% (79% of whom on statins) and obesity in 36%; almost all the cohort (96%) was on antidiabetic therapy (mean HbA1c $7 \pm 1.1\%$); elevated levels of AST, ALT and GGT were present in only 8%, 12% and 13% of patients, respectively. The overall prevalence of US hepatic steatosis was 89% (severe in 17%), confirmed in 72% of cases by CAP (available in 238 cases). CAP values significantly correlated with US steatosis grades (p for trend < 0.001). CAP ≥ 248 Db/m was associated at multivariate analysis with waist circumference (WC) (OR 1.07, 95% C.I. 1.0-1.15, $p=0.05$) and

triglycerides (OR 1.02, 95% C.I. 1.0-1.04, $p=0.01$). Presence of severe fibrosis (LSM $\geq 8.7/7.2$ kPa) was detected in 51 (13%) and correlated at multivariate analysis with serum GGT (OR 1.03; CI 95% 1.01-1.05; $p=0.001$), hyperuricemia (OR 9.1; CI 95% 1.9-41.6; $p=0.004$), BMI (OR 1.2; CI 95% 1.1-1.4; $p=0.03$), severe steatosis (OR 14; CI 95% 2.4-79.1; $p=0.003$).

Conclusion

NAFLD is highly prevalent in T2DM patients (89%), advanced liver fibrosis is detectable in 13% of them, despite normal transaminases in the majority of cases. Therefore, we suggest a careful non-invasive screening for liver disease in diabetics in primary care, especially if severe steatosis, obesity and hypertriglyceridemia also coexist. In addition, hyperuricemia and GGT may be useful markers to detect liver damage in this category of patients.

#1647 - Case Report

PERSISTENT CHOLESTASIS DUE TO TERBINAFINE

Ana Castro Barbosa, André Mendes Martins, Inês Machado Leite, Marina Duque Fonseca, Rui M. M. Victorino
Centro Hospitalar Universitário Lisboa Norte, EPE, Lisboa, Portugal

Introduction

Terbinafine is an oral antifungal agent that is commonly used to treat superficial fungal infections of the skin and nails. It's associated with mild liver biochemistry abnormalities in about 1% of treated patients. However, the incidence of clinically significant liver injury attributed to terbinafine is unknown. The liver injury may be hepatocellular at initial presentation but usually evolves into a cholestatic profile over time. Additionally rare instances of severe hepatitis, acute liver failure and fatalities have been described with terbinafine use.

Case description

A 53-year-old man from Sacavém, Portugal, construction worker, presented with abdominal pain, vomiting and dark urine. His medical history was remarkable for onychomycosis treated with terbinafine during about one month until three days before onset of abdominal pain. On physical examination no abnormalities except for jaundice were found. Laboratorial tests showed a cyto-cholestatic pattern (aspartate aminotransferase 324 U/L; alanine aminotransferase 615 U/L; gamma-GT 581 U/L; alkaline phosphatase 460 U/L; total bilirubin 6.91 mg/dL; direct bilirubin 5.12 mg/dL). Ultrasonography of the upper abdomen showed normal non-dilated bile ducts and no gall stones. Hepatitis A, B and C were serologically excluded and no autoantibodies were demonstrated. A biopsy, performed nine days after terbinafine was discontinued, showed a moderate inflammatory infiltrate in the portal areas and several foci of necroinflammatory activity and intrahepatic cholestasis of predominantly centrilobular distribution. Laboratory tests for cholestasis remained in ascending profile until four weeks after drug withdrawal (aspartate

aminotransferase 261 U/L; alanine aminotransferase 461 U/L; gama-GT 404 U/L; alkaline phosphatase 461 U/L; total bilirubin 24.97 mg/dL; direct bilirubin 18.90 mg/dL). He was started on prednisolone however laboratory values began to decrease only six weeks after this treatment was initiated. The patient remained asymptomatic and without evidence of liver failure.

Discussion

The liver function abnormalities in the patient described were probably due to treatment with terbinafine because of the temporal relationship between the drug intake and the occurrence of symptoms, and because extrahepatic cholestasis, viral hepatitis and autoimmune disease were excluded. Another important fact is that hepatic injury was confirmed by liver biopsy.

#1648 - Abstract

TYPE 2 DIABETES MELLITUS AND CHRONIC HEPATITIS C - A CASE STUDY OF A HEPATOLOGY CONSULTATION

Maria Pacheco, Ana Teresa Moreira, Nuno Rodrigo Maia Alves, Adriano Cardoso

Hospital de Sousa Martins, Guarda, Portugal

Background

Several recently published studies suggest Hepatitis C Virus (HCV) infection as a risk factor for Type 2 Diabetes Mellitus (T2DM), either by the inflammatory cascade triggered by the virus or by its molecular characteristics. On the other hand, T2DM accelerates the clinical and histological progression of liver disease, with an increased incidence of cirrhosis and hepatocellular carcinoma and increased of hepatic decompensation. The degree of hepatic fibrosis, cirrhosis and HCV infection are considered independent risk factors for T2DM. At the same time, it is assumed that the prevalence of T2DM in patients with HBV infection is similar to that of the so-called healthy population. The purpose of this study is to determine the incidence of T2DM in patients with viral hepatitis from the hepatology department of a medium size General Hospital.

Methods

Review of the medical records of patients with viral hepatitis, followed in the hepatology department between 2017 and 2018. For each patient, we analyzed the presence of the viral agent; the treatment and the response to it; clinical evolution; HBA1C value, and other cardiovascular risk factors such as arterial hypertension, obesity and dyslipidemia.

Results

This study included 177 patients with a 57-year-old mean age, 61% where male. Ninety-two had chronic Hepatitis C, of which 34% had hypertension, 57% had dyslipidemia, and 8% (n=7) had T2DM. The presence of T2DM did not imply a significant difference in the response to treatment. Of the eighty-two patients with

chronic hepatitis B, 46% had arterial hypertension and 43% had dyslipidemia. The prevalence of T2DM in the population with HBV infection was 19%. The presence of the virus also showed no influence on therapeutic outcome.

Conclusion

This study results, clearly didn't meet the results obtained in the different study's published until now. In this cohort, patients with HCV infection weren't more prone to develop T2 DM. This may be due to the small number of participants, and also by the fact that the patients only source was the liver disease consultation, and many where under the new direct antivirals treatment. Despite of what has been described, there were also no worse outcomes of Hepatitis C patients with T2 DM, and this may be justified by the short follow-up time and by the fact that the patients were in early disease stages. As result of this, we started a prospective study, to evaluate this interaction, as well as with other cardiovascular risk factors, over time.

#1659 - Case Report

ATYPICAL FINDINGS IN HEPATOBILIARY SICKLE CELL DISEASE

Raquel Lopes Brás¹, Maria Ribeiro Cunha², Ana Brázio^{1,3}, João Meneses Santos^{1,3}, Helena Cortez-Pinto^{4,5}, Rui M. M. Victorino^{1,3}

¹ Department of Internal Medicine II, North Lisbon University Hospital Center - Santa Maria Hospital, Lisbon, Portugal

² Department of Infectious Diseases, North Lisbon University Hospital Center - Santa Maria Hospital, Lisbon, Portugal

³ Medicine II University Clinic, Faculty of Medicine - University of Lisbon, Lisbon, Portugal

⁴ Department of Gastroenterology and Hepatology, North Lisbon University Hospital Center - Santa Maria Hospital, Lisbon, Portugal

⁵ Gastroenterology University Clinic, Faculty of Medicine - University of Lisbon, Lisbon, Portugal

Introduction

Sickle-cell liver disease can have very diverse presentations. Acute manifestations have been divided into acute sickle cell hepatic crisis, acute hepatic sequestration and acute intrahepatic cholestasis. However, some patients exhibit atypical forms of hepatobiliary disease, which can present a diagnostic and therapeutic challenge.

Case description

We describe the case of a 64-year old Angolan African male with history of sickle cell disease. He presented with general malaise, diarrhea with the occasional blood, and upper respiratory symptoms. Physical examination revealed jaundice, and abdominal examination revealed ascites and hepatomegaly. Laboratory studies revealed a predominantly cholestatic pattern (ALT 34 U/L, AST 60 U/L, γGT 227 U/L, ALP 254 U/L total bilirubin 8.78 mg/dL, direct bilirubin 5.18 mg/dL and LDH 760 U/L). Imaging studies revealed an enlarged heterogenous liver with no dilated

biliary ducts. Fibroscan was suggestive of advanced fibrosis, with no steatosis. Endoscopy revealed incipient esophageal varices. Etiologic investigation excluded active viral hepatitis, cardiac cirrhosis (no right-sided cardiac failure), harmful alcoholic consumption past or present, secondary hemochromatosis (normal serum ferritin and no signs of iron overload on MRI), autoimmune hepatitis (negative immunologic tests) or alpha-1-antitrypsin deficit. Alpha-fetoprotein was normal. He was then presumed to have sickle cell cholangiopathy. While awaiting liver biopsy, he developed sudden worsening of jaundice (bilirubin rising from 5 to 27 mg/dL). The absence of upper quadrant pain or worsening of anemia and lack of resolution after treatment of infection and supportive measures makes it difficult to categorize these changes into acute sickle cell hepatic crisis or acute hepatic sequestration. He did not fulfill criteria for acute intrahepatic cholestasis (no elevated transaminases; alkaline phosphatase and bilirubin not elevated enough). Liver biopsy revealed moderated fibrosis and nodular hepatocellular regeneration and signs of chronic cholestasis.

Discussion

Sickle-cell hepatic disease can be multifactorial and hard to characterize or divide into clear distinct syndromes. This and other atypical cases call forth the need to review our current understanding of sickle cell liver disease.

#1681 - Case Report

ZENKER'S DIVERTICULUM: A RARE CAUSE OF DYSPHAGIA

Fabiana Gouveia, Diogo Raposo André, Rafael Nascimento, Helena Freitas Luís, Rita Vieira, João Miguel Freitas, Luz Brazão
Hospital Central do Funchal, Funchal, Portugal

Introduction

The Zenker's Diverticulum (ZD) emerges from increased chronic pressure in an area of weakness of the hypopharynx known as the Killian triangle, formed by the cricopharyngeus and inferior pharyngeal constrictor. It is a rare entity, which occurs predominantly in males and is more frequent in the seventh and eighth decades. The most common symptom is dysphagia and may be associated with weight loss, heartburn or regurgitation. Diagnostic gait begins in the clinical history and is confirmed by Barium Contrast Radiography (BCR), as an initial test before esophagogastroduodenoscopy (EGD). Manometry can be performed if there is suspicion of an associated esophageal motility disorder. The treatment of symptomatic DZ evolved from an open surgical approach to endoscopic techniques.

Case description

A 73-year-old man, with a history of hypertension and dyslipidemia, who attended Internal Medicine appointments due to a predominantly solid upper dysphagia, with a 5-year evolution. He also reported regurgitation, sialorrhoea, halitosis, globus

pharyngeus, and unproductive coughing, with worsening in the last months. He denied weight loss or dysphonia. The objective examination showed no changes.

Analytically, there were no changes and a radiographic study with barium suspension ingestion showed a large diverticular formation in the cervical esophageal lumen, with superior communication and about 5 cm in diameter suggestive of ZD, causing a slight mass effect on the esophageal lumen and surrounding tissues. Then, it was requested an esophageal manometric study (no alterations) and an EGD that revealed a pharyngeal pouch with alimentary remains and apparently normal-looking mucosa. Computed tomography of the neck confirmed the diverticulum without significant irregularities of this cavity. Endoscopic treatment was suggested, which the patient awaits at the date of submission of this work.

Discussion

ZD is an acquired pulsed pseudo-diverticulum and its diagnosis is suspected based on the patient's complaints and confirmed by BCR or EGD. Manometry is generally not necessary, however, may help to clarify the pathogenesis of the diverticulum. However, as symptoms usually appear in the seventh and eighth decades of life, minimally invasive endoscopic approaches have gained popularity in recent years because of the surgical risk inherent in this age group.

#1689 - Case Report

EOSINOPHILIC GASTROENTERITIS IN A YOUNG WOMAN

Bárbara Saraiva, Francisco Lopes Morgado, Celestina Blanco Torres, Luis Manuel Sanchez
ULS- Guarda, Guarda, Portugal

Introduction

Eosinophilic gastroenteritis (EGE) is a rare and heterogeneous disease, defined by eosinophilic infiltration and peripheral eosinophilia. It can be seen anywhere in the gastrointestinal tract (GI). The pathogenesis is not well understood, but hypersensitivity is a major factor. The diagnosis is based on upper gastrointestinal endoscopy (GE) followed by histopathological examination of the biopsies, which shows eosinophilic infiltration in different layers of GI tract.

Case description

A 32-year-old woman admitted with the complaint of an abdominal pain of 3 weeks of evolution, nausea, diarrhea, sensation of postprandial fullness and increased abdominal perimeter. Diagnostic exams include laboratory confirmation of severe eosinophilia (36.5% of total leukocytes 13360 / mm³). Rx of abdomen with air-fluid levels in the right quadrant. An Abdominal CT with diffuse parietal thickening of the lower 2/3 of the esophagus, moderate ascites, and distention of the thin loops in the left quadrants. GE with 40 cm peptic ring and hyperemia of the body and mucosal antrum. The colonoscopy (CP) showed congestive and petechial ileocecal valve and colon mucosa with

evidence of submucosal circulation. Biopsies of the colon showed mucosa with hyperplasia and an increased number of eosinophils. In the paracentesis guided by ultrasound the presence of 6912 leukocytes/mm³, of which 93.3% were eosinophils. After the results of the exams, the diagnosis of EGE was established; the patient was given prednisolone 40 mg/die orally (vowel) with clinical and analytical improvement. Currently, no corticosteroid is being used, being asymptomatic.

Discussion

In the EGE the heterogeneity is determined by the site of the eosinophilic infiltration, so the involvement of the different layers gives enlargement to distinct symptomatology. In this case the important characteristic is the high number of eosinophils in the peripheral blood, besides the muscular layer compromise with common manifestations in the involvements of the mucous membranes (abdominal pain and vomiting) and serous (ascites). EGE presents a large number of diversities regarding its clinical manifestations and is generally a devalued condition, which requires a clinical evaluation focused on the investigation of the patients. The GE, along with CP and the histological examination are of paramount importance for the diagnostic confirmation, which allows the settlement of the specific therapy for the clinical condition of each patient.

#1740 - Case Report

USE OF HALO CATHETER IN ANTRAL VASCULAR ECTASIA. ABOUT A CASE.

Andrea Gonzalez Pascual, Marta Esles Bolado, Cristina Limia Vita, Lucia Paz Fajardo, Esther Hierro Ciria
Hospital Sierrallana, Torrelavega, Spain

Introduction

Gastric antral vascular ectasia (GAVE) or watermelon stomach is an uncommon cause of upper gastrointestinal bleeding (4% of non-variceal bleeding). It is more common in women older than 70 years and is associated with cirrhosis (31% of patients with GAVE) and with some autoimmune diseases, such as systemic sclerosis. It usually manifests as chronic iron deficiency anemia.

Diagnosis is established by the endoscopic image which shows vascular ectasias in the mucosa and submucosa, distributed longitudinally from the pylorus to the antrum.

Treatment is based on the correction of anemia with ferrotherapy and transfusions. Endoscopic coagulation techniques help to reduce the degree of bleeding. Antrectomy is reserved for cases refractory to previous treatments.

Traditionally, the most commonly used endoscopic hemostasis technique has been electrocoagulation with argon. However, its effectiveness is limited by the size of the lesions.

Case description

We present the case of an 86-year-old woman, with antecedents of hypertension and good functional situation. She is admitted

to our service in 2014 for severe iron deficiency anemia, being diagnosed with GAVE. Since then she is being followed in our consultation.

During this time, she has received medical treatment with tranexamic acid and octreotide and several sessions of endoscopic electrocoagulation with argon. Despite the treatment, she keeps maintaining high transfusion requirements of approximately two weekly red blood cell concentrates.

In November 2017, it was decided to perform a first radiofrequency ablation session with a HALO 90 catheter. Five months later, in April 2018, a second session was held. From then on, there is a reduction in the frequency of transfusions until reaching the current situation, in which the patient requires an average of 2 red cell concentrates per month.

Discussion

HALO catheter is a radioablation system consisting of an energy generator and two different catheters: HALO360 for the circumferential lesions and HALO90 for the focal ones.

By radiofrequency it produces the destruction of the entire epithelial layer, lamina propria and part of the muscularis mucosae, without injuring the submucosa. Its most widespread use is the treatment of dysplasia in Barrett's esophagus.

Recently, studies show good results in patient with refractory GAVE, with lower rate of recurrence of bleeding, after the use of this technique.

#1749 - Medical Image

GASTRO-HEPATIC FISTULA: A RARE COMPLICATION OF GASTRIC ULCER

Vasco Tiago, Raquel Sousa, Fernando Aldomiro
Fernando Fonseca Hospital, Amadora, Portugal

Clinical summary

A 73-year-old male, with known peptic ulcer disease and not on any medication, came to the emergency room after a first episode of haematochezia presenting as hypovolaemic shock, recovering after fluid challenge and blood transfusion. He had tarry stools for more than a year, along with non-quantified weight loss and anorexia. His admission haemoglobin was 5.8 g/dL. Upper endoscopy revealed a nonbleeding gastric ulcer, highly suggestive of malignancy. While awaiting results from biopsy, a CT scan for staging of presumed cancer demonstrated a gastro-hepatic fistula with liver abscess. He underwent Billroth II gastrectomy and surgical abscess drainage. Biopsy samples from both upper endoscopy and surgical resection specimen were compatible with chronic gastritis and negative for cancer.

#1762 - Case Report

NON-BLOODY CHRONIC WATERY DIARRHEA IN AN ELDERLY PATIENT - WHAT IS THE DIAGNOSIS?

Miguel Borges Da Silva, Albina Moreira

Hospital Pedro Hispano, Unidade Local de Saúde de Matosinhos, Matosinhos, Portugal

Introduction

Microscopic colitis (MC) is a common cause of chronic non-bloody diarrhea. The CM examines two histological entities: lymphocytic colitis (LC) and collagenous colitis (CC) and has as its diagnostic triad: (1) non-bloody aqueous diarrhea; (2) absence of macroscopic changes in colonoscopy; (3) and typical LC or CC histology. This entity is more frequent in the female sex (20:1), with a peak incidence in the 6th-7th decade, with no defined etiologic cause. Morbidity and mortality are related to the consequences of diarrhea and are generally not life-threatening.

Case description

We report the case of an 83-year-old female patient with a history of dyslipidemia and hypertension. Interned in August / 2018 due to diarrhea, non-bloody aqueous with 2 months of evolution and weight loss. Exhaustively investigated (endoscopic studies with normal colon biopsy, negative coprocultures), was discharged without diagnosis even with episodes of some episodes of diarrhea. Reintroduced in September 2018 for diarrhea, weight loss, dehydration and hypokalemia (2.4 mEq/L). Among the 2 hospitalizations, there were asymptomatic periods alternating with periods of watery diarrhea, without blood. Significant weight loss. From the study, we highlight: coprocultures and parasitological of negative stools, positive leucocyte leucocytes. Abomino-pelvic computed tomography without abnormalities, colonoscopy and normal upper digestive endoscopy; biopsies of the colon and duodenum showed "mild lymphoplasmacytic inflammatory infiltrate and some eosinophils." Suspected microsomal colitis, as likely to trigger drugs (reported in the literature): omeprazole and simvastatin, suspended this therapy initiated loperamide with significant improvement in diarrhea.

Discussion

The case described above demonstrates the need to pursue a diagnosis and to repeat endoscopic studies and biopsy in the suspicion of microscopic colitis until a diagnosis can be made.

#1769 - Case Report

BLACK ESOPHAGUS, A RARE DISEASE

Ivo Castro, Ana Filipa Matos, Adelaide Figueiredo, Maria Cristina Esteves

Hospital Distrital de Santarém, Santarém, Portugal

Introduction

Acute esophageal necrosis, more frequently mentioned as "black esophagus", is a rare disorder, whose diagnosis is obtained

on endoscopy. The etiology of acute esophageal necrosis is multifactorial, and usually develops when several ischemic offences are combined, particularly hypoperfusion, corrosive injury from gastric contents, gastric outlet obstruction and/or poor nutritional status. It is more frequent in older males with comorbidities.

Case description

We present a case of a 90-year-old male patient with a history of chronic obstructive pulmonary disease, heart failure, hypertension, dyslipidemia and Parkinson disease, who was admitted for acute onset of community-acquired pneumonia. On the third day after admission, the patient presented an upper gastrointestinal bleeding and, after an esophagogastroduodenoscopy, the diagnosed of black esophagus was established. The patient was exclusively medically treated, i.e., no surgery was performed. The placement of a nasogastric tube was required in order to protect the esophageal mucosa and allow to safely feed the patient. The medical approach was essentially based on proton pump inhibitor, sucralfate suspension and corticoid. After a sixteen days hospitalization the patient was referred for external consultation and died after one year due to cardio-respiratory failure.

Discussion

The acute esophageal necrosis is a rare diagnostic that need to be made by esophagogastroduodenoscopy. For the prognosis look to be more important the comorbidities of patient than the esophageal complications.

#1774 - Case Report

ARIADNE'S THREADGiulia Francesca Manfredi¹, Mattia Bellan¹, Rachele Rapetti¹, Stefano Fangazio¹, Carlo Smirne¹, Sergio Gentilli², Giordana D'Aloisio², Giuseppe Guzzardi³, Mario Pirisi¹¹ Division of Internal Medicine, "AOU Maggiore della Carità", Novara, Italy² Department of Surgery, "AOU Maggiore della Carità", Novara, Italy³ Interventional Radiology, "AOU Maggiore della Carità", Novara, Italy**Introduction**

As in the myth of Theseus and Princess Ariadne, who helped the hero defeat the Minotaur, also in this patient we had to retrace the thread to find the way out of the labyrinth.

Case description

A 75-year-old man was admitted to our hospital complaining persistent and widespread abdominal pain from 5 days; except for inappetence, no other symptoms were reported. He had a history of acute lithiasic pancreatitis, ischemic and valvular heart disease treated with CABG and mitral valve plastic, chemoembolization of pseudoaneurysm at the mesenteric artery, performed approximately 8 months earlier, with application of three metal spirals. On physical examination the abdomen was soft but widely painful. Laboratory tests showed only a modest neutrophilic

leukocytosis and a slight rise in C-reactive protein, hepatic transaminases and pancreatic enzymes levels were normal. Abdominal ultrasound revealed the presence of gallstones and biliary sludge, pancreas was not evaluable. A plain abdominal X-ray was normal except for signaling the presence of multiple metal wires in the abdomen. Despite the therapy, the abdominal pain remained unchanged. An EGDS was performed that was negative for ulcers or other injuries. The CT scan reported the presence of a radiopaque wire 2 mm-thick that extends from the III portion of the duodenum to the hepatic flexure. This wire was referable to the slinking of one of the spirals previously used for the embolization procedure.

Discussion

The slinking of spirals used in these procedures is a rare complication. In this case, the decubitus first occurred and then the foreign body entered the small intestine; gradually it has been extended by the intestinal peristalsis. A second extended EGDS confirmed the duodenal entry of the wire, with concomitant mucosal ulceration. This case shows the importance of a precise past medical history and how a non-surgical presentation of abdominal pain can hide a real surgical problem. The cooperation between Internists and Surgeon allowed the management of this unique case.

#1783 - Case Report

A CASE OF DRUG INDUCED LIVER INJURY

Joana Milho, Ana Rita Lambelho, Sofia Guerreiro Cruz, Ana Pinheiro Sá, José Barata

Hospital Vila Franca de Xira, Vila Franca De Xira, Portugal

Introduction

Drug induced liver injury (DILI) accounts for about 10% of all cases of acute hepatitis.

Lamotrigine is an anti-epileptic drug that rarely can cause hypersensitivity reactions with liver injury with a wide range of severity, from mild liver enzyme elevation to fulminant hepatic failure.

Case description

A twenty four year old woman presented to the hospital with fever, myalgia, and macular rash for 4 days. She had a history of bipolar disorder and 3 weeks previous to this episode was started on lamotrigine.

The initial evaluation showed liver enzyme elevation with a hepatocellular pattern: aspartate aminotransferase (AST) 544 U/L, alanine aminotransferase (ALT) 460 U/L, gamma-glutamyl transpeptidase (GGT) 36 U/L. INR 1, normal renal function, C-reactive protein 2 mg/dL, Leucocytes 4.2x10³/μL without eosinophilia. Serologies for hepatitis were negative. Abdominal ultrasound and CT didn't show masses or biliary tract obstruction. She was admitted to further investigation.

We assisted to deterioration of liver function - AST 7779 U/L, ALT

4363 U/L, bilirubin: total 2.12 mg/dL, direct 1.5 mg/dL, INR > 1.5, hypoalbuminemia, factor V 7%, thrombocytopenia 109 x 10³/μL but with no signs of encephalopathy, which led to admission in the intensive care unit.

A drug reaction was suspected so all potential hepatotoxic drugs were stopped.

A hepatic biopsy was performed and showed apoptosis and an inflammatory infiltrate constituted predominantly by eosinophils, characteristic for drug hypersensitivity reaction

With the withdrawal of lamotrigine and supportive care we assisted to an improvement of hepatic function tests. The patient was discharged one week later.

Discussion

Lamotrigine hypersensitivity reactions are not dose dependent and are impossible to predict. With this case the authors pretend to demonstrate that, although rare, lamotrigine hepatic injury can be severe so it's important a high level of suspicion.

The treatment consists on discontinuation of the offending drug with the majority of patients experiencing complete recovery.

#1792 - Case Report

AUTOIMMUNE HEPATITIS – AN OVERLOOKED ENTITTY

Ana Rita Lambelho, Luísa Gomes Silva, Joana Milho, Leuta Araújo, Ana Pinheiro Sá, José Barata

Hospital Vila Franca Xira, Vila Franca De Xira, Portugal

Introduction

The differential diagnosis of acute hepatitis is broad and often includes viral hepatitis, drug-induced liver injury, and alcoholic liver disease. Autoimmune hepatitis has an incidence of only 2.5% in the general population, which makes it a diagnosis often overlooked in the initial evaluation of acute hepatitis.

Case description

The authors present the case of a 46-year-old woman who went to the Emergency Department reporting a 2 day course of jaundice, choloria and abdominal pain. This was accompanied by a worsening asthenia, nausea and myalgias that started 3 weeks prior to its onset. She denied alcohol or drugs consumption. At observation she was icteric and presented with hepatalgia. The analytical evaluation showed elevated serum aminotransferase levels (AST 1713 IU/L, ALT 2273 IU/L), bilirubin (total 8.53 mg/dL, conjugated 6.86 mg/dL), GGT 411 IU/L and AP 213 IU/L elevation, as well as an INR of 1.32. An abdominal ultrasound was performed and excluded lithiasis or obstruction. The patient was hospitalized for further investigation. An abdominal CT scan was performed and did not reveal any significant changes. The viral serology markers were all negative along with the VDRL test. During hospitalization, a progressive improvement of the clinical status was observed with supportive therapy and she was discharged with normalized hepatic function. At the follow-up, a floating pattern of elevation of serum

aminotransferase levels were observed and a liver biopsy was performed. It revealed aspects of chronic hepatitis with fibrosis and inflammatory activity. ANA were present (1:640) and the remaining autoantibodies were negative (AMA, ASMA, ALC-1 and ALKM-1). A diagnosis of autoimmune hepatitis was made and the patient was referred to the Gastroenterologist where immunosuppression using glucocorticoid and azathioprine was initiated with progression to normal serum aminotransferase levels.

Discussion

Autoimmune hepatitis is a chronic inflammatory disease of the liver characterized by circulating autoantibodies. The disease may start as an acute hepatitis and progress to chronic liver disease and cirrhosis with high morbidity. This diagnosis is suspected when both characteristic serologic or histologic findings and the elevation of serum aminotransferase levels are present in the absence of other forms of chronic liver disease. As a result autoimmune hepatitis is a diagnosis often neglected in the initial management of acute hepatitis despite its serious consequences.

#1806 - Case Report

MULTIPLE RISK FACTORS FOR HEPATOCELLULAR CARCINOMA

José Da Cunha Marques, José Faria Costa, Catarina Vilaça Pereira, Fernando Miranda Nogueira, José Ribeirinho Soares, Diana Seixas Ferrão, António Jorge Almeida

Centro Hospitalar Universitário São João, Porto, Portugal

Introduction

Hepatocellular carcinoma (HCC) has no specific manifestations. It is often an incidental finding in imaging studies.

We present the case of a patient with multiple risk factors that show synergism for the development of HCC.

Case description

55 years old, male. History of alcoholism (60 grams/day), smoking (56 PY) and alcoholic cirrhosis.

Followed by Neurology due to parkinsonism secondary to hepatocerebral degeneration. No chronic medication. Referred to Internal Medicine department due to changes in liver tests. Patient denies fever and other constitutional symptoms. No history of previous gastrointestinal bleeding, ascites or encephalopathy. On physical examination with bilateral gynecomastia, cutaneous hyperpigmentation, digital clubbing and edema of the lower limbs. Total alcohol withdrawal counseling. Abdominal ultrasound shows a 49x39mm nodular lesion in the right hepatic lobe and 15cm splenomegaly. Analytically with thrombocytopenia and leukopenia, albumin 27.3 g/L, AST 103 U/L, ALT 80 U/L, GGT 133 U/L, alkaline phosphatase 154 U/L, total bilirubin 1.93 mg/dL, DHL 205 U/L, seric iron 172 g/dL, ferritin 1384 ng/mL, transferrin saturation 83%, betagama fusion on proteinogram and negative alpha-fetoprotein. Immune to hepatitis B virus, serology is negative for hepatitis C.

Chest-abdomen-pelvis CT revealed a liver with a dysmorphic aspect suggestive of chronic liver disease, a 46mm nodule suspected of HCC accompanied by a cavernomatous transformation of the portal vein.

Hepatic MRI demonstrates nodular lesion in the hepatic segment 8 of 47x42 mm, with washout compatible with HCC, chronic portal vein thrombosis with cavernomatous transformation, as well as iron overload raising suspicion of hemochromatosis. A genetic study was carried out with heterozygosity of the H63D gene.

Discussion

Patient in alcohol withdrawal for more than 6 months, good performance status, Child-Pugh B stage, without extrahepatic metastization, with chronic portal vein thrombosis. The case was discussed with the Oncology Group, that decided to perform radioembolization of the hepatic lesion. This is an illustrative case where the synergism between multiple risk factors culminated in the development of HCC.

#1808 - Case Report

THE CONJUGATION OF TWO RARE ENTITIES...

Ana Oliveira Costa, Pedro Pereira, Nuno Silva, Pratima Isvarlal, Paulo Carrola

Centro Hospitalar de Trás os Montes e Alto Douro, Vila Real, Portugal

Introduction

Pylephlebitis is a septic thrombophlebitis of the portal vein. Its clinical presentation may be highly variable requiring a high clinical suspicion for its diagnosis. Although a rare phenomenon, it is still associated with high mortality rates therefore, early aggressive interventions play an important role predicting their outcomes.

Case description

51-year-old woman, obese, medicated with oral contraceptive, presented to ED with progressive abdominal pain for 5 days, fever and anorexia. On physical examination hemodynamically stable but with tenderness in the right upper quadrant and lumbar percussion. Laboratory data revealed leukocytosis and elevation of CRP, mild cholestasis and hyperbilirubinemia. Abdominal CT revealed signs of acute thrombosis and pylephlebitis of the left portal and inferior mesenteric branches, without other intraabdominal focus, and no permeability of the right branch with right lobe atrophy and left lobe hypertrophy suggesting chronicity. Gynecology identified trichomoniasis without signs of pelvic infection. Additional questionnaire revealed mild abdominal trauma 2 years before. The patient was admitted with parenteral antibiotic therapy and hypocoagulation and carried out complementary investigation: no microbial isolation or septic focus identified; negative screening for solid and haematological malignancy; small varicose veins in the oesophagus and negative auto-immune study. However acute phase pro-thrombotic study revealed negative antiphospholipid antibodies, it also revealed heterozygous G20210A prothrombin

gene mutation and homozygous MTHFR C677T polymorphism, despite no hyperhomocysteinemia. Antibiotic therapy was maintained for 5 weeks and hypocoagulation to date (7months). MRI 5 months later still revealed thrombosis of the splenoportal axis with extension to the superior and splenic mesenteric veins and signs of portal cavernomatous transformation.

Discussion

This case meets 2 rare entities: a chronic noncirrhotic nontumoral portal vein thrombosis (PVT) and a pylephlebitis with no identifiable primary focus that did not recanalize. Regarding PVT in up to 80% the underlying cause is identified when exhaustively researched. In this case, the conjugation of prothrombotic susceptibility, obesity, oral contraception, and previous abdominal trauma may be the etiology of chronic thrombosis. Given prothrombotic disorder, recurrence and extent of thrombosis as well as the absence of recanalization, ad eternum hypocoagulation may be unavoidable.

#1812 - Case Report

RIBOCICLIB: FROM BREAST CANCER TREATMENT TO DEATH BY LIVER FAILURE

Ana Realista Pedrosa, Leila Barrocas, Sofia Moura, Conceição Barata

Hospital do Espírito Santo - Évora, Évora, Portugal

Introduction

Acute liver failure is a rare syndrome, characterised by an acute abnormality of liver blood tests in an individual without underlying chronic liver disease. Ribociclib is used in the treatment of postmenopausal women with metastatic breast cancer. It is associated with a moderate rate of serum aminotransferase elevations during therapy and to clinically apparent liver injury in some patients. Experience with ribociclib is limited, but it appears to be capable of causing significant liver injury. To the extent of our knowledge, acute liver failure associated with ribociclib has not been documented in the literature.

Case description

In this case report, we describe the evolution of acute liver failure in a 69-year-old woman with breast cancer stage IV (invasive carcinoma) with bone metastasis, treated with letrozole and ribociclib (suspended at admission), admitted with the diagnosis of febrile neutropenia. We objected a significant derangement in liver function, associated with jaundice, pruritus and hepatic encephalopathy. We rolled out liver metastasis, thrombotic events, compression of the biliary tree and viral infection. No other causes of acute liver failure were identified, leading to the presumptive diagnosis of hepatic toxicity secondary to ribociclib. Given the patient's history of metastatic cancer, she was not a candidate to liver transplant. Although supportive management and treatment with N-acetylcysteine were instituted, it was observed a poor outcome, neither biochemical test, nor encephalopathy were reversed, leading to death.

Discussion

This case report highlights the possibility that ribociclib can cause significant liver injury, leading to acute liver failure. We point out the importance of early recognition of liver injury and pharmacological toxicity since evolution to acute liver failure, though rare, is associated with a significant morbimortality.

#1815 - Abstract

AUTOIMMUNE GASTRITIS, A FREQUENTLY UNDERDIAGNOSED CAUSE OF IRON DEFICIENCY ANEMIA

Mafalda Ferro Teixeira¹, Inês Santos², Ana Sousa², Ricardo Paquete Oliveira¹, Bruno Grima¹, José Delgado Alves¹

¹ Hospital Professor Doutor Fernando da Fonseca, Lisboa, Portugal

² Hospital do Espírito Santo de Évora, Évora, Portugal

Background

Iron deficiency anemia occurs in 2-5% of adult men and postmenopausal women in the developed world and is a common cause of referral to Internal Medicine consultation. Autoimmune gastritis (AIG) is a chronic progressive inflammatory condition encountered in 20-27% of patients with obscure, or refractory iron deficiency. Although it is estimated to be 4 to 6 times more common than celiac disease it is frequently underdiagnosed and its association with other autoimmune endocrinopathies and gastric cancer is therefore overlooked. Aim: To characterize clinical, laboratorial and endoscopical profile of a population with iron deficiency anemia secondary to AIG.

Methods

A descriptive, observational study including 14 patients with a diagnosis of autoimmune gastritis (positive parietal cell antibody and gastric corpus atrophy) in the setting of refractory iron deficiency anemia and requirement for intravenous iron therapy, after exclusion of other potentially contributing causes of anemia. Data were retrospectively collected from clinical files, including: demographic age (age, gender), laboratorial evaluation (Hb, serum ferritin, B12 vitamin, folic acid, intrinsic factor autoantibodies, parietal cell autoantibodies, thyroid antibodies) and endoscopic findings. Descriptive statistical analysis was performed (mean, median and standard deviation).

Results

The mean age of all 14 patients was 54±18 years and 86% of the patients were female. 29% had concomitant vitamin B12 deficiency (pernicious anemia). 21% of the patients with AIG also had autoimmune thyroiditis. During iron deficiency anemia investigation, upper GI investigation (UE) was performed in 86% of the patients but only 50% were submitted to colonoscopy and an even lower percentage (7%) to videocapsule endoscopy. 58% of the patients submitted to UE had a macroscopically normal exam and only 17% had macroscopic evidence of corpus gastric mucosa atrophy. Gastric biopsies were performed in 83% of these patients.

Conclusion

We highlight autoimmune gastritis as a diagnosis to be considered when investigating refractory iron deficiency anemia particularly in women between the third and fifth decades of life. About one third of the patients with AIG have autoimmune thyroiditis. The initial pre-atrophic stages of AIG are not associated with substantial macroscopic changes, therefore the diagnosis may not be suspected endoscopically and the acquisition of mucosal samples are mandatory.

#1826 - Medical Image

ASPIRATION PNEUMONITIS

José Da Cunha Marques, Marta Baptista Freitas, Marta Sá Patacho, Catarina Vilaça Pereira, Fernando Miranda Nogueira, José Ribeirinho Soares, Diana Seixas Ferrão, António Jorge Almeida

Centro Hospitalar Universitário São João, Porto, Portugal

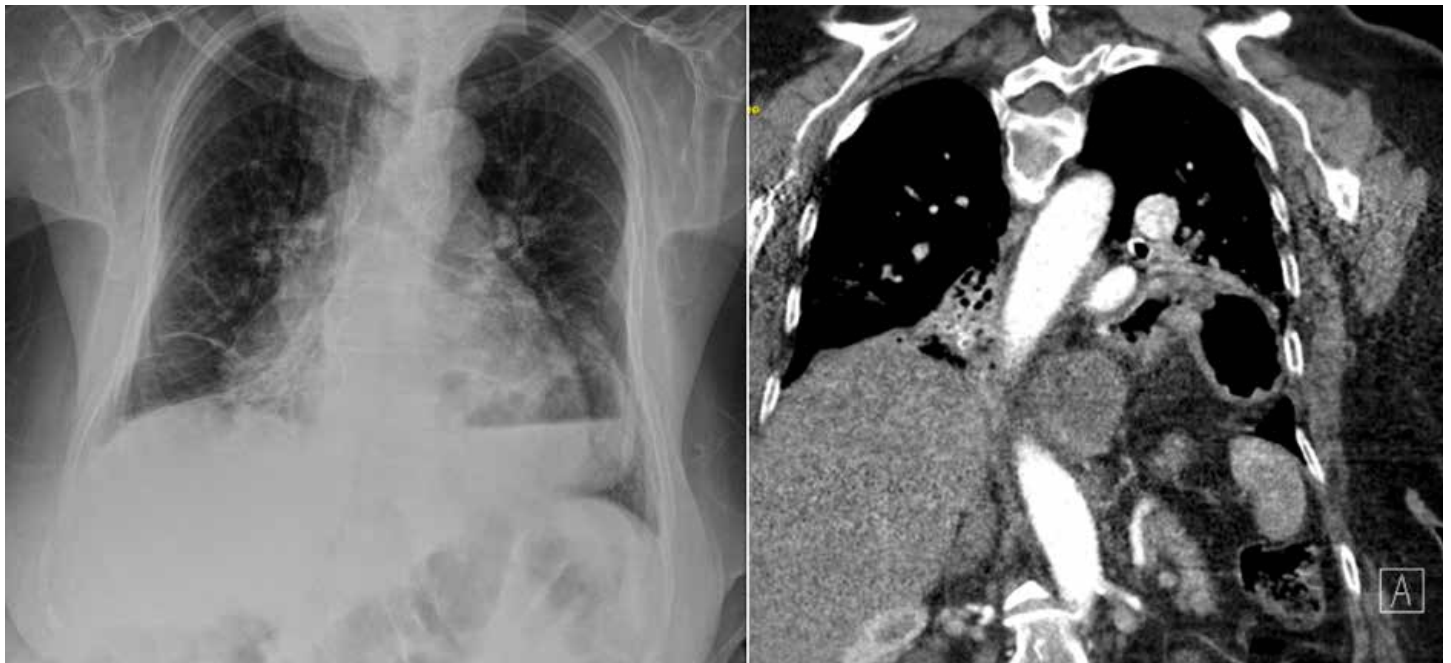

Figure #1826.

#1835 - Case Report

ACUTE HEPATITIS IN DRESS SYNDROME

Ana Mestre¹, Ana Oliveira¹, Filipe Damião², Sofia Carvalhana²

¹ Hospital Distrital de Santarém, Santarém, Portugal

² Centro Hospitalar Lisboa Norte - Hospital de Santa Maria, Lisboa, Portugal

Introduction

Dress syndrome (DS - Drug Reaction with Eosinophilia and Systemic Symptoms) is a severe and potentially life-threatening hypersensitivity reaction to drugs, with up to 10% mortality rate. It is characterized by a mild exanthem to extensive macular erythema, fever, eosinophilia, lymphadenopathy and systemic involvement. Hepatic injury is frequent but generally mild, with

Clinical summary

A 78-year-old woman goes to the emergency department due to cough and dyspnea for small efforts with two weeks of duration. Without fever or other organ/system-specific complaints. On physical examination: hemodynamically stable, no fever, labial cyanosis and scattered crackles in both lung fields. Arterial gasometry with respiratory insufficiency. Analytically: high PCR (231 mg/L), without leukocytosis, BNP 1369.1 pg/mL, urinary antigen tests negative for *Streptococcus pneumoniae* and *Legionella pneumophila*. Chest X-ray with hydro-aerial level in the lower 1/3 of the left hemithorax (pulmonary abscess?).

CT scan of the thorax revealed a hiatal hernia with the entire stomach localized in the thoracic cavity and the patient was directed to General Surgery.

transaminases elevation not greater than 10 times the normal value. Hepatic insufficiency is rare.

Case description

A 45-year-old woman presents to the emergency department with a 7 days history of a non-pruritic cutaneous rash, that started 3 weeks after the introduction of sulfasalazine for seronegative arthritis. On physical examination she was febrile (38°C) and presented an extensive maculopapular eruption with erythema and edema of the face. Laboratory studies revealed normal white blood cell count (5900 cell/ μ L) with absolute eosinophil count of 2000 cell/ μ L, with no atypical lymphocytes. Liver enzymes were mildly elevated: aspartate transaminase (AST) 54 IU/L; alanine transaminase (ALT) 235 IU/L; alkaline phosphatase (AP) 234 IU/L; gamma-glutamyl transferase

(gGT) 216 IU/L; total bilirubin 1.40 mg/dL, with normal prothrombin time (PT). Renal function was normal at presentation. The patient was admitted to the dermatology ward and started on 1mg/Kg/day dose of prednisolone with clinical improvement. A skin biopsy was performed showing superficial dermal perivascular lymphocytic inflammatory. Five days after the admission she was started on cefuroxime, for urinary tract infection, with recurrence of rash and fever after 3 days. There was a sudden and severe rise in liver enzymes (AST 6364 IU/L; ALT 3133 IU/L; AP 291 IU/L; gGT 481 IU/L) total bilirubin was elevated (10.03 mg/dL) and PT slightly prolonged. Other causes of hepatitis were excluded, and a liver biopsy was performed revealing acute hepatitis confluent bridging necrosis, suggestive of toxic etiology. After withdrawal of all the drugs, with the exception of prednisolone, there was a progressive improvement.

Discussion

DS pathogenesis, is to this day, not completely understood, however, drugs like antibiotics are known triggers, specially in patients previously exposed to sulfasalazine. Treatment is based on the discontinuation of the culprit drug and administration of corticosteroid. Although rare, acute hepatitis is a potentially fatal complication of DS.

#1851 - Case Report

A HIDDEN FOE - A CASE OF CHRONIC LIVER DISEASE

José Pereira, Juliana Magalhães, Inês Antunes, Ivone Barracha, Rosa Amorim

Centro Hospitalar do Oeste - Hospital de Torres Vedras, Torres Vedras, Portugal

Introduction

Hemochromatosis is a recessive autosomal hereditary disease. Its mutations impact the function and production of hepcidine, consequently unregulating iron homeostasis and allowing the accumulation of iron on the organ tissues. Despite being a notorious etiology of liver disease, when in presence of another, more common, cause, its investigation is often overlooked, resulting in significant underdiagnosis. Late onset of treatment might allow disease progression, with development of chronic liver disease (CLD) and severe impact on prognosis.

Case description

We report the case of a 57 year old male fisherman, with a history of type-2 diabetes, hypertension, smoking and drinking habits, the latter spanning over 4 decades. He had a presumptive diagnosis of alcoholic liver disease, and was sent by his family doctor to a diabetology appointment due to worsening metabolic control. Initial laboratory assessment revealed macrocytosis (104 fL), thrombocytopenia (94,000) and hyperbilirubinemia (2.1 mg/dL), with mild cytolysis (TGO 78U/L, TGP 67U/L) and cholestasis (AF 156 U/L, GGT 60 U/L). Abdominal ultrasound revealed only moderate hepatomegaly and upper GI endoscopy was unremarkable. The

patient was classified as a Child-Pugh A (Score 6). Iron studies revealed serum iron levels of 237 mcg/dL and a 14532 ng/mL ferritin. AFP was 4 ng/mL and viral serologies were negative. The patient presented a greyish skin tone, initially ignored given the patient's job and subsequent heavy sun exposure. An MRI revealed important hepatic and splenic iron overload and HFE gene testing identified the c.845G>A (p.Cys 282Tyr) mutation.

Discussion

The authors present this case report given the presence of a concurrent frequent and obvious cause of hepatic disease, which delayed clinical suspicion and diagnosis of hemochromatosis. The patient's skin tone and the presence of high ferritin led to further investigation, which culminated in a diagnosis. The authors would also like to emphasize the need for a thorough approach of CLD patients, even in alcoholics, given the potential prognosis impact of early treatment in some cases.

#1923 - Case Report

CROHN'S DISEASE: A DIAGNOSTIC CHALLENGE

Isabel Maria Pinheiro

Hospital Santa Maria, CHLN, EPE, Lisboa, Portugal

Introduction

Crohn's disease is an inflammatory, chronic, idiopathic disease that can affect any segment of the digestive tract and may evolve with periods of activity and remission, including abdominal pain and diarrhea with mucus and blood, fistulas, obstruction, malnutrition and several extra-intestinal manifestations, namely genito-urinary, musculo-skeletal, dermatological, ophthalmologic and hypercoagulable states.

Case description

69-year-old white male, retired accountant, married, with previous tonsillectomy 20 years ago; laparoscopic cholecystectomy; smoking; pulmonary emphysema; benign prostatic hypertrophy and ureteral meatus stenosis; thrombosis of the mesenteric artery recanalized (of unclear etiology). Recently admitted with pyelonephritis due to *Enterococcus faecalis*, balanitis due to *Candida albicans* and external hemorrhoid thrombosis. He also complained of diarrhea in the last year, 4 daily dejections, sometimes with mucus but without blood. At the physical examination he was pale, without jaundice, emaciated, abdomen was diffusely painful to palpation but without pain at decompression or other alterations, without palpable adenopathies. Analytically: Hb 12.6g/dL; normal B2-microglobulin and serum electrophoresis; negative serology for cytomegalovirus, hepatitis B and C and HIV1, negative antibodies anti-gliadin and anti-endomysial, interferon gamma release assay (IGRA) was negative. *Clostridium difficile* toxin, stool culture and parasitological examination of feces were negative.

The colonoscopy showed 5 cm of ileum, with 2 deep linear ulcers and an irregular mucosa. Biopsies were inconclusive. The capsule

endoscopy revealed deep ulcers in jejunum, one of which occupied 2/3 of the circumference and was responsible for secondary stenosis, and mucosal aspects suggestive of active ulcer disease of the small intestine. The entero-resonance showed extensive and active ulcerated disease of the whole ileum, short bowel, non-active entero-enteric fistula and mesenteric reactive adenopathies. The upper gastrointestinal endoscopy was normal and abdominal computed tomography, revealed aspects of superior mesenteric vein thrombosis recanalised and collateral venous circulation. He was medicated with prednisolone with clinical improvement.

Discussion

This extensive disease was reasonably tolerated. We assumed that superior mesenteric vein thrombosis occurred in the context of hypercoagulability associated with Crohn's disease.

#1959 - Medical Image

AEROPORTIA – SIGNAL OF ADVANCED BOWEL ISCHEMIA

Anilda Barros, Elena Pirtac

Hospital Garcia de Orta, Almada, Portugal

Clinical summary

A 93-year-old woman with previous history of chronic atrial fibrillation requiring the reversal of anticoagulation therapy due to spontaneous abdominal wall hematoma. She presented with acute abdominal pain and a diagnosis of mesenteric ischemic was made. Toraco-abdomino-pelvic CT scan showing exuberant aeroportia and intestinal pneumatosis.

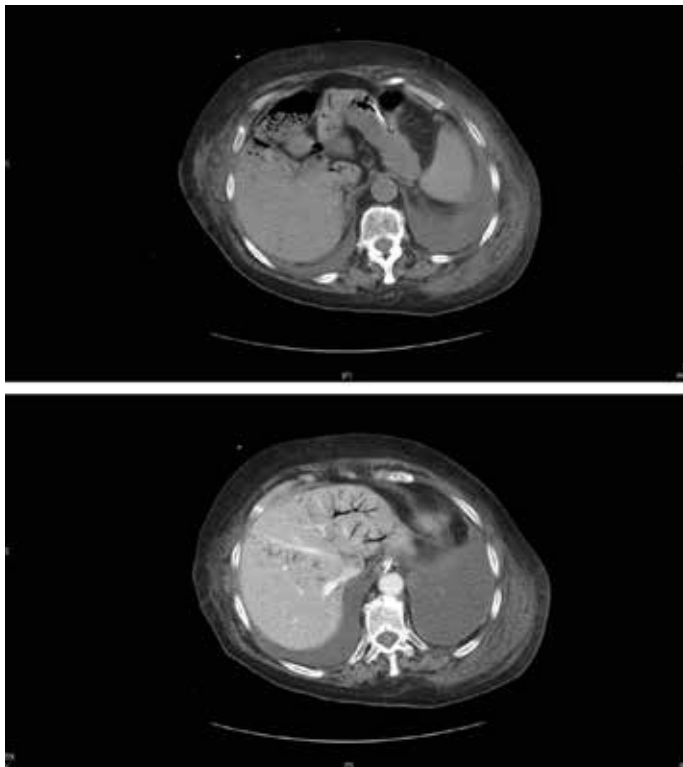


Figure #1959.

#2005 - Abstract

PROTEIN PUMP INHIBITORS IN A MEDICAL WARD

Estefânia Turpin, Rita Valente, Filipa Cardoso, Inês Lopes, Maria Amaral

Centro Hospitalar Universitário de Lisboa Central, Lisboa, Portugal

Background

Protein pump inhibitors' (PPI) prescription is widely disseminated. Although according to the current guidelines, published by the American Society of Healthsystem Pharmacists SHP, there is no indication for prescribing PPI for stress ulcer prophylaxis (SUP) in patients admitted to the hospital outside intensive care units the reality is most patients are medicated with these drugs.

Methods

In this study we selected all patients hospitalized in three different internal medicine wards during the same 24 hours and checked if they were medicated in that moment with PPI. We then used the proposed risk stratification score by Herzig SJ et al to classify them in to low risk (LR) (score ≤ 7), low-medium risk (LMR) (score 8-9), high-medium risk (HMR) (score 10-11) or high risk (HR) (score ≥ 12) for digestive haemorrhage. Only the HMR and HR patients have indication for PPI. We also took in account history of dyspepsia, gastritis, esophagitis, gastric reflux disease and gastric or duodenal ulcer as these diseases may cause symptoms that could have indication for treatment with PPI, and upper intestinal bleeding.

Results

Of the 132 patients hospitalized, 67 corresponding to 50,8% were medicated with PPI but only 38 (28,8%) had indication for SUP. Among the LR and LMR patients 9 had gastro-oesophagi pathology that could justify treatment with PPI. Surprisingly among the 38 patients who had indication for SUP, only 17 were prescribed PPI. There were 8 cases of upper gastrointestinal bleeding, 5 among patients with score ≥ 10 , and 3 among LR and MLR patients, and they were all medicated with PPI. 53 patients (40.2%) were medicated with PPI before being admitted, 35 with LR and MLR, of which 26 were medicated with PPI in the hospital, and 18 with HMR and HR, 15 of these medicated medicated with PPI in the hospital.

Conclusion

In these medical wards PPI are overprescribed in patients who don't have indication for SUP and under-prescribed in those who do have. Some of the perceived overprescription could be explained by other indications for PPI like symptoms of dyspepsia or heartburn. The fact that patients were previously medicated with PPI could also incline doctors to continue this prescription in the hospital. This shows the importance of further studies to validate a risk score and its uniformed use. PPI have known side effects in the intestinal flora and potentially cognitive impairment. Like any other drug they are not innocuous and their prescription should be carefully considered.

#2029 - Case Report

PORTAL HYPERTENSION: WHEN THERE IS NO EVIDENT CAUSE

Joana Borges¹, Carolina Teles², Teresa Vaio², Rui Santos², Armando Carvalho²

¹ Respiratory Medicine Service, Centro Hospitalar e Universitário de Coimbra, Coimbra, Portugal

² Internal Medicine Service, Centro Hospitalar e Universitário de Coimbra, Coimbra, Portugal

Introduction

Portal vein obstruction (PVO) that leads to portal hypertension (PH) is classified based upon the site of obstruction. PVO can occur due to a disturbance in any one of the Virchow triad components: reduced flow, hypercoagulable state or endothelial disturbance.

Case description

A 39-year-old woman was seen in the Emergency Department with upper quadrant abdominal pain as well as nausea, fatigue, and anorexia for a month. She denied fever. No other symptoms were recorded. Besides being obese, she had no relevant past medical history. She had been taking Desogestrel with Ethinylestradiol. She had had no recent surgery, hospital admission or trauma. She had no smoking or alcoholic habits. On admission, she had leucocytosis and raised C-reactive protein, aminotransferases (AST 48 U/L, ALT 86 U/L) and γ glutamyltransferase (152 UI/L). Ultrasound with Doppler flow study showed absent flow in the portal vein. She was admitted, the oral contraceptive was stopped and anticoagulation was initiated. Endoscopy revealed oesophageal varices. Contrast-enhanced abdominal computed tomography revealed thrombosis of the inferior vena cava, portal vein (with cavernous transformation of it), splenic vein and superior mesenteric vein. Serological testing for viral hepatitis was negative. Levels of lipid panel, immunoglobulins, iron saturation, serum ferritin, ceruloplasmin, copper, and α -1-antitrypsin levels were normal. Tests for antinuclear, antimitochondrial, anti-smooth muscle, anti-liver cytosol, anti-liver/kidney microsomal, anticardiolipin and anti-beta2-glycoprotein I antibodies and lupus anticoagulant were negative. She had no antithrombin or protein S or C deficiencies and no factor V Leiden and JAK2 V617F mutations. Paroxysmal nocturnal haemoglobinuria (PNH) was excluded by the absence of PNH white blood cells. She had homozygosity for MTHFR c.665C->T but not an increase in plasma homocysteine that would increase the thrombophilic risk. Anticoagulation was initiated with enoxaparin (1 mg/kg twice a day) and then changed to warfarin (dose-adjusted). Upon clinical and analytical improvement the patient was discharged from the hospital.

Discussion

This case report highlights the importance of the identification of the cause of PVO, as it can imply different management approaches. No apparent cause is found in 25% of patients and many of these patients probably have an underlying hypercoagulable state. Clinical presentation is often non-specific, which makes a PVO diagnosis extremely difficult.

#2054 - Case Report

COMPLICATED PANCREATIC PSEUDOCYST

Catarina Jorge¹, Tânia Gago², Bruno Peixe², Tatjana Mihailovic¹, Sérgio Silva¹, Domingos Sousa¹, Sara Duarte¹, Diana Reis¹

¹ Algarve's University Hospital Centre - Faro Unit, Internal Medicine Department, Faro, Portugal

² Algarve's University Hospital Centre - Faro Unit, Gastroenterology Department, Faro, Portugal

Introduction

The pseudocyst is defined as a fluid collection that result from pancreatic inflammation and necrosis. It's commonly associated with alcoholic etiology and occurs in 20 to 40% of cases of chronic pancreatitis. Infection, hemorrhage and rupture are examples of complicated pseudocysts.

Case description

A 47-year-old woman is brought to the Emergency Department (ED) by a generalized tonic-clonic seizure, lasting 30 seconds, with sphincter incontinence, without tongue biting. New seizure was observed in the ED that subsided with diazepam. The family reported that the patient had fever and abdominal pain with 3 days of evolution associated with vomiting the day before. History of alcohol habits for about 6 years (192 g/day) and smoking. No history of epilepsy. No other organ or system focusing symptomatology. At admission, the patient was vigilant, disoriented, hypertensive, eupneic, febrile, without cardiopulmonary alterations. Soft and depressible abdomen, with palpable mass in epigastric and periumbilical region, about 8 cm in diameter, elastic consistency, painful, with signs of peritoneal irritation. Negative meningeal signs. Analytically, elevation of inflammatory markers, hyperglycemia, cytocholestase pattern and elevation of amylase (721 U/L) and lipase (771 U/L). Abdominal ultrasound revealed a well-defined lesion, heterogeneous, 15x7cm, difficult to visualize if there was communication with a part of the pancreas. For better characterization, abdomen CT scan was performed, showing a well-defined, encapsulated collection in the pancreatic body and tail, suggesting a pancreatic pseudocyst with an internal hemorrhagic area (pseudoaneurysm rupture). Pancreatitis of alcoholic etiology was admitted with pancreatic pseudocysts complicated with hemorrhage and infection. Seizures in the context of alcohol withdrawal syndrome.

Discussion

The present case report pancreatic pseudocyst complicated by infection and hemorrhage, which is a rare condition. In addition, the clinical presentation as a seizure was an initial confounding factor, reinforcing the primordial value of the complete anamnesis in the establishment of the diagnosis.

#2060 - Medical Image

FROM OLGIVIE'S SYNDROME TO RESPIRATORY FAILURE

Francisca Santos, Daniela Félix Brigas, Eugénio Dias, Susana Marques

Centro Hospitalar de Setúbal, Setúbal, Portugal

Clinical summary

A 90-year-old man was admitted at the Emergency Department after being found fallen at home. Upon the objective examination, it should be highlighted the presence of a very voluminous abdomen with marked tympanism at percussion. Rectal examination showed a normotonic sphincter, without stenosis. Analytically, there were no major changes. An abdominal x-ray was performed and suggested a megacolon and the abdominal-pelvic computed tomography confirmed an important distension of the colonic frame, with no significant distension of the thin loops, with presence of fecaloma in the sigmoid and rectal ampulla. It appeared to be a case of megacolon in the sequence of Olgivie's syndrome. Despite the medical measures, the patient died in a respiratory failure sequence.

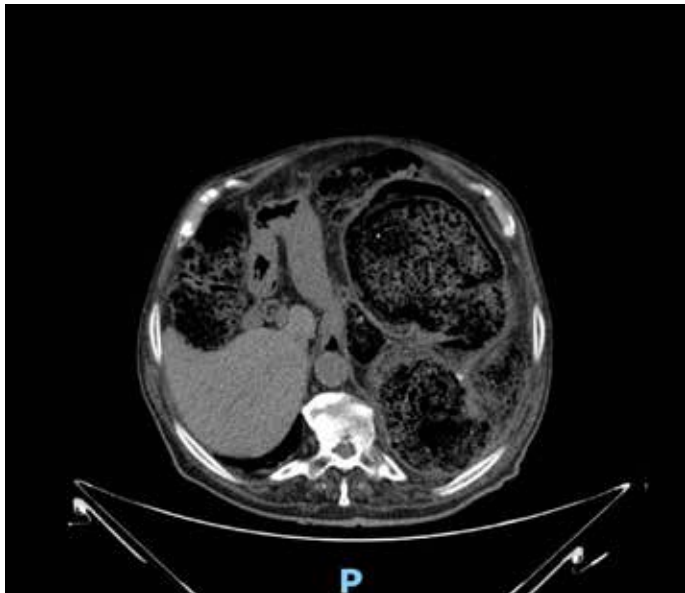


Figure #2060. Computed tomography findings of a case of megacolon associated with Olgivie's syndrome.

#2098 - Case Report

PRIMARY SCLEROSING CHOLANGITIS AND ULCERATIVE COLITIS IN A YOUNG WOMEN

Cristina Moreira Marques, Ana Francisca Pereira, Carina Costa Silva, João Pedro Abreu, Márcia Ribeiro, Ana Ogando, Carlos Oliveira

Hospital Santa Maria Maior, Barcelos, Portugal

Introduction

Primary sclerosing cholangitis (PSC) is the cholestatic hepatobiliary disorder more common in males and usually presents at 40 years of age. It is a chronic immune-mediated disease of intra and

extrahepatic bile ducts, primarily affecting large ducts. Is usually common in patients with inflammatory bowel disease (IDB), particularly those with ulcerative colitis (UC) with a phenotype involving rectal sparing, right colonic disease with backwash ileitis; and generally, its diagnosis is posterior to the IBD.

Case description

18-year-old female, without previous relevant medical history or medication, presented in the ER with abdominal pain in the right hypochondrium, pruritus and diarrhea without blood or mucus, without fever, with two months of evolution. She had a normal physical exam. Blood work was done, with normal blood count, AST 193 IU/L; ALT 668 IU/L; AP 485 IU/L; GGT 1165 IU/L, normal bilirubin and CMV, HBV, HCV and HIV negative serologies. Due to the alterations, a CT scan was performed that showed a "mild dilatation of the intrahepatic biliary tract". She was then directed to the Internal Medicine Consultation to continue the study. A MRI showed "mild ectasia of the intrahepatic bile ducts, which alternate with areas of mild stenosis". The colonoscopy showed typical signs of ulcerative colitis, in particularly cecal patch. The autoantibody test performed revealed ANA; ANCA; LC1 and anti-ML positive. The patient was diagnosed with primary sclerosing cholangitis and ulcerative colitis, started on ursodeoxycholic acid with improvement of the liver function and symptoms.

Discussion

The diagnosis and management of PSC presents itself with several challenges. Many times patients are asymptomatic or present with mild symptoms. In this case, the diagnose of PSC prior to that of the IDB, which should alert us to the importance of the diagnosed of the associated diseases that sometimes do not have the most common presentation. The treatment of this entity is of vital importance once our goal is to achieve delay or reversal of the disease and its complications.

#2106 - Case Report

GASTRIC OUTLET OBSTRUCTION- FIRST MANIFESTATION OF DUODENAL ULCER SUCCESSFULLY TREATED WITH DRUG THERAPY

Federica Parlato¹, Pedro Silva Gaspar^{1,2}, Manuel Silvério António³, Maria Margarida Andrade¹, Sandra Braz^{1,2}, Rui Victorino¹

¹ Serviço de Medicina 2, Hospital de Santa Maria (Director: Prof. Doutor Rui M. M. Victorino), Centro Hospitalar Lisboa Norte, Lisboa, Portugal

² Faculdade de Medicina, Universidade de Lisboa, Lisboa, Portugal

³ Serviço de Reumatologia e Doenças Ósseas Metabólicas (Director: Prof. Doutor João Eurico da Fonseca), Hospital de Santa Maria, Centro Hospitalar Lisboa Norte. Unidade de Investigação em Reumatologia, Instituto de Medicina Molecular, Centro Académico de Medicina de Lisboa, Faculdade de Medicina, Universidade de Lisboa, Lisboa, Portugal

Introduction

The prevalence of peptic ulcer disease (PUD) has significantly

decreased over the past several decades due to treatment of *H. pylori* infection and the development of drugs such as proton pump inhibitors (PPI). However, complications such as hemorrhage, perforation and obstruction still occur. Gastric outlet obstruction (GOO) is the least frequent complication occurring in 3% of the cases. Definitive treatment may include endoscopic balloon dilatation or surgery.

Case description

A 81-year-old male patient, with prior medical history of primary hemochromatosis, arterial hypertension and type 2 diabetes mellitus, was admitted with a 1-week history of nausea, epigastric pain and bloating relieved by vomiting. He denied hematemesis or melena. On physical examination he was dehydrated and had abdominal distension with tenderness over epigastrium and left hypochondrium. Laboratory findings were as follow: hemoglobin 15 g/dL, urea 148 mg/dL, serum creatinine 2.14 mg/dL, Na⁺ 141 mmol/L, K⁺ 3.7 mmol/L. Abdominal x-ray showed exuberant gastric distension and computed tomography scan revealed parietal thickening of the gastric antrum-pyloric region and duodenal bulb of about 2.5cm in length. Upper endoscopy showed intense edema and hyperemia of the bulbar mucosa and a severe stenosis at that level. Biopsies were taken and a nasogastric tube was placed. Histopathology revealed intense chronic antral and pyloric inflammation, mucosal ulceration and the presence of *H. pylori*. There was no evidence of fibrosis or malignant tissue. *H. pylori* infection eradication therapy (intravenous amoxicillin, metronidazole and high dose PPI) was started. On the second week of therapy, liquid diet was initiated and tolerated. Upper endoscopy was repeated on the third week of high dose PPI and showed partial resolution of the stenosis. The feeding tube was removed and soft diet was initiated. Three months after the diagnosis of GOO the patient tolerates normal diet.

Discussion

PUD, both acute and chronic, can lead to GOO and accounts for about 5% of the cases of obstruction. In this case GOO was the inaugural manifestation of DUP. The sudden onset of the clinical picture, the intense hyperemia and edema of the duodenal mucosa, the presence of an inflammatory infiltrate and absence of fibrosis in the tissue supports this diagnosis. In these cases, drug therapy is a reasonable, safe and efficacious option. Endoscopic dilatation and/or stricturoplasty should be reserved for patients who fail to respond to drug therapy.

#2116 - Case Report

VON MEYENBURG COMPLEX AS DIFFERENTIAL DIAGNOSIS OF SOLID LIVER LESION.

Pedro Manuel Reis Pereira, Patrícia Chow Liu, Joana Liz Pimenta, Paula Vaz Marques, Sandra Alves Morais
Centro Hospitalar de Trás-os-Montes e Alto Douro, Vila Real, Portugal

Introduction

Hepatic lesions are a common finding in clinical practice. The aetiology of solid liver lesions is diverse, dividing mainly into benign and malignant lesions. Patients with chronic liver disease have a higher risk of malignant lesions, therefore, a close screening and detailed investigation of new solid liver lesions should be performed.

Case description

We present the case of a 58-year-old male with an alcoholic liver disease at a compensated cirrhotic stage, followed at the hepatology outpatient clinic. During an abdominal ultrasound screening an hypoechoic nodule was found on the right hepatic lobe, with a diameter of 19 mm. Hepatic MRI described the presence of a nodule with a diameter of 16 mm of which the unspecific imagiological features resembled a colangiocarcinoma or an hyalinized hemangioma (atypical hepatic hemangioma). Given the doubts raised by the imaging exams, a nodule biopsy was performed, and the histological examination described the presence of lesions suggestive of bile ducts hamartomas. Based on the benignity of the diagnosis, this compensated cirrhotic patient remained on a biannual screening regime, and maintains a stable evolution.

Discussion

Bile ducts hamartomas, also known as Von Meyenburg complex, are rare, benign and asymptomatic hepatic malformations, with variable imagiological findings that may sometimes resemble malignant lesions. The radiological presentation demonstrate multiple small lesions scattered throughout the liver, or more rarely an isolated nodule, thus, imaging exams are not reliable methods for the differential diagnosis. Biopsy of the liver lesion remains the gold standard for a definitive diagnosis of Von Meyenburg complex. In the present case, we intend to demonstrate an atypical presentation of a rare benign entity, in which radiological similarities with malignant lesions may lead to a incorrect and inconclusive interpretation of the findings. We highlight the importance of histologic evaluation, especially in cirrhotic patients in order to diagnose a rare and not frequently considered entity in clinical practice.

#2122 - Abstract

MORTALITY AFTER VARICEAL HEMORRHAGE IN CIRRHOTIC PATIENTS: IDENTIFYING RISK FACTORS

Margarida Viana Coelho¹, Pedro Campelo², Claudia Camila Dias^{3,4}, Isabel Jesus Pereira^{5,3,4}

1. Internal Medicine Department, Hospital de Faro, Centro Hospitalar Universitário do Algarve, Faro, Portugal
2. Gastroenterology Department, Hospital de Faro, Centro Hospitalar Universitário do Algarve, Faro, Portugal
3. Department of Community Medicine, Information and Health Decision Sciences-MEDCIDS, Faculty of Medicine of the University of Porto, Portugal, Porto, Portugal
4. CINTESIS – Center for Health Technology and Services Research, Porto, Portugal, Porto, Portugal
5. Emergency and Intensive Care Department, Hospital de Faro, Centro Hospitalar Universitário Do Algarve, Faro, Portugal, Faro, Portugal

Background

Variceal hemorrhage in cirrhotic patients is a medical emergency with an estimated mortality of 15– 20% during the first episode. Risk classification can be assessed by Child-Pugh class, Model for End Stage Liver Disease (MELD) score, variceal size, and endoscopic findings.

Our aim was to identify factors associated with mortality in patients with esophageal and gastric variceal hemorrhage.

Methods

A retrospective observational study was conducted between 1 January and 31 December 2017. All cirrhotic patients admitted with acute variceal hemorrhage were included. Clinical records were revised for data retrieval on end stage liver disease related complications (hepatic encephalopathy, ascites, spontaneous bacterial peritonitis and hepatocellular carcinoma (HCC)), and for scores of severity and prognosis (Child-Pugh and MELD). The course of hospitalization was investigated through the presence of hemodynamic instability, hemoglobin values, active bleeding at the initial endoscopy and subsequent episodes hemorrhage. Statistical analysis was performed according to the collected variables and objectives and data was analyzed using SPSS v25.

Results

A total of 57 cirrhotic patients with esophageal and gastric variceal hemorrhage on admission were included, of whom 87,7% were male (n=50) with a mean age of 60,5 years; 91,2% had alcoholic etiology. The mean MELD score was 19,1; 57,9% of patients had Child-Pugh class B (n=33) and 33,3% Child-Pugh class C (n=19). In-hospital mortality was 15.8% (n=9); and 42.1% (n=24) at 30-days

In-hospital mortality was strongly associated with hepatic encephalopathy (p=0.002), hemodynamic instability (p=0.008), ascites (p=0.012), active bleeding at the initial endoscopy (p=0.048) and relapsing hemorrhage (p=0.022).

Mortality at 30 days was strongly associated with hepatic

encephalopathy (p=0.000), ascites (p=0.024), Child Pugh Class B and C (p=0.001), relapse bleeding (p=0.004) and HCC (p=0.005).

Conclusion

Attention should be addressed towards the prevention of major cirrhosis complications. As described in other series, mortality was strongly influenced by hepatic encephalopathy, ascites and relapse bleeding. When considering 30-day mortality, Child-Pugh class and HCC were also strongly associated with increased mortality.

In the acute setting, hemodynamic resuscitation and hemorrhage treatment must be concomitant with the identification and treatment of cirrhosis complications, as these are predictors of mortality.

#2134 - Medical Image

AN ATYPICAL PRESENTATION OF AN ASYMPTOMATIC PANCREATITIS WITH A LATE COMPLICATION: WON

Marta Sáenz De Tejada López, Gloria Rojano Rivero, Maria Elena Mansilla Rodriguez

Hospital Infanta Elena, Huelva, Spain

Clinical summary

A 53-year-old patient with a history of hypertension, dyslipidemia and smoking.

Admitted for 4-days-evolution of a biliary colic with a lipase in 208 mg/dl and PCR 72, without leukocytosis and normal hepatic profile. Diabetes not previously known with HbA1c 7.5%. We found a suspect image in US of a cystic lesion in the head of the pancreas. In the abdomen scan, we see an image of a large imprecise multicystic lesion in the head/uncinate process of 43x38x43 mm, impressing of pancreatic cystic tumor. USE-PAAF, describes an encapsulated necrotic collection, suggesting WON (Walled-off necrosis) and the biopsy of the lesion dismiss malignancy. It was made a necrosectomy and cholecystectomy, due to bad evolution. It's an atypical late complication of acute pancreatitis, asymptomatic in this case.

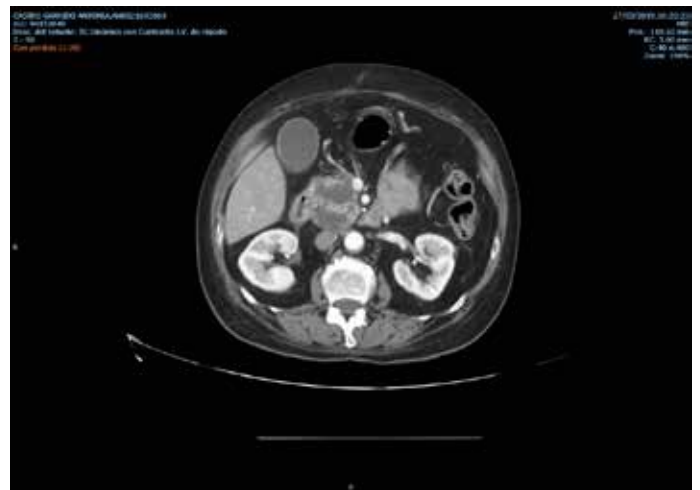


Figure #2134. Scan of the pancreatic lesion.

#2152 - Case Report

RETROPERITONEAL LIPOSARCOMA – A RARE ENTITYMiguel Alexandre Alves¹, Sergio Alves¹, Filipa Lucas²¹ ULSNE, Bragança, Portugal² Hospital de Cascais, Cascais, Portugal**Introduction**

Retroperitoneal sarcomas are rare tumors, with incidence around 2.5 cases / million inhabitants. Within these, the liposarcomas represent about 20% of cases. They are usually slow growing, oligosymptomatic tumors, reaching large sizes at diagnosis.

Case description

We present a case of a man of 69 years of age, with marked alcoholic / smoking habits that reported a progressive increase in abdominal perimeter, with weight loss of 12 kg during the last year. He had na abdominal voluminous mass that occupied the right quadrants. Abdominal ultrasound was not enlightening and therefore an abdominal CT was performed, revealing a heterogeneous mass measuring 24x18x21 cm, which occupied almost all of the abdominal cavity. MRI showed good cleavage planes with adjacent structures and confirmed the retroperitoneal location of the lesion. The complementary study did not show any secondary lesions. He underwent surgery for removal of the retroperitoneal tumor and complementary appendectomy due to adhesion. The main piece weighed 5.220 kg and the surrounding retroperitoneal fat about 1.360 kg. The postoperative period was uneventful. The anatomical-pathological study revealed a predominance of adipocyte cells with nuclear and abundant atypia connective septa, compatible with a well differentiated liposarcoma. Currently the patient is being treated with Radiotherapy.

Discussion

Clinically it presents, in the great majority of cases, as an asymptomatic abdominal mass, not painful to palpation. When symptoms are present, they are responsible for the effect of local tumor invasion, such as: early satiety, gastrointestinal occlusion, lower limb or abdominal edema. The first-line treatment is surgical, with block resection of the tumor and adjacent structures or organs with direct evidence of invasion, since the negative histological margins represent the main prognostic factor.

#2204 - Medical Image

A FEVER KEPT IN A POCKET

Mafalda Corrêa Figueira, Margarida Lopes Madeira, Goncalo Amaral Mendes, Bárbara Lobão, José Pedro Villa De Brito, Ermelinda Pedroso

Centro Hospitalar de Setúbal, Setúbal, Portugal

Clinical summary

A 72-year-old male patient was admitted due to progressive and worsening dysphagia accompanied by severe weight loss and intermittent fever.

During the first evaluation he was found to have a giant zenker diverticulum.

He had a relapsing-remitting fever so that infectious, autoimmune and neoplastic etiologies were investigated and excluded. After surgical intervention to remove zenker diverticulum he stopped having fever.

It was hypothesized that the debris that accumulated in esophageal pouch, probably with some component of lung microaspirations, could explain the recurrence of fever.

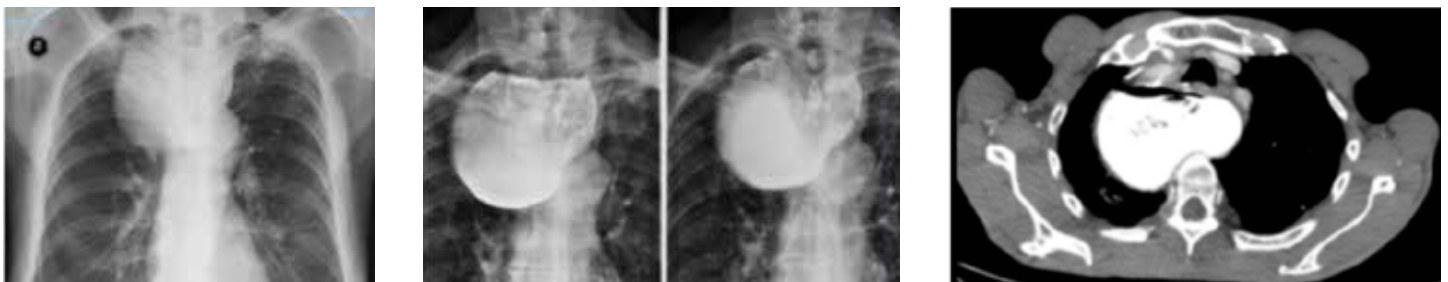


Figure #2204. Giant Zenker diverticulum.



GERIATRICS AND MULTIMORBIDITY

#31 - Abstract

ASSESSING COMORBIDITY AND QUALITY OF LIFE IN EXTREMELY ELDERLY PEOPLE

Laisa Socorro Briongos Figueroa¹, Marta Cobos Siles¹, Jessica Abadía Otero¹, Miriam Gabella Martín¹, Ana Aguado De La Fuente², Juan Carlos Martín Escudero¹

¹ Internal Medicine Service, Rio Hortega University Hospital, Valladolid, Spain

² Nursing Care Department, Rio Hortega University Hospital, Valladolid, Spain

Background

Spanish population life expectancy is one of the longest in the world. Moreover, it's known that elderly people have less chronic illnesses associated to aging. Our aim was to analyze interactions between comorbidities and health related quality of life (HRQoL) in extremely elderly patients

Methods

Cross-sectional study including Internal Medicine in-patients over 80 years-old without diabetes mellitus during 2018. Clinical information was obtained from medical records. Comorbidity was evaluated using Charlson index (CI) and HRQoL with EuroQoL (EQ-5D-3L). Data analyzed using SPSS v.15.0

Results

We identified 305 patients, 59% women. Mean age was 88±5, 38% were aged over 90 and 64% were living in family home. For the previous year, mean number of visits at primary care system were 5.5±3.3 and 2.4±1.8 at the emergency department. Most common comorbidities were hypertension (78%), hypercholesterolemia (37%), atrial fibrillation (31.5%), dementia (23.6%), chronic respiratory disease (19.7%) and heart failure (6%). Corrected CI mean score was 6.2±1.7, without comorbidity in 51% and high comorbidity in 28.5% of patients (higher in men: 33.6% vs 25%, $p=0.049$). Estimated HRQoL was 0.43±0.33 on a scale between 0 and 1 for index value and 55.7±19 for visual analogue scale with a CI correlation of -0.171 ($p=0.003$) for EQ-5D-3L index value

Conclusion

As a novelty, present study showed that about half of our non-diabetic-patients have no comorbidities. Furthermore, weak negative correlation between IC and HRQoL was detected: as CI

increased a worse subjective HRQoL appeared. This fact matches with the high prevalence of absence of comorbidities in our extremely elderly population.

#34 - Case Report

A DEADLY FORM OF DELIRIUM

Xin Zhang, Bernard Aoun

Mayo Clinic, Rochester, United States

Introduction

Acute onset mania is rare in the older adults and should raise suspicion for delirium or dementia. Delirious mania is a rare and potentially deadly etiology of acute onset mania in hospitalized patients.

Case description

A 62-year-old woman, with psychiatric history of major depression, was hospitalized for urinary tract infection. During her hospitalization, she exhibited unusual behaviors consisting of paranoia, disinhibition, and pressured speech. Interestingly, she did not have fluctuations in orientation or alertness suggestive of acute delirium. Because of the manic symptoms, she was started on risperidone and haloperidol. Unexpectedly, she developed hallucinations and signs of catatonia. She had extensive evaluation for somnolence and was found to have pneumonia. CT head showed mild leukoaraiosis. EEG demonstrated diffuse slowing and intermittent runs of generalized triphasic waves consistent with delirium. Risperidone was discontinued without improvement in her mental status. Despite aggressive medical therapy, she developed multiorgan failure and passed away after 30 days in the hospital.

Discussion

Delirious mania is a highly fatal, acute, rapidly progressive and under recognized syndrome of alternating delirium, mania, catatonia and psychosis. In 1 study, 75% of patients with delirious mania died while hospitalized. Unlike in acute delirium, antipsychotics may worsen symptoms. Benzodiazepines and electroconvulsive therapy are the recommended treatments.

#134 - Abstract

HOSPITAL READMISSIONS IN ELDERLY PATIENTS WITH HEART FAILURE. A RETROSPECTIVE STUDY

Rita Vieira Alves, Marília Andreia Fernandes, Diogo Drummond Borges, Inês Rego Figueiredo, Ana Margarida Antunes, Heidi Gruner

Centro Hospitalar Universitário Lisboa Central, Lisboa, Portugal

Background

Heart failure (HF) is a major cause of morbidity and mortality worldwide. The prevalence increases with age and usually progresses, leading to repeated hospital admissions and significant symptom burden for patients. The correct management of these patients may decrease readmissions and increase quality of life.

Methods

Retrospective study, consulting patient's clinical records, population over 65 years of age with HF, hospitalized in 2017, in an internal medicine ward in a tertiary hospital. Patients were divided into 2 groups with (wR) and without (woR) readmission within 1 year and were compared regarding the patient's gender, age, level of autonomy, comorbidities and reason for hospitalization. The etiology of heart disease, BNP assay and echocardiogram were characterized. The primary outcome was death at 12 months.

Results

Eighty-nine patients were included, 60 woR and 29 wR, mean number of readmissions within a year was 2.6. There was no gender difference between groups; the wR group had older patients (77.3 years woR/79.5 years wR) with no difference in independence in activities of daily living (35.0% woR/34.5% wR). The most frequent comorbidities included atrial fibrillation (46.6% wo / 1.7% wR) and hypertension (41% woR/40% wR). The most frequent cause of hospitalization was HF due to insufficient therapy or progression of the disease (45.0% woR/72.4% wR), or an infectious process as decompensating factor (16.6% woR/20.7% wR). The etiology of HF was mainly hypertensive (51.0% woR/41.4% wR) and ischaemic (21.0% woR/37.9% wR). The wR group had more patients classified as NYHA >III (16.6% woR / 31.0% wR). Seventy-five patients had an echocardiogram, all with structural changes and 10% woR vs 48% wR had decreased ejection fraction (EF). No difference between groups in BNP quantification (941 pg/mL woR / 807 pg/mL wR). 57 patients were taking beta-blocker, 52 were on angiotensin converting enzyme inhibitors or angiotensin receptor blockers and 69 were taking a diuretic at admission. Mortality at 12 months was higher in the group with repeated admissions (16.6% woR/31.0% wR)

Conclusion

HF is a progressive disease, which causes repeated hospitalizations, especially in more advanced stages of the disease, in patients with decreased EF and is associated with higher mortality, as was the case in our small sample. The characterization of this population

allows us to highlight the causes of decompensation and to review medication in order to increase the quality of life.

#142 - Abstract

CLINICAL ADVERSE EVENTS IN A MEDICAL WARD - A PROSPECTIVE STUDY

Rita Vieira Alves, Marília Andreia Fernandes, Diogo Drummond Borges, Inês Rego Figueiredo, Ana Margarida Antunes, Heidi Gruner

Centro Hospitalar Universitário Lisboa Central, Lisboa, Portugal

Background

Adverse events (ADEs) are a significant problem and may particularly affect the elderly population, which constitutes a significant part of hospitalized patients. In clinical practice, fewer than 5% of ADEs are reported, even when reporting is mandatory.

Methods

A prospective study, consulting patient's electronic clinical notes over 6 months (June to December 2017) in an Internal Medicine ward of a tertiary hospital. ADEs reported in the clinical notes were selected and the drug or intervention responsible noted. Patients were grouped by age; group A <65 years, group B 65-80 years, group C >80 years and compared in terms of gender, autonomy status, comorbidities, diagnosis at admission and readmission rate within one year. Primary outcomes included mean length of stay and mortality.

Results

Sixty-two episodes, equivalent to 61 patients (8% of the 706 admitted) with ADEs were included. Autonomy decreased with increasing age; 100% independent in A, 65% B and 47% C. 30% had hypertension, 30% atrial fibrillation, 18% diabetes and 17% ischemic heart disease. In 56% of the cases, the ADE was the cause of admission. Readmission rate was 54% (61% A, 61% B, 47% C). The most frequent ADEs included analytical changes including acute renal failure and electrolyte imbalance (30% total; 30% A, 23% B, 39% C), anemia and blood loss (28% total; 23% A, 23% B, 34% C), infection (18% total; 38% A, 19% B, 0.5% C) and altered state of consciousness (15% total; 0% A, 19% B, 17% C). The most commonly implicated therapies were drugs; anticoagulants (23%), antihypertensives and diuretics (17%), immunosuppressive therapy (16%), beta-blockers (1%) and insulin (1%). Mean length of stay was 17 days (16.0 days A, 17.5 B, 18.3 C), considerably longer than the average length of stay of 11 days for the same period. Mortality within one year of hospitalization was 30%, again significantly higher than the 9% mortality rate calculated for the same period (10% A, 27% B, and 43% C).

Conclusion

Pharmacovigilance is a clinical responsibility, particularly in the polymedicated and increasingly elderly population in hospital. Length of stay and mortality are increased in patients with ADE,

as is the case in our small sample, which reflects findings in recent literature. A limitation in this study is that the collected data included only the ADE reported in the clinical notes, furthermore only drug related ADE were found; it is likely that this study will significantly underestimate the prevalence of ADE in hospital settings.

#159 - Abstract

CLINICAL PROFILE OF HYPERTENSIVE PATIENTS WITH HEART FAILURE IN A COUNTY HOSPITAL

Julio Osuna Sánchez¹, Antonio Ubiña Carbonero²

¹ Hospital Comarcal Melilla, Melilla, Spain

² Centro de Salud San Andrés-Torcal, Málaga, Spain

Background

Carry out a retrospective descriptive study of hypertensive patients admitted for heart failure in the Internal Medicine service of our hospital during 2017.

Methods

This is a transversal descriptive analysis of patients admitted to internal medicine for heart failure (HF) in 2017 who were hypertensive. A detailed study was carried out of all the risk factors presented by patients, the associated comorbidities, as well as personal history. We have analyzed the discharge reports of our service along with the review of medical records. A descriptive study of the characteristics of patients using frequency measurements has been carried out, analysing the type of sample to see whether or not they remained normal.

Results

There were a total of 120 patients hospitalized for HF, of which 62.5% were hypertensive. 58.7% were women. The mean age was 80.69±10.07 years. 8% of the patients were institutionalized, 18.7% were dependent for all the basic activities of daily life. 57.3% were of Caucasian ethnicity and 42.7% were Berber. 89.3% had social security.

Regarding personal history: 26.7% previous ischemic heart disease; 61.3% HBP; 36% A-fib; 13.3% COPD; 34.7% dyslipidemia; 9.3% sleep apnea; 12% anemia; previous stroke 8% and 14.7% neoplasia (active or not). The most frequent causes of admission were the ischemic cause with 38.5% and the valvular heart disease with 38.5%. As an important finding, 10.7% of the patients presented cognitive impairment to some degree. 100% of patients had 2 or more pathologies at the time of admission. The medication prescribed was as follows: ACE inhibitors 30.7% (enalapril (77.8%)); beta-blockers 45.3% (bisoprolol (8.8%)); ARBs 32% (valsartan (27.3%)) and calcium antagonists 18.7%. The mean stay of hospital admission was 10±8.77 days, being exitus 10,7% of the patients.

Conclusion

Heart failure is a problem for both public health and the doctor who must face it daily. Once diagnosed the prognosis becomes

ominous as approximately 50% of patients die within the next 5 years. Early diagnosis and treatment of HF is important to prevent its complications, slow its evolution, decrease its symptoms and avoid the need for hospitalizations once the diagnosis is confirmed. This picture worsens when as a comorbidity we add HBP, making it harder to manage and the morbidity and mortality is higher. Patients admitted for acute HF with HBP have a multi-pathological profile with multiple diseases so we should do a closer follow-up if possible due to the high mortality rate.

#250 - Case Report

RAOULTELLA PLANTICOLA INFECTION AND WHEN TO STOP

Flávio Pereira, Joel Pinto, Mariana Da Silva Leal, Viktor Malyarchuk, Jorge Henriques, Susana Cavadas
Centro Hospitalar do Baixo Vouga, Aveiro, Portugal

Introduction

Raoultella planticola is a Gram negative bacillus that is present in the soil and water. It rarely causes infection in immunocompetent hosts. This microorganism has aroused interest in the scientific community due to the increasing number of identifications. As a member of the Enterobacteriaceae family, it has a huge potential to develop multi-resistance.

Case description

87-year-old woman, bedridden, with severe functional dependence (Barthel Scale 20 points) and severe sarcopenia presents to the emergency room with vomiting and decreased urinary output. Two days before she had initiated flucloxacillin for left lower limb cellulitis. She presented with temporo-spacial disorientation and inflammatory signals in pre-tibial region of the left lower limb at admission. Complementary study revealed leukocytosis ($20.3 \times 10^9/L$) with neutrophilia ($17.00 \times 10^9/L$), elevated C reactive protein (15.89 mg/dL), acute kidney injury (Urea 182.5 mg/dL; Creatinine 5.93 mg/dL), hepatic cholestasis (alkaline phosphatase 1068 U/L; gamma-GT 1061 U/L) and urine dipstick with leukocyturia. Abdominal ultrasonography revealed a nodule of 35 mm near the hepatic hilum in the right hepatic lobe. Blood and urine cultures were done and patient started ceftriaxone and clindamycin. Body computed tomography revealed a nodule in the right hepatic lobe, near the hilum and multiple micro nodules in right lung, suggestive of metastasis. Patient exhibited good clinical and analytic evolution of the septic condition. Urine culture revealed positivity for *Raoultella planticola* resistant to ampicillin and fosfomicin. Pulmonary and hepatic metastization by an unknown occult neoplasia was assumed. Given the previous functional state and after discussion of the clinical condition with the patient's family, it was decided to stop the etiological study.

Discussion

Raoultella planticola infection is frequently associated with immunosuppression. In this case, there was an elevated suspicion

of advanced oncologic disease, beyond immunosenescence. This case highlights the importance of avoiding the diagnostic and therapeutic rampant and adjust the degree of investment to the patient general state. Patient and family should be included in the decision making process.

#352 - Abstract

THE INFLUENCE OF COGNITIVE FUNCTION ON OUTCOME AFTER HIP FRACTURE IN OLDER PEOPLE

Cristina Carvalho Gouveia¹, Ana Lopes Santos¹, Sofia Duque¹, Luís Campos¹, Rosana Andrade², Fátima Falcão²

¹ Hospital de São Francisco Xavier, Centro Hospitalar de Lisboa Ocidental, Lisbon, Portugal

² Centro Hospitalar de Lisboa Ocidental, Lisbon, Portugal

Background

Hip fracture (HP) is associated with considerable morbidity and mortality, especially in older people. Cognitive impairment, which has been found in 31-88% of older patients experiencing HP, has been demonstrated to be associated with poorer functional recovery after HP surgery. We aim to study the cognitive function in this population and its possible association with adverse outcomes after hospital discharge for HP.

Methods

Retrospective study of older outpatients previously admitted to an Orthogeriatric Unit for HF. We included patients whose follow-up consultation was between May and December 2018. The population was separated accordingly to the Global Deterioration Scale (GDS) at hospital admission: group A – no cognitive impairment (GDS 1 and 2), B – mild cognitive impairment (GDS 3), C – moderate to severe cognitive impairment (GDS 4-7).

Results

42 patients were included. 40.5% (n = 17) had cognitive impairment. The follow-up evaluation was performed 201 days (mean) after hospital discharge. Patients in group C had worse functional status before hospital admission, as demonstrated by a lower Barthel index (57.2 vs A: 90.2 vs B: 90 points), lower Holden classification (2.8 vs A: 4.2 vs B: 4.3 points) and higher Charlson index (5.7 vs A: 4.0 vs B: 4.4 points). Group C had also more institutionalized patients (44.4 vs A: 4.0 vs B: 12.5%). The preoperative time was longer in group C (6.0 vs A: 4.6 vs B: 4.9 days). At discharge, the majority of patients was able to walk with support (A: 88.6, B: 87.5 and C: 88.9%) and none of the patients, of any group, was bedridden or able to walk without support. Almost all patients started physiotherapy for gait rehabilitation after discharge (A: 97.1, B: 100 and C: 100%). Patients in group C had a more pronounced deterioration in functional status, as demonstrated by a higher decline in the Barthel index (23.3 vs A: 15.2 vs B: 0.15 points). Also, group C had significantly less patients able to walk independently (0 vs A: 40 vs B: 50%) and more bedridden patients (22.2 vs A: 8.0 vs B: 0%).

Conclusion

Cognitive impairment is prevalent in this population. In this study, moderate to severe cognitive dysfunction seemed to be associated with worse functional outcomes after hospital discharge for HP, regarding the ability to walk and perform the activities of daily living. These results may justify a more thorough approach to cognitive impaired patients, in order to provide them a better quality of life.

#356 - Abstract

POTENTIALLY INAPPROPRIATE MEDICATIONS IN OLDER ADULTS - PREVALENCE IN THE WARD ACCORDING TO UPDATED AMERICAN GERIATRICS SOCIETY 2019 BEERS CRITERIA

Mariana Da Cruz, Nuno Zarcos Palma, Gisela Vasconcelos, Ligia Santos, Margarida Cruz, Catarina Couto, Ricardo Meireles
Centro Hospitalar Tâmega e Sousa, Penafiel, Portugal

Background

Prescription and polypharmacy are extremely important topics in the geriatric population due to their weakness and multiple comorbidities. The American Geriatrics Society reviewed in 2019 the criteria of Beers attempting to detail potentially inappropriate medications (PIM) in order to avoid the use of these as first-line therapy in the elderly. The aim of this study is to estimate the prevalence of PIM using the Beers criteria in the elderly population hospitalised in the medical department and general surgery ward.

Methods

Retrospective, cross-sectional study. Eligibility criteria were: patients with 65 years old and over, admitted under the care of the medicine department: internal medicine and pneumology (6 wards) and general surgery services (2 wards). Patients in the ICU and with a palliative care setting were excluded. At the prescribed drugs were applied the 2019 updated Beers criteria and thus observed its prevalence.

Results

A total of 324 clinical processes were analyzed, of which 201 met the inclusion criteria, 56% (n=112) female, 44% (n=89) male, with a mean age of 80.6±7.9 (65-96) years. The length of hospital stay was, on average, 12.9±16.1 (1-42) days. The sample had a moderate dependence according to an average Katz score of 4, and a high risk of falling, with a Morse scale greater than 45 points in 58% (n=118). The most frequent reason for hospitalisation was community acquired pneumonia (n=56) followed by acute cerebral vascular disease (n=35). A median of 9 drugs per patient were prescribed, with the most common being acetaminophen (n=198), proton pump inhibitors (n=190), low molecular weight heparin (n=193) and rapid insulin (n=184). When the Beers criteria were applied, 66% of the patients had PIM prescriptions, corresponding to 428 drugs. The most common drugs were: PPI (n=198) typical

and atypical antipsychotics (n=60), metoclopramide (n=53) and benzodiazepines (n=43). Drugs targeting the central nervous system account for 53% of PIM.

Conclusion

In the literature there is a strong association between the drugs included in the Beers criteria and a worse prognosis in patients, despite this preponderant information, PIM are still frequently prescribed. It is noteworthy that the medical prescription should always be individualized considering a multiplicity of factors. Training is needed for rational drug use and polypharmacy in the elderly population. The authors emphasize the importance of training in geriatrics.

#443 - Abstract

SUPPLEMENTATION WITH VITAMIN E IN ELDERLY PATIENTS WITH CARDIOVASCULAR DISEASE

Eugenia Corina Zorila¹, Liana Mioara Mos¹, Eva Mera²

¹ "V. Goldi" Western University, Arad, Romania

² S.C.Clinical Laboratory SRL, Arad, Romania

Background

It is known that Vitamin E protects cell membranes from damage by oxygen free radicals. Low plasma levels of Vitamin E has been associated with a risk factor of 2.6 times higher of early vascular disease.

Objectives. We studied the effect of supplementation with vitamin E on oxidative stress using markers of lipid peroxidation in a group of elderly people with known cardiovascular disease.

Methods

We studied a group of 33 patients over 65 years with ischemic cardiovascular disease and/or hypertension (Group I) hospitalized in our clinic. We administered 600 mg alpha-tocopherol/day (Vitamin E) for 7 days in capsules. The vascular damage was evaluated using intimal media thickness of the common carotid artery by ultrasonography in lying supine. In order to determine the oxidative stress we have determined Thiobarbituric Acid (TBA)-reactive substances by Satoh method in peripheral venous blood, prior to administration of vitamin E and the after supplementation treatment. We compared this group (Group I), with another group of patients with symptomatic vascular disease (Group II) without nutritional supplementation

Results

Group I characteristics was : hypertension was present in 54.4% of studied patient, myocardial ischemia (angina or equivalents) in 38.5% of cases, aortic valve disease in 6.06%, patients with cardiomegaly and those with left ventricular hypertrophy represented 63.6% of the group I and only 36.4% of patients had normal sized heart. Baseline average level of TBA-reactive substances was similar in the two groups, but was significantly

lower in group I after nutritional supplementation with alpha-tocopherol, 4.54 ± 0.62 nmol/l vs 2.69 ± 0.54 nmol/l ($p < 0.001$).

Conclusion

Vitamin E (Alpha-tocopherol) supplementation in patients with chronic cardiovascular disease, over 65 years, revealed a significant decrease in oxidative stress evaluated by markers of lipid peroxidation, with possible protective effect on endothelial dysfunction

#446 - Abstract

THE INCREASING BURDEN OF AGING ON ADMISSION, HOSPITAL STAY AND TARIFF IN AN ACADEMIC DIVISION OF INTERNAL MEDICINE IN SOUTHERN ITALY

Marina Nuzzo¹, Michela Capurso¹, Anna Belfiore¹, Paolo Buonamico¹, Francesco Minerva¹, Vincenzo Ostilio Palmieri¹, Stefania Pugliese¹, Emilio Molina-Molina¹, Francesco Albergo², Piero Portincasa¹

¹ Clinica Medica "A. Murri", Department of Biomedical Sciences and Human Oncology, University of Bari "Aldo Moro" Medical School, Bari, Italy

² School of Management, Università LUM "Jean Monnet", Bari, Italy

Background

In 2015, subjects older than 65 years in Italy were 21.7% and figures are growing, with enormous burden on national health systems, also worldwide. We describe the impact of aging on the hospitalization profiles and diagnosis-related group (DRG) tariff in an Academic Division of Internal Medicine, in Southern Italy.

Methods

We included data from hospital registry of elective and emergency admissions on three consecutive years (2016-2018) of patients aged 15-100.

Results

Admitted were 2586 patients (1255 F, 1331 M, mean age $69.6 \pm SE 0.3$ yrs. Median 73); 1786 patients (69.1%) aged ≥ 65 . Patients from Emergency Room (ER) were 1924 (74.4%) of total admissions, were older than elective patients (mean age 71.5 ± 0.4 vs. 64.1 ± 0.6 yrs, $P = 0.0000$), had longer hospital stay (9.3 ± 0.2 vs 4.6 ± 0.2 days, $P = 0.0000$) and higher DRG tariff ($\text{€}2,992 \pm 38$ vs $2,594 \pm 73$, $p = 0.0000$). Hospital stay ($r = 0.14$; $P = 0.0000$) and DRG tariff ($r = 0.17$; $P = 0.0000$) increased significantly with age. The impact of aging on hospital stay and DRG tariff was further evaluated on four age groups, i.e., < 65 , 65-74, 75-84 and ≥ 85 yrs (30.9%, 22.6%, 29.7% and 16.7% of total, respectively). A progressive increase at each age group occurred for both mean hospital stay (6.9 ± 0.3 , 7.9 ± 0.3 , 8.9 ± 0.3 , 9.1 ± 0.3 days respectively, $p = 0.0000$) and mean DRG tariff ($\text{€}2525 \pm 70$, 2943 ± 70 , 3111 ± 59 , 3103 ± 67 respectively, $p = 0.0000$).

Conclusion

In an Academic Division of Internal Medicine in Southern Italy opened to ER, geriatric patients account for 69% of total admissions. This population drains major clinical and economic efforts. Geriatric expertise and cost-effective strategies are urgently required to cope with elderly and fragile patients' management.

#460 - Abstract

THREE-MONTH MORTALITY IN PERMANENTLY BEDRIDDEN MEDICAL NON-ONCOLOGIC PATIENTS: THE BECLAP STUDY

Luca Matteucci, Valeria Giosia, Antonio Luca Brucato

University of Milan, Milan, Italy

Background

Nowadays bedridden status is a major problem and it may have a role in increasing mortality among patients hospitalized in medical wards. The aim of BECLAP study (permanently BEDridden, creatinine CLearance, Albumin, Previous hospital admissions study) is to predict the three-months mortality in permanently bedridden medical non-oncologic inpatients.

Methods

2788 consecutive patients admitted in 5 Italian Internal Medicine units from January 2016 through January 2017 were prospectively screened; 644 oncologic patients were excluded; 2144 non-oncologic patients (1021 female) were followed-up for mortality for 6 months. The main outcome was 3-months mortality in permanently bedridden inpatients with at least 2 of creatinine clearance <35 ml/min; albumin <2.5 mg/dl; at least 2 hospital admissions in the previous 6 months. Advanced dementia and dysphagia were also recorded.

Results

Mean age of the 2144 patients was 73.9 (SD, 14.9) years; 374 (17%) were permanently bedridden, 435 (20%) had a creatinine clearance <35 ml/min, 217 (10%) albumin <2.5 mg/dl, 112 (5%) at least 2 hospital admissions in the previous 6 months. Seventy-seven (4%) patients were permanently bedridden with at least 2 of the above-mentioned items, and 48 of them died within 3 months (62%) ($p < 0.001$; 95% CI 51-73%). Regression coefficients of the variables associated with 3-months mortality in multivariate analysis in 998 patients of unit 1 (training cohort) were used to create a simple score, which was validated in the 1146 patients of the other units (validation cohort) and performed well in predicting the 3-months mortality.

Conclusion

Approximately two out of three non-oncologic medical patients permanently bedridden having 2 of the abovementioned items are dead 3 months after index admission; a simple score including bedridden status, creatinine clearance, albumin, dysphagia, age, and sex may help discuss management priorities.

#488 - Abstract

ORAL HEALTH IN THE ELDERLY PATIENT HOSPITALIZED IN AN INTERNAL MEDICINE DEPARTMENT

Fatma Ben Fredj¹, Thabet Maissa¹, Raouaa Belkacem², Omar Marouene², Jihed Anoun¹, Anis Mzabi¹, Monia Karmeni¹, Amel Rezgoui¹, Chadia Laouani¹, Nabiha Douki²

¹ Université de Sousse, Faculté de Médecine de Sousse, Hôpital Sahloul, Service de Médecine Interne, Unité de Recherche de Gériatrie et Gérologie Clinique, Sousse, Tunisia

² Université de Sousse, Hôpital Sahloul, Service de Médecine Dentaire de Sahloul Sousse, Sousse, Tunisia

Background

The aim of this study was to evaluate the oral state of patients aged 65 years or over hospitalized in an internal medicine department.

Methods

This is a prospective study conducted at Sahloul Hospital of Sousse over a period of 1 month (March 2019) including all patients aged 65 or over hospitalized in the Sahloul Internal Medicine Department. A systematic oral examination was performed for all these patients. We examined the periodontal state (presence of tartar, plaque and bleeding index...), the examination of the mucous membranes and a dental examination (CAD index and dental formula...)

Results

Of 27 hospitalized patients, 12 were aged 65 or older. There were 5 men and 7 women (SR=0.7), the mean age of our patients was 71.23 years [65-90].

Six patients had hypertension and four were diabetic, three of whom were on insulin therapy.

The mean MMS score of our patients was 21.02 [14-27]. The evaluation of their mood showed an average score of mini-GDS at 2.4 [1-3]. Mean ANM was 10.7 [7-12]. Eight of our patients were autonomous.

Oral hygiene was inadequate in all our patients. One-third of the patients included never used toothbrushes.

Periodontal examination showed poor hygiene in all patients with at least moderate periodontitis. It was generalized in 9 cases. Mucosal involvement was observed in 3 patients (maculae, whitish and purplish lesions).

The dental examination revealed that eleven patients had at least 3 missing teeth and 7 patients had untreated dental caries.

As for the therapeutic needs, eleven patients had prosthetic needs; five had surgical needs and seven has restoration needs. Whereas, periodontal therapy was indicated for all patients.

Conclusion

The results of this study show that an annual oral examination seems necessary for elderly. The oral health and hygiene of older people is not sufficient and could be improved with oral care education of caregivers and regular professional dental care to elderly.

#607 - Abstract

MULTIMORBIDITY AND OLD AGE - IMPACT OF ILLITERACY AND RESIDENCE IN RURAL AREAS

Josiana Oliveira Duarte, Isabel Taveira, Sofia Sobral, Tiago Fiúza, Rui Seixas, Ana Cláudia Vicente, Adelaide Belo
Hospital do Litoral Alentejano, Santiago Do Cacém, Portugal

Background

Thinking of the constant concerns about the use of the emergency service and avoidable hospitalizations, in January 2017 emerged the Case Management Project. This project included patients with 4 or more episodes of emergency room visits during the previous 365 days or 3 or more admissions in the previous year, with 2 or more comorbidities and 6 or more drugs, with the aim of improving patient and consequently less use of emergency services, reduction of avoidable hospitalizations and health costs. This required greater coordination of care, communication between professionals, interaction with the community and investment in training.

Methods

We present a retrospective study of the population that integrated the Case Management Project in the year 2018, whose main objectives were to assess whether the degree of illiteracy and residence in rural areas would have a statistically significant influence on the use of emergency services before and after integration in the project.

Results

It is a population with 85 patients, 47 men, average age of 78 years, of whom 15 have died. For the purposes of statistical analysis, only patients with 6 months or more of integration into the project (58 patients, min 6 months, max 22 months) were included. Regarding the data prior to integration into the project, using the Mann Whitney test, we concluded that the residence in rural areas is statistically significant for increasing the number of emergency room visits ($p=0.001$). Similarly, regarding illiteracy, we conclude that the level of schooling less than or equal to the 4th class is statistically significant for the increase in the number of emergency room visits ($p=0.013$). After 1 year of the project, we found that the fact of living in rural areas was no longer statistically significant ($p=0.094$) and that the level of education less than or equal to the 4th class remained statistically significant for the increase in the number of visits to the ER ($p=0.012$).

Conclusion

On the basis of these data, we conclude that integration into the project has made patients living in rural areas less likely to go to the emergency department, most likely by moving the case manager/health care to the patient's home. The degree of illiteracy has remained a statistically significant factor, presumably because the ability to understand the recommendations given to these patients may be compromised. This suggests that more training strategies appropriate to the degree of illiteracy are necessary.

#621 - Abstract

EFFECTIVENESS OF THALIDOMIDE IN THE TREATMENT OF RECURRENT GASTROINTESTINAL BLEEDING

Pedro J Maese Rufino, M^a Asunción Navarro Puerto, M^a Isabel Melguizo Moya, José Antonio Mira Escarti
Hospital Virgen de Valme, Internal Medicine, Sevilla, Spain

Background

Patients with recurrent gastrointestinal bleeding (onwards, GI bleeding) are a challenge to treat. According to scientific literature, the main etiology are vascular malformations (angiodysplasias). These lesions are even more frequent in elder and comorbid population (up to 8% of all GI bleeding), often a complex clinical scenario without options of endoscopic neither surgical approach. Thalidomide has demonstrated good results in controlling bleedings, as well as diminishing blood transfusions requirements.

Methods

An observational, retrospective study was developed on patients receiving thalidomide for GI bleeding in our Hospital (period 2008 - 2018). We analyzed bleeding events, blood hemoglobin evolution and transfusion requirements during 6 months of follow-up.

Results

28 patients were included (median age 76, 53% females, high comorbidity according Charlson index) receiving thalidomide for GI bleeding. Most of them (85%) did not present a major GI bleeding during follow-up.

Thalidomide demonstrated a significant reduction in transfusion requirements (81% before - 43% under thalidomide, p value=0.003). An increase in the median hemoglobin level was observed: from 7.35 g/dL at the start of treatment to 11.5 g/dL at 6 months.

Incidence of intolerances reached 25%, without dangerous side-effects.

Conclusion

Thalidomide seems a safe and effective drug for the treatment of recurrent GI bleeding in elderly comorbid patients.

#647 - Abstract

UTILITY OF THE NAURSE SCALE FOR PREDICTING IN-HOSPITAL MORTALITY IN PATIENTS OVER 90 YEARS OLD.

Magdalena Martín Pérez, Rocio Rojas Lorence, Isabel Ríos Holgado
Hospital Punta de Europa, Algeciras, Spain

Background

The current demographic trend reveals that the world population and, in particular, the Spanish population will be growing. This progressive aging implies an increase in people over 90 years of age,

with a worse social, physical and cognitive situation and, therefore, with an increase in the needs and consumption of health resources. In 2014, the results of a simple in-patient mortality prediction rule were published in nonagenarians based on 4 variables collected on admission (NaURSE score) with promising results. The objective is to use this scale in our population over 90 years old to predict in-patient mortality, which may be useful in the patient's first care, determining the need for a more aggressive immediate action or the indication of conservative / palliative measures.

Methods

Cross-sectional retrospective study of the income of patients over 90 years of age in the Internal Medicine Unit during 2018. The variables collected were: sociodemographic (age, sex), sodium concentration (>145 mEq/L), blood urea (>84 mg/dl), respiratory rate (>20 rpm) and the shock index (heart rate/systolic blood pressure >1), which constitute the acronym NaURSE, as well as the total of variables of this scale present in the subgroup of deceased patients.

Results

104 patients were analyzed. Average age was 92.4 years, predominantly women (653%); mortality was 21% and no more variables were found within the subgroup of deceased: 40% had 2 variables, 27% only one and only 4% met the 5 variables studied. The most frequent variable found was urea (> 84mg / dl) at 33.6% followed by respiratory rate (>20 rpm) at 22.1%.

Conclusion

Most studies in the nonagenarian population are descriptive, without predictive mortality scales. The classic prognostic factors (age, comorbidity, dependence) do not seem to be associated with mortality in several studies, which indicates the difficulty to find reproducible predictors in this highly heterogeneous type of population.

In our attempt to validate the NaURSE score, we have not observed that mortality increases as the variables studied are met, which reveals the physical, psychological and social complexity of this population, possibly linked to the sample size of our study. An individualized evaluation of the patient and the clinical judgment of the doctor remain irreplaceable.

#674 - Abstract

MEDITERRANEAN DIET IS INVERSELY RELATED TO ADMISSION DURATION AND MORTALITY IN ELDERLY, HOSPITALIZED PATIENTS: A 2-YEAR PROSPECTIVE STUDY

Christos E Lampropoulos, Maria Konsta, Vicky Dradaki, Irini Dri, Afroditi Roumpou, Ioanna Papaioannou
Argolidos General Hospital, Nafplion, Greece

Background

Mediterranean diet has been associated with lower incidence of cardiovascular disease and cancer. Purpose of our study was

to examine the hypothesis that mediterranean diet may reduce duration of admission in elderly, hospitalized patients and protect against long-term mortality.

Methods

Sample population included 183 patients (91 men, 92 women, mean age 80±8.4). The following data were taken into account in analysis: anthropometric and laboratory data, dietary habits (MedDiet score), patients' nutritional status [Mini Nutritional Assessment (MNA) score], physical activity (International Physical Activity Questionnaires, IPAQ), smoking status, cause and duration of current admission, medical history (co-morbidities, previous admissions). Primary endpoints were mortality (from admission until 2 years afterwards) and duration of admission, compared to national guidelines for closed consolidated medical expenses. Logistic regression and linear regression analysis were performed in order to identify independent predictors for mortality and extended hospitalization respectively.

Results

According to MNA, nutrition was normal in 83/183 (45%) of patients, 47/183 (25%) of them were at risk of malnutrition and the rest 53/183 (30%) were malnourished.

After performing multivariate logistic regression analysis we found that the odds of death decreased 22% per each unit increase of MedDiet score (OR=0.78; 95% CI:0.7-0.86; p<0.0001). Patients with cancer-related admission were 12 times more likely to die, compared to those with infection (OR=12.95% CI:2.4-58, p=0.002).

According to multivariate linear regression analysis, admission duration was inversely related to mediterranean diet, since it was decreased 0.28 days on average for each unit increase of MedDiet score (b:-0.28; 95% CI:-0.4 - -0.15; p<0.0001). Additionally, the duration of current admission increased on average 0.6 days for each previous hospital admission (b:0.6; 95% CI:0.3-0.85; p<0.0001). The admission duration of patients with cancer was on average 5 days higher than the patients who admitted due to infection (b:5; 95% CI:1.6-8.3; p=0.004).

Conclusion

Mediterranean diet adequately protects elderly, hospitalized patients against long-term mortality and reduces the duration of hospitalization.

#676 - Abstract

FULL MINI NUTRITIONAL ASSESSMENT QUESTIONNAIRE AND THE RISK OF MALNUTRITION AND MORTALITY IN ELDERLY, HOSPITALIZED PATIENTS: A 2-YEAR PROSPECTIVE STUDY

Christos E Lampropoulos, Maria Konsta, Irini Dri, Vicky Dradaki, Afroditi Roumpou, Ioanna Papaioannou
Argolidos General Hospital, Nafplion, Greece

Background

Full Mini Nutritional Assessment (MNA) questionnaire is one of the most useful tools in diagnosing malnutrition in hospitalized patients, which is related to increased morbidity and mortality. The purpose of our study was to assess the nutritional status of elderly, hospitalized patients and examine the hypothesis that MNA may predict long-term mortality and extension of hospitalization.

Methods

183 patients (91 men, 92 women, mean age 80 ± 8.4) were included in this prospective study. The following data were taken into account in analysis: anthropometric and laboratory data, physical activity (International Physical Activity Questionnaires, IPAQ), smoking status, dietary habits, cause and duration of current admission, medical history (co-morbidities, previous admissions). Primary endpoints were mortality (from admission until 2 years afterwards) and duration of admission. The latter was compared to national guidelines for closed consolidated medical expenses. Logistic regression and linear regression analysis were performed in order to identify independent predictors for mortality and extended hospitalization respectively.

Results

According to MNA, nutrition was normal in 83/183 (45%) of patients, 47/183 (25%) of them were at risk of malnutrition and the rest 53/183 (30%) were malnourished.

After performing multivariate logistic regression analysis we found that the odds of death decreased 15% per each unit increase of full MNA score (OR=0.85; 95% CI 0.8-0.9; $p < 0.0001$). Patients who admitted due to cancer were 10 times more likely to die, compared to those with infection (OR=10; 95% CI 2.3-48; $p = 0.002$).

As far as admission duration is concerned, according to multivariate linear regression analysis, each unit increase of full MNA, decreased the admission duration on average 0.3 days ($b = -0.3$; 95% CI -0.4 - -0.14; $p < 0.0001$). Patients admitted due to cancer had on average 5 days higher duration of hospitalization, compared to those admitted for infection ($b = 5$; 95% CI 1.6-8.3; $p = 0.004$). Additionally, the duration of current admission increased on average 0.5 days for each previous hospital admission ($b = 0.5$; 95% CI 0.27-0.8; $p < 0.0001$).

Conclusion

Mortality and extension of hospitalization is significantly increased in elderly, malnourished patients. Full MNA score is a useful diagnostic tool of malnutrition.

#700 - Abstract

QUALITY OF LIFE FOR CAREGIVERS OF ELDERLY PATIENTS

Maissa Thabet, Jihed Anoun, Najeh Adaily, Imen Saoud, Monia Karmeni, Fatma Ben Fredj, Amel Rezgui, Chedia Laouani
Université de Sousse, Faculté de Médecine de Sousse, Hôpital Sahloul
Service de Médecine Interne, Unité de Recherche de Gériatrie et Gériologie Clinique, Sousse, Tunisia

Background

With the aging of the population, the number of caregivers caring for the elderly is increasing considerably. These carers are essential partners for a best quality of life (QOL) for elderly in the perspective of a home support. The health status and QOL of these caregivers deserve to be studied.

The aim of this study is to evaluate the QOL of caregivers of non-autonomous elderly people living at home.

Methods

Prospective observational study conducted in the internal medicine department of Sahloul hospital during the month of March 2019. Elderly of over 70 years old hospitalized in the department and their caregivers were included. The QOL was assessed by the Zarit score.

Results

Ten couples of "elderly person-caregiver" were evaluated. The average age of elderly was 79 ± 6 years with 4 men and 6 women. The caregivers were spouses in 4 cases (average age 74 years, 100% women) and children in 6 cases (average age 49 years, 50% women).

Five caregivers lived at the same home of the elderly person and five spent each day between 30 minutes and 1 hour to visit their elderly parent. The average time spent with the elderly parents was more than 10 hours per day for 3 caregivers.

Seven caregivers were married and six had children in charge, two of whom had more than three children. Four caregivers worked full time and reported that taking care of their elderly relative forced them to adapt or reduce their professional activity.

Six caregivers had themselves chronic illnesses and were on long-term treatment, and four reported that caring for elderly relatives disturbed their social and family lifestyle.

The evaluation of the Zarit score in the caregivers showed that 7 caregivers had a score between 21 and 40 and therefore a light load and that three carers had a score between 41 and 60 indicating a moderate load. Any of the caregivers said that caring was a burden.

Conclusion

The QOL of elderly is closely dependent on caregivers and vice versa. Improvement of caregivers' QOL may have a direct impact on the psychotic symptoms of elderly and indirectly on their QOL. This may confirm the need for ongoing family interventions.

#725 - Abstract

THE INFLUENCE OF MALNUTRITION ON ADMISSION DURATION AND MEDICAL EXPENSES IN ELDERLY, HOSPITALIZED PATIENTS

Christos E Lampropoulos, Maria Konsta, Afroditi Roumpou, Vicky Dradaki, Irini Dri, Ioanna Papaioannou
Argolidos General Hospital, Nafplion, Greece

Background

Malnutrition of elderly, hospitalized patients is a poor prognostic factor for survival and admission duration. Many validated scores have been developed to assess patients' physical activity and the risk for malnutrition. Aim of this study is whether malnutrition increases the medical cost due to extended hospitalization.

Methods

183 patients (91 men, 92 women, mean age 80 ± 8.4) participated in the study. The following data were analyzed: anthropometric and laboratory data, dietary habits (MedDiet), nutritional status scores [Mini Nutritional Assessment (MNA) scores (screening, total), Malnutrition Universal Screening Tool (MUST), Short and Simplified Nutritional Assessment Questionnaire (SNAQ)], physical activity (International Physical Activity Questionnaires, IPAQ). The expected duration and financial costs of the admissions as well as the additional ones (due to extended hospitalization) were calculated according to national guidelines for closed consolidated medical expenses. Spearman coefficient was used for correlation between variables and Kruskal-Wallis test for group comparisons. Multivariate regression analysis was applied for independent predictors of extended hospitalization and additional cost.

Results

The additional medical cost per patient was inversely correlated to screening ($r = -0.35$, $p < 0.0001$) and total ($r = -0.4$, $p < 0.0001$) MNA, MedDiet ($r = -0.6$, $p < 0.0001$), IPAQ ($r = -0.4$, $p < 0.0001$), albumin ($r = -0.4$, $p < 0.0001$), Hb ($r = -0.14$, $p = 0.04$) and positively correlated to MUST ($r = 0.4$, $p < 0.0001$) and SNAQ ($r = 0.33$, $p < 0.0001$). The mean cost per patient increased on average 60 (0-300), 480 (180-1380) and 0 (0-450) euros for admissions due to infection, cancer and stroke respectively ($p = 0.008$).

According to multivariate logistic regression analysis, the additional cost per patient decreased on average 25 euros per each unit increase of MedDiet ($b = -24.6$; 95% CI -36, -13; $p < 0.0001$) and 118 euros ($b = -118$; 95% CI -227, -8.7, $p = 0.03$) per each unit increase of albumin.

Concerning admission duration, according to multivariate linear regression analysis, each unit increase of full MNA or MedDiet decreased the duration on average 0.2 days ($b = -0.2$, 95% CI -0.3, -0.04, $p = 0.02$) and 0.22 days ($b = -0.22$, 95% CI -0.4, -0.06, $p = 0.008$) respectively.

Conclusion

Malnutrition and poor physical activity are related to extended hospitalization and increased associated medical expenses. Higher adherence to mediterranean diet and increased serum albumin reduce the financial cost for each patient's admission.

#760 - Abstract

PROGNOSTIC FACTORS FOR MORTALITY AND DURATION OF ADMISSION IN MALNOURISHED HOSPITALIZED, ELDERLY PATIENTS: A 2-YEAR PROSPECTIVE STUDY

Christos E Lampropoulos, Maria Konsta, Vicky Dradaki, Afroditi Roumpou, Irini Dri, Ioanna Papaioannou
Argolidos General Hospital, Nafplion, Greece

Background

Malnutrition in hospitalized patients is related to increased morbidity and mortality. Purpose of our study was to assess nutritional status of hospitalized, elderly patients and detect unfavorable prognostic factors, related to increased mortality and extended duration of admission.

Methods

183 patients (91 men, 92 women, mean age 80 ± 8.4) were included in the study. Nutritional status was assessed by screening and full Mini Nutritional Assessment (MNA), Malnutrition Universal Screening Tool (MUST), short Nutritional Appetite Questionnaire (sNAQ) and mediterranean diet (MedDiet). The following data were incorporated in analysis: anthropometric and laboratory data, physical activity (International Physical Activity Questionnaires, IPAQ), smoking status, cause and duration of admission, medical history (co-morbidities, previous admissions). Primary endpoints were mortality (from admission until 2 years afterwards) and duration of admission, compared to national guidelines for closed consolidated medical expenses. Mann-Whitney two-sample statistics or t-test was used for group comparisons and Spearman or Pearson coefficients for testing correlation between variables.

Results

Normal nutrition was assessed in 84 (46%), 137 (75%) and 136 (74%) of patients, according to MNA, MUST and sNAQ respectively.

Mortality rate was 48% (88/183 patients). These patients had lower BMI (24.5 ± 4 vs 26.3 ± 5 , $p = 0.01$), albumin (3.1 ± 0.7 vs 3.6 ± 0.6 , $p = 0.0001$), screening MNA (8.5 ± 4 vs 11 ± 3 , $p < 0.0001$), full MNA (16.5 ± 6.7 vs 22.4 ± 5 , $p < 0.0001$), MedDiet (26.6 ± 5.7 vs 33.3 ± 5.4 , $p < 0.0001$) and IPAQ [$0(0-16.5)$ vs $390(0-760)$, $p < 0.0001$] compared to remaining one. In contrast, the aforementioned patients had higher MUST [$1(0-3)$ vs $0(0-0)$, $p < 0.0001$] and sNAQ [$1(1-4)$ vs $0(0-1)$, $p < 0.0001$]. These patients had extended hospitalization [$3(0-6)$ vs $0(-2, 1)$ days, $p < 0.0001$].

Duration of admission was inversely related to screening (Spearman $r = -0.32$, $p < 0.0001$) and full MNA (Spearman $r = -$

0.36, $p < 0.0001$), MedDiet (Spearman $r = -0.4$, $p < 0.0001$), IPAQ (Spearman $r = -0.34$, $p < 0.0001$), albumin (Pearson $r = -0.3$, $p < 0.0001$) and Hb (Pearson $r = -0.14$, $p = 0.05$). On the other hand, duration was positively correlated to MUST (Spearman $r = 0.37$, $p < 0.0001$) and sNAQ (Spearman $r = 0.3$, $p < 0.0001$).

Conclusion

A great proportion of elderly, hospitalized patients are malnourished or at risk of malnutrition. All nutritional scores, physical activity and albumin are significantly related to mortality and increased hospitalization.

#781 - Abstract

CHANGES IN HOSPITALIZATION AMONG ELDERLY PATIENTS FROM 2000 TO 2015: A RETROSPECTIVE STUDY USING THE SPANISH NATIONAL HOSPITAL DISCHARGE DATABASE

Sergio Palacios-Fernandez¹, Mario Salcedo¹, Jose Manuel Ramos²

¹ Valencia University, Valencia, Spain

² Miguel Hernandez of Elche University, Alicante, Spain

Background

Elderly patients are an increasing population in developed countries, which involves an augmenting number of admissions to hospitals. The aims of this study are to analyze and compare the demographic characteristics, health outcomes and costs of the population older than 65 admitted to hospitals in Spain in the years 2000 and 2015.

Methods

All patients older than 65 years discharged from Spanish hospitals in the years 2000 and 2015 were analysed using the data from the Minimal Basic Data Set (MBDS) provided by the Spanish Ministry of Health. We retrieved data related to the next variables: number of discharges each year, all cause in-hospital mortality, average stay and average cost in the studied population.

We tabulated the information and computed secondary data such as absolute or relative magnitude of the referred variables in each age group, and the ratio with respect to the total discharged population.

Finally we compared the data between the years 2000 and 2015 and elaborated a table showing the progress.

Results

The number of discharges in older than 64 patients was 1,200,016 in 2000 (37% of total discharges) and 1,721,073 in 2015 (46% of total discharges), which means 124% more discharges in that age group. The gap is much broader if we focus on those older than 84, who were 164,713 in 2000 (5% of total discharges) and 428,217 in 2015 (11% of total discharges), which means 259% more discharges, and an increase of 10% more very old patients each year.

In 2000, in-hospital mortality in patients between 64 and 74 years old was 4.9% and in patients older than 84 was 13.6%. Mortality has maintained stable in the studied years, although the ratio of mortality of patients older than 64 has increased with respect to the total discharged population.

Average stay is longest in the age group between 74 and 84 years old, decreasing in younger and older patients. Compared to 2000, average stay has decreased a 7% in patients older than 64.

Finally, cost is slightly higher in those older than 64 (5295 euros/discharge in 2015) than the average cost (4866 euros/discharge). Nonetheless, cost has decreased around a 10% between 2000 and 2015. The reduction is higher the older is the patient.

Conclusion

The burden of elderly patients in Spanish hospitals is rapidly increasing. However between 2000 and 2015 mortality has stabilized in each age group and cost and average stay have slightly decreased.

#802 - Abstract

RISK FACTORS FOR FALLS IN PATIENTS OF THE GERIATRIC HOSPITAL IN THE RUSSIAN FEDERATION

Anton Naumov, Natalia Khovasova, Viktoriya Moroz

Pirogov Russian National Research Medical University (RNRMU), Moscow, Russia

Background

Aim. To assess the structure and prevalence of risk factors of falls among people over 60 years.

Methods

In the research have been included 125 geriatric patients at the age of 75.66 ± 7.98 years (110 women, 88%) with at least one fall occurred during the last year. A general clinical study, a comprehensive geriatric assessment, as well as an assessment of the risk of falls (Morse scale, a self-assessment scale of falls) have been carried out during the research period.

Results

Before hospitalization in the Geriatric hospital, the program of prevention of falls was not been implemented in these patients. The decline Activities of daily living (IADL) is identified in 57.6%. The high risk of falls was determined in 82.4% of cases according to the self-assessment scale and in 28% of cases according to the Morse scale. The number of falls during the year was 2.42 ± 1.9 , more than 2 falls occurred among 71 people (56.8%). Consequences of falls: non-severe - 84%, severe (fracture - 11.2%, traumatic brain injury - 4.8%). The most common causes of falls are imbalances (64.8%) and unstable gait (36%), the use of mobility aids (35.2%), and diseases of the musculoskeletal system: osteoarthritis (61.6%), foot pathology (7.2%). Moreover, the significant risk factors of falls were polypharmacy (52%), single accommodation (44.8%), fear of

falling (42.4%), cognitive impairment (39.2%), depression (13.6%), incontinence (36%), dizziness (36%), orthostatic hypotension (7.2%). However, the most common factors were visual impairment (70.4%), fall during anamnesis (89.6%) and chronic pain (89.6%). In almost half (44.6%) of cases, chronic pain was constant, and moderate intensity was by (40.5±0.57 according to VAS). By every fourth person, the low back pain, in half of cases in the large joints. 62 patients used NSAIDs, of which 41.9% used it more than 1 time per week, and 17.7% used it daily. In 21 cases (18.75%), chronic pain caused a limitation of physical activity. A decrease in the quality of life was noted by every third patient.

Conclusion

More than a half of the patients had 2 or more episodes of falls during the last year. In 15% of cases, a fall resulted severe consequences. Chronic pain, polypharmacy, fear of falling and cognitive impairment are most common risk factors for falls.

#855 - Abstract

DO OLDER PEOPLE RECOGNIZE THEIR TREATMENTS?

Rezgui Amel, Maïssa Thabet, Najah Adaily, Jihed Anoun, Monia Karmeni, Fatma Ben Fredj, Chedia Laouani

Université de Sousse, Faculté de Médecine de Sousse, Hôpital Sahloul
Service de Médecine Interne, Unité de Recherche de Gériatrie et
Gérontologie Clinique, Sousse, Tunisia

Background

Poly-medication is particularly common in elderly patients because of poly-pathology, which suggests that patients should recognize the different treatments they take.

The objective of this study was to evaluate the recognition of medications by the elderly followed in an internal medicine department.

Methods

This is a cross-sectional observational study conducted in Internal Medicine Department (university Hospital Sahloul) over one-month period (March 2019) and including all patients aged 65 or older who were receiving long-term treatments. Patients were asked about the number of medications taken, the schedule and number of administrations a day, as well as the commercial names of their treatments and its therapeutic effects.

Results

Fifty three patients were included, with 24 men and 29 women (SR=0.8). The average age was 71 [65-92 years]. Twenty nine patients (54%) were hypertensive and 26 (49%) had endocrinopathy. Nineteen patients (35%) were diabetic, four (7%) had hypothyroidism and two had adrenal insufficiency. Dyslipidemia was noted in 15 patients (28%).

There were 42 illiterate patients in our population. No one had cognitive trouble according to MMS score.

The average number of drug therapy taken per day by our patients was 4.6 [1-10]. Thirteen patients (24%) were on oral antidiabetics and twelve (22%) were on insulin therapy with an average of 2 to 3 injections per day. All our patients self-injected insulin. Eight patients (15%) were on acenocoumarol (Sintom *).

Forty-one patients (7%) were autonomous according to the ADL score and eleven patients (20%) reported needing a third person to take their treatments.

Forty-six patients (86%) recognized their drugs only by their color and geometric shape. Thirty-three patients (62%) memorized their treatments by their therapeutic effects. Forty eight patients (90%) were well aware of the number and timing of catches. Seven patients (13%) were able to name their treatments by their trade names. Nineteen patients (35%) have made a mistake when we asked them to show their treatments.

Conclusion

Older people in our population face multiple challenges in recognizing their medications. According the high risk of polymedication in this age group, an appropriate and up-to-date therapeutic education of patients and their entourage seems obligatory.

#950 - Abstract

FACTORS ASSOCIATED WITH 120-DAY SURVIVAL AND RECOVERY OF PRE-FRACTURE FUNCTIONAL MOBILITY AFTER MINIMAL TRAUMA HIP FRACTURE SURGERY IN OLDER PERSONS

Roshan Gunathilake^{1,2}, Susan Mcneil¹

¹ John Hunter Hospital, Newcastle, Australia

² University of Newcastle, Callaghan, Australia

Background

There is scarcity of published data about survival and functional recovery in older persons after hip fracture in the Australian context. The aim of the study was to determine patient factors associated with 120-day survival and walking recovery after orthopaedic surgery for minimal trauma hip fracture in a cohort of older persons presenting to an orthogeriatric service in a major teaching hospital in Australia.

Methods

Demographic and baseline clinical characteristics of 389 consecutive patients were extracted from the local hip fracture registry and electronic medical records. Functional ambulatory status was evaluated using an ordinal scale based on the use of an assistive device. Patients were followed up prospectively and mortality and walking recovery at 120 days after surgery was determined by telephone interviews and by review of electronic health records linked to the New South Wales birth and death registry.

Results

All-cause mortality rate was 20% at 120 days after hip surgery. Only 42% of the survivors had recovered their pre-admission walking ability within 120 days. In the Cox proportional hazards model, advanced age, male gender, living in a residential aged care facility, higher ASA grade and low serum albumin were significantly associated with 120-day mortality. In multivariate logistic regression analysis, age, pre-fracture mobility and ASA grade were significantly associated with 120-day walking recovery.

Conclusion

Minimal trauma hip fracture was associated with high mortality and the majority of patients did not recover pre-fracture mobility. Baseline patient characteristics can predict mortality and loss of walking ability in hip fracture patients receiving orthogeriatric care.

#992 - Abstract

IMPROVEMENT ON THE BARTHEL INDEX AFTER 1 YEAR OF SACUBITRIL-VALSARTAN

Raquel Rodil-Fraile¹, Gregorio Tiberio-Lopez²

¹ Clínica San Miguel, Pamplona, Spain

² Complejo Hospitalario de Navarra, Pamplona, Spain

Background

It has been reported that treatment with sacubitril-valsartan improved the performance of activities of daily living and quality of life compared to enalapril.

With the aim to provide evidences about the variation in the Barthel index after 1 year of treatment with sacubitril-valsartan, we report data about a 1-year observational pros HFrpared to enalapril.

Methods

Observational study. Multimorbidity patients with sintomathic chronic heart failure (CHF) with reduced ejection function in treatment with sacubitril-valsartan follow-up by the Internal Medicine of Complejo Hospitalario de Navarra during 1 year.

For data analysis student t-test for paired samples we were performed. All tests were performed using STATA version 9 (Texas, NC).

Results

We included 46 multimorbidity (3 or more chronic medical conditions: isquemic cardiopathy, diabetes, chronic kidney disease, HF, COPD, dementia) patients with symptomatic heart failure reduced ejection function (HFrEF) (67% males with mean age of 79±7.41 years) in follow-up in the Chronic-Multimorbidity Unit of the Complejo Hospitalario de Navarra in the period from September 2016 to February 2018. The median Charlson comorbidity index was 8 points. Chronic kidney disease was the most common co-morbidity (91%), presenting 64% of patients

with moderate/severe kidney disease. The most common etiology of HFrEF was ischemic (65%). Year follow up, the majority of patients (74%) tolerated the maximum dose of 24/26 mg BID. There is a significant improvement in the Barthel index in our patients after one year of sacubitril-valsartan treatment (77 vs 84 points, p= 0.006, 95%CI -12.34 - -2.24).

Conclusion

Sacubitril-valsartan improve the functionality of patients, measured under the Barthel index, in multimorbidity patients with HFrEF.

#1058 - Case Report

AZITHROMYCIN – A VERY RARE CAUSE OF ACUTE CONFUSIONAL SYNDROME

Alexandra Ávila¹, Vanda Conceição¹, Ricardo Filipe¹, Margarida Rosado², Nuno Vieira¹, Maria José Grade¹, Luisa Arez¹

¹ Serviço de Medicina 3, Unidade Hospitalar de Portimão do Centro Hospitalar Universitário do Algarve, Portimão, Portugal

² Faculdade de Medicina da Universidade de Lisboa, Lisboa, Portugal

Introduction

Drug-induced delirium is a common neuropsychiatric disorder that often affects the elderly people. Antibiotics such as azithromycin are drugs less associated with this disorder, but it can cause it too.

Case description

We present a case of a 72-year-old woman, hypertensive and diabetic, treated with oral antidiabetic and antihypertensive drugs, none of these drugs had been introduced recently. She was referred to the Emergency Room for behavioral changes, altered mental status and aphasia with 12 hours of evolution. On examination, the patient was disoriented in time and space, with global aphasia, decreased strength in the right upper limb and hemianopsia on the right. She had no fever, no respiratory, urinary, or other changes suggestive of infection. Days before admission, the patient had an upper respiratory infection, for which she was given Azithromycin 500 mg/day for 6 days.

The clinical investigation was unrevealing for a definite etiology: blood count, leukogram, ionogram, liver and renal function tests, urine type II, blood cultures, uroculture, viral serologies and research of drugs of abuse, arterial blood gases, were performed without alterations. Images studies: chest x-ray, cranioencephalic computed tomography (CT), cranio-encephalic Angio CT, and cranioencephalic magnetic resonance imaging showed no alterations, as well as electroencephalogram with aspects suggestive of metabolic/drug dysfunction.

With these results, the suspicion of delirium induced by Azithromycin arose, since this had been the only recently initiated medication. At the seventh day after the end of the drug, the patient was totally oriented, without language alterations and without focal neurological deficits. After one month of follow-up the patient was asymptomatic.

Discussion

When compared with other cases described in the literature, the symptoms of this patient had a later onset and resolution, which can be explained by the high half-life of azithromycin (68 hours), as well as by the high plasma levels observed in geriatric patients (30-50%) compared to young adults, which may potentially be a cause of delirium in this population.

#1097 - Abstract

COMPREHENSIVE GERIATRIC ASSESSMENT IN EMERGENCY DEPARTMENT

Isabel Pulido Valente, Carla Nunes, Paulo Boto, Sónia Martins, Manuel Lopes

National School of Public Health, Lisboa, Portugal

Background

Older population increases use Emergency Department (ED) adding 12% to 21% of the total. Studies suggest that even after being observed in the ED, the older persons continue to have unresolved needs. Objective: epidemiological, clinical, functional and social characterization of the older population that goes to a tertiary central hospital emergency department.

Methods

426 questionnaires during their stay in the ED. Inclusion: all patients over 65 admitted to the ED of Lisbon central hospital. Exclusion: not collaborate in the study. Variables: Age, sex, polypharmacy, comorbidities, were applied basic and instrumental evaluation tests, cognitive evaluation, humor, nutrition and social tests. Functional, social, clinical and social scores were constructed. SPSS Statistics software (v. 24). A χ^2 test was performed and a ROC curve model performed.

Results

53.6% women, mean age 79.3 (min-65, max-101) 75 to 84 years. 26.5% live alone. 97.1% take chronic medication, with 6.7 different drug qualities (min-0, Max-19). The average admissions for ED in 2017 were 2.7 admissions / year (Min-0; Max-21). 99.5% had comorbidities (min-1; max-15) had an average of 4.9 comorbidities. 70.6% were discharged. 51.2% of patients were dependent on basic life activities and 75.6% were dependent on instrumental life activities. 62.5% had gait autonomy and 11.5% had ineffective gait. 51.7% depression. 50% dementia and 63% with nutritional changes. 17% illiterate and 55% primary education. 33% social risk. The scores were adverse in 48,6% of social score, 79,6% clinical score, 54,9% of functional score and 83,1% of mental score. The social and clinical score were found to be statistically significant for the probability of admission.

Conclusion

we concluded by an older population with a predominance of polypharmacy, multimorbidity, social needs and complex clinics that, the ED, as it currently stands, is incapable of allowing

effective and timely responses, neither the necessary screening nor the referral of patients.

#1158 - Abstract

POTENTIALLY INAPPROPRIATE MEDICATION IN ELDERS OLDER THAN 75 YEARS OLD

Maria Maia, Adriana Watts Soares, Virginia Visconti, João Espírito Santo, José Lomelino Araújo

Hospital Beatriz Ângelo, Lisboa, Portugal

Background

Ageing of the population is associated with different physiologic processes that lead to the need of adapting prescription of medication. The term “polymedication” emerged to express the abusive use of pharmacological therapy in aged people. More recently, it started to be applied when potentially inappropriate medication (PIM) is being used. PIMs are considered the main responsible for the adverse drug events observed in the older adult. There are different scales and criteria that allow an analyse of the pharmacological therapeutic and identification of the PIM. A list of PIMs was developed and published by Beers and colleagues in the 90's, in the United States of America, and subsequently expanded and revised to be used in hospitalization and ambulatory, in patients older than 65 years old.

Methods

Identification of PIMs in a small sample of patients, using Beers Criteria, in pre-hospitalization medication chart, of patients older than 75 years old, hospitalized in an Internal Medicine Ward.

Results

The sample had 34 patients, 18 with more than 75 years old, of these 72.2% were female; 61.1% were living at home. Barthel index average was 52.7 (median 52). From these sample of patients, 55.5% had 4 or more comorbidities. About the medication, each patient had in average 6.4 drugs prescribed (minimum 0, maximum 12) and 50% of the patients had in their drug chart 7 or more drugs. Applying Beers Criteria, 20.5% of the total medication were PIM, and of these 52.2% were benzodiazepines or antipsychotics.

Conclusion

These small sample reflects the importance of identifying the PIM so we can prevent and predict adverse events, that bring an elevated morbidity and mortality in this population. Concerning the criteria's that were used, adapting these to a European reality urges, so they can be applied in a transversal way. Some European criteria already exist, more studies are required in order to be used and applied or the population.

#1229 - Abstract

USE OF GABAPENTIN IN HOSPITALIZED PATIENTS

André Filipe De Jesus Teixeira, Helena Manso, Marília Fernandes, Inês Rego Figueiredo, Rita Alves, Diogo Drummond Borges, Heidi Gruner, António Panarra

Centro Hospitalar e Universitário Lisboa Central, Lisboa, Portugal

Background

Gabapentin is widely used for the control of neuropathic pain, mainly peripheral diabetic neuropathy and postherpetic neuralgia, but also in epilepsy. Studies suggest benefits for the use in visceral and bone pain and in neuropathic cancer pain in combination with opioids. Its use in medical wards have been increasing due to professional experience, proven efficacy, safety and tolerability. However some adverse effects, addiction and withdrawal have been reported.

Methods

Retrospective evaluation of the electronic records of all patients admitted to an Internal Medicine Unit in a tertiary Hospital in 2018 (January 1st to December 31st) that used gabapentin. Patients were characterized according to gender, age, average length of stay, comorbidities, therapeutic adjuvants and intrahospital mortality. Dose, length of use of gabapentin and indication for prescription were taken into account.

Results

Of the 1338 patients admitted, 41 (3.1%) were on gabapentin with an average age of 68.8 years. 21 (51.2%) were male and the average length of stay was 15.6 days. There was a "de novo" use in 4 (9.8%) patients and chronic use (>1 year) in 30 (73.2%) patients, of which the main indication was diabetes (n=13). Indication for overall prescription was diabetes (18 patients, 43.9%; average HbA1c of 6.9%), neuropathic pain (18 patients), epilepsy (1 patient) and alcohol withdrawal (1 patient). Other found comorbidities, besides diabetes, were depression in 10 (24.4%) patients.

Concerning adjuvants there were mainly benzodiazepines (19 patients, 46.3%) and analgesics including morphine (14 patients, 34.1%); previous pregabalin use was seen in 6 (14.6%) patients. Daily doses varied from 100mg to 1200mg (average was 467.7 mg) with only one patient above 900mg.

Inpatient mortality was 24.2%, slightly lower for chronic users (17.24%) and higher for diabetic patients (28.6%).

Conclusion

In our small sample the average age was lower than in the internal medicine ward (68.9 vs 78.3 years) and female gender was not favored as usual in published studies. Current doses were infra therapeutic (<900 mg) in almost all cases, considering the recommendations available. Average length of stay (15.6 vs 10.8 days) was higher than the internal medicine ward as was inpatient mortality (24.2% vs 8.9%).

There's a need for understanding the usage of infra therapeutic doses and its efficacy in pain management and control.

#1368 - Abstract

DIRECT ANTICOAGULANTS: SAFETY IN THE ELDERLY SUFFERING FROM ATRIAL FIBRILLATION

Gemma Ortiz Llauradó, Esther Llinàs Coronado, Daniel Iglesias Sáenz, Fireli Oblitas Béjar, María Victoria Pardo Ortega

Hospital de Terrassa, Terrassa, Spain

Background

Non-valvular atrial fibrillation (NVAf) is the most common cardiac arrhythmia and its incidence increases with age. Some of these patients have an indication for oral anticoagulant therapy (OA) for the prevention of systemic embolisms. The classic treatment is OA with anti-vitamin K (AVK) (acenocumarol), however in the last years several direct oral anticoagulants (DOAC) have been commercialized. The pivotal studies of DOACs include patients up to 73 y-o without comorbidity. The inclusion criteria are not a representative sample of the patients that are attended in real practice, for this reason, it is difficult to predict the complications that may occur. We want to evaluate the safety of DOACs in elderly patients (EP) with NVAf, compared to AVK in relation to hemorrhagic event, catalogued SACODA by Spanish Ministry of Health and admitted by Ethics Committee

Methods

Observational, retrospective, descriptive study. Inclusion criteria were >75 y/o patients and clinical indication of therapy with either AVK or DOAC (dabigatran, rivaroxaban or apixaban), treated from January 2012 to December 2015, and followed them for at least 2 years. Patients were selected from our data base. Exclusion criteria were mitral stenosis, mechanical prosthetic valves and treatment with other oral anticoagulants, were excluded, as well low molecular weight heparins, stage 5 chronic kidney disease, any other causes of thrombophilia and termination of AO by recovery of atrial rhythm in the last year. We included patients from January 2012 and December 2015, who were followed for at least 2 years.

Results

942 patients (59% male) between 75 and 99 y/o (mean 83,7 ± 4,8 y/o), CHA2DS2VASc and HASBLED mean scores 4.65 ± 1.35 and 2.41 ± 0,9 respectively. Most of them had polypharmacy (87%), cognitive impairment (low 17%, moderate to severe 12%) and a third of the sample had a Charlson comorbidity index >3 points. We registered 181 hemorrhagic events (1% deaths). The multivariable analysis did not show significant statistical differences in bleeding depending on the type of OA nor the basal and clinical characteristics of the patients. The digestive hemorrhage was most frequent (48%). It increases as the kidney disease worsens and it is independent of the basal characteristics of the patients.

Conclusion

Our data suggest that in real-life the bleeding rate in our EP

population has not significant differences in DOAC vs AVK. The stage of renal impairment seems to be strongest than the age as a bleeding factor.

#1379 - Abstract

AGING WITH INTERNAL MEDICINE: PORTRAIT OF A DISTRICT HOSPITAL

Joana Carneiro, Mariana Magalhães, Ana Valada Marques, Joana Louro
Western Hospital Centre, Caldas Da Rainha, Portugal

Background

Population is aging and the number of people living with multiple chronic diseases and frailty syndrome is increasing. While the characteristics of our population are changing, internists have to deal with patients who are old, polymedicated, and have more complex medical, psychiatric and social issues.

Methods

The aim of this study is to characterize the overall health status of elderly patients hospitalized in the Internal Medicine Department. For this, we conducted a retrospective and observational study using medical records of a random sample of 100 patients over 65 years of age who were hospitalized in Internal Medicine Department in 2018. Statistical analysis was made using SPSSstatistic14®.

Results

Our sample consisted of 100 patients with the age of 65 years or older, equally divided by gender. The mean age was 82.8 ± 7.37 years. 51% of the patients had some degree of dependence, 27% were bedridden and 30% had no description of the performance status. Patients had an average number of comorbidities of 4.71 ± 1.98 . 83% were polymedicated (defined as 5 or more drugs), with an average of 7.87 ± 3.65 number of medications per patient. 70% of the patients were medicated with at least one of the drugs included in the "Beer Criteria for Potentially Inappropriate Medication in Older Adults" at the admission. There was no statistically significant difference between the number of the drugs prescribed at discharge comparing with the admission, as well as between the number of patients medicated with drugs included in the Beer list before and after the hospitalization. Of the 22% of patients who died during hospitalization, 73% had a non-resuscitation order, of these, 55% did complementary diagnostic exams and 45% received antibiotics after the non-resuscitation order decision and only 61% of the patients' clinical records mentioned analgesia.

Conclusion

The world is changing and internal medicine is changing with it. The complexity of this older population adds a tremendous challenge to internal medicine not only in the diagnostic and therapeutic approach at hospitalization but also at discharge. Hierarchizing

priorities and valuing the focus of the therapeutic approach implies a profound paradigm shift in internal medicine and it is essential to ensure the best medical care to this population.

#1502 - Abstract

OBESITY IN THE ELDERLY - PROFILE OF THE ELDERLY PATIENTS FOLLOWED IN OBESITY CONSULTATIONS

Telma Alves, Joana Paixão, Leila Cardoso, Leonor Aleluia, Fátima Silva, Pedro Ribeiro
Serviço de Medicina Interna, Centro Hospitalar e Universitário de Coimbra, Coimbra, Portugal

Background

Obesity is a chronic metabolic disease whose global prevalence is estimated to have risen in the elderly population, mainly due to dietary changes and sedentary lifestyles. This fact has negative repercussions in morbidity/mortality, quality of life and comorbidities. Intentional weight loss through dietary reeducation and physical exercise, prevents the occurrence of harmful and irreversible consequences on geriatric population health, namely sarcopenic obesity, decreased bone density and metabolic syndrome.

Methods

Retrospective characterization of patients aged ≥ 65 years who attended obesity appointments between January 2017 and January 2019. The variables considered were: demographic characteristics, provenience, weight variation, body mass index, abdominal perimeter, exercise practice, and pre and post comorbidities.

Results

During this period, 59 patients were observed, of which 67.24% (n=39) were women and 32.76% (n=19) were men, with a mean age of 69 years. Regarding the origin of referrals: 29.31% (n=17) General and Family Medicine; 20.69% (n=12) of Internal Medicine; 18.97% (n=11) of Pneumology; and 29.31% (n=17) of other specialties. Considering weight profile evolution, 8 (13.79%) patients gained weight, 25 (43.10%) lost $>5\%$ and 33 (56.90%) lost $<5\%$. Of the patients with a weight loss superior to 5%, 36% had a decrease in systolic blood pressure (SBP) higher than 10 mmHg. Of the total number of patients, 26% (n=15) experience a reduction of abdominal perimeter $>5\%$ and the majority implemented physical exercise in their daily routines 70.69% (n=41). Concerning comorbidities, 91.38% (n=53) patients presented arterial hypertension, 39.66% (n=23) diabetes mellitus, 74.14% (n=43) dyslipidemia, 63.79% (n=37) osteoarticular disease, 34.48% (n=20) obesity syndrome hypoventilation/obstructive sleep apnea syndrome, and 6.90% (n=4) thyroid pathology.

Conclusion

Increasing levels of obesity may compromise future gains in

life expectancy with the desired quality. Fortunately, our work reveals the growing interest of this pathology among physicians. We concluded that the prevalence of risk factors observed in the studied population is alarming, especially considering that the majority of them is associated with higher all-cause mortality. Therefore, the reduction of the weight profile and abdominal perimeter have a positive impact on the patient's SBP profile and consequently on the metabolic syndrome, independently of the other risk factors that define it.

#1571 - Abstract

CLINICAL CHARACTERISTICS OF MUSCULOSKELETAL DISEASES FALLING PATIENTS OVER 60 YEARS

Anton Naumov¹, Viktoriya Moroz², Natalia Khovasova¹

¹ Department of deases of aging of Pirogov Russian National Research Medical University (RNRMU), Moscow, Russia

² Russian Clinical and Research Center of Gerontology of Pirogov Russian National Research Medical University (RNRMU), Moscow, Russia

Background

To study the prevalence of musculoskeletal diseases falling patients over 60 years

Methods

142 patients of the Moscow geriatric hospital have been examined. In their anamnesis have been diagnosed more than one falls during the previous year. The average age of the patients was 75.52±8.28 (120 women). The average number of falls over the past year was 2.63±2.28. Two or more falls over the past year have been detected among 61.26% patients. The risk of falls according to the Morse scale averaged 42.29±19.6; more than 51 points has been detected by 40.8%. The self-assessment risk scale of falls has shown the high risk among 87.4% of patients.

Results

Osteoarthritis has been diagnosed among 62.7% of patients, low back pain has been detected among 32.4% of patients, and foot pathology only by 2.8%. Among patients with osteoarthritis pain in large joints has been found in 60.7%, pain in small joints over 2.24%. Chronic pain syndrome has been detected among 42.25% of patients. Patients with persistent pain syndrome comprised 20.5%. Patients with chronic pain syndrome had suffered the intensity of pain (VAS) by 56.9±17.82, with intermittent pain - 36.9±25.5. Among patients with chronic pain syndrome, weak pain has been detected only by 23.3%, medium intensity - 63.3%, strong- 13.3%. Among patients with persistent pain: weak - 47.7%, medium intensity -27.3%, strong 6.8%. Over patients with chronic pain syndrome 71.7% used NSAIDs, and in the group of patients with persistent pain only 44.5%. Neuropathy has been estimated by 20% of patients with chronic pain (DN4), and by 14.7% of patients with persistent pain. Moreover, an assessment of depression development risk (PHQ-2) has been carried out:

among 35% of patients with chronic pain syndrome has been detected the risk of depression, and among 24.4% of patients with persistent pain syndrome respectively. Decrease in basic and functional activity (IADL) has been detected by 81.7% of patients with chronic pain and by 68% with persistent pain. Two or more falls occurred among 68.3% of patients with chronic pain and among 59 % with persistent pain.

Conclusion

88.73% of patients who have experienced a fall had musculoskeletal system diseases. More often there are osteoarthritis and low back pain. Every fifth patient with chronic pain syndrome, who has experienced a fall, has a neuropathic component, and 35% have a psychogenic component.

#1715 - Abstract

DEPRESCRIBING IN ADVANCED DEMENTIA AND ITS EFFECT ON SURVIVAL

Marta Briega, Noemi Gilabert, Nicolas Labrador, Jose Virgilio Torres, Enrique De Vega-Ríos, Jose Curbelo, Carmen Suarez Hospital Universitario de La Princesa, Madrid, Spain

Background

The aim of this study is to compare 12-month mortality after discharge in two cohorts of patients with advanced dementia: those in whom a deprescription strategy was undertaken (deprescription group; DG) and those in whom deprescription did not happen (control group; CG).

Methods

Retrospective cohort study of all patients with advanced dementia discharged from the Department of Internal Medicine in a hospital in Madrid, during 2016. A follow-up period of 12 months after discharge was planned. One-year mortality rates was compared between groups. A stratified analysis of 12 month mortality rates, categorizing patients into subgroups depending on the deprescribed medication (statins, antihypertensives, antiosteoporotic, antiplatelet, anticoagulant, antidementia or other cardiovascular prevention drugs), was also performed. Demographic and clinical variables were collected, including sex, age, mortality at 12 months, cause of death and hospital readmission at 3 and 12 months.

Results

133 patients were analyzed with an average age of 89,4 years of which 93 (70%) were women. Deprescription was performed in 73 (55%) cases. Overall 12-month mortality rate was 45%, ranging from 58% in the deprescription group to 41% in the control group (NS). Hospital readmission rates were 11% in the DG and 32% in the CG at 3 and 12 months respectively. The most frequent causes of death on readmission were infectious diseases in 18 cases (33%), stroke in 6 cases (11%), non-cerebral cardiovascular disease in 2 cases (3.7%), VTD in 2 cases (3.7%) and surgical reasons in 2 cases

(3.7%). Cause of death was unknown in 24 cases (44%).

We have not found statistically significant differences in the stratified, subgroup analysis of 12-month mortality rates in patients in whom statins (DG 43% v CG 26% NS), antihypertensives (37% v 44% NS), antiosteoporotic (40% v 55% NS), antiplatelets (52%-36% NS), anticoagulants (33% v 39% NS) nor other cardiovascular prevention drugs were deprescribed (47% v 35% NS). However, a statistically significant survival difference was found in patients who maintained antedementia drugs v those who did not (CG 33% v DG 63%, $p < 0.05$).

Conclusion

Deprescription of several frequent groups of medication in elderly patients with advanced dementia did not result in a statistically significant higher mortality. Infectious diseases were accountable for the most cases of death. Deprescription of anti-dementia drugs was linked to a higher mortality, this finding requires further exploration.

#1939 - Abstract

COMPARISON OF NUTRITIONAL ASSESSMENT SCORES IN DETECTING MALNUTRITION IN ELDERLY, HOSPITALIZED PATIENTS

Christos E Lampropoulos, Maria Konsta, Vicky Dradaki, Irini Dri, Afroditi Roumpou, Ioanna Papaioannou

Department of Internal Medicine, Argolidos General Hospital, Argos, Greece

Background

Malnutrition has been related to increased morbidity and mortality. Purpose of our study was to estimate the utility of various nutritional scores in detecting malnutrition in elderly, hospitalized patients and correlate them with long-term mortality and medical cost of admission.

Methods

Sample population included 183 patients (91 men, 92 women, mean age 80 ± 8.4). Mini Nutritional Assessment (MNA full, screening), Malnutrition Universal Screening Tool (MUST) and Short Nutritional Appetite Questionnaire (SNAQ) were used to estimate the nutritional status. After adjustment for the cause of current admission, a known prognostic factor according to previously applied multivariate models, sensitivity and specificity, positive and negative predictive values and ROC curves were assessed. Primary endpoints were mortality (from admission until 2 years afterwards) as well as the financial cost of current admission, compared to national guidelines for closed consolidated medical expenses.

Results

Concerning mortality, MNA (screening) and SNAQ had similar, low sensitivity (55.7% and 44% respectively) while MNA (full)

and MUST had higher one (65% and 60% respectively). All the questionnaires had relatively high specificity (80-85%). Screening MNA had the best positive predictive value (80%) whereas all questionnaires had similar negative predictive value (66-71%). They all had similar ROC curves (0.74-0.78).

With regard to additional medical cost due to extended hospitalization, all scores (MNA screening and total, MUST, SNAQ) had relatively low sensitivity (65%, 67%, 53% and 72% respectively), positive (70%, 71%, 76% and 67% respectively) and negative predictive value (61%, 62%, 58% and 64% respectively). MUST had higher specificity (79%) compared to the rest (58-67%). ROC curves were similar for all scores (0.68-0.73).

Conclusion

As far as it concerns mortality, screening MNA had higher specificity and positive predictive value than the rest. MUST questionnaire seems more advantageous in predicting additional medical cost because of extended hospitalization, due to its higher specificity.

#1947 - Abstract

EVALUATION OF DRUG-DRUG INTERACTIONS AMONG ELDERLY PEOPLE OF AN INTERNAL MEDICINE WARD: A RETROSPECTIVE STUDY

Mafalda Miranda Baleiras, Cristina Carvalho, Sofia Duque, José Guia, Luís Campos

Hospital São Francisco Xavier, Lisbon, Portugal

Background

Ageing increases multimorbidity, thus pushing drug prescription upwards. Polypharmacy increases the likelihood of drug-drug interactions (DDI). A DDI happens when two or more drugs interact in such a way that either the effectiveness or toxicity of at least one drug is changed. DDI can result in therapeutic failure, adverse drug reactions (ADR) or even death. According to literature, 17% of all preventable ADR in hospitalized patients are caused by DDI.

Methods

This is a retrospective study aiming to assess the DDI prevalence in elderly and describe the most prevalent interactions. It uses a sample of patients over 65 years-old admitted to an internal medicine ward from January to August 2018. Prescriptions at admission were checked. "Medscape Drug Interaction Checker" was used to evaluate and grade the DDI.

Results

The study included 104 patients, with a mean age of 78.5 years. Mean number of drugs prescribed to patients on admission was 8.3. Polypharmacy was identified in 78 cases (75%). A total of 398 DDI were identified, approximately 4 per patient. According to severity classification, 23 (5.8%) were serious DDI, 317

(79.6%) were significant and 58 (14.6%) were minor. 75% of the patients in the study sample had at least one clinically relevant DDI (significant or serious). Central nervous system depression (18.8%), hyperkalaemia (11.8%) and prolongation of QT interval (6.3%) were the most common potential clinical consequences of the identified DDI. Proton pump inhibitors, psychotropic and nonsteroidal anti-inflammatory drugs were the most commonly involved drug substances among the clinically relevant DDI.

Conclusion

Age-related physiologic changes and polypharmacy make elderly people susceptible to ADR from potential DDI. Personalized drug prescribing strategies and close monitoring of patients are keys to achieve optimal therapeutic results. Freely available software solutions on the Internet can help to predict clinically relevant DDI. DDI should be promptly identified in order to prevent adverse outcomes.

#1996 - Case Report

THE USE OF PROVERTINUM, A NON-ACTIVATED PLASMA-DERIVED FACTOR VII TO TREAT A SEVERE GASTRIC HEMORRHAGE OF UNKNOWN AETIOLOGY

Gabriella Oliva, Carolina Bologna, Marina Lugara, Anna Guida, Maria Gabriella Coppola, Pasquale Madonna, Paolo Tirelli, Antonietta De Sena, Nunzia Silvestri, Claudio De Luca, Ernesto Grasso

Asl Napoli 1, Ospedale del Mare, Napoli, Italy

Introduction

The hemorrhagic shock in elderly patients represents a challenge for physicians. Bleeding control is usually achieved by blood products, or by surgery when feasible. However, when bleeding is not managed only by transfusion of red blood cells, platelets or fresh frozen plasma, the use of coagulation factors is necessary.

Case description

An 87-year-old woman was admitted to the Internal medicine ward for dyspnoea, swollen limbs and mild anaemia. She was affected by colon cancer, treated with sub-total hemicolectomy, cryptogenic cirrhosis, chronic kidney disease, atrial fibrillation in direct anticoagulant therapy (rivaroxaban 15 mg/day) and is currently being treated with low-molecular-weight heparin (4000 UI twice daily), previous thyroidectomy for carcinoma, macrocytic anaemia. A colonoscopy was performed, no bleeding sources were identified. During the hospitalization, she presented melena and hemorrhagic shock. Hemoglobin (Hb) values rapidly dropped from 9.1 g/dl to 8 g/dl, coagulation tests were in normal range. Therefore, an esophagogastroduodenoscopy was performed and showed a clot in the stomach, without active bleeding. An abdominal CT scan with contrast and arteriography were performed and did not show an active bleeding source. The patient was transfused with 4 units of concentrated red blood cells, and 4 units of fresh

frozen plasma. The Hb drop continued until 4.4 g. In order to achieve the haemostasis, the patient was treated with 1800 UI of Provertinum, a non-activated Plasma-derived factor VII (posology 30 UI/kg) and transfused with a further unit of concentrated red blood cells. The hemorrhage stopped, blood pressure increased and the Hb rapidly reached the value of 8.5 g/dl and subsequently 9 g/dl (PT 80%, INR 1.10, a.PTT 40 sec). This value remained stable and no further blood transfusion or antihaemorrhagic therapy was needed until the patient was discharged. No thromboembolic complications were observed.

Discussion

Although not included in the European guidelines on the management of major bleeding, the successful use of Provertinum, non-activated plasma-derived factor VII, in this patient with hemorrhagic shock (due to a severe gastric hemorrhage of unknown aetiology), has effectively determined the recovery of the described clinical scenario, allowing the complete stabilization and safe discharge of the patient. Further investigations are needed, but we would recommend the use of Provertinum to control bleeding in this type of patient.

#2040 - Abstract

PRESCRIPTION OF PROTON PUMP INHIBITORS IN AN INTERNAL MEDICINE WARD

Cristina Carvalho Gouveia, Mafalda Miranda Baleiras, Pedro Ferreira, Sofia Duque, Luís Campos

Hospital de São Francisco Xavier, Centro Hospitalar de Lisboa Ocidental, Lisbon, Portugal

Background

The prescription of proton pump inhibitors (PPI) has significantly increased over the last few decades. When PPIs are inappropriately prescribed, they can contribute to polypharmacy and risk of nonadherence, adverse reactions, drug interactions and hospitalization. PPI can also be associated to hypomagnesemia, vitamin B12 deficiency, small intestine bacterial overgrowth and bone fractures. In this study, we aim to identify potential risk factors associated to PPI prescription and to evaluate the adequacy of their prescription in an internal medicine ward.

Methods

Retrospective study of patients admitted to an internal medicine ward between January and February 2017. The population was separated in two groups: group A – patients using PPI and B – patients not using PPI. The appropriateness of PPI prescription was evaluated by reviewing the medical records of the patients in group A.

Results

144 patients were included. 52 of them (36.1%) were using PPI (group A), 46 of which (88.5%) at hospital admission and 52

(100%) at discharge. Omeprazole was the most prescribed drug (55.8%), followed by pantoprazole (28.8%), esomeprazole (9.6%) and lansoprazole (5.8%). In group A, only 30 patients (57.7%) had appropriate indications for PPI prescription and the main one was prophylaxis of gastrointestinal bleeding in high-risk patients. The principal inappropriate indication for PPI prescription was anticoagulation alone. The mean age of patients in group A was 74.8 years-old and in group B 76.4 years-old. Patients in group A had higher Charlson index (5.5 vs B: 4.6 points) and mean number of medications at hospital admission (7.7 vs B: 5.5) and discharge (9.8 vs B: 6.1).

Conclusion

In our study, the prevalence of inappropriate PPI prescription was noteworthy. Polypharmacy and comorbidity (higher Charlson index) seemed to be associated to prescription of PPI, while higher age did not seem to be related to prescription of these medications. Since the overuse of PPI has a negative impact on healthcare costs and may lead to adverse effects, it is essential to regularly re-evaluate the patients by reassessing the need for ongoing PPI use, in order to decrease iatrogenic illness.

#2089 - Abstract

PREDICTING PERIOPERATIVE PERFORMANCE IN COMPLEX PLURIPATHOLOGICAL PATIENTS

Maria Gema Pelayo Garcia

Internal Medicine Service. Hospital Punta Europa, Algeciras, Spain

Background

Due to improvement in surgical and anesthetic procedures, older and more complex patients undergo surgical treatment. Hip fractures account for a significant disease burden in elderly population. The rise of this activity urges to identify these patients with the aim to enhance disease prevention, chronic disease management, and perioperative treatment. For that matter, orthopedic-hospitalist comanagement (OHC) service was established at our hospital to manage hip fracture patients. Our objective was to assess the most prevalent comorbidities and complexity at admission in this population with the aim to develop tailored health-care strategies.

Methods

We retrospectively identified a sample of 111 patients aged ≥ 65 years who underwent surgical repair of hip fractures in our hospital over a year period between January 2017 and December 2017. General data (age range, sex, Charlson Comorbidity Index (CCI), pluripathology and polipharmacy status) were collected from charts of every patient during the hospital stay. The study was approved by the Hospital Research Ethical committee.

Results

Age 65-74 yr: 13 (11.7%); 75-84 yr: 50 (45%); 85-94 yr: 35 (31.5%);

>95 yr: 13 (11.7%). Male accounted for 21.6 %. Pluripathology: 47.7%. The most prevalent conditions were stroke, dementia and motoneuron disease: 40, 5%, cardiovascular disease: 37.8%, moderate to severe chronic renal disease and anemia/malignancy: 20.7%. CCI <5: 26%, 5-9 > 72%, >9: 1.8%. Polipharmacy: 52.25%

Conclusion

Hip fractures are a public health problem worldwide and related to elderly suffering from chronic complex disease. The most important principle in limiting the possibility of perioperative complications is prevention by means of correct identification.

#2167 - Abstract

HOSPITALIZED ELDERLY PATIENTS: CLINICAL CHARACTERISTICS

Margarida Viana Coelho, Rui Marques Osorio, Domingos Sousa, Sergio Antunes Da Silva, Rita Martins Fernandes, Ana Isabel Rodrigues

Internal Medicine Department, Hospital de Faro, Centro Hospitalar Universitário do Algarve, Faro, Portugal

Background

Internal medicine departments of acute care hospitals admit many elderly adults who have particular characteristics, such as severe frailty and an elevated number of comorbidities. Frailty is defined by increased vulnerability, due to a cumulative decline of the homeostatic reserve. It is a problematic expression of population ageing, leading to a state where a stressor, like an acute disease, elevates the risk of adverse events.

Our objectives were to determine the frailty score of hospitalized elderly patients, the number of comorbidities in this population, the length of stay and readmission rates.

Methods

Retrospective study of all patients with 65-years or older, hospitalized in a ward of an internal medicine department of a tertiary-care teaching medical center in Portugal. We have studied electronic medical records from January 1, 2017 through December 31, 2017. For each patient we evaluated demographic characteristics, prior performance status, comorbidities, length of stay and readmission rates.

Results

We included 316 patients with an average age 76,81 years. Frailty score higher or equal to four was present in 67% of the patients. Only 33% had a Frailty score below four. The major causes of hospitalization were respiratory diseases corresponding to 40,4%, followed by circulatory diseases in 37,4% of the cases. The medium number of comorbidities was four per patient, with a predominance of diabetes, hypertension, atrial fibrillation and dyslipidemia. The length of stay was 18 days and there was an 9,8% rate of readmissions in patients with Frailty score above four versus 7,3% in patients with less severe Frailty.

Conclusion

Elderly hospitalized patients in our study had high Frailty scores and an elevated number of comorbidities. Respiratory and circulatory diseases were the most prevalent causes of hospitalization. This population has higher lengths of stay. Recurrent hospitalizations were more frequent in patients with severe Frailty score.

#2188 - Medical Image

A STONE-AGE CONFUSIONAL SYNDROME

Margarida Lopes Madeira, Gonçalo Mendes, Mafalda Figueira, Daniela Félix Brigas, Francisca Santos, Diana Silva, Eugénio Nóbrega Dias, Clara Rosa, Ermelinda Pedroso
Centro Hospitalar de Setúbal, Setúbal, Portugal

Clinical summary

A 82 year-old female patient was admitted to hospital with confusion. Medical history included: chronic kidney disease, renal lithiasis and dementia.

In the Emergency Department, in addition to the confusion, the patient also had cough and expectoration, so she was diagnosed with pneumonia and transferred to the Internal Medicine Service. After 5 days antibiotic therapy the patient presented partial clinical improvement, maintaining the confusional syndrome. Due to the worsening of renal function, the introduction of a urinary catheter was attempted, which was made difficult by the presence of a foreign body: a stone measuring 6x3 cm. Removal the foreign body solved the confusional syndrome.



Figure #2188.



INFECTIOUS DISEASES

#22 - Case Report

CUTANEOUS CRYPTOCOCCOSIS IN A PATIENT WITH HAIRY CELL LEUKEMIA

María Alejandra Pérez Ardila, Juan David Zuluaga, Henry Augusto Millán, Fredy Andrés Luna, Juliana Villa, Iván Enrique Noreña
Fundación Cardioinfantil, Bogotá, Colombia

Introduction

In patients with hematologic neoplasms, one of the complications is invasive fungal infection, which can occur in up to 10.2% of patients, with *Aspergillus* spp. and *Candida* spp. as the main microorganisms isolated. These infections are associated with a 40% mortality. *Cryptococcus* spp. infections may occur less frequently; in patients with hematologic neoplasms infected by this microorganism 45% are non-Hodgkin lymphomas; in this group, 10 cases have been reported in association with hairy cell leukemia.

Case description

We present the case of a 51-year-old man with a diagnosis of hairy cell leukemia who had not started chemotherapy. He presented with febrile neutropenia associated with micronodular lesions on chest tomography as well as parahilar and mediastinal adenopathies. *Mycobacterium tuberculosis* infection was established by a mediastinal lymph node biopsy. In the second phase of the tuberculosis treatment he was referred to the emergency department for a nodular lesion in the thigh which did not improve with antibiotic treatment and progressed to ulceration. Due to the suspicion of fungal infection a biopsy was performed showing structures compatible with *Cryptococcus* spp, the culture was positive for *C. Neoformans*. We did not have this isolation in bronchoalveolar lavage or in studies of cerebrospinal fluid. After receiving antifungal treatment and debridement the lesion improved.

Discussion

This corresponds to the 11 th case reported of *Cryptococcus* spp. infection in a patient with hairy cell leukemia. These patients have a higher risk of compromise in the central nervous system and disseminated forms so early detection is critical for the prognosis.

#25 - Medical Image

FUSARIUM INFECTION IN A PATIENT WITH LEUKEMIA: NOT ALL HYPHAE ARE ASPERGILLUS

María Alejandra Pérez Ardila, Juan David Zuluaga, Henry Augusto Millán, Fredy Andrés Luna Vela, Juliana Villa, Iván Enrique Noreña
Fundación Cardioinfantil, Bogotá, Colombia

Clinical summary

A 46 year old female patient with acute promyelocytic leukemia began chemotherapy with trans retinoic acid and idarubicin; the patient developed febrile neutropenia with erythematous lesions nodular lesions in the arms and legs thighs which were warm and indurated. The skin lesions were biopsied due to suspected disseminated fungal infection. The result of two blood galactomannan measurements was negative, with no microorganisms isolated from blood cultures. Management with amphotericin B was started without observing improvement in the lesions, with persistence of fever. The pathology showed structures compatible with *Fusarium* spp in the skin biopsy. Voriconazole was added to the treatment with which the lesions resolved. Fungal culture in the skin biopsy and blood cultures was negative.

#27 - Case Report

GENERALIZED TETANUS IN A PATIENT IN COLOMBIA: REMINISCENCE OF A FORGOTTEN DISEASE

María Alejandra Pérez Ardila, Juan David Zuluaga, María Valentina Perdomo, Henry Augusto Millán, Fredy Andrés Luna Vela, Ivan Noreña
Fundación Cardioinfantil, Bogotá, Colombia

Introduction

Clostridium tetani is an obligate anaerobic gram-positive microorganism causative of tetanus. Most cases occur in developing countries, the spores reside in the soil and can enter through skin lesions. The vaccine prevents the development of the infection and is found in Colombia's immunization plan. In 2018, 30 cases were confirmed in the country, with a rate of 0.06 per 100,000 inhabitants.

Case description

We present the case of a 39-year-old male patient from a rural area of Colombia who works in agriculture, without reliable data on the vaccination scheme. He consulted for 8 days of evolution with pain in the lower left limb, described as a sensation of weight that impeded gait, associated with paresthesias in this same location. 3 weeks earlier he had presented a wound with a wire in the left thigh. Physical examination showed episodes of contractions in the left thigh, trismus, and sardonic laugh, accompanied by episodes of tachycardia and profuse diaphoresis of short duration. Diagnosis of generalized tetanus was made so metronidazole was started. Alprazolam and magnesium sulfate were used to control the symptoms of dysautonomia and the severity of the spasms. After 2 days of treatment the patient presented progressive improvement of the symptoms until complete resolution.

Discussion

The diagnosis is based on the physical examination, history of immunization and clinical findings since laboratory tests can not confirm or exclude the disease. Mortality can reach 60%, so antibiotic treatment should be started early associated with immunization, wound management and physical therapy.

#28 - Case Report

VIBRIO CHOLERAЕ IN TRANSPLANT PATIENTS: NEW ENEMY IN SIGHT

María Alejandra Pérez Ardila, [Juan David Zuluaga](#), Henry Augusto Millán, Fredy Andres Luna Vela, Ivan Noreña, Juliana Villa
Fundación Cardioinfantil, Bogotá, Colombia

Introduction

Diarrhea in recipients of solid organ transplants has a prevalence of 20-50%, the most common infectious causes are *C. difficile*, norovirus and CMV, other bacterial and protozoal infections are less frequent. We present two cases of infection by *Vibrio cholerae* in transplant patients.

Case description

Case 1

53-year-old male patient with a history of kidney and liver transplant 9 months ago; in ambulatory management with ciclosporin, mycophenolate sodium and prednisolone. He consulted for 1 week of evolution with liquid stools not associated with abdominal pain, without emesis, fever or chills. Filmarray was performed which detected: *Vibrio cholerae*, enterotoxigenic *E. coli* and *Shigella*. He received treatment with ceftriaxone for 7 days and a single dose of doxycycline with resolution of the gastroenteritis symptoms.

Case 2

62 years old female with a history of liver transplantation in 2007, in management with Tacrolimus and prednisolone. She consulted for 2-day diarrhea. In the Filmarray *Vibrio cholerae* was isolated, dicloxacillin was administered in a single dose with resolution of the symptoms.

Discussion

According to the WHO, in 2016, 132 121 cases of *Vibrio cholerae* were reported. In the Americas no cases reported were from Colombia. The reported cases ignite alarms about the sanitation system in the country. Taking into account the possibility of infection by this microorganism, the use of multiplex PCR is recommended as an approach in infectious gastroenteritis in this group of patients, with greater probability of detection of the causative micro-organism with respect to conventional methods (culture, EIA, single PCR).

#30 - Case Report

DISSEMINATED PARACOCIDIOIDOMYCOSIS IN AN IMMUNOCOMPETENT PATIENT

María Alejandra Pérez Ardila, [Juan David Zuluaga](#), Henry Augusto Millán, Fredy Andrés Luna Vela, Juliana Villa, Ivan Noreña
Fundación Cardioinfantil, Bogotá, Colombia

Introduction

Paracoccidioidomycosis is a systemic disease caused by the fungus *Paracoccidioides brasiliensis* and *P. lutzii*, endemic in South America and Central America. The main risk factor is exposure in rural areas, with greater prevalence in farmers and ranchers. In Colombia, the incidence fluctuates between 0.5 -2.2 per 100 000 inhabitants.

Case description

69-year-old male patient, farmer from Bogotá. I have consulted for convulsive episodes, significant weight loss, vomiting and generalized hyperpigmentation. Hyponatremia and hyperkalemia were found. Brain MRI is performed in which focal lesions in the central nervous system are observed. On suspicion of metastatic disease, abdominal CT is performed in search of a primary focus that shows mass in the adrenal glands. Low cortisol levels associated with elevated ACTH were found, consistent with primary adrenal insufficiency. Subsequently, a biopsy of the suprarenal glands and central nervous system is performed, which confirms disseminated paracoccidioidomycosis. Antifungal therapy is started with amphotericin B in the induction phase and itraconazole in maintenance phase and treatment for adrenal insufficiency with prednisolone and fludrocortisone

Discussion

Paracoccidioidomycosis with simultaneous dissemination to the adrenal glands and central nervous system is an unusual presentation of the disease. In the chronic disseminated form, the involvement of the adrenal glands occurs in 40% of the cases, of which only 10% show clinical signs of adrenal insufficiency. The dissemination to the central nervous system has an incidence of 1.2-12.5%. This highlights the importance of making a thorough evaluation to patients this pathology to rule out infection in organs other than lung and mucous membranes.

#49 - Abstract

PERTUSSIS PREVALENCE AMONG ADULT PATIENTS WITH ACUTE COUGH ILLNESS

Ahmet Ilbay¹, Mine Durusu Tanriover¹, Pinar Zarakolu², Ezgi Çaliskan Güzelce¹, Hatice Bolek¹, Serhat Unal²

¹ Department of Internal Medicine, Hacettepe University, Faculty of Medicine, Ankara, Turkey

² Department of Infectious Diseases and Clinical Microbiology, Hacettepe University, Faculty of Medicine, Ankara, Turkey

Background

Pertussis (whooping cough) is a very contagious vaccine preventable disease that continues to persist despite high childhood vaccination rates. Pertussis in adults can be easily overlooked or misdiagnosed especially in acute cases with other probable diagnoses.

Methods

We aimed to determine the prevalence of pertussis in adult patients with acute cough illness. Secondly, we aimed to determine the clinical features of the pertussis cases. Internal Medicine and Pulmonary Medicine inpatient wards and outpatient clinics were screened between March 1 and June 22, 2018. Patients with cough duration between one week and one month were enrolled. Those who were on antibiotics for more than 5 days were excluded. Nasofaringeal swabs were taken from the patients who were eligible and who consented. Polymerase chain reaction (PCR) analyses were done to detect *B. pertussis*, *Bordetella parapertussis*, *Bordetella holmesii* and pertussis toxin genes.

Results

A total of 115 patients were enrolled and swabbed. According to CDC pertussis case definitions, 47.8% of the patients were diagnosed with probable pertussis. *Bordetella pertussis* PCR positivity was detected in four patients. We found the prevalence of pertussis as 3.5% in our cohort. All of the patients with pertussis had a history of paroxysmal cough with a mean duration of 20 days at presentation.

Conclusion

Pertussis continues to be a health problem for adults and may present with acute cough illness. The growing number of adult pertussis cases suggest that vaccination of children is inadequate to prevent pertussis and the concept of 'lifelong vaccination' should be strengthened.

#54 - Case Report

BACTEREMIA CAUSED BY MICROCOCCUS LUTEUS: A CASE REPORT

Diana Katherine Guavita Navarro, Vanessa Barbosa Prieto
University Hospital Mayor Mederi, Bogota, Colombia

Introduction

The *Micrococcus* genus, are gram positive cocci, strictly aerobic, commonly isolated in skin and nasopharynx. Usually they are not

associated to any disease, however they had been found in some literature cases of endocarditis, pneumonia and mostly in infection associated with medical devices.

Case description

We are presenting the case of a 19-year-old patient in a primary glomerulopathy study who performance of the outpatient renal biopsy. He later entered for 1 day of facial edema, fever and arthralgias. The echocardiogram is negative for endocarditis and the ultrasound of the abdomen shows a left inferior perirenal hematoma not susceptible to drainage. Extension studies document positive blood cultures for *Micrococcus luteus*. 14 days of antibiotic therapy with vancomycin are completed with resolution of bacteremia and satisfactory evolution.

Discussion

Bacteremia due to *M. luteus* is an unusual and important event given the antibiotic spectrum that should be used and the association of biomedical materials with the acquisition of the infection. This is the first case in a renal biopsy context, without permanent devices.

#56 - Case Report

NECROTIC PINNA INFECTION IN AN IMMUNOCOMPROMISED, ELDERLY PATIENT SECONDARY TO ASPERGILLUS

Andrew Groff, Chavely Valdés Sánchez, Rama Vunnam, Kaleigh Krill, Jennifer Saigal, Rohit Jain
Hershey Medical Center, Hershey, United States

Introduction

Aspergillus species is an opportunistic fungal infection that primarily affects pulmonary and central nervous system. Cutaneous infection is a rare presentation in an immunosuppressed individual. Prompt diagnosis and treatment is crucial to prevent disseminated infection.

Case description

Patient is a 76-year-old female with a history of rheumatoid arthritis on methotrexate and abatacept, who presented with a two-week history of painful papules and worsening erythema on her left ear despite one-week treatment with antibiotics and topical antifungal. Left ear was tender to palpation, edematous, and erythematous with several black eschars on the root of helix, lateral helix/antihelix, tragus, antitragus and lobule. Initial tissue biopsy showed invasive fungal infection with angioinvasion and surgical pathology revealed extensive necrosis of the skin, subcutaneous tissue, and cartilage angioinvasion. Septate fungal hyphae, most consistent with *Aspergillus* was identified. Tissue culture also grew 4+ *Stenotrophomonas maltophilia* and 2+ *Pseudomonas aeruginosa*. Immunosuppressed medications were held. Patient was treated with voriconazole, levofloxacin, and valacyclovir and wound care. Patient ultimately needed a skin graft from the left supraclavicular fossa.

Discussion

Aspergillosis is the second most common fungal infection, which often affects immunosuppressed individuals. Cutaneous presentation is rare, whereas patients presenting with pulmonary and central nervous system infections are common. Treatment for cutaneous aspergillosis involves voriconazole and surgical debridement to avoid potential disseminated disease, which is associated with high mortality. This case highlights the importance of including rare fungal infections in the differential diagnosis, when evaluating cutaneous infections in immunosuppressed patients.

#57 - Abstract

VASCULAR CATHETER-SITE CARE USING DIFFERENT SKIN ANTISEPTICS FOR PREVENTION OF CATHETER-RELATED BLOOD STREAM INFECTION: A META-ANALYSIS

Martin Kristoffer Elises Ogbac¹, Euodia Padilla Guinmapang², Frederick Elises Ogbac³

¹ C P Reyes Hospital, Tanauan, Philippines

² Perpetual Help Medical Center - Las Pinas, Las Pinas, Philippines

³ Ospital ng Makati, Makati, Philippines

Background

Infections are common complications among end-stage kidney disease (ESRD) patients undergoing hemodialysis (HD). Catheter-related blood stream infection (CRBSI) plays a significant role among ESRD patients.

CRBSI develops from bacterial colonization of the central venous catheter (CVC). Bacteria colonize the CVC with subsequent access to the blood by 3 routes – external surface of CVC through contaminated insertion site; internal surface of CVC through contaminated catheter hubs, injection ports and lines usually by the hands of healthcare workers or patients; contaminated intravenous drugs and nutritional preparations.

Several guidelines are proposed to prevent CRBSI including topical solutions to disinfect the access site. The 2 most commonly used solutions are chlorhexidine and povidone-iodine. This study aims to identify which is more effective in preventing CRBSI.

Methods

Several published randomized controlled trials about the different topical solutions in preventing CRBSI were identified using MEDLINE, COCHRANE, and EMBASE. The studies included were published from 1990 to 2018. The primary outcome was the incidence of catheter colonization and CRBSI.

Results

8 studies were included. 4902 central vascular insertions were identified. Patients enrolled in the chlorhexidine group had a catheter bacterial colonization incidence of 5.17% while those in the povidone-iodine group had 7.9%. Patients in the chlorhexidine

group had a CRBSI incidence of 2.9% while those in the povidone-iodine group had 4.6%.

Conclusion

Chlorhexidine is superior in preventing colonization of central vascular catheters compared to povidone-iodine. It is not clear, however, whether which intervention is more effective in preventing CRBSI as both groups demonstrated almost similar incidence of CRBSI.

#65 - Abstract

MANAGEMENT OF COMMUNITY ACQUIRED PNEUMONIA AT A TERTIARY-CARE TEACHING HOSPITAL

Mukhtar Alomar¹, Aseel Alsuwayegh², Nora Alkhayat², Daad Almuqbel², Ahmed Mayet²

¹ King Fahad Medical City, Riyadh, Saudi Arabia

² King Saud University Medical City, Riyadh, Saudi Arabia

Background

The implementation of community-acquired pneumonia (CAP) guidelines has led to shorten the duration of antibiotic treatment, reduce costs, and improve pneumonia-related morbidity and mortality. The adherence to CAP guidelines is varied in multiple international studies. This study aimed to evaluate the rate of adherence to Infectious Diseases Society of America (IDSA) and the American Thoracic Society (ATS) guidelines 2007 for the diagnosis and treatment of CAP in hospitalized patients and to identify patient-related factors that may have influenced the adherence to treatment guidelines at our tertiary care teaching hospital.

Methods

The patients admitted with CAP; their charts were prospectively reviewed from April 1st until July 31st, 2018. The patients were eligible to participate in the study if they were >18 years of age and admitting diagnosis with CAP. Demographic data, comorbid conditions, smoking history, antibiotic culture and sensitivity, duration of antibiotic therapy, relevant laboratory data, and the diagnostic procedures were retrieved from the medical records. The proportion of patients who were treated according to CAP guidelines were recorded and compared with the most widely referenced guideline; IDSA/ATS for treatment of CAP. Descriptive statistics with frequency, percentages, mean, and standard deviation (SD) were used to illustrate the study results. Odds ratios (OR) of associated factors were also calculated.

Results

During the study period, 138 eligible patients were identified, 51.4% were female, their mean age was 59.1±20 years, and 49.3% had diabetes. Only 8% patients received a single initial empirical antibiotic whereas 92% received combination antibiotics. One hundred twenty-two patients received appropriate initial

empirical therapy on the first day of hospitalization; 9.4% patients received broad-spectrum antibiotics that were not warranted. Eighty-one 58.7% of the patients had a change in antimicrobial regimen during the hospital admission. Overall appropriateness of CAP management based on the composite of initial empirical treatment, duration of treatment, and switching antibiotics according to culture and sensitivity during the admission period was 58.0%; Severe respiratory illness was the most significant independent risk factor.

Conclusion

The study shows adherence to CAP guidelines for an initial empirical therapy on the first day of hospitalization was optimal whereas overall adherence to CAP management throughout the hospital stay was low.

#66 - Abstract

A CASE SERIES OF WEST NILE VIRUS NEUROINVASIVE DISEASE IN A TERTIARY CARE HOSPITAL IN ITALY IN 2018

Lorenzo Maria Canziani, Guendalina De Nadai, Federica Maria Pilar Tordato, Daria Pocaterra, Maddalena Casana, Paola Morelli
Istituto Clinico Humanitas, Milano, Italy

Background

In 2018, 2083 West Nile virus (WNV) infections have been reported in Europe.

Methods

In 2018, we diagnosed 4 cases of WNV neuroinvasive disease between week 33 and 36.

Case Description

Case 1

A 74-year-old man, known for epilepsy and cirrhosis, developed fever and seizures on week 33. On day 4 of hospitalization, the patient presented acute vision loss. WNV-IgM was positive on serum and CSF, WNV-RNA was present on CSF. Few days after, the patient was comatose and transferred in ICU. The patient acquired a multidrug-resistant *A. baumannii* skin colonization. The patient's mental status slowly improved, and he was rapidly discharged thereafter. The neurological sequelae at discharge included blindness (0.2/10 bilateral), left motor hemisindrome and postural instability with gait disturbances.

Case 2

A 80-year-old man presented with fever and stupor during week 34. He was known for gastric DLBCL on treatment with R-CHOP, ischemic cardiopathy, previous aortic valve substitution, and chronic HCV infection. The CSF appearance was typical for viral meningitis. A cerebral MRI revealed bilateral thalamic lesions, with hyperintensity on FLAIR. WNV-RNA was present only on serum, and WNV-IgM was negative. The patient died after few days.

Case 3

A 73-year-old man presented with fever, asthenia, diffuse aches, confusion, and hearing loss during week 36. He was known for diabetes mellitus, ischemic cardiopathy, hypertension, COPD, previous aortic valve substitution, past duodenal ulcer, chronic HCV infection. WNV-RNA was present on urine, WNV-IgM was present in serum and CSF. The mental status improved over days. One month after discharge, the patient reported persistent hearing loss and gait disturbances.

Case 4

During week 36, a 77-year-old otherwise healthy man was admitted because of persistent fever, lethargy and stupor. WNV-IgM was positive on serum and liquor. The mental status improved over days. At discharge, the patient presented gait disturbances that resolved within 3 months.

Conclusion

Between week 33 and 36 of 2018, we diagnosed 4 cases of WNV neuroinvasive disease. All patients were male, elderly, and reported multiple insect bites; significant comorbidities were present. Common traits were sudden onset of high-grade fever and stupor. One patient died, two of them partially recovered with notable disabilities, and one patient recovered completely. Our experience suggests that, as WNV disease incidence grows and the European population ages, more frail people will suffer from WNV neuroinvasive disease.

#76 - Abstract

DETERMINING THE NEUROCOGNITIVE STATUS AND THE FUNCTIONAL ABILITY OF PATIENTS TO SCREEN FOR HIV-ASSOCIATED NEUROCOGNITIVE DISORDER (HAND)

Ritika Agarwal, Ravinder Singh Aujla, Amit Gupta, Mukesh Kumar Agarwal

Chandra Laxmi Hospital, Ghaziabad, India

Background

To adequately evaluate the extent of neurocognitive impairment, a battery of neuropsychological tests is typically administered which are neither cost effective nor time efficient in the outpatient clinical setting as they often require several hours to complete and can be labor intensive requiring additional trained personnel to administer and correctly score. The aim of the study was to find a brief screening tool to identify those who would benefit from a full diagnostic evaluation.

Methods

The study enrolled 160 patients living with HIV (PLHIV) (80 pre-ART and 80 On-ART) fulfilling the inclusion and exclusion criteria. Neurocognitive assessment and an assessment of Functional ability was done by using the Montreal Cognitive Assessment (MoCA) and Lawton and Brody IADL Scale respectively.

Results

The study population consisted of 75.6% males and 24.4% females with mean age of 44±10 years. All of the subjects were literate (61.2% subjects had received up to high school level education), 76.2% were married. The mean duration of HIV infection among ART naive PLHIV and those on ART was 2±1.33 years and 3±2.10 years respectively. The mean CD4 count of the study population at study enrolment was 361.46±187.28 cells/mm³ (range 34 - 844 cells/mm³). Only 5% of subjects were found to have mild impairment in ADL with the most common affected domain being food preparation (50%). The overall prevalence of HAND in the study subjects was 52.5%. Of these, 47.5% had ANI and 5% had MND. In MoCA, the most frequently affected domains were Language (97.6%), visuospatial ability (92.9%) and memory (71.4%).

Conclusion

The prevalence of HAND is one in two PLHIV have neurocognitive dysfunction. The prevalence of HAND among Pre-ART subjects (i.e. ART naive) and those on ART is similar suggesting that neurocognitive impairment starts early in HIV infection. Older age (>40 years) and fewer years of formal education were important determinants statistically associated with the presence of HAND. HAND involves both cortical and subcortical regions of the brain with subcortical involvement being predominant. The most frequently affected neurocognitive domains were Language, Visuospatial function and Memory. Memory and Visuospatial function impairment had the most predictive potential for detecting the presence of HAND. HAND screening is recommended in all PLHIV at enrolment into care. Simple tools like MoCA can be used in busy outpatient settings by healthcare workers to screen for HAND.

#79 - Case Report

WEIL SYNDROME - A CASE REPORT

Ana Beatriz Amaral, Pedro Duarte, Cláudia Rodrigues, Luís Dias
Hospital do Divino Espírito Santo de Ponta Delgada, Ponta Delgada,
Portugal

Introduction

Leptospirosis is a zoonosis caused by bacteria of the genus *Leptospira*. Clinically, it is very heterogeneous, varying from asymptomatic cases to severe and fatal forms.

Case description

A 22-year-old male farmer, went to the emergency department for a clinical presentation after 5 days with fever, associated with holocranial headache, myalgias, and dry cough with haemoptysis. On examination he was conscious, eupnoic, hypotensive and tachycardic, without other signs of relief. Chest X-ray without changes. Blood analysis with leukocytosis (12.89x10³/μL) with neutrophilia, thrombocytopenia (98x10³/μL) and CRP of 14 mg/dL. Blood samples for culture were taken and the patient was

medicated with ceftriaxone. Genetic investigation of leptospira, later confirmed the diagnosis. In a few hours there was clinical and laboratorial aggravation, with abundant haemoptysis, hemodynamic instability and respiratory difficulty. Chest x-ray showed bilateral cotton infiltrate. The patient was admitted to the Intensive Care Unit (ICU) in need of invasive mechanical ventilation, with the diagnosis of leptospirosis with septic shock and alveolar haemorrhage, requiring a blood transfusion. During ICU stay, jaundice, worsening of liver function and acute renal injury were observed. Transferred to the Internal Medicine ward after 6 days of hospitalization at the ICU. After three more days and clinical improvement, he was discharged and sent home.

Discussion

Weil Syndrome represents the most serious clinical manifestation of Leptospirosis, occurring in about 5-10% of patients. It is characterized by the appearance of jaundice, acute renal failure and haemorrhagic diathesis. The diagnosis of Leptospirosis often implies a high degree of suspicion and it is important to initiate treatment early.

#83 - Case Report

ANGIOINVASIVE ASPERGILLOSIS CONFINED TO THE GASTROINTESTINAL TRACT WITH NEGATIVE GALACTOMANNANS DURING CYTARABINE TREATMENT

Julian Alberto Naranjo¹, Iván Noreña¹, Maria Cynthia Fuentes Lacouture¹, Joaquín Guerra²

¹ Fundación Cardioinfantil, Bogotá D.c, Colombia

² Fundación Cardioinfantil, Bogotá D.c, Colombia

Introduction

Angioinvasive aspergillosis in patients with febrile neutropenia is frequent. We present the case of a patient with acute myeloid leukemia (AML) who develops invasive aspergillosis confined to the gastrointestinal tract without pulmonary primary infection.

Case description

A 50-year-old patient is diagnosed with non-M3 AML. During treatment, he develops febrile neutropenia, treated with antibiotics. Because of persistent fever despite treatment, galactomannans, serum cultures and bronchoalveolar lavage were performed, which were all negative. On day 20 of chemotherapy with cytarabine and idarubicin, patient manifests abdominal pain and bloody diarrhea. Abdominal CT reveals concentric thickening of sigmoid colon, suggestive of ischemic colitis, and he is taken to surgical resection. On fifth day post-surgery, he develops bloody stools and changes in color of colostomy mucosa. On second surgery 3 wall perforations were found, intestinal pathology showed invasive aspergillosis on colonic walls. Treatment with voriconazole was given for 4 weeks, with adequate clinical and paraclinical evolution until now.

Discussion

Angioinvasive aspergillosis is a well-known complication among patients with febrile neutropenia. Nevertheless, gastrointestinal tract aspergillosis is still infrequent, and manifests usually as a dissemination from a primary pulmonary source, rarely being described as an isolated organ infection. It has also been linked to a possible mucosal damage secondary to cytarabine treatment. Opportune diagnosis is required to avoid complications and death.

#87 - Medical Image

A CASE OF INFLUENZA AND INVASIVE ASPERGILLOSIS IN A STEROID-TREATED PATIENT

Lorenzo Maria Canziani, Francesca Colapietro, Niccolò Stomeo, Luca Careno, Alberto Malesci, Maurizio Cecconi
Istituto Clinico Humanitas, Milano, Italy

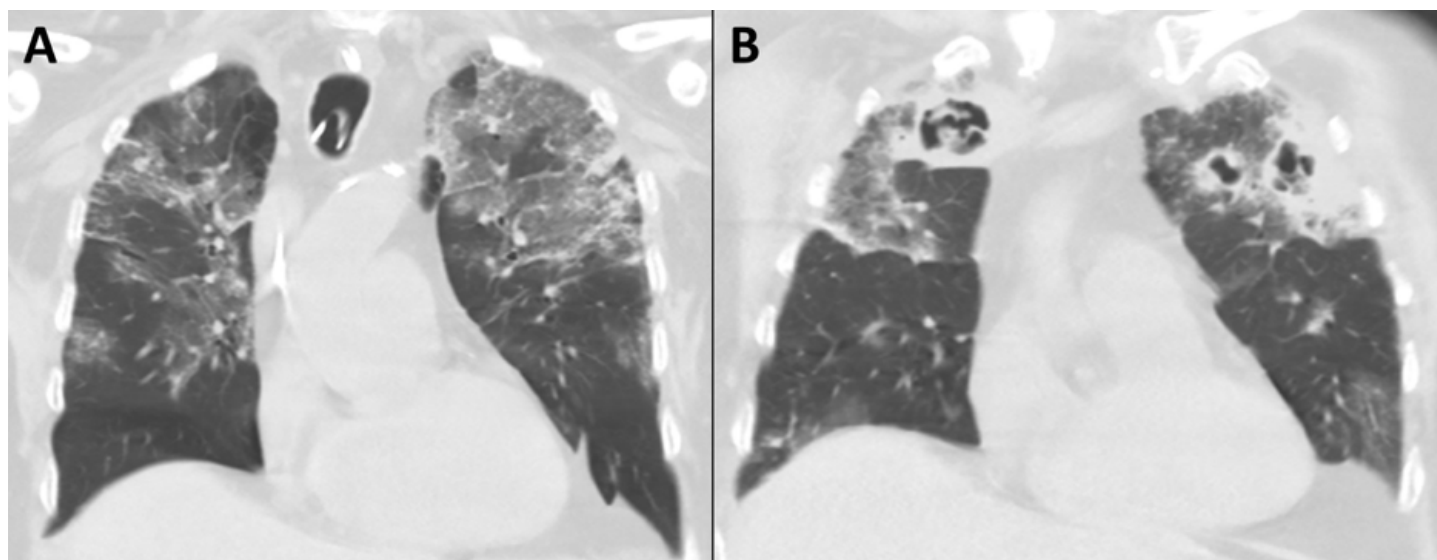


Figure #87. Panel A: Thorax CT scan at day 1 of hospitalization, with bilateral diffuse consolidation and ground-glass pattern, due to Influenza A. Chronic bullous emphysema with bronchiectasis are also present. Panel B: Thorax CT scan at day 22 of hospitalization: the ground glass opacities are reduced, but new excavated lesions with crescents were present bilaterally. Later, invasive aspergillosis is confirmed.

#120 - Case Report

ENDOBONCHIAL TUBERCULOSIS, A RARE MANIFESTATION OF TUBERCULOSIS

Ivo Cunha, Ricardo Pereira
Hospital Pedro Hispano, Matosinhos, Portugal

Introduction

Endobronchial tuberculosis (ET) is a rare manifestation of tuberculosis. The evolution and prognosis are varied from complete resolution to the formation of severe bronchial stenoses. The exact incidence of ET is not known, because bronchofibroscopy (BFC) is not performed in most cases of tuberculosis. BFC is the most important method in the early diagnosis of ET through the histological and microbiological study of biopsied material and to exclude local complications and other pathologies.

Clinical summary

A 61-year-old man presented to the ED with fever and dyspnea. His medical history included COPD and past spine surgery. For persistent back pain he received high dose steroids. Influenza A was rapidly diagnosed. The patient was not vaccinated and had a sick contact. A CT was compatible with secondary ARDS (Panel A). Despite two weeks of proper treatment, respiratory failure persisted. A CT showed multiple new excavated lesions with crescents (Panel B). Invasive aspergillosis was confirmed by Galactomannane positivity on serum. After 50 days, patient died of acute respiratory hemorrhage. Steroid use is associated with influenza and aspergillosis. Preventive measures as influenza vaccination for patients and households may help reducing complications and curbing hospitalization costs.

Case description

We report the case of a 78-year-old man with chronic obstructive pulmonary disease. He presented with 6 months of evolution of mucopurulent cough, asthenia, nocturnal hypersudoresis and weight loss of 18 kg. In this time interval he performed antibiotic therapy with temporary clinical improvement. Mycobacteria in sputum was negative. Tomography showed bronchiectasis in the right lower lobe. Analytically, only with a VS of 55 mm/1h and PCR of 47 mg/dL. Mantoux test with 20 mm induration. BFC showed a 3 cm polyp on the right main bronchus with no further changes. Histologically there was no evidence of malignancy and a lymphoplasmacytic inflammatory infiltrate without granulomas was observed. BAAR research was positive. Microbiological study of the bronchial lavage was negative. Koch bacillus by PCR was negative. Due to the degradation of the clinical status of the

patient, the presumptive diagnosis of ET was assumed and the initiation of antibiotic therapy was carried out, with a progressive improvement of the clinical status and resolution of complaints, supporting the definitive diagnosis of ET.

Discussion

In this case, the pedicled lesion manifested with cough and bronchorrhea. The location in the main right bronchus is the place most frequently involved. Bronchiectasis in the right lower lobe, ipsilateral to the pedicled lesion, is one of the reported complications of ET. BFC played a key role. In spite of the microbiological examinations of the bronchial lavage samples that this technique allowed to obtain, they did not allow the isolation of the BK, the performed biopsy was fundamental to exclude a malignant lesion and to obtain a sample where the study of BAAR by the ZN technique was positive. This last finding, plus the lymphoplasmacytic infiltrate, the constitutional syndrome and the evidence of previous contact with the Koch bacillus, ended up providing a presumptive diagnosis of TE. Tuberculosis should be considered in the differential diagnosis of endobronchial masses.

#123 - Case Report

LARGE CELL PNEUMONIA IN A IMMUNOCOMPETENT ADULT

Nuno Vieira E Brito, Ricardo Taborda, Paula Alcantara
Centro Hospitalar de Lisboa Norte, Lisboa, Portugal

Introduction

Parainfluenza virus infections are a season condition that mainly affect children with a benign course. Reinfection can occur through life causing complications in the elderly and in immunosuppressed individuals. Pneumonia due to parainfluenza 3 (HPIV3) is rare in adults with mostly severely immunosuppressed individuals afflicted

Case description

A 55 years old female with type 1 diabetes since 36, complicated multiple episodes of ketoacidosis was brought to the emergency department for nausea, vomiting and liquid diarrhoea with one week of duration progressing to altered mental status and ketoacidosis. She had no respiratory complaints or fever. She was polypneic, hypotensive, a pH of 6.9, ketonemia of 6.5 and blood sugar of 486. She had 96% saturation on ambient air. Blood work showed a leucocytosis (19,800 with 85.3% neutrophils), haemoconcentration, negative C reactive protein, chest x ray showed diffuse interstitial infiltrate with an exudative characteristic. During the following 3 days the patients condition progressed to Acute Respiratory Distress Syndrome. Blood cultures, serology and urinary test where negative for bacterial agents or atypical pneumonia agents. Autoimmunity was negative. She was transferred to the intensive care unit at day 3 of admission due to a need for non-invasive ventilation with 100% oxygen and underwent bronchoscopy showing thick secretions with bronchial

lavage with an inconclusive cytological study due to thickness and chest CT with diffuse alterations of the lung parenchyma, ground glass opacifications and crazy paving with spared zones. A second lavage showed the giant cells with foreign body aspect and a low cell count for immunotyping. Microbiology of the lavage was positive for HPIV3 in the respiratory virus screening. The patient evolved favourably with support therapy with no further need for non invasive ventilation and returned to the ward at day 10 and was discharged at day 17 undergoing respiratory therap

Discussion

HPIV3 Pneumonia is rare in immunocompetent adults. It has been described in immunosuppressed individuals and children with born immune deficiencies the mortality of large cell pneumonia induced by this virus is up to 40% and in some cases associated with a alveolar proteinosis, hypothesis that was raised in this patient by the thick lavage fluid and crazy paving. may occur related to duration and degree of hyperglycaemia as well as periods of ketosis causing alterations of lung surfactant as well as neutrophil defences.

#157 - Case Report

AUSTRIAN SYNDROME – A RARE CASE REPORT

Ana Sacchetti Corte-Real, Patrícia Vasconcelos, Daniela Madeira, Inês Bargiela
Hospital Prof. Doutor Fernando Fonseca, Amadora, Portugal

Introduction

Austrian Syndrome (AS) is the rare combination of meningitis, endocarditis and pneumonia, due to infection by Streptococcus pneumoniae (SP) and it's associated with a high death rate.

Case description

We report a 78-year-old diabetic, chronic alcoholic man who was admitted to our hospital because of 3-day history of fever and dyspnea. Physical examination revealed a GCS of 12, neck rigidity, hypotension, polypnea, fever and rales above left lower lob. Blood tests revealed leukocytosis and blood cultures were obtained. A chest x-ray revealed left consolidation, a brain CT scan was unremarkable, and cerebrospinal fluid (CSF) analysis was compatible with bacterial meningitis; Gram staining was positive. We started antibiotherapy (AB) with ceftriaxone. On the third day of hospitalization the patient developed a systolic cardiac murmur in auscultation. The echocardiography revealed aortic endocarditis. The blood and CSF cultures revealed multisensitive SP. We changed the AB to penicillin G and the patient was discharged after 6 weeks of this treatment. Vaccination for SP and alcohol abstinence was recommended.

Discussion

The predominant clinical presentation of SA is acute, with a rapid and aggressive clinical course. Alcohol consumption and

advanced age are major risk factors and the aortic valve (AoV) is predominantly affected, accordingly to our case. Pneumococcal endocarditis has become a rare disease since the introduction of penicillin but a large number of cases have been recently reported. We aim to emphasize that early diagnosis is essential for a prompt treatment and better prognosis. So, a high index of clinical suspicion is warranted.

#180 - Abstract

MULTI-RESISTANT MICROORGANISMS: CLINICAL AND EPIDEMIOLOGICAL CHARACTERISTICS OF INFECTIONS IN A DISTRICT HOSPITAL

Isabel Moreno Lucente, Vanesa Muñoz Mendoza, Francisco Javier Ramos Germán

Hospital Obispo Polanco, Teruel, Spain

Background

The indiscriminate global consumption of antibiotics has generated multiresistant microorganisms (MRM) in recent times. The infections produced by these germs are associated with an increase in mortality, as a consequence of the limitations in its treatment. The objective of this study is to know the clinical and epidemiological characteristics of patients infected or colonized by MRM.

Methods

The present is a descriptive, retrospective study based on the review of medical records. The histories were selected from the database of the Microbiology service, in relation to all MRM isolations between January 1st and December 31th, 2017.

The main MRM isolates were: *Escherichia coli*, *Klebsiella pneumoniae*, *Proteus mirabilis*, *Morganella morganii*, *Enterobacter cloacae*, *Pseudomonas aeruginosa* and *Staphylococcus aureus*. The main mechanisms of resistance observed were: beta-lactamases of extended spectrum (BLEE) production, beta-lactamases AmpC type production, carbapenemases production and resistance to methicillin.

Results

During the study period, 127 isolates of MRM belonging to 93 patients were detected. The average age was 72.7 years. In the 76.7% of the cases the isolates took place in elderly patients (over 70 years). The microorganism found most frequently was methicillin-resistant *S. aureus* (39.4% of cases), followed by *E. coli* BLEE (39.4%). Regarding the place of isolation, 28.6% occurred in the Internal Medicine and 26% in the Intensive Care Unit. As for the antimicrobial treatment, in 60.7% it was adjusted according to the isolated germ and the results of the antibiogram; in the remaining 24.4% the antibiotic regimen was not modified. The most frequently observed risk factors were: Diabetes Mellitus (34%), Chronic Kidney Disease (16%), institutionalization (16%), neoplasia (14.2%) and immunosuppression (12%).

Conclusion

In the health area of Teruel, MRM isolates are more frequent in the elderly population, probably related to comorbidity and previous hospitalizations. The main risk factors for the development of MRM infections were the existence of Diabetes Mellitus, Chronic Kidney Disease and institutionalization. The most frequently found MRM is methicillin-resistant *S. aureus*, followed by *E. coli* BLEE. Suboptimal prevention measures may encourage the dispersion of these MMRs, and improvement is imperative.

#190 - Case Report

EPIDURAL ABSCESS AS A COMPLICATION OF ACUTE OTITIS MEDIA

Vanesa Muñoz Mendoza¹, Isabel Moreno Lucente¹, Bianca Ridaura Aparisi²

¹ Obispo Polanco Hospital, Teruel, Spain

² Sagunto Hospital, Valencia, Spain

Introduction

Intracranial complications of acute otitis media (AOM) are unusual with an incidence of 0.36%, but potentially serious, with a high mortality rate. These complications occur frequently in children and young adults.

Case description

We report a case of a 21-year-old male with no history of previous disease.

He reported right otalgia in the last week, he was diagnosed of acute otitis media by his general practitioner and started antibiotic treatment with amoxicillin/clavulanate. In the last two days the patient refers severe holocranial headache and fever. He came to the emergency room, and in the physical examination was observed a bulge and translucent tympanic membrane and unilateral temporary hemianopsia. A cranial CT was performed and was found an epidural abscess in temporal lobe and right mastoiditis. It was initiated broad spectrum antibiotics (ceftriaxone- vancomycin and metronidazole) and was performed an eardrum perforation and drainage. A surgical intervention was performed with drainage of the abscess, but it was incidentally discovered a cholesteatoma.

Post-op period was positive, and antibiotics was progressively de-escalated, but some long-term damages persisted as hearing impairment.

Discussion

Epidural abscesses resulting from acute or chronic ear infections present most commonly as headache that is occasionally relieved by profuse otorrhea. Treatment requires surgical drainage after identification of the abscess on MRI or CT imaging, in addition to intravenous antibiotics.

Underlying cholesteatoma is common and is usually associated with intracranial abscess or sinus thrombosis.

#193 - Case Report

HUMAN IMMUNODEFICIENCY VIRUS PRIMAINFECTION – AN ATYPICAL PRESENTATION IN ADULT

Daniela Casanova, David Paiva, Ana Luisa Campos, Isabel Trindade, Jorge Cotter

Hospital Senhora da Oliveira, Guimarães, Portugal

Introduction

The human immunodeficiency virus (HIV) has a wide spectrum of clinical manifestations, it can present as a mononucleose-like syndrome. Given such unspecific symptoms, if the level of suspicion isn't high enough, the diagnosis may pass unknown. About 10-60% of the patients are asymptomatic during primoinfection. The remaining usually became symptomatic 2 to 4 weeks after exposition. With constitutional symptoms and lymphadenopathies being the most common manifestations, usually at the second week of disease, corresponding to the specific immune response to HIV.

Case description

A 50-year-old man, smoker of about 30 pack-year. Without other relevant clinical history. Admitted on the emergency department with cervical, axillary and inguinal lymphadenopathies detected in the previous 3 weeks. Associated with marked hypoacusia, with sudden onset, and weight loss. Blood analysis showed lymphocytosis and monocytosis. It was performed a computed tomography (CT) thoraco-abdominopelvic that showed multiple unspecific lymphadenopathies. From the virologic study performed positivity to type 1 HIV. Given the hypoacusia we performed a Cranial CT that described "extensive content with soft tissue density in the tympanic and mastoid cells, suggesting bilateral otitis media". Submitted to nasolaryngoscopy with observation of diffuse lymphoid tissue hypertrophy at the level of the pharyngeal cavum and dysfunction of the eustachian tube, compatible with bilateral effusive otitis media. It was initiated empiric antibiotherapy with amoxicillin/clavulanic acid, with gradual audition improvement. The patient had clinical discharge, referred to Infectious diseases evaluation in order to start antiretroviral therapy.

Discussion

In this case we have an atypical presentation of HIV primoinfection. Although lymphoid hypertrophy is more frequently described as manifestation in the pediatric population, where the lymphoid tissue hypertrophy of Waldeyer's ring leads to the obstruction of the eustachian tube, it is described as a rare manifestation in adults. Due to the presence of typical symptoms, such as lymphadenopathies and constitutional symptoms, the level of suspicion of acute viral infection was high enough to diagnose it on this case.

#195 - Medical Image

NECROTIZING FASCEITIS-PASTEURELLA MULTOCIDA

Sorina-Monica Safciuc

SMU Moinesti, Bacau, Romania

Clinical summary

A 59-year-old diabetic man who came at Urgence for pain and swelling leg and ankle unilateral (onset 48 hours) with aggravation during hospitalisation.

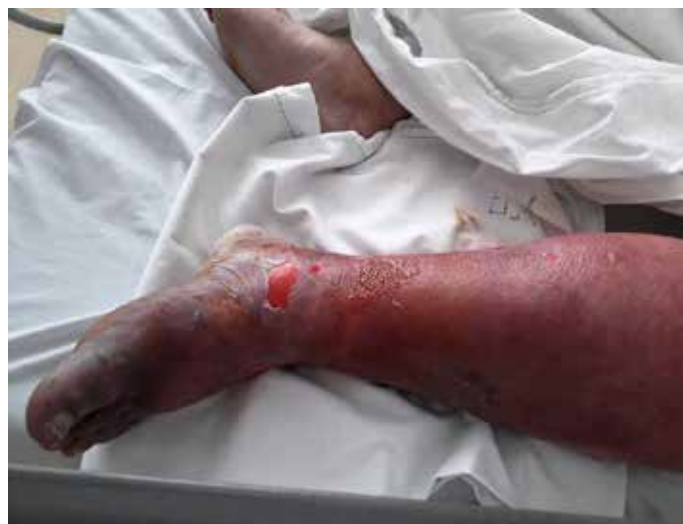

Figure #195. A 59-year-old diabetic man who came at Urgence for pain and swelling leg and ankle unilateral (onset 48 hours) with aggravation during hospitalisation.

#209 - Case Report

WHEN IT'S NOT WHAT IT SEEMS... AN INSIDIOUS TB DIAGNOSIS

Valeria Giosia

University of Milan, Milano, Italy

Introduction

Extrapulmonary tuberculosis (TB) may have various clinical and radiological features.

Differential diagnosis includes neoplasia (eg: secondary lesions, lymphoma), infections, and infiltrative diseases like sarcoidosis.

Case description

A 78 year-old man with history of prostate cancer in remission after treatment with radio and chemotherapy, presented with recent onset of normocytic, normochromic anemia, mildly elevated inflammatory markers and significant weight loss.

Recent diagnosis of duodenal ulcer and suspect esophageal fistula was made. Histology was negative for cancer cells in duodenum, with evidence of erosive inflammation. The fistula was not confirmed at a following EGD.

CT-scan showed numerous necrotic-colliquating adenopathies in mediastinum, thorax, and abdomen, associated with pleural

and peritoneal effusion and different inflammatory lesions in the left lung. In addition, hypodense pancreatic lesions suspect for neoplasia were found, accompanied by findings suggestive of peritoneal carcinosis.

Given the high suspicion of lymph node and pancreatic neoplasia, an endoscopic US-guided FNAB was performed, negative for neoplastic cells but showing giant histiocytic, inflammatory cells. Serum tumor markers were negative.

The patient underwent bronchoscopy with BAL, resulted negative for cancer cells, with negative Ziehl Neelsen stain.

A thoracic wall biopsy was performed and histology revealed a granulomatous, giant-cellular, chronic inflammation. Given the granulomatous aspect of the lesion, a PCR for M. Tuberculosis was asked on the bioptic specimen, eventually resulting positive.

The patient was then promptly referred to the Infectious Disease Unit for appropriate treatment.

Discussion

Nowadays the incidence of extra-pulmonary TB is increasing in developed countries due to, among other causes, migratory flows, HIV "epidemics" and increased chemotherapy availability. Besides, signs at presentation may be similar to those of neoplastic and infiltrative diseases.

For these reasons, whenever biopsies are negative for neoplasia but signs of chronic and granulomatous inflammation are found, TB should be considered and looked for, with cultures and genome search on bioptic samples.

#231 - Case Report

OROPHARYNGEAL CANDIDIASIS (OC) IN IMMUNOCOMPETENT PATIENT

Miriam Vieitez Santiago¹, Alba María Martínez Torrón², Rita Nogueiras Álvarez², Ana Campo Ruiz¹, Raquel Jaso Tejera¹, Miguel Carrascosa Porras¹, María Elena Casuso Sáenz¹, Paloma Sánchez Junquera¹, Nuria Díez Herrán¹, Ana Isabel González-Torre González¹

¹ Hospital Comarcal de Laredo, Laredo, Spain

² Hospital Universitario Marqués de Valdecilla, Santander, Spain

Introduction

Oropharyngeal and esophageal candidiasis is an opportunistic infection that sometimes affects healthy individuals but is usually asymptomatic.

Candida albicans is the most common species that causes this type of candidiasis.

Case description

70-year-old female with a history of ex-smoking. Non-acute COPD with mild obstruction. Anxiety-depressive syndrome in treatment.

She goes to the internal medicine clinic for more than 6 months of evolution, odynophagia and oropharyngeal burning that makes it difficult to swallow. Associates weight loss of 20kg.

In the last 3 months, *Candida albicans* is isolated in the oropharynx and treated twice with fluconazole 100 mg daily for 14 days and once with itraconazole for 7 days. The patient persists symptomatically. Sampling is repeated at the end of the two antifungal guidelines with no response to treatment.

On physical examination: Weight: 53.1 kg; Size: 157 cm. IMC: 21,5. Small whitish lesion on the oral mucosa in the lateral area of the right cheek. Normohydrated. No adenopathy at any level. Rest of the exploration without significant findings.

Tests are performed for the study of general syndrome (complete analysis, chest X-ray, abdominal ultrasound, CT scan) and immunodeficiency (review of blood smears, serology, immunology) with all results being normal. Finally, gastroscopy is performed where there is no objective esophageal affection by candida.

Antifungigram is not performed in our hospital; but due to the patient's medical history, it is most probable that it was an oropharyngeal candidiasis (OC) resistant to treatment with azoles. That is why we contacted the Hospital Pharmacy service of the reference hospital for the preparation of oral amphotericin B treatment (100 mg every 6 hours for 14 days).

It is not a usual form of administration and should be done with a master formula to dose the appropriate and individualized dose into rinsing vials and swallow.

After treatment with oral amphotericin B she comes to the consultation for revision and the patient has clearly improved. Culture is taken, being this negative for fungi.

Discussion

The development of OC is almost always related to local factors, such as the use of broad-spectrum antibiotics or inhaled corticosteroids, xerostomia, or radiation treatment. But in our case there were none of these.

What has led us to consider in this case is the need to have an antifungigram. Since the patient would have been treated correctly from the beginning without presenting so much affection.

#235 - Case Report

CONSTITUTIONAL SYNDROME IN SUB-SAHARAN WOMEN

Isabel Moreno Lucente¹, Jose Ignacio Mateo González², Magdalena García Rodríguez², Carlos De Andrés David², Bianca Ridaura Aparisi², Camilla Nardini²

¹ Hospital Obispo Polanco, Teruel, Spain

² Hospital General de Valencia, Valencia, Spain

Introduction

Emerging infectious diseases are those caused by an infectious agent recently identified and previously unknown, capable of causing public health problems at the local, regional or global level. The appearance of new infectious diseases is increasingly frequent. This is due to factors such as the global population increase, globalization, increasing antibiotic resistance and international travelers.

Case description

82-year-old woman from Equatorial Guinea, arrived in Spain 20 days ago, who consulted for constitutional syndrome of several months of evolution. She reports postprandial abdominal pain with sensation of abdominal distension and retrosternal burning discomfort that the patient describes as "sensation of ascending worms". It associates anorexia and denies fever or athermal sensation.

Physical examination revealed a large not painful hepatosplenomegaly. In lower extremities skin lichenified dermatitis and hypopigmented areas.

Analytics showed bicytopenia with hemoglobin <10bg/dl and thrombopenia <55000. Alterations in coagulation and high eosinophilia were also observed. The initial suspicion of malaria was not confirmed after a negative thick drop test, as well as PCR and antigen determinations for plasmodium with negative results. Determinations of retrovirus, hepatotropic viruses and mycobacterias were requested; so how serologies for schistosome, oncocerca and filaria's. Likewise, in order to rule out a possible lymphoproliferative process, a body CT was performed. The results of abdominal CT were hepatomegaly, 18 cm splenomegaly, dilation of splenic axis with collateral circulation and gastric varices. This correlated with the positivity for HCV. The patient left the hospital with an appointment in outpatient clinics to take the pending results. In external consultations, the patient was informed of the final diagnoses of hepatitis C, infestation by *Mansonella perstans* and positive serologies for oncocerca, where she received treatment with sofosbuvir/velpatasvir, ivermectin and dosicycline.

Discussion

Filariasis are parasitic diseases that mainly affect lymphatic tissue and skin, which are caused by nematodes. They need insects that act as vectors to infect humans, which are the only reservoir. They are usually neglected diseases that present high incidence and prevalence in underdeveloped and developing countries. The diagnosis is made with the detection of microfilariae blood/skin and it is important that the treatment must be individual and collective.

#246 - Case Report

MYCOPLASMA PNEUMONIAE: A CASE OF PERICARDIAL EFFUSION IN THE ABSENCE OF RESPIRATORY SYMPTOMS

Mariana Soares, Iolanda Oliveira, Margarida Massas, Sara Correia, Carmen Corzo, Conceição Barata

Hospital Espírito Santo de Évora, Évora, Portugal

Introduction

Mycoplasma pneumoniae is a common pathogen in pediatric population and young adults, mainly causing respiratory tract infection, as community acquired pneumonia. Extra respiratory involvement is rare, predominantly seen as arthralgia or myalgia, and can be explained by blood or lymphatic spread, as well as by direct invasion of structures in proximity to the lung. Cardiac

involvement is very rare, with a recognized incidence of 1-5%. We present a case of pericardial effusion, attributed to *Mycoplasma pneumoniae* infection, in a 49-years-old woman.

Case description

Patient admitted to a psychiatric ward due to nervous anorexia, observed by internal medicine owing to pancytopenia. She presented with no symptoms, other than psychiatric, namely fever, hemorrhage or respiratory manifestations. During etiologic study of pancytopenia, auto-immune and serologic testes were performed, with identification of positive IgM and IgG to *Mycoplasma pneumoniae*. Even though the low body weight could be attributed to nervous anorexia, we opted to perform CT of thorax, abdomen and pelvis, to exclude occult neoplasm. The CT showed only pericardial effusion and thickness of the left pleura, followed by an echocardiogram, confirmatory of a moderate pericardial effusion. The patient never presented respiratory symptoms, chest pain or hemodynamic compromise, reason why we didn't perform pericardiocentesis, nor started antibiotherapy, convinced of an immunologic mechanism of pericardial effusion. We started therapy with colchicine and continued to follow the patient in consult, for echocardiographic re-evaluation, keeping in mind the possible future need to start antibiotics.

Discussion

Pericarditis and pericardial effusion are rare manifestations of *Mycoplasma pneumoniae* infection, normally seen in patients with respiratory symptoms, with or without pulmonary infiltrates. In the presented case, pericardic involvement occurred in the absence of respiratory manifestations, only associated with left pleural thickness, which led us to believe in an immunological mechanism. This case elucidated us about the possible interest of including serologic testing of *Mycoplasma pneumoniae* in the routine evaluation of pericardial effusion, since treatment with non-steroid anti-inflammatories and antibiotics proved its efficacy. The implementation of this study could probably show a higher incidence of the association between these two entities.

#251 - Case Report

TESTICULAR TUBERCULOSIS, REPORT OF 2 CASES

Flávio Pereira¹, André Terras Alexandre², Mariana Conceição³, Sara Raimundo², Ana Rafaela Araújo¹, Inês Ladeira⁴

¹ Centro Hospitalar do Baixo Vouga, Aveiro, Portugal

² Centro Hospitalar de Trás-os-Montes e Alto Douro, Vila Real, Portugal

³ Centro Hospitalar Centro Hospitalar Tondela, Viseu, Portugal

⁴ Centro Hospitalar Vila Nova de Gaia/Espinho, Vila Nova De Gaia, Portugal

Introduction

Tuberculosis is an infection caused by *Mycobacterium tuberculosis* that demands prolonged anti-bacillary treatment. Testicular tuberculosis is a rare presentation of genitourinary tuberculosis.

Case description

Case 1

67-year-old male presented with right-sided testicular swelling for 2,5 years. There was no history of respiratory or constitutional symptoms. He underwent left-sided orchidectomy which showed chronic granulomatous orchi-epididymitis with necrosis. Ziehl-Neelsen staining was negative. Interferon Gamma Release Assay was positive. Sputum sample mycobacterial culture was negative. Probable testicular tuberculosis was assumed and patient started rifampicin 600 mg, isoniazid 300 mg, pyrazinamide and mg ethambutol 1200 mg daily for 2 months followed by rifampicin 600 mg and isoniazid 300 mg daily for 10 months with complete response.

Case 2

48-year-old South African male presented with slight painful, right-sided testicular swelling for 2 months. There was no history of respiratory or constitutional symptoms. He was in Portugal for more than 20 years, but he had been in South Africa 2 years before the presentation for 2 weeks. Ultrasonography revealed a solid, vascularized lesion adjacent to the right epididymis. The patient underwent surgical resection which showed multiple epithelioid granulomas with central necrosis and mixed inflammatory cells. Both Ziehl-Neelsen staining and Xpert MTB-RIF Assay were negative. Sputum and urine samples were negative for alcohol acid fast bacilli. Thoracic computed tomography was normal. Probable testicular tuberculosis was diagnosed, and patient started rifampicin 600 mg, isoniazid 300 mg, pyrazinamide 1500 mg and ethambutol 1200 mg daily. Patient is currently in follow-up visits, in the intensive treatment phase.

Discussion

Although rare, testicular tuberculosis must be considered in the differential diagnosis of prolonged symptoms. Isolation of *Mycobacterium tuberculosis* is hard and most times impossible if the surgical piece is not sent to mycobacterial culture. Molecular testing improves diagnostic accuracy but is not always positive. Sometimes treatment has to be initiated when the diagnosis. Complete diagnostic confirmation is not always possible.

#262 - Case Report

PRIMARY PSOAS PYOMYOSITIS WITH HIP JOINT SEPTIC ARTHRITIS AND METHICILLIN SUSCEPTIBLE STAPHYLOCOCCUS AUREUS (MSSA) BACTEREMIA

Than Zaw Oo

Singapore General Hospital, Singapore, Singapore

Introduction

Staphylococcus Aureus is a skin commensal bacteria and primary *Staphylococcus Aureus* infection without any apparent cause is uncommon. This case is reporting a case of a pre-morbidly healthy and immunocompetent patient who was diagnosed with primary psoas pyomyositis with hip joint septic arthritis and MSSA bacteremia.

Case description

A 65 years old Chinese female presented with left hip joint pain for one week and fever onset of one day duration. She was found to have MSSA bacteremia and MRI of the hip joint revealed a left psoas muscle abscess and septic arthritis. The intravenous injection of antibiotic was started and the abscess was drained under imaging guidance. Echocardiogram did not reveal any signs of infective endocarditis. She was discharged with prolonged course of intravenous antibiotic injection.

Discussion

This patient is an immunocompetent individual without any significant predisposing factors. The psoas pyomyositis was indolent and there was no other apparent cause that could be found. Pyomyositis is well known to have predilection for large muscle groups and often results in localized abscess formation as in our patient. In view of the indolent nature and insidious onset of such infection, high clinical suspicion is required to identify this disease entity.

#265 - Abstract

HOSPITALIZED Q FEVER: IMPACT ON THE SPANISH PUBLIC HEALTH SYSTEM (1998-2017)

Beatriz Rodríguez Alonso¹, Hugo Almeida², Montserrat Alonso Sardón³, Juan Miguel Manrique Pérez¹, José Luis Pérez Arellano⁴, Moncef Belhassen García¹

¹ Complejo Asistencial Universitario de Salamanca, Salamanca, Spain

² Unidade Local de Saúde da Guarda, Guarda, Portugal

³ Universidad de Salamanca, Salamanca, Spain

⁴ Hospital Universitario de Gran Canaria Doctor Negrín, Gran Canaria, Spain

Background

Q fever (QF) is a zoonosis caused by *Coxiella burnetii*. It is a "Notifiable Disease", worldwide expanded and with different clinical manifestations depending on the geographic zone. The impact of Q fever cases in-patients is not well described.

Methods

We present a retrospective descriptive study using the Minimum Basic Data Set (CMBD in Spanish) in patients admitted to hospitals of the National Health System (NHS) between 1998 and 2017 with a diagnosis of Q fever (International Classification of Diseases, ICD-9: 083.0.)

Results

We have found 4,214 hospitalized patients diagnosed with Q fever. The mean age was 50.1±19.3 years. 3,147 cases were men (74.7%). The period incidence rate was between 0.41 y 0.65 cases per 100,000 person-years, which was similar during all the period we have studied. It was a primary diagnosis in 3,071 cases (89.8%) and a second one in 1,143 (27.1%) of them. The mean hospital

stay was 22.8 ± 21.4 days. The lethality rate was 1.95 in 1998 and it was progressively increasing until 4.26 in 2015, even though the cohort of cases was stable between all these years. The states with higher incidence were Balearic Islands, Canary Islands and Cantabria, respectively. Nevertheless, the higher lethality rate took place in Asturias, Galicia and Cantabria, respectively. Each case admitted to hospitals diagnosed of Q fever had a mean health cost of $36.600.1 \pm 39.421.8$ € for the Spanish government. That means a total of 154,232,778.6 € during these twenty years.

Conclusion

Q fever is an endemic disease in our country and, though the notification is increasing, is underestimated yet. Despite of our health system has experienced an exponential development in the last twenty years; the mortality rate of this disease has been increasing progressively. Furthermore, it has a long hospital stay which implies an important economic cost to our health system.

#272 - Case Report

PERITONEAL CARCINOMATOSIS OR SOMETHING ELSE?

Ana Andrade Oliveira, Joana Morais, Inês Burmester, Olga Pires, Isabel Marques, Filipa Rodrigues, Mariana Devesa, Maria João João Regadas, Paulo Gouveia

Hospital de Braga, Braga, Portugal

Introduction

Peritoneal tuberculosis is a rare entity, being the 6th most frequent location of extrapulmonary tuberculosis. Its diagnosis is difficult given the absence of specific clinical and imaging characteristics, is sometimes confused with peritoneal carcinomatosis.

Case description

A 64-year-old woman with hypothyroidism and history of nephrectomy due to recurrent pyelonephritis was referred from primary care after an abdominal CT raised the possibility of peritoneal carcinomatosis ("adenopathies at the cardiophrenic angles, peritoneal effusion with nodular densification and small peritoneal implants"). She reported peri-umbilical abdominal pain and discomfort in the last 3 months and 5 kg of weight loss in the last month. She denied fever, night sweats or other constitutional symptoms. Laboratory tests showed normocytic normochromic anemia and positive CA-125 (100 U/ml). The first paracentesis showed a predominance of neutrophils. Endoscopy, colonoscopy, pelvic-US, mammography and mammary-US all showed no abnormalities. PET-CT was consistent with carcinomatosis showing increased uptake in supra and infra-diaphragmatic adenopathies and peritoneum. Then, she underwent an exploratory laparoscopy, unmasking a peritoneum with a raspberry appearance. Samples of peritoneum were taken which revealed a necrotizing granulomatous inflammation. A new paracentesis was done that revealed a high adenosine deaminase and 56% of lymphocytes. The Interferon Gamma Release Assay to detect *Mycobacterium tuberculosis*

infection (IGRA) was also positive. Peritoneal tuberculosis was at that time assumed as the final diagnosis, and antibiotic therapy was initiated. Shortly after that, her symptoms started to improve and she regained her weight.

Discussion

Many non-neoplastic conditions can mimic peritoneal carcinomatosis, such as tuberculosis. The histology samples with necrotizing granulomatous inflammation, high adenosine deaminase, and positive IGRA confirmed the diagnosis of peritoneal tuberculosis, even though it wasn't one of our first hypothesis.

#281 - Case Report

STREPTOCOCCUS GALLOLYTICUS ENDOCARDITIS IN A PATIENT WITH COLON CANCER

João Aurélio, Joana Nascimento, Tiago Vasconcelos, Pedro Rouxinol, Marta Duarte Segurado, Raquel Pinho, Helena Rita, Luisa Arez

Centro Hospitalar Universitario do Algarve, Portimão, Portugal

Introduction

Several associations between bacteria and gastrointestinal neoplasia have been reported, with the best documented relationship being streptococcus Bovis, primarily *S. Gallolyticus* subspecies, and colon cancer.

Case description

We describe the case of a 65 years old male, previously diagnosed with neoplasia of ascending colon, admitted for pre-surgical care. On admission patient presented with bad general status, weight loss (>10% in 3 months) fever, elevated inflammatory markers, Leucocyturia (initially diagnosed as urinary tract infection). Started empiric antibiotic therapy, with previous collection of blood and urine cultures.

In the fifth day of admission, the patient developed signs and symptoms of heart failure, blood cultures were positive for *Streptococcus gallolyticus* which prompted the realization of an echocardiography that showed aortic valve vegetations. Based on the diagnosis of infective endocarditis antibiotic was switched to ampicillin + gentamicin.

During therapy Patient developed acute heart failure in context of severe aortic valve insufficiency, leading to urgent valvulotomy. After surgery and resolution of acute status, patient was referred for Surgery consult for new evaluation and if possible curative surgery.

Discussion

Despite the strength of the correlation between *Streptococcus gallolyticus* infective endocarditis and colon cancer, it is source of debate whether *S. gallolyticus* bacteremia is consequence of the gastrointestinal lesion or a trigger of colorectal neoplasia.

Currently both European Society of Cardiology (ESC) and

American Heart Association (AHA) recommend rulling out gastrointestinal neoplasia in patients diagnosed with *S. bovis* infective endocarditis or bacteremia. ESC adds that in the absence of any tumour, schedulling annual colonoscopy is highly suggested.

#289 - Abstract

DO WE COMPLY WITH THE TREATMENT RECOMMENDATIONS FOR INFLUENZA?

Victoria Palomar, Sara Muñoz, Victor Madrid, Carlota Tuñón, Luis Miguel Palomar, María Montserrat Chimeno
Complejo Asistencial de Zamora, Zamora, Spain

Background

During influenza activity, influenza testing should be obtained in the following patients: immunocompromised/at high risk for complications outpatients or patients who require hospitalization with acute onset of respiratory symptoms with or without fever; patients requiring hospitalization with acute respiratory illness or with acute worsening of chronic cardiopulmonary; individuals who develop acute onset of respiratory symptoms with or without fever, after hospital admission.

IDSA's guidelines recommend prompt initiation of antiviral therapy for individuals with suspected or confirmed infection and any of the following features: patients hospitalized with influenza or outpatients with severe or progressive illness, regardless of illness duration prior to hospitalization and outpatients who are at high risk of complications.

Methods

Observational, cross-sectional and descriptive study to describe the patterns of hospitalized patients for suspected influenza in a B-level Hospital between the 2017-2018 and 2018-2019 seasons. We collect the diagnostic tests for influenza A or B by PCR for in pharyngeal swabs, between October 2017-February 2018 and October 2019-February 2019 requested at the Zamora Healthcare Complex in charge of Internal Medicine and Pulmonology. The following variables are analyzed: sex, age, flu CPR and treatment with oseltamivir.

Results

In first season, 195 tests were requested against 268 in second season.

In season 2017-2018, 80.5% were requested in patients > 65 years. 74 were positive, of which 23% for influenza B and 14% for influenza A. 32.3% were treated with oseltamivir, 20% with negative test result, 50.5% influenza A and 28.5% influenza B.

In season 2018-2019, 79% were requested in patients > 65 years. 103 were positive exclusively for influenza A. 36% were treated, 20.6% with negative results and 79.3 % influenza A.

Conclusion

1. In season 2018-2019, 73 more tests were requested, obtaining 29 positive tests more than the previous season.

2. In season 2018-2019, 100% of the positive tests were for influenza A compared to 14% of the previous season.
3. Regarding the age and months with the highest incidence of tests requested, the findings were similar, prevailing at > 65 years and January and February.
4. In both seasons the negative results are similar as well as the percentage of treated patients.
5. All patients who require admission and suspected influenza have conditions to start treatment with Oseltamivir, however 2/3 do not receive treatment.

#290 - Abstract

ARTIFICIAL NEURAL NETWORKS APPLIED TO BODY TEMPERATURE ANALYSIS AND FEVER FORECASTING

Borja Vargas¹, Juan Carlos Colás², José Manuel Mira², Paula González¹, Manuel Varela¹, Luis Vigil¹, María José Fernández-Cotarelo¹, Óscar Vázquez¹, Ana Colás³

¹ Hospital Universitario de Móstoles, Móstoles, Spain

² Universidad Politécnica de Madrid, Madrid, Spain

³ Hospital Universitario 12 de Octubre, Madrid, Spain

Background

Artificial neural networks (ANN) are a powerful statistical tool for classification purposes. Although not common in clinical practice, body temperature monitoring provides a substantial amount of information about thermoregulation that could be used to forecast fever. ANN might be an appropriate strategy in this setting.

Methods

Body-temperature time series were obtained from 17 patients admitted to a general Internal Medicine ward because of fever, accounting for 21233 measurements. Body temperature was measured in the external auditory canal (EAC) and over the forearm skin. Several surrogate variables were obtained and included in the ANN as predictors.

Assessment of fever prediction was based on the ability of the model to classify temperature measurements as "pre-febrile" if temperature in the EAC reached 38°C sixty minutes later, and as "not pre-febrile" otherwise. The training set included 14800 measurements and the validation set, 6433.

Classification accuracy of the ANN model was evaluated with the area under the receiver-operating curve (AUC), and a confusion matrix was created for different thresholds, in order to choose the most convenient model for clinical purposes.

Results

The AUC of the model was 0.871. For a threshold of 0.3, the ANN had a sensitivity of 61.42% (269 out of 438), a specificity of 87.87% (5268 out of 5995), and a global accuracy rate of 86.07%. For a threshold of 0.6, the sensitivity was 22.15% (97 out of 438), the specificity 97.23% (5829 out of 5995) and the global accuracy rate 92.12%. On the 6433 measurements of the validation series,

there were 7 fever peaks, 5 of which were forecasted by the ANN model, with only one false positive (one peak was predicted with no fever in the following minutes).

Depending on the threshold established, anticipation to fever spikes ranged from a minimum of 14 minutes to a maximum above 90 minutes.

Conclusion

Artificial neural networks (ANN) are a powerful statistical tool for classification purposes. Although not common in clinical practice, body temperature monitoring provides a substantial amount of information about thermoregulation that could be used to forecast fever. ANN might be an appropriate strategy in this setting.

#304 - Case Report

SPONDYLODISCITIS: ABOUT A CLINICAL CASE

Margarida Melo De Moraes, Maria Jesus Silva

Centro Hospitalar Lisboa Norte, Lisboa, Portugal

Introduction

Spondylodiscitis is an infectious disease of the spinal column, involving the vertebral bodies and intervertebral discs, more commonly the lumbar structures.

Fever, back pain and neurological deficits are described as frequent findings.

The diagnosis is often delayed, probably due to an indolent presentation of the disease, with unspecific symptoms, such as asthenia.

Tubercular spondylodiscitis is the most common form of musculo-skeletal tuberculosis.

Despite the aetiology, this is a potentially fatal condition, which requires a long and challenging treatment period and a long stay at the hospital.

Case description

We expose a case of a 70 years old man, who presents, 3 weeks prior to the hospital commitment, with right testicle pain, symmetric loss of strength of the lower limbs and urinary retention.

The patient also referred asthenia and anorexia, associated with a loss of 6 Kg in a period of 2 months.

Initial laboratory works showed an elevated CRP and microcytic anaemia. Spondylodiscitis involving L4-L5 and L5-S1 levels was documented in a CT scan.

The patient was submitted to multiple empirical antibiotic cycles, once we could not identify an infectious agent, with no success.

Anti-tubercular therapy was instituted, with clinical, laboratory and imagological improvement.

Discussion

Despite the lower mortality rate associated with this entity after the introduction of antibiotherapy, spondylodiscitis still presents as a significant challenge in terms of treatment and accompanying potential morbidity.

The identification of an infectious agent is very important to a better management of the patient.

Infection by Mycobacterium tuberculosis should be considered.

#305 - Abstract

ASSESSMENT OF CARDIOVASCULAR RISK AND ARTERIAL STIFFNESS IN PATIENTS WITH HUMAN IMMUNODEFICIENCY VIRUS

Mariana Sousa Freitas, Clarisse Coelho Neves, Helena Jacinto Sarmento

Senhora da Oliveira Guimarães Hospital, Guimarães, Portugal

Background

Several studies suggest that patients infected with human immunodeficiency virus (HIV) under highly active antiretroviral therapy (HAART) have higher cardiovascular risk than general population. Arterial stiffness is an independent predictor of cardiovascular events and can be measured through PWV (carotid-femoral pulse wave velocity). The HIV role on arterial stiffness is a controversial issue. The objectives of this study were to characterize a sample of patients infected with HIV under HAART regarding the cardiovascular risk; to compare PWV values of this group of patients with uninfected controls; and to investigate predictors of PWV in HIV-infected group.

Methods

PWV was measured and data was collected from a sample of 125 HIV-infected patients under HAART. PWV measurements in study group were compared with those in a control group of 250 subjects similar in sex, age, prevalence of hypertension and type 2 diabetes mellitus (DM). A linear regression model was constructed to identify predictors of PWV in HIV-infected group.

Results

In the HIV-infected group, composed mostly by men, the mean age and respective standard deviation were 48.6 ± 11.6 years. In this group, 112 individuals (89.6%) presented moderate to very high cardiovascular risk. Significant differences were found in median PWV between HIV-infected and control groups (8.56 vs. 8.00 m/s, $p = .002$). Age, peripheral systolic blood pressure, presence of DM, amount of alcohol consumed and current CD4+ T cell count were independent predictors of PWV in HIV-infected group.

Conclusion

The group of HIV-infected patients showed higher cardiovascular risk and arterial stiffness measurements than general population. PWV may be an important predictor of subclinical cardiovascular disease in HIV-infected patients.

#310 - Case Report

A FATAL STRONGYLOIDES STERCORALIS HYPERINFECTIOIN SYNDROME IN A HIV-INFECTED PATIENT

Vicente David De La Rosa Valero, María Del Carmen Hernández Murciano, Elena Del Carmen Martínez Cánovas, Carlos Báguena Pérez-Crespo, Ignacio Iniesta-Pino Alcázar, Gabriel Puche Palao, Ana Martín Cascón, Mónica Martínez Martínez, Lia Ferraro, Enrique Bernal Morell

Hospital General Universitario Reina Sofía De Murcia, Murcia, Spain

Introduction

Strongyloides stercoralis is a parasite that is endemic in tropical and subtropical regions and occurs sporadically in temperate areas. The clinical presentation of strongyloidiasis varies from asymptomatic infection and mild symptomatic abdominal disease to fatal disseminated infection in immunosuppressed patients.

Case description

A 46-years-old man, originally from Dominican Republic, has lived in Murcia (Southeast of Spain) for 16 years. Doesn't refer medical history of interest. He comes to our emergency department due to a three-days history of diarrhea and vomiting, consisting of three vomits of alimentary content and eight liquid stools daily without pathological products. On physical examination, he was hypotensive (BP 100/60), tachycardic (111 rpm), with signs of muco-cutaneous dehydration, with normal cardiorespiratory auscultation and abdominal palpation. The emergency department's analysis showed severe hyponatremia (sodium 115), so admission to Internal Medicine was decided after sodium replacement. The next day in hospitalization plant, he becomes unstable with a severe respiratory distress, so he enters in ICU. There, he was found to be hypotensive (BP 78/35) and hypoxemic (PaO₂ 63.7 mmHg) with muco-cutaneous pallor and malaise, so intensive fluid therapy is initiated and is intubated. Chest X-ray showed an alveolar-interstitial pattern encompasses both lungs and analysis showed an anemia (Hb 4.9) with lymphopenia (300). Given the clinical picture of respiratory distress along with severe anemia, there was a suspicion of pulmonary hemorrhage, so transfusions of six packed red blood cells are started and after that, an emergency bronchoscopy is performed. This showed large amounts of mucus mixed with abundant red blood and *S. stercoralis* larvae could be seen microscopically. It was performed an HIV test was finally positive with CD4 lymphocyte levels of 20. Subcutaneous ivermectine and intravenous meropenem were started but without clinical improvement, so he died in a few hours due to massive pulmonary hemorrhage. No retroviral treatment was started due to the risk of immune reconstitution syndrome.

Discussion

S. stercoralis is capable of staying in same host for a long time (even several decades) due to its self-infectation cycle. If an immunosuppressive factor interferes (HIV infection, for example) favors a pattern of disseminated hyperinfection affecting several systems by invasion of them (in our case, pulmonary and digestive).

#313 - Case Report

A RARE CASE OF ACTINOMYCES EMPYEMA IN AN IMMUNOCOMPETENT YOUNG MALE

José Miguel Lessa Silva, Joana Gomes Cochicho, Sara Viana, Rita Parente, Ruben Raimundo, Adriano Pacheco Mendes, Ana Neves, André Mendes, Tamar Nunes Garcia, Isabel Soles
Hospital Doutor José Maria Grande, Portalegre, Portugal

Introduction

We present a rare clinical report of a complicated respiratory infection by an isolated *Actinomyces* bacteria.

This is a rare clinical entity, with no pathognomonic presentation, which embraces a diagnostic challenge, easily confused with other entities.

Case description

A 34-year-old male, rubber industry worker and smoker, with a clinical record of multiple pulmonary infections treated with short course oral antibiotic therapy; presents at emergency service with a 3 week's history of pleuritic chest pain and dyspnea. The patient also referred nocturnal fever, night sweats and cough with purulent sputum.

At admission, presented hemodynamically stable, with reduced breath sounds in the left lung, and type 1 respiratory insufficiency. Chest X-Ray showed lower left pulmonary hypotransparency, and CT-scan documented a massive multi-loculated left pleural effusion with condensation.

Laboratory analysis demonstrated increased inflammatory markers, with a negative serological study.

The patient was submitted for empirical antibiotic treatment with levofloxacin, but due to lack of response in the initial 48 hours Clindamycin was added with a good response.

Initially a thoracentesis was performed and the analyses of the pleural fluid obtained was suspicious of empyema, and culture in aerobic environment was negative.

Taking into account the extension of pleural effusion and its possible consequences in a young patient, a video-assisted thoracic surgery with pleural debridement was performed.

It was then that the microbiology of the pleural fluid obtained revealed the growth of *Actinomyces meyeri* and *Streptococcus intermedius*.

Discussion

Actinomyces genus are anaerobic Gram-positive bacilli that typically reside in mouth, gastrointestinal tract, and reproductive system.

The diagnosis and isolation of this pathogen is challenging, taking into account its rarity and resemblance with other chronic suppurative chest diseases and malignancy.

The nonspecific history, physical examination, radiological and laboratorial findings presented in this patient lead us to an extensive differential diagnosis.

This remarkable case shows the importance of a holistic approach to the clinical investigation of an extensive differential diagnosis, natural to an internal medicine clinician.

#317 - Case Report

A YOUNG NEUTROPENIC PATIENT WITH GLYCOGEN STORAGE DISEASE AND DIARRHEA: AN UNDERLYING INFECTION OR HER PRE-EXISTING CROHN'S LIKE DISEASE?

Chryssi Koliaki, Christos Siafarikas, Aristeidis Tsakanikas, Aggeliki Georgopoulou, Maria Mylona

1st Department of Propaedeutic & Internal Medicine, Laiko General Hospital, Athens University Medical School, Athens, Greece

Introduction

Clostridioides difficile infection (CDI) is a symptomatic infection due to the spore-forming bacterium *Clostridioides difficile*, which makes up about 20% of cases of antibiotic-associated diarrhea. Symptoms include watery diarrhea, fever, nausea and abdominal pain, while its complications may include pseudomembranous colitis, toxic megacolon with or without perforation and sepsis. Herein we present an interesting case of a neutropenic patient with prior history of glycogen storage disease-associated Crohn's like colitis, who presented with diarrhea and histologic diagnosis of CDI.

Case description

A 30-year old Caucasian woman, with a history of type IB glycogen storage disease (GSD) and GSD-associated neutropenia and Crohn's like colitis, was admitted to our clinic due to fever (up to 38.5° C twice daily), diffuse abdominal pain and progressive worsening of watery mucous diarrhea (up to five times daily) for the last 15 days despite the prescribed antibiotic therapy with ciprofloxacin and metronidazole. She was febrile and physical examination was unremarkable apart from tachypnea, -previously known-hepatosplenomegaly and diffuse abdominal tenderness. Blood chemistry revealed neutropenia (500 PMNs/uL), highly elevated inflammation markers, lots of leucocytes and plenty of mucous in the stool samples, negative blood and stool cultures for any pathogen including *Clostridium difficile* and toxins A or B. Her abdominal CT scan was unremarkable apart from inflammation of the ileum. She underwent colonoscopy with findings consistent with the pre-existing Crohn's like colitis. The patient was initially treated with GCSF and piperacillin/tazobactam IV. Post-colonoscopy budesonide was also initiated. On the 5th day of hospitalization, colon pathology revealed CDI and pseudomembranous colitis. Antibiotics were immediately discontinued and treatment with vancomycin 125 mgx4 per os was initiated. She clinically improved rapidly and was discharged four days later.

Discussion

The use of systemic broad-spectrum antibiotics causes the normal microbiota of the bowel to be altered predisposing -especially immunocompromised- hosts to *C. difficile* overgrowth and its complications

#318 - Case Report

A RARE CASE OF AN AFEBRILE PATIENT WITH HAEMOPHILUS DUCREYI- ASSOCIATED COLD PAROTID ABSCESS

Vasileios Andrianesi¹, Ioannis Deliolanis², Eugenia Malliarou¹, Maria Mylona¹

¹ 1st Department of Propaedeutic & Internal Medicine, Laiko General Hospital, Athens University Medical School, Athens, Greece

² Microbiology Department, Laiko General Hospital, Athens, Greece

Introduction

Haemophilus ducreyi (HD) is a fastidious gram-negative coccobacillus bacterium, which causes the sexually transmitted disease chancroid, a major cause of genital ulceration in developing countries characterized by painful sores on the genitalia. Herein, we present an interesting case of an afebrile immunocompetent patient with HD-associated parotid abscess.

Case description

A 54-year old Caucasian man, with a history of epilepsy under treatment, was admitted to our clinic due to progressive worsening of painless right anterior cervical swelling with no clinical response to a 5-day antibiotic treatment with cefuroxime. He was afebrile and physical examination was unremarkable apart from the cervical swelling and two mildly painful genital ulcers. Blood chemistry revealed mildly elevated inflammation markers. The patient underwent a right cervical ultrasound, where two right parotid lesions (~ 5x7cm and 3x4 cm respectively) were revealed. The thoracic, upper/lower abdominal CT scans were unremarkable. He was then subjected to a fine needle biopsy of the greater lesion, which revealed parotid gland lymphadenitis. *H. ducreyi* was at the same time isolated from two blood cultures. HIV, HBV, HCV and syphilis testing was negative. The patient revealed dangerous sexual practices. He was treated with ciprofloxacin for the next 14 days showing complete remission of his symptoms. Post treatment-imaging showed full remission of his lesions.

Discussion

H. ducreyi is an opportunistic microorganism that infects its host by way of breaks in the skin or epidermis. Inflammation then takes place as the area of infection is inundated with lymphocytes, macrophages, and granulocytes. This pyogenic inflammation causes regional lymphadenitis in the sexually transmitted disease, chancroid. *H. ducreyi*-bacteremia in an afebrile immunocompetent patient with a cold parotid abscess is an unusual clinical entity and a real diagnostic challenge for the physician, who should be aware of atypical forms of sexually transmitted diseases.

#319 - Case Report

CHRONIC ENTERIC ISCHEMIA: A RARE CASE OF PROTEIN LOSING ENTEROPATHY

Vasileios Andrianesis¹, Matthew Katsaras¹, Sofia Fragioudaki¹, Dimitrios Dimitroulis², Maria Mylona¹

¹ 1st Department of Propaedeutic & Internal Medicine, Laiko General Hospital, Athens University Medical School, Athens, Greece

² 2nd Surgical Propaedeutic Department, Laiko General Hospital, Athens University Medical School, Athens, Greece

Introduction

Protein losing enteropathy (PLE) has been associated with various different conditions, including almost all gastrointestinal diseases (celiac, Crohn's disease, Whipple's, intestinal infections) and multiple other cardiac or liver diseases or autoimmunity disorders such as lupus or sarcoidosis. Herein we present an interesting case of PLE in a patient with chronic enteric ischemia.

Case description

A 58-year old Caucasian man, with a history of an ischemic stroke 10 years ago without treatment, was admitted to our clinic due to prolonged intermittent fever (up to 38° C once or twice daily) for the last 7 months -non-responsive to empiric antibiotic treatment and corticosteroids prescribed for possible underlying autoimmune or autoinflammatory disease-, severe weight loss (more than 10 kg) and diffuse abdominal pain. He was febrile and physical examination was unremarkable apart from low BMI and livedo reticularis. Blood chemistry revealed normocytic anemia (Hb 9 g/dl), highly elevated inflammation markers and low albumin levels (1.6 g/dl) without renal protein loss. His abdominal CT scan revealed diffuse small intestine inflammation, while his stool sample was consistent with malabsorption findings. Stool a1- antitrypsin levels were elevated (>2.25mg/g). The patient's upper and lower abdomen endoscopies were unremarkable and pathology was negative for Whipple's and amyloidosis. FDG PET/CT scan revealed hypermetabolic activity of the small intestine, especially of the jejunum. Gene testing for autoinflammatory disorders was also negative. The patient experienced two TIAs during his hospitalization. Heart echo, carotid artery triplex and testing for underlying thrombophilia were unremarkable. He was treated with double antiplatelet therapy and rosuvastatin 20 mg daily ever since and underwent small intestine enterectomy. Pathology suggested chronic enteric ischemia with CMV infection. The patient was discharged after 14 days of IV ganciclovir treatment, afebrile and clinically significantly improved.

Discussion

PLE is a complex, relatively rare clinical entity associated with multiple conditions. It is surprisingly disappointing that several physicians are not familiar with PLE and thus they delay and complicate its diagnosis.

#320 - Abstract

CARBAPENEM-RESISTANT KLEBSIELLA PNEUMONIAE OXA-48 OUTBREAK – HOW TIGHT INFECTION CONTROL MEASURES STOPPED TRANSMISSION

Ana Gorgulho¹, Ana Maria Grilo¹, Manuel De Figueiredo^{1,2}, Joana Selada^{1,3}, Ana Paula Antunes¹, Carolina Sequeira¹

¹ Hospital de Cascais - Dr Jose de Almeida, Cascais, Portugal

² GCL-PPCIRA, Cascais, Portugal

³ SYNLAB Lisboa, Lisboa, Portugal

Background

Carbapenem resistance was uncommon in our hospital until 2018. There was a worrying growth in isolates during the first months of 2018.

We had the objective of analysing the evolution of carbapenem-resistant Klebsiella pneumoniae (KP) OXA 48 isolates in a Portuguese regional hospital, during the year of 2018, and the impact of reinforcing tight control measures on the isolate numbers. We also aim to describe the infection control measures taken and the results afterwards.

Methods

Between March and June of 2018 a growing number of KP OXA 48 isolates detection (that were very uncommon in the previous years) raised suspicion of nosocomial transmission. This triggered our Infection Control Committee to reinforce infection control measures for the whole hospital staff. A task force dedicated to only patients infected/colonized with these strains was created. Patients were isolated in a cohort regardless of their illness being surgical or medical. Patients and families were also educated.

Results

In March we had the first isolate of KP OXA 48 of the year. In April none was detected. In May there were 4 new isolates and in June 12. Many of them were in-patients at the same time. During June the infection control measures were implemented. The number of isolates per month reached a peak in July and diminished steadily until the end of the year.

Conclusion

Carbapenem resistance is a global threat that does not leave many antibiotic options. Infection control measures should always be adhered to and periodic reinforcement of education for staff, patients and families has perceptible results.

#321 - Abstract

CARBAPENEM- RESISTANT ENTEROBACTERIACEAE IN A PORTUGUESE REGIONAL HOSPITAL – 5 YEAR ANALYSIS OF THE PATIENTS CHARACTERISTICS

Ana Gorgulho¹, Ana Maria Grilo¹, Manuel De Figueiredo^{1,2}, Joana Selada^{1,3}, Ana Paula Antunes¹, Carolina Sequeira¹

¹ Hospital de Cascais - Dr José de Almeida, Cascais, Portugal

² GCL-PPCIRA, Cascais, Portugal

³ SYNLAB Lisboa, Lisboa, Portugal

Background

Carbapenem resistance is a global growing threat and some patients are in larger risk than others. We aim to analyse the epidemiology, including demography, cause of admission, presence of medical devices and previous antibiotic therapy, from patients infected/colonized with carbapenem-resistant Enterobacteriaceae.

Methods

Retrospective analysis of patients admitted to a Portuguese regional Hospital between 2015 and 2018 who had carbapenem-resistant Enterobacteriaceae isolates detected on any culture test performed.

Results

We had a total of 113 patients with carbapenemase-resistant enterobacteriaceae isolates detected between 2015 and 2018. The incidence of infection/colonization was higher in males (75%) and the average age was 75.6 years with a range from neonate to 100 years old. Sixty-six percent (n=75) of the patients lived at home while 31% (n=35) were institutionalized (nursing home or rehabilitation center). The main causes of admission were urinary tract infections (31%, n=35), respiratory infections (17%, n=19) and diabetic foot ulcer infection (8%, n=9). Medical implantable devices were present in 36% (n=41) of our patients, with urinary catheters being the most frequent (25% of the patients, n=28). Antibiotic treatment in the 30 days previous to the carbapenemase-resistant enterobacteriaceae detection had been prescribed to 71% (n=80) of the patients and 58% (n=46) had 2 or more antibiotic courses. The antibiotic classes most prescribed were penicillins (60%, n=48), third-generation cephalosporins (20%, n=16) and carbapenems (19%, n=15). Most of our patients (88%, n=99) had been hospitalized for more than 5 days prior to the sample collection or had a previous hospital stay in the 12 months before.

Conclusion

Carbapenem resistance is a major health threat that should be globally feared. Demographic changes are important in the risk of being infected/colonized with carbapenemase-resistant enterobacteriaceae strain, with older age being a trend in patients with these isolates. It is also worrying that most of these patients come from the community (even though most of them had prior

hospitalizations). Medical interventions, such as antibiotic treatment and medical devices, should always be carefully considered so as not to do more harm than good

#322 - Abstract

CARBAPENEM-RESISTANT ENTEROBACTERIACEAE IN A PORTUGUESE HOSPITAL – 5 YEAR ANALYSIS OF INFECTION CHARACTERISTICS, RESISTANCE MECHANISMS AND TREATMENT

Ana Gorgulho¹, Ana Maria Grilo¹, Manuel De Figueiredo^{1,2}, Joana Selada^{1,3}, Ana Paula Antunes¹, Carolina Sequeira¹

¹ Hospital de Cascais - Dr Jose de Almeida, Cascais, Portugal

² GCL-PPCIRA, Cascais, Portugal

³ SYNLAB - Lisboa, Lisboa, Portugal

Background

In the growing trend of carbapenemase resistance in our hospital, we aim to describe the main infection sites, bacterial species, resistance mechanisms, treatment and outcomes of carbapenemase-resistant Enterobacteriaceae isolates.

Methods

Retrospective analysis of patients admitted to a Portuguese regional Hospital between 2015 and 2018 who had carbapenem-resistant Enterobacteriaceae (CPE) isolates detected on any culture test performed. Analysis of these isolates' characteristics.

Results

We had a total of 113 patients with CPE isolates (104 from culture tests, 9 from rectal screening test) between 2015 and 2018. Urine was the site most affected (69%, with 8% of these also having bacteremia). The sputum was affected in 9% (10% of these with bacteremia), wound exsudates/surgical aspirates in 6%, ascitic fluid in 1% and 8% of the patients had isolated bacteremia. Only 65% of patients were considered infected, with the remaining being colonized.

From culture tests, *Klebsiella pneumoniae* was the most common bacteria (87%, n=90), followed by *Enterobacter cloacae* (10%, n=10) and *Escherichia coli* (3%, n=3), with only one *Citrobacter freundii*. OXA-48 was the most common carbapenemase, found in 62% (n=64) of our isolates, followed by KPC (15%, n=16). Two had a metallo-beta-lactamase (MBL), two a MBL plus AmpC enzyme and one a MBL plus KPC. The remaining were not conclusive. Co-production of ESBL occurred in 63% of isolates.

From the 104 culture tests, 88% were resistant to ertapenem but 74% remained susceptible to meropenem. The mortality rate at 30 days was 32% (39% in those infected and 9% in the colonized). Susceptibility-guided treatment was initiated in 54 patients. The treatment most used was meropenem+amikacin, followed by meropenem + colistin, meropenem alone, ceftazidime-avibactam, colistin alone and tygecyclin+colistin. Those treated with combination of antibiotic classes had better results.

Conclusion

Carbapenem resistance is a major health threat that does not leave many antibiotic options. It is interesting that our most common carbapenemase was OXA-48 since KPC is usually more common in our country. It retains more susceptibility to meropenem which aided treatment. Combination therapy with 2 or 3 antibiotic classes has been recommended. We have a small group of patients treated but those treated with a combination scheme had better results.

#323 - Case Report

CEREBELLAR ABSCESS – CLINICAL CASE

Lília Castelo Branco, Ana Margarida Coelho, Cátia Marisa Loureiro Pereira, Elisabete Pinelo, Eugénia Madureira

Internal Medicine Department, Unidade Hospitalar de Bragança, Unidade Local de Saúde do Nordeste, Bragança, Portugal

Introduction

Intracranial abscesses are uncommon life-threatening infections classified according to the anatomical location or the etiologic agent. The predisposing factors are underlying diseases (e.g. immunosuppression), disruption of the natural protective barriers surrounding the brain in 50% of the cases (e.g., due to an operative procedure, trauma, mastoiditis, sinusitis, or dental infection), or hematogenous spread in 1/3 (e.g., endocarditis or bacteremia). Elimination of infection before spread is the ideal prevention of complications.

Case description

A 69-year-old woman, immunocompetent, with hypertensive heart failure, presented to emergency department with temporo-spatial disorientation, somnolence and bilateral periorbital hematoma. She had a facial trauma in context of disequilibrium resulting in broken nose septum 10 days earlier, she was submitted to nasal tamponade and sept alignment on that time. Since that trauma she progressively lost the ability to walk and had more incoherent speech. On examination she was conscious, cooperative, disoriented in space and time, with dysmetria in cerebellum tests; nuchal rigidity, Kernig's and Brudzinski's signs, and cranial hypertension signs weren't present; march was not possible. Laboratory workup revealed neutrophilia and C reactive protein of 3.72 mg/dL. Head computerized tomography showed a right cerebellar lesion with poor defined limits with a gas focus inside, supratentorial hydrocephaly, posterior herniation of cerebellar amygdala and remodeling in right mastoid process. She was referred to neurosurgery. The magnetic resonance was suggestive of brain abscess. The treatment was empiric antibiotic therapy after blood cultures and surgical drainage. A multiresistant bacteria (*Proteus vulgaris*) was isolated from the collected pus susceptible to ceftazidime that was prescribed for 6 weeks with clinical and imagological favorable evolution. Blood cultures were negative and transthoracic echocardiogram had no suggestion of endocarditis. The patient was discharged to convalescence unit completing more 4 weeks with cotrimoxazole.

Discussion

Although rare, a cerebellar abscess may occur as a complication of head/facial trauma or otogenic/mastoid infections and require a high index of suspicion. The evolution of symptoms is extremely variable, but most patients present to the hospital until 12 days following the onset of symptoms. Appropriate imaging studies and multidisciplinary expertise are crucial in diagnosis and management.

#325 - Abstract

DO WE STILL NEED TO WORRY ABOUT MRSA INFECTIONS? 5-YEAR RETROSPECTIVE ANALYSIS OF MRSA ISOLATES IN A PORTUGUESE INTERNAL MEDICINE DEPARTMENT

Joana Azevedo Carvalho, Marisa Neves, José Delgado Alves
Medicine IV, Prof. Dr. Fernando Fonseca Hospital, Amadora, Portugal

Background

The European population-weighted mean methicillin-resistant *Staphylococcus aureus* (MRSA) percentage has been decreasing. In 2017, it was 16.9%. However, MRSA remains an important pathogen in Europe and the levels of resistance are still high in some countries. Portugal has a high percentage of invasive isolates with resistance to methicillin (25-50%).

We aim to characterize the population of patients with MRSA isolates in a Portuguese internal medicine department.

Methods

Retrospective analysis of patients with a MRSA isolate during the hospitalisation period, between January 2012 and December 2016.

Results

We included 100 patients with a median age of 73,0±14,5 years. Bacteraemia was the most frequent infection [42% (n=42)], followed by respiratory tract infection [26% (n=26)]. Colonization was considered in 8 patients. About 53% of *S. aureus* isolates had a minimum inhibitory concentration of vancomycin inferior to 0,5. Forty-three percent had another hospital-acquired infection during hospitalisation, namely *Pseudomonas aeruginosa* (n=21), *Acinetobacter baumannii* (n=10) and *Klebsiella pneumoniae* ESBL (n=10). Male sex (p=0.002) and a longer stay at the hospital (p=0.006) were associated with a second infection. The median duration of hospitalisation was 27 days [IQR:25]. The mortality during hospital stay in this population was 34% and 6 patients had died before the microbiological isolate has been determined. Previous antibiotic exposure within the last 3 months was associated with increased mortality [OR 5.985 (p=0.019)]. The total number of isolates of MRSA has been decreasing since 2013.

Conclusion

This study shows that MRSA isolates tended to decrease in recent years in Portugal, which has also been seen in other European

countries. MRSA infection is associated with a high mortality. Co-infection with different hospital-acquired bacteria is a threatening reality. The investment on the rational use of antibiotics and reduction in the duration of hospitalisations seem to be some of the urgent measures to decrease the incidence and mortality associated with resistant bacteria such as MRSA.

#327 - Case Report

REVIEW OF NOCARDIA INFECTION – ABOUT FOUR CASE REPORTS

Tiago Guimarães Costa¹, Henrique Rijo Elvas¹, Cláudia Costa², Luis Afonso², Margarida Mota², Vitor Dias²

¹ Centro Hospitalar de Vila Nova de Gaia, Porto, Portugal

² CHVNG, Vila Nova De Gaia, Portugal

Introduction

Nocardiosis is an uncommon gram-positive bacterial infection caused by aerobic actinomycetes in the genus *Nocardia*. Two characteristics of nocardiosis are its ability to disseminate and its tendency to relapse or progress despite appropriate therapy. Although there are no pathognomonic signs or symptoms of nocardiosis, it should be suspected in any patient who presents with brain, soft tissue, or cutaneous lesions and a concurrent or recent pulmonary process.

Case description

We describe 4 cases of nocardiosis, in patients with ages, at the date of diagnosis, comprised between 62 and 74 years, one in 2014, another in 2018 and two in 2019. Four different species (*N. cyriacigeorgica*, *N. exalbida*, *N. farcinica* and *N. africana/nova*) were isolated in lung, ocular and cerebral biopsies and in cultures of the bronchial lavage and hemocultures. Of the four patients, 3 were immunodepressed and 1 was immunocompetent. All patients presented with pulmonary involvement, and 3 presented disseminated disease with concomitant cerebral involvement and of these, one also presented ocular involvement.

After the diagnosis, all started trimethoprim-sulfamethoxazole at similar doses (15 mg/kg/day) divided into 2, 3 or 4 doses. In association with this drug, 2 started ceftriaxone and the other 2 the meropenem, and one patient still performed a third association with linezolid.

Discussion

Nocardiosis has a broad range of clinical presentations and can present similarly to several other infections as well as malignancy. The lungs are the primary site of nocardial infection in more than two-thirds of cases. *Nocardia* appears to have special tropism for neural tissue, and the hallmark of CNS nocardiosis is formation of a parenchymal abscess that can occur in any region of the brain. Clinical isolates of *Nocardia* spp. are variably resistant to antibiotics. As a result, it is recommended empiric coverage with two or three agents in patients with severe infection.

Most authorities recommend trimethoprim-sulfamethoxazole

(TMP-SMX) as part of first-line therapy for nocardiosis. The optimal duration of antimicrobial treatment for severe disease has not been determined, but most recommend a prolonged course because of the relapsing nature of *Nocardia* infection, and can vary between 3 months to more than a year.

#328 - Case Report

SECOND AUTOCHTHONOUS CASE OF INFECTION BY THE VIRUS PRODUCING THE CRIMEAN-CONGO HEMORRHAGIC FEVER IN SPAIN. IDENTIFICATION OF A NEW VIRUS

Cristina Arroyo¹, Marco Antonio Budiño¹, María Escamilla¹, Demetrio Sánchez¹, María Angeles Garcinuño¹, César Alberto De La Hoz¹, Rafael Sánchez¹, Sonsoles Sánchez¹, María Paz Sánchez-Seco², Ana Isabel Negro²

¹ Complejo Asistencial de Avila, Avila, Spain

² Instituto de Salud Carlos III, Madrid, Spain

Introduction

The virus producing the Crimean-Congo Hemorrhagic Fever (CCHF) is a febrile disease that can lead to a severe and often fatal hemorrhagic disease. It is produced by a virus of the genus *Nairovirus* and transmitted to humans by infected ticks of the genus *Hyalomma*. The presence of CCHF has been confirmed in ticks captured on wild animals in large areas of the central and southwestern Iberian peninsula. However, infection was only described in humans in 2016 when a man developed a fatal condition after being bitten by a tick in the province of Avila (Castilla y León, Spain) and infected a nurse who was taking care of him during his stay in a hospital in Madrid. In both cases, it could be determined that the virus belonged to the Africa III phenotype.

Case description

It was a patient of 74 years, with the following personal history; hypertension, and active smoker. On July 31st 2018, he went to the Emergency Department of the Hospital N^o S^a de Sonsoles on Ávila (Castilla y León) for a sudden onset of chills with shivering, fever of up to 39 degrees centigrade and lumbago. On August 4th, the patient returned to the Emergency Room. In addition to fever, also referred headache, myalgias, arthralgias, dizziness, nausea, abdominal pain and diarrhea without pathological products. We proceeded to hospital admission. The patient then referred to having participated on July 24th in a hunt boar in the town of Helechosa de los Montes (Badajoz, Extremadura). He reported having a tick removed from his back, although no bite injury was observed on physical examination. He presented non-pruritic petechial lesions on the anterior face of both lower extremities. In the analytic, plaquetopenia and slight alteration of the hepatic profile were highlighted. On August 7th, there was a clinical deterioration associated with intense cytolysis, coagulopathy and active bleeding in areas of venipuncture. The patient died due to circulatory collapse at 3:30 am on the morning of August 8th. Since blood samples were kept in the laboratory, they were sent

to the National Center of Microbiology for detection of RT-PCR of CCHF, reporting as positive.

Discussion

The virus that caused this fatal case was the product of a genetic rearrangement ("reassortment") genotype III/IV, a phenomenon described in CCHF. In Spain, there are at least two different viruses that can cause fatal cases of Crimean-Congo haemorrhagic fever.

#345 - Abstract

USE OF THE ARM ANKLE INDEX FOR THE DETERMINATION OF CARDIOVASCULAR RISK IN HIV PATIENTS

Susana Vicente Rodrigues¹, Diego Jose Gudiño Aguirre², Máximo miguelez Morales¹

¹ Servicio de Medicina Interna, Hospital Universitario Nuestra Señora de La Candelaria, Santa Cruz De Tenerife, Spain

² Servicio de Medicina Interna, Hospital Universitario Nuestra Señora de La Candelaria, Santa Cruz De Tenerife, Spain

Background

Cardiovascular disease has become an important cause of morbidity and mortality in patients infected with the human immunodeficiency virus (HIV). The introduction of highly active antiretroviral therapy (HAART) has drastically reduced mortality related to HIV infection, however, the increase in patient survival, the high prevalence of traditional cardiovascular risk factors and metabolic disorders produced by antiretroviral drugs have contributed to an increase in cardiovascular risk in this population.

Aims

To know the prevalence of cardiovascular risk factors and try to demonstrate the usefulness of using the Index Ankle Arm in vascular risk stratification comparing with Framingham equation in HIV patients.

Methods

A longitudinal observational study was designed on a target population of 302 patients. Another study was nested observational (phase II) among that population of high cardiovascular risk. A questionnaire about cardiovascular risk factors, blood tests, and ankle-brachial index were performed in all cases. Cardiovascular risk at 10 years was assessed by Framingham equation.

Results

85.5% were males with an average age of 36 years. 89.4 % received antiretroviral therapy, among them 36.5% received protease inhibitors. The prevalence of cardiovascular risk factors was the following: hypertension: 27%; diabetes 3%; smoking 45%; hypercholesterolemia 40%; hypertriglyceridemia 28%; overweight or obesity 38%. 39.7% patients had high cardiovascular

risk according to Framingham equation. We had a mortality of 2.3% and a cardiovascular event rate of 12x10³ people/year. Values of ankle-brachial index were altered in 32.8% cases.

Conclusion

There is a high prevalence of cardiovascular risk factors in the HIV population. We think that is required the development and use of cardiovascular risk categorization in clinical practice models developed in subjects with HIV infection, which besides the presence of traditional cardiovascular risk factors consider exposure to antiretroviral therapy and possibly also incorporating or other ways to determine vascular risk stratification such as the ankle-brachial index.

#353 - Case Report

VISCERAL LEISHMANIASIS - A CASE OF A YOUNG FEMALE IMMUNOCOMPETENT PATIENT

Miguel Rodrigues Monteiro, Filipa Gomes, João Machado
Hospital Professor Doutor Fernando da Fonseca, Amadora, Portugal

Introduction

Visceral Leishmaniasis (VL) or Kala-azar is a parasitic disease caused by the protozoan *Leishmania* which is transmitted by the bite of infected female phlebotomine sandflies. The estimated global incidence of leishmaniasis is 0.7 to 1 million new cases per year, from which 50,000 to 90,000 are attributed to VL, the majority caused by *Leishmania donovani* and *Leishmania infantum* species. In the Mediterranean basin, *L. infantum* is the endemic species, the dog is the main host and reservoir for human visceral infection and most cases occur in rural environments. Without treatment, VL is fatal in two years in more than 90% of cases.

Case description

A 29-year-old portuguese woman, previously healthy, presented in the emergency department reporting symptoms dating back to two months earlier, consisting of moderate grade intermittent fever, chills, night sweats, 10% weight loss, anorexia and asthenia. She lived in a rural area, had frequent contact with wild dogs and had not travelled to an endemic area previously. Examination revealed fever (39.9°C), tachycardia, discrete generalized hyperpigmentation of the skin, conjunctival icterus, enlarged liver 10 cm under the right costal border, nontender to palpation, enlarged spleen reaching the left lumbar region and lower limb symmetrical edema. Laboratory parameters revealed pancytopenia (Hb 7.0 g/dL, 2.0x10⁹ leukocytes/L and 29x10⁹ platelets/L), elevated ESR (120 mm/h) and PCR (2.16 mg/dL), elevated coagulation tests, cyto-cholestatic pattern with hyperbilirubinemia, hypoalbuminemia and polyclonal hypergammaglobulinemia with elevated IgG (4.52 g/L). HIV testing and other viral serologies were negative. Blood and sputum cultures were negative. The abdominal and pelvic computed tomography revealed an important hepatosplenomegaly. A bone

marrow biopsy was done, which revealed *Leishmania amastigotes*. The serum *Leishmania* serology and PCR were negative. The patient was treated with liposomal amphotericin B, with rapid clinical and analytical recovery.

Discussion

VL is commonly associated with immunocompromised states in non-endemic regions, being HIV-*Leishmania* co-infection the most prevalent one. For instance, a rare case of VL was reported in an immunocompetent patient, provided that only 15 to 20 cases of VL are diagnosed each year in Portugal in this group of people. Since VL is a potentially fatal and infrequent disease, it is important to have a high index of suspicion, so that a successful treatment can be achieved.

#365 - Medical Image

MOTH-EATEN ALOPECIA AS A MANIFESTATION OF SECONDARY SYPHILIS

Vicente David De La Rosa Valero, Maria Del Carmen Hernández Murciano, Elena Del Carmen Martínez Cánovas, Carlos Báguena Pérez-Crespo, Ignacio Iniesta-Pino Alcázar, Gabriel Puche Palao, Ana Martín Cascón, Mónica Martínez Martínez, Francisco Javier Hernández Felices, Enrique Bernal Morell

Hospital General Reina Sofía De Murcia, Murcia, Spain

Clinical summary

A 16-years-old male from Manaus (Brazil) consulted for alopecia of two weeks. He had sexual relations without preventive measures. HIV, hepatitis and lues serology were performed. Reagin antibodies (RPR 1/32) and treponemal antibodies were positive (TPHA 1/2560), without other alterations. He denied having presented any manifestation of primary syphilis, although, there were numerous alopecic plaques on the scalp of irregular distribution, of non-scarring characteristics, without inflammatory signs or desquamation and predominantly in occipital region. The dermatological lesion described is called moth-eaten alopecia, an infrequent sign of secondary syphilis. It was treated with a single dose of penicillin G benzathine (2,400,000 IU) and resolved completely after three months.

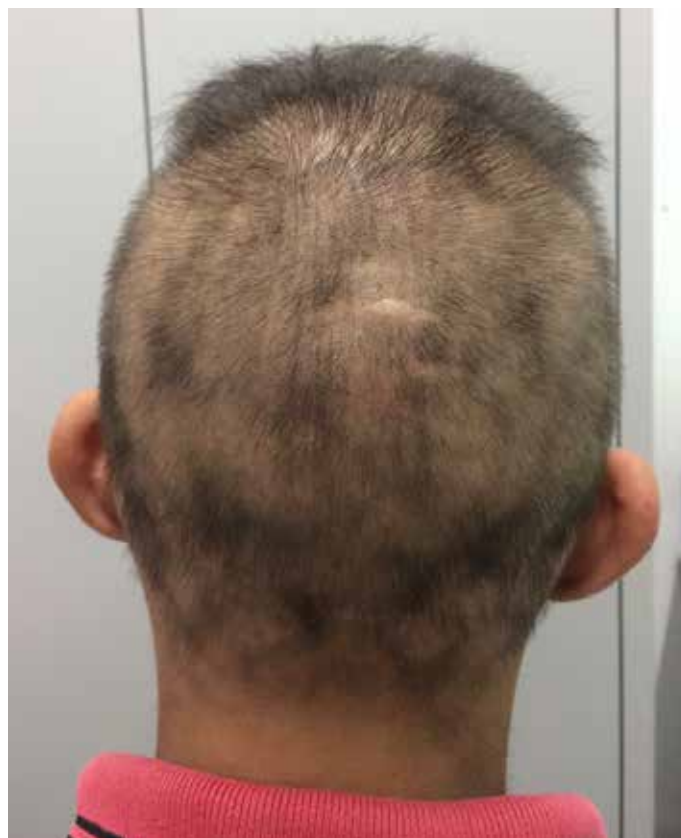

Figure #365.

#385 - Case Report

LYMPH NODE TUBERCULOSIS - A DIFFICULT DIAGNOSIS

Mafalda Ferreira, José Eduardo Mateus, Rita Gomes, Helder Esperto, José Bernardes Correia, Armando Carvalho
Centro Hospitalar e Universitário de Coimbra, Coimbra, Portugal

Introduction

Lymph node tuberculosis is the most frequent form of extrapulmonary tuberculosis and it can pose a problem as it makes differential diagnosis with other pathologies such as lymphoproliferative diseases or sarcoidosis.

Case description

A 69-year-old woman, hospitalized for progressive debilitation, unintentional weight loss of 20 kg in 3 months (>10%) and modification of the usual intestinal pattern associated with increased abdominal volume and early satiety. She denied fever, anorexia, nausea, vomiting or other symptoms. She had a past medical history of type 2 diabetes and hypertension; no epidemiological context was identified. Examination revealed decreased sounds in the right pulmonary base, distended abdomen with central tympanism and a discrete edema of the ankles. She performed abdominal ultrasound that showed ascites and right pleural effusion. Upper and low digestive endoscopy showed no alterations. CT scan showed massive right pleural effusion, multiple supra and infra-diaphragmatic adenopathies,

splenomegaly and omental fat densification, omental cake type. PET-CT detected hypermetabolic involvement of the peritoneal and supra and infra-diaphragmatic ganglion. All microbiology tests including Ziehl–Neelsen staining and molecular biology for mycobacteria in several biological products were negative.

Excision of cervical adenopathy revealed necrotizing granulomatous lymphadenitis of unknown cause. No change in peripheral blood or ganglion immunophenotyping. Bronchofibroscopy and thoracentesis of subpulmonary effusion were performed with cloudy and thick orange fluid drainage. We also performed a biopsy of retroperitoneal adenopathy guided by CT. Although there was no identification of mycobacteria, after extensive medical team discussion, anti-bacillary therapy was started. One week later Mycobacterium tuberculosis complex was isolated from lymph node biopsy.

Discussion

After extensive study the neoplasm hypothesis became less likely. The clinical debate between peers is fundamental for diagnostic and therapeutic management of complex clinical cases like this one. At this moment, the patient has no complains, and tuberculostatic therapy will be completed soon.

#403 - Case Report

AN ATYPICAL CASE OF SPONDYLODISCITIS

Catarina Cabral, Joana Alves Vaz, Maria Manuela Soares, Isabel Madruga

Hospital de Egas Moniz - Centro Hospitalar de Lisboa Ocidental, Lisboa, Portugal

Introduction

Spondylodiscitis is defined as an infection that destroys the vertebral bodies, with secondary involvement of the intervertebral discs. It is usually a monobacterial infection and most cases in Europe are caused by *Staphylococcus aureus*. The most common pathogen worldwide is *Mycobacterium tuberculosis*.

Case description

65-year-old, caucasian, male. Personal background of arterial hypertension, dyslipidemia, peripheral venous disease, smoker (45 SPY). Medicated accordingly, with no allergies or surgeries described. Patient resorts to the Emergency Room (ER) complaining of cervical and dorsal pain, with inflammatory rhythm and functional limitation. The patient's family doctor prescribed ketoprofen and thiocholchicoside with partial relief. Due to maintenance of symptoms it was ordered a vertebral column CT which revealed suspicion of spondylodiscitis/neoplasm. At the ER the patient was observed by Neurosurgery, detecting pain during palpation of the interscapular region and right cervical rotation limitation. Neurologic exam and analytic evaluation were unremarkable. The MRI demonstrated spondylitis vs spondylodiscitis (with abscessed paravertebral components D1-D2 and D12-L1 and inflammatory/infectious disc-vertebral

and right posterior articular infiltration C5-C6 and right C6-C7 periarticular tissues); Central spinal stenosis in C5-C6 and C6-C7, posteromedial disc protrusions and hypertrophy of the yellow ligaments, with medullary compression, C5-C6 with central myelomalacia and atrophy. The patient was admitted for etiologic study and treatment. Of the performed study, we highlight negative seriated hemocultures; negative HIV 1 and 2, Brucella, Troponema Pallidum and IGRA; positive IgG CMV; positive IgG EBV; positive AchBs and AchBc; negative AgHBs; HBV viral load: < 20IU/mL; negative AchHCV. The patient was empirically medicated with meropenem and vancomycin for 4 weeks, with partial regression of the lesions and pain relief. After new evaluation by Neurosurgery, the patient was proposed to anterior cervical discectomy and cage placement, which was uneventful. The patient was discharged and maintained follow-up on Neurosurgery and Internal Medicine.

Discussion

The average period between the first symptoms and diagnosis has been reported to be two to six months, due to diffuse symptoms. This case shows that differential diagnosis is vast and patients are frequently thought to be suffering from degenerative diseases, delaying much needed treatment.

#415 - Case Report

LYMPH NODE TUBERCULOSIS: A CHALLENGE DIAGNOSIS

Joana Sousa Morais, Isabel Andrade Oliveira, Olga Pires, Inês Burmester, Maria João Regadas, Paulo Gouveia

Hospital de Braga, Braga, Portugal

Introduction

Lymph node tuberculosis is uncommon in developed countries and is more prevalent in immunocompromised patients. Diagnosis is often only possible because of high clinical suspicion and treatment is usually long lasting.

Case description

Male, 81 years old, with a history of hypertension, gastritis and thrombocytopenia in study. Referred to the Internal Medicine consultation for asthenia, adynamia, anorexia and weight loss (10 kg) with 6 months of evolution, associated in the last 2 months of fever of nocturnal predominance, and hypersudorese, without other complaints. Of the previously performed complementary exams, to emphasize, pancytopenia and increased sedimentation velocity and in abdominal imaging multiple abdominal adenopathies dispersed. Therefore, patient was admitted for study, however, due to the high clinical suspicion and worsening of the general condition of the patient during the first days of hospitalization, anti-tuberculous therapy was initiated (ethambutol, rifampicin, isoniazid and pyrazinamide). During hospitalization, confirmation of fever and nocturnal hyperhidrosis and in abdominal and pelvic CT of several necrotic retroaortic, mesenteric, duodenal and retroperitoneal adenopathies. Therefore, a lymph node biopsy

was performed, only possible by laparoscopic surgery and a IGRA test was requested, whose results, later available, were respectively granulomatous lymphadenitis with necrosis (Ziehl-Neelsen negative) and positivity. Two weeks after starting treatment, patient with good clinical evolution, and therefore was discharged, maintaining the follow-up in Internal Medicine consultation. 6 months later, patient with clinical improvement, namely weight recovery, sustained afebrile and recovery of muscle strength, abdominal and pelvic CT were repeated, where no adenopathies were identified.

Discussion

This case stands out, for presenting some of the most typical clinical findings of tuberculosis, however, with uncommon organ involvement and no evidence of lung injury. It is also worth noting, the lack of agent isolation in all the requested tests, but an excellent response to anti-tuberculous treatment, demonstrating the importance of the signs and symptoms, in detriment to the complementary exams, in some clinical cases.

#427 - Case Report

A RARE COMPLICATION OF INFECTIOUS MONONUCLEOSIS DUE TO EPSTEIN-BARR VIRUS

Joana Carreiro, Catarina Machado, Maria Guadalupe Benites, Almerindo Rego

Terceira Island Santo Espirito Hospital, Angra Do Heroísmo, Portugal

Introduction

Epstein-barr virus (EBV) is a highly prevalent, widespread virus, and the most common cause of infectious mononucleosis (IM), which can have a wide spectrum of clinical presentations most commonly asymptomatic infection or with symptoms like fever, sore throat and lymphadenopathy. Abdominal pain, albeit uncommon, can be the result of splenic enlargement. Various complications associated with IM due to EBV infection have been described.

Case description

We present a case of a 44 year old male that presented initially with anorexia, asthenia, myalgias, fever with maximum temperatures of 40°C and abdominal pain with 1 week of evolution. On examination he had a fever of 38°C, a painful abdomen on palpation of the upper quadrants, a palpable liver (~2 cm below the costal grid) and a palpable spleen. Analytically he presented with leukopenia (2560/ul) and thrombocytopenia (80000/ul), and elevated lactate dehydrogenase, aspartate transaminase, alanine transaminase and C reactive protein. Abdominal ultrasound confirmed hepatosplenomegaly. The patient was admitted to the medical ward for surveillance and further study.

The serology for EBV viral capsid antigen (IgM and IgG) was positive and such the diagnosis of IM due to EBV infection was confirmed. Later the patient developed symptoms of sore throat

and, on examination, a tonsillar enlargement was observed. Since he maintained complaints of abdominal pain, now localized on the upper left quadrant he was submitted to a CT-scan that revealed an splenic infarction, which was assumed as a complication of the EBV infection.

Further analytical studies revealed an homozygosity to the MTHFR gene and a protein S deficiency.

During his hospital stay, the patient improved clinically, with resolution of the fever and the abdominal pain.

On a follow up consultation, 3 months later, his protein S levels remained low, so it was decided to begin anticoagulation therapy.

Discussion

Although rare, cases of splenic infarction in patients with IM due to EBV infection and presenting with abdominal pain have been described. In some case reports it is suggested the EBV infection leads to a transient procoagulant state, while others described it as a first manifestation of a thrombophilia. In this case it appears to be the latter hypothesis. A thrombophilia screening should be considered in all cases of splenic infarction in patients with IM due to EBV infection, and a reassessment of those results should be performed on a follow up consultation.

#429 - Abstract

FIVE YEARS OF LEPTOSPIROSIS

Joana Carreiro, Maria Beatriz Santos, Magda Garça, Maria Guadalupe Benites, Almerindo Rego

Terceira Island Santo Espirito Hospital, Angra Do Heroísmo, Portugal

Background

Leptospirosis is a zoonosis most common in developing countries. In Azores there's an increase of its incidence (11 cases per 100,000 inhabitants), in comparison with the rest of the country. The clinical presentation may vary between influenza like symptoms to an icterohemorrhagic form (Weil syndrome).

The goal was to characterize the population of patients with leptospirosis diagnosis over the past five years, documenting the most common symptoms, laboratorial alterations and therapeutic measures used.

Methods

Systematic review of inpatients' files with final diagnosis of leptospirosis, from 2014 to 2018, admitted to the Internal Medicine ward.

Results

There were a total of 65 cases of leptospirosis in five years, approximately 13 cases per year (23 cases/100,000 inhabitants), mostly male (95%), with ages comprised between 18 and 78 years. 94% had a known epidemiological context for the disease. The most common symptoms were fever (100%), myalgia (98%), chills (82%) and headache (54%). 25% developed respiratory symptoms, 12% jaundice and 5% hemorrhagic symptoms. One presented with

myocarditis an 17 cases were admitted to the intensive care unit. Regarding the laboratorial testing 89% of the patients presented with hematuria, 85% with thrombocytopenia and 83% with elevation of liver enzymes. 58% of the patients presented increased bilirubin and kidney function was compromised in 40% of cases.

20 patients had positive antibodies to leptospira spp, 26 had PCR positive for leptospirosis interrogans and 8 patients had a positive microagglutination test.

The antibiotics used were doxycycline (36%), ceftriaxone (41%) and penicillin (26%).

Conclusion

Being an area that has mild climate and in which the main form of income is agriculture-based jobs, Azores have a higher incidence of leptospirosis than the rest of the country. Its symptoms are highly variable and thus its diagnosis is challenging, leading sometimes to its be overdiagnosis.

#449 - Case Report

DISSEMINATED HERPES INVOLVING THE SACROILIAC PLEXUS IN AN IMMUNOCOMPROMISED PATIENT

Andreas Antonakis¹, Melina Kavousanaki¹, Spiros Stavratidis¹, Emmanouil Giannakoudakis², Konstantinos Psillakis³, Nikolaos Papanikolaou¹, Sotirios Souris¹

¹ A' Internal Medicine Department, Venizeleio General Hospital, Heraklion Crete, Greece

² Neurology Department, Venizeleio General Hospital, Heraklion Crete, Greece

³ Radiology Department, Venizeleio General Hospital, Heraklion Crete, Greece

Introduction

Varicella zoster virus associated plexopathy is a rare post-ganglionic peripheral neuropathy usually allocated in the brachial plexus. Herein, we describe the case of an immunocompromised patient who was diagnosed with disseminated herpes and plexopathy in the rather unusual anatomical position of the sacroiliac plexus.

Case description

A 52 year old woman with history of bone marrow transplantation for acute biphenotypic leukemia presented with generalized rash of two days. She also complained of left lower limb paresthesia, weakness and hip pain dating five days for which she had been examined by an orthopaedic. She had undergone a lumbar spine MRI scan (without use of intravenous contrast agent) that only revealed a known spinal disc protrusion at the L3-L4 level without spinal cord compression. Objective examination at her presentation revealed focal neurological deficit involving her left L4-S1 neurotomes, i.e. reduced power in dorsi flexion - inversion and eversion of the foot and inability in plantar flexion with loss

of sharp sensation allocated to the respective dermatomes. The plantar reflexes were normal bilaterally and she did not have any signs indicating meningism. We performed lumbar puncture that revealed lymphocytic pleocytosis (998 cells per μ L - 95% lymphocytes) and a biochemical profile compatible with viral central nervous system infiltration. Cerebrospinal fluid polymerase chain reaction and peripheral blood IgG and IgM serology tests were positive for VZV. Peripheral blood and CSF immunophenotype and CSF cytology were negative for leukemia relapse. The patient underwent contrast enhanced MRI scan that demonstrated high signal and asymmetrical enhancement of left L4-S1 nerves - compatible with lumbosacral plexopathy. She received intravenous antiviral therapy for four weeks, the rash resolved and her neurological status was partially ameliorated. However, the patient suffered from intense postherpetic neuralgia thereafter. An electromyogram was performed following her discharge that confirmed the diagnosis of lumbosacral plexopathy.

Discussion

Varicella associated sacroiliac plexopathy is a rare and poorly described disease with atypical laboratory and imaging findings. It can be easily misdiagnosed with other peripheral polyneuropathies and is associated with high incidence of postherpetic neuralgia and permanent neurological deficits. Thus, description of more such cases is necessary to improve diagnosis and management of this very clinical entity.

#452 - Case Report

A 50-YEAR-OLD MAN WITH ABDOMINAL PAIN AND SPLENOMEGALY

Javier Béjar-Valera, Gerardo Alonso-García, María José Serna-Muñoz, Fabio Hugo Escobar-Arias, Hermógenes Francisco Fernández-Muñoz, Begoña Soledad Muiña-Juárez, Antonio Miguel Navarro-Castro, Adela Periago-Peralta, María José Romero-Orcajada

Rafael Méndez Hospital, Lorca, Spain

Introduction

The finding of splenomegaly in a patient is always a diagnostic challenge that is interesting for the professional. We have to take into account all the possible causes that can produce it: hepatic, infectious, immunoregulation disorders, hematological and others such as amyloidosis, sarcoidosis or deposits diseases.

Case description

A 50-year-old male from Morocco without known drug allergies or toxic habits, with a personal history of rheumatoid arthritis with a positive rheumatoid factor and on treatment with Metotetrate 20 mg, 5 mg folic acid, 5 mg prednisone and 20 mg omeprazole. Independent for all the basic activities of daily life.

He went to the hospital for abdominal pain of two weeks of evolution in both hypochondria without irradiation, accompanied by asthenia, generalized weakness and cough without expectoration. In

addition, two days before the consultation, he also had a sensation of dysthermia and profuse sweating. A month and a half prior to the current consultation he made a trip to his country.

The physical examination revealed a temperature of 38,9°C and an annoyance to palpation in mesogastrium. Rest of the exploration completely normal exploration. PCR 9.62 mg/dl, leukocytes 2600/uL, neutrophils 1300/uL, lymphocytes 900/uL, hemoglobin 11.8 g/dL and platelets 77000/uL. Ultrasonography of the abdomen showed a splenomegaly of 14.6 cm in length. Coagulation, urine, chest x-ray and electrocardiogram are normal.

At this time, we consider the differential diagnosis about the probable causes of pancytopenia and splenomegaly of our patient: Felty syndrome, sarcoidosis, leishmaniasis, viriasis, medullary aplasia secondary to methotrexate, medullary infiltration or primary spinal cord disease.

The serology of Leishmania was positive for Leishmania infantum so treatment was initiated with liposomal amphotericin B. In the bone marrow aspirate, an intraleukocyte infestation inside the macrophages was observed. And in bone marrow biopsy, a presence of structures compatible with Leishmania within macrophages was observed. The PCR of Leishmania spp in bone marrow was positive. Therefore, the definitive diagnosis of our patient was that of Visceral Leishmania or Kala-Azar by Leishmania infantum.

Discussion

Given the important prevalence of the Moroccan population in our health Area and the frequent contact of southern Spain, where our hospital is located, with North Africa, it makes us an area where the diagnosis of Leishmaniasis is not very rare.

#455 - Case Report

A 71-YEAR-OLD MAN WITH PAIN IN THE LEFT MAXILLA

Javier Béjar-Valera, Gerardo Alonso-García, Hermógenes Fernández-Muñoz, María José Serna-Muñoz, Begoña Soledad Muiña-Juárez, Adela Periago-Peralta, Antonio Miguel Navarro-Castro, María José Romero-Orcajada

Rafael Méndez Hospital, Lorca, Spain

Introduction

A 71-year-old man with no known drug allergies or toxic habits. Personal history of type 2 diabetes mellitus, dyslipidemia, stable chronic ischemic heart disease, right peri-insular ischemic stroke, normal LVEF and multiple myeloma IgG in early progression. In chronic treatment with calcium carbonate 600 mg, risedronic acid 5 mg, clopidogrel 75 mg, rosuvastatin 20 mg, patches of nitroglycerin 15 mg, bisoprolol 2.5 mg, rabeprazole 20 mg, linagliptin 5 mg and solifenacin/tamsulosin 6/0,4 mg.

Case description

The patient presents pain in the left maxilla of a week of evolution without fever and without other symptoms added. The physical examination is anodyne unless there is exposure of the left

maxillary bone. In the analytical, it was highlighted: 14,000/uL leukocytes, 70% neutrophils and 12 mg/dl CRP. Normal chest x-ray and electrocardiogram. The first suspicion was of maxillary osteonecrosis secondary to treatment with bisphosphonates, so facial and sinus CT scans were requested in which a lytic lesion could be seen with some sclerosed areas in the left upper jaw bone with extension to the left maxillary sinus. It is diminished in size and occupied by soft tissue density material.

Subsequently, maxillofacial surgery was used to perform surgical excision of the lesion in the left maxillary bone and during surgery biopsy of the maxillary sinus material was taken for pathological anatomy. In the biopsy were found "sulfur granules" composed of microorganisms compatible with *Actinomyces israelii*, so we are facing a case of actinomycosis in a patient with osteonecrosis of the left maxilla.

After surgery, the patient persists afebrile and hemodynamically stable. Intravenous penicillin is administered for 2 weeks with good clinical response. After hospital discharge, the patient was prescribed treatment with oral amoxicillin for 6 months and, subsequently, in the outpatient clinic to decide whether or not to continue antibiotic treatment.

Discussion

Actinomyces israelii is a gram-positive bacillus that is part of the oropharyngeal and colonic flora. Actinomycosis is a suppurative granulomatous infection of subacute or chronic evolution that extends by contiguity without respecting the tissue planes and tends to fistulization and extensive fibrosis formation. Due to the increased use of bisphosphonates, the prevalence of maxillary or mandibular osteonecrosis has increased in recent years. In addition, as a peculiarity of this case, the patient develops a secondary actinomycosis.

#457 - Case Report

IN SICKNESS AND IN HEALTH... FOODBORNE BOTULISM IN A MARRIED COUPLE

Valeria Giosia^{1,2}

¹ University of Milan, Milan, Italy

² Fatebenefratelli Hospital, Milan, Italy

Introduction

Foodborne botulism is a rare, life-threatening disease. Symptoms result from *C. Botulinum* neurotoxins (BoNT) ingestion, leading to descending paresis up to respiratory insufficiency due to diaphragm and upper airway muscles paralysis. Symptoms onset ranges from 12-36 hrs to weeks after infection, resulting in more difficult clinical suspicion.

Antitoxin is the main therapeutic option but should be administered as early as possible.

Disease incidence is decreasing but Italy keeps on having one of the highest rates in Europe (20-30 cases/year), also due to the traditional production of home-canned food. Thus, botulism should be suspected, also if considered rare.

Case description

A 63-year-old woman and her 71-year-old husband presented to the emergency room with vomit and diarrhea started 3 days after eating an Italian dessert (panettone). The man was discharged in good clinical conditions while his wife was hospitalized with acute renal insufficiency associated with gastroenteritis.

Six days later she developed ptosis, dysphonia, dysphagia, dyspnea and signs of respiratory distress. She was thus transferred to the Intensive Care Unit.

Contemporarily, her husband presented again to the emergency room with dysphagia, dyspnea, severe respiratory insufficiency and stupor. They were both hospitalized in the ICU, with invasive ventilation and enteral tube feeding.

Given the presentation and disease course, started with gastrointestinal symptoms and evolved with respiratory distress, foodborne botulism was suspected and blood and stool samples were collected. BoNT detection in blood was negative while BoNT producing genes were found with PCR on stools of both patients, confirming the diagnosis.

Antitoxin was not administered given the prolonged interval from infection to diagnosis but patients underwent complete recovery with support therapy alone.

Deeper anamnestic collection showed that the couple also ate home-canned tomatoes and sausages, typically associated with botulism. Food samples were analyzed, resulting negative. Analysis of the meal actually eaten by the couple was however impossible.

Discussion

Foodborne botulism is a public health challenge. It should always be suspected in case of progressive weakness, paralysis and respiratory difficulty even if the course may be atypical, to allow early treatment and diagnosis. A full dietary history should be collected, including all food eaten. When available, remnants should be analyzed. Prompt reporting to authorities is necessary.

#465 - Case Report

BILATERAL PANUVEITIS

Carlos De La Torre Solís¹, María Guil García², Patricia De La Palma Fernández Ramos¹, Jose Antonio Lomeña Villalobos¹, Silvia Moga Lozano¹, Ricardo Gómez Huelgas²

¹ Centro de Salud de Torre del Mar, Vélez-Málaga, Spain

² HRU Málaga, Málaga, Spain

Introduction

Uveitis are part of immunological, infectious, tumoral or idiopathic diseases. Know the etiology and be able to perform a correct treatment, is a challenge for the internist.

Case description

22-year-old male with pain, conjunctival hyperemia and ptosis in the left eye for a month. In treatment for ophthalmology for two weeks, two days ago the same symptoms in the right eye. Eczematous skin lesions on arms and abdomen. Unquantified

weight loss, no fever, no night sweats, no photosensitivity, no arthritis, no arthralgias.

Ophthalmological examination: right eye: miosis; left eye: dysflexic mydriasis

Both eyes: Tyndall +++

Right eye fundus: vitreous turbidity ++. Lower area with white necrosis

Left eye fundus: vitreous turbidity ++. Lower and temporary region to macula with white necrosis.

With the diagnosis of bilateral panuveitis and progressive external necrotizing retinitis due to herpes simplex associated with HIV, the patient is admitted for study with treatment with acyclovir IV, penicillin, ganciclovir and methylprednisolone prior to the study.

The blood count and elemental biochemistry are normal.

Serology: VIH screening (+), Western-Blot VIH (+), HBsAg (-), Ac AntiHBs (-), Ac Anti HBC (-), Ac Anti HVC (-), RPR 1/64, Ac Anti Syphilis Total (+) Ac Anti CMV IgG (+) and IgM (+), Toxoplasma IgM and IgG (-) EBV IgG (+) IgM (-). Anti VHA (-)

CD4 lymphocyte subpopulations 483 (36%), viral load 94043 cop/ml Quantiferon-TB (-, HLAB5701 (-)

PCR in blood: HSV1, HVS2, CMV, EBV (-)

PCR in aqueous humor HSV1, HSV2, CMV, EBV y varicella zoster (-)

Chest x-ray: (-)

After the results, penicillin and methylprednisolone are maintained 14 days, with gradual improvement of uveitis, being diagnosed of bilateral panuveitis with acute retinal necrosis of syphilitic cause, HIV primoinfection and neurosyphilis of ocular involvement

Discussion

Worldwide there are about 12 million new cases of syphilis each year. Of these, 10% In Europe and the United States, the majority of reported cases have been men, particularly those who have sex with other men.

The coinfection *Treponema pallidum* and HIV, alters its natural course and the typical clinical presentation of the disease.

In all patients with ocular syphilis, the presence of HIV infection should be ruled out; both diseases share the same risk factors, and both may be present.

Ocular syphilis may be more severe in HIV-infected patients who are not receiving antiretroviral therapy.

#466 - Case Report

BACTEREMIA RELATED TO INDWELLING CENTRAL VENOUS CATHETERS CAUSED BY PANTOEA AGGLOMERANS

María José Redondo Urda, Juan Carmona García, Igor Andronic, Carlos Hernando Martín, Purificación Sanchez Oliva, Ruben Berriel Martín, Araceli Sánchez Sánchez

Hospital Santa Bárbara, Soria, Spain

Introduction

The strains of *Enterobacter* are opportunistic pathogens. *Enterobacter cloacae* and *Enterobacter agglomerans* (currently

called *Pantoea agglomerans*) belong to this group. Next we will discuss a case of bacteremia by *Pantoea agglomerans* that we have recently diagnosed.

Case description

82-year-old woman with a personal history of breast cancer, treated the previous year with surgery, adjuvant chemotherapy and radiotherapy. She carries since then, a subcutaneous reservoir (port-a-cath), which had been manipulated the previous week. She was seen in the emergency department for a feverish peak of 38°C, shivering and dysuria. The exploration highlighted BP 95/59, temperature 38.2°C and regular general condition. At the analytical level, moderate neutropenia (700/ μ L), elevated C reactive protein (60.1 mg/dl) and procalcitonin (11.24 ng/ml) and systematic normal urine were observed. She was admitted to the Internal Medicine department and empirically treated as a urological sepsis with Piperacillin/tazobactam. Urine culture was negative and blood cultures were extracted from the reservoir and peripherally, which showed growth of a gram-negative bacillus. Given the high suspicion of catheter-associated bacteremia, it was decided to withdraw it. This bacillus was identified as *Pantoea agglomerans*, sensitive to all antibiotics tested (aminoglycosides, β -lactam, quinolones). Antibiotic treatment was suspended three days after the removal of the catheter. Subsequently, the patient presented good clinical and analytical evolution and remained afebrile.

Discussion

Pantoea agglomerans, is a bacillus gram negative facultative anaerobic which is fundamentally related to nosocomial infections in immunocompromised patients. They include bacteremia associated with catheter infection commonly by contamination of an intravenous infusion (because they can grow in rich media into glucose). An increase in the resistance of this microorganism to β -lactam antibiotics has been reported, which may motivate the use of carbapenems in certain cases. That is why it is a pathogen that we should consider in bacteremia related to indwelling central venous catheters in an immunosuppressed patient.

#477 - Case Report

FROM CELLULITIS, TO ENDOCARDITIS, TO MENINGITIS

Laura Costa, Inês Gonçalves, Filipa Pinho, Luísa Pinto, Francisco Gonçalves, Carlos Capela

Hospital of Braga, Braga, Portugal

Introduction

Infective endocarditis (IE) remains a major clinical problem, with mortality rates of 20–40%. The epidemiology of *Staphylococcus aureus* (SA) endocarditis has changed from a community acquired infection in endovenous drug users to secondary infections from bacteremia related to healthcare contact. Neurological complications occur in 20–40% of patients and have been linked to a poorer outcome.

Case description

We describe the case of a 63 years-old male, with hypertension and type 2 diabetes complicated with chronic renal disease (CRD) who, 2 months earlier, had been hospitalized due to severe leg cellulitis and need for combined therapy with meropenem and linezolid. He was readmitted with nonoliguric acute kidney injury (AKI) in CRD with eosinophilia and eosinophiluria and also severe anaemia and generalised eczema that had started 2 months earlier. There was no apparent infectious focus or other plausible explanation for renal function decline, including nephrotoxic drugs. The patient was never febrile, microbiological studies were negative and the transthoracic ultrasound (US) identified minor degenerative valve changes. His renal function improved slightly during the following days. On the 20th day he developed absence seizures, along with high fever, and a systolic murmur became apparent on auscultation. Cerebrospinal fluid analysis identified inflammatory changes attributable to secondary infectious meningeal involvement. Prompt antimicrobial therapy for endocarditis and bacterial meningitis was initiated. Three days later a MSSA was identified in blood cultures and the cerebral magnetic resonance identified several bihemispheric embolic infarctions. The transesophageal US confirmed mitral valve IE. He completed 5 weeks of flucloxacillin and 2 of cefazolin (antibiotic switch due to hematologic toxicity from flucloxacillin) with resolution of eczema and eosinophilia but maintenance of renal insufficiency, with need for regular dialysis. The patient was discharged after 98 days. He had functional status deterioration and slight cognitive impairment and dysarthria that were improving with cognitive/physical therapy.

Discussion

This case combines a set of rare events, from a staphylococcal IE possibly secondary to bacteremia during the first hospitalization to cerebral embolization from IE. The AKI and cutaneous alterations were probably framed in post-infectious glomerulonephritis. We highlight the importance of clinical suspicion, particularly in a patient with recent hospitalization.

#478 - Case Report

LEPTOSPIROSIS HEMORRHAGIC PNEUMONITIS: THE IMPORTANCE OF EPIDEMIOLOGICAL HISTORY

Joana Afonso Branco, Inês Luz, Susana Moreira, Catarina Martins, Inês Claro, Carlos Lopes, António Pais De Lacerda, Pilar Azevedo
Centro Hospitalar Lisboa Norte, Lisboa, Portugal

Introduction

Leptospirosis is a rare multisystemic anthroponosis caused by pathogenic spirochetes of the genus *Leptospira*. Pulmonary manifestations vary from none/atypical symptoms/mild cough to acute respiratory distress syndrome or severe pulmonary hemorrhage, being the major cause of death in the most severe forms.

Case description

A 35 year old smoker (40 pack-year) city garbagemen with no known comorbidities, presented to the ED with a 2 days history of fever (39°C), headache, mild confusion, myalgia, tachypnea and cough with hemoptysis, with hypoxemic respiratory failure, and elevated C-reactive protein and liver enzymes, after having been cleaning a dumpster some days before the onset of symptoms. Bilateral alveolar infiltrates were shown in chest X-ray, and “crazy-paving” patterns on computed tomography. Amoxicillin/clavulanic acid plus azithromycin were empirically instituted. Clinical deterioration occurred in the first 24h, with persistent anemia (Hb 6g/dL) due to massive hemoptysis (5 packed red blood cells bags), hypovolemic shock with acute kidney injury (AKIN 2) and respiratory failure (PO_2/FiO_2 190). Mechanical ventilation and vasopressor therapy were initiated, and antibiotics changed to piperacillin/tazobactam. Despite the initial microbiological results of bronchial secretions (*E coli*, Coronavirus), and due to the lack of improvement, and the epidemiological context, doxycycline was added, awaiting serology results for *Leptospira*. The patient recovered clinically with reduction of inflammatory parameters and resolution of respiratory insufficiency, being extubated the 3rd day of mechanical ventilation. Antibiotic treatment was stopped at the 7th day of doxycycline. He was discharged from the respiratory ICU on the 12th day of hospitalization. Initial serological results were weakly positive for *Leptospira* (IgM), but the 2nd week serology (IgG) was strongly positive.

Discussion

Pulmonary hemorrhage in leptospirosis is thought to correlate with disruption of endothelial cells associated with deposits

of immune globulins and complement component C3. It is associated with a high mortality, although that, after a proper early presumptive diagnosis, it can be treated easily. In the case of a patient with hemoptysis in an infectious context, priority should be given to the known (and suggestive) epidemiological features, and leptospirosis should be considered in its differential etiologies in an effort to an earlier and effective treatment.

#479 - Medical Image

THE IMAGE OF NEUROCYSTICERCOSIS

María Teresa Pérez Sanz, Esther Donis Sevillano, María Jesús Granda Martín

Hospital General Universitario Gregorio Marañón, Madrid, Spain

Clinical summary

The neural involvement by the larval stage of “*Taenia solium*” is known as neurocysticercosis. It is transmitted by ingestion of eggs shed in the stool of a carrier of the adult tapeworm.

Computer tomography and magnetic resonance imaging are key in the diagnosis. Viable parenchymal lesions are seen as non-enhancing vesicular lesions. The image of a scolex within a cystic lesion is considered a pathognomonic radiographic finding. Parasites in the process of degeneration are seen as cystic or nodular enhancing lesions with surrounding edema. When the cysts finally collapse nodular calcifications appear.

Treatment in most cases consists in management of acute symptoms such as intracranial hypertension or seizures, antiparasitic therapy for viable and degenerating cysts and corticosteroids.

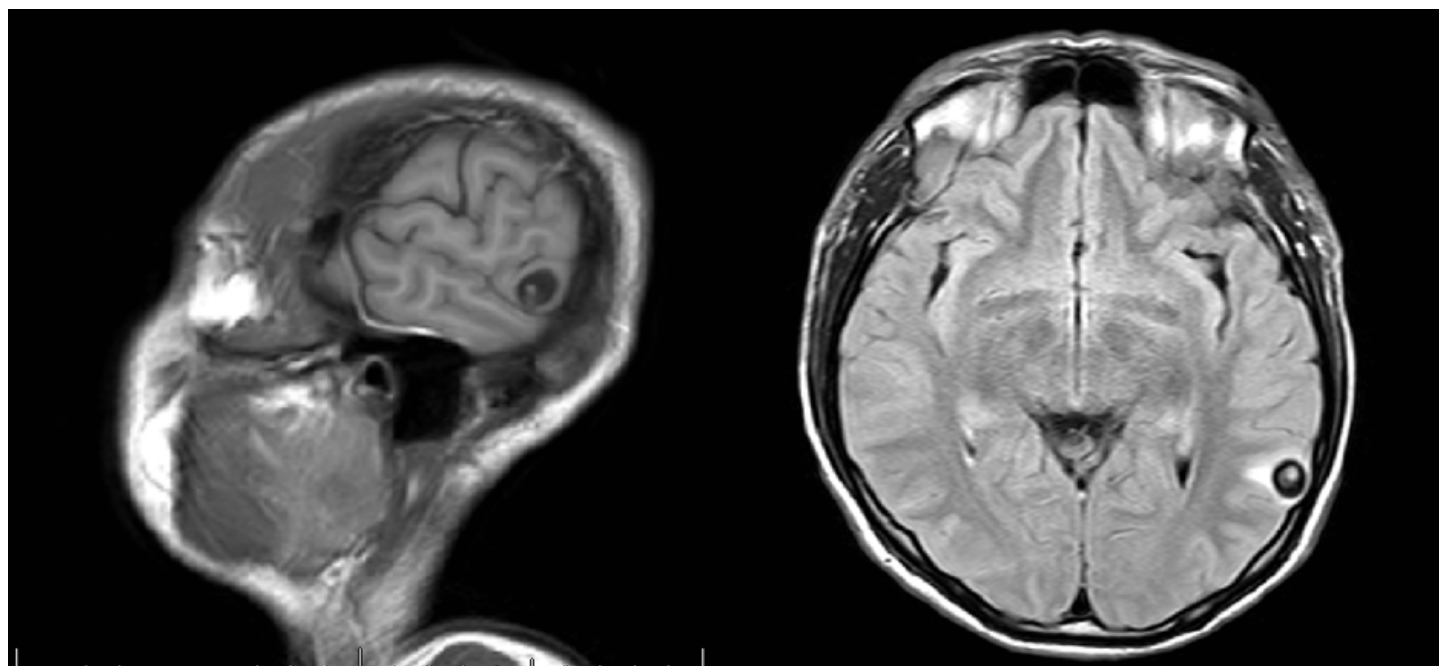


Figure #479.

#487 - Abstract

STAPHYLOCOCCUS AUREUS METHICILLIN-RESISTANT COLONIZATION AND ERADICATION IN A PORTUGUESE INTERNAL MEDICINE WARD

Diogo Costa Santos, Dora Lameiras, Joana Vaz, Graça Lérias, Isabel Madruga

Hospital de Egas Moniz - Centro Hospitalar Lisboa Ocidental, Lisboa, Portugal

Background

Staphylococcus aureus methicillin-resistant (MRSA) is recognised as part of the normal body flora, especially in the nose and is associated with nursing homes, exposure to the healthcare system and after antibiotic use. Colonization is a risk factor for the subsequent development of a MRSA infection and eradication may reduce the risk of infection and prevent transmission to other patients.

Methods

Retrospective study including patients admitted to a Portuguese Internal Medicine ward between July and December of 2018, screening patient charts for MRSA nasal swab tests, number of eradication interventions performed if swabs were positive and successful eradication of MRSA on subsequent testing.

Results

436 patient charts were screened. Age average was 78,7 years and 57,6% (n=251) of patients were women. Out of all patients analysed only 15,6% (n=68) were tested with nasal swabbing for MRSA colonization, having had at least one risk factor. Most patients with risk factors for colonisation were not tested, most notably patients in nursing homes, of which only 26,1% (n=23) were tested.

Out of all patients tests 39,7% (n=21) were positive for MRSA. Eradication protocol included application of a mupirocin nasal ointment and chlorhexidine antiseptic head, body and mouth wash performed for 5 days on patients positive for MRSA in nasal swab testing. The maximum number of protocols performed on a single patient was 2. Only 18,5% (n=5) of patients had a negative nasal swab test negative for MRSA after the eradication protocol. Out of those, 2 patients required a single protocol, while the remaining 3 patients required two eradication protocols. 3 patients were discharged home after completing a single eradication protocol without nasal swab reevaluation. The remaining 70,3% (n=19) patients performed two eradication protocols and remained MRSA positive on subsequent nasal swab tests, being discharged as such.

Conclusion

The low success rate of MRSA colonization eradication procedures has been recently documented in literature and is also reflected in our findings. Care staff MRSA colonization rates are unknown and may be a reason for low decolonization success rates. Perhaps a better compliance of nursing and medical staff to both isolation and eradication protocols in these patients could provide results.

#494 - Case Report

AN UNEXPECTED DIAGNOSIS

Carolina Vasconcelos Barros, Carolina Morna, Mariana Gomes, Teresa Faria

Hospital Central do Funchal, Funchal, Portugal

Introduction

The growth of *Salmonella typhi* (ST) serotypes is limited to a human host, in which these microorganisms cause enteric fever (EF). Ingestion depends on the intake, usually in water or contaminated food. EF is rare in developed countries.

Case description

A 44-year-old caucasian man went to the emergency department for a continuous fever with 10 days of evolution, maximum axillary temperature of 40°C which did not go down with the antipyretics. Also accompanied with frontal oppressive headaches and general malaise. The patient denied gastrointestinal complaints, abdominal pain and other symptomatology. No recent travel history, no contact with agricultural activity or animals. He had been given cefatrizine and prednisolone four days ago for the suspicion of polyssinopathy, without any clinical improvement. At the physical examination he was oriented, febrile with a tympanic temperature of 40°C and with sphingothermal dissociation, without meningeal signs and any other changes to be recorded. Analytically, there was an increase in C-reactive protein accompanied by leukocytosis and neutrophilia; chest radiography did not show any acute changes. The patient was hospitalized for study of a fever of unknown etiology and there were collected aerobic blood cultures. On the first day of hospitalization he remained febrile and although he did not present abnormal heart murmurs it was performed a transthoracic echocardiogram compatible with absence of vegetation or masses. He also performed a Thoracic-Abdominal-Pelvic Computed Tomography, which demonstrated diffuse circumferential parietal thickening of the lower third of the ascending colon and ileo-cecal adenopathies. On the second day of hospitalization, there was an isolation of ST in the aerobic blood cultures collected at the admission. The patient started ceftriaxone, completing fourteen days of antibiotic therapy. The fever ended up only giving way to the twelfth day of hospitalization with subsequent clinical and analytical improvement.

Discussion

The essential characteristics of EF are very variable which requires a high level of clinical suspicion. Except for positive culture no specific laboratory examination is diagnostic of this entity. This case demonstrates a presentation of the disease without gastrointestinal complaint. It is also a case of EF in a developed country, with no previous travel history, which makes us suspect of a chronic carrier in the region.

#515 - Case Report

CHRONIC OSTEOMYELITIS VS BONE METASTASIS

Carolina Paiva, Denise Magalhães, Helena Greenfield, Raquel Santos, Catarina Tavares, Joana Cancela

Hospital Pedro Hispano, Matosinhos Local Health Unit, Matosinhos, Portugal

Introduction

Osteomyelitis is a progressive inflammatory process resulting in bone destruction and sequestrum formation. It affects the quality of life of the patient and, as such, a prompt diagnosis and aggressive management are critical to the prognosis and final outcome.

Case description

A 68 year old male, with a history of smoking (50 pack-year), presented to the Emergency Room with difficulty in walking, with loss of strength in both inferior and left superior limbs which had begun one week earlier. Physical examination showed muscle strength grade 4/5 in both inferior limbs, masses of stony consistency in the right hypochondrium and right inframammary region, and an 8cm non-exudative ulcer on the right leg with bone exposure which the patient did not recall evolution time. Cerebral tomography revealed space-occupying lesions in the right temporo-parietal, left frontal, left parietal and right frontal cortical areas, suggestive of metastasis. Thoraco-abdomino-pelvic tomography showed a neoplastic mass in the right upper lung lobe with invasion of the mediastinum, costal arch, brachiocephalic veins, and superior vena cava; multiple pulmonary metastasis, and large right costal and subcutaneous metastasis in the right hypochondrium. Flexible bronchoscopy permitted biopsy of a polypoid lesion with histology consistent with small cell carcinoma. Thus a diagnosis of small cell carcinoma cT4N1M1 was made. This raised the possibility of the ulcerated lesion being in the context of metastasis (cutaneous or bone), however a magnetic resonance imaging reported findings consistent with osteomyelitis in the middle third of the tibia. A definitive diagnosis was possible, with bone biopsy revealing trabecular bony tissue with the presence of necro-inflammatory changes, with no signs of malignancy.

Discussion

Chronic osteomyelitis is characterized by long term infection, lasting months or years. It can occur due to inadequate treatment of acute osteomyelitis, hematogenous dissemination or contiguous spread from soft tissue, trauma or iatrogeny. The authors consider this case relevant since the patient did not present a clear precipitating factor for the lesion, the timeline was not clear and as such was a differential diagnosis of bone or skin metastasis.

#525 - Case Report

SEPSIS AFTER A PHARYNGOTONSILLITIS: A CLINICAL REPORT OF A LEMIERRE'S SYNDROME

María Mercedes Ferreiro-Mazón Jenaro, Cristina Llamazares Mendo, Marta Bacete Cebrián, Guillermo Soria Fernández-Llamazares, Eduardo Luis Peñaloza Martínez, Antonio Muiño Míguez, María Gómez Antúnez

Gregorio Marañón General University Hospital, Madrid, Spain

Introduction

Postanginal sepsis is a clinical condition characterized by an oropharyngeal infection followed by septic thrombophlebitis of the internal jugular vein. Septic emboli aren't rare findings. Its incidence has been reduced since the rise of the use of antibiotics for throat infections.

Case description

A 19-year-old female with no previous diseases came to the Emergency Department with a one-week history of fever, shiver, dyspnoea and dry cough, denying any abdominal or urinary symptom. She had been taking amoxicillin for a week due to an acute pharyngotonsillitis, without improvement. On physical examination she was tachycardic and febrile, with no other pathological finding. The blood test showed signs of sepsis (14700 leukocytes/ μ L, 33000 platelets/ μ L, INR 1.37, CRP 16 mg/dL, procalcitonin 10.18 μ g/L) and the chest radiograph displayed an interstitial pattern, so she was admitted to hospital with suspected atypical pneumonia. Urinary antigens of Legionella and Pneumococcus were negative. Serologies for HIV, HCV, HBV, EBV, CMV, Parvovirus B19, Toxoplasma, syphilis, Legionella and Mycoplasma were negative as well. The three blood cultures grew *Fusobacterium necrophorum* and the cervical CT scan showed thrombosis of the internal jugular vein, the facial vein and the ascending cervical vein, so Lemierre's syndrome was diagnosed. Another chest radiograph showed a nodule accompanied by bilateral pleural effusion, suggesting a septic pulmonary embolus. No hepatic nor splenic abscesses were found. The patient was treated with meropenem for two weeks and amoxicillin/clavulanic acid for another week along with anticoagulation, having a good clinical and radiological response.

Discussion

This is a rare disease with an incidence of 3.6 per million persons per year according to a Danish prospective study, so a high degree of clinical suspicion is needed. Internal abscesses should be looked, as the duration of the treatment depends on its resolution. The resistance to fluoroquinolones, aminoglycosides and often to macrolides leaves few therapeutic alternatives. The empiric antibiotic therapy scheme needs to include a β -lactamase inhibitor, since *F. necrophorum*'s β -lactamase production has been described. It is accepted a two-week intravenous therapy followed by an oral antibiotic. In case of no response, surgical excision of the internal jugular vein might be needed. Abscesses can be drained as well. There is uncertainty about the use of anticoagulation because there are no proper studies.

#530 - Case Report

MYSTERIOUS JAUNDICE

Sylvia Dražilová, Dominika Martinkova, Adam Vojtek

Hospital Poprad, Poprad, Slovakia

Introduction

Jaundice, or icterus, is a clinical sign caused by hyperbilirubinemia, which can be due to various etiological factors. The evaluation of the patient who is jaundiced requires an understanding of bilirubin production and metabolism. In this case report will be described one of the unusual etiological cause.

Case description

A 22-year-old gypsy man, without any medical history, without any regular medication, presented to the Hospital with jaundice and fever. Subjectively complained about lower back pain. On further questioning patient denied any use of hepatotoxic medication, ingestion of mushrooms, alcohol or any drugs intake. Laboratory tests showed elevated renal and hepatic parameters, signs of inflammation with severe thrombocytopenia and mineral deficit. Additional blood tests as albumin level and prothrombin time were normal. Abdominal ultrasound and X-rays did not show significant findings. Serology tests for acute hepatitis A, B, C and E infections were negative, also other infectious causes as parvovirus B19, hantavirus, *Coxiella burnetii*, *Legionella*, *Rickettsia*, HIV were excluded. Metabolic disease as Wilson's disease and also because of high incidence of hereditary hyperbilirubinemia (Dubin-Johnson and Rotor syndrome) in Slovakian Gypsy population in Spis region, were excluded. The patient was treated empirically using antibiotics and symptomatic with fluid resuscitation and platelet's substitution. On this treatment improved the renal functions, decreased inflammatory markers and normalized platelets, but level of bilirubin significantly raised and patient underwent treatment with MARS (Molecular Adsorbent Recirculating System). Consequently, the patient's status started to improve. Meanwhile, the result of Microscopic Agglutination Test (MAT) was obtained, which confirmed antibodies against *Leptospira pomona*.

Discussion

Leptospirosis is common worldwide and potentially fatal zoonosis. Human infections vary from asymptomatic or flu-like cases to severe forms. The illness may progress to renal and liver failure, pulmonary hemorrhage and other severe complications. The adequate clinical suspicion and early confirmation of diagnosis remains significant for treatment and prognosis of patient.

#538 - Abstract

CHARACTERISTICS AND MANAGEMENT OF CYSTICERCOSIS AND TAENIASIS IN A TERTIARY HOSPITAL IN MADRID THROUGHOUT THE LAST 30 YEARS

María Teresa Pérez Sanz, Alejandro Parra Virto, Sandra Piqueras Ruiz, Mercedes Ferreiro Mazón, Víctor Mato Jimeno, María Jesús Granda Martín

Hospital General Universitario Gregorio Marañón, Madrid, Spain

Background

The characteristics and management of patients with cysticercosis and taeniasis have been well defined for years. We want to verify if the patients diagnosed during the last 30 years in a tertiary hospital, the Gregorio Marañón Hospital in Madrid, have been handled correctly.

Methods

Retrospective descriptive study based on clinical records of the patients diagnosed or treated in our center between 1990 and the present year (65 patients). We conducted a research of the hospital files with the terms "teniasis" and "cisticercosis" according to ICD-9 and ICD-10.

Results

65 patients were studied. The average age was 36.53 years and 29 were women. 46 came from Latin America, 2 from Africa and 2 were Spanish; 15 had unknown origin. 62 were diagnosed with neurocysticercosis, 2 had muscle or subcutaneous tissue involvement, 1 had an adult intestinal tapeworm and 1 had unspecified cysticercosis.

Medical records of the 1990s did not include information on symptoms, diagnostic tests or treatment, so these data have been analyzed since 2000 (52 patients): 30 had seizures, 11 had intracranial hypertension (IH), 10 had headache without IH data, 7 had focal neurologic signs, 1 had meningitis, 1 had abdominal symptoms and 1 had iron deficiency anemia. The eosinophil count was determined in 34 patients; 6 presented eosinophilia (average values of 975/ μ L and 9.4% of the total leukocyte count). Magnetic resonance imaging was performed in 43 patients, computed tomography in 37 and soft tissue radiography in 7. Stool examination was performed in 17. Serological determinations of 31 patients were performed, 9 of which were positive. Electroencephalograms were performed in 21 patients; 2 presented activity compatible with epilepsy. Only 15 patients underwent ophthalmological examination, 12 were screened for tuberculosis, and 17 were tested for *Strongyloides stercoralis* (3 were diagnosed with Strongyloidiasis). 43 received albendazole. However, only 39 received corticosteroids. 34 required antiepileptic drugs and 9 surgical procedures. 7 patients did not need any treatment.

Conclusion

We did not find differences in epidemiological characteristics and

symptoms with respect to previous studies. We found deficiencies around the management of these patients in the tests that needed to be performed (especially the ophthalmological examination), in the treatments applied (since the use of corticosteroids is not reported in all patients receiving albendazole), as well as in the necessary screening tests.

#544 - Case Report

STREPTOCOCCUS SALIVARIUS AND BACTERIAL MENINGITIS: AN “EMERGING” PATHOGEN

Christian Oblitas, María Dolores Pulfer, Antonio Sánchez-Soblechero, Alejandro Del-Castillo-Rueda

Hospital General Universitario Gregorio Marañón, Madrid, Spain

Introduction

The most common agents in acute bacterial meningitis are *Streptococcus pneumoniae*, *Neisseria meningitidis*, *Haemophilus influenzae*, *Streptococcus agalactiae* and *Listeria monocytogenes*. Due to the advent of the vaccines some agents have been decreased dramatically its incidence, but still remains high morbimortality. For empirical treatment in acute bacterial meningitis acquired in the community the use of cephalosporins associated with vancomycin with/without another beta lactic antibiotic is recommended.

Case description

A 54-year-old woman was attended at the emergency department with history of sudden headache, fever (38.5°C), nausea and vomiting. On physical examination, BP: 198/100 mmHg, HR: 106 bpm, 95% basal saturation, and temperature 37,6°C. Neurological examination showed Glasgow Scale of Coma M6,V4,O3. Brain CT scan was normal. Lumbar puncture showed cloudy cerebrospinal fluid (CSF), 5.360/uL leukocytes (normal < 5) with 74% polymorphonuclear, proteinorrachia 173 mg/dL (normal < 30), and glycorrachia 60 mg/dL (normal 40 -70) with plasma glucose 154 mg/dL. Intravenous treatment was started with ceftriaxone, vancomycin, ampicillin, and dexamethasone (single dose). The protein chain reaction (PCR) 16S rRNA in CSF was negative for *S. pneumoniae*, *L. monocytogenes* and *N. meningitidis*, and positive for *Streptococcus salivarius*. Blood culture (1 out 3) was positive for *S. salivarius*. During anamnesis, the patient referred “sweet tears” in reference to right rhinorrhea related with postural positions. Rhinorrhea was analyzed as a CSF showing glucose 51 mg/dL, leukocytes 17/uL and proteins 89 mg/dL. Facial scanner and MRI-brain showed a right ethmoidal fistula owing to a mucocele, without signs of myeloencephalocle.

Treatment was completed with ceftriaxone during 14 days, and after discharged she underwent for surgical repair without any complications.

Discussion

Streptococcus salivarius belongs to the viridans group streptococcus. Despite its low virulence, there are described

cases of bacteraemia, sinusitis, endocarditis and meningitis. It has been related with CSF fistulas, sinusitis, brain abscesses, cranial traumatism, and anaesthetic procedures by direct droplet transmission.

In conclusion, we present a clinical case of meningitis by *S. salivarius* due to ethmoidal mucocele and CSF fistula, and make a call to the need of routine implementation of the use of face-mask during spinal procedures.

#547 - Abstract

HIV TESTING IN PATIENTS DIAGNOSED WITH COMMUNITY ACQUIRED PNEUMONIA OR PRIMARY LUNG CANCER FROM 2014 TO 2018 IN A TERTIARY HOSPITAL IN NAVARRA (SPAIN)

Joao Luis Modesto Dos Santos, Marta Adelantado Lacasa, María Eransus Garzaron, Aitziber Aguinaga Perez, Carmen Martín Salas, Julio Sánchez Alvarez

Complejo Hospitalario de Navarra, Pamplona, Spain

Background

Clinical guidelines have highlighted the need for HIV testing in patients diagnosed with community acquired pneumonia (CAP) or primary lung cancer (PLC). The aim of this study is to evaluate the frequency for HIV testing on patients admitted to a tertiary reference hospital with CAP or PLC.

Methods

The authors present an observational study at the Complejo Hospitalario de Navarra (Spain), evaluating HIV testing in patients diagnosed with CAP or PLC from January 2014 to June 2018. Patients were included by CIE-10 diagnostic codes in clinical records, and HIV testing was assessed by crosschecking databases. The Local Ethics Committee approved this study.

Results

A total of 7119 patients were diagnosed with CAP and 2988 with PLC, with a total of 10107 opportunities for HIV testing. Patients were mostly males (62.7%) and with similar ages in both groups: 68.6 and 65.9 years-old in CAP and PLC, respectively, with a difference of 2.75 (IC95% 1.84-3.65). HIV testing was requested in 1060 patients (10.49%), detecting a higher request rate in patients with CAP than PLC (11.00% vs 9.27%), with a statistically relevant difference of 1.73% ($p=0.0097$). HIV testing was also more frequent in male patients (OR 1.41, IC95% 1.22-1.61), independently from diagnosis. Logistic regression model demonstrated that for each year of age the probability for HIV testing was reduced in a 1.30% (OR adjusted for gender and diagnosis 0.987, IC95% 0.984-0.989). In the CAP subgroup, HIV was more frequently tested when patients were admitted to the ICU (22.73%) or to an Infectious Diseases unit (ID) (34.29%), rather than Internal Medicine (IM) (11.63%) or Pneumology (8.20%). However, most patients with CAP (65.82%) were admitted to IM

and Pneumology. From the 1060 patients with CAP or PLC tested for HIV, 21 samples were not processed and, from the other 1039, 3.56% (37) presented a positive result. The proportion of positive HIV tests was similar in both diagnosis (CAP 3.92% vs PLC 2.56%, $p=0.29$) and gender (males 3.31% vs females 4.13%, $p=0.52$), with a mean age of 48.8 years-old (IC 95% 45.84-51.84). Only 13 of the 37 positive HIV tests were new diagnosis of HIV (35.1%), representing 1.23% of the HIV tests requested in this study.

Conclusion

HIV testing in patients with CAP or PLC in this cohort is very low, with many HIV diagnostic opportunities lost. Therefore, HIV testing must be encouraged in general, but mainly in those services admitting patients with CAP more often such as Internal Medicine and Pneumology.

#549 - Abstract

HIV NEW DIAGNOSES IN COMMUNITY ACQUIRED PNEUMONIA OR PRIMARY LUNG CANCER PATIENTS: DATA FROM 2014 TO 2018 IN A TERTIARY HOSPITAL IN NAVARRA (SPAIN)

Joao Luis Modesto Dos Santos, Marta Adelantado Lacasa, María Eransus Garzaron, Carmen Martin Salas, Aitziber Aguinaga Perez, Julio Sánchez Alvarez

Complejo Hospitalario de Navarra, Pamplona, Spain

Background

Clinical guidelines have highlighted the need for HIV testing in patients diagnosed with community acquired pneumonia (CAP) or primary lung cancer (PLC). The aim of this study is to evaluate the rentability for HIV testing in patients admitted to a tertiary reference hospital with CAP or PLC.

Methods

The authors present an observational study at the Complejo Hospitalario de Navarra (Spain), assessing newly diagnosed HIV patients from HIV testing in patients diagnosed with CAP or PLC from January 2014 to June 2018, and evaluating initial CD4 count, viral load and coinfections. Patients were included by CIE-10 diagnostic codes in clinical records, and HIV testing was assessed by crosschecking databases. The Local Ethics Committee approved this study.

Results

7119 patients were diagnosed with CAP and 2988 with PLC, with a total of 10107 opportunities for HIV testing. HIV testing was requested in 1060 patients (10.49%), detecting a higher request rate in patients with CAP than PLC (11.00% vs 9.27%), with a statistically relevant difference of 1.73% ($p=0.0097$). From the 1060 patients with CAP or PLC tested for HIV, 21 samples were not processed and, from the other 1039, 3.56% (37) presented a positive result. The proportion of positive HIV tests was similar

in both diagnosis (CAP 3.92% vs PLC 2.56%, $p=0.29$) and gender (males 3.31% vs females 4.13%, $p=0.52$), with a mean age of 48.8 years-old (IC 95% 45.84-51.84).

Only 13 of the 37 positive HIV tests were new diagnosis of HIV (NDHIV) (35.1%), representing 1.23% of the HIV tests requested. NDHIV patients had a mean age of 43.9 years-old (IC 95% 40.53-47.16) and with 61.54% males. All the NDHIV were patients admitted with CAP. Infection source was only mentioned for 4 patients, all with sexual intercourse (heterosexual and men having sex with other men, in equal proportions). Finally, NDHIV mean CD4 count at diagnosis was 142.4 cells/mm³ (IC 95% 74.2-210.6) with a mean viral load of 802062.6 copies/mL (IC95% 262523.2-1341602). All NDHIV where late diagnosis, with 53.85% of them being very late. In fact, all patients where stage III or IV at the WHO classification (46.15% and 53.85%, respectively), being 84.62% of patients stage C3. One of the NDHIV presented a coinfection by HCV.

Conclusion

HIV testing in patients with CAP or PLC in this cohort is very low, restricting the number of new diagnosis of HIV. This is a matter of high concern as newly diagnosed HIV from this cohort are made at a very late stage with low CD4 counts.

#550 - Medical Image

POTT'S SPINE

Maria J Piteira^{1,2}, Teresa Piteira³, Sérgio Paulo²

¹ Hospital do Espírito Santo de Évora, Évora, Portugal

² Centro Hospitalar Lisboa Norte - Santa Maria, Lisboa, Portugal

³ Centro Hospitalar Lisboa Central - São José, Lisboa, Portugal

Clinical summary

A 21 year-old African woman, nonsmoker, HIV negative, presented with severe back pain lasting 5 months. Due to the appearance of paraplegia, fecal and urinary incontinence, she had to be evacuated to Portugal. Magnetic resonance imaging of the spine showed kyphosis on D12 due to extensive osteolysis (D12 e L1) and spread of an abscess into the para-spinal tissues and spinal canal. The patient had surgery with fixation and arthrodesis of the segments involved. Surgical biopsy revealed Mycobacterium tuberculosis. The patient was treated with 2 months of HRZE (isoniazid, rifampin, pyrazinamide, ethambutol) and then HR until 1 year. She has now chronic back pain controlled with medication, no neurological impairment, or significant kyphotic deformity.

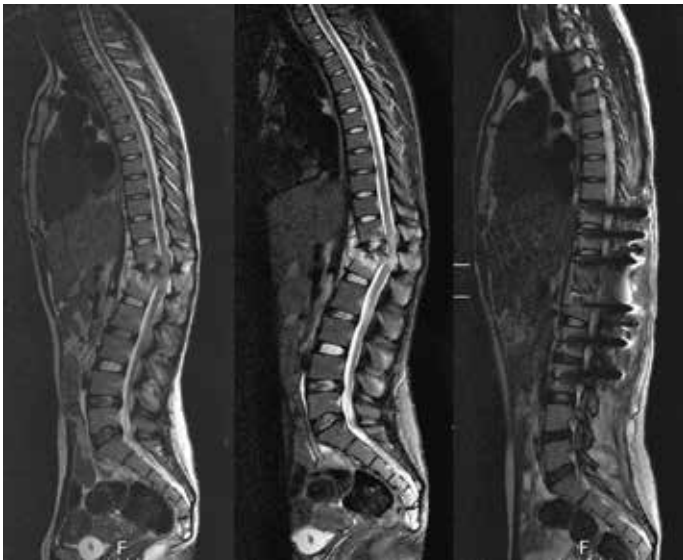


Figure #550.

#555 - Case Report

CAN HAIR REMOVAL KILL YOU?

Eduardo Fernández Carracedo, Víctor Mato Jimeno, Sergio Moragon Ledesma, Alvaro Alejandro De Oña, Cristina Ausin García, Victoria Sampedro Martínez, Purificación Suarez Herranz, María Victoria Villalba García

Hospital General Universitario Gregorio Marañón, Madrid, Spain

Introduction

Pantoea agglomerans is associated with plants infections. However, it could be a cause of opportunistic human infections, mostly by wound infection with plant material, or as a hospital-acquired infection by fluids contaminated.

Case description

A 49-year-old woman with history of hypothyroidism. She went to our hospital due to malaise and fever. She only referred as a possible focus of infection axillary hair removal three days before with onset of an erythematous plaque on the right side of chest starting on right armpit confirmed by physical examination. She presented fever and hypotension on arrival without response to fluids. Lab tests showed leukocytosis and elevated acute phase reactants, coagulopathy and acute kidney failure. We started empiric therapy with ceftriaxone and clindamycin and she was admitted to the Intensive Care Unit with the diagnosis of sepsis. After 5 days she has an excellent response to treatment and she was transferred to an Internal Medicine Unit. *Pantoea agglomerans* grew in pus culture of cellulitis. Blood cultures sets were negative. HIV serologic screening was negative. A magnetic resonance of soft tissues of the chest was performed, showing inflammation of subcutaneous fat tissue, fasciitis and myositis on the right side of chest wall. The patient evolves favorable and she was discharged after 3 weeks of intravenous treatment and continue oral therapy until completing 6 weeks of treatment with clinical improvement and complete healing.

Discussion

We present a rare case of extense cellulitis and myositis after hair removal by *Pantoea agglomerans* in a non-immunosuppressed patient. There are few cases of skin infections by this bacteria, usually following piercing or laceration of skin with a plant thorn, wooden splinter or other plant material and subsequent inoculation of the plant-residing bacteria. In our case there was no contact with plants and the only relevant data in the medical history was hair removal.

#561 - Case Report

REFRACTORY BRONCHOSPASM IN ACUTE RSV INFECTION - LIFE SAVING MEASURES IN A POOR PROGNOSIS PATIENT

Torcato Moreira Marques, Teresa Ferreira, Cristiano Cruz, Diogo Antão, Lourenço Cruz, Valentina Tosatto, Paula Nascimento, André Almeida

Internal Medicine Department, Hospital de Santa Marta, CHULC, Lisboa, Portugal

Introduction

Respiratory syncytial virus (RSV) is a common respiratory virus that most frequently causes mild, flu-like symptoms. It can be the reason of serious illness in infants, the elderly or immunocompromised, many time leading to fatal outcomes.

Case description

We present the case of a 91 yo woman, with medical history of HF, atrial fibrillation (AF) and dementia. She was medicated with warfarin, nebivolol, furosemide. The patient was admitted to the emergency department (ED) in January with dyspnoea. The symptoms had started 3 days prior, and empirical antibiotic treatment was started with no signs of improvement. In the ED the patient was afebrile, haemodynamically stable, with pulmonary auscultation revealing bilateral crackles and wheezing. Additional O₂ was needed for Sat >90%. Chest X-ray was innocent and the arterial blood gas showed only hypoxemia. Blood work was unremarkable. Severe bronchospasm developed and aminophylline was administered, causing AF with rapid ventricle response, which was treated with amiodarone. A nasal and oropharyngeal swab was done showing a positive PCR for RSV. She was admitted to an Internal Medicine ward and in the day after she developed respiratory acidosis and maintained the bronchospasm. Several courses of salbutamol, ipratropium bromide, corticosteroids, magnesium sulphate and aminophylline were done with no impact. Because of the global clinical status, no ICUs were contacted for transfer and with family support, non invasive ventilation was decided as ceiling of treatment. Oxygenation improved with NIV but acidosis sustained and, despite not being in an ICU, ketamine was used, as IV bolus (0.5 mg/kg) and infusing over the next two hours (0.5 mg/kg/h), always monitoring for adverse reactions. Bronchospasm resolved during the infusion and along with the NIV and opioids, normal pH was restored (7.36). NIV and additional oxygen supply were discontinued. Over the rest of

the patients stay in the hospital, blood work never showed infection parameters. Patient was discharged back to the nursing facility with no ventilatory support.

Discussion

This case illustrates the severity of bronchoreactivity caused by RSV and its impact on patients ventilation dynamic. Even in patients with poor prognosis, life saving measures can be taken and although there are only few cases describing the use of ketamine in refractory bronchospasm in acute RSV infection, it has proven to be an effective drug in life threatening situations like the one reported.

#570 - Case Report

A SEVERE CASE OF HAND, FOOT AND MOUTH DISEASE IN THE ADULT

Filipa Sofia Silva, Ana Rita Piteira, Patrícia Domingues, Joana Ferreira, Diana Pedreira, Pedro Carreira, Paula Lopes, Manuela Fera Setúbal Hospital Center, Setúbal, Portugal

Introduction

Hand-foot-and-mouth disease (HFMD) is an acute viral illness that usually presents as a vesicular eruption in the mouth, but it can also involve hands, feet, buttocks, and genitalia. HFMD is common in infants and children younger than 5 years old, however, older children and adults can also get HFMD. It usually clears up by itself in 7 to 10 days.

Case description

Authors present a case of a healthy 40-year-old caucasian female, taking progesterin-only contraception implant. She went to the Emergency Department because of erythematous lesions and blisters, which started on the hands with posterior extension to the elbows, feet, ankles, knees and buttocks. She denied fever. The remaining objective examination was completely normal. Analytically there weren't changes. Once the diagnosis of bullous dermatosis was accepted, skin biopsy was performed and the case was discussed with Dermatology. It was decided to start topical mometasone and an antihistamine drug. In the course of the study of bullous dermatosis, an eventual autoimmune or neoplastic etiology was excluded. HIV and hepatitis research was negative. Urinalysis was normal. The two blood cultures and three urocultures were sterile.

During two weeks of hospitalization it was observed an improvement of skin lesions. Patient was discharged with symptomatic control therapy and she was followed up at the Internal Medicine appointment. After two months there were no visible lesions anymore. The histopathological result of skin biopsy confirmed the existence of intraepidermal and subepidermal bullous dermatosis suggestive of HFMD.

Discussion

With the presentation of this clinical case, authors would like to recall that the diagnosis of HFMD should be also considered in adults, although it is more common in children.

#575 - Case Report

DISSEMINATED LESIONS - A CASE REPORT

Mariana Formigo, Magda Costa, João Martins, Sandra Barbosa, Helena Sarmento, Jorge Cotter

Hospital Senhora da Oliveira, Guimarães, Portugal

Introduction

Disseminated tuberculosis (DT) may infect any number of organs, it occurs in about 2% of all reported cases of tuberculosis and accounts for up to 20% of all extra-pulmonary tuberculosis cases.

Case description

A 61-year-old man presented to the Emergency Department complaining of lumbar pain over the last month that started after falling. He was observed by Orthopedics, submitted to lumbar X-ray and lumbar computerized tomography (CT) showing recent fractures in the vertebral bodies of L1 and L2 and a new lesion in the left paravertebral soft tissues of the L1-L3 segments suggesting a tumor etiology.

He was observed and admitted in Internal Medicine care which documented left parasternal and retroaxillary thoracic mass and 20% weight loss over the last 2 months. Analytically, there was a slight increase in systemic inflammatory parameters. The patient performed a parasternal mass ultrasound revealing uncertain results and a thoracoabdominopelvic CT revealing masses in right and left superior lobes, inflammatory micronodules, mediastinal adenomegalies, a hypodense lesion in the spleen and a hypodense lesion on the sternum and left shoulder. Viral markers and serologies were negative. At 5th day of hospitalization, the masses were punctured and pus was aspirated from the masses. At 12th day of hospitalization, mycobacterium tuberculosis DNA scan was positive in the purulent material aspirated. He started antibacterial (rifampicin 600 mg od; isoniazid 300 mg od; pyrazinamide 1500 mg od; etambutol 1200 mg od). The remaining microbiology (aerobic, anaerobic and mycobacteriological culture) was negative. Echocardiogram revealed no alterations. Parasternal mass histology was compatible with chronic granulomatous inflammatory process with no evidence of neoplastic cells. The patient was submitted to bronchofibroscopy and then had a positive M. tuberculosis DNA result in bronchoalveolar lavage.

He was discharged at 25th day of hospitalization referred to Internal Medicine, Orthopedics and Physiatry appointments.

Discussion

If untreated, DT is almost always fatal. Although most cases are treatable, the mortality rate remains high (around 25-30% in adults). One of the main causes for these high mortality rates includes late detection of the disease caused by non-specific symptoms.

#582 - Case Report

A CURIOUS CASE OF SIMULTANEOUS DIAGNOSIS OF BEHÇET DISEASE AND CUTANEOUS TUBERCULOSIS

Sara Mendonça Freitas, Joana Marques, Ana Grilo, Fernando Gonçalves, José Araújo

Hospital Beatriz Ângelo, Loures, Portugal

Introduction

Behçet disease, is characterized by recurrent oral aphthae and several systemic manifestations. Rarely, Behçet or pseudo Behçet disease are associated with tuberculosis, and clinical manifestations are considered to be hypersensitivity reactions to *Mycobacterium tuberculosis*.

In this report we present a rare case of Behçet disease and cutaneous tuberculosis diagnosed shortly after.

Case description

A 70 year-old woman, with history of recurrent face angioedema (followed at Allergy and Clinical Immunology clinic) and oral aphthae (more than 3 episodes per year) and inflammatory arthritis in the past, was admitted at emergency department due to pain and oedema of the left upper limb and a diagnosis of venous thrombosis of cephalic, axillary, subclavian, internal jugular, brachiocephalic veins was made through CT-scan and initiated treatment with enoxaparin and later warfarine. Inherited Thrombophilia's and antiphospholipid syndrome investigation workup were negative, ANA 1:640, with speckled pattern, anti-SSA and anti-SSB antibodies, rheumatoid factor and anti-CCP antibodies were negative. HIV and HBV and HCV serologies were also negative. CT-scan of thorax, abdomen and pelvis and upper endoscopy showed no significant changes. Colonoscopy showed, at ascending colon a diffuse, eosinophilic inflammatory infiltrate, that suggested focal colitis vs inflammatory bowel disease. After discharge, clinical investigation was proceeded and regarding clinical history, HLA B51, extensive venous thrombosis and positive pathergy, Behçet's disease was diagnosed. Due to shoulder and wrist arthritis prednisolone 20mg id was initiated and gradually reduced.

After 4 months she was hospitalized again due to abdominal pain and thoracic wall and inguinal area nodules with fistulisation. The TC-scan showed an abscess in the cellular subcutaneous tissue of right hypochondrium and ultrasound guided aspiration was performed, and mycobacterial culture was positive for *Mycobacterium tuberculosis* at the 18th day of culture.

Discussion

Behçet disease and cutaneous tuberculosis are extremely rare conditions and the simultaneous diagnosis is even rarer. It is thought that Behçet disease by itself may produce a defect in cell-mediated immunity, which increases the individual susceptibility to Tuberculosis.

This is a complex and challenging case that reflects the Internal Medicine specialist's role on the diagnosis and management of multiple conditions.

#600 - Abstract

PREDICTIVE VALUE OF HEMOGLOBIN FOR THE INFECTION OF VASCULAR ACCESS IN PATIENTS WITH CHRONIC KIDNEY DISEASE IN HEMODIALYSIS

Gabriel Antonio Rios, Luis Benjamin Godínez

Instituto Guatemalteco de Seguridad Social, Guatemala, Guatemala

Background

Anemia in patients with chronic kidney disease is due to at least two conditions, erythropoietin deficiency and disorders in the disposition of iron, currently it has been established that there is an association between anemia, infection or inflammatory diseases and that the renal replacement therapy itself leads to constant inflammation. The association between hemoglobin level and risk of infection has not been established in our population.

Methods

We studied 116 patients with chronic kidney disease on hemodialysis who attended the External Consultation Unit of Diseases of the Social Security Institute during 2016 to 2017. We aimed to predict vascular access infection based on hemoglobin values in patients with chronic kidney disease on hemodialysis and estimate the difference in hemoglobin levels between patients. The student t test of independent samples or Mann-Whitney U test was used for numerical variables and chi-square or Fisher's exact test for the categorical variables as appropriate. For the analysis of the differences between the hemoglobin means and the groups according to the type of infection, we performed an analysis of the variance (ANOVA) and a multinomial logistic regression for the determination of the risk factors of the vascular infection.

Results

The model showed that according to the hemoglobin levels, patients have a OR 1.8 (C.I. 1.160-2.814) $p = 0.009$ to present a vascular infection and a predicted percentage of 85.7%, with hemoglobin levels of 7.50 g/dl or less. With a hemoglobin level of 12.50 g/dl or above the predicted percentage decreased to 14.2%.

Conclusion

The values of hemoglobin were shown to influence in the risk of vascular access infection. More studies are needed to further evaluate the association between hemoglobin and the risk of infection.

#604 - Case Report

**FUSOBACTERIUM NECROPHORUM
BACTERAEMIA AND ATYPICAL LEMIERRE'S
SYNDROME**

Jesús Ramírez Navarro, Jaime Alonso Muñoz, Cristina Llamazares Mendo, Cristina Díez Romero, María Teresa Aldámiz-Echevarría Lois

Hospital General Universitario Gregorio Marañón, Madrid, Spain

Introduction

Fusobacterium necrophorum is a rare infection, known for causing Lemierre's syndrome. It consists of a primary oropharyngeal infection and evidence of internal jugular vein thrombosis, with associated bacteraemia and/or septic metastases. We present a case report of a variant of Lemierre's syndrome with no internal jugular vein thrombosis.

Case description

A 23-year-old man with no medical history presented to the emergency department with a 4-day history of sore throat, 40°C fever and generalized joint and muscle aches. Physical examination revealed fever, tachycardia, erythematous tonsils with no exudate and painful bilateral cervical lymphadenopathies. Blood tests showed thrombocytopenia, lymphopenia, elevated lactate, mild hyperbilirubinemia and elevated C-reactive protein (29.9 mg/dL) and procalcitonin (>100 µg/L). Sepsis due to cervical infection was suspected so antibiotic therapy with meropenem and clindamycin was initiated. Contrast-enhanced computed tomography of the neck revealed several inflammatory lymphadenopathies and findings suggestive of right maxilar vein thrombophlebitis. The patient was admitted to the Intensive Care Unit due to persistent hypotension and low oxygen saturation despite of fluids and oxygen therapy. A computed tomography of the chest was performed, which showed multiple bilateral pneumonic foci. Serologies were positive for acute Epstein Barr Virus (EBV) infection (IgM). Anaerobic blood cultures grew *Fusobacterium necrophorum*. The patient received intravenous ceftriaxone and metronidazole with a good clinical response, and was discharged from hospital after a week of intravenous treatment.

Discussion

Lemierre's syndrome is a rare disease with an incidence of 2-3 cases per million people per year, according to different studies. Its diagnosis requires a high degree of clinical suspicion along with data that indicates internal jugular vein thrombophlebitis (although it may not be present), sepsis, or septic emboli. Its association with EBV infection is not well characterized. Its management consists of an emergency antibiotic treatment, combining a third-generation cephalosporin or a betalactam with metronidazole. The role of anticoagulation is controversial, and the outcomes appear to be good without it. However, anticoagulant therapy could be used in high-risk situations related to thrombosis. Surgical treatment, such as surgical excision of affected veins or abscess drainage, may be required.

#615 - Case Report

**SPOROTRICHOID MYCOBACTERIUM
MARINUM INFECTION: A RARE CASE OF SKIN
ULCERS**

Miguel Martínez Lacalzada, Octavio Arce García, Grisell Starita Fajardo, Yasmina Sarhane, Marta Molins, Javier Bernal Maurandi, Jose María López Pintor-Huertas, José Luis Calleja López Ramón y Cajal University Hospital, Madrid, Spain

Introduction

Mycobacterium marinum is a slowly growing non tuberculous mycobacteria (NTM) found in non-disinfected salt and freshwater such as swimming pools and fish tanks. Among NTM it is the leading cause of extrapulmonary human infections worldwide.

Case description

A 57-year-old male was admitted to the hospital due to 16 days history of deep edema on the right hand and forearm with erythematous-scaly nodules and sporotrichoid distribution, some of them ulcerated. There was no lymphadenopathies, fever, arthralgia or any other systemic signs or symptoms. He described having 3 fish tanks at home and a skin trauma with a cactus 17 days before, treated with oral amoxicillin-clavulanic acid for 1 week without clinical improvement. Laboratory tests did not show significant findings. Skin biopsy was performed, histopathological examination showed septal panniculitis with lymphomonocytic infiltration and multiple foci of neutrophils with multinucleated giant cells infiltration without granuloma. Microbiological stains performed in biopsy specimen were negative. A Löwenstein-Jensen culture was performed at low temperature between 28°C-32°C as cutaneous *M. marinum* infection was suspected and patient was treated with clarithromycin (500 mg twice per day) and etambutol (800 mg per day). *M. marinum* was isolated 3 weeks later and lesions disappeared 2 months later.

Discussion

M. marinum grows on Löwenstein-Jensen substrate within 2-3 weeks at 30-32°C. The infection is primarily localized at the inoculation site in the skin, lesions appears 2-3 weeks after exposure as an ulcerated nodule, a central clearing verrucous plaque or a sporotrichoid lesion on areas exposed to trauma. The frequently delayed diagnosis is attributed to the rare nature of this infection, the fact that cutaneous elements can resemble *Staphylococcus* spp. infection and the low yield of acid-fast bacilli microscopy, so a negative result cannot rule out this diagnosis and must be accompanied by culture. Histological image of early lesions usually shows non-specific inflammation. There is no consensus on the treatment, according to IDSA guidelines a combination of oral clarithromycin and ethambutol is preferred for at least two months more from the clinical cure, with rifampicin addition for deep structure infection. So, cutaneous "*M. marinum*" infection has a long delay in diagnosis and should be a high index of suspicion in slow developing cutaneous lesions and relevant aquatic exposure, a combined antibiomatic treatment is preferred

#619 - Medical Image

PULMONARY CAVITATION - TUBERCULOSIS AT THE HEART OF THE DIAGNOSIS

Magda Sofia Silva, Francelino Ferreira, Rúben Reis, Anneke Joosten, Ana Paula Pona, Laurinda Pereira, Fátima Campante
Centro Hospitalar Barreiro Montijo, Barreiro, Portugal

Clinical summary

Pulmonary cavitation is the classic hallmark of Tuberculosis and is associated with antimycobacterial-drug resistance and treatment failure. We report the case of a 46-year-old man, with no past medical history or relevant epidemiological context, admitted in the ER with a 3-months of progressive asthenia, unintentional weight loss and fatigue. Physical examination showed cachectic state, febrile, polipneic at rest, and decreased vesicular murmur in the upper half of the right hemithorax, with bilateral crepitations. Chest radiography showed bilateral parenchymal infiltrations with predominance in the upper lobes with multiple cavitations. Many BAAR were observed in the examination of sputum. It was initiated therapy with HERZE, but patient died during the first month of treatment.

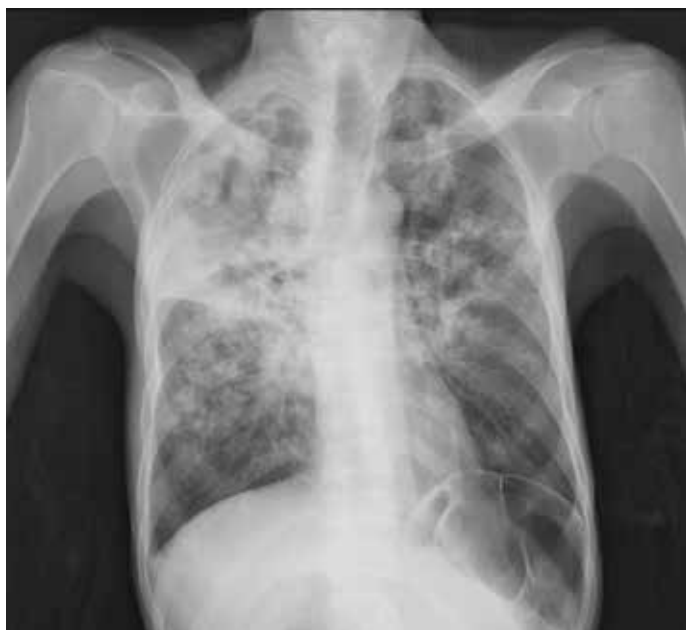

Figure #619. Tuberculosis.

#623 - Case Report

USE OF DALBAVANCINA IN PATIENT WITH SECONDARY RED MAN SYNDROME TO VANCOMYCIN

Juan Miguel Manrique Perez, Beatriz Rodriguez Alonso, Amparo López Bernús, María Sánchez Ledesma, Moncef Belhassen
Complejo Asistencial Universitario, Salamanca, Spain

Introduction

We present the following case to demonstrate the efficacy and safety of dalbavancin in a patient who presented red man syndrome secondary to vancomycin.

Case description

A 28-year-old male with a diagnosis of sepsis secondary to folliculitis in the beard, abscess in the naso-genian region with facial vein thrombosis. Septic pulmonary emboli and secondary pulmonary infarction and septic arthritis. Empirical antibiotic treatment is established with meropenem and vancomycin. Two blood cultures are positive for *Staphylococcus aureus* methicillin resistant at 24 hours. The patient presented an erythematous reaction suggestive of “red man syndrome” after the slow administration of vancomycin, so a change was made to daptomycin. After clinical stability, hospital discharge with dalbavancin was decided for 4 weeks with good response.

Discussion

Dalbavancin is a lipoglycopeptide derived from teicoplanin, which allows its administration in a single weekly or biweekly intravenous dose, which positions it as an excellent therapeutic option for ambulatory use in stable patients. The red man syndrome is characterized by a maculopapular skin rash on the neck, face, upper part of the trunk and upper extremities. Sometimes associated with increased temperature, hypotension, bradycardia, and even cardiac arrest. Our patient presented generalized cutaneous rash on the trunk and extremities. This adverse effect usually appears during or immediately after the administration of vancomycin, is generally self-limiting and decreases when the administration of the same is interrupted, manifestations that were not presented later with the administration of dalbavancin. The studies published so far have confirmed the efficacy, safety and tolerability of dalbavancin in the treatment of skin and soft tissue infections. Side effects of dalbavancin were mild, including nausea, diarrhea, fever, headache, oral candidiasis, and pruritus. Serious events were infrequent and included episodes of transitory urticaria, cellulitis, anaphylactic reaction and leukopenia. We note that dalbavancin may be a safe and effective option in patients with red man syndrome secondary to vancomycin if positive GRAM infection is suspected. Although more studies are needed to define its exact role.

#627 - Case Report

PROSTHETIC AORTIC VALVE ENDOCARDITIS WITH PROPIONIBACTERIUM ACNES

Simone Arnold¹, Peter Ballmer^{1,2}

¹ Departement of Medicine, Kantonsspital Winterthur, Winterthur, Switzerland

² Zürcher RehaZentrum, Davos Clavadel, Switzerland

Introduction

Endocarditis is typically symptomatic and patients present in reduced condition. The diagnosis can be missed in patients with atypical germs with mild or uncommon symptoms. *Propionibacterium acnes* is a rare cause of infective endocarditis; it is part of the normal flora of the human skin and known for acne.

Case description

A 73-year old man presented to the emergency room due to binocular loss of vision in the upper right quadrant without other neurological deficiency. The cMRI showed multiple ischemic cerebral strokes. The patient had an aortic valve replacement 6 years previously.

A cardioembolic cause of the insults was postulated, but neither an atrial fibrillation was documented nor valve vegetations were found with transthoracic echocardiography. We initiated a secondary prophylaxis with apixaban and atorvastatin. Three weeks later the patient suffered from chills and subfebrile temperatures and was again hospitalised because of suspected aortic valve vegetations in a transoesophageal echocardiography (TEE).

The physical examination revealed a systolic cardiac murmur without additional pathologic findings. Inflammatory blood parameters were slightly elevated.

In a second TEE vegetations were confirmed (without aortic insufficiency). In 3/3 anaerobic blood cultures *Propionibacterium acnes* was detected. Other germs typically for culture negative endocarditis such as *Bartonella henselae*, *Brucella* und *Coxiella burnetii* were ruled out. Another cMRI revealed new septic embolisms with hemorrhagic infarction and subarachnoid bleeding. Retrospectively, all cerebral infarctions were caused by septic embolisms, therefore we stopped anticoagulation.

An antibiotic therapy with gentamycin and penicillin was initiated. The inflammatory parameters were decreasing, and the patient was no more subfebrile; the TEE showed unchanged valve vegetations after two weeks of treatment. The indication for a surgical valve replacement was given. More than two months after the diagnosis, the operation successfully took place, after intracerebral bleeding was mostly resorbed.

Discussion

Propionibacterium acnes is an uncommon germ of endocarditis. The diagnosis is difficult because of the atypical symptoms. Septic embolism is common. Even if the endocarditis is not causing a valve insufficiency redo should be considered because progressive embolism can be clinically silent.

#632 - Case Report

BRUCellar SPONDYLODISCITIS: AN UNUSUAL DIAGNOSIS

Mariana Costa¹, Marina Vitorino¹, Beatriz Porteiro¹, Marinela Major¹, João Machado²

¹ Hospital Professor Doutor Fernando da Fonseca, Lisboa, Portugal

² Hospital Professor Doutor Fernando da Fonseca, Lisbon, Portugal

Introduction

The diagnosis of brucellar spondylodiscitis is often difficult since the clinical presentation may be obscured by many other conditions. The diagnosis of human brucellosis requires isolation of the bacteria or confirmation through serologic tests. However, culture sampling

sensitivity is often low, depending on the disease stage. Over time, there have been major advancements in all aspects of molecular diagnostics with regard to human brucellosis. PCR-based tests are proving to be faster and more sensitive than traditional methods.

Case description

A 69-year-old man was admitted to the hospital due to a back pain with irradiation to the left lower limb, that had gradually developed over 3 months. In association he referred night sweats and a weight loss (5 Kg). He had no medical problems; was retired and raised goats and sheep. He reported that months before the beginning of the symptoms, had participated in the delivery of a sheep whose fetuses showed multiple malformations. The general physical examination was normal. Neurologically the Lasegue sign was positive in left leg. The initial laboratory studies didn't show significant alterations. A MRI showed: a lesion on the anterior epidural portion of L4 continuous with the posterior portion of the intervertebral disk of L3-L4 that conditioned a molding of the dural sac; and an epidural collection in the anterior portion of L4. A CT guided percutaneous biopsy of the epidural collection was performed in which the PCR for *Brucella* was positive. The cultures of the collection and the blood were negative. Serologies for *Brucella* (ELISA and the rose of Bengal) were positive. Antibiotherapy with doxycycline, rifampicin and gentamicin, the latter during 7 days, was started. The patient had a favorable evolution and was discharged but on the seventh day after the discharge there was a clinical and imagological worsening. Consequently he was submitted to an emergency surgery. It was performed a laminectomy of L3 and L4, foraminectomy of L3-L4 and L4-L5 and a discectomy. After the intervention, the antibiotherapy with rifampicin and doxycycline was maintained during 6 months and a new course of gentamicin was started and maintained during 30 days.

Discussion

In this case the epidemiological history was determinant for the diagnosis orientation, but it was the positivity of the PCR for *Brucella* that allowed the definitive diagnosis. This case illustrates the increasing importance, despite some limitations, of molecular diagnosis of brucellosis.

#642 - Case Report

WHIPPLE'S DISEASE WITH ASYMPTOMATIC INVOLVEMENT OF THE CENTRAL NERVOUS SYSTEM.

Gabriela Alexandra Casinos Isart, Ramon Boixeda, Manuela Josefa Sampedro, Olga Eulàlia García Vidal, Maria Montserrat Duh, Montserrat Mauri, Peter Reth, Marta Parra, Raquel Aranega, Laura Pacho, Paula Fernández, Aleix Serrallonga, Carlos Lopera, Mariela Silvana Plenc, Celina Suarez, Angela Felip
Hospital de Mataró, Mataró, Spain

Introduction

A sixty-four year old man was admitted in the internal medicine

unit to further study explaining a two months history of watery diarrhea, abdominal pain, fever and weight loss. He had a history of seronegative rheumatoid polyarthritis.

Case description

Blood tests showed signs of inflammation, malabsorption and iron deficiency anemia. An MRI revealed mesenteric nodes and a totally concentric enhancement around the last portion of the duodenum. We underwent an upper gastrointestinal endoscopy. Biopsy specimens revealed infiltration of periodic acid-Schiff (PAS)- positive macrophages in the lamina propria of the duodenum, which suggested the diagnosis of Whipple's disease.

Discussion

As polymerase chain reaction (PCR) assay of *T. whipplei* was positive in the cerebrospinal fluid study, we decided to keep ceftriaxone 2 g daily for four weeks, followed by oral Trimethoprim-sulfamethoxazole 160/800 mg daily for a year. The patient remains asymptomatic.

#648 - Abstract

CONTAMINANTS IN HEMOCULTURES: A SINGLE-CENTER PILOT STUDY IN A TERTIARY CARE TEACHING HOSPITAL IN ITALY

Lorenzo Maria Canziani, Guendalina De Nadai, Federica Maria Pilar Tordato, Daria Pocaterra, Paola Morelli

Istituto Clinico Humanitas, Milano, Italy

Background

In 2017, an internal report at our Institution revealed that Coagulase Negative Staphylococci (CoNS) represented 30.7% of positive hemocultures (295/962 events). This was partly due to the fact that in this report contaminations were counted as infections. According to literature, the fraction of patients with CoNS-positive blood cultures with a significant bloodstream infection represents 12-25% of cases. We wanted to define the rate of contamination in hemocultures sampling and to describe CoNS-related infections.

Methods

We prospectively collected all consecutive positive hemocultures in patients who were admitted to our 750-bed teaching hospital from 1 July 2018 to 31 December 2018. To assess if a positivity represented a contamination, we used microbiological (time of growth, number of samples with the same germ, judgment by clinical microbiologist) and clinical variables (need of antibiotic therapy, clinical judgment of attending physician). We also recorded the sampling ward to stratify wards according to the quality of sampling.

Results

Over a period of 6 months, 634 positive hemocultures were collected in 327 patients. 191 (30.1%) were contaminants.

CoNS represented the largest population of contaminants (160, 83.77%). The most frequent bacteria involved were *S. epidermidis* (35%), *S. hominis* (25%), *S. capitis* (9%), *S. haemolyticus* (5%).

Among CoNS positive hemocultures (247), 87 represented infection (35%). 61 of them were related to central venous lines (70%). Intrahospital mortality was 16%.

S. hominis and *S. capitis* were less likely involved in infection (25% and 26%, respectively) than *S. epidermidis* or *S. haemolyticus* (44% and 47%, respectively, p-value .046).

In wards with at least 30 positive hemocultures, rate of contamination on total of positive hemocultures ranged from 20% to 42%.

Conclusion

At our Institution, contamination of hemocultures is a frequent problem and represents a laboratoristic and diagnostic challenge. CoNS were the most common cause of contamination. Some CoNS seem to be more likely to represent infection when found in hemocultures. In this pilot study, the wide range of contamination rate gives proof of concept of possible reduction of false positive results during sampling of hemocultures.

#656 - Case Report

BRUCELLOSIS AND CERVICAL EPIDURAL ABSCESS: A CASE REPORT

Afroditi Roumpou, Christos E Lampropoulos, Ioanna Papaioannou

Argolidos General Hospital, Nafplion, Greece

Introduction

Brucellosis is caused by a gram-negative coccobacillus of the genus *Brucella* (*B. melitensis* is the most common). It is transmitted by consumption of unpasteurized milk, dairy products or direct contact with infected animals. Half of the cases occur in the meat-processing industry. Osteoarticular involvement occurs in 40% of cases (arthritis, sacroiliitis, Spondylitis, osteomyelitis). Spondylitis and epidural abscess most commonly affect the lumbar spine while cervical is rarely affected.

Case description

A 70 year-old lady farmer presented fever, knees swelling, nocturnal sweats, cervical and lumbar pain the last month. Her medical history included hypertension and brucellosis 30 years ago. Clinical examination revealed tenderness of cervical and lumbar spine with motion restriction but no neurological deficits. Blood tests revealed Ht:35.4%; AST:71 IU/L; ALP:167 IU/L; ESR: 80 mm/h; rheumatoid factor:132 IU/mL. Mantoux test and blood cultures were negative. Abdominal ultrasound showed hepatosplenomegaly, lumbar MRI disc herniations and cervical MRI spondylodiscitis at C4-C5 with epidural abscess compressing the spinal cord. Despite initial brucella negative tests empirical treatment was applied with streptomycin (1gr/day) and doxycycline (100 mgx2). After the 3rd week streptomycin was substituted by rifampicin (900 mg/d). Fever gradually declined with improvement of cervical pain and motion. Blood tests were

repeated after 10 days, with positive antibodies against Brucella [IgG 70IU (negative <30), IgM 46IU (negative <20)]. She was treated for 4 months with amelioration of epidural abscess and decompression of spinal cord.

Discussion

Epidural abscess is responsible for 1/1,000 admissions. The most common cause is *Staphylococcus aureus* while *Brucella* is responsible for only 0.1% of the cases. Risk factors are immunosuppression, spinal procedures or trauma. Diagnosis is based on cultures (intermittent bacteremia) or positive serology (may initially be negative). Most epidural abscesses are located in thoracic and lumbar spine, whereas cervical abscesses are rare. Treatment consists of combined-drug regimen, rifampicin plus doxycyclin with addition of aminoglycosides in severe cases (treatment duration 6 weeks – 1 year). Surgical intervention is recommended for spinal cord compression or neurologic deficits. Delayed diagnosis may lead to permanent neurologic sequelae. Brucellosis must always be considered in patients with spinal cord pain, especially in endemic areas.

#667 - Case Report

EXTENSIVE INTESTINAL TUBERCULOSIS WITH MULTIPLE, LARGE GRANULOMAS: A CASE REPORT

Afroditi Roumpou, Christos E Lampropoulos, Ioanna Papaioannou
Argolidos General Hospital, Nafplion, Greece

Introduction

Intestinal tuberculosis (ITB) affects especially the ileum, ascending and transverse colon. It is classified in the ulcerative, hypertrophic (scarring, fibrosis, mass-like appearance) and ulcerohypertrophic form (mixed features). Patients present abdominal pain, weight loss, night sweats, low grade fever, palpable mass, malabsorption or altered bowel habits. Treatment consists of antibiotics or surgical intervention in case of complications (perforation, hemorrhage, ileus, acute abdomen).

Case description

A 42-year old man presented low-grade fever, weight loss (20kg), pain of right iliac fossa, constipation and tendency to vomit the last 2 months. His medical history was free. Clinical examination revealed abdominal wall rigidity and rebound tenderness of the right iliac fossa. Chest x-ray showed a small (<1cm) nodule of right upper lobe and abdominal x-ray dilatation of right colon with air-fluid levels. Abdominal ultrasound revealed lymphadenopathy. Laboratory investigation showed leukocytosis, thrombocytosis and high ESR (45/1h). He was operated immediately because of acute abdomen. Terminal ileum, ileocaecal valve and ascending colon were occupied and distorted by multiple, large masses with enlarged lymph nodes in mesentery. A right hemicolectomy was performed whereas tissue biopsy revealed large confluent granulomas with central necrosis and Langerhans cells infiltrating

mucosa, submucosa, smooth muscles as well as lymph nodes, a finding compatible with TB. Tuberculin skin test was positive (16 mm). Patient was started on four-drug regimen: rifampicin 600 mg/d, isoniazid 300 mg/d, pyrazinamide 1.500 mg/d and ethambutol 1.000 mg/d. He was discharged after ten days with marked improvement. Six months later he was in very good condition with normal weight and without symptoms.

Discussion

ITB is common in developing world but not in western countries. Symptoms are not specific and ITB usually manifests as ileitis. Diagnosis is based on detection of bacilli in biopsy (sensitivity 25-35%), positive cultures (diagnosis after 4-8 weeks, positive in 30%), PCR (sensitivity 40-75%) and Quantiferon-TB Gold. ITB must be differentiated mainly by Crohn's disease (CD) and colon cancer. ITB and CD are chronic granulomatous diseases with common clinical, endoscopic, radiologic and histopathologic findings. Therefore, their differentiation is crucial for treatment determination.

#670 - Case Report

PERITONEAL TUBERCULOSIS AS A CAUSE OF ASCITES IN A PATIENT WITHOUT PORTAL HYPERTENSION

Luis Benjamín Godínez, Juan Francisco Barrios, Gabriel Antonio Ríos, Rudy López

Instituto Guatemalteco de Seguridad Social, Guatemala, Guatemala

Introduction

TB is a worldwide disease. In 2015, there were an estimated 10.4 million new TB cases worldwide, of which 5.9 million (56%) were men and 3.5 million (34%) were women. Peritoneal TB accounts for about 0.1%–0.7% of all cases of TB. In general, in developing countries, the disease is observed predominantly in females.

Case description

A 24-year-old female patient with no known medical history comes to the emergency with a history of abdominal distension which was associated with weight loss, hyporexia, nausea and unquantifiable fever. The physical examination showed an increase in abdominal diameter, with gastrointestinal noises increased in intensity and frequency, and pain on palpation. The laboratories are normal and peritoneal fluid analysis showed a predominance of neutrophils and a gradient of serum-ascitic albumin <1.1 mg/dl, the Gram rub did not report any microorganism and the culture was reported as negative. The analysis for acid-resistant bacilli was negative and the culture was pending. Imaging studies were performed, in which the liver, bile ducts and peritoneum were normal, on the chest tomography apical pneumoatelectasis in the right lung is observed. Considering tuberculosis as the first option, GeneXpert is performed, which is positive for mycobacteria and does not report resistance to rifampicin. Therefore, treatment with a four-drug regimen is initiated. However, the patient

presents a poor evolution, so it is necessary to perform two decompressive paracentesis, complementary tests are performed which are reported as normal. Finally, the culture result for mycobacteria is obtained, which reports *M. tuberculosis* MDR; for which the patient is referred to a quaternary care center to receive treatment. For psychosocial reasons the patient requests a contraindicated discharge and dies 4 weeks later.

Discussion

Tuberculous peritonitis is rare, and the diagnosis of this disease requires a high clinical index of suspicion and should be considered in the differential of ascites with a lymphocyte predominance and serum-ascitic albumin gradient of <1.1 mg/dl. Microbiological or pathological confirmation remains the gold standard for diagnosis. Although the treatment is generally effective, even with MDR stains, there are many factors that can influence in the prognosis. There were no risk factors identified in this patient other than poor conditions of living.

#677 - Medical Image

PULMONARY ASPERGILOSIS IN AN IMMUNOCOMPETENT ADULT

Ana Corte Real¹, Tiago Duarte², Alexandra Caeiro², Nuno Germano², Fernando Maltez²

¹ Centro Hospitalar do Oeste, Hosp. de Caldas da Rainha, Caldas Da Rainha, Portugal

² Centro Hospitalar Lisboa Central, Hosp. de Curry Cabral, Lisboa, Portugal

Clinical summary

A 43 years-old male, from Guiné-Bissau, with type 1 diabetes and pulmonary tuberculosis (TB) 3 years before, presented fever, hemoptoic sputum, 30 Kg weight loss and abdominal pain. He had leukopenia, CPR 1.8 mg/L and pulmonary cavitated lesions with mycetomas and pneumatoceles. Bacilloscopy and HIV serology were negative. Galactomannan antigen, *M. tuberculosis* nucleic acid amplification and culture for *Aspergillus flavus* were positive in bronchoalveolar lavage. He started anti-TB drugs and amphotericin B. Abdominal CT scan showed mucosal thickening (ileus, appendix and colon) and endoscopy an ulcerated esophagus and stomach with mucosa edema. Biopsies were inconclusive. He evolved to septic shock and death (11th day).

Diabetes was the only immunosuppression risk factor we found.

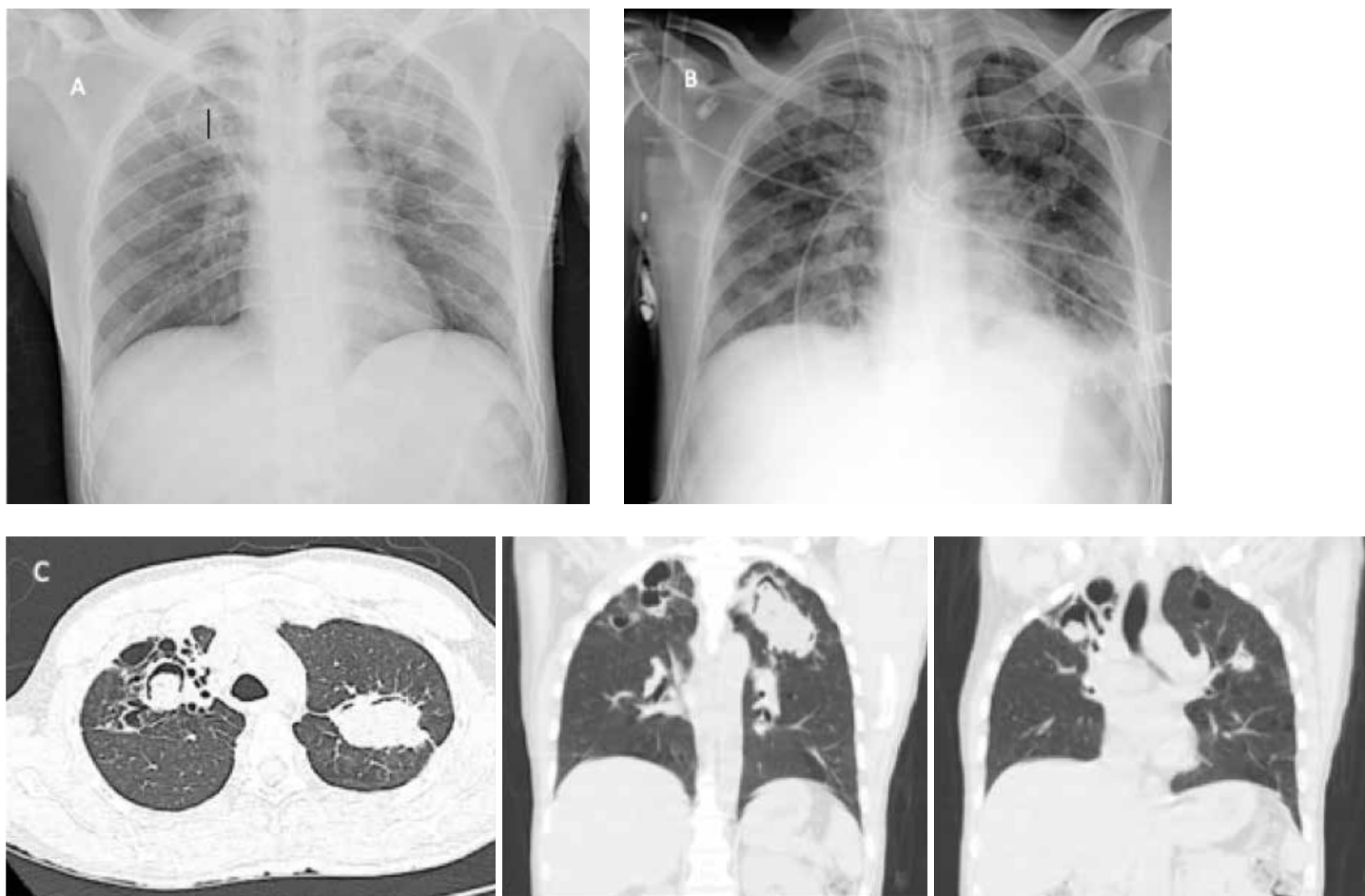


Figure #677. Panel A: Thorax X-ray at admission with hypotransparency of left pulmonary apex. Panel B: Thorax X-ray after orotracheal intubation, 7 days after image A, with cavitations and hypotransparent mass inside of them, both sides; Panel C: Thorax CT scan with numerous pneumatoceles and mycetomas, both apices.

#693 - Case Report

SKIN TUBERCULOSIS LESIONS IN A PATIENT WITH POTT DISEASE

E.Paula Fernandez Fernandez, Josep Antoni Capdevila, Gemma Sais, Mariona Perez, Marta Parra, Ramon Boixeda, Gabriela Casinos, Astrid Joanne Vera Arkesteijn, Laura Pacho, Aleix Serrallonga, Raquel Aranega, Carles Lopera, Celina Suarez, Mariela Silvana Plenc, Angela Felip

Hospital de Mataró. Consorci Sanitari del Maresme, Mataró, Spain

Introduction

Tuberculosis (TB) continues to be a highly prevalent pathology worldwide. Caused by *M. tuberculosis*, musculoskeletal tuberculosis represents 10-35% of cases of extrapulmonary TB and vertebral location, also known as Pott's disease, is the most frequent (50%). Cutaneous tuberculosis is a rare presentation (1-2%), and metastatic abscesses or gumma are a very infrequent form of it. Both presentations in immunocompetent patients are infrequent in literature.

Case description

We report a case of a thirty-year-old women admitted in our hospital for study of diffuse lumbar pain with asthenia and hyporexia of six-month duration. The patient, from Morocco, was living in Spain for two years. Physical examination revealed papular skin lesions, some necrotic and ulcerated, predominantly in the extremities. Lumbar magnetic-resonance (MRI) was performed, revealing spondylodiscitis from L1 to L3 vertebra, and epidural abscess in the paravertebral space and left psoas muscle. Biopsy of paravertebral mass and skin lesions were performed. Pathological examination showed granulomas with caseation necrosis. For high suspicion of tuberculous aetiology, antituberculostatics were initiated. Subsequently, biopsy-tissue culture was positive for *M. tuberculosis*, and diagnosis was confirmed. The patient presents progressive improvement of lumbar pain and resolution of skin lesions.

Discussion

Our case report is an uncommon and widespread affectation of *M. tuberculosis* in a non-immunocompromised patient. Cutaneous abscesses and vertebral lesions result from haematogenous spread of *M. tuberculosis* from a primary focus. Usually more than two vertebrae are affected and eventually, infection can spread to adjacent soft tissues forming cold abscesses and narrowing of the spinal canal, with risk of spinal compression and neurological deficits.

Symptoms are non-specific being chronic and progressive lumbar pain the most frequently. Delay in diagnosis is common and the probably of neurological complications is high. Cutaneous lesions are also rare and very heterogeneous, and they occur in a large profile of patients, independent of the immunitary status. Confirmatory diagnosis is based on the identification of the mycobacterium in cultures but MRI is very sensitive tool in the assessment of neurological commitment.

It is important to take into account this aetiology in chronic low

back pain or suspicious skin lesions due to early diagnostic and prompt treatment has prognostic and epidemiological importance.

#695 - Abstract

INTRA-ABDOMINAL INFECTIONS: THE ROLE OF DIFFERENT CLASSIFICATIONS ON THE SELECTION OF THE BEST ANTIBIOTIC TREATMENT

João Silva Nunes¹, Teresa Cardoso^{1,2}

¹ Instituto de Ciências Biomédicas Abel Salazar, Universidade do Porto (ICBAS-UP), Porto, Portugal

² Hospital de Santo António - Centro Hospitalar Universitário do Porto (HSA-CHUP), Porto, Portugal

Background

Intra-abdominal infections (IAIs) represent one of the most frequent gastrointestinal emergencies. Two classifications are used: uncomplicated or complicated, considering the extent of infection, and community-acquired, healthcare-associated or hospital-acquired, based on the place of acquisition. Inadequate antibiotic therapy is associated with treatment failure and increased mortality. This study was designed to determine the accuracy of the different classifications of IAIs to identify infections by pathogens sensitive to current treatment guidelines helping in the selection of the best antibiotic therapy

Methods

Retrospective cohort study including all adult patients discharged from the hospital with the diagnosis of IAI between 1st of January and 31st of October of 2016. All variables potentially associated with pre-defined outcomes: infection by a pathogen sensitive to non-pseudomonal cephalosporin or ciprofloxacin plus metronidazol (ATB1), sensitive to piperacillin-tazobactam (ATB2) and hospital mortality were studied through logistic regression. The accuracy of the models was assessed by the area under receiver operating characteristics (AUROC) curve and calibration was tested using the Hosmer-Lemeshow goodness-of-fit test.

Results

Of 1804 patients screened 154 met the inclusion criteria. Sensitivity to ATB1 was independently associated with male gender (adjusted OR=2.612) and previous invasive procedures in the last year (adjusted OR=0.424) (AUROC=0,65). Sensitivity to ATB2 was independently associated with liver disease (adjusted OR=3.580) and post-operative infections (adjusted OR=2.944) (AUROC=0.604). Hospital mortality was independently associated with age ≥ 70 (adjusted OR=4.677), solid tumour (adjusted OR=3.127) and sensitivity to non-pseudomonal cephalosporin or ciprofloxacin plus metronidazole (adjusted OR=0.368). The accuracy of pre-existing classifications to identify infection by a pathogen sensitive to ATB1 was 0.59 considering place of acquisition, 0.61 extent of infection and 0.57 local of infection, for ATB2 it was 0.66, 0.50 and 0.57, respectively.

Conclusion

In this study, none of the existent classifications had a good discriminative power to identify IAls caused by pathogens sensitive to current antibiotic treatment recommendations. A new classification that includes individual characteristics of the patients like those included in the current model might have a higher potential to distinguish IAls by resistant pathogens allowing a better choice of antibiotic.

#697 - Case Report

COULD IT BE CREUTZFELDT-JAKOB DISEASE?

Sofia Manuela Perdigao¹, Ana Sofia Alves¹, Cristiana Sousa¹, Paula Vaz Marques¹, Rafael Geraldo Jesus², Ana Rita Raimundo²

¹ CHTMAD, Chaves, Portugal

² CHTMAD, Vila Real, Portugal

Introduction

The Creutzfeldt-Jakob (CJ) disease or also known as prions disease, is characterized by a vast number of symptoms that include progressive cognitive deterioration, myoclonus and walking disturbance. Usually transmission occurs via ingestion of contaminated food, or contact with a poised brain or fluids. The prion accumulates in the brain causing a spongiform encephalopathy, initially there are complains of amnesia, later begins myoclonus and then in advanced stages are walking disturbances and severe cognitive alterations, even coma.

Case description

A 66-years-old woman, previously autonomous. History of depression, hypertension, diabetes type 2 insulin dependent, osteopenia and narrow lumbar canal. The patient was submitted to a laminectomy and arthrodesis of lumbar vertebrae, in March of 2018. The procedure was complicated with a spondylodiscitis that required remove of orthopedic material and progress to post-operation shock with multiple organ dysfunction that required organ support and large spectrum antibiotic with favourable response and resolution of the complication. In September of 2018, she starts with episodes of amnesia, myoclonus in the left side of body and face and walking disturbances with 2 weeks of evolution, she was observed by a neurology and she was ingress to complementary study. It was performed a brain magnetic resonance (MRI) and an encephalogram that suggested CJ. The lumbar puncture was positive for the 14.3.3 protein. During the hospitalization the patient presented a rapid deterioration of her conscious level, with dystonic postures, tetraparesis and non-controlled status epilepticus. After exclude all metabolic, autoimmune and infectious causes, the patient repeated the MRI that once more was suggestive of CJ disease. So the diagnosis was assumed but the family refused autopsy for a definitive diagnosis. Due to the clinic evolution and poor prognostic, comfort measures were assumed and the patient died at day 39 of hospitalization.

Discussion

Although a rare disease CJ must not be forgotten, because of its bad prognostic and fast mental deterioration. After all remaining causes excluded and in the presence of suggestive findings, such as fast mental deterioration, it should be equated.

#709 - Medical Image

MILIARY TUBERCULOSIS: IMAGIOLOGIC PERSPECTIVE OF A CLINICAL CASE

Miguel Gonzalez Santos, Adriana Bandeira, Tatiana Costa Pires, Diana Castro, Ana Rita Rodrigues, Ana Catarina Santos, Miriam Magalhães, Alcina Ponte

Centro Hospitalar de Leiria, Leiria, Portugal

Clinical summary

Seventy year old male patient, completely dependent, with a history of multiple previous hospital admissions for Pneumonia. He presents, once again, in the emergency department with dispnoea and fever. Blood work revealed only leucocitosis and elevated CRP. On chest X-ray, there was evidence of right lung opacity, compatible with pneumonia. Sputum culture was positive for *P. aeruginosa*. Sputum direct analysis (Ziehl-Neelson coloring) was negative for *M. Tuberculosis*.

Specific antibiotic therapy was started.

In spite of evident improvement on chest X-ray, the patient maintained fever and high CRP. A chest CT was, therefore, ordered. It revealed right superior lobe "bud-tree" micronodular condensation. Micobacterium culture turned out positive later on.

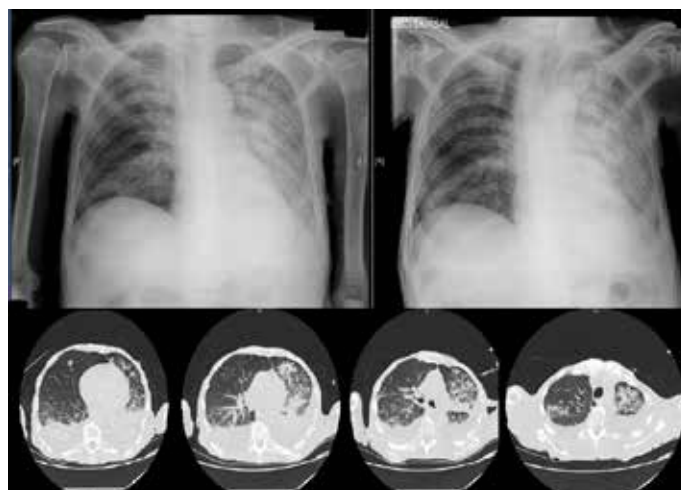


Figure #709. Image showing X-ray evolution (above) and respective diagnostic CT scan (below).

#711 - Case Report

MILIARY TUBERCULOSIS ASSOCIATED WITH SEVERE THROMBOCYTOPENIA

Laura Pacho Millan, Marta Parra Navarro, Gabriela Casinos Isart, Raquel Aranega Gonzalez, Carlos Lopera Marmol, Paula Fernandez Fernandez, Josep Anton Capdevila Morell
Hospital de Mataro, Mataro, Spain

Introduction

Patient male of 38 years of old, born in Gambia and living in Spain for two years, that consults for fever during two months.

Case description

38 year-old patient that consulted for two months of fever and night sweats, arthromyalgias, cephalgia and dyspnea. The patient also reported autolimited macroscopic hematuria and unquantified weight loss. He did not present cough neither expectoration.

The physical examination showed inguinal adenopathies, jaundice and painful hepatosplenomegaly.

The blood analysis showed severe hepatic cholestasis and the chest radiography showed a bilateral reticular pattern compatible with miliary tuberculosis. An sputum BK was positive, so it confirmed the diagnostic of disseminated miliary tuberculosis. A regimen of three antituberculous drugs was initiated with rifampicin, isoniazid and ethambutol (without pyrazinamide because of the severe cholestasis).

The patient was progressively improving clinically, remaining afebrile, and improving analytically with a decrease of the bilirubin levels and improving nutrition parameters in need of enteral nutrition.

A week before discharge, the patient presented an abundant epistaxis and an urgent blood analysis was performed showing severe anemia with hemoglobin levels of 6.5 g/dl and thrombocytopenia with a total count of platelets of 4000/ μ L, requiring transfusion support. An urgent bone marrow aspirate was performed showing abundant megakaryocytes. It was initiated oral corticosteroid therapy with 1 mg/kg/day dosage improving the platelet counting with a total number of 57000/ μ L at the hospital discharge.

Discussion

Miliary tuberculosis is rarely associated with severe thrombocytopenia in the literature. There are two pathophysiological ways described in the literature. It can be drug-induced because of the antituberculous drugs, the most frequent related is rifampicin, but also there are cases described with isoniazid and ethambutol; and it can be an idiopathic immune thrombocytopenia (ITP) associated to a miliary tuberculosis.

They are two entities clinically and diagnostically indistinguishable because both are responsible of severe thrombocytopenia and can respond to corticosteroid therapy, and both show megakaryocytes in the bone marrow aspirate. Antiplatelet antibodies can be performed in order to make the differential diagnosis but they are unprofitable in most cases.

It is interesting to do an interdisciplinary follow up of these patients in the outpatient clinics by the internist and the hematologist

#718 - Case Report

CRYPTOCOCCUS INFECTION IN A NON-HIV PATIENT - A CASE REPORT

Roberto Calças Marques¹, Anabela Malho Guedes¹, Mafalda Aveiro², Ana Ribeiro³, António Veiga Moura³

¹ Nephrology Department, Centro Hospitalar e Universitário do Algarve, Faro, Portugal

² Family Medicine, USF Ossónoba, ACES Algarve Central, Faro, Portugal

³ Internal Medicine Department, Centro Hospitalar e Universitário do Algarve, Faro, Portugal

Introduction

Cryptococcal meningitis (CM), caused by *Cryptococcus neoformans*, is a life-threatening HIV-related opportunistic infection. In recent decades the incidence of CM has increased, especially in immunocompromised HIV-negative patients. Factors predisposing to cryptococcal infection include diabetes, cancer, chemotherapeutic agents, corticosteroid therapy and renal failure/dialysis. Suspicion to diagnose begins with clinical symptoms that can be non-specific, such as headaches and vomiting. We present a case of steroid-induced cryptococcal infection in a non-HIV infected person.

Case description

A 67-year-old male with history of systemic lupus erythematosus, taking high-dose chronic corticosteroid, was presented to the emergency department with complaints of frontal headache, nausea, vomiting, dizziness and occasional horizontal diplopia over a week period. He was afebrile, hemodynamically stable, oriented and displayed completely normal neurologic functioning. The patient underwent a cranial computerized tomography (CT) and a subsequent magnetic resonance imaging, which were normal. He returned 2 days later with bilateral papillary oedema revealed in ophthalmological examination. Laboratory results included a normal white blood cell (WBC) and a C reactive protein (CRP) of 61 mg/L. Serological test for HIV was negative. As the immunological tests showed positive lupus anticoagulant and anti-beta2 glycoprotein I and considering the high levels of d-dimer, he did CT venography that excluded venous thrombosis. Lumbar puncture was performed. Cerebrospinal fluid analysis confirmed cryptococcal Ag with a titer of 1:4, WBC 59/mm³, glucose 56 mg/dL and proteins 30 mg/dL. Culture was positive to *Cryptococcus neoformans*. The patient completed a 4-week course of amphotericin B and 5-Fluorouracil and was discharged with complete resolution of the presented symptoms.

Discussion

Chronic steroid use can predispose patients to many infections. The inclusion of cryptococcal antigen test in the initial cerebrospinal fluid analyses led to the diagnosis. This case report emphasizes the

need to recognize cryptococcus as a possible cause of meningitis in all immunosuppressed patients, not only in those with HIV.

#719 - Case Report

PROGRESSIVE MULTIFOCAL LEUKOENCEPHALOPATHY SECONDARY TO CHRONIC LYMPHOCYTIC LEUKEMIA: A RARE ETIOLOGY IN A RARE DISEASE

Filipa Sousa Gonçalves, Nina Jancar, Mariana Simões, Patrício Aguiar, José Luís Ducla Soares
Centro Hospitalar Universitário Lisboa Norte, Lisbon, Portugal

Introduction

Progressive multifocal leukoencephalopathy (PML) is a demyelinating disease of the central nervous system, caused by the reactivation of the John Cunningham (JC) virus, which is almost exclusively associated with severe immunosuppression, such as in human immunodeficiency virus (HIV) infection.

Case description

A 77-years old female patient, with no previous diseases, presented to the emergency department with paresthesias of the left upper limb, fever and night sweats in the previous week. She also reported asthenia, anorexia, weakness, decreased visual acuity, productive cough and progressive non-quantified weight loss in the last 3 months. On examination, it was found: massive splenomegaly, left homonymous hemianopsia, left hemispatial neglect, left hemiparesis (strength grade 3) and Babinsky's sign on the left side. Complementary exams showed leucocytosis (19,370 μ l) with lymphocytosis (93%) and dysmorphic lymphoid population in the peripheral blood smear. Immunophenotyping of the peripheral blood revealed a monoclonal B-lymphocytes population and moderate splenomegaly was identified in the abdominal ultrasound. These findings defined the diagnosis of B cells chronic lymphocytic leukemia (CLL), stage 4 (Rai) and C (Binet). To clarify neurological findings, a cranial computed tomography was performed and showed extensive areas of vasogenic edema in the periventricular white matter adjacent to the atrium and posterior portion of the lateral ventricle body, extending to the splenius of the corpus callosum and subcortical white matter. This study was complemented by a cerebral magnetic resonance imaging that revealed intra-axial lesions of the bi-parietal white matter hyperintense in T2 and hypointense in T1, with greater expression in the right side and with extension to the corpus callosum and the midbrain. In the lumbar puncture it was found the JC virus. All blood serologies were negatives, including HIV. A diagnosis of LEMP in the context of CLL was made, and, despite treatment with mirtazapine, the patient died about 2 months after diagnosis.

Discussion

PML in CLL patients is often associated with chemotherapy, being extremely rare in treatment naive CLL patients. There is

no specific treatment defined for PML, although there is usually a stabilization of the disease with the improvement of immunity function, which gives this combination a particularly adverse prognosis and highlights the need for new therapeutics options.

#730 - Case Report

A REVEALING BACK PAIN

Filippo Sartori

ASST-Mantova, Carlo Poma, Mantova, Italy

Introduction

A 79-year-old man came to our Emergency Room for recurrent hyposthenia of the right upper limb and aphasia (2nd episode in a month). In anamnesis: arterial hypertension; ADR to iodinated contrast medium; onset of low back pain in the last month.

Case description

A first brain CT scan was negative, so we decided to undergo the patient to a brain MRI that detected multiple cerebral lesions in the left hemispheric cortex, compatible with repetitive lesions. To identify a possible occult neoplasm, the patient underwent a PET-CT scan, resulted negative. In the following days the patient presented remitting fever, so we performed blood cultures that detected an infection by *Streptococcus gallolyticus*, treated with vancomycin with benefit. No cardiac vegetations were observed in a transesophageal echocardiogram. Two weeks later, a second brain and lumbar spine MRI showed the reduction of the previously described cerebral lesions and the presence of L3-L4 spondylodiscitis. The lumbar puncture was normal.

Discussion

On the basis of these findings we could diagnose a spondylodiscitis with cerebritis outbreaks in a sepsis from *S. Gallolyticus*. The patient was shifted to Amoxicillin/clavulanate and levofloxacin therapy (8 weeks), with complete regression of the symptoms. *Streptococcus Gallolyticus* is known for its association with endocarditis and colorectal carcinoma; rare cases of meningitis are reported.

This case shows an unusual presentation of an infection unusual itself. More, it reminds us never to underestimate our patients' symptoms.

#737 - Case Report

A CASE OF SEVERE MALARIA - A DIAGNOSTIC DILEMMA

Carina Rôlo Silvestre, Juliana Magalhães, André Pinto, José Morgado, Teresa Vilaça, Inês Antunes, Ivone Barracha
Centro Hospitalar do Oeste, Torres Vedras, Portugal

Introduction

Malaria is an important cause of morbidity and mortality worldwide, since it is not endemic to Europe, the reported cases are almost exclusively in travelers returning from malaria-endemic areas.

Our aim is to present a patient with severe malaria that shows difficulty in the interpretation of the results of a rapid immunographic test

Case description

A 41-year-old male from Mozambique, presented to the emergency department with fever, myalgias, severe headache associated with vomiting for 4 days prior to admission. Personal history revealed an episode of malaria in the past.

On admission, his physical examination revealed a fever (38.6°C), tachycardia, but normal breath sounds, normal abdominal examination and there were no petechiae or haemorrhages. Analytically there was no anemia (hemoglobin 14.4 g/dL) with thrombocytopenia (23,000), leukocyte count (7,940 u/L), CRP (10.5 mg/dL), mild hepatic dysfunction (total bilirubin 2.9 mg/dL) and LDH elevation (321 U/L); blood gases showed metabolic acidosis; biochemical analysis of urine with hemoglobinuria; electrocardiogram showed a sinus tachycardia with no other abnormalities. A rapid immunographic test result was positive for *P. Falciparum*, *P. Vivax* and *P. Malariae*. Surprisingly, the examination of a peripheral blood smear showed only *P. falciparum* - infected erythrocytes with a parasitemia index of 6.2%.

Admitted the diagnosis of severe malaria with hepatic and hematologic dysfunction. The patient was treated with intravenous quinine and doxycycline with improvement of his clinical condition and decreased of his parasitemia to 0.1% after 3 days. He was discharged after 7 days.

Discussion

The presence of a triple positive rapid test does not confirm the worthiness of mixed malaria, since the presence of high parasitemia index of *Plasmodium falciparum* can lead to false positives. The diagnosis depends on an experienced microscopist who can differentiate the various types of malaria parasites in thin blood films. A wrong interpretation of the results could lead us to escalate therapy.

#738 - Case Report

WEIL'S DISEASE - A SEVERE FORM OF LEPTOSPIROSIS

Cristina Moreira Marques¹, Ana Francisca Pereira¹, Cristiana Fernandes², José Miguel Ferreira², Ana Ogando², Carlos Oliveira²

¹ Hospital Santa Maria Maior, EPE, Barcelos, Portugal

² Hospital Santa Maria Maior, Barcelos, Portugal

Introduction

Leptospirosis is a zoonosis caused by a spirochete infection - *Leptospira* spp. The most common reservoirs are rodents, especially rats, and their transmission is through contact through the skin or mucous membranes with water or soil contaminated with urine of an infected animal. Most patients have a mild form of this disease, but a minority may evolve with multiorgan dysfunction, with a 5-10% mortality.

Case description

40-year-old male, living in Portugal for the last 3 months (previously immigrated to France), construction worker, with no recent travel history. History of headache and cholecystectomy. No usual medication. He reported alcohol consumption of 120g/day and smoking of 20 UMAS. He went to the ER for productive cough, pleuritic chest pain, myalgias and fever (T 39.5°C) with 48h of evolution. He was given levofloxacin 750mg in the last 24 hours without improvement. The observation showed TA 120/65 mmHg; FC 82 bpm; SpO₂ (aa) 93%, fever (T 38.1°C), icteric skin and sclera, without other alterations to physical examination. Of the complementary study performed, it presented thrombocytopenia (56,000 platelets) and anaemia (Hb 11.4 g/dl), relative neutrophilia (84%), increased VS, negative serologies to HIV, HBV, HCV and CMV, direct and indirect negative Coombs test; hyperbilirubinemia (Direct bilirubin 3.41 mg/dl); hepatic cholestasis; proBNP 2397 pg/ml and C-reactive protein 9.33 mg/dl; urine II with erythrocytes; blood gas analysis with hypoxemia (pO₂ 53 with FiO₂ 21%); abdominal ultrasonography with findings of chronic hepatopathy and CT scan without laterations; ECG with first degree BAV. Due to the progressive aggravation and taking into account the epidemiological context of the patient, a positive *Leptospira* study was performed. Assumed sepsis for Leptospirosis with multiorgan dysfunction. Initiated antibiotic therapy with ceftriaxone and azithromycin with favourable clinical and analytical evolution. At the time of discharge, the patient was asymptomatic, without fever in the 5 days prior, and regularization of the organic dysfunctions.

Discussion

The diagnosis of this entity is often forgotten, and a high clinical suspicion is necessary. The authors of this paper intend to alert to the clinical importance of this disease, which is often fatal. The recognition is especially important in the most severe cases that present with multiorgan dysfunction since the directed antimicrobial therapy can reduce its severity, duration and improve the prognosis of the patient.

#748 - Abstract

SPONDYLODISCITIS: A SERIES OF EIGHT CASES

Filipa Nunes, Marina Vitorino, Whine Pedro, Beatriz Porteiro, Mariana Costa, Alexys Reis Borges, Marinela Major, João Machado HFF, Amadora, Portugal

Background

Spondylodiscitis is the infection of the intervertebral disc and contiguous vertebrae which can be associated with local abscesses. The diagnosis needs high index of suspicion towards at-risk patients presenting back pain, fever and neurological deficits.

Methods

Retrospective observational study of eight patients with spondylodiscitis proven in the image exams in a Service of Internal

Medicine from January 2017 to March 2019. Demographic data, clinical presentation, risk factors, sites of infection, microbiology, imaging, treatment and outcome were described.

Results

The cases analysed represented 0.24% of all patients admitted (n=3389). Patients included seven males and one female, five Caucasians and three Africans, with a mean age of fifty-nine years. All patients had back pain, three had neurological deficits and fever was present in two patients. The symptoms were present for a mean time of one hundred and six days before the diagnosis. Four patients were alcoholic, one was an intravenous (IV) drug user, three had diabetes mellitus, one had bladder cancer and one had a recent surgery. All patients underwent magnetic resonance imaging (MRI) showing localized infection in the lumbar spine in seven patients and in the cervical and lumbar spine in one. All had psoas, paravertebral or epidural abscesses. Percutaneous aspiration identified Mycobacterium tuberculosis in two patients and Brucella spp in one patient. Two patients had blood cultures with methicillin-sensitive Staphylococcus aureus (MSSA) and one had urine culture with Staphylococcus lugdunensis. There was no isolation of gram-negative bacteria or Candida spp. Patients with tuberculosis and brucellosis were treated with standard guided therapy. Patients with MSSA were treated with flucloxacillin during four to six weeks. Empirical treatment with IV vancomycin and meropenem followed by oral levofloxacin was used when there was no isolation. Three patients underwent surgery. One patient died of septic shock in the postoperative care.

Conclusion

In our series we found that spondylodiscitis had a late diagnosis in patients with predisponent comorbidities. Back pain associated with fever and neurological deficits were the most common presenting symptoms. MRI was central to establish the diagnosis. Cultures were confirmed in most patients, in which two had tuberculosis and one had brucellosis. In most cases we verified a favourable evolution requiring prolonged treatment.

#752 - Abstract

WHEN INFLUENZA INFECTION COMPLICATES – ANALYSIS OF HOSPITALISATIONS IN INTERNAL MEDICINE DEPARTMENT

Joana Alves Vaz, Catarina Cabral, Maria Manuela Soares, Isabel Madruga
Hospital Egas Moniz, Lisboa, Portugal

Background

Influenza is a self-limiting infection in most cases. However, when complicated, it can lead to appearance of serious respiratory infections requiring hospitalization and with higher mortality. OBJECTIVE: Characterize patients hospitalized for influenza in the medical department from 1 January to 31 st March 2019.

Methods

Observational and cross-sectional study of patients hospitalized for influenza in the medical department from 1 January to 31 March 2019.

Results

During this period 283 patients were admitted. Thirty-one patients were admitted for influenza with a mean age of 79.7 years and 58,1% of males (n=18); 77,4% were also diagnosed with bacterial superinfection. Microbiological cultures were positive in only 19.4% of patients (H.influenzae in 66.6% of this group) and, on average, these patients fulfilled 6.4 days of antibiotic therapy, being the most used scheme amoxicillin-clavulanic acid plus clarithromycin (36.9%). Co-morbidities conditioned a mean Charlson index of 7.7 (estimated survival at 10 years of zero). About 48,4% of the patients were smokers.

The most isolated strain was H1N1 (90.3%, n=28), followed by non-H1N1 Influenza (9.7%, n=3). Due to lack of information, it was difficult to understand if vaccination was done in 74.2% patients. About 19,0% of the patients were vaccinated and also had manifestations of the disease requiring hospitalization. During this period, the mean hospital stay was 10.7 days and the mortality proportion verified was 9.2%.

Of the total, mortality proportion in influenza patients was superior (12.9%) and bacterial superinfection occurred in 75,0% of the patients in this group. Mean hospital stay in influenza group was 12.5 days and 12.9% of the patients needed non-invasive ventilation, with a superior mean hospital stay (19.2 days). All patients had access to antiviral treatment, except for one patient who, due to renal impairment did not receive antiviral treatment with oseltamivir.

Conclusion

Although influenza generally translates into frequent and indolent infection, it can complicate with organic failure and motivate hospitalisation, especially in patients with lung disease and smokers. Therefore, it is necessary to reinforce the importance of seasonal vaccination and early diagnosis to avoid complications associated with viral infection.

#779 - Abstract

ELECTROLYTE IMBALANCE AND INFLUENZA VIRUS – IS THERE A LINK?

Catarina Cabral, Joana Alves Vaz, Maria Manuela Soares, Isabel Madruga
Hospital de Egas Moniz - Centro Hospitalar de Lisboa Ocidental, Lisboa, Portugal

Background

There has been reports of electrolyte imbalance associated with Influenza A virus infection, primarily hyponatremia. We present an observational and cross-sectional study of patients admitted with the diagnosis of Influenza virus, and associated variables, as a possible etiology for the development of electrolyte imbalance.

Methods

A linear probability model was used to assess the possible impact of an array of pre-selected independent variables on the development of electrolyte imbalance on 31 patients admitted with the diagnosis of Influenza virus from the 1st of January – the 30th of March.

Results

Of the 31 patients admitted, 58.1% were men and 41.9% were women, with a mean age of 79.7 years; 29.0% presented with electrolyte imbalance during the course of the illness, with 66.7% of the patients presenting with imbalance of a single ion, predominantly hyponatremia (33.3%); There was no pattern on the patients presenting with multiple ion imbalance; 90.3% had infection with Influenza A H1N1 and only one (n=1) patient was not medicated with oseltamivir due to renal impairment; 77.4% were diagnosed as well with bacterial pneumonia; Of the other variables used 48.4% were smokers and there was the need for non-invasive ventilation on 12.9% of the patients. After the application of the statistical model, Influenza A serotype H1N1 was associated with a 29,6% increase on the development of electrolyte imbalance (CI 95%, 0.10 to 0.49, p-value=0.0034); On the other hand, oseltamivir intake showed a 70.3% reduction on the development of electrolyte imbalance (CI 95%, -0.89 to -0.51, p value=2.73x10⁻⁸).

Conclusion

Even though there were some limitations to this study, we can conclude that the serotype H1N1 of the Influenza A virus assumed a major importance on the development of electrolyte imbalance, reinforcing the necessity of the holistic approach that should be applied to all of the patients we treat. We also emphasize the need for further studies to test each specific ion imbalance and Influenza virus.

#783 - Case Report

NECROTIZING SOFT TISSUE INFECTION: A CASE REPORT

Dimitrios Tsiolpidis, Christina Kotsiari, Alexandros Damotsev, Konstantinos Pavlou, Konstantinos Kaniotis, Asimina Migdalia, Palmyra Tsiftsi, Theodoros Kostakis, Paris Poursanidis, Bilal Bilal, [Triada Exiara](#)

General Hospital of Komotini, Komotini, Greece

Introduction

Necrotizing soft tissue infection (NSTI) is a rare but potentially fatal infection involving skin, subcutaneous tissue and muscle. Its diagnosis and treatment are challenging

Case description

A 68-year-old woman, presented to the emergency department because of a four day history of abdominal pain, nausea, vomiting and fever. The patient's past medical history was notable diabetes

mellitus type 2 was treated with insulin. She was hypothermic, hypotensive, tachycardic, hyperglycaemic and confused. Her abdomen was distended and a large area over the upper abdominal wall was erythematous, indurated and very tender to palpation. In the central zone there was sloughed off skin with a circle of necrosis and crepitations. Blood tests showed elevated inflammatory and muscle markers, acute kidney injury and compensated metabolic acidosis. Her clinical picture indicated a state of bacterial sepsis and systemic toxemia. The patient was resuscitated with intravenous fluid, cultures were taken and intravenous antimicrobial therapy was started (vancomycin, clindamycin and piperacilline/tazobactam). CT scan revealed large collections of fluid and gas in the upper abdominal wall (rectus abdominis) with spread into the thoracic wall as well as inflammation surrounding the left colon. An exploratory abdominal fasciotomy was performed which revealed irreversible muscle necrosis of the various muscle groups. Even though was on multiorganic support, the patient died a few hours after surgery. Definitive cultural results showed Group A Streptococcus (GAS) isolates.

Discussion

NSTT is a rare and potentially fatal surgical emergency. An early diagnosis and treatment with intravenous antibiotics and aggressive surgical debridement is critical.

#797 - Medical Image

“FOOTPRINTS” OF A KILLER. RUPTURED MYCOTIC ANEURYSM IN A 23YRS OLD PATIENT WITH INFECTIVE ENDOCARDITIS REMINDS US: ONCE YOU THINK IT, TREAT IT!

Dimitrios Sagris¹, Aggelos Stefanos¹, Theofanis Giannis², Aristotelis P. Mitsos³, Konstantinos P. Makaritsis¹, George N. Dalekos^{1,4}

¹ Department of Medicine and Research Laboratory, University Hospital of Larissa, Larissa, Greece

² Department of Neurosurgery, University Hospital of Larissa, University of Thessaly, Larissa, Greece

³ General Army Hospital, Athens, Greece

⁴ Institute of Internal Medicine and Hepatology, Larissa, Greece

Clinical summary

A woman with Systemic Lupus Erythematosus and positive antiphospholipid antibodies admitted due to fever, despite quinolone treatment prescribed by her GP, one month after dental procedures. Janeway lesions, Osler nodes and a new systolic murmur on apex were noticed. She was treated with ceftriaxone, vancomycin and gentamycin, as possible IE. Cardiac echo confirmed IE and *S. aureus* (MSSA) was isolated. On day 1st, hemiplegia and coma developed. Intracerebral hemorrhage, due to a mycotic aneurysm in a distal middle cerebral artery was diagnosed, requiring neurosurgical intervention. She is alive with residual neurologic deficits. In this patient, with probable concomitant Libman-Sacks endocarditis, delayed diagnosis led to catastrophic complications. Regarding IE: once you think it, treat it!

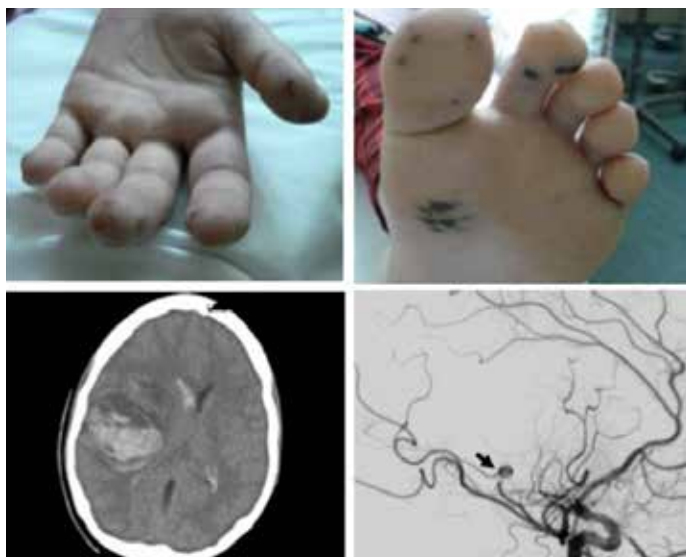

Figure #797. Janeway lesions and Osler nodes (upper panel). Intracerebral haemorrhage and mycotic aneurysm of the right middle cerebral artery (lower panel).

#809 - Case Report

CRYPTOCOCCUS INFECTION REMAINS AN IMPORTANT PRESENTING MANIFESTATION OF HIV DESPITE THE GREAT VICTORIES OF THE EARLY DIAGNOSIS AND HAART

Mariana Certal, Rita Cunha, Adelaide Moutinho, Sofia Perdigão, Sandra Tavares

Centro Hospitalar de Trás-os-Montes e Alto Douro, Chaves, Portugal

Introduction

Cryptococcus infection suspicion begins with clinical symptoms that can be non-specific such as fevers, cough or headaches, and the diagnosis is largely associated to immunocompromised patients. Despite considerable declines in prevalence during the highly active antiretroviral therapy (HAART) era, Cryptococcus remains an important opportunistic infection in HIV patients that cannot be forgotten.

Case description

A 73 years-old male with a long history of heavy smoking and alcohol use, arterial hypertension and risk sexual behaviors, was admitted to the hospital with a 1-month history of adynamia, asthenia, behavior changes, disorientation and prostration. He also complained of photophobia. On examination, he was a thin and ill-appearing man, was hemodynamically stable and subfebrile. Cardiac and pulmonary auscultations were normal. On neurological examination, he was alert but disoriented to place and time, without other alterations. Kernig's test and Brudzinski's sign were negative. Initial laboratory results included a white blood cell count of 5600/uL, hemoglobin 16.3 g/dL, AST 36 U/L, ALT 82 U/L, G-GT 101 U/L and creatinine 1.1 mg/dL. Head computed tomography (CT) scan showed several lacunar infarctions without evidence of acute injury. Chest X-ray revealed a right hilar

nodular opacity which was confirmed by CT as a non-specific consolidation focus. Admission lumbar puncture was negative for TPHA/TPPA/TP, Herpes 1 and 2, Haemophilus influenzae b, Neisseria meningitis, Streptococcus pneumoniae, Varicella-zoster, Prechovirus, and positive for Cryptococcus neoformans, confirming cryptococcal meningitis. Patient was found to be HIV-positive with CD4 counts of 3 cells/uL and viral load of 24800.0 copies/mL, indicative of severe immunosuppression. Viral serologies demonstrated toxoplasmosis IgG and IgM negative. The patient underwent a 6-weeks therapy with amphotericin B and fluconazole, and control lumbar puncture was negative for Cryptococcus. Unfortunately, he developed a nosocomial infection and died, despite medical efforts.

Discussion

Suspicion of cryptococcal neurologic infection can be difficult due to the non-specific presentation, and lumbar puncture is essential to establish the diagnosis. Despite the reduced number of cases among HIV patients since the advent of HAART in the developed world, approximately one million cases of cryptococcosis occur worldwide each year, and several of them with unfavorable outcomes.

#824 - Case Report

TUBERCULOSIS (TB) IN HUMAN IMMUNODEFICIENCY VIRUS (HIV)-PATIENT WITH UNDETECTABLE VIRAL LOAD: IS HIV REALLY BEING CONTROLLED?

Mariana Certal¹, Rita Cunha¹, Adelaide Moutinho¹, Ana Sofia Alves¹, Fernando Magalhães², Sandra Tavares¹

¹ Centro Hospitalar de Trás-os-Montes e Alto Douro, Chaves, Portugal

² Centro Hospitalar de Trás-os-Montes e Alto Douro, Vila Real, Portugal

Introduction

TB is still a major opportunistic infection in HIV-infected patients. Several studies demonstrated that the prevalence of TB among HIV-infected patients remains high, with a strong association with CD4 cells count below 200 cells/mL.

Case description

The authors present the case of a 46-year-old male, ex-injecting drugs user under methadone therapy, with HIV infection known since 1998 but with treatment initiation in 2005 with Tenofovir/Emtricitabine plus Efavirenz, with CD4 cell count 347 cells/mm³ and undetectable HIV viral load for several years, and cured chronic hepatitis C since 2015. He was admitted with a 1-month complaints of anorexia, weakness, asthenia, weight loss, cough and dyspnea. On general examination, he was a thin man, with temperature of 36°C, heart rate 106 bpm, blood pressure 92/61 mmHg, and oxygen saturation of 87% on room air. Cardiac auscultation was normal and pulmonary auscultation revealed a diminished lung sounds at the apical level bilaterally, without

adventitious sounds. Abdomen was normal. Blood examinations showed a hemoglobin level of 16.1 g/dL, a white blood cell count of 8200/uL, and platelet count of 203000/uL. C-reactive protein was elevated (13.9 mg/dL). His renal function tests were within normal range. TGO 60U/L, TGP 15 U/L, GGT 103 U/L, FA 137 U/L and DHL 803 U/L. Arterial blood gas analysis showed pH 7.43, pO₂ 47 mmHg, pCO₂ 35 mmHg, HCO₃⁻ 23.2 mmol/L and lactates 5 mmol/L. Chest X-ray showed extensive upper lobes bilateral opacities with some areas of evident milliar pattern. Chest computed tomography (CT) scan confirmed the presence of multiple centrilobular nodules and extensive ground glass opacity condensations in both lungs, with a predominance in the upper 2/3, associated with cavitation in the upper lobes. Sputum and bronchoalveolar lavage samples were positive for *Mycobacterium tuberculosis*. *Pneumocystis* was negative. Hemodynamic instability and respiratory failure led the patient to be admitted to the intensive care unit with poor prognosis.

Discussion

This clinical case shows that despite normal CD4 cells count and undetectable HIV viral load for several years, it is important to consider TB diagnosis since it may have an unfavorable outcome. This clinical case may be explained by the presence of HIV-associated immune dysregulation that affects other cell lines beyond CD4 T lymphocytes.

#825 - Case Report

THE GREAT MASQUERADE!

Cátia Costa Oliveira¹, Isabel Durães Campos¹, Paulo Medeiros¹, Carla Pires Rodrigues¹, Nuno Antunes¹, António Gaspar¹, Catarina Vieira¹, Carlos Galvão Braga¹, Luís Dias¹, Jorge marques¹, José Pinheiro Torres², Elson Salgueiro²

¹ Hospital de Braga, Braga, Portugal

² Centro Hospitalar de S. João, EPE, Porto, Portugal

Introduction

Bartonella is a cause of “culture-negative” IE with subacute clinical course with nonspecific symptoms and immune-complex glomerulonephritis is a common feature. Involvement of prosthetic valves is associated with aggressive disease marked by rapid progression to heart failure as in this case.

Case description

A 33 years old male with a previous history of aortic valve replacement with a biologic valve 10 years ago at Brazil for infective endocarditis (IE) went to our emergency room for fever with 3 weeks of evolution. Transthoracic echocardiogram (TTE) showed severe depression of the left ventricle function (LVEF of 30 %) and highly calcified and severely dysfunctional aortic valve prosthesis. A presumptive IE diagnosis was made and patient was medicated for 4 days with empiric antibiotherapy until a transesophageal echocardiogram showed no signs of vegetations or abscesses. Hemocultures were also negative. Therefore, IE diagnosis was not

confirmed. Patient started experiencing episodes of hemoptysis and a thoracic CT showed alveolar hemorrhage. Urine analysis had signs of hematuria and proteinuria. A positive ANCA PR3 title was identified suggesting a lung-kidney syndrome associated vasculitis. A kidney biopsy was made. After discussion with Internal Medicine and Nephrology and given the gravity of the clinical presentation, immunosuppression and plasmapheresis were initiated. Though hemoptysis stopped, patient kept degrading with severe heart failure. A TTE showed a LVEF of 5-10% and a LVOT VTI of 5 cm with a dysfunctional prosthesis. In this scenario, nitroprussiate de sodium infusion was started with LVOT VTI improvement. Patient was transferred to a surgical center. New thoracic CT showed not only a left atrial thrombus but also the hypothesis of IE was again suggested. Antibiotherapy was started and he was submitted to surgical aortic valve replacement. Despite macroscopic analyses of the prosthesis did not showed signs of IE, *Bartonella* sp DNA was identified in blood and in the prosthesis. IE was finally confirmed (1 major criteria plus 3 minor criteria). Patient underwent 6 weeks of doxycycline with good response. A TTE showed progressive improvement of systolic function and a normofunctional aortic biologic prosthesis. Previous kidney biopsy confirmed a membranoproliferative glomerulonephritis.

Discussion

This case shows the difficulty on the diagnosis of culture-negative IE and highlights the high immunological events of *Bartonella* IE which can masquerade the real diagnosis

#826 - Abstract

DESCRIPTIVE STUDY OF BRUCELLA IN A TERTIARY HOSPITAL

Helena Molina Llorente¹, Daniel Toresano López¹, Ana María Arnáiz García¹, Francisco Alejandro Caballero Avendaño¹, Marta González Martínez², Paula Hernández Martínez¹, Iria Sanlés González¹, Cristina Baldeón Conde¹, Alicia Cuesta Marín¹, Paula González Bores¹, Zaida Salmón González¹, Laura López Delgado¹, Tamara Maestre Orozco¹, Andrés Fernando Jimenez Alfonso¹, Joel Andrés Mazariegos Cano¹

¹ Hospital Universitario Marqués de Valdecilla, Santander, Spain

² Hospital Sierrallana, Torrelavega, Spain

Background

Brucellosis is one of the most important zoonoses worldwide, especially in endemic areas (Latin America, mediterranean countries). Transmission occurs secondary to direct exposition to certain infected animals (eg. cattle, goats, sheeps and pigs), or to indirect exposition (ingestion of unpasteurized dairy products). Acute infection can cause fever, malaise, headache or arthralgias. Relapsing form (Malta fever) can cause hepatitis, arthritis, uveitis, depression, orchiepididymitis and fever of unknown origin. Chronic infection can affect any organ, or may cause local forms of brucellosis, like spondylitis or uveitis, without systemic symptoms.

Methods

Retrospective descriptive analysis of patients with diagnosis at discharge of brucellosis in the last 10 years, from 2008 to 2018, in our hospital.

Results

Study group: 13 patients (54% males); mean age 58 ± 14 years; average hospital stay: 21 ± 10 days; discharge services: 46% Internal medicine, 15% Rheumatology, 8% Cardiology, 8% Digestive Medicine, 8% Nephrology, 8% Oncology, 8% others. Risk factors: contact with animals (57%), previous tuberculosis (23%), taking immunosuppressants (23%), taking corticosteroids (8%), diabetes mellitus type 2 (8%), sarcoidosis (8%), heart transplant (8%), liver transplant (8%), breast metastatic tumor (8%), colorectal metastatic tumor (8%), HIV (8%).

Clinical symptoms: fever (76%), arthralgia (38%), headache (15%), respiratory symptoms (8%), diarrhea (8%), weightloss (8%), asymptomatic (8%). Clinical presentations: sacroileitis (15%), neurobrucellosis (15%), arthritis (15%), endocarditis (8%), granulomatous liver disease (8%), pneumopathy (8%), serositis (8%). Analytically: mean leukocytes: 9700, mean ESR: 56 ± 36 , mean PCR 6 ± 6 , liver dysfunction (38%), kidney failure (31%), positive blood cultures (8%), positive rose bengal test (100%), positive coombs test (92%), positive brucella serology (100%), Ig M title most frequent 1:20 (38%).

The most frequent treatment: combination doxycycline + rifampicin (38%). Most frequent treatment duration: 6 weeks. No treatment side effects. No development of autoimmune disease after treatment.

Conclusion

Brucellosis in our series is related to contact with cattle, taking immunosuppressants or previous tuberculosis. It usually presents clinically as fever, arthralgias, headache or even asymptomatic. Usually alters liver and kidney function tests. The most used treatment in our area is doxycycline and rifampicin, with 6 weeks as the most frequent duration.

#829 - Abstract

FIGHTING ANTIMICROBIAL RESISTANCE IN AN INTERNAL MEDICINE WARD

Beatriz Chambino, Carolina Capucho Pereira, Lénia Pereira Rodrigues, Manuel Araújo, Susana Ramos Jesus, Ana Leitão, Cândida Fonseca, Luis Campos

Serviço Medicina (UFIII), Hospital São Francisco Xavier, CHLO, Lisboa, Portugal

Background

Hospital acquired infections (HAI) in acute care hospital alone are responsible for more deaths in the Europe Union and European Economic Area than all other infectious diseases under surveillance. Resistance to back-up antibiotics will be 70% higher in 2030 compared to 2005.

We aim to review the prescription rate of back-up antibiotics as first line therapy, verify the amount of time under no antibiotics prescription and the outcomes.

Methods

A retrospective observational study of patients in an internal medicine ward of a University hospital admitted and discharged between October and December 2018. Data were obtained from individual clinical process. We divided patients as group 1 with an infectious disease and group 2 without atb exposure. Back-up atb were considered according to the hospital pharmacy guidelines.

Results

From the 110 patients included: 60% female, middle age 80 years old (yo) and mean Charlson index (CI) 6.67 (0% of 10-year survival). Mean length of in-hospital stay (ALOS) was 11days.

Group 1 (n=57, 51.8%) had an infectious disease: 73.9% and 26.1% were admitted for community and healthcare-associated infections, respectively. From all patients, 12.7% were treated for a presumed HAI. This group had mean age 80yo; mean CI 7; ALOS 13.5days; mean length of atb therapy 9days. Empirical back-up atb were used in 68% of cases. The free time of atb exposure in this group was 27%. Group 2 (n=53, 48.2%) was free of any atb exposure mean age 81yo; mean CI 6.8 and ALOS 8.9days.

Global mortality rate at discharge was 19.1%. In three months follow-up, re-hospitalization rate was 21.3% (57.9% for infectious cause) and mortality rate was 24.7%. Comparing the outcomes of groups 1 and 2: mortality rate at discharge was 22.8% vs 15%; and at three months follow-up the re-hospitalization rate was 25% vs 17.7% and mortality rate was 34% vs 15.6%.

Conclusion

Both groups were epidemiological and demographically similar. In this small study sample, we found a high use of empirically prescribed back-up antibiotics. Although critical epidemiological period of the study, elderly population with many co-morbidities, half of patients was free of any antibiotics exposure. Infection was an independent risk factor for a poor outcome. Despite antimicrobial stewardship programs, according to our results, better management of antibiotics therapy is needed to decrease rates of antimicrobial resistance.

#835 - Case Report

A 78-YEAR-OLD MAN WITH CHRONIC HEPATITIS C AND INTERSTITIAL PNEUMONIA

Carla De Benedittis, Silvia Strada, Pier Paolo Sainaghi, Daniele Sola, Mattia Bellan, Mario Pirisi

Università del Piemonte Orientale, Translational Medicine, Novara, Italy

Introduction

A 78-year-old man with chronic hepatitis C, ischemic cardiomyopathy, atrial fibrillation on amiodarone, and a mechanical aortic valve was admitted to the hospital for worsening dyspnea,

orthopnea and cough in the last week. At physical examination, body temperature was 37°C, BP 125/75 mmHg, HR 135/min, RR 23/min. Crackles were audible at the bases bilaterally. Blood gas analysis demonstrated pH 7.40, PaO₂ 42, PaCO₂ 29, HCO₃⁻ 20; C-reactive protein was 13 mg/dl, white blood cell count 15×10⁹/L. Chest X-ray showed diffuse pulmonary thickening and bilateral opacities.

Case description

A first-line antibiotic regimen for community-acquired pneumonia was started but the patient did not improve, requiring non-invasive ventilation. HIV serology turned negative. A HRCT chest-scan showed significant interstitial lung disease (ILD), with multiple parenchymal opacities and lymphadenopathy. Broncho-alveolar lavage fluid yielded *P. Aeruginosa* and *P. Jirovecii*. Introduction of intravenous ciprofloxacin, trimethoprim/sulfamethoxazole, and corticosteroids was followed by a slow but sustained clinical recovery. Three months after discharge, full-blown polyarthritis and positivity for cyclic citrullinated peptide antibodies (CCP) led us to formulate a diagnosis of rheumatoid arthritis (RA).

Discussion

ILD, though a frequent extra-articular manifestation of RA usually diagnosed late in the course of the disease, is rarely a presenting feature of RA and may be complicated by opportunistic infections. The case underlines the difficulty of the differential diagnosis of ILD in the presence of polymorbidity and polypharmacy.

#841 - Case Report

TROUBLED VACATIONS DUE TO STREPTOCOCCUS PNEUMONIAE

Mariana Figueiras, Rosário Sáez, Tiago Branco, Hugo Calderon, Sofia Amálio, Cristina Granja
Hospital de Faro, Faro, Portugal

Introduction

Acute middle ear and/or mastoid infections are very common in general population. The prognosis has changed during time due to antibiotics, nevertheless complications like meningitis can occur.

Case description

We present a 63-year-old woman on vacation in the Algarve. On the day she traveled to Portugal she reported otalgia and headache with improvement of symptoms with paracetamol. The next morning she was found on the toilet floor not being able to verbalize or carry out orders and with sphincter incontinence. On arrival to the hospital she was hemodynamically stable (BP 149/80 mmHg, HR 70 bpm, SaO₂ 97%), with fever of 38.7°C, agitated, aphasic, with right hemiparesis difficult to evaluate due to agitation. Meningeal signs were negative. Brain CT scan had no changes suggestive of acute cerebral vascular disease but in the MRI areas are defined as hypersignal with respect to the cerebral cortex and inflammatory pansinusopathy and inflammatory

filling of the mastoid. Blood test revealed partial respiratory insufficiency, hyperlactacidemia (PaO₂ 61 mmHg, lactates 4.1 mmol/L), leukocytosis of 27.5 × 10⁹/L with 83% of neutrophilia and CRP of 299 mg/L and lumbar puncture had hypercellularity (33 cells/mm³), proteins of 834 mg/dL, glucose <1 mg/dL, lactic acid in the CSF of 23 mmol/L and Gram-positive diplococci were observed in direct examination. Pansinusopathy/mastoiditis complicated with bacterial meningitis with diplococci is admitted and the patient is admitted to the ICU with 9 points in the Glasgow coma scale (O2V2M5) with periods of tachypnea and apnea. She was kept in the hospital for 10 days with good evolution and following antibiotic therapy with ceftriaxone and ampicillin. Bilateral miringotomy with removal of foreign bodies, cerumen and purulent drainage was performed. *S. pneumoniae* was isolated in the blood cultures. She was discharged without alterations to the neurological examination and oriented to consultation of otolaryngology review.

Discussion

In this case, the initial presentation made the differential diagnosis challenging between vascular disease, epilepsy and infection. Our patient had flown, with a middle ear infection and pressure variations during the flight may have contributed to complicate it. Bacterial meningitis is a medical emergency. Even with optimal therapy, there is a high failure rate, which makes timely diagnosis so important.

#843 - Case Report

EBV ENCEPHALITIS

Isaac Pereira
ULSBA, Beja, Portugal

Introduction

Epstein-Barr virus (EBV) belongs to the human herpesvirus family and is ubiquitously found in the adult human population, and the most common clinical manifestation of EBV is the syndrome of infectious mononucleosis. Although possible, central nervous system involvement by EBV is rare, with very few cases of EBV encephalitis reported. The following is one of such cases.

Case description

A 81 year old male independent in daily living activities, whit a personal history of high-grade dysplasias of the skin and Basalioma (in remission), hypertension, benign prostatic hypertrophy and ferropenic anemia.

Resorted to the ER after a fall of is own height whit resulting amnesia and face trauma. He was observed by surgery and discharged on the next day. The patient was again referred to the ER on the same day since he remained disorientated and whit gait changes. He also had a fever, but without other symptomatology. He didn't have analytical alterations of mention and whit an normal chest radiograph.

Of the workup in the ER, to note:

- Computed tomography of the brain: "There is a good definition of the brain grooves, a decrease in the attenuation coefficients of the deep white substance, translating and pole perfusion with small lacunar images, which is common in the age group. No intra-or extra-axial hepatic densities were observed, without expansive lesions, mass effect or deviations from midline structures."
- Lumbar puncture: Cephalo-Raquidian Fluid (CRF) macroscopically clean CSF, without reticulum. Cytochemistry of the (CRF): innocent (1 nucleated cell, 70 mg / dL glycerin, 40mg / dL of protein, chloride of 120mg / dL). Cryptococcal screening as negative. The rest has in progress.

He was then hospitalized for a better workup of the clinical situation.

The screening of viral antigens / DNA in the CRF identified the Epstein-Barr virus (EBV) (~ 3710 copies gp 220 capsid protein), so supportive therapy was instituted with progressive clinical improvement.

Discussion

In the present case, we have a patient with acute neurological and behavioral changes, associated with a febrile condition, that was diagnosed with EBV encephalitis, a rare but possible and important entity, that should be part of the diagnostic hypotheses when faced with a patient with similar complaints.

#851 - Abstract

DESCRIPTIVE STUDY OF MENINGITIS IN A TERTIARY HOSPITAL

Helena Molina Llorente¹, Daniel Toresano López¹, Ana María Arnáiz García¹, Miriam Vieitez Santiago², Francisco Alejandro Caballero Avendaño¹, Aurelio Juan Bueno Álvarez³, Marta González Martínez⁴, Joel Andrés Mazariegos Cano¹

¹ Hospital Universitario Marqués de Valdecilla, Santander, Spain

² Hospital Comarcal de Laredo, Laredo, Spain

³ Hospital Tres Mares, Reinosa, Spain

⁴ Hospital Sierrallana, Torrelavega, Spain

Background

Meningitis is a serious infection, potentially fatal, so a diagnostic suspicion based on clinical symptoms and physical examination is important, including obtaining the cerebrospinal fluid (CSF) without delaying the establishment of early antibiotic treatment. The aim of this study was to define the clinical characteristics, microbiological findings and antimicrobial treatment of patients with meningitis.

Methods

Retrospective descriptive analysis of patients diagnosed with meningitis from November 2015 to November 2017 in our hospital.

Results

54 patients were included, 65% male and 35% female, with a very

broad age range (0 to 88 years), and an average of 28 ± 28 years. Clinical symptoms: fever (91%), headache (52%), vomiting (39%), cognitive-behavioural alteration (26%), constitutional syndrome (18%), seizures (9%), diarrhea (7%), visual disturbance (4%).

Physical examination: neck stiffness (41%), neurological focality (11%), petechiae (6%), rash (9%).

92% were acute meningitis and 8% chronic.

Etiology: viral (41%), bacterial (31%), tuberculous (6%), without germ (20%), syphilitic (2%).

Risk factors: previous otitis (33%), tumor (22%), immunosuppression (11%), ventriculo-peritoneal shunt (6%), bacteremia (6%), premature delivery/rupture of membranes (6%), liver disease (6%). 18% presented sepsis criteria, 28% required admission to Intensive Care Unit. Two patients (4%) died.

CSF Microbiology: E.coli: 4%; Enterovirus: 33%; H. influenzae: 6%; Herpes simplex-1: 4%; Herpes simplex-2: 2%; Herpes zoster: 2%; K. pneumoniae: 2%; M. tuberculosis: 6%; N. meningitidis B: 4%; S. pneumoniae: 11%; T. pallidum: 2%; S. agalactiae: 2%; S. constellatus: 2%.

9 patients (16%) associated bacteremia (E. coli 4%, H. influenzae 2%, N. meningitidis 4%, S. pneumoniae 4%, S. constellatus 2%).

The most frequent treatment combination in 40% was cefotaxime + vancomycin.

Conclusion

Most are acute meningitis, and viral is the most common (Enterovirus), followed by bacterial (S. pneumoniae). The most frequent clinical presentation is fever, followed by headache and vomiting, and neck stiffness in physical examination. The most frequent combination was cephalosporins (cefotaxime) and vancomycin, adding in some cases ampicillin and in viral infection, acyclovir. The duration of antibiotic treatment is 2 weeks, except complications in which it can be extended for one month or in tuberculous etiology that can be prolonged up to one year. Mortality was low.

#857 - Case Report

SECONDARY TETRAPHASE TO OSTEOMYELITIS BY TUBERCULOSIS INFECTION

Palomar-Muñoz Carmen, Ballesteros- Chaves Isabel, Perez-Vazquez Gloria, Gil- Gascon Jose Manuel, Bianchi- Llave Jose Luis Servicio Andaluz de Salud- Hospital Punta Europa, Algeciras, Spain

Introduction

Description of a low incidence clinical case.

Case description

51-year-old male admitted to the ICU for febrile syndrome, progressive weakness that caused tetraparesis in the lower limbs and impaired respiratory function. CT was performed showing abscesses and cellulitis in cervical prevertebral soft tissues that affected C1-2 and right vertebral artery. Due to

bone involvement secondary to infection (osteomyelitis) fracture of odontoid, anterior dislocation with stenosis of the canal and cranial upheaval of C2 (left side). Upon suspicion of tuberculous infection, treatment with four antituberculostatic drugs was initiated and surgery was performed to drain the abscess. Cultures were taken, and a first cervical fixation is placed through an external craniocervical halo that is maintained until a definitive occipitocervical fixation was made. Micobacterium tuberculosis was isolated in a single culture, rest were negative. The patient presented incomplete medullary lesion of at least C4 sensitive with central-medullary characteristics and right Brown-Sequard, force improved with rehabilitation treatment, presenting 3/5 from L2 to S1 bilaterally and force 2/5 in C5-D1 and 3/5 on C5-D1 left. The patient progressed and recovered at the present time neurological deficits, ability to walk autonomously.

Discussion

Pott's disease or tuberculous spondylodiscitis, is the most frequent musculoskeletal system localization of the tuberculous infection (50%). Adults, affecting vertebrae between T10-L4. It should be suspect in all spondylodiscitis, and tuberculostatic treatment must not be delayed, being able to withdraw it later if in the another germ is isolated.

#858 - Case Report

PIOMIOSITIS BY ESCHERICHIA COLI

Palomar- Muñoz Carmen, Ballesteros- Chaves Isabel, Perez-Vazquez Gloria, Gil- Gascon Jose Manuel, Bianchi- LLave Jose Luis
Servicio Andaluz de Salud- Hospital Punta Europa, Algeciras, Spain

Introduction

Description of pyomyositis case due to Escherichia coli in an immunocompromised patient.

Case description

66-year-old woman with a invasive ductal breast carcinoma with bone metastasis under chemotherapeutic treatment. Admitted with unknown origin sepsis and antibiotic therapy with meropenem was initiated. After two days, the patient reported pain, erythema, pasture, temperature increased and fluctuation on left shoulder. CT was performed, whith clavicular fracture and pyomyositis at trapezius muscle were observed. E. coli was isolated in blood cultures and in shoulder's exudate, ciprofloxacin treatment was initiated. After consulting with Traumatology Unit conservative management was decided, due to the high surgical patient's risk, maintaining antibiotherapy and cleaning the wound. The patient evolved favorably from the infectious point of view, but presented a fluctuation in the level of consciousness, CT scan was performed showing multiple brain metastases. Despite the treatment adjustment, the patient died.

Discussion

Pyomyositis is an infection of the striated muscle. The bacteria

responsible for more than 90% of cases is Staphylococcus aureus, although sporadically cases have been described with Gram-negative bacteria, such as Escherichia coli. This microorganism predominates in patients with immunosuppression. An increase of cases has been described in patients with hematologic tumors, solid tumors' chemotherapeutic treatment and corticosteroid prolonged treatment. In patients with such antecedents, we should not lose sight of the possible etiology due to Gram-negative pathogens and initiate empirical treatment with antibiotic therapy until the result of the cultures.

#859 - Abstract

SEPSIS AT AN INTERNAL MEDICINE DEPARTMENT

Dimitrios Tsiolpidis¹, Christina Kotsiari¹, Palmyra Tsiftis¹, Chasan Ali¹, Savvas Katsaridis², Vasilios Tspizidis¹, Asimina Migdalia¹, Theodoros Kostakis¹, Bilal Bilal¹, Berkay Mollagiousoufoglou¹, Argyrios Tsatsakoulis¹, Triada Exiara¹

¹ General Hospital of Komotini, Komotini, Greece

² Alexander Technological Educational Institution of Thessaloniki
Department of Nutrition and Dietetics, Thessaloniki, Greece

Background

Sepsis is a frequent inflammatory disease with a high mortality and morbidity rate among hospitalized patients. The aim of this study was to determine the prevalence of sepsis and record the clinical and laboratory findings of patients with sepsis in our internal medicine ward.

Methods

From a total 2978 patients admitted to our department during a two-year period, 87 (2.9%) patients with sepsis according to the definitions of the American College of Chest Physicians/Society of Critical Care Medicine Consensus Conference, 51 (58.6%) female and 36 (41.4%) male, with mean age of 74.8 years, were included in this study respectively. Clinical, laboratory and microbiological data, causes of sepsis, co-morbidities of patients and outcome were registered and analyzed.

Results

82 (94.3%) of patients had at least one co-morbidity. The frequencies of co-morbidities were: 46 (56.1%) diabetes mellitus, 33 (40.2%) malignancies, 32 (39%) heart failure, 24 (29.3%) respiratory failure, 19 (23.2%) neurologic disability, 18 (21.5%) chronic kidney disease. Sepsis most frequently came from genitourinary 27 (32.9%), respiratory tract 21 (25.6%), and gastrointestinal tract 14 (17.1%). Blood cultures were positive in 74 (90.2%) patients and the isolated microorganisms were: E. Coli 29 (39.2%), Staphylococcus spp 13 (17.6%), Klebsiella spp 12 (16.2%), Enterobacter spp 10 (13.5%), Pseudomonas spp 7 (9.4%). The mortality rate was 35.4% versus 8.1% of the total number of hospitalized patients.

Conclusion

The sepsis was present in 3% of cases in our department. The patients were older with immunosuppressive underlying disease and the most frequent microorganisms were gram negative bacteria. Timely diagnosis and accurate evaluation of the severity of sepsis is required to ensure a better outcome for the patients.

#861 - Case Report

INVASIVE ASPERGILLOSIS IN A NON-NEUTROPENIC CRITICALLY ILL PATIENT

Joana Azevedo Carvalho¹, Micaela Caixeiro¹, Leonor Boavida¹, Fabiana Pimentel², Afonso Santos¹, João Ribeiro¹, Agostinho Napato³, Nahete Cambelela⁴, Ana Paula Fernandes¹, Paulo Freitas¹

¹ Hospital Prof. Dr. Fernando Fonseca, Amadora, Portugal

² Centro hospital do Oeste, Torres Vedras, Portugal

³ Clínica Sagrada Esperança, Luanda, Angola

⁴ Clínica Girassol, Luanda, Angola

Introduction

Invasive aspergillosis (IA) in an immunocompetent host is an emergent condition. Despite of a rapid diagnosis and treatment, the mortality is high. Corticotherapy, multiple organ dysfunction, malnutrition, chronic pulmonary obstructive disease and H1N1 Influenza A infection are considered important risk factors. Non-specific symptoms and low accuracy of diagnostic tests make the diagnosis extremely challenging.

Case description

We report a case of a 62 years-old man with bipolar disorder and smoking habits. He was admitted with community-acquired pneumonia. X-ray showed bilateral hypotransparency. Laboratory evaluation revealed a bicytopenia (leucopenia of 2900/mm³ and thrombocytopenia of 75000/mm³) and elevated C-reactive protein (5.4 mg/dL). Atypical bacteria and Influenza infections were excluded.

On admission, the patient's condition aggravated and he developed an ARDS with multiorgan failure. Sequential antibiotic escalation and corticotherapy were needed due to clinical deterioration and higher C-reactive protein. On day 14 after hospital admission, *Pseudomonas aeruginosa* was isolated in blood cultures. Since patient's condition had not improved with standard-to-care measures, extra-pulmonary infection was excluded by CT-scan. A few days later, the antibiogram of *Pseudomonas aeruginosa* had changed and a multi-resistant strain was isolated in sputum. Amikacin and ciprofloxacin were started and inflammatory markers decreased. Patient-targeted sedation was reduced and he presented a left sided hemiparesis. CT-scan showed a right frontoparietal abscess with 28x26 mm. Infectious endocarditis was excluded by echocardiogram. The patient was treated with surgical drainage of the brain abscess and *Aspergillus fumigatus* species complex was isolated. To exclude invasive aspergillosis, thoracic CT-scan was repeated and it revealed a cavitated nodule with an air-fluid level in the right superior lobe. Bronchoalveolar

lavage fluid was sterile and serum galactomannan test negative. Twelve weeks of treatment with voriconazole were completed. Neurologic deficits and critical illness myopathy improved with rehabilitation.

Discussion

Corticosteroids in sepsis, multiple organ dysfunction and structural lung disease were considered three important risk factors that predisposed our patient to fungal infection. IA is a challenging diagnosis in critical care and few data are available on the epidemiology and outcome of patients with IA in this setting.

#862 - Case Report

A STRANGE CASE OF TUBERCULOSIS

Joao Frutuoso, Patricia Soares, Margarida Lopes, Jose Vaz ULSBA, Beja, Portugal

Introduction

Tuberculosis, virtually, can affect any organ of the human body, being one of them the brain. Cerebral tuberculomas, are due to hematogenic dissemination through the brain, and occur in approximately in 1% of the cases. Immunocompromised patients, with malnutrition, alcoholism and malignancies, are considered risk patients for haematogenic dissemination

Case description

Patient admitted in the emergency room with progressive right body palsy. CT scan showed a poorly characterized lesion. Further study with MRI showed ringed lesions with unspecific characteristics. Initial blood work shown no immunologic deficiency and elevated C reactive protein.

Through bronchofibroscopy, bronchial secretions were collected that didn't detected Koch bacillus. In order to shed some light in the problem a spinal tap was made, that, detected *M. tuberculosis* DNA through PCR.

The patient started isoniazid, rifampicin, pyrazinamide and ethambutol with little to none benefit. After one month of therapy, he was later transferred to Neurosurgery where the lesions were biopsied showing neutrophils, macrophages and lymphocytes. Abscess cultures were negative. The patient was later transferred back to our ward where continued rehabilitation and RHZE.

Discussion

Although CT and MRI were suggestive of tuberculomas there was a continuous presence of negative cultures and laboratory procedures, with the exception of PCR. It was thought that the abscess cultures would put a final nail in the coffin, but, possibly due to a month of tuberculostatic therapy, were also negative.

#866 - Abstract

DESCRIPTIVE STUDY OF DOMICILIARY MANAGEMENT OF LIVER ABSCESS IN A TERTIARY HOSPITAL

Helena Molina Llorente¹, Daniel Toresano López¹, Ana María Annáiz García¹, Francisco Alejandro Caballero Avendaño¹, Miriam Vieitez Santiago², Aurelio Juan Bueno Álvarez³, Juan José Parra Jordán¹, Stefanie Francesca Pini¹, Carmen Rosa González Fernández¹, Pedro Sanroma Mendizábal¹, Javier Bustamante Odriozola¹, Erick Alfonso Lino Montenegro¹, Marta González Martínez⁴, Joel Andrés Mazariegos Cano¹

¹ Hospital Universitario Marqués de Valdecilla, Santander, Spain

² Hospital Comarcal de Laredo, Laredo, Spain

³ Hospital Tres Mares, Reinosa, Spain

⁴ Hospital Sierrallana, Torrelavega, Spain

Background

Hepatic abscess is an infrequent clinical entity. The aim of this study was to define the clinical characteristics, microbiological findings and antibiotic treatment of patients with hepatic abscesses admitted to Domiciliary Hospitalization Unit (DHU) to control and complete treatment by home intravenous antibiotic therapy (HIAT).

Methods

Retrospective descriptive study of patients admitted to our DHU for follow-up and HIAT of liver abscess from January 2016 to June 2018.

Results

16 patients, 71% male, 29% female, an average age of 68 ± 14 years.

Mean hospital stay 35 ± 9 days. Digestive causes: chronic liver disease (57%), hepatocarcinoma (7%), cholangitis (21%), pancreatitis (21%), cholecystitis (21%), overinfected hepatic hydatid cyst (7%), post-cholecystectomy abscess (7%), post-ERCP (14%).

Symptoms: fever (100%), right hypochondrial pain (57%), vomiting (21%), hepatomegaly (21%).

Multiple abscesses (57%), single abscess (43%).

Etiology: bacterial (86%), polymicrobial abscess (36%), 49% Gram (+), 42% Gram (-), 7% anaerobes. Blood culture positive (57%), culture of abscess positive (29%). Microbiology: *E. coli*: (14%); *C. perfringens*: (7%); *E. faecium*: (14%); *E. faecalis*: (14%); *E. avium*: (7%); *E. cloacae*: (7%); *K. pneumoniae*: (14%); *L. monocytogenes*: (7%); *P. aeruginosa*: (7%); *S. epidermidis*: (7%). Antibiotic: ertapenem (57%), ceftriaxone alone or with metronidazole (21%), others (augmentine, meropenem ...) (21%). The duration of antibiotic treatment was 30 ± 8 days, of which 20 ± 7 days was in DHU. 36% required drainage.

5 patients (35%) presented sepsis and 2 patients were admitted to the Intensive Care Unit. There were no deaths and only 2 patients (14%) re-entered at 4-5 months.

Conclusion

The most common etiology is the digestive.

The bacterial etiology is the most frequent, Gram (+) (*Enterococcus*) and Gram (-) (*E. coli*, *K. pneumoniae*), with bacteremia in half of the cases.

The predominant symptoms are fever and pain at right hypochondrium, and leukocytosis and elevated CRP.

The duration of antibiotic treatment is prolonged, 4-6 weeks (30 ± 8 days) of which at least 3 weeks intravenously. The most used antibiotic was ertapenem with 57%, followed by ceftriaxone with metronidazole in 21%.

The evolution was good, so HIAT of hepatic abscess seems a safe and effective alternative in most patients.

#888 - Case Report

HERPES SIMPLEX VIRUS ENCEPHALITIS ASSOCIATED WITH VASCULITIS AND ELSBERG SYNDROME: A CASE REPORT

Victor Bemfica¹, Renata Fachada^{1,2}, Bianca Feldman¹, Rafaela Mamfrim¹, Thales Rizzi¹, Thaisy Secco¹, Luiza Flores¹, Priscilla Vieira¹

¹ Hospital Municipal Miguel Couto, Rio De Janeiro, Brazil

² Fundação Técnica Souza Marques, Rio de Janeiro, Brazil

Introduction

Herpes Simplex Virus (HSV) encephalitis is often accompanied by urinary retention and fecal incontinence. Elsberg Syndrome (ES) is an infectious syndrome HSV-related consisting of acute bilateral lumbosacral radiculitis, often accompanied by myelitis confined to the lower spinal cord.

We present a 25-year-old man that was admitted at our department with a development of HSV encephalitis associated with secondary vasculitis causing ischemic stroke and Elsberg Syndrome (ES).

Case description

A 25-year-old man, with no previous comorbidities, was admitted in our department reporting a 20 days history, beginning with odynophagia and low grade fever, evolving to a lower level of consciousness, blurred vision, diplopia, prostration, hyporexia, urinary retention, fecal incontinence and discrete right labial commissure deviation. At the physical exam he was in a regular general condition, sialorrheic with multiple ulcerated lesions in the oropharynx associated with hyperemia, prostrated, oriented, with deviation of labial commissure to the right and palpable bladder. Cranial CT performed at his admission revealed an ischemic insult in the right internal capsule territory. With the hypothesis of herpetic encephalomyeloradiculitis, treatment with aciclovir for 21 days concomitantly with corticosteroids in high doses for 5 days was associated with partial remission of the neurological symptoms, with persistently urinary retention and fecal dysfunction, but in lower proportion. He was discharged from hospital with an ambulatory follow up.

Discussion

The cause of urinary retention and fecal incontinence is likely to be associated with invasion of the HSV into the lumbosacral spinal cord as a complication after the encephalitis onset. A formal case definition, that defines the minimum criteria to diagnose this syndrome and identifies exclusionary findings suggesting alternative diagnoses does not exist.

In this case it was not possible to dose the anti-HSV type 1 and type 2 antibodies due to lack of resources at that time. In view of the severity of the clinical picture and compatible clinical evaluation, it was decided to initiate acyclovir as a therapeutic test obtaining an excellent and rapid response, strongly suggesting the herpetic etiological diagnosis of encephalomyelocaradiculitis. This case report emphasize that Elsberg Syndrome may occur in HSV encephalitis, with a significant possibility of recovery with an early treatment.

#890 - Case Report

WEIL'S DISEASE – A CASE REPORT

Isabel Maria Dias Martins Freitas, Tatiana Salazar, Ana Pessoa, Ana Lima Silva, Alice Pinheiro, Ana Luísa Cruz, Augusto Duarte
CHMA- Famalicão, Famalicão, Portugal

Introduction

Leptospirosis is a rare zoonosis caused by *Leptospira interrogans*. Rodents are the main reservoirs of its a etiological agent. This condition is characterized by a broad spectrum of clinical manifestations, from mild influenza-like illness to a severe, potentially fatal, multiorgan involvement, the so called Weil's disease. Our goal is to emphasize the clinical importance of this nosological entity.

Case description

A 54-year-old farmer male, without relevant previous medical history, presented to our hospital with a five-day persistent fever, fatigue and myalgia. Patient also presented with a decreased urine output, hematuria and vomiting from the previous day. He had no alcoholic habits. According to epidemiological context, there was no history of recent travel, although there was reference to contact with rats due to his job. Upon physical examination, he revealed icteric skin and sclera, and a painful abdomen at the upper right quadrant with palpation. Initial laboratory study revealed platelets of 59000/uL, white blood cells of 16870/uL with neutrophilia (91%), creatinine of 1.73 mg/dL, urea of 128 mg/dL, total bilirubin of 12,mg/dL, direct bilirubin of 8,47 mg/dL, alkaline phosphate 99UI/L, aspartate aminotransferase of 122 UI/L, alanine aminotransferase of 104 UI/L and C-reactive protein of 23.6 mg/dL. Chest x-ray, abdominal and pelvic ultrasonography were normal. He was admitted in an Intermediate care unit with a diagnosis of sepsis with multiorgan failure. Given the strong clinical and epidemiological suspicion of Leptospirosis, ceftriaxone was empirically initiated and new enzyme-immune assay and serum and urinary protein chain reaction (PCR) for

leptospirose were performed. During the first two days, the patient's hyperbilirubinemia, leukocytosis and acute renal failure had worsened. As such, renal replacement therapy was implemented and patient was transferred to an intensive unit care (ICU). Serologic tests for hepatitis A, B, C, Epstein-Barr virus human immunodeficiency virus and antibodies for rickettsia were negative. While in IUC IgM antibody and PCR for leptospire were positive, which confirmed the diagnoses of Weil's disease. Patient clinical and analytical status started to improve after 6 days, with posterior complete resolution.

Discussion

Leptospirosis should be considered early in the diagnosis of any patient with acute, non-specific febrile illness with multiorgan system involvement, especially in cases where an history of contact with rodents is present.

#903 - Case Report

VARICELLA-ZOSTER WITHOUT ERUPTION A RARE PRESENTATION

Ana Isabel Oliveira, Patricia Ramos, Madalena Paulino, Ana Nunes, Ana Pidal, Marta Quaresma, Sofia Cruz, José Barata
Hospital de Vila Franca de Xira, Vila Franca De Xira, Portugal

Introduction

Herpes zoster virus infection is more common in women and in old age. Cases of allodynia, without a vesicular rash in the affected dermatomus, or "zoster sine herpete" have been described. Complications include post-herpetic neuralgia, acute neuritis, which may precede vesicular eruption, and aseptic meningitis.

Case description

A 76-year-old woman, with history of chickenpox, obesity, hypertension, type II diabetes mellitus, dyslipidemia, acute myocardial infarction and vertigo syndrome, resorted to emergency department (ED) due to fever 38°C, positional vertigo with gait imbalance, odinophagia, hyperesthesia of the left hemiface, fluid dysphagia, deviation of the lip commissure and decreased visual acuity on the left.

She reported odinophagia in the previous 2 weeks, diagnosed with acute bacterial tonsillitis and medicated with amoxicillin. After 9 days she started mild dysphagia and dysphonia.

Observation on ED: mild dysphonia; left peripheral facial paresis with Bell's sign; allodynia on palpation of the left hemicranium, hemiface and upper lateral cervical region; and mild dysmetria of the left limbs.

Cranioencephalic, neck and soft tissues CT and analysis unchanged. Evaluated by Otorhinolaryngology that assumed left peripheral facial paralysis grade III/VI and hypomobility of the left hemilarynx with edema/hyperemia. Neurology described cranial polyneuropathy of the V, VII, IX and X cranial nerves on the left. Due to the type and area of allodynia, Varicella Zoster virus (VZV) infection was suspected. She was hospitalized for etiological study,

from which it stands out: IgM negative and IgG positive Anti-VZV antibodies (>4000); Cranioencephalic MRI with contrast: reinforcement of linear signal in the fundus of the left internal auditory canal, in relation to VII pair neuritis. Lumbar puncture: clear CSF, pleocytosis (73 cells) - 97% mononuclear and elevated proteins (72.30 g/ml), negative bacteriological examination; IgG positive anti-VVZ Acs.

It was assumed Herpes Zoster's neuritis of the VII pair.

Discussion

A detailed clinical history is crucial for the suspicion and diagnostic gait adopted.

The case describes a facial paresis by Herpes zoster, associated with a rare complication - aseptic meningitis, without cutaneous signals.

IgM and IgG titers are influenced by the time of evolution and previous virus infection, being lower than in primoinfection.

The patient evolved with complete resolution of dysphagia, dysphonia and facial paresis, without introduction of antiviral drugs.

#916 - Abstract

CORRELATION BETWEEN CAPILLARY C-REACTIVE PROTEIN (CRP) AND VENOUS CRP IN LOWER RESPIRATORY TRACT INFECTIONS

Ester Paula Fernández Fernández¹, Ramón Boixeda Viu¹, Jordi Almirall¹, Pere Toran², Josep Roca²

¹ Hospital, Mataro, Spain

² ICS Metropolitana Nord, Mataro, Spain

Background

Lower Respiratory Tract Infections (LRTI) are one of the most common consults in Primary Care. Although most of them are caused by virus, in practice it is really difficult to make a correct etiological differentiation. Because of that, in clinical practice there is an antibiotic overprescription.

Acute-phase protein (CRP) concentration in venous blood is useful in diagnosis and monitoring response to treatment. Previous literature, has demonstrated that levels under 20 mg/l rule out pneumonia with a negative predicted value of 97.4% and levels upper 100 mg/l are highly suggestive of pneumonia.

There are point of care tests (POCT) to determine CRP concentration in capillary blood but we don't have found correlation studies between levels of CRP in venous blood and in capillary blood in clinical practice.

The main objective of our study was to check the correlation between CRP level in capillary blood and in venous blood in patients with low respiratory infection.

Methods

We designed an observational, prospective, multicentric population based study. We enrolled patients over than 15 years-old with symptoms of LRTI.

QuikRead®101 instrument was used to determine CRP level in capillary blood. This test measure concentrations ranges from 8 to 160mg/l. Aleatory, with 1:3 rate, venous CRP concentration was determined by standard laboratory assay.

Results

We enrolled 515 patients of whom CRP concentration was determined by both techniques in 159. 76.1% were men, middle aged 60.91 years old (DE 17.16).

Kappa Index between levels of CRP in capillary blood and venous blood was 0.62 p <0.001.

In the subgroup of capilar-CRP concentration between 8-160mg/l we applied quantitative test that also demonstrated a good correlation with a result of 0.757 [0.637 - 0.842] p<0.001.

Conclusion

CRP concentration in capillary blood is well correlationated with CRP in venous blood in patients with LRTI.

Further studies need to be made to determine usefulness of measurement of capilar-CRP to manage LRTI in clinical practice.

#919 - Case Report

RECURRENT PULMONARY TUBERCULOSIS IN A PATIENT WITH COLORECTAL ADENOCARCINOMA: NOT EVERYTHING IS AS IT SEEMS

José Mário Bastos, Marta Barbedo, Luís Andrade, Vitor Paixão Dias

Centro Hospitalar Vila Nova de Gaia/Espinho, Vila Nova De Gaia, Portugal

Introduction

Tuberculosis (TB) is a common infectious cause of mortality worldwide (particularly in developing countries) that is caused by Mycobacterium tuberculosis and that typically affects the lungs, even though it may virtually spread to any organ.

Although TB incidence has been significantly decreasing in developed countries, Portugal was, by 2015, the Western Europe country with the highest incidence rate of TB.

Case description

We describe a case of a 67 years old woman admitted to the emergency department for a dry cough and dyspnea with 4 hours of evolution. The patient had no other symptoms. At admission the patient was eupneic and had a fever of 38°C. Pulmonary auscultation evidenced crackles in the upper right hemithorax. Rest of physical examination was unremarkable.

Patient had relevant antecedents of colorectal adenocarcinoma (diagnosed for about a month, and still in staging) and active pulmonary tuberculosis diagnosed 3 years ago, medicated and treated. Patient had also been recently hospitalized for E. coli secondary peritonitis due to iatrogenic small intestine perforation. Blood work showed leukocytosis and neutrophilia. A chest X-ray was performed and demonstrated a nodular opacity at the apex of

the right upper lobe. Blood cultures were positive for E.Coli. The patient was diagnosed with bacteremia with a probable abdominal starting point and suspected pulmonary dissemination, and was admitted to the internal medicine department in order to receive intravenous antibiotherapy.

During the hospitalization a chest CT scan was performed showing a 21 mm nodular image in the right upper lobe. Suspecting of infected pulmonary metastasis, a biopsy was performed and revealed a caseous necrotic lesion, with no signs of malignancy. The sample was positive for M. tuberculosis at PCR technique. Bronchoalveolar lavage was performed in order to test for resistances.

Discussion

This case underlines the importance of always thinking of pulmonary tuberculosis as a differential diagnosis for a pulmonary nodule (despite the decreasing incidence in developed countries) and of taking into account the existence of cases of reinfection and/or multidrug resistance tuberculosis. Our patient was diagnosed with TB, despite having a previous treated event and other differential diagnoses could be more likely at first sight (such as pulmonary metastasis, for example). High clinical suspicion and critical thinking are essential features that make internists the diagnostic physicians per se.

#936 - Medical Image

BRAIN TOXOPLASMOSIS

Daniela Neto, Salomé Marques, Juliana Silva, Cristina Silva, Helena Sarmento, Jorge Cotter

Hospital Senhora da Oliveira, Guimarães, Portugal

Clinical summary

44-year-old male, with known HIV and HCV infection, non-compliant and heroin user. Presented to the ER with dysarthria, gait imbalance, left hyposthesia and hemiparesis. Brain CT revealed bilateral subcortical edematous areas, mainly parietal, in the right temporal occipital region, and hypodense areas in the right thalamus. Of the study carried out: CD4+ 56/uL; toxoplasma was detected in the liquor; Pneumocystis jirovecii was identified in the sputum; brain MRI showed multiple corticossubcortical intra-axial expansive lesions with vasogenic oedema. Treatment with cotrimoxazole was initiated and antiretroviral therapy was resumed. At the time of discharge the patient was clinically improved and maintained follow-up in the Internal Medicine-Infectious Diseases consultation.

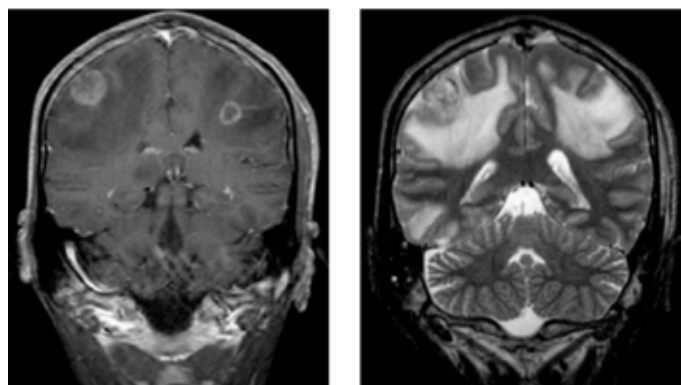


Figure #936. Brain MRI.

#947 - Case Report

“DOCTOR, I HAVE BEEN HAVING NIGHTMARES”

Elena Del Carmen Martínez Cánovas¹, José Manuel Rodríguez García¹, María Consuelo Alcalde Rumayor¹, Ana Martín Cascón¹, Vicente David De La Rosa Valero¹, Ignacio Iniesta-Pino Alcázar¹, Lia Ferraro¹, María Carmen Hernández Murciano¹, Carlos Báguena Pérez-Crespo¹, Gabriel Puche Palao¹, Sergio Antonio Pastor Marín¹, Caridad Beatriz Martínez Cánovas¹, Rosalía Vázquez Vicente², Indra Martínez Hernández², Carlota Royo-Villanova Reparaz¹, Victoria Callejo Hurtado¹, Ángela Santo Manresa¹, María Carmen Vera Sánchez-Rojas¹, Emma Muñoz Pérez¹, María José Martínez Cánovas¹

¹ Hospital General Universitario Reina Sofía, Murcia, Spain

² Hospital Universitario Virgen de la Arrixaca, Murcia, Spain

Introduction

Nocardiosis is an uncommon infection caused by aerobic Gram-positive bacteria of the genus Nocardia. It is considered an opportunistic infection, as it primarily affects people with certain predisposing conditions.

Case description

We present the case of a 68 year-old man admitted in our hospital, describing an increase of his daily dyspnea, purulent sputum and cough. He used to be a smoker (more than 2 packets per day for 30 years) and had a history of severe chronic obstructive pulmonary disease (COPD) frequently exacerbated. His base treatment was triple inhaler therapy (LAMA, LABA and an inhaled glucocorticoid). In the last 3 months, he had been under high-dose of systemic glucocorticoids and different antibiotic therapies to treat frequent exacerbations.

In the previous month, he had been presenting respiratory symptoms described above, apart from weight loss, low-grade fever and night sweats. His wife also reported that he suffered from restiveness sleeping with screamings and nightmares. Physical examination did not reveal any neurological focus. During his stay in hospital, the patient did not report substantial improvement, in spite of receiving antibiotic therapy with Meropenem. A Computed tomography was performed to exclude

complicating processes, showing multiple cavitated nodules. On the fifth day of hospitalization, *Nocardia cyriacigeorgica* was found on sputum culture. Given this fact associated to the behavioral disturbance, brain magnetic resonance was requested, confirming two brain cystic lesions, with contrast-enhancing fine walls, compatible with parenchymal abscesses. Long-term antibiotic therapy with trimethoprim-sulphamethoxazole was initiated. Given the size of the abscesses, he did not need to undergo evacuation surgery.

Discussion

Nocardiosis has the particular ability to disseminate to any organ, considering a special tropism to the central nervous system. The risk of nocardial infection is increased in immunocompromised patients, particularly those with defects in cell-mediated immunity (solid organ or hematopoietic cell transplantation, glucocorticoid therapy as our patient had received, HIV infection, malignancy and diabetes mellitus). At this point, we wish to emphasize the importance of suspecting Nocardial infection in immunocompromised patients and, once the diagnosis is done, considering brain imaging if there is any symptoms or signs indicative of neurological dissemination.

#956 - Case Report

THE IMPORTANCE OF A GOOD ANAMNESIS

Sergio De Santos Belinchón, Lucía Ordieres Ortega, Sandra Piqueras Ruiz, Juan Carlos Cano Ballesteros, Eduardo Fernández Carracedo, Marta Bacete Cebrián, Andrés Enríquez Gómez, Laura Clara Abarca

Hospital General Universitario Gregorio Marañón, Madrid, Spain

Introduction

Central nervous system infections due to *Pseudomonas aeruginosa* are extremely uncommon. They are usually hospital onset and typically related to neurosurgery procedures. Symptoms are typically non-specific, including fever, confusion or seizures. In some studies mortality rates reach 80%.

Case description

We present a 66-year-old woman who arrived at the Emergency Department with a chief complaint of generalized myalgia, muscle spasticity and urinary symptoms.

The patient presented a personal history of multiple progressive sclerosis of 24 years of evolution (Expanded Disability Status Scale 8). The patient lived in a nursing home, being partially dependent for daily activities without evidence of cognitive deterioration. She was under treatment with natalizumab and oral baclofen.

The patient was hospitalized with a diagnosis of urinary infection and ertapenem was initiated. However, her level of consciousness progressively decreased, and she presented generalized seizures. Her family then referred an intrathecal baclofen injection for the spasticity one week before her arrival to the hospital. Our diagnosis possibilities were expanded from progressive multifocal

encephalopathy to chemical baclofen meningitis, considering central nervous system infection as our first possibility. Ceftriaxone, vancomycin, ampicillin and acyclovir was started. Spinal fluid was cultured, with *Pseudomonas aeruginosa* isolation. The patient underwent treatment with intravenous ceftazidime for 28 days, with excellent results and returned to her previous clinical conditions without neurological sequelae. Consecutive microbiological cultures were negative.

Discussion

Pseudomonas meningitis is an uncommon infection. It is therefore difficult to suspect and becomes a problem when empirical therapy does not include this pathogen in its spectrum.

Pseudomonas aeruginosa has a high resistance profile and treatment options are limited to intravenous drugs such as ceftazidime, carbapenems, ciprofloxacin and aminoglycosides, combined with intretecal agents. Duration of therapy is recommended to extend at least 14 to 28 days.

It is important to determine the risk factors for a clinical suspected diagnosis to initiate immediate treatment and thus reduce the incidence of complications.

#973 - Case Report

AFTER ALL, IT WAS NOT JUST A PNEUMONIA...

Daniela Marto, Hélder Pinheiro, Teresa Martins, Maria José Manata, Fernando Maltez

Centro Hospitalar Universitário de Lisboa Central, Lisbon, Portugal

Introduction

Portugal has one of the highest burden of tuberculosis (TB) of the European Union (>20 cases/100,000 individuals), despite a consistent decrease in the last decades, and the disappearance of high incidence regions (>50 cases/100,000 individuals). But the district areas of Oporto, Lisbon and Setubal still have an intermediate incidence of TB (20-50 cases/100,000 individuals). It is known that TB is more frequent in AIDS/HIV infected patients, and in low-income individuals, especially in industrialized countries, and that could partially explain the higher incidence of TB in those highly populated metropolitan areas.

Case description

A 26-year-old immunocompetent female complained for 4 months with dyspnea, cough, right thoracalgia, asthenia, anorexia, fever, night sweating and weight loss (~10%), and went several times to healthcare services, including emergency departments. Radiologically she had a hypotransparency of lower third of right lung, that was interpreted as recurrent pneumonia, and she was prescribed with several antibiotics (amoxicillin/clavulanate, azithromycin, clarithromycin, levofloxacin and doxycycline).

She was sent to an outpatient Internal Medicine consultation, and after careful history taking and clinical examination, she was admitted to inpatient care facilities, she underwent

bronchofibroscope, acid-alcohol-fast bacilli were positive in bronchoalveolar lavage and sputum samples, and thus the diagnosis of baciliferous pulmonary tuberculosis was assumed.

Hence, she was transferred to respiratory isolation rooms of Infectious Diseases department of our hospital, and she was started on a standard 4-drug regimen (isoniazid, rifampicin, pyrazinamide and ethambutol). There was no drug-resistance mutations for isoniazid or rifampicin by molecular testing, and later it was isolated *Mycobacterium tuberculosis* complex in sputum samples, fully susceptible to first line anti-TB drugs. The thorax computed tomography showed alveolar consolidation in right inferior lobe, with air bronchogram, areas of cavitation, and moderate pleural effusion.

Discussion

Although the patient was not immunocompromised, and the radiological findings were not classical, the presence of recurrent pneumonia should raise suspicion, especially in a country like Portugal, with unneglectable burden of TB. In this case, careful history taking was the key for the diagnosis, and in an era of impressive medical technological advances, it should not be disregarded.

#976 - Abstract

EPIDEMIOLOGY, RISK FACTORS AND CLINICAL COURSE OF CARBAPENEM RESISTANT ENTEROBACTERIACEAE INFECTIONS IN A GENERAL HOSPITAL BETWEEN 2015 AND 2018

Pedro Manata¹, Raquel Almeida¹, Carla Ferreira², Ana Grais², Maria João Pinto¹, Inês Monteiro Ferreira¹, João Matos Cost¹

¹ Department of Internal Medicine, Hospital Distrital Santarém, Santarém, Portugal

² Infection Control Committee, Hospital Distrital Santarém, Santarém, Portugal

Background

Carbapenem-resistant Enterobacteriaceae (CRE) infections are a serious public health issue, specially in fragile, immunocompromised patients with prolonged hospitalizations. The spread of Extended Spectrum B-lactamase (ESBL) and consequent exposure to carbapenems were crucial for the rise of CRE infections. Given the severity of these cases, treatment should be prompt, aggressive and efficient. Colistin is one of the last remainder options for treatment of *Klebsiella pneumoniae* carbapenemase (KPC) - producing bacteria infections, however its increased use has led to the emergence of resistance.

Methods

Prospective study from 2015 to 2018. All patients with CRE infection or colonization were included. Clinical data was collected from medical records and the following parameters were analysed: demographic, comorbidities, invasive procedures,

concomitant infections, anatomical location of the isolates, resistance to antibiotics and previous exposure to antibiotics or antifungals.

Results

A total of 52 patients were included, 41 with CRE infection and 11 with CRE colonizations. There was an increasing number of cases over the years (76.9% in 2018). The most common strain was *Klebsiella pneumoniae* (83%). Only 6 cases of KPC were identified, with no information on the type of carbapenemase in the remaining cases. Specimens were detected in urine (30.8%), respiratory tract (25%), rectal exudate (23.1%) in screening context, blood (17.3%), skin and catheter tip (1.9%). In patients with CRE infection, 32 were submitted to targeted therapy and colistin was the most used antibiotic (44%). There was no gender predominance (M:F=51.9%), 88.5% of the patients were over 60 years old and 30.8% were admitted from nursing homes. Diabetes and chronic kidney disease were the most frequent comorbidities. The mean length of stay was 39.7 days (SD=33.6). Mortality rate was 44.2%, higher in patients coming from nursing homes (56 % vs 33 %).

Conclusion

Despite treatment with colistin, the mortality rate remained high, which, as well as the observed risk factors, were consistent with the literature. Previous antibiotic exposure should be taken into account in prolonged hospital admissions.

#977 - Medical Image

EXTENSIVE LUNG DESTRUCTION CAUSED BY TUBERCULOSIS

Mariana Costa, Marina Vitorino, Beatriz Porteiro, Whine Pedro, Filipa Nunes, Joao Machado, Marinela Major
Hospital Professor Doutor Fernando da Fonseca, Lisbon, Portugal

Clinical summary

A 28 year-old man was admitted to our hospital due to an episode of hemoptysis in small amount. He referred having productive cough with mucous sputum, night sweats and weight loss, in the past 3 months. 2 years before, he had contact with a person that was diagnosed with pulmonary tuberculosis but didn't made any screening at the time. He was HIV negative and had no past medical history. The CT scan revealed a cavity extending from the apical segment of the left superior lobe, measuring 10.5 cm in anterior posterior axis. The lesion communicated with varicose bronchiectasis. The BAAR in sputum was negative. A bronchofibroscope was made, and in the secretions collected the PCR for *Mycobacterium tuberculosis* complex was positive. Therapy was started with a favorable evolution.

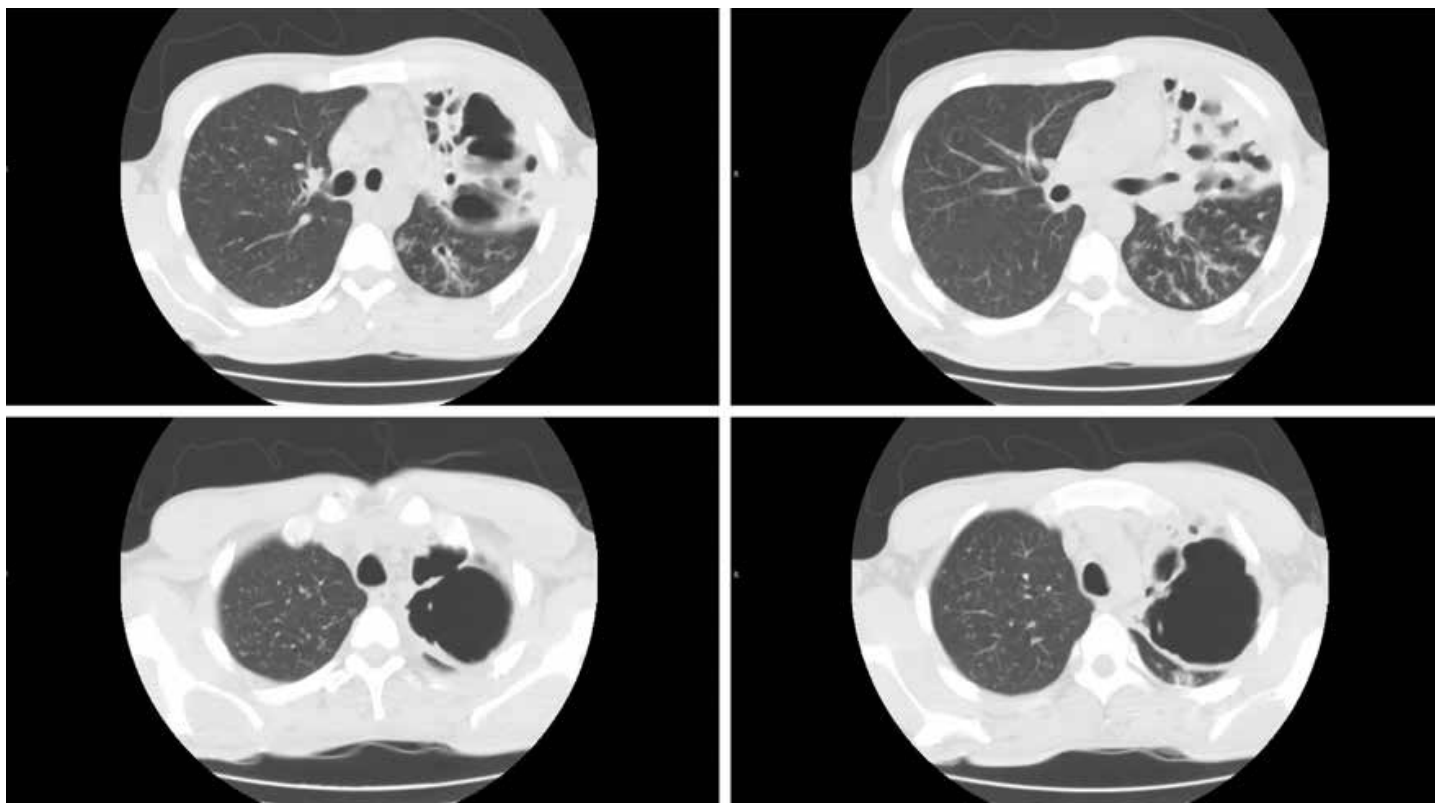


Figure #977. Extensive cavitation in the left lobe.

#1005 - Case Report

ICTEROHEMORRHAGIC LEPTOSPIROSIS

Maria Beatriz Santos, Magda Garça, Pedro Cota, Joana Carreiro, Paulo Ávila

Hospital of the Holy Spirit of Terceira Island, Angra Do Heroísmo, Portugal

Introduction

Leptospirosis is a widespread and prevalent zoonotic disease caused by pathogenic spirochetes of the genus *Leptospira*. Its global incidence is unknown because it is an underreported disease. Human infection usually results from exposure to environmental sources and the natural hosts includes a variety of wild and domestic mammals, especially rodents.

Case description

43 years old male patient, construction field worker and animal breeder. Personal history of chronic alcoholism and severe smoking habits. Admitted with jaundice, asthenia, polydipsia and oliguria with 7 days of evolution. Objectively identified tachycardia, hypotension and hyperglycemia. The blood tests presented leukocytosis (16.710/ μ L), thrombocytopenia (35.000/ μ L), kidney dysfunction (urea 240 mg/dL, creatinine 5.59 mg/dL), hyponatremia (120 mmol/L), elevated hepatic transaminases (TGO 71 U/L and TGP 184 U/L), LDH 1354 U/L, direct hyperbilirubinemia (serum bilirubin 23 mg/dL), total creatine kinase 2664 U/L and c-reactive protein 154.7 mg/l. The blood gas test indicated metabolic acidosis. It was presumed leptospirosis with organ failure, the patient was admitted at the ICU and

started antibiotic treatment with IV penicillin. After 4 days, there was clinical improvement and the patient was transferred to the Internal Medicine Ward. Afterwards, Leptospirosis was confirmed by polymerase chain reaction (PCR).

Discussion

Weil disease or Icterohemorrhagic Leptospirosis is a rare severe form of the bacterial infection (*Leptospira interrogans icterohaemorrhagiae*) and it is characterized by the presence of jaundice, kidney and liver failure. In some cases, there is also persistent fever, hemoptysis, hematochezia, hematuria, petechiae, enlarged lymph nodes and respiratory distress syndrome. A high index of suspicion is required to make the diagnosis based on epidemiologic exposure and clinical manifestations, since clinical and laboratory findings are nonspecific. The diagnostic tools include microscopic agglutination test, blood culture, serological tests immunofluorescence assay and molecular techniques such as real time PCR.

Given the clinical presentation and the personal history of chronic alcoholism and smoking habits, the authors considered hepatic neoplasia as a possible diagnosis, which was excluded after the workup. On this case report, the epidemiologic context was decisive to initiate the antibiotic therapy before the confirmation.

#1035 - Abstract

BACTEREMIA AND QSOFA ARE ASSOCIATED WITH EXCESS LONG-TERM MORTALITY IN OCTOGENARIANS AND NONAGENARIANS: A 1 YEAR COHORT STUDY

Sergio Palacios-Fernandez¹, Ruben Hernandez-Quiles², Adela Fernandez-Gil², Esperanza Merino-Lucas², Vicente Boix³, Beatriz Valero³, Rosario Sanchez-Martinez², José M. Ramos-Rincón²

¹ Servicio de Medicina Interna, Hospital Universitario de San Juan y Facultad de Medicina, Universidad Miguel Hernández de Elche, San Juan De Alicante, Spain

² Servicio de Medicina Interna, Hospital General Universitario de Alicante y Facultad de Medicina, Universidad Miguel Hernández de Elche, Alicante, Spain

³ Unidad de Enfermedades Infecciosas, Hospital Universitario de Alicante y Facultad de medicina, Universidad Miguel Hernández de Elche, Alicante, Spain

Background

The proportion of very elderly people in the population is increasing, and infectious diseases in this patient group may present with specific characteristics. Bacteremia is an important cause of mortality. Whereas the association between bacteremia and a high 1-year mortality is no well-established in very elderly patients

Methods

Objective is to assess long-term mortality (at 1 year) of bacteremia in the very elderly patients (octogenarians and nonagenarians).

A retrospective cohort study of bacteremia patients ≥ 80 years and non-bacteremia controls with suspecting of sepsis, matched on sex, year of birth and calendar time. Setting: University General Hospital at Alicante (Spain). We calculated absolute mortality and adjusted hazard ratio (aHR) in 1 year follow up period.

Results

The mortality and the incidence rate of deaths at 1 year for bacteremia patients ($n=336$) and non-bacteremia patients (controls) ($n=336$) was 45% and 2.06 deaths per 1000 person-years versus 34% and 1.3 deaths per 1000 person-years. The mortality at 12 months was also higher in patients with a quick Sepsis Related Organ Failure Assessment (qSOFA) ≥ 2 (68.1% vs 34.2%) and in nonagenarians than octogenarians (51.3% vs 36.6%), and in patients with hypernatremia (56.7% vs 38.4%).

In the multivariate analysis aHR for bacteremia patients was 1.31 (95% CI, 1.03-1.67), for qSOFA ≥ 2 was 2.71 (95% CI, 2.05-3.57), and for being nonagenarians was 1.53 (95% CI, 1.17-1.99)

Conclusion

Bacteremia is associated with a poor prognosis and excess a long-term mortality compared with non-bacteremia patients. Moreover, other factors related with excess of mortality was qSOFA ≥ 2 and ≥ 90 year-old.

#1038 - Abstract

INFLUENZA A – A CALM AFTER THE STORM?

Ana Paula Antunes¹, Tânia Strecht¹, Madalena Sousa Silva¹, Carolina Sequeira¹, Ana Gorgulho¹, Inês Vicente¹, Alexandre Nascimento Fernandes¹, Joana Selada², António Figueiredo³, Catarina Vizinho Oliveira¹

¹ Hospital de Cascais, Lisboa, Portugal

² Laboratório Hospital de Cascais (Synlab), Lisboa, Portugal

³ Grupo de Prevenção Local - Programa de Prevenção e Controlo de Infecções e de Resistência aos Antimicrobianos (GCL-PPCIRA) - Hospital de Cascais, Lisboa, Portugal

Background

After the 2009 H1N1 virus pandemic, preoccupation with influenza A flu has diminished over time. However, it is still an important cause of major complications and even death.

Methods

Retrospective analysis based on procedural data of the population with a positive influenza result since October 2018 to March 2019 at Cascais Hospital. Excel program was used.

Results

There was a total of 164 cases positive for influenza A [94 (84%) subtype H3 and 18 (16%) subtype H1]. Most cases between January and February (71 and 81 cases respectively, 43.3% and 49.4%). Eighty-nine were men (54.3%) and 75 women (45.7%), average of 69 years. Of the 116 cases with flu-like symptoms, the most frequent were cough (87 cases) and fever (72 cases). Antigen screening was positive in 77 cases (50%); when negative, viral RNA was requested [detectable in 94.9% (112)].

A hundred and eight patients were older than 65 years (65.9%) and of these 9 (7.3%) were vaccinated.

Of the total who were vaccinated, 7 had lung disease (12.3%); 7 were diabetic (20.6%); 2 with renal insufficiency (8.3%); 1 immunosuppressed (7.1%).

Eleven patients with neoplasia were not vaccinated, as well as 5 HIV-infected, 3 health professionals and 4 pregnant women.

A hundred and seventeen patients required hospitalization (71.3%), with a Charlson Comorbidity Index (CCI) of 5 and an average of 77 years. Nosocomial infection occurred in 12 cases (10.3%); 67 had pneumonia (40.9%) and 116 had concomitant bacterial infection (70.7%). Ten patients needed Intensive Care Unit (ICU, 8.5%). There was a mortality rate of 7.3% (12 deaths - mean CCI of 7 and average of 81 years, all unvaccinated; 10 with pneumonia and 9 with bacterial co-infection).

Conclusion

There are still no definitive national incidence results that allow the comparison. The vaccination status was verified in procedural data, so it isn't possible to calculate the vaccination rate and its efficacy.

The sensitivity of rapid antigen screening is similar to that reported by Centers for Disease Control and Prevention (40-70%).

Regarding the severity of the disease, pneumonia and bacterial co-infection were serious complications, documented in 83% and 75% of deaths (respectively), similar to those observed in pandemics. The rate of nosocomial infection was not higher than expected (studies show rates of 10-60%).

We highlight the fact that 10 patients were hospitalized on ICU, higher than the national average per ICU recorded in the same period (about 5 cases).

#1042 - Case Report

A CASE REPORT OF A COMPLICATED INFECTIVE ENDOCARDITIS

Ana Margarida Mosca, David Garcia, José João Martins, Rosário Araújo, António Oliveira E Silva
Hospital de Braga, Braga, Portugal

Introduction

Infective endocarditis (IE) is a febrile disease that results in the rapid destruction of cardiac structures. The presenting symptoms can arise from extracardiac embolization. If untreated, IE is associated with high mortality. In developed countries its incidence ranges from 4-7/100,000 inhabitants.

Case description

We present a case of an 65-year-old man with a history of hypertension, dyslipidemia and alcoholism, who was admitted to the emergency department with general malaise and disorientation. Physical examination: Fever, sinus tachycardia, heart murmur not known before and Janeway lesions. We performed a transthoracic echocardiogram (TTE) that revealed thick leaflets compatible with vegetations on aortic valve and good biventricular systolic function. Brain CT scan revealed diffuse hypodensities suggesting recent ischemic injury in the middle cerebral artery.

The patient was admitted to the Internal Medicine department with the diagnosis of native valve endocarditis with peripheral embolization. The patient initiated antibiotherapy with Ceftriaxone+Vancomycin; however, fever and elevated inflammatory parameters persisted. On the 6th day of hospitalization, due to sudden dyspnea, he repeated TTE which revealed aortic regurgitation de novo. The patient evolved unfavourably; due to clinical and analytical worsening and suspicion of perivalvular involvement, he was transferred to an Intensive Care Unit. He was also started on Flucloxacillin for a MSSA isolate in blood cultures. Transesophageal echocardiogram showed infiltration and disinsertion of the right coronary cusp, with a mass (25x7 mm) attached to its ventricular surface. He also developed severe aortic insufficiency. Brain CT scan showed new brain abscesses. Abdominal CT also revealed areas of infarction in the right kidney. The patient improved his clinical status with stabilization of inflammatory parameters. Repeated blood cultures were negative.

Lately, he's status worsened again, with recurrent episodes of

pulmonary oedema. It was urgently transferred to Cardiothoracic Surgery to perform aortic valve replacement. Valve cultures were negative. TET showed a correctly placed biological prosthesis with no signs of perivalvular complications.

Discussion

Intracardiac and CNS complications contribute to the morbidity and mortality of IE and may require surgical treatment. Despite some controversy, surgical intervention in complicated IE appears to be associated with a significant benefit in 6-month survival.

#1046 - Case Report

CLASSICAL COMPLICATION AS A FORM OF CLINICAL PRESENTATION

Paulo Duarte Medeiros, Ana Sá, Vanessa Palha, Teresa Pimentel, Narciso Oliveira, Carlos Capela
Hospital de Braga, Braga, Portugal

Introduction

Infectious endocarditis is associated with high rates of morbidity and mortality. Among the "typical" microorganism isolates, we know that the *S. bovis* group is especially prone to embolize and this may sometimes dominate the clinical picture.

Case description

We present the case of a 58yo male with previous history of smoking and alcohol abuse. He's under no medications. He presented to the emergency room with complaints of lack of strength on the left side of the body, compromising the gait. He had no visual deficits, headache or other symptoms.

He was conscious and cooperating with the physical examination. SpO₂ 98%, BP 110/62 mmHg; HR 82 bpm; T 38.3°C. On neurological exam, we observed central facial palsy and left hemihypoesthesia. Pulmonary auscultation was unremarkable; there was a systolic murmur on cardiac auscultation, predominantly at the aortic focus.

Brain CT showed no signs of acute vascular injury. AngioCT revealed bilateral stenosis (60%) in the internal carotid arteries, but no hemodynamic compromise. ECG on sinus rhythm. Biochemical tests were unremarkable, except for an elevated leucocyte count on the urinary sediment. The patient was started on dual antiplatelet therapy and amoxicillin/clavulanate. Due to lumbar pain, we performed an abdominal CT which revealed an area of splenic infarction.

After admission to the Internal Medicine Department, we performed a brain MRI that showed an acute ischemic lesion by thrombus in right posterior cerebral artery area. On echocardiogram we identified a vegetation attached to the aortic valve, confirmed later by transesophageal echocardiogram. *S. lutetiensis* was isolated from blood cultures; then we switched to Ampicillin, with favorable clinical response. After 5 weeks on antibiotic, the patient had an episode of acute pulmonary edema. This time, besides the vegetation, we identified severe aortic

regurgitation on echo. The patient was emergently taken to surgery for valve replacement, which was a successful procedure. Due to the association between *S. bovis* group bacteremia and colorectal cancer, we performed a lower colonoscopy that was unremarkable. By the time of discharge, we assigned the patient for functional/motor rehabilitation.

Discussion

This case illustrates the complexity of EI, by enabling us to work on the infection itself, local complications and embolic phenomena. In addition, this bacterial isolate is known to embolize frequently. Patient's prognosis is largely dependent on the evolution of functional status.

#1053 - Case Report

39-YEAR OLD WOMAN WITH SEPTIC SHOCK SECONDARY TO PYOMETRA

Kaihei Masuda, Ivor Cammack

Teine Keijinkai Hospital, Sapporo, Japan

Introduction

Pyometra, is a rare condition, defined as a collection of pus within the uterus. It occurs predominantly in postmenopausal women, due to constriction of the cervical canal or difficulty with self-hygiene.

Case description

A 39-year-old G3P3 woman with a past history of dysmenorrhea, cervical intraepithelial neoplasia (CIN) and cervical stenosis, presented with a 15-hour history of progressive lower abdominal pain and vaginal bleeding.

The patient's cervical stenosis was a complication of a cervical cone biopsy 6 years ago and had been treated with surgical dilatation.

She took no regular medications but had a levonorgestrel secreting intrauterine device (IUD) for her dysmenorrhea.

On examination, her heart rate was 72/min, blood pressure was 56/26 mmHg, temperature was 36.6 °C, respiratory rate was 18/min, oxygen saturation was 99% on room air, and Glasgow Coma Scale score was 14 (E3V5M6). She had lower abdominal tenderness but no signs of peritonitis. Labs showed leukopenia (580/mm³), thrombocytopenia (87000/mm³) and coagulopathy (INR 1.33). Bedside ultrasonography demonstrated free fluid in the abdomen, and CT scan showed a large volume of free fluid in the uterine cavity and small volume ascites in the Pouch of Douglas.

Septic shock secondary to pyometra was diagnosed and she was admitted to the intensive care unit for ongoing management.

We initiated broad-spectrum antibiotics (meropenem and vancomycin) to cover *Streptococcus* species, *Bacteroides fragilis* and *Escherichia coli*, and inserted a catheter into the uterine cavity using a probe to allow drainage of the pus. The patient had severe constriction of the cervix, making the IUD difficult to remove. It was eventually done under local anesthetic the

following day. Blood and swab cultures grew *Escherichia coli*, and we de-escalated her antibiotics to cefazolin.

Discussion

Pyometra is rare in young women as the premenopausal endometrium is relatively resistant to infection because of cyclical menstrual shedding and consequent drainage of infected material. In premenopausal women, it is usually associated with a history of cervical intervention or congenital anomaly. In this case, the patient had cervical stenosis as a complication of her cone biopsy, and the IUD also contributed to the development of pyometra. This condition can lead to life-threatening sepsis and should be considered in females presenting with abdominal pain and sepsis, particularly those with a history of cervical problems.

#1057 - Case Report

FOUR CONSECUTIVE EPISODES OF MALARIA – MORE THAN JUST BAD LUCK

Estela Ferrão, Francisca Pulido Valente, Rodrigo Pereira Andrade, Maria José Grade, Luísa Arez

Hospital de Portimao, Department of Internal Medicine, Portimão, Portugal

Introduction

Plasmodium falciparum malaria is more severe than the disease caused by other plasmodium species, being responsible for a considerable morbidity and mortality rate. If the patient receives an inadequate therapeutic, allowing the parasite to survive inside the red cell, there is a possibility of recrudescence of the disease.

Case description

We present a case of a 50-years-old man, living in Portimão but working in a mine in Africa during half of the year. He had a past history of 3 malaria episodes in the last 6 months, treated with a 3 days course of non-specified medication. He denied ever having received chemoprophylaxis. On month after the last episode, he returned to Portugal, and presented to the Emergency Room with high fever, chills, generalized weakness, myalgia and jaundice.

Physical exam: Axillar temperature 39°C. Icteric sclera. Tachycardic, rhythmic heart sounds. Painful hepatosplenomegaly. Laboratory results: leucocytes 6300; neutrophils 5300; RPC 281.17 mg/L; PT 15 sec, platelets 52000; total bilirubin 2.3 mg/dl; direct 0,7mg/dl; LDH 822 U/L; HIV 1 and 2 negative.

Malaria rapid diagnostic test negative. Peripheral blood smear: mature and young trophozoites, schizont forms, gametocytes, red blood cells infected with parasites, with parasitemic index of 2%.

Abdominal ultrasound: mild hepatomegaly and splenomegaly. He had a 7 days course of quinine sulfate and doxycycline, becoming afebrile and asymptomatic in the 3rd day of hospitalization, with elimination of the parasite in the peripheral blood smear at the same time.

As intercurrent, iatrogenic QT interval prolongation (ECG) and mixed hepatocellularcholestatic liver injury.

Discussion

In this particular case the plasmodium falciparum recurrent malaria was consistent with a recrudescence caused by a therapeutic failure, which is known to occur mainly in not immunized patients. The authors want to highlight how important it is to assure that travelers and expatriates workers receive proper malaria chemoprophylaxis before going to an endemic area. They should be alarmed to the danger of contracting the disease and when and how to obtain the proper treatment, mainly in remote rural areas. This case demonstrates the occurrence of malaria infection cases out of a formal health sector, passing unnoticed to public health surveillance systems and how the therapeutic regimes adapted do not comply with the OMS recommendations.

#1059 - Case Report

LOW DIGESTIVE BLEEDING – ALMOST FATAL CASE OF TYPHOID FEVER

Alexandra Ávila, Vanda Conceição, Francisca Pulido Valente, Nuno Vieira, Maria José Grade, Luisa Arez

Serviço de Medicina 3 – Unidade Hospitalar de Portimão do Centro Hospitalar Universitário do Algarve, Portimão, Portugal

Introduction

Although infrequent, sporadic cases of typhoid fever continue to occur in developed countries. Most often benign, especially with the advent of the new antibiotic therapy, the disease can be severe and cause complications in about 10-15% of patients, and gastrointestinal bleeding is the most common.

Case description

A 54-year-old man with a previous history of coronary angioplasty, and doubly antiaggregated in this context, resorted to the Emergency Room for epigastric pain from the previous day. At the examination was founded fever, profuse sweating and epigastric pain on abdominal palpation. In the initial exams, he had to highlight the elevation of the inflammatory parameters only. He was hospitalized, it was collected septic screening and he started piperacillin-tazobactam. On the 3rd day he maintained a high fever, chills and started hematochezia, which was complicated hypovolemic shock requiring hemodynamic and transfusional support. The upper digestive endoscopy had no changes; the 1st colonoscopy was inconclusive due to blood and fresh clots in the colon. On 5th day, it was isolated a tiphy salmonella in blood cultures and was altered the antibiotic therapy for ceftriaxone. The 2nd colonoscopy showed ulceration of the terminal ileum corresponding to CT angiography thickening. When we explored more, the patient reported the ingestion of fresh eggs at home in the days before. The patient had a favorable clinical and analytical evolution, with no hematic losses.

Discussion

In this case, there is various confounding factors that made the differential diagnosis of an already challenging entity. The fact that

the patient presents nonspecific symptoms (fever and epigastric pain) confirms the variability of the clinical presentation of typhoid fever. Epidemiological history, especially in rural settings, can be determinant in clinical practice. The development of digestive haemorrhage is a rare complication in the 1st week of acute typhoid fever and under antibiotic therapy. Finally, it is reinforced that the approach even in severe cases is mainly conservative with antibiotic therapy and hemodynamic and transfusional support.

#1061 - Case Report

BONE TUBERCULOSIS AN ANCIENT THREAT THAT STILL CONCERNS NOWADAYS

Alexandra Ávila, Vanda Conceição, Rita Fernandes, Nuno Vieira, Maria José Grade, Luisa Arez

Serviço de Medicina 3 – Unidade Hospitalar de Portimão do Centro Hospitalar Universitário do Algarve, Portimão, Portugal

Introduction

Tuberculosis is an infectious disease that co-evolved with humans for 70000 years. There are studies of Egyptian skeletons dated from 3500BC showed that 11% of mummies had morphological alterations characteristic of vertebral Tuberculosis.

Nowadays, developed countries treat pulmonary Tuberculosis timely controlling its spreads for extra pulmonary locations. Due to an increase of emigration rates it is important to keep in mind the natural history of Tuberculosis infection to enhance the suspicion grade for diagnosing these old frequent complications.

Case description

A 22 years-old man, emigrant from Guinea-Conakry, living in Algarve for 6 years now with his father and brother went to the Emergency Room with high fever, chills, persistent dry cough, left base pleuritic chest pain, malaise and myalgias for 48 hours. He was medicated with antibiotherapy (amoxicillin/clavulanic acid) the day before, but he could not take it or eat due to nausea and vomit. Family describes anorexia, asthenia and weight lost for at least 2 weeks.

Past medical history of infant parotiditis, convex scoliosis and previous appointments for back pain/abdominal pain with back irradiation.

He was admitted in the hospital and started treatment with amoxicillin/clavulanic acid + azitromicin. Three days after, he initiated respiratory failure with polypnea and cough worsening. Repeated X-ray showed complete opacification of left lung and the Angio-CT revealed extended left pleural effusion and osteolytic lesions in inferior dorsal column. He was admitted in ICU with Acquired Community Pneumonia and Spondylodiscitis.

Thoracocentesis showed pleural liquid with lymphocytic exudate and a high adenosine deaminase (123 U/L) suggestive of pleural tuberculosis. MRI identified a paravertebral mass in D9-D10 and vertebral body D11 was biopsied with Ziehl-Neelsen positive at direct examination suggestive of bone tuberculosis. It was started tuberculostatic therapy and was discharged a few days later, continuing ambulatory treatment.

Discussion

This case reveals the importance of a thorough clinical history and the differential diagnosis to the back pain and the earlier treatment to prevent the complications of infection disease.

#1070 - Case Report

DISSEMINATED HERPES ZOSTER - A CASE OF CUTANEOUS AND MENINGEAL DISEASE IN A PATIENT WITH HIV INFECTION

Ana Luísa Campos, David Paiva, Daniela Casanova, Isabel Trindade, Jorge Cotter

Hospital da Senhora da Oliveira, Guimarães, Portugal

Introduction

Reactivation of the herpes zoster virus occurs in 10-20% of HIV-infected patients, indicates a modest decline in immune function and may be the first sign of clinical immunodeficiency.

Case description

Male, 53 years old. HIV-HCV co-infection. Complaints of vesicular lesions and pain in the left lumbar and inguinal regions and base of the penis. No fever, emaciated and with herpetic lesions in the supradescrpt location. Of the diagnostic tests: anemia (12.8 g/dL), lymphopenia (900/ μ L), without other alterations. Of note, the last count of CD4+ T lymphocytes (80/ μ L) and HIV viral load (24.10 copies/mL) were from 2 months ago.

The immunocompromised patient was hospitalized for herpes zoster infection and treatment with acyclovir was instituted.

On the 2nd day of hospitalization he started complaints of headache and fever. Lumbar puncture was performed. CSF analysis: normal opening pressure, 103 leukocytes/ μ L with a predominance of mononuclear cells, increased proteins (152.60 mg/dL), and normal glucose and adenosine deaminase levels. The CSF PCR analysis for varicella zoster was positive. There was good clinical progress. The patient completed 14 days of acyclovir and was discharged.

Discussion

VZV is among the most common viral meningitis agents. The typical CSF is characterized by pleocytosis with predominance of lymphocytes, normal or slightly increased proteins, normal glucose and normal opening pressure. In this case, the analysis of the CSF corroborated the clinical suspicion of VZV meningitis, which should be suspected in the presence of concomitante varicella or herpes zoster, especially in immunocompromised patients. VZV infections with neurological complications should be tretated with acyclovir.

#1072 - Case Report

CHIKUNGUNYA FEVER CASE REPORT - THE IMPORTANCE OF EPIDEMIOLOGY IN DIAGNOSIS

Carolina Morna, Carolina Barros, Jessica Chaves, Tiago Esteves Freitas, Maria Luz Brazão

Hospital Central Funchal, Funchal, Portugal

Introduction

Chikungunya is an infection caused by the Chikungunya virus (ChikV), an alphavirus transmitted by the mosquito vectors *Aedes aegypti* e *Aedes albopictus*. Previously restrict to west Africa and Asia, major outbreaks have been report at South and Central America. Europe has minor incidence rates caused by imported cases from travelers. Until 2018, Portugal had only four cases detected. *Aedes aegypti* populations on Madeira Island are competent vectors.

The incubation period is typically 3 to 7 days. Characteristic symptoms include sudden onset of high fever and severe symmetric polyarthragias and rash. Other unspecific symptoms, as fatigue, malaise and digestive complains are usual. Symptoms are generally self-limited. The same mosquito vectors transmit dengue and Zika viruses and coinfections have been documented. Since they have the same geographic distribution and their symptoms can be mistaken, the screening of the three viruses is recommended.

Case description

A 76 years old male patient, Portuguese, living partially in Madeira Island and in Brazil. Returned from Brazil two days before admission.

Healthy until 5 days before admission, when he started presenting high fever, myalgia, expressive diffuse polyarthralgias, mainly on the limbs, and headache. Upon examination, he was alert, febrile (tympanic temperature 39.4°C), hemodynamically stable, with a macupapular rash affecting the superior limbs and trunk. Cardiopulmonary examination was normal. Laboratory data: white blood cells 8200 uL, 4.6% lymphocytes, 93.7% neutrophils; platelets 166000; C-reactive protein 131 mg/dl. Chest x-ray, mild bilateral parahilar infiltrate. The patient was medicated with antibiotics with resolution of the fever two days after. Due to persistence of severe polyarthralgias and malaise, the patient returns to the emergency room. Based on the symptoms and the epidemiological background, screening for dengue, ckikungunya and zika was performed. Lab results revealed positive IgM antibody against ChikV. IgM antibody against Zika and Dengue viruses and NS1 antigen test were negative. It was instituted supportive care with complete resolution of the clinical condition.

Discussion

The aim of this report was to highlight the importance of the epidemiological context on diagnosis and the risk of spreading geographically to regions with appropriate climate where competent mosquitoes exist.

#1090 - Case Report

A RARE CASE OF SPONTANEOUS SUBDURAL HEMORRHAGE IN A PATIENT WITH MENINGOENCEPHALITIS CAUSED BY WEST NILE VIRUS

Eleftheria Ztriva, Christos Savopoulos, Dimitrios Pilalas, Areti Sofogianni, Dimitrios Milonas, Anastasia Erythropoulou, Maria-Christina Grammenou, Thomas Tegos, Apostolos Hatzitolios

A¹ Propaedeutic Department of Internal Medicine, AHEPA University General Hospital, School of Medicine, Aristotle University of Thessaloniki, Greece, Thessaloniki, Greece

Introduction

West Nile Virus (WNV) is an RNA virus that causes West Nile fever. Two evolutionary species have been reported as pathogenic to humans. The virus is most commonly spread to people via infected mosquitoes. Most people infected by the WNV do not develop any symptoms, 25% develop West Nile fever and 1:150-250 people develop a neuroinflammatory disease. Risk factors are the advanced age, diabetes mellitus, cancer, immunosuppression and renal disease. Mortality is about 10%.

Case description

A 74-year-old patient, with medical history of diabetes mellitus and coronary artery disease, presented to the emergency department with complaints of recurrent fever waves since two weeks, delirium, and left leg paresis. The patient was a resident of an urban area but he mentioned no contact with animals and no travel history for the last 6 months. The brain CT scan showed no significant lesions. A lumbar puncture showed evidence of viral meningitis and the patient was treated with vancomycin, meropenem and acyclovir. The lumbar fluid serological test revealed positive IgM antibodies for WNV recent infection. At the sixth day of his hospitalization the patient showed atrial fibrillation and was treated with low molecular weight heparin (LMWH). Next day, a MRI cerebral scan showed no significant lesions as well. At the eighth day of hospitalization, the patient showed acute neurologic deterioration with Glasgow Scale 6/15. An emergency CT scan showed an extended right hemispheric hematoma with edema, elimination of subarachnoid spaces and 11.5cm displacement of the middle line. The patient was submitted to an emergency decompressive craniotomy and was transferred to the Intensive Care Unit, where he died some days later because of an in-hospital infection.

Discussion

In 2018 there was a wide epidemic spread of the WNV in Greece. 316 cases were reported. 241 developed a neuroinflammatory disease and 47 died. Our patient was infected by the WNV and developed severe meningoencephalitis. He presented a combination of risk factors for adverse outcome - diabetes mellitus, advanced age and coronary artery disease, that affected his acute deterioration. According to the literature, no cases of spontaneous subdural hemorrhage have been reported as a complication of meningoencephalitis in patients infected by WNV. Some cases of intracerebral hemorrhage attributed

to the inflammation of the vascular endothelium have been reported. In our case, the onset of LMWH was also an aggravating factor.

#1104 - Case Report

ULCERATIVE GINGIVITIS AS A MANIFESTATION OF EXTRAPULMONARY TUBERCULOSIS IN A PATIENT WITH CROHN'S DISEASE UNDER ANTI-TNF TREATMENT

Fazia Mana¹, Ana Tache², Caroline Geers², Deborah De Geyter², Patrick Lacor²

¹ Kliniek Sint-Jan, Brussels, Belgium

² UZ Brussel, Brussels, Belgium

Introduction

Patients receiving anti-TNF therapy have a higher incidence of disseminated and extrapulmonary tuberculosis (TB) despite screening for latent disease. The highest risk for TB is associated with the use of adalimumab and infliximab. Typical extrapulmonary sites of TB include pleural space, lymph nodes, peritoneum and pericardium. Gingival involvement is an infrequent manifestation.

Case description

A 58-years old woman with a history of Crohn's disease on maintenance treatment with subcutaneous adalimumab, was admitted to the hospital because of ulcerative gingivitis with swelling of the right cheek, resulting in disabled oral intake and weight loss. Her symptoms had begun 6 weeks earlier. Treatment with oral clindamycin, followed by amoxicillin-clavulanate and metronidazole had not resulted in any improvement. Gingival biopsy, performed elsewhere, had shown granulomatous inflammation that was attributed to Crohn's disease. Adalimumab was therefore switched to ustekinumab, an IL-12/IL-23-blocking agent, but without clinical improvement.

Physical examination showed inflammatory gingivitis mainly at the level of the upper right incisor and canine teeth. CT-imaging showed diffuse swelling of subcutaneous right maxillary tissue, with enlarged right submandibular lymph nodes. There were no signs of bone involvement. A gingival biopsy was performed and revealed mucosal inflammation with caseating granulomas. PCR for Mycobacterium tuberculosis was positive. Total body CT-scan was negative for pulmonary lesions but showed enlarged lymph nodes at the level of the mediastinum, the right hilus as well as retroperitoneally. Tuberculous skin test was positive.

Biologicals were stopped and anti-tuberculous quadritherapy was started. Four weeks later, there was major clinical improvement, with restoration of normal oral feeding and almost complete regression of mucosal swelling and gingival inflammation. In the meantime, the cultures of the gingival biopsy had become positive for Mycobacterium tuberculosis, sensitive to all antibiotics used.

Discussion

Patients on anti-TNF treatment have a higher incidence of disseminated and extrapulmonary tuberculosis. Therefore, a low

threshold should be kept to include this infection in the differential diagnosis when these patients develop new symptoms, even if the clinical presentation is atypical. In this patient, the rare manifestation of gingival involvement led to a delay in diagnosis.

#1108 - Case Report

STTD: A SEXUALLY TRANSMITTED TUBERCULOUS DISEASE

Madeleine Larissa De Rooij, Michelle Gompelman, Stella Tiersma, Marije Bomers
Amsterdam UMC, Vrije Universiteit Amsterdam, Amsterdam, The Netherlands

Introduction

Tuberculous endometritis is a common cause of secondary amenorrhea and female infertility in regions where tuberculosis is highly prevalent. In Western countries, this diagnosis should be considered in immigrants from these regions with endometritis.

Case description

A 29-year-old Eritrean woman presented with secondary amenorrhea, after she had been sexually assaulted in her homeland two years earlier. Hysteroscopy showed endometrial adhesions in the inner ostium of the cervix, which were relapsing despite several adhesiolyses. Histologic examination of the adhesive tissue revealed chronic inflammation with granulomas. Stains and cultures for bacterial (including *Actinomyces*) and fungal infections were negative, as well as stain and PCR for *M. tuberculosis*, and serology for syphilis and schistosomiasis. Finally, mycobacterial culture of the removed endometrium confirmed an infection with *M. tuberculosis*. There were no signs of other localizations of tuberculosis. The patient was treated with tuberculostatic therapy during six months. Six weeks after treatment initiation her regular menstrual cycle returned.

Discussion

We present a case of secondary amenorrhea caused by tuberculous endometritis. Although this form of tuberculosis is rare in Western countries, it should be considered in women originating from endemic countries presenting with infertility, menstrual abnormalities or lower abdominal/pelvic pain. The exact pathogenesis varies. Mostly there is hematogenous spread from a pulmonary or other non-genital localization. Also direct contamination from peritoneal tuberculosis (via oviduct) and sexual transmission from a partner with tuberculous epididymitis are possible. In this patient the route of transmission is unclear; there were no signs of extragenital localization, pointing towards inoculation from a male sexual partner. In case of hematogenous spread, the injured genital tract might have acted as locus minoris, predisposing the uterus for bacterial seeding. To start early treatment and limit the risk of infertility, it is critical to have a high awareness of this disease and to consider this cause of endometritis in women originating from countries where tuberculosis is endemic.

#1109 - Case Report

TODAY IS YOUR LUCKY DAY

Alejandro Bendala Estrada, María Toledano Macías
University General Hospital Gregorio Marañón., Madrid, Spain

Introduction

A 26-year-old woman came to the Emergency Department due to fever, rash and polyarthralgia. The examination shows erythematous-violaceous maculo-papules on the hands and feet without other findings. She was discharged after extraction of blood cultures with antipyretics, glucocorticoids and evolutionary control at home

Case description

3 days later, persistence of fever of 39°C, intense pain and functional impotence in several joints, with arthritis at the ankles, elbows and metacarpophalangeal. Apparition of an erythematous plaque of more than 40 cm in the right lower limb, and lymphangitis in the left thigh. Severe tenosynovitis at the bilateral metatarsal. However, the most remarkable is the presence of edema in the right eye with inability to open, with pain and significant conjunctival hyperemia. No neurological focus to exploration. We found isolation of *Neisseria meningitidis* serotype C in blood cultures.

Blood analysis is requested in which leucocytosis with neutrophilia, elevation of fibrinogen, PCR and procalcitonin. Alterations in the hepatobiliary profile and coagulopathy. Without deterioration of renal function. Urine analysis, chest x-ray and electrocardiogram without alterations. New blood cultures are extracted and a lumbar puncture is performed, no pathological (with PCR for *Neisseria* and culture both negatives).

An Ophthalmology assessment is requested that confirms the presence of right endophthalmitis of endogenous origin and initiates intravitreal injections with Vancomycin and Ceftazidime. In view of the meningococemia disease, we decided isolation, anti-inflammatory treatment and antibiotic coverage with intravenous Ceftriaxone was decided with excellent evolution.

Discussion

Symptoms of *N. meningitidis* infection range from fever and bacteremia to a fulminating illness within a few hours. It is an urgent notifiable disease. There are several clinical cases described, the least frequent being chronic meningococemia. In our case, the patient is diagnosed with chronic meningococemia, fulfilling the criteria described by Solomon in 1902: fever of more than a week of evolution, rash, positive blood culture to *N. meningitidis*, and joint affectation. In 5% of cases, arthritis and pericarditis can occur due to the deposition of immune complexes. Similar percentage develops maculopapular rash, osteitis and endophthalmitis.

Luckily, our patient has not developed a meningitis, since more than 80% of cases of meningococemia produce purulent meningitis.

#1115 - Abstract

EXPERIENCE IN THE USE OF CEFTAZIDIME-AVIBACTAM IN A TERTIARY HOSPITAL

Mario Salcedo^{1,2}, María Sahuquillo¹, Iván Castro Hernández¹, Marta Montero Alonso¹, María Tasia Pitarch¹, Eva Calabuig Muñoz¹, Miguel Salavert Lleti¹

¹ Hospital Universitario y Politécnico La Fe, Valencia, Spain

² Universidad de Valencia, Valencia, Spain

Background

Ceftazidime-avibactam is the combination of ceftazidime and avibactam, expanding the activity of ceftazidime against β -lactamases of classes A and C and carbapenemase type KPC and OXA-48 producer enterobacteria.

Objective

To evaluate the experience using Ceftazidime-Avibactam in a tertiary hospital.

Methods

A retrospective study that included all the episodes of patients who received Ceftazidime/Avibactam in the period from January 2018 to January 2019. The epidemiological, clinical and microbiological characteristics, the antibiotic treatments received, their duration, and the evolution of patients were obtained and analyzed.

Results

Ceftazidime-avibactam was used in 32 infectious episodes (29 patients). They had a median age of 56.5 years, with 86.2% of males. Most common base diseases: 31% haematologic neoplasia, 31% solid organ cancer, 13.8% transplanted and 6.9% cystic fibrosis. The most frequent infections that motivated its use were respiratory in 37.5% of episodes, abdominal 25% and urinary 21.9%. In 21.9% of episodes, this treatment was initiated in sepsis or septic shock. The most frequently implicated microorganisms were Gram-negative bacteria producers of β -lactamases and carbapenemases: *P. aeruginosa* 25%, *K. pneumoniae* 21.9% and *E. cloacae* 6.2%. In 90.6% another antibiotic was associated, being the aminoglycosides the most frequent (27.6%), followed by colistin (24.1%). In 9.4% episodes, adverse effects were described (leuko, neutro and thrombocytopenia, and diarrhea), which conditioned discontinuation in 66.6% of them. In 6.3% of episodes, antibiotic treatment was administered at home with Home-Care Unit support, and 3.1% in Day-Hospital. Clinical curation was achieved in 81.3% of episodes, 9.4% had a recurrence, 6.2% died and 3.1% did not improve.

Conclusion

In our experience, ceftazidime-avibactam has been used mainly in the indications collected in the data sheet, caused mostly by *P. aeruginosa* and *K. pneumoniae* producers of β -lactamases and/or carbapenemases. The profile of patients was middle-aged men with neoplasms or transplanted. In most cases, an association was made with other antimicrobials, especially aminoglycosides. In general, it was well tolerated, with haematological toxicity being

the most frequently described. Its use in combination with other antibiotics was associated with high response rates.

#1119 - Abstract

CLINICAL EXPERIENCE IN THE REAL-LIFE DALBAVANCIN USE IN A TERTIARY HOSPITAL

Mario Salcedo^{1,2}, María Sahuquillo¹, Marta Montero Alonso¹, María Tasia Pitarch¹, Eva Calabuig Muñoz¹, Iván Castro Hernández¹, Miguel Salavert Lleti¹

¹ Hospital Universitario y Politécnico La Fe, Valencia, Spain

² Universidad de Valencia, Valencia, Spain

Background

Dalbavancin is a new antimicrobial lipoglycopeptide approved for the treatment of acute skin and soft tissue infections caused by Gram-positive bacteria such as *Staphylococcus aureus* sensitive and methicillin-resistant, staphylococci coagulase negative, *Streptococcus* spp. and *Enterococcus* spp. Few data have been published on the use of dalbavancin in daily practice and its effectiveness in other types of infections.

Objective

To evaluate clinical experience using Dalbavancin in complicated or off-label infections.

Methods

A retrospective study that included all the patients who received at least one dose of dalbavancin from October 2017 to December 2018 in our centre. Clinical-epidemiological, microbiological and therapeutic characteristics of the patients were collected, as well as their response and clinical evolution.

Results

A total of 13 patients (53.8% men) with a median age of 62 years (18-87) received dalbavancin during the study period. The infections treated were: 53.8% osteoarticular infection, 28.5% infection of the skin and soft tissues, and 7.6% central venous catheter infection. The microorganisms involved were: 3 *S. aureus* (1 MRSA), 4 coagulase negative staphylococci, 2 *E. faecalis*, 1 *S. agalactiae* and 1 viridans group *Streptococcus*. Dalbavancin was prescribed to facilitate home discharge in 85% and in 15% because of other antibiotics' side effects.

A second antibiotic was associated in 53.8% of the cases, fluoroquinolones were the most commonly added (28.5%). Most treatments were administered during hospitalization, 53.8% prior to discharge, 28.5% at the Day hospital and 7.6% in the Home-Care Unit. In 92.3% of the patients the infection was resolved without subsequent recurrence. During the treatment, no adverse effects were observed.

Conclusion

In our experience, dalbavancin has been an effective and well tolerated treatment even when it has been used in off-label

indications, such as osteoarticular and central venous catheter infections. Due to its long half-life and good safety profile, dalbavancin could reduce the days of hospital staying, easing the discharge process with other healthcare supports.

#1120 - Case Report

NON PHARMACOLOGICAL APPROACH IN CLOSTRIDIUM DIFFICILE RECURRENT DISEASE

Tiago Vasconcelos¹, Francisca Pulido Valente², Joana Nascimento¹, Cristina Pita³, Marta Duarte¹, Raquel Pinho¹, Rui Ferreira³, Helena Tavares Sousa², Helena Rita¹, Domitília Faria¹, Luísa Arez¹

¹ Serviço de Medicina 3, Unidade de Portimão (CHUA). Algarve Biomedical Center, Portimão, Portugal

² Serviço de Gastroenterologia, Unidade de Portimão (CHUA). Algarve Biomedical Center, Portimão, Portugal

³ Serviço de Patologia Clínica 2, Unidade de Portimão (CHUA). Algarve Biomedical Center, Portimão, Portugal

Introduction

Clostridium difficile (recently reclassified as *clostridioides difficile*) is a commensal bacteria of gastrointestinal tract, however, if there is an imbalance of the normal intestinal microbiota, this bacteria could precipitate intestinal disease and, as a spore-producing bacteria, it is able to spread and contaminate the environment and other persons, being the major cause of hospital acquired diarrhea. Among 20-25% of patients develop recurrent disease, the main risk factors being: previous *C. difficile* infection (CDI), ≥ 65 years, antibiotics after CDI, proton pump inhibitors, prolonged or recent stay in a health institution. The current literature consistently shows CDI cure rates above 90%, through fecal microbiota transplantation (FMT).

Case description

We present the case of an 84-years-old woman, personal history of chronic anemia, hypertension and type 2 diabetes, advanced stage heart failure, chronic kidney disease, with recent prolonged hospitalization due to decompensation of these medical conditions, complicated by nosocomial CDI, treated with vancomycin with resolution of symptoms. Readmitted 14 days after discharge with recurrence of CDI, repeated vancomycin in a tapered and pulsed regime. Readmitted 15 days after discharge with new recurrence, therapy was modified to fidaxomicin. After the fourth recurrence, given the prolonged and debilitating CDI and inefficacy of standard antibiotic treatment, it was decided to proceed to FMT. A healthy family donor was selected, the fecal transplant prepared in the laboratory and delivered by colonoscopy in the terminal ileum, ascendent, transverse, descendent and sigmoid colon, with recovery and rapid resolution of the clinical picture, with no recurrences at tenth day.

Discussion

The main goal of presenting this clinical case is to alert medical

professionals regarding the clinical burden of recurrent CDI, in which, if pharmacological therapy is ineffective, one should consider FMT, since it is a highly effective treatment method with excellent cost-benefit ratio and high cure rate, accessible to perform even in low resources institutions, only requiring simple laboratory techniques and a trained endoscopist. Authors present full iconography of the procedure from collection of material, until intestinal infusion through colonoscopy with ileoscopy.

#1127 - Case Report

WASHING THE SEWER

Inês Goulart, Tiago Petrucci, Joao Virtuoso, Ana Bento Rodrigues, Joana Rosa Martins, Manuel Ferreira Gomes, Paulo Cantiga Duarte

Centro Hospitalar Lisboa Norte, Lisboa, Portugal

Introduction

Leptospirosis is a zoonosis caused by the leptospira bacteria, which can infect humans through exposure to urine of animals that are natural hosts (including rodents). The clinical course is varies, and its most severe form is known as Weil's syndrome.

Case description

The authors present the case of a 41-year-old man, in prison for about a year, with no past medical history. He was taken to the emergency room due to nausea, vomiting brown content, diarrhea and choluria. He also complained of abdominal and lumbar pain. The symptoms had started 4 days before going to the hospital and he had been given metoclopramide and loperamide, in the past 2 days, without improvement.

On observation there was jaundice (sclerae and skin) and diffuse painful abdominal pain. The laboratory workup showed rising acute phase reagents, thrombocytopenia, acute renal injury (AKIN III), high aminotransferases and hyperbilirubinemia. HIV, HCV and HBV were negative. An abdominal ultrasound was done that did not show any alterations. Weil Syndrome was considered as a hypothesis (there was confirmation of rats exposure in prison) so the patient was started on doxycycline.

During hospitalization, there was worsening kidney failure with anuria and metabolic acidosis, so the patient was put on dialysis with subsequent recovery after 3 sessions.

There was improvement of kidney function and recovery of hematological changes such as anemia and thrombocytopenia (minimum 7000/mcL). The patient also suffered from non-lithiasic pancreatitis with rising amylase and cholestatic pattern (total bilirubin higher level was 19.92mg/dL and direct bilirubin was 12.1 mg/dL); there was also rhabdomyolysis (CK 761U/L). There was central nervous system involvement with mental confusion and motor discoordination.

The patient was on doxycycline for 10 days with clinical improvement and decrease of the inflammatory markers. There was posterior confirmation of leptospirosis with positive c-reactive protein in blood and urine.

Discussion

The authors pretend address the importance of epidemiological context in differential diagnosis of infectious diseases, reporting a case with several complications, in which the right diagnosis was determinant for patient survival.

#1132 - Case Report

LEMIERRE SYNDROME

Estefanía Martínez De Viergol Agrafojo, Ángela Sóler Gómez, Ricardo De Los Rios De La Peña
Hospital Universitario Puerta del Mar, Cádiz, Spain

Introduction

Lemierre's syndrome is a rare, potentially fatal condition characterized by internal jugular vein thrombosis with septicemia following an acute oropharyngeal infection. Lemierre's syndrome has been termed the "forgotten disease".

Case description

A 21-year-old male presented to emergency because of a history of fever and odynophagia, he was diagnosed with tonsillitis and treated with erythromycin. Two days later he returned due to persistence of fever, jaundice and pain in the right laterocervical region. He had a history of allergy to Amoxicillin, smoking, a recent tattoo, and cleaning of a well in the days before the hospital admission.

On physical exam, there was left peritonsillar swelling, also had mild tenderness near the right jaw angle that was exacerbated by turning his head to the right. The neck was nontender to palpation without lymphadenopathy.

Initial labs were significant for a leukocytosis of 13880 cell, 44,000 platelets/ μ L, total bilirubin 5.87 mg / dl and direct bilirubin 4.96 mg/dl, PCR 227 mg/l and procalcitonin 61 ng/ml.

Blood culture was positive for the growth of *Serratia marcescens*, patient was treated with intravenous Aztreonam and Ciprofloxacin. We had the suspicion of septic thrombosis of the jugular vein and we requested an ultrasonography of the neck that revealed a right internal jugular vein thrombosis. Patient was diagnosed as Lemierre syndrome and was treated with intravenous clindamycin.

We receive the blood cultures that was positive of *Fusobacterium necrophorum*. We replaced the treatment of ciprofloxacin with Levofloxacin and continued with clindamycin.

The patient began with a sensation of dyspnea, in the chest CT, bilateral pleural effusion and numerous pulmonary nodules suggestive of septic thrombosis were found. We decided to perform thoracentesis to rule out an empyema. The study of pleural fluid showed an empyema and decided not to place a chest tube and see the clinical evolution.

After starting intravenous therapy patient symptomatically improved in two two weeks, then he shifted to oral antibiotic therapy. After 6 weeks completion of full course of the therapy, patient was improved clinically.

Discussion

In this case report, we describe a young patient diagnosed with the Lemierre syndrome. Although classically *Fusobacterium necrophorum* has been described as the most frequent germ, there are described cases of polymicrobial flora. The finding in *Serratia* blood cultures is an interesting observation although the reason for this is unclear.

#1133 - Abstract

CARBAPENEMASE PRODUCING BACTERIA-CASE SERIES REVIEW ON ICU

Claudia Janeiro¹, Rita Santos¹, Felisbela Gomes¹, Filomena Lourenço²

¹ Medicina 2.1; hospital Santo antonio dos Capuchos, Centro hospitalar Lisboa central, Lisboa, Portugal

² Unidade de Urgência Medica, Hospital de Sao José, Centro hospitalar Lisboa central, Lisboa, Portugal

Background

In recent years, infections with carbapenemase-producing enterobacteriaceae (CPE) have been increasing globally and present a major public health challenge. Patients infected with CPE have limited treatment options and high mortality rates (26-44%).

Methods

Review of all patients admitted in Intensive care unit between January and September 2017 with isolation of CPE agent.

Results

Total: 34 patients; 74% male and 26% female with median age 64.26 years (no significant differences between sex).

Majority of patients admitted from Internal medicine ward (32%) or directly from emergency room (29%) and 44% of patients with septic shock as diagnosis of admission.

The mortality rate was about 56% and the median days of stay in ICU was 19.88 days.

The isolation of the agent was found in broncheal secretions (27%); blood cultures (25%); rectal swab (23%); vascular catheters (9%); surgical wound sample (9%); urine culture (2%) and others (5%) such as pleural and cerebrospinal fluid. The agent isolated in 100% was *Klebsiella pneumoniae*.

Conclusion

Although it is a small sample to make big conclusions we can say that these infections are being more and more prevalent in hospital, with a very high mortality rate (and also very prolonged hospital stay).

It is also important to mention the screen for colonization (positive culture in rectal swab) because without formal indication for treatment, there is high need for contact measures so that we can prevent spreading of infection.

#1138 - Case Report

MORE THAN A FALL IN AN ELDERLY: A NOT SO COMMON COURSE OF OSTEOMYELITIS.

Sara Duarte, André Santos, Sérgio Silva, Catarina Jorge, Diana Reis, Ana Rodrigues, Domingos Sousa, Rita Fernandes, Margarida Coelho, Karolina Aguiar, Armindo Figueiredo

Centro Hospitalar e Universitário do Algarve, Faro, Portugal

Introduction

Osteomyelitis is an inflammatory and infectious process involving the bone. Bone is normally resistant to bacteria, but events, such as, trauma, surgery, protheses placement, may disrupt its integrity, leading to infection mainly caused by *Staphylococcus aureus*, with the spine, hips and feet being the most affected locations. Symptoms range from pain to weakness, and fever may be present. Diagnosis is based on blood tests, images or bone biopsy. Infections associated with protheses and trauma should be treated with combination of rifampin and other antibiotics, and, if necessary, surgery.

Case description

Male patient, 75 years old, caucasian, Portuguese, retired. Presented to the ER with pain on his right thigh after a fall a month before. The patient states night sweats but denies any other symptom, and has been taking analgesics every few hours, for the last month. As important past history, patient had a partial femur replacement 20 years ago after a car accident. Diagnostic workup at the ER included a right thigh X-ray showing a hypotransparency on the periphery of femur prothesis. Blood tests showed ALT/AST above 150 IU/L, GGT 358 IU/L, ALP 610 IU/L, CRP 366 mg/L, remaining blood tests were within reference range. A gastroenterologist evaluated the patient and performed an abdominal ultrasound without any abnormal finding, assuming the excess of analgesics intake as the cause of elevated transaminases. An orthopedist examined the patient and scheduled a CT-scan. To clarify the blood tests findings and patient's symptoms, he was admitted to the internal medicine ward. Blood cultures were obtained, showing positivity for MSSA and the scheduled CT scan showed liquid on the periphery of the right iliac psoas with a partially intersected prosthetic material on the femur. A bone scintigraphy with ^{99m}Tc was done afterwards but it was inconclusive so, a second bone scintigraphy with marked leukocytes was performed, showing intense radiopharmaceutical uptake on the diaphysis of the right femur, translating an osteomyelitic process. Other screenings, as concerning neoplasias and endocarditis, were negative. Patient initiated doxycycline and rifampicin with good clinical response and he was discharged with antibiotics ad eternum and follow-up appointments.

Discussion

A detailed history and past medical information is very important. This clinical case shows an infrequent course of the disease and the importance of the various diagnostic tools for a correct diagnosis and adequate treatment.

#1139 - Abstract

POTT DISEASE : ABOUT TWENTY THREE PATIENTS

Haifa Hajji, Maroua Slouma, Rim Dhahri, Leila Metoui, Najeh Boussetta, Nourhouda Guedich, Rim Abid, Faïda Ajili, Riadh Battikh, Imen Gharsallah, Bassem Louzir

Hopital Militaire de Tunisi, Tunisi, Tunisia

Background

Tuberculosis is the most common forms of skeletal TB occurring in 50% of cases of skeletal TB.

Methods

A retrospective study conducted in the department of internal medicine in Tunisia between 2009 and 2018. We reviewed the medical records of all patients diagnosed with Tuberculous spondylodiscitis.

Results

Twenty three patients were included. Sex ratio M/F was 0.39. The mean age was 51 years. Two patients had a history of cancer and were under an immunosuppressive treatment. None of them had history of TB infection. The thoracic segment was the most frequently affected (n=10), followed by thoraco-lumbar (n=8) and lumbar (n=5). Extra-skeletal TB was associated in 9 cases. The sites infections were: pulmonary (n=3), cerebral (n=3) and nodes (n=3), genitourinary (n=2), splenic (n=1), hepatic (n=1) and pericardial (n=1). Patient presented with: spinal pain (n=21), anorexia (n=15), weight loss (n=17) and night sweats (n=10). Neurological signs revealed the spinal TB infection in 2 cases. An epidural involvement was noted in 7 cases. Inflammatory markers were increased in 12 cases. The mean C reactive protein (CRP) and erythrocyte sedimentation rate was 44.02 mg/l and 60.125 mm/1h respectively. Tuberculin Skin Test was positive in 16 cases. MRI was performed in 18 cases. It demonstrated involvement of the vertebral bodies on either side of the disk, disk destruction (10 cases), cold abscess (15 cases), vertebral collapse (5 cases), and presence of vertebral column deformities (1 case). CT-guided bone biopsy was performed in 10 cases. Histological examination revealed gigante-cellular granuloma in 4 cases and caseous necrosis in 3 cases. Anti-TB treatment was conducted in all cases. A surgical treatment was necessary in 6 cases: iliopsoas abscess (n=5) and a decompressive laminectomy in one case. Most of the patients well progressed under anti-TB drugs except for one patient whose radiological lesions did not regress. Four patients were lost of sight during the follow-up.

Conclusion

Our study showed that TB spondylodiscitis affected commonly the thoracolumbar site. It is also more associated with abscesses and epidural involvement. The inflammatory markers are usually not high. The diagnosis is not always easy and requires the use of CT-guided bone biopsy and imaging technique such as MRI.

#1144 - Case Report

A CASE REPORT ON CHLAMYDIA-INDUCED REACTIVE ARTHRITIS

Ana Maria Baltazar, Vera Costa Santos, Tiago J. F. Branco
Centro Hospitalar Universitário Lisboa Norte, Lisboa, Portugal

Introduction

Reactive arthritis belongs to the spondylarthritides family and it is defined as an arthritis that occurs between days to weeks after a bacterial infection, mostly from gastrointestinal or genito-urinary tract. Urogenital infection by *Chlamydia trachomatis* is the most common aetiology of reactive arthritis. Therapy consists of non-steroidal anti-inflammatory drugs, corticosteroids, and if necessary also disease-modifying drugs, such as sulfasalazine and methotrexate, and antibiotic therapy directed at the origin of the infection.

Case description

A 65-year-old man, with a recent diagnosis of urethritis, to which he had completed therapy with azithromycin, without improvement, and subsequently with doxycycline, with resolution of the symptoms in the previous two months. At that time, with positive serology for *Chlamydia trachomatis*.

Referred to the medicine consultation for generalized joint pain (large and small joints, interphalangeal, knees, ankles) and low back pain, which improved slightly with movements. The patient also reported some night sweats, chills and intestinal transit alterations, with diarrhea (3-4 days a day without blood, mucus or pus). Also to be noted the previous history of self-medication with celecoxib 200mg with some improvement. He denied ocular and neurological changes, allodynia, nausea, vomiting and weight loss. Objective examination without major changes, such as inflammatory signs or joint deformities. A high erythrocyte sedimentation rate (52 mm) and a slightly elevated C-reactive protein (1.34 mg / dL) were observed. Autoimmunity study revealed no changes. The diagnosis of reactive arthritis induced by *Chlamydia trachomatis* was considered.

The patient was then medicated with naproxen 500 mg 12/12h, for two weeks, with resolution of symptoms.

Discussion

Reactive arthritis induced by *Chlamydia trachomatis* continues to be under-diagnosed in Portugal, due to the high rate of remission prior to diagnosis, the high frequency of asymptomatic infections and the lack of specific diagnostic criteria. Non-steroidal anti-inflammatory drugs are the main modality of treatment, since it usually is a self-limiting disease and does not require additional drugs to control inflammation or to prevent joint erosion.

#1147 - Case Report

NOCARDIOSIS: A DIAGNOSIS TO BE CONSIDERED

Eduarda Milheiro Tinoco, Ana Rita Gigante, Carla Ribeiro, Eloísa Silva, Teresa Shiang, Manuela Vanzeller
Centro Hospitalar Vila Nova de Gaia/ Espinho, Gaia, Portugal

Introduction

Nocardiosis is an uncommon and opportunistic infection with the ability to disseminate to virtually any organ. Despite appropriate treatment nocardiosis tends to relapse and progress.

Case description

Male, 73 years old and former smoker. Personal history of small cell lung cancer T3/4N2M0, submitted to sequential chemoradiotherapy completed 1 month before, and HIV (CD4+ 423 cells/ μ L, Viral load 20 copies/ml) under antiretroviral therapy. Patient presented in the ER with persistent fever (maximum 39,1°C) and productive cough. One week before he had been diagnosed with influenzae A infection and treated with levofloxacin and oseltamivir; thorax CT done at that time showed ground glass opacity as a new finding raising also the possibility of radiation pneumonitis. Pulmonary auscultation had audible crackles in the right lung base. Analytically had elevated CRP (27.84mg/dl) and chest x-ray showed a new rounded opacity in the lower third of the right lung field. Patient was admitted for pneumonia and antibiotherapy with piperacillin/ tazobactam was initiated. A new thorax CT revealed a new rounded consolidation in the right lower lobe as well as persistent alterations in the left inferior lobe suggesting radiation pneumonitis. In spite of clinical and analytical improvements, fever persisted with no infectious agent detected. Steroids were initiated considering radiation pneumonitis achieving apyrexia. Few weeks after discharge *Nocardia africana/ nova* was isolated in bronchoalveolar lavage and therapy with cotrimaxazole and ceftriaxone was initiated - the latter altered to linezolid due to toxic hepatitis. Head MRI revealed new lesions but it was impossible to determine its cause - metastatic or infectious. The patient is currently receiving treatment and is progressing favorably. A new head MRI is programmed to evaluate cerebral lesions evolution.

Discussion

Nocardiose is a rare and opportunistic infection that must be considered in immunocompromised patients since it can be the cause of severe and disseminated disease.

#1148 - Medical Image

CERVICAL ABSCESS WITH SEPTIC ARTHRITIS AND PULMONARY EXTENSION

Márcia Machado, Sílvia Nunes, Gonçalo Castelo Branco, Glória Alves, Jorge Cotter

Hospital Senhora da Oliveira, Guimarães, Portugal

Clinical summary

An 86-year-old woman was admitted with a right cervical pain with a 1-week course. The physical exam revealed a febrile patient with a hard lesion on the right sternocleidomastoid muscle. The neck-CT revealed a fluid collection of the sternocleidomastoid, with 8cm of greater extension, inseparable from the sternoclavicular joint, compatible with septic arthritis; also described in the upper right

pulmonary lobe a fluid formation compatible with intrathoracic extension of the inflammatory process. Empirical treatment was initiated with ceftriaxone and vancomycin. An ESBL positive and multiresistant *Escherichia coli* was identified in the blood cultures

demanding antibiotic escalation for meropenem with clinical improvement. The image guided drainage was performed with 4 weeks of antibiotics.

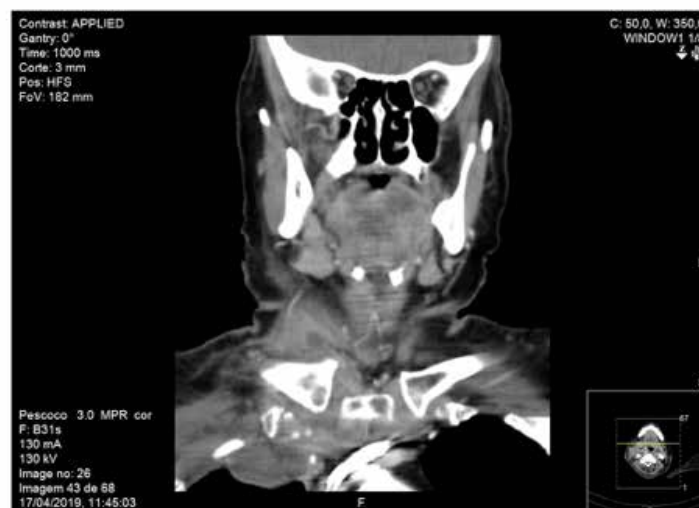
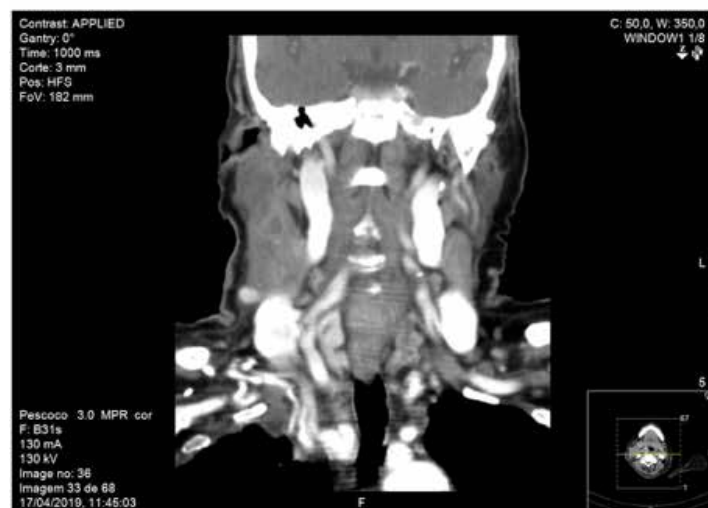
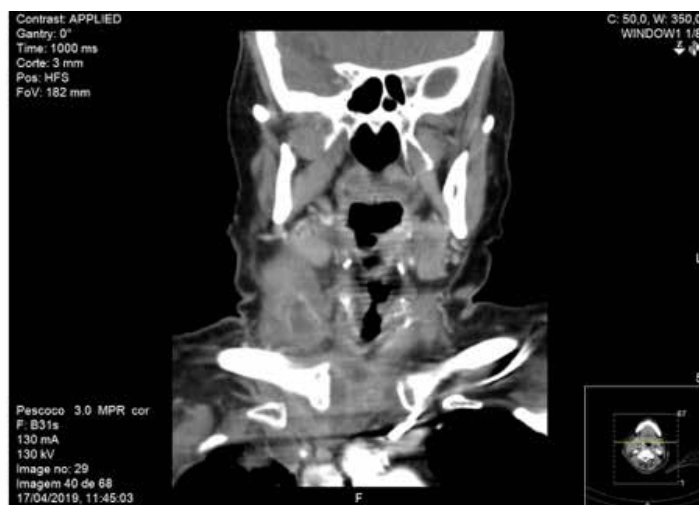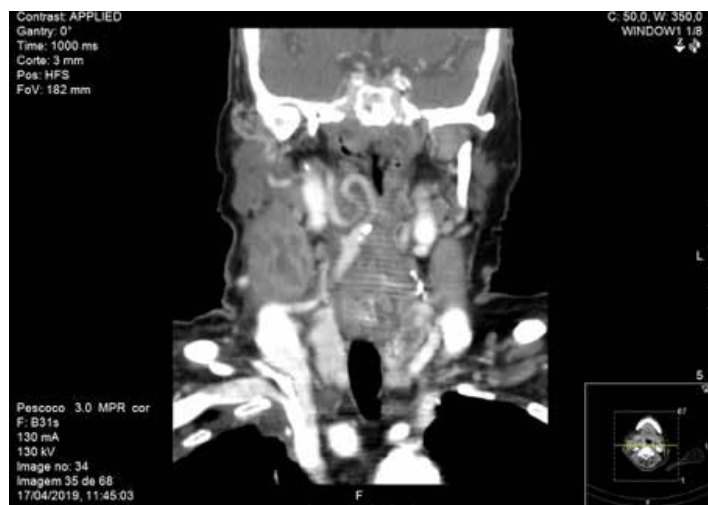Figure #1148.

#1160 - Case Report

NEUROSYPHILIS PRESENTING AS A STROKE MIMIC - THE IMPORTANCE OF DIFFERENTIAL DIAGNOSIS

Mariana Silva Leal, Carolina Amado, Tiago Valente, Marcelo Aveiro, Lorrane Viana, Mariana Sousa
Centro Hospitalar Baixo Vouga, Aveiro, Portugal

Introduction

Neurosyphilis (NS) is an infection of the central nervous system caused by *Treponema pallidum* and can be classified both as precocious and late, characterized by a variable clinical presentation. In an initial approach to the patient, the signs and symptoms can fit into an extensive range of diseases which may difficult its diagnose and make it a challenge. Stroke mimic is a wide-ranging term that encompasses a set of conditions that upon

admission might be confused with acute ischemic stroke, which diagnosis is not confirmed until subsequent study.

Case description

The authors describe the case of a 74 years old male patient, with a medical history of obesity and smoking habits, admitted in emergency department with left temporal headache of moderate intensity with 2-hour evolution and spontaneous resolution, associated with language impairment (naming alteration) that reverted completely as well. He also referred a history of nausea with several months of evolution. Cranioencephalic computed tomography revealed hypodensity in the left corona radiata with short evolution time. A diagnosis of a possible ischemic stroke in the early stage was assumed. In the course of hospitalization, patient has shown occasional dizziness, without recrudescence of other deficits. Cerebral magnetic resonance imaging suggesting

a non-vascular aetiology. Laboratory study showed high serum Venereal Disease Research Laboratory (VDRL) with positive microhemagglutination test for antibodies to *T. pallidum*; HIV and autoimmune study were negative. Lumbar puncture was performed with evidence of protein elevation in cerebrospinal fluid, positive VDRL and Fluorescent treponemal antibody absorption (FTA-ABS). The diagnosis of NS was assumed and treatment was initiated with Penicillin EV.

Discussion

The clinical history and physical examination in the approach of a patient with neurological symptoms are fundamental. However, they do not always help in the immediate definition of a diagnosis, valuing the importance of the study of other pathologies that can mimic stroke. Syphilis is a sexually transmitted infection easily diagnosed and treatable, whose involvement of the central nervous system occurs in a minority of patients, making important to consider and test it in patients with neurological impairment. In this case, although the diagnose of stroke was presumed, its etiological and differential study indicated the presence NS, allowing the direct and correct treatment.

#1161 - Case Report

A SPLENIC ABSCESS WITH UNDERTERMINED ETIOLOGY

Carolina Carrilho Palma, Ricardo Pereira, Inês Costa Santos, Joana Patrício, Ana Catarina Emídio, João Tavares, Beatriz Navarro, Hugo Casimiro, Joana Carreira, Mário Parreira, Ermelinda Pedroso Centro Hospitalar de Setúbal, Hospital de São Bernardo, Setúbal, Portugal

Introduction

Splenic abscesses are rare entities, most commonly seen in immunocompromised patients, usually secondary to hematogenous spread. It is more common in patients who have been diagnosed with endocarditis. However, it is important to consider other pathophysiologic mechanisms, such as contiguous spread (from pancreatic, other retroperitoneal or subphrenic abscesses, gastric or colonic perforations (including diverticulitis), direct trauma, or patients with prior splenic infarction, secondary to systemic disorders (vasculitis, hemoglobinopathies, specially Sickle Cell Disease).

Case description

Hereby we will be presenting a 75 year old male, with a clinical history of uncontrolled Diabetes Mellitus type 2, diabetic nephropathy, arterial hypertension, obstructive sleep apnea and obesity. The patient presented at our medical emergency unit with the following complaints: fever, productive cough and dyspnea. During clinical examination the patient was febrile, pale, sudoretic and presented a systolic heart murmur (unregistered until this time), pulmonary auscultation revealed inspiratory crackles in the right lung and innocent abdominal examination. Laboratory blood tests revealed hypoxemia, marked leukocytosis and neutrophilia,

increased C reactive protein (19 mg/dL) and gamma glutamyl transferase 300 mg/dL. Chest X ray showed a reticulonodular opacity in the right lung. The patient was admitted to the Internal Medicine Department, diagnosed with community acquired pneumonia and medicated with amoxicillin/ clavulanic acid and azithromycin.

However, the patient presented fever (max temp of 40°C) even after completing 48 hours of antibiotics. A transthoracic echocardiogram was performed, showing no signs of endocarditis. Consecutive blood cultures were taken, no pathogens were detected. A CT scan was performed- massive liquid collection, that also contained gas, was found comprising 2/3 of the spleen (12x7.9x10 cm). CT guided percutaneous aspiration was successful and antibiotics were kept for 5 weeks in total (meropenem and clindamycin). Imaging control showed complete resolution of the abscess.

Discussion

Clinical history and physical examination are extremely important for establishing a diagnosis and to understand its possible etiologies. Although this was a successful case, one will never know the etiology of this splenic abscess.

#1173 - Medical Image

A RARE CASE OF SUPERINFECTED PELLAGRA LEADING TO SEPSIS

Jose Claro Rodriguez¹, Jose Ramon Seco Vasco¹, Agueda Romero Bernal², Eva Toro Valiente¹

¹ Sccu Sevilla Sur. Servicio Andaluz De Salud., Sevilla, Spain

² Har Moron De La Frontera. Asbg., Moron De La Frontera, Spain

Clinical summary

Male, 56 years-old, living alone, slight intellectual disability, self neglect, poor nutrition. Low grade fever (37.5°C), hypotensive (67/40 mmHg), and drowsy patient; 10 days with progressive photosensitive dermatitis, evidence of blistering and foul odor purulent secretions in both legs. Culture of exudate: *S. aureus* and *S. dysgalactiae*. Very low blood levels of niacin and thiamine and hypocromic anemia. Successfully treated with usual emergency measures, then adequate nutrition, B vitamin and Fe supplements, IV penicillin, then PO clyndamicin, and topical cures.

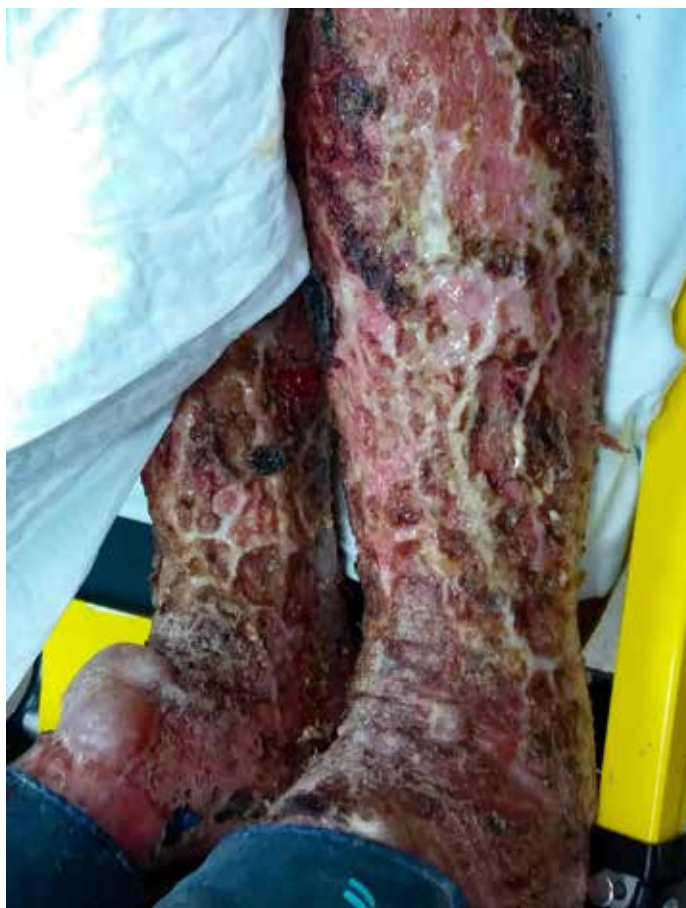

Figure #1173.

#1175 - Case Report

NON-RADIOGRAPHIC PNEUMOCYSTIS PNEUMONIA COMPLICATING LOW-DOSE METHOTREXATE THERAPY IN A PATIENT WITH PSORIATIC ARTHRITIS

Jorge Vaz Lourenço¹, Patricia Carreira², Jose Luis Pablos²

¹ Centro Hospitalar Universitario de Coimbra, Coimbra, Portugal

² Hospital Universitario 12 Octubre, Madrid, Spain

Introduction

Pneumocystis jirovecii (PJ) is an opportunistic pathogen associated with severe acute and subacute infections, mostly pneumonia (PCP) affecting immunocompromised and, in rare cases, immunocompetent patients, the latter considered transiently natural reservoirs. The definite diagnosis of PCP is made through colorimetric or immunofluorescent stains or polymerase chain reaction (PCR) assays. The serum levels of (1-3)- β -D-Glucan (BG) - a common cell wall constituent of most pathogenic fungi - can be measured in order to differentiate colonization from PCP.

Case description

We present a case of a 55-year old woman with a 2 year history of psoriatic arthritis in remission with long-term methotrexate (MTX) therapy 15mg per week, presenting cutaneous and articular manifestations (dactylitis and oligoarthritis of carpal

and metacarpophalangeal joints). She was admitted at the emergency department complaining about a 2-week history of exertional dyspnoea, non-productive cough and high-grade fever (mainly 39°C). There was no prior history of recurrent respiratory infections, sexual risk behaviour, recent travel or contact with animals. The patient was normotensive and febrile (37.8°C) with shortness of breath and persistent cough with no abnormal auscultatory findings; arterial blood gas test confirmed respiratory failure. During hospitalization, the patient presented a normal thoracic x-ray and a CT-scan with discrete signs of centriacinar emphysema with air bronchogram at the right inferior lobe. The blood test results showed no lymphopenia, a CRP elevation (7.15 mg/dl) and increased LDH levels (360 U/L). The direct microscopic examination of sputum was negative, as well as blood cultures, nasopharyngeal swab and serologic assays for H. influenzae, C. pneumoniae and M. pneumoniae. Another sample of sputum was collected for PCR assay, which came positive for PJ and BG were also elevated (249 U/mL), which confirmed PCP. The patient began antibiotic therapy with sulfamethoxazole-trimetoprim, showing significant improvements after the first week of therapy.

Discussion

Some authors estimate that previously colonized patients with rheumatic diseases could develop PCP at least 4 weeks after the beginning of immunosuppressive therapy. Up to 15% of these patients could have significant respiratory symptoms with a normal thoracic x-ray. The nonspecific clinical features of PCP set a significant challenge for early diagnosis, which could partly explain its high mortality rate.

#1176 - Case Report

A COMMON MISTAKE WITH AN UNCOMMON DIAGNOSIS: ENCEPHALITIS BY HUMAN HERPESVIRUS 7 (HHV-7) IN AN IMMUNOCOMPETENT ADULT.

Rui Seixas, João Gamito Lopes, Leonor Gama, Ana Silva, Lucas Ruiz, Armindo Ribeiro, José Sousa E Costa

Unidade Local de Saúde Litoral Alentejano, Santiago Do Cacém, Portugal

Introduction

Acute neurological changes are most often due to an ischemic stroke or intracranial bleeding, however, other diagnosis must be kept in mind, specially if fever is present. An acute encephalitis can be easily mistaken by a stroke and if not treated quickly, can be just as deadly.

Case description

A 77-year-old man, with clinical history of arterial hypertension and dyslipidemia, was admitted in the Emergency Room (ER) due to acute onset of anisocoria and hemiparesis of the right arm. Head computerized tomography (CT) didn't show any lesions and the patient was transferred to the Acute Stroke Unit with the

diagnosis of Minor Ischemic Stroke. Despite treatment the patient did not show any neurological improvement. New head CT and magnetic resonance imaging (MRI) failed to show any ischemic or hemorrhagic lesions. The patient developed fever without any clinical or lab results that could find an infection so a lumbar puncture was made which showed a mononuclear pleocytosis and low glucose. Assuming a diagnosis of either a viral encephalitis or tuberculous meningitis, the patient began treatment with aciclovir 800 mg three times a day and antibacillary drugs however with very little neurological improvement. Analysis of the cerebral spinal fluid (CSF) came negative for almost all neurotropic viruses as well as Mycobacterium tuberculosis but positive for HHV-7. Treatment with aciclovir and antibacillary drugs was interrupted and the patient began treatment with ganciclovir 700 mg/day with great neurological improvement and was transferred to another hospital to an Infectious Diseases Department to continue treatment and monitoring.

Discussion

Cases of acute encephalitis by HHV-7 occur rarely in immunocompetent adults being more commonly present in children or immunocompromised adults. This patient had no history of previous infections and all viral serologies were negative. If untreated an acute encephalitis can have serious consequences so it is important not to misdiagnose these patients with a possible stroke, specially if other symptoms such as fever are present.

#1179 - Case Report

SEPTIC EMBOLISM. CASE REPORT

Juan Carmona García, Ruben Berriel Martín, Lidia Hernanz Roman, María José Redondo Urda, Carlos Hernando Martín, Araceli Sánchez Sánchez, Francisco José Zamudio Moya, Purificación Sanchez Oliva, Igor Andronic Andronic

Hospital Santa Bárbara, Soria, Spain

Introduction

Prosthetic aortic graft infection (PAoGI) is a important complication that accours in 1-1.5% of patients undergoing endovascular repair of an abdominal aortic aneurysm. Its clinical presentation often makes its diagnosis difficult because it can manifest itself in an insidious way.

Case description

We present the case of a 68-year-old man with medical history of hypertension, dyslipidemia, chronic ischemic heart disease and he carries an aortobifemoral prosthesis graft due to spontaneous abdominal aneurysm rupture in 2010. He came to the emergency room due to pain and functional impotence of left lower extremity in last two days without previous trauma, left knee temperature increased and left toes pads skin lesions. His body temperature was 38°C, blood pressure 135/77 mmHg, acceptable general state and peripheral pulses conserved. The blood test included: 17500/ml leukocytes with 85% neutrophils, C- reactive protein

of 250 mg/L and procalcitonin of 5.25 ng/ml. In the blood cultures Streptococcus grew, but wasn't leaked.

As complementary tests, chest radiographs, transthoracic and transesophageal echocardiograms were normal, as well as arthrocentesis, in which no microorganism was isolated.

Finally, a thoraco-abdominal CT was performed in which multiple abscesses were observed, the largest one in the left iliac fossa that included bifemoral prostheses and septic embolism.

With these results, percutaneous drainage of the abscess located in the left iliac fossa was done, and later, a supra-umbilical laparotomy resecting the infected left iliac branch of the endoprosthesis graft, and placing a new dacron one. Moreover, the patient was treated empirically with meropenem and daptomycin since admission.

In the periprosthetic and intraabdominal abscesses cultures, *C. albicans*, *C. glabrata*, *S. constellatus* and *B. thetaiotamicron* grew, so caspofungin was added to the treatment.

Although in the beginning the evolution was torpid with several complications derived from the surgery, acute phase reactants were progressively diminished until antibiotherapy could be de-escalated to continue daily outpatient treatment

Discussion

PAoGI is an uncommon but serious entity, difficult to diagnose and treat. Half of the cases occur between 25 and 70 months after the intervention, so we should suspect it in patients with cardinal symptoms and the presence of polymicrobial bacteremia. The treatment combines intravenous antibiotics and surgery. Mortality is 14% , and the reinfection rate is around 20%.

#1180 - Case Report

HEPATOCELLULAR CARCINOMA WITHOUT ADVANCED LIVER FIBROSIS IN A REINFECTED HCV PATIENT

Domingos Sousa^{1,2}, Sérgio Antunes Silva¹, Rita Martins Fernandes¹, Catarina Jorge¹, Ana Isabel Rodrigues¹, Margarida Viana Coelho¹, Rui Osório¹, Amparo Mingo¹, Elena Rios¹, Armindo Figueiredo¹

¹ Centro Hospitalar Universitário do Algarve, Faro, Portugal

² Faculdade de Ciências da Saúde - Universidade da Beira Interior, Covilhã, Portugal

Introduction

Hepatitis C Virus (HCV) infection is a major cause of chronic liver disease, with approximately 71 million chronically infected individuals worldwide. Clinical care for patients with HCV-related liver disease has advanced over the last years.

The long-term natural history of HCV is highly variable. The hepatic injury can range from minimal histological changes to extensive fibrosis and cirrhosis with or without hepatocellular carcinoma (HCC). Recent case reports point that HCV reinfected patients have higher risk of HCC despite of the liver fibroses stage.

Case description

A 53-year-old man, with a past medical history of HIV1-HCV

coinfection. HCV was treated twice (due to reinfection) and last treatment with direct acting agents (DAAs) achieving sustained virologic response (SVR). Elastography with a METAVIR score F2. HIV suppressed with antiretroviral therapy with a T-cell CD4+ count of 220 cells/micrL.

Patient was admitted to our department with a four-month history of low back pain and a one-month history of jaundice, abdominal distention, abdominal pain, asthenia, anorexia and ascites. Blood tests showed mild cytolysis and total bilirubin 8.7. The abdominal CT-scan described an enlarged liver with lobulated outline. Complete obliteration of the lumen of the portal vein and a hypodense area with hypo-coaptation at segment VII with 45x40 mm. Further studies revealed an alpha-fetoprotein of > 1660 UI/mL.

Patients condition deteriorated leading to dying two weeks later.

Discussion

In patients without cirrhosis who achieve an SVR, HCV infection can be considered definitively cured. Patients with pre-existing cofactors for liver disease (history of excessive alcohol drinking, obesity and/or type 2 diabetes) should be carefully and periodically subjected to a thorough clinical assessment. Only patients with advanced fibrosis (F3) and patients with cirrhosis (F4) who achieve an SVR are recommended to remain under surveillance for HCC every 6 months. Long-term post-SVR follow-up studies showed that the risk of developing HCC remains in patients with cirrhosis who eliminate HCV. Thus, the duration of HCC surveillance in patients with advanced fibrosis or cirrhosis who achieve an SVR is indefinite. International recommendations point that patients with moderate fibrosis (F0-F2), with SVR and no ongoing risk behaviour should be discharged.

This case reinforces the need of regular surveillance of HCV re-infected patients with F2 due to a possible increased risk of evolution to HCC.

#1204 - Case Report

FROM SKIN LESIONS TO THE DIAGNOSIS OF NEUROSYPHILIS

Daniela Neto, Salomé Marques, Marta Cunha, Ana Costa, David Paiva, Cristina Silva, Filipe Gonçalves, Jorge Cotter

Hospital Senhora da Oliveira, Guimarães, Portugal

Introduction

Neurosyphilis refers to the infection of the central nervous system by the agent responsible for syphilis, *Treponema pallidum*, which may occur at any time after infection. This infection may be asymptomatic in the early stages or progress to paralytic dementia or locomotor ataxia if left untreated. The diagnosis is based on the detection of *Treponema* in the liquor by VDRL and the treatment consists of 14 days of intravenous penicillin G.

Case description

41-year-old female, married, with a personal history of anxiety and chronically medicated with alprazolam, who had a 3-month

history of pruritic cutaneous lesions in the trunk, head and limbs (with greater expression in the lower limbs). At the time of the onset of this symptoms she also had red eye and was medicated with brivudine and bilastine. However, due to the maintenance of the symptoms, the patient presented to the ER and was medicated with atropine sulfate and prednisolone in a weaning scheme, and was also oriented to the consultation of Dermatology. At the Dermatology consultation were described scattered rounded maculo-erythematous papules, some of which were desquamative, an analytical study with syphilis screening and viral markers was carried out and a skin biopsy was performed.

After two weeks, lesions similar to the previous described started to appear on the face and neck, and the syphilis screening was positive with subsequent RPR of 1/128. It was clarified the epidemiological context with confirmation of the existence of an extramarital relationship and was confirmed that the patient's legal companion was not infected. At this moment was requested the collaboration of Internal Medicine. A lumbar puncture was performed and the analysis of the cerebrospinal fluid showed no elevation of the liquor protein concentration, with glucose consumption, VDRL was positive and confirmed by WB. A brain CT scan was normal. In this way it was possible to establish the diagnosis of syphilis with asymptomatic neurological involvement, and the patient was admitted to fulfil fourteen days of intravenous penicillin.

The hospitalization was uneventful and the patient was discharged on the 14th day with indication to maintain follow-up in the dermatology consultation and to initiate follow-up in the internal Medicina-Infectious Diseases consultation.

Discussion

With this case we intend to highlight the importance of high clinical suspicion combined with a good clinical history in order to initiate therapy in a timely manner.

#1207 - Abstract

SPONDYLODISCITIS: A 5-YEAR RETROSPECTIVE STUDY OF THE INTERNAL MEDICINE DEPARTMENT OF A TERTIARY HOSPITAL CENTRE

Andreia Amaral¹, Daniela Carneiro¹, Rita Alves², Sofia Mateus¹, Salvador Morais Sarmiento¹, Dina Pita¹, Daniela Marto¹, Ana Brito¹, Hugo Inácio¹, Miguel Sousa Leite¹, Pedro La Féria¹, Marta Moitinho¹, Catarina Espírito Santo¹, Catarina Salvado¹

¹ Centro Hospitalar Universitário de Lisboa Central, Hospital Santo António dos Capuchos, Lisboa, Portugal

² Centro Hospitalar Universitário de Lisboa Central, Hospital Curry Cabral, Lisboa, Portugal

Background

Spondylodiscitis is a disease characterized by infection of the soft tissues of the spinal column with or without neurological compromise. The diagnosis follows a multimodal perspective,

mainly through clinical radiological and microbiological findings. The classical pathogens most frequently responsible for this disease are *S. aureus*, *M. tuberculosis* and *Brucella* spp, however that isn't the case in the latest clinical studies. There seems to be an increased incidence of this condition in recent years and some patients are diagnosed during investigations in Internal Medicine wards. However, there are few to no studies focusing on this specific population, regarding the demographics, risk factors, symptoms, diagnostic method, location of disease, culprit agent, therapeutic strategies and outcome.

Methods

The authors present a 5-year retrospective study conducted by the department of Internal Medicine including all the patients with the diagnosis of spondylodiscitis, accessing the hospital database.

Results

We included a total of 20 patients of which 25% (n=5) had a baseline diagnosis of spondylodiscitis. The mean age was 73 years-old and 65% (n=13) were men. The most reported symptoms were lower back pain in 65% (n=13) and fever in 45% (n=9), followed by neurologic deficits in 35% (n=7). Known risk factors for spondylodiscitis were observed in 90% (n=18) patients. Magnetic resonance imaging was performed in 90% (n= 18) of patients and 55% (n = 11) performed a biopsy. The lumbar spine was the most frequent location (60%, n=14). Of the studied patients, 5% (n=1) had concomitant endocarditis, 10% (n= 2) were diagnosed with meningitis and 35% (n=7) had other complication associated. Pathogens were isolated in 70% (n=14) of cases and methicillin-sensitive *Staphylococcus aureus* was the most frequent organism (30%, n=6). Almost all patients (95%, n=19) received antibiotics and one patient (5%) had a surgical intervention. The average time for hospitalisation was 53 days and the mortality rate was 20% (n=4).

Conclusion

The study shows that these patients had similar characteristics to the population described in other similar studies, including the demographics, risk factors, the microbiological agents identified, the location of the infection and the mortality rate. All these cases presented as diagnostically complex and with challenging treatment approaches, demanding a high level of suspicion and a multidisciplinary team.

#1209 - Case Report

LATE DIAGNOSIS OF HIV FROM A CHEST X-RAY

Bianca Ridaura Aparisi¹, Isabel Moreno Lucente², Vanesa Muñoz Mendoza²

¹ Hospital de Sagunto, Valencia, Spain

² Hospital Obispo Polanco, Teruel, Spain

Introduction

The diagnosis of late HIV infection can lead us to find stages of the disease that involve the development of opportunistic and

neoplastic infections related to lymphocyte CD4 counts below 200/mm³ that without treatment, generally, establish a survival of less than 3 years.

Case description

A 51-year-old male originally from Peru and living in Spain for 12 years. No later trips to tropical areas. Non-insulin-dependent diabetic works as a clinical assistant. History of general deterioration with asthenia and weight loss of about 20kg that began in September 2018, associating a history of retrocardiac pneumonia in January 2019 treated with cephalosporins and maxillary sinusitis in February 2019 treated with quinolones. Currently, he goes to the emergency room for symptoms of malaise with nausea and vomiting together with a 48-hour history of dysthermia.

During admission, an alveolar interstitial pattern was observed on chest X-ray, which suggests that the initial diagnosis is raised: viral pneumonia vs. hypersensitivity pneumonia. Before radiological deterioration, fiberoptic bronchoscopy was requested with positive PCR results for *Pneumocystis Jirovecii*. Upon the suggestion of immunosuppression, viral serologies and lymphocyte populations were tested, which yielded the following results: Western Blot HIV-1 positive, viral load 102,000 copies/ml with CD4 + lymphocytes 27 cells/ul. Double positive lytic serology for anti-*Treponema Pallidum* Reagin (RPR) and serum FTA.

At this time, treatment with intramuscular penicillin, cotrimoxazole and corticosteroid therapy at medium doses is started, after which, finding of oropharyngeal candidiasis and poor metabolic control, which requires adjustment of insulin regimen. It was decided to start antiretroviral treatment at the third week of treatment for *Pneumocystis*.

Discussion

P. Jirovecii is a microorganism that penetrates the human being by respiratory route. Traditionally, it was considered reactivation of endogenous infection in a situation of cellular immunodeficiency with inverse correlation with the degree of immunodeficiency. Currently, several data suggest that the disease is probably due to an exogenous reinfection due to the increase of IgM against *P. Jirovecii* during the disease and the absence of detection of genetic material in highly sensitive techniques (PCR) in lung samples of subjects without disease., who advocate reinfection in situations of immunosuppression as the main mechanism of disease.

#1219 - Case Report

FOCUSING ON NEURO-LYME

Helena Greenfield, Carolina Paiva, Frederico Duarte, José Alberto Lemos, Mariana Taveira

Hospital Pedro Hispano, Matosinhos Local Health Unit, Matosinhos, Portugal

Introduction

Neuro-Lyme is the clinical consequence of central nervous system involvement by the spirochete *Borrelia burgdorferi* and has a very

broad spectrum of symptoms, mostly radicular pain, headache, paresthesia, peripheral facial nerve palsy, meningeal signs but also, ophthalmological disturbances.

Case description

The authors present the case of a 57-year-old male with multiple cardiovascular risk factors and bilateral cataract surgery in the recent past. He sought medical help with complaints of myodesopsia and loss of visual acuity which had started several months previously, denying any other symptoms or relevant epidemiological risk factors. Visual acuity was 7/10 on the right eye, and on the left, 8/10, and there was optic disc paleness and a relative afferent pupillary defect. Visual fields analysis showed a global constriction and bilateral central scotoma. A diagnosis of bilateral optic neuropathy was made and extensive diagnostic search was initially inconclusive (brain imaging, immunological study and viral markers). Borrelia ELISA was performed showing an IgM of 105.7 RU/mL (positive above 22), confirmed by Western-Blot. The patient was diagnosed with Neuro-Lyme and was started on doxycycline, 200mg daily for 14 days. A few weeks after treatment, although maintaining myodesopsia, visual acuity improved (9/10 bilateral) and Borrelia ELISA IgM and Western-Blot were both negative.

Discussion

This case illustrates a rare ophthalmologic manifestation of Lyme disease as well as the high diagnostic suspicion that is necessary for the correct medical and pharmacological orientation of these patients. It is a diagnostic hypothesis that should always be placed on patients at high risk of exposure and living in endemic areas to avoid persistent deficits such as permanent vision loss.

#1228 - Case Report

MYELOYDYSPLASTIC SYNDROME AND PACEMAKER IMPLANTATION: A CASE OF INFECTIVE ENDOCARDITIS

Frederico De Almeida Garrett Soares Da Silva¹, Maria Inês Simões¹, Helena Rita¹, Luisa Arez²

¹ Centro Hospitalar Universitário do Algarve - Unidade de Portimão - Serviço de Medicina 3A, Portimão, Portugal

² Centro Hospitalar Universitário do Algarve - Unidade de Portimão - Serviço de Medicina, Portimão, Portugal

Introduction

Myelodysplastic syndromes are clonal disorders of hematopoietic stem cells and are mostly observed in elderly patients. They are characterized by ineffective hematopoiesis, high risk of progression to acute myeloid leukemia, and linked to a higher risk of severe infections.

Although *Escherichia coli* is among the most common causes of Gram-negative bacteremia, infectious endocarditis (IE) due to this pathogen is rare.

Dermatologic manifestations, such as Osler's nodes and Janeway lesions, are found only in 5-15% of IE patients.

Case description

This case report documents a 79-year old woman, autonomous, with recent implantation of a pacemaker in the context of an AV block, with history of relevant COPD, thyroidectomy, osteoporosis and dyslipidemia.

Admitted through the emergency room complaining of fatigue for progressively minimal exercise in the 3 months. On admission she presented pale skin, anorexia, fever with no other relevant clinical findings. Laboratory tests revealed leukocytosis of 26,000, 193,000 platelets and normocytic and normochromic anemia Hb 9.4 g/dL, and high PCR. The myelogram revealed a myelodysplastic syndrome multilineage.

On the 7th day of hospital stay, purple/brown macules were noticed, some of them painful to touch, all over the toes and soles of both feet, with absence of superficial necrosis, measuring 3.0x5.0 mm, and desquamation, highly suggestive of Janeway lesions and Osler nodules. After few days, two ulcerative lesions appeared on both arms.

Blood cultures were positive for *Escherichia coli* in two peripheral blood samples, as well as a culture from pus material obtained from the arm lesions.

No vegetations or masses were detected by transthoracic/transesophageal echocardiogram or thoracic echography of the PM placement location. These findings were suggestive of Infective Endocarditis (1 major and 4 minor Duke's criteria).

A cycle of antibiotherapy with gentamicin and ceftriaxone was administered with subsequent negative blood cultures, progressive resolution of characteristic skin lesions and decline of inflammatory parameters.

Discussion

This case-report aims to highlight the importance of a thorough differential diagnosis in situations where infection predisposing conditions present simultaneously, such as myelodysplastic syndrome and a recent pacemaker implantation.

#1231 - Case Report

MALARIA A CASE REPORT

Andreia Cinara Branco Diegues, Filipa Rodrigues, Rita Silva, Elisa Tomé, Eugénia Madureira
ULSNE, Bragança, Portugal

Introduction

Malaria is a frequent parasitic infection prevalent in least developed regions of the world, like Africa. It had been identified four human parasitic species, *Plasmodium falciparum*, *P. vivax*, *P. ovale* and *P. malariae*. Malaria is an significant cause of morbidity and mortality, principally the *P. falciparum*. In Europe are almost exclusively in travellers returning from malaria-endemic areas, so the strategies to counteract malaria were very important.

Case description

A caucasian 33-year-old woman, living in Mozambique, that didn't make malaria prophylaxis, with an episode of malaria in the past at 2015, without other medical history, recurred to our emergency department in Portugal complaining of fatigue, fever and abdominal pain for the past 3 days. She returned from Mozambique 4 days before admission to the hospital. At a physical examination, blood pressure was 99/45 mmHg, pulse rate was 77 beats/minute and temperature was 38.8 °C, with abdominal tenderness. Laboratory test results showed haemoglobin 10.2g/dL, leukocyte 2.99×10^9 cells/L, thrombocyte 55×10^9 /L, C-reactive protein 23.58mg/dL, Bilirubin total 2.22mg/dl, direct bilirubin 1.26mg/dL, alkaline phosphatase 146 U/L, alanine transaminase 210 U/L, aspartate transaminase 164 U/L, albumin 2.6 g/dl, total protein 4.7 g/dL and total calcium 7.2mg/dL. Plasmodium LDH/ rapid diagnostic tests revealed positive and peripheral blood smear showed plasmodium infected erythrocytes with a parasitemia index <10%, consistent with malaria. Abdominal ultrasound without abnormalities. Patient was admitted in the medical ICU and started treatment with intravenous quinine and doxycycline. She remained daily monitored, with fever spikes of 38°C at the first three days. Blood count cells and liver enzymes with progressive improvement. On day 5, she was discharged with oral quinine and doxycycline for 10 days. At the three weeks' control without symptoms, anaemia or thrombocytopenia and liver enzymes normalized.

Discussion

Malaria is a potential medical emergency and sometimes it can present as a severe infection as sepsis, like we see in this case, so it should be treated accordingly. Delays in diagnosis and treatment are leading causes of death in many countries. Clinic history of fever and fatigue, travel history to endemic places like eastern Africa and microscopic examination can do the diagnosed earlier. Although none prophylactic regimen may offer complete protection, it is crucial in order to reduce malaria risk and your transmission.

#1233 - Abstract

LOW INCIDENCE BUT HIGH-RISK GROUPS FOR LEPTOSPIROSIS

Ana Teresa Marques Afonso, Néstor Vázquez Agra, Martín Vidal Vázquez, Jonathan Montoya Valdés, Lucía Barrera López, Hadrián Pernas Pardavila, María López Rodríguez, Ariadna Helena Andrade Piña, Emilio Manuel Páez Guillan, Alba García Villafranca, Ignacio Novo Veleiro, Lara Mateo Mosquera, Iván Fernández Castro, Clara Casar Cochetex

Hospital of Santiago de Compostela, Santiago De Compostela, Spain

Background

Leptospirosis is an infectious disease caused by the genus *Leptospira*. It is widespread all over the world, but specially in the tropical regions.

Galicia, autonomous community of Spain, known by the

economic activities of the primary sector, such as cattle farming, slaughterhouse, fishing and agriculture. The percentage of people at risk of developing Leptospirosis is higher than in other regions of Spain. Nevertheless its incidence is smaller compared with the rest of the country (0.27 cases per million and 0.86 cases per million, respectively).

Having this in mind, we decided to investigate the features of this disease in the area of Santiago de Compostela, capital of Galicia.

Methods

Observational, retrospective and descriptive study of patients admitted to the Hospital of Santiago de Compostela with the diagnosis of Leptospirosis from 1990 to 2018. The cases were collected from a codified database provided by the Hospital Admission Service. The medical history was accessed by the electronic medical record database of the health service of Galicia. The epidemiological, clinical, analytic and prognostic data was then analyzed by SPSS.

Results

From 1990 to 2018 there were 8 cases of Leptospirosis in the area of Santiago de Compostela. The accumulated incidence in this area was 0.0018% in 28 years. The average age was 53.25 (sd 11.54). Male was the gender more affected (75%), coinciding with other reports. The distribution of incidence of leptospirosis along the year was more heterogeneous than in other studies. Analyzing the three cases detected after 2015, all the patients lived in a rural area, had several domestic animals and no travel history. One case had a clear contact with rodents. The three cases presented conjunctival suffusion and none had respiratory manifestations. The blood tests showed thrombocytopenia, anemia, elevation of liver enzymes, and hyperbilirubinemia. Regarding the diagnostic tools, most of cases had serological conversion. All patients were treated with Ceftriaxone. No patients died during the hospital stay.

Conclusion

We had demonstrated a low incidence of Leptospirosis in Santiago de Compostela, although its incidence is likely underestimated, as the majority of cases don't need hospital admission and sometimes not even medical assistance. In the other hand, health education and conditions of sanitation may play a role to counter the high occupational exposure to this bacteria. More studies are needed.

#1234 - Case Report

THINK OUTSIDE THE BOX – THINK RAMSAY-HUNT

Daniela Brito, Marta Sousa, Carmen Ferreira, Mario Monteiro, Samba Balde, Fátima Pimenta

Médio Tejo Hospital Center, Abrantes, Portugal

Introduction

Ramsay Hunt Syndrome (RHS) is a rare, severe complication of varicella zoster virus (VZV) reactivation. The presence of otalgia,

ipsilateral peripheral facial paralysis along with vesicles in the auditory canal and auricular pavilion, are its classic syndrome of (RHS). Although the RHS diagnosis is clinical, virological and serological tests to identify the VZV can be performed.

Case description

We report the case of a 62-year-old woman with history of obesity and hypertension. The patient presented to the emergency department (ED) with left hemiface edema and ipsilateral otalgia. At that time, she was diagnosed with a dental abscess and discharged with antibiotics. She returned two days later to the ED with inability to move the left hemiface and to close the left eye. She denied other accompanying symptomatology, namely fever and dental pain. At observation she presented left hemiface edema, left peripheral facial paresis with present Bell sign, vesicles in the left ear canal and palate region. Blood tests and cranioencephalic computed tomography were normal. Due to its clinical value, the diagnosis of RHS was made. The patient started aciclovir and rehabilitation treatment with a good improvement.

Discussion

In the RHS the institution of combined therapy in the first 72 hours of the symptoms resulted in a better prognostic and lower sequelae rate, having a percentage of total healing in 75% of cases. The difficulty in the diagnosis is associated with the common symptoms that are also frequent in other pathologies, therefore a high level of suspicion is needed.

#1240 - Case Report

A NEW CLINICAL TRIAD?

Daniela Brito, Ana Rita Abrantes, Lucília Pessoa, Ana Araujo, Tiago Pereira, Nuno Catorze

Médio Tejo Hospital Center, Abrantes, Portugal

Introduction

Neurological changes such as encephalopathy and neuropathy may correspond to many different pathologies, making it difficult to establish a correct diagnosis. In the elderly the multiple risk factors and comorbidities make the association of these different pathologies possible and their treatment complex.

Case description

70-year-old woman with history of arterial hypertension, ischemic heart disease and degenerative joint disease. Admitted to the emergency room (ER) with decreased muscle strength of the right upper limb with hours of evolution. After examination she was kept under surveillance. She evolved with decreasing consciousness, Glasgow coma scale 3, and was submitted to orotracheal intubation. After admission to the intensive care unit a lumbar puncture and blood tests were performed. Laboratory studies showed a cerebrospinal fluid (CSF) albuminocytologic dissociation; positive CSF and serum anti-Borrelia-burgdorferi antibodies and B12 vitamin deficiency. Antibiotic therapy

with ceftriaxone and B12 vitamin replacement was initiated. The progressive improvement allowed extensive neurological evaluation, revealing multidirectional nystagmus, diplopia in the horizontal gaze to the left, peripheral left facial paresis, weak gag reflex, flaccid tetraparesis and generalized areflexia. Miller Fisher syndrome was suspected. Therapy with immunoglobulin was initiated, but discontinued after one day, because of late initiation and previous improvement of the patient. She was submitted to mechanical ventilation for 9 days. After x days in the ICU she was transferred to Internal Medicina ward. The remaining deficits at time of transfer were peripheral facial paresis, ataxia, and decreased overall muscle strength.

Discussion

Central nervous infection with *Borrelia-burgdorferi* can occur in 15% of the affected patients. Its clinical course is highly variable. This disease is associated with B12 vitamin deficiency and can mimic or even trigger Guillain-Barre Syndrome (GBS). Miller Fisher Syndrome is a rare variant of GBS, characterized by ophthalmoplegia, areflexia and ataxia. Our case suggests that, although rare, this triad can occur.

#1251 - Case Report

HEPATIC FASCIOLIASIS: CASE REPORT

Maria Pacheco, Ana Teresa Moreira, Ivanna Ostapiuk, Adriano Cardoso

Hospital Sousa Martins, Guarda, Portugal

Introduction

Hepatic Fascioliasis is a zoonosis caused by Trematoda Fasciola hepatica. The parasite mainly affects herbivorous animals that feed on or in the vicinity of wetlands. Infection in humans is associated with the ingestion of raw watercress or water contaminated with cercariae. This disease presents a hepatobiliary tropism with a diversified clinical spectrum. Diagnosis clinically based, by the presence of eggs in stools and on immunological tests, and courses characteristically with prolonged fever, weight loss and painful hepatomegaly. At laboratory level, the presence of anemia, eosinophilia, hypoalbuminemia, and increased erythrocyte sedimentation rate (ESR), alkaline phosphatase (ALP) and Gamma-glutamyltransferase (GGT), are frequent. Imaging also plays an important role: the acute phase is characterized by the appearance of nodular liver lesions with hepatic ramifications on computed tomography (CT) scan. Abdominal ultrasound is important in the chronic phase and may show movable vermiform structures in the biliary tract.

Case description

We present a clinical report of an 82-year-old woman that attended to the Emergency Department reporting clinical complaints, with one-month evolution, composed of asthenia, anorexia, occasional nausea and vomiting, weight loss of about 4 kg, sub-febrile/febrile temperature associated with tremors of evening predominance.

In the physical exam, there was evidence of abdominal pain in the epigastric area as well as normocytic normochromic anemia, leukocytosis without eosinophilia, elevation of the ESR, ALP and GGT. The CT scan revealed the presence of a multiloculated liquid collection compatible with a hepatic abscess, also, biliary tract dilatation and bilateral pleural effusion, where present. The patient was admitted to the ward and empirically initiated meropenem, vancomycin and albendazole in single dose. Later, serology for *Faciola* resulted positive and this, associated with poor clinical response to treatment, lead to prescription of triclabendazole, with a remarkable and definitive clinical, serological and imaging improvement.

Discussion

We present a rare but underdiagnosed entity. Our intention is to highlight the importance of the clinical history and the epidemic context in the differential diagnosis of liver lesions. Considering the proven inefficacy of other treatments existing in the literature, triclabendazole is considered the treatment of choice in fascioliasis.

#1255 - Medical Image

A CASE OF LUMBAR PAIN

Magda Joana Garça, Maria Beatriz Santos, Paulo Ávila, Alexandra Freitas

Hospital of the Holy Spirit of Terceira Island, Angra Do Heroísmo, Portugal

Clinical summary

A 63-years-old female patient, with recent hospitalization due to endocarditis and bacteremia to methicillin-resistant *Staphylococcus aureus* (MRSA), starts with fever and intense lumbar pain. Patient was hypotensive, with pain on the palpation of the dorso-lumbar vertebrae, without neurological deficit. Elevated inflammatory parameters and MRSA were observed. Placed hypothesis of spondylodiscitis. CT scan of lumbar spine: osteolysis of D7/D8 vertebrae. MRI lumbar spine: Partial destruction of the vertebral bodies of D7 and D8 with a collection in the anterior slope of the spinal canal that extends significantly up to D11. (Figures 1 and 2). Treated with vancomycin and linezolid for 12 weeks with clinical and imagiological improvement. (Figures 3 and 4).

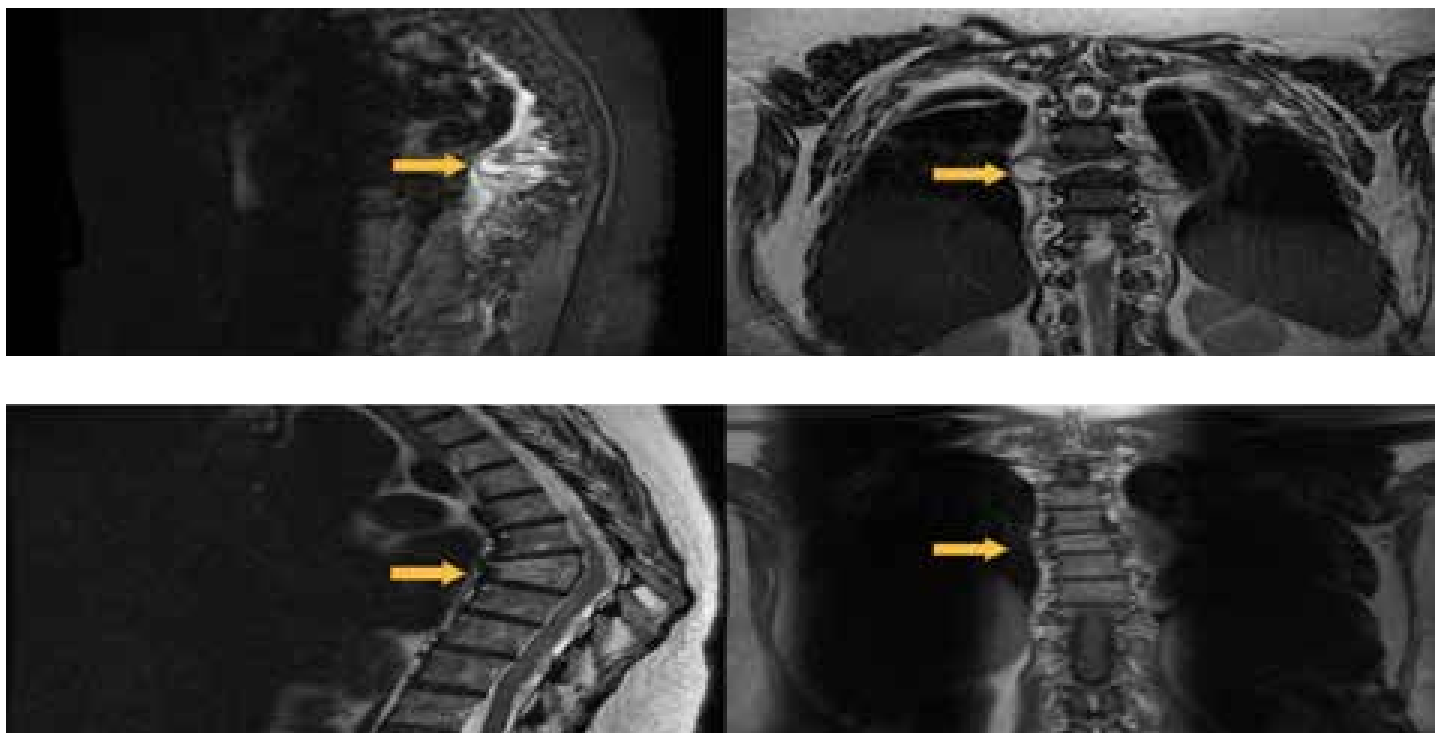


Figure #1255. Spondylodiscitis - temporal evolution in MRI. Panel 1-2: MRI of the spine T2 weighted images. Panel 3-4: MRI of the spine T1 weighted images - 9 months after.

#1265 - Case Report

REACTIVE ARTHRITIS OF AN UNUSUAL CAUSE

Catarina Maciel, Rui Carvalho, Paulo Subtil

Internal Medicine Department from Hospital of Vila Real - CHTMAD, Vila Real, Portugal

Introduction

Reactive arthritis is an inflammation of the joints - usually

asymmetrical and migratory - that occurs between days to weeks after an infection, usually of genitourinary or gastrointestinal (GI) origin.

Case description

The authors present a case of a 40-year-old obese female patient with intrauterine device (IUD), replaced 4 months before, admitted due to fever, subacute diarrhea with onset for 3 months,

and migratory polyarthralgia, with marked functional limitation. The fever was constant, refractory to antiinflammatory and antimicrobial therapy, with 1 month of evolution. We decided to initiate several cycles of broad-spectrum antibiotic therapy, initially, towards GI focus, but we found no clinical or laboratory response, with fevers of 39°C, shivering and marked asthenia, with the patient maintaining migratory polyarthralgia. The GI symptomatology was resolved after initiation of symptomatic treatment. No microbiological isolates were obtained at the level of hemo, uro and coprocultures, serially collected. Given the list of possible differential diagnoses, a diagnostic march was started aiming at infectious, inflammatory, autoimmune, and neoplastic pathologies, with results that became inconclusive/negative. The patient was also observed by Gynecology due to past reference of an abnormal vaginal discharge, but without alterations either at the gynecological examination or at the gynecological ultrasound, with no signs suggestive of local complications.

After a 4-day course of ATB with ciprofloxacin, 11 days of metronidazole, 10 days of ceftriaxone and doxycycline, and 7 days of piperacillin/tazobactam, in subsequent cycles, it was decided to remove the IUD to exclude any foreign body reaction or infectious focus, due to maintenance of febrile syndrome with indeterminate focus, associated with asthenia, polyarthralgia and malaise. Since that moment, we observed a progressive and favorable improvement in both the febrile pattern and the osteoarticular symptomatology, with laboratory recovery to negative C-reactive protein, compared to previous maximum values of 30mg/dL. The IUD was sent to a microbiological study with isolation of MR E. faecium and K.pneumoniae and favorable antimicrobial response after directed treatment.

Discussion

Thus, reactive arthritis was established as secondary to IUD-related infection with causality assumption, since the symptom onset was initiated after approximately 1-2 months of IUD substitution and resolution of those obtained after IUD removal.

#1268 - Case Report

PROLONGED DENGUE FEVER

Kwok Chin Chong, Chaozer Er

Woodlands Health Campus, Singapore, Singapore

Introduction

Dengue virus infection consist of three phases: a febrile phase, a critical phase, and a recovery phase. The febrile phase of dengue fever usually lasts 3-7 days. We hereby present a case of dengue fever with prolonged fever of 2 weeks. (Prolonged fever was defined as fever lasting more than 7 days).

Case description

A 52-year-old Malay gentleman presented to us with 10 days of fever associated with loss of appetite, myalgia and generalised weakness. His dengue NS 1 antigen was positive. He remained

febrile till day 5 of admission. His prolonged dengue fever was associated with severe thrombocytopenia that required platelet transfusion twice during hospitalization, platelet reading was < 10 (172-378 x10⁹/L) on admission.

He also presented with deranged liver function test with Aspartate transferase (AST) >1000 (10-34 U/L) and high creatinine kinase (24-200 U/L).

Further workup to rule out possible causes of fever including other viral fever and intraabdominal collection revealed negative response. Patient's febrile phase ended on day 6 of admission with only symptomatic treatment, accompanied with improvement in platelet count and liver function test.

Discussion

Dengue fever with prolonged fever is known to be associated with more severe disease. Clinical manifestation of dengue fever includes by high grade fever, headache, vomiting, myalgia, arthralgia and a transient macular rash. Warning signs of dengue include persistent vomiting, increasingly severe abdominal pain, tender hepatomegaly, increasing haematocrit level with concurrent rapid decrease in platelet count, development of pleural effusion and/or ascites, mucosal bleeding, lethargy or restlessness.

Prolonged fever has been studied and is associated with various warning signs (mucosal bleeding, anorexia, abdominal pain, nausea or vomit, lethargy, clinical fluid accumulation, hepatomegaly, leukopenia, higher alanine transferase (ALT) and aspartate transferase (AST)) , more severe form of dengue (Dengue Hemorrhagic Fever, Dengue Shock Syndrome, Severe Dengue), and significantly associated with nosocomial infection according to a local study in Singapore in 2016. The presence of prolonged fever in dengue therefore should prompt detailed evaluation for complications of dengue.

#1269 - Medical Image

INFECTIVE ENDOCARDITIS

Kayleigh Huimin Ho

Singapore General Hospital, Singapore, Singapore

Clinical summary

54 year old male with no past medical history presents with 5 days of fever and painful lesions on his hands and feet. He had a tooth extraction 1 month ago.

Examination found early diastolic murmur and multiple tender vasculitic lesions on his hands and feet (Osler nodes).

Infective endocarditis was confirmed with an echocardiography showing multiple mobile vegetations on the aortic valve, complicated by mod-severe aortic regurgitation. Blood culture grew methicillin sensitive staph. aureus. He was treated with IV cloxacillin, ceftriaxone and gentamicin -later switched to IV cloxacillin for 6 weeks. CTS was consulted but decision was made for conservative management as operative risks outweighed the benefits (he was also diagnosed with Child's B cryptogenic liver cirrhosis this admission).

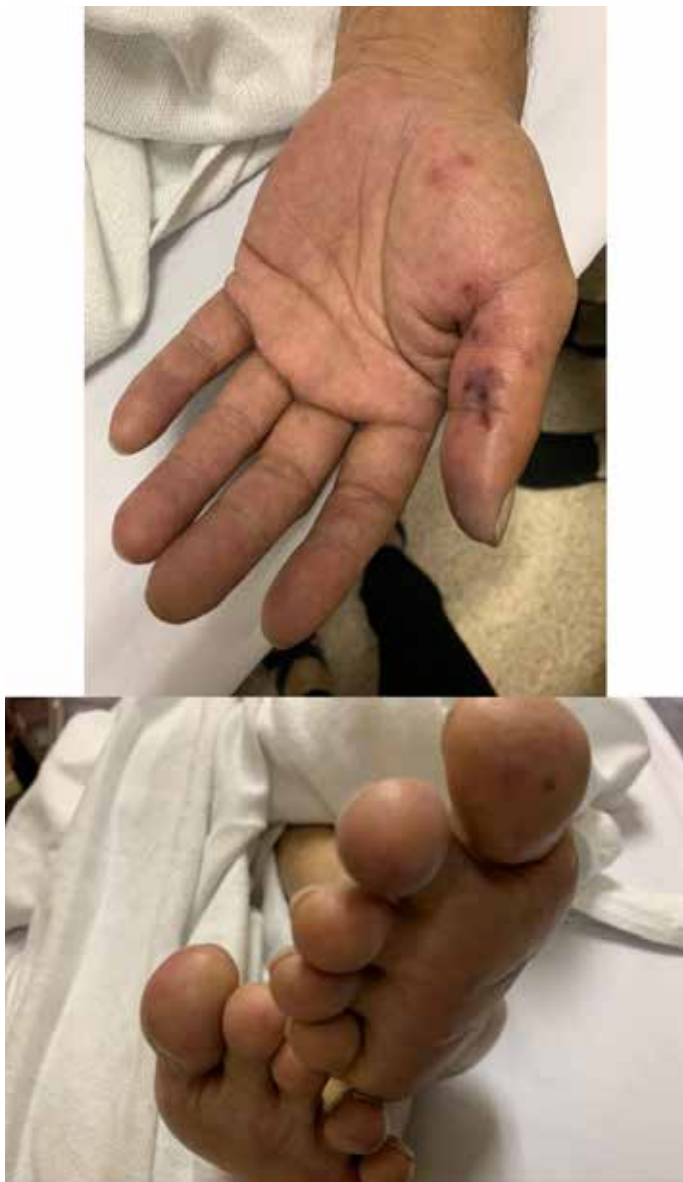

Figure #1269.

#1271 - Abstract

RESPIRATORY VIRAL INFECTIONS IN HOSPITALIZED ADULT PATIENTS: PROSPECTIVE OBSERVATIONAL STUDY

Hatice Bölek¹, Lale Ozisik¹, Zafer Çalışkan², Mine Durusu Tanriover¹

¹ Hacettepe University Faculty of Medicine, Department of Internal Medicine, Ankara, Turkey

² Hacettepe University Faculty of Economics and Administrative Sciences, Department of Economics, Ankara, Turkey

Background

Respiratory viral infections are amongst the most common acute diseases in all ages and are important causes of hospitalization, resource utilization and cost spendings. Influenza and rhinovirus are the most common etiologic factors that result in community acquired pneumonia requiring hospitalization. We aimed to

examine the clinical features and outcomes of hospitalized patients with viral respiratory tract infections.

Methods

Patients hospitalized in internal medicine wards and who had nasal swab sampling for a suspected viral infection were included between 1 August 2018 to 31 March 2019. Real time polymerase chain reaction was utilized to identify the viruses. Patients were followed until discharge or exitus.

Results

Two hundred seventy-six patients were identified who had undergone nasopharyngeal swabbing. Nineteen patients were excluded (due to patient's refusal to participate or inconvenient health status for interview), six patients were still hospitalized. Data of 251 patients were included in the final analysis, 120 patients were infected with at least one viral pathogen. Median age was 63.1 years and length of stay in the hospital was 17 days. Influenza (42%) and rhinovirus (29%) were the most common agents identified, followed by respiratory syncytial virus (12%) and coronavirus (6%). Influenza positive patients presented with a higher rate of dyspnea (72% vs 47%), oxygen demand (70% vs 46%), intensive care hospitalization (17% vs 2%) when compared to other patients with other viruses. 15% of the influenza positive patients had seasonal influenza vaccine in the 2018-19 season. Nine patients (7.5%) with a viral pathogen identified died during the hospital course.

Conclusion

Respiratory viral infections can result in morbidity and mortality in adult patients. In this study, influenza and rhinovirus were the most common pathogens, sometimes as co-pathogens, detected in nasopharyngeal specimens of adult patients who were suspected to have a respiratory viral infection. Patients infected with influenza and with other viruses were similar in terms of demographic features and co-morbid diseases. However, influenza-positive patients were more likely to be admitted to intensive care and require oxygen treatment. Although influenza vaccination is a safe and effective option to prevent influenza infection, 15% of the patients acquired the infection despite getting the vaccine in the particular season.

#1275 - Medical Image

CYSTICERCOSIS

Joana Liz Pimenta, Patrícia Liz Chow Liu, Emanuel Cadavez, António Trigo Faria

Centro Hospitalar de Trás-os-Montes e Alto Douro, Vila Real, Portugal

Clinical summary

A 99-year-old male was admitted to Emergency department due to dyspnoea. As part of the exam an X-Ray was performed, showing pulmonary consolidation, pleural effusion and numerous muscular calcifications. The patient was admitted by Internal Medicine with

acute decompensated heart failure due to community acquired pneumonia. Neurologic symptoms and muscular pain were absent. The patient referred pig breeding when younger. After 13 days, patient was discharged in his baseline status, without any specific treatment to cysticercosis.

Following the ingestion of *Taenia solium* it disseminates to brain and/or extraneural sites. Intramuscular cysts that underwent calcification may be identified in radiographic imaging. Asymptomatic nonviable phase does not require treatment.

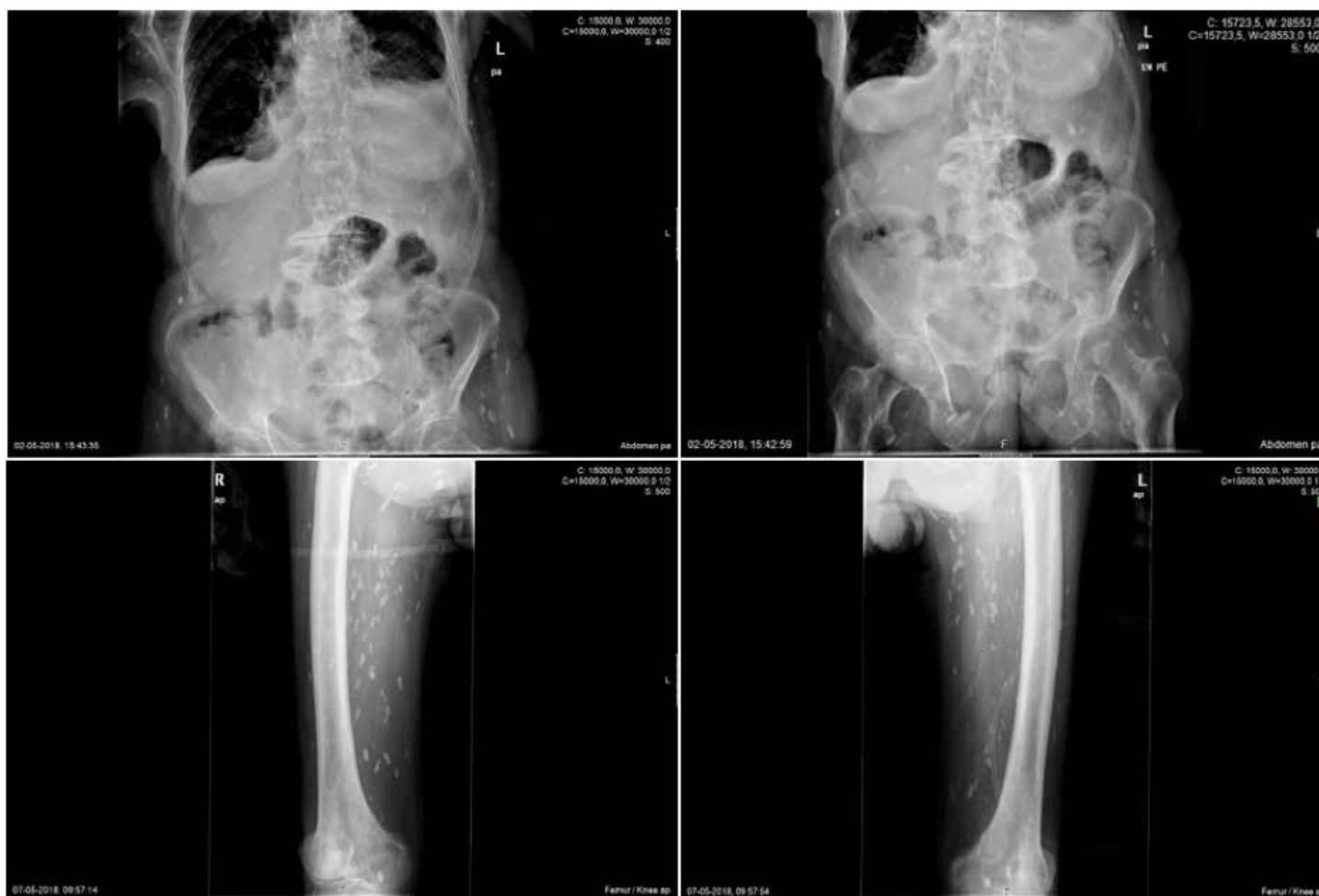

Figure #1275.

#1301 - Case Report

EXTRAPULMONARY MANIFESTATION AS INITIAL PRESENTATION OF ATYPICAL PNEUMONIA

Carina De Sousa, Andrea Silva, Sara Sintra, Adélia Simão, Armando Carvalho

Coimbra Hospital and University Centre, Coimbra, Portugal

Introduction

Mycoplasma pneumoniae (MP) is a major cause of respiratory infection in children and is reported in up to 10% of adults with pneumonia. Extrapulmonary manifestations in adults are rare and include hemolysis, central nervous system disease, dermatitis, carditis, joint and gastrointestinal disease.

Case description

We present a case of a 47-year-old man who was admitted

with a 2-week history of high-grade fever, nausea, self-limited non-bloody diarrhea and upper right abdominal colic without irradiation. He denied respiratory or genitourinary symptoms, recent travels or previous contact with infectious diseases. Past medical history included arterial hypertension, type 2 diabetes mellitus, dyslipidemia and class I obesity. At the admission he was febrile (39.2°C), complaining of upper right abdominal pain on palpation with an enlarged liver about 5cm below the costal margin; the rest of the exam was unremarkable. Abnormal laboratory findings on admission included hypokalaemia 2.8mmol/L (normal range, 3.5-5.1 mmol/L), alanine aminotransferase 301U/L (normal range, <45U/L), aspartate aminotransferase 160U/L (normal range, <35U/L), gamma-glutamyl-transferase 606U/L (normal range, <55U/L), alkaline phosphatase 481U/L (normal range, 30-120U/L), C-reactive protein 18.73mg/dL (normal range, <0.5mg/dL). Abdominal sonography revealed hepatomegaly with steatosis. Hepatitis A, B, C serologies were negative as well as

herpes simplex virus, cytomegalovirus, Epstein-Barr virus and leptospira. Alcoholic or drug-induced liver injury was not probable due to absence of risk factors. Anti-nuclear, antimitochondrial and anti-smooth-muscle antibodies were negative. On the third day the patient developed irritative, nonproductive cough with bibasilar rales on auscultation. Chest radiograph showed bibasilar nodular opacities. A quinolone-based regimen was initiated in the emergency department. However, the patient remained febrile. Further serologic workup revealed acute MP infection. Antibiotic therapy was then switched to doxycycline, which resulted in a rapid clinical and laboratorial improvement.

Discussion

This case illustrates the importance of extrapulmonary manifestation as first presentation of atypical pneumonia even in adults. First-line treatment options include macrolides, tetracyclines and respiratory quinolones. As there was no response to the latter, a potential quinolone MP resistant isolate, not described to date, should be considered.

#1309 - Case Report

TUBERCULOUS MENINGITIS: ABOUT A CASE

Miguel Alexandre Alves¹, Anabela Mesquita², Luis Ribeiro², António Maia Gonçalves², Dina Leal², Ricardo Alves², Luís Lencastre²

¹ ULS Nordeste, Bragança, Portugal

² Hospital de Braga, Braga, Portugal

Introduction

Tuberculous meningitis (TM) is the most serious form of infection of *Mycobacterium tuberculosis*, although it is not a contagious form, it presents neurological sequelae in more than 50% and a high mortality rate. It is developed in two stages. First, the bacilli enter the host by droplet inhalation, initiating an infectious pulmonary process with lymphatic spread, reaching the meninges and brain via the lymphohematogenous route. Second there is the rupture of small tubers in the subarachnoid space, which are implanted in the brain and meninges, accompanying respiratory primoinfection.

Case description

A 55 year-old woman, autonomous, with no pathological history, was brought Emergency Department (ED) due to behavioral change, fever, prostration and progressive deterioration with two weeks evolution. In ED, presented a depression of the state of consciousness, anisocoria E> D, requirement of invasive ventilation, remaining hemodynamically stable. Performed CT Cerebral revealed a Supratentorial Ventriculomegaly with need of external ventricular derivation (EVD) and Thoraco-Abdomino-Pelvic CT with extensive micronodular pattern in the upper and middle lobes with nodular areas and parenchymal infiltrate suggestive of miliar tuberculosis. Placed EVD and sample of spinal head fluid (SHF) that was normal. Admitted to the ICU. Made

hemocultures and bronchial aspirate and starting Ceftriaxone (suspended at day 5) and isoniazid, rifampicin, pyrazinamide and ethambutol. Analytically, with leukocytosis, neutrophilia, high c-reactive protein. Serologies and immunological study turned out to be negative. Performed Fibrobronchoscopy with bronchoalveolar lavage objectified ziehl neelsen positive, cultural positive and PCR screening detection for mycobacterium tuberculosis. Was repeated lumbar puncture, SHF with PCR negative for mycobacteria. She remained with the same neurological state, requiring invasive ventilation and aminergic support due to hemodynamic instability. Two weeks later the patient eventually passing away.

Discussion

TM is a rare form of extrapulmonary tuberculosis. The disease develops slowly, and is difficult to diagnose, because it does not manifest itself initially with characteristic symptoms. The condition of the patient deteriorated significantly with the emergence of subsequent symptoms proving the progression of the disease, and the prognosis for total recovery, without significant neurological deficits depended on the time of antituberculous treatment implementation.

#1320 - Case Report

A NEW TREND IN HEPATITIS A TRANSMISSION IN JAPAN: A SUDDEN INCREASE IN INFECTION RATES AMONGST MEN WHO HAVE SEX WITH MEN

Mari Fujisawa, Ivor Cammack

Teine Keijinkai Hospital, Sapporo, Japan

Introduction

Hepatitis A Virus (HAV) is transmitted primarily by the faecal-oral route through contaminated food, especially clams in Japan, and water or through direct contact with an infectious person. In Japan, contaminated food was the most common cause, but in 2018 this trend changed and more cases were connected to men who have sex with men (MSM). We describe a male patient who was infected with HAV by contact with a male sex worker.

Case description

A healthy 27-year-old Japanese man presented to the internal medicine department with a 1-week history of malaise, fatigue and anorexia. The patient reported oral sex with a male sex worker 2 weeks prior to onset of symptoms. He denied eating clams or wild game. He has not traveled overseas recently.

On examination, he appeared well and his vital signs were normal. Abdominal examination revealed splenomegaly but there was no hepatomegaly.

Laboratory results showed elevated AST (487 U/L) and ALT (1,000 U/L) but other liver function tests (albumin 47 g/L, bilirubin 1.4 mg/dL) were normal.

Viral hepatitis screen showed anti-HAV IgM antibody and anti-

HAV IgG antibody positive, and the final diagnosis was acute Hepatitis A.

Hepatitis A is a notifiable disease in Japan, but in this case we were unable to complete contact tracing. The patient was admitted for observation and recovered with supportive therapy.

Discussion

MSM are a high-risk group for HAV infection, with recent reported outbreaks among MSM in Europe and in America, areas with traditionally low endemicity. In 2017, the WHO placed an alert on Hepatitis A outbreaks among MSM. High endemic areas such as Africa and parts of South Asia tend not to have outbreaks because of high levels of population immunity. On the other hand, low endemic countries such as Japan, where over 98% of people under 50 years old are HAV antibody negative, have higher outbreak potential. Between 2011 and 2017, the incidence of infection was between 100 and 300 cases. Then, in 2018, there was a sudden spike with 925 reported cases, predominantly in urban Tokyo and Osaka.

In addition, sexual contact has suddenly become the predominant route of transmission from 2018, particularly in the MSM community. Between 2015 to 2017, sexual transmission explained only 4% of cases, whereas in 2018 that ratio had increased to 51%. Furthermore, only 17 cases in total between 2015-2017 were reported in the MSM population, but this figure skyrocketed to 364 cases in 2018.

#1337 - Case Report

A 26-YEAR-OLD MAN PRESENTING FEVER, COUGH AND NIGHT SWEATS.

Elena Del Carmen Martínez Cánovas¹, María Jesús Avilés Inglés¹, Mónica Martínez Martínez¹, Francisco Javier Hernández Felices¹, Vicente David De La Rosa Valero¹, Ana Martín Cascón¹, Ignacio Iniesta-Pino Alcázar¹, María Carmen Hernández Murciano¹, Sergio Pastor Marín¹, Caridad Beatriz Martínez Cánovas¹, Indra Martínez Hernández², Rosalía Vázquez Vicente², Ángela Santo Manres¹, Victoria Callejo Hurtado¹, María Josefa Martínez Cánovas¹, Carlota Royo-Villanova Reparaz¹, María Carmen Vera Sánchez-Rojas¹, Lia Ferraro¹, Emma Muñoz Pérez¹

¹ Hospital General Universitario Reina Sofía, Murcia, Spain

² Hospital Universitario Virgen de la Arrixaca, Murcia, Spain

Introduction

Mycobacterium tuberculosis infects one third of the world's population and causes nine million new cases of tuberculosis (TB) and approximately two million deaths each year. Infection is more likely to produce disease in infancy, ages 15 to 25 and old age. AIDs, malnutrition, renal failure and immunosuppression favor progression of infection to active disease. That is why screening for latent TB infection must be tested in patients immunosuppressive therapy.

Case description

We present the case of a 26-year-old man with history of inflammatory bowel disease treated with adalimumab (previously

azathioprine produced bone marrow suppression). The patient was admitted to our hospital referring cough, high fever and night sweats for two weeks. Physical examination revealed crackles in left hemithorax and several cervical adenopathies. Despite the start of a Fluoroquinolone, fever was maintained for the following week. CT showed alveolar infiltrate in left lung, especially in lingula. As there were not any microbiological finds, bronchoscopy and culture of bronchoalveolar lavage was practiced, being positive for Mycobacterium tuberculosis. Treatment with Isoniazid, Rifampin, Ethambutol and Pyrazinamide was started. Nowadays, after two months, the patient presents two cervical necrotic adenopathies but good general condition and ustekinumab will be started soon.

Discussion

Tumor necrosis factor alpha inhibitors (TNF-alpha inhibitors) increase the risk of TB and nontuberculous mycobacterial infections, particularly involving extrapulmonary sites and usually disseminated disease at presentation. All patients being considered for TNF-alpha inhibitor therapy should be screened for latent tuberculosis infection. Appropriate screening includes a careful history focused on epidemiologic risk factors for prior TB exposure, physical examination, the use of screening tests such as the tuberculin skin test or interferon-gamma release assay (IGRA), and a chest radiograph in those with a positive TST or IGRA or a history or physical exam suggestive of TB. Anti-TNF-alpha therapy should be discontinued in patients who develop active TB at least until clinical improvement has been achieved.

In our patients, tuberculin skin test was performed, but it was a false-negative test. One to four weeks later, a second tuberculin test ("booster") could have been ruled out or IGRA, in order to discard anergy.

#1353 - Case Report

ALVEOLAR HAEMORRHAGE DUE TO WEIL'S DISEASE TREATED WITH STEROIDS

Georgios-Charis Paskalis, Christina-Chrysanthi Theocharidou, Christina Kotsiari, Lazaros Sideras, Vasiliki Tsoutsouli, Zacharo Sachla, Konstantinos Gkogkos

Internal Medicine Clinic of G.Papanikolaou General Hospital, Thessaloniki, Greece

Introduction

Weil's disease is the most severe form of leptospirosis, with jaundice, acute renal injury and bleeding disorders as main manifestations. The disease has worldwide distribution and is associated with exposure to contaminated water, animals and farming works. We present a rare case of alveolar haemorrhage, with quick improvement after steroid administration.

Case description

Sixty-five year old male, working as a breeder in the fur industry, presented with high fever, jaundice and muscle pain for three days. His laboratory blood tests revealed anemia, low platelets, acute

renal injury, high liver enzymes and direct bilirubin. Due to possible occupational exposure to rodents, leptospira infection was suspected and confirmed by serologic tests. Despite the antibiotic treatment, he progressively developed dyspnoea, haemoptysis and respiratory failure. A CT scan was performed and confirmed diffuse alveolar haemorrhage. Along with supportive measures, prednisolone 1 mg/kg per day was administered, divided in three doses. Platelets normalized rapidly and the patient showed gradual clinical and radiological stabilization. He was discharged 8 days later with normal laboratory tests, chest x-ray and no need for further supplementary oxygen treatment. Instructions were given for quick tapering of prednisolone and follow-up visits.

Discussion

Weil's disease has variable severity, mainly depending on which systems are affected. Alveolar haemorrhage is the most life-threatening complication; nevertheless, there are not any specific treatment guidelines. Pulses of methylprednisolone have been used. We hereby present a case with excellent response to a different corticosteroid regimen. Definite answers about the optimal treatment could be given only by randomized studies.

#1370 - Case Report

PARVOVIRUS B19 INFECTION PRESENTED AS FEVER OF UNDETERMINED ORIGIN WITH POLYSEROSITIS, MYOPERICARDITIS AND AORTITIS.

Dúlio Teixeira Passos¹, Ana Cardoso¹, Vilma Salgado¹, Nuno Jacinto¹, Paula Rocha^{1,2}, João Meneses Santos^{1,2}, Rui M. M. Victorino^{1,2}

¹ Department of Internal Medicine II, North Lisbon University Hospital Center - Santa Maria Hospital, Lisbon, Portugal

² Medicine II University Clinic, Faculty of Medicine - University of Lisbon, Lisbon, Portugal

Introduction

There is a wide spectrum of clinical findings in immunocompetent patients with parvovirus B19 (B19) infection. Approximately 25% of infected individuals will be completely asymptomatic, while 50% will have only non-specific flu-like symptoms. The remaining 25% of infected individuals present with the two classic syndromes, rash of erythema infectiosum and/or arthralgias. B19 infection has also been reported in association with a wide range of diseases and clinical manifestations including with polyserositis, myocarditis, vasculitis as well as many other conditions.

Case description

A 73-year-old woman with chronic gastritis and incipient dementia was admitted due to an episode of self-limited asthenia, anorexia, headache and fever for the last month. Upon objective examination, she was febrile with only slight crackling at pulmonary auscultation. Her blood tests revealed: a normochromic normocytic anemia, C-reactive protein 5.6 mg/dL and a mild elevation of GGT 54

U/L and LDH 402 U/L. Ultrasonography showed homogenous hepatomegaly. Undetermined febrile syndrome was admitted. Further etiological investigation showed positive IgM antibody and a negative IgG antibody for B19. The remaining viral, bacterial and mycobacterial serologies were negative. Autoimmune, neoplastic and primary immunodeficiencies were also excluded. However, thoraco-abdominal-pelvic computer tomography showed a moderate pleural and pericardial effusion, a small peritoneal effusion and thickening of the wall of the thoracic and abdominal aorta arteries. Transthoracic echocardiography showed systolic collapse of the right atrium, increased filling pressures and pericardial mass compatible with fibrin. Pericardiocentesis was performed with drainage of 450 mL of sero-hematic fluid with exudate characteristics with negative viral, bacteriological and mycobacteriological serologies. Neither EKG changes nor elevation of myocardial necrosis markers was recorded, but an episode of extreme bradycardia with junctional rhythm, required placement of a definitive pacemaker. Polyserositis, myopericarditis and aortitis in the context of B19 infection was diagnosed and the patient recovered under supportive treatment. During follow-up, B19 IgM turned negative and IgG positive.

Discussion

Poliserositis, myopericarditis and aortitis should be considered as a possible complication of B19 infection in immunocompetent patients and the serology for B19 should be included in the workout of such cases.

#1374 - Abstract

INFECTIONS TRENDS ON AN INTERNAL MEDICINE WARD: A 3-YEAR CROSS-SECTIONAL STUDY

Inês Rego De Figueiredo, Anna Taulaigo, Rita Vieira Alves, Madalena Vicente, Mário Ferraz, André Dias, Marta Leal Santos, Sara Guerreiro Castro, Ana Margarida Antunes, Cláudia Míhon, Ana Iladó, Heidi Gruner, António Panarra

Hospital Curry Cabral, Centro Hospitalar Universitário Lisboa Central, Lisboa, Portugal

Background

Infectious diseases often warrant decompensation of chronic pathologies and/or are facilitated by the same. The purpose of this work is to characterize infections in patients admitted in Internal Medicine Wards over a 3-year period.

Methods

A cross-sectional study by retrospective electronic medical record revision of patients admitted to an internal medicine ward with an infectious diagnosis was performed over a 3-year period. Data collected was both demographic and regarding the characteristics of the infection. A comparison over the 3 years was performed to ascertain for any trend.

Results

A total of 1501 patients fulfilled the inclusion criteria. There was a slight male preponderance (52%), with an average age of 77 years. Hospitalization time was an average 11,6 days and Charleston index was 5.9, with a nearly significant decrease over the 3 years (from 6 to 5.9; p-value=0,05).

The main diagnosis were respiratory (55% - pneumonia 38.8% and bronchitis 16.5%) and urinary (32% - cystitis 17.8% and pyelonephritis 13.6%). However, over the 3-year period there was a significant decrease in respiratory diagnosis (61% vs 54%) and increase in urinary (26% vs 30.4%) (p-value=0.006 for diagnostic category, <0.001 for diagnosis).

Considering the microbiological agents, there was a significant increase in isolation with 76.9% versus no isolation in 2012 and 60.8% in 2014 (p-value <0.001). The most common agents were: *Escherichia coli* (31.4%), as well as 8% of Extended-spectrum beta-lactamase *E. coli*, with a significant increase over the 3 years (0.8% vs 13%). Overall mortality was 12%.

Conclusion

Despite patient features being relatively stable, the characteristics of their infections changed. Even with a small time frame, there was a decrease in respiratory infections, with an increase in urinary. Microbiologic isolation yield is improving, which is extremely important in directing antibiotics therapy. More aggressive agents are being isolated as well.

#1385 - Abstract

REAL-TIME BODY TEMPERATURE MONITORING: DESCRIPTION OF THE PROCEDURE AND PRELIMINARY RESULTS ON FEVER DETECTION.

Borja Vargas¹, Paula González¹, María José Fernández-Cotarelo¹, Óscar Vázquez¹, Luis Vigil¹, David Cuesta-Frau², Manuel Varela¹

¹ Hospital Universitario de Móstoles, Móstoles, Spain

² Universitat Politecnica de Valencia, Alcoi, Spain

Background

Several biological signals are monitored in real time in the clinical practice to get tight control of patient status and to improve clinical decision making. Body temperature monitoring could be useful to control fever with precision and to identify some peaks that might be overlooked by standard measurements. In this work, we describe a procedure to perform real-time monitoring of body temperature and display the results of preliminary tests on several cases to check the feasibility of its application.

Methods

Patients are monitored with a tympanic temperature probe placed on the external auditory canal (EAC) and a cutaneous temperature probe placed over the skin of the forearm. Both probes are connected to a Holter device that processes both signals and sends them via Bluetooth to a computer. Data are

analyzed by a specific program and an alarm is sent by e-mail when a temperature threshold is exceeded.

A post hoc analysis has been performed to series in which at least a fever peak was identified (defined as at least one measurement of temperature above or equal to 38°C), applying a logistic model to evaluate if those peaks could have been predicted in real-time.

Results

Fourteen patients have been monitored with this system. In 3 cases, higher temperature values were obtained during the time of surveillance than with standard measurements by infrared thermometers, with differences ranging between 0.33 and 1.21°C. In other three cases, temperature values were similar to those registered with standard measurements (differences were smaller than 0.3°C).

In four cases, temperature measurements had to be adjusted with a correction factor because misplacement of the EAC probe, but the monitoring was correct.

In other four cases, we had trouble placing the EAC probe, frequent disconnections of the probe occurred or the transmission of data between the device and the computer was not reliable, making these cases not suitable for analysis.

When a predictive model for fever detection was applied to those time series with fever, 7 fever peaks were foreseen within an interval between 10 and 60 minutes, and only 1 peak could not be predicted.

Conclusion

Continuous body temperature monitoring seems to be useful in patients with confirmed or suspected infectious diseases, since it may provide information about the presence of fever and help to anticipate fever spikes.

#1391 - Case Report

DISSEMINATED TUBERCULOSIS (NEUROLOGICAL, SPONDYLODISCEITIS, PULMONARY) - CLINICAL CASE

Hilda Freitas¹, Natalia Oliveira¹, Antonio Cabral¹, Paulo Ferreira², Vanessa Machado², Cristina Ramalho²

¹ TrofaSaude Hospital Braga Sul, Braga, Portugal

² TrofaSaude Hospital Braga Centro, Braga, Portugal

Introduction

Miliary tuberculosis (TB) refers to clinical disease that results from the hematogenous dissemination of *Mycobacterium tuberculosis*; can arise as a result of progressive primary infection or via reactivation of a previously contained latent focus with subsequent spread. Latent foci can reactivate at any time after the primary infection.

Case description

The authors describe a clinical case of 86 years old women, autonomous, with a medical history of Diabetes, Heart Failure

and Atrial Fibrillation. She had hospitalization 3 months before for urosepsis, with associated spondylodiscitis. She underwent treatment with improvement. She presented a constitutional framework prolonged from a year before, with progressive deterioration of the general state, lombar pain aggravated and progressive readiness from the previous month. With intermittent fever. She went to the Emergency Department for prostration, decreased muscle strength in both lower limbs and slower voice with 5 days of evolution, with evolution to dysarthria. Computed tomography angiography of Brain and Echocardiogram without important changes. We found pulmonary diffuse micronodular pattern at chest x-ray. Magnetic Resonance Imaging of the Lumbar Spine: "Spondylodiscitis recurrence?". IGRA positive. The family refused to perform invasive techniques. It was decided to initiate a trial with tuberculostatic therapeutic. Was discharge wandering autonomously. Cultural examinations were negative. Later, she had toxicodermia; it was necessary to adjust bacillary therapy. She kept follow-up in the Internal Medicine consultation.

Discussion

The authors intend with this case to show the challenge that tuberculosis can represent, showing the case of a patient accompanied by us for more than 1 year, needing several hospitalizations. On one hand there was the prolonged time of disease evolution, masked, on the other hand there was the polymedication of the patient associated with age. The appearance of complications made the necessity of a constant and tight vigilance of the patient, frequent therapeutic adjustments, and a desirable multidisciplinary mutual support between Internal Medicine, Infeciology and Dermatology, which occurred, certainly contributing to the favorable clinical response that the patient presented, nevertheless all adversities.

#1392 - Case Report

BRANCH RETINAL ARTERY OCCLUSION AS MANIFESTATION OF CAT-SCRATCH DISEASE

Ana Cardoso¹, Vilma Salgado¹, Dúlio Teixeira Passos¹, Nuno Jacinto¹, Inês Leal², João Meneses Santos^{1,3}, Rui M. M. Victorino^{1,3}

¹ Department of Internal Medicine II, North Lisbon University Hospital Center - Santa Maria Hospital, Lisbon, Portugal

² Department of Ophthalmology, North Lisbon University Hospital Center - Santa Maria Hospital, Lisbon, Portugal

³ Medicine II University Clinic, Faculty of Medicine - University of Lisbon, Lisbon, Portugal

Introduction

Cat-scratch disease (CSD) is a systemic disease caused by the Gram-negative bacillus *Bartonella henselae*. The most common manifestation is the papulo-erythematous reaction at the site of inoculation with regional lymphadenopathy and flu-like symptoms. Dissemination may occur, with ocular or hepatosplenic involvement, encephalitis, pneumonia or osteomyelitis. Although neuroretinitis is a frequent ocular manifestation, branch retinal

artery occlusion (BRAO) is still uncommon and poorly described in literature.

Case description

A 36-year-old man with no prior medical history was admitted with a central scotoma in his left eye. In the previous month, the patient had complaints of intermittent fever and myalgias. No epidemiological context was present apart from a pet cat. Medical examination revealed skin scratch lesions without inflammatory signs and the ophthalmoscopic exam found a pale lesion of the left optic disc. The results of laboratory tests revealed normal white blood cell count, erythrocyte sedimentation rate of 76 mm/h, and C-reactive protein of 6.04 mg/dL. Brain and orbit computer tomography were reported unaltered. A fluorescein angiography revealed BRAO. Due to suspicion of infectious disease, serological tests for infectious agents, interferon gamma release assay and blood cultures were performed, all negative but *Bartonella henselae* with a IgG titer 1/256. Other causes for this clinical condition were excluded such as infective endocarditis or atrial myxoma, with a normal echocardiogram. Primary vasculitis was also excluded with negative autoimmune serologies and normal arterial doppler ultrasound. Primary prothrombotic disorders were also excluded. When faced with the diagnosis of CSD with ocular manifestation, the patient underwent a treatment with doxycycline with favorable clinical evolution apart from the established ophthalmologic manifestation. The pet cat was diagnosed with feline bartonellosis by polymerase chain reaction method and also underwent antimicrobial therapy.

Discussion

Bartonella henselae is an intracellular bacterium that infects erythrocytes and endothelial cells and may cause vascular occlusion due to its affinity for vascular endothelium. When BRAO occurs as an early sign of the disease, prompt recognition may prevent further events.

#1393 - Case Report

INFECTION BY MYCOBACTERIUM ABSCESSUS: A CLINICAL CHALLENGE

Ana Cardoso¹, Vilma Salgado¹, Dúlio Teixeira Passos¹, Inês Pintado Maury², Patrícia Miguel Semedo³, Nuno Jacinto¹, Anabela Silva⁴, Aida Pereira^{2,5}, João Meneses Santos^{1,5}, Rui M. M. Victorino^{1,5}

¹ Department of Internal Medicine II, North Lisbon University Hospital Center - Santa Maria Hospital, Lisbon, Portugal

² Department of Infectious Diseases, North Lisbon University Hospital Center - Santa Maria Hospital, Lisbon, Portugal

³ Department of Medical Oncology, North Lisbon University Hospital Center - Santa Maria Hospital, Lisbon, Portugal

⁴ National Laboratory of Mycobacteria Reference, Department of Infectious Diseases - Ricardo Jorge National Institute of Environmental Health, Porto, Portugal

⁵ Medicine II University Clinic, Faculty of Medicine - University of Lisbon, Lisbon, Portugal

Introduction

Mycobacterium abscessus complex comprise a set of fast-growing non-tuberculous mycobacteria. These agents are a rare cause of clinical infection. Although any organ can be affected, pulmonary involvement is most often reported with varying outcome. Disseminated infection is rare and most often described in immunocompromised patients or associated with prosthetic material.

Case description

A 59-year-old woman with a mechanical mitral valve and pacemaker following a rheumatic fever carditis in the youth, was admitted in Cape Verde due to a 1-month history of fever, sweating, fatigue and anorexia. The patient underwent empiric antimicrobial therapy for endocarditis without clinical improvement and returned to Portugal being admitted in our hospital. The laboratory tests revealed normal white blood cell count, erythrocyte sedimentation rate of 120 mm/h, and C-reactive protein of 4.0 mg/dL. *Mycobacterium abscessus* was identified in admission blood and bone marrow cultures. No signs of valvular vegetations were found on the trans-esophageal echocardiogram. Further investigation with positron-emission tomography (PET) showed disseminated infection with prosthesis endocarditis, cerebral, splenic and hepatic abscesses and subcutaneous nodular lesions. In spite of antimicrobial therapy there was no clinical improvement and bacteremia persisted. The molecular study showed resistance to macrolides and sensitivity to aminoglycosides and phenotypic study showed sensitivity to amikacin, linezolid and cefoxitin and resistance to amoxicillin-clavulanate, sulfamethoxazole and moxifloxacin. Antimicrobial therapy was adjusted according to the antibiogram and surgical replacement of prosthetic material was performed after persistently negative blood cultures. The patient was discharged with oral therapy with moxifloxacin, linezolid, doxycyclin, clofazimine and inhaled amikacin, without clinical worsening or emergence of new skin lesions.

Discussion

This case represents the utility of PET in the diagnosis of infective endocarditis in patients with prosthetic valves and high clinical suspicion in spite of normal echocardiography. It also represents a clinical challenge due to resistance to multiple antimicrobials and the limited experience and lack of consensus regarding the treatment of this mycobacteriosis.

#1398 - Case Report

PNEUMONIA ASSOCIATED ACUTE GLOMERULONEPHRITIS: A RARE CASE

Sara Raquel Pereira Martins¹, Ramon Nogué Bou²

¹ Centro Hospitalar do Porto, Porto, Portugal

² Hospital Montserrat Lleida, Lleida, Spain

Introduction

Post-infectious glomerulonephritis, caused by prior infection

with nephritogenic strains of group A B-hemolytic streptococcus, remains a common cause of nephritis in children. Although rare, synchronous association of pneumonia and acute glomerulonephritis (AGN) has also been described, with *Streptococcus pneumoniae* and *Mycoplasma pneumoniae* being the most frequently related agents.

Case description

A 17-year-old boy presented with a 3-day history of fever and 2 day-history with tea-colored urine, bilateral low back pain and dry cough. Denied dysuria or increased urinary frequency, other respiratory symptoms, skin or throat infection, sick contacts or recent travel history. On physical examination was febrile, had normal blood pressure and O₂ saturations and no signs of tonsillitis or respiratory distress. Auscultation revealed discrete late inspiratory crackles. He had no edema. Blood tests showed normal hemoglobin (14.6 g/dL), normal leukocyte count (11.04x10³/uL) with slight neutrophilia (8.09x10³/uL) and high C reactive-protein levels (68 mg/dL). Serum creatinine and urea were normal but urinalysis showed hematuria (30/HPF) without red blood cell casts, leukocyturia (5/HPF), proteinuria (1932 mg/24h urine). Urine and blood cultures were negative, as were urinary antigen tests for pneumococcus and legionella. Hepatitis B, C and HIV were ruled out by serological tests. Point-of-care ultrasound (POCUS) showed normal renal size, absence of ureterohydronephrosis, normal vascular renal perfusion and bilateral ureterovesical jet. Lung ultrasound showed consolidation, confirmed with CT. Complement levels and serological tests to streptococcus or mycoplasma were not performed since it would not change the course of treatment. The patient was started on ceftriaxone but maintained fever and developed type 1 respiratory failure. Azithromycin was empirically associated acknowledging the reports of pneumonia and AGN related to *Mycoplasma pneumoniae*. Complete clinical resolution was achieved and hematuria and proteinuria had resolved at 1 month follow-up consultation.

Discussion

We report a rare case of pneumonia and concomitant AGN, diagnosed early through POCUS. Although immune alveolitis or pulmonary edema associated with AGN could have been misinterpreted as pneumonia, respiratory manifestations presented synchronously, the radiologic pattern was suggestive of pneumonia and there was response to antibiotics, making pneumonia the most probable diagnosis.

#1403 - Case Report

DISSEMINATED VARICELLA WITH CENTRAL NERVOUS SYSTEM INVOLVEMENT

Jaime Alonso Muñoz, Ester Martín Higuera, Cristina Llamazares Mendo

Hospital General Universitario Gregorio Marañón, Madrid, Spain

Introduction

Varicella zoster virus (VZV) infection is a mild disease in children. However, in adults its presentation may be severe, so its prompt diagnosis is very important to start the treatment early.

Case description

An 85-year-old female with medical history of arterial hypertension, dyslipidemia and right vestibular hypofunction consulted in the emergency department after several falls related to gait instability in the last four days and sleepiness. She was under treatment with oral famciclovir for cutaneous lesions of probable herpetic origin at the left gluteal region. In the emergency department a blood test, a urinalysis, a cranial computed tomography and an electrocardiogram were performed. They showed no significant alterations except for a slight increase in creatinine kinase and an acute renal failure of prerenal origin that resolved after fluid therapy. She was admitted to Internal Medicine to complete study. During the following days new papular lesions appeared in the thorax, the back and the limbs and disseminated herpes zoster with possible involvement of the central nervous system was suspected, so we performed a lumbar puncture which showed an opening pressure of 12 cm H₂O and we obtained a sample of clear cerebrospinal fluid (CSF). Its laboratory characteristics (10 red blood cells/μl, 100 leukocytes/μl, mononuclear 98%, polymorphonuclear 2%, glucose 42 mg/dl, proteins 116 mg/dl) were compatible with infection of viric origin so we started treatment with intravenous acyclovir at a dose of 10 mg/kg/8 hours. The next day we were informed that the polymerase chain reaction for VZV in the CSF was positive, which confirmed the diagnosis of encephalitis by VZV. We completed the study with a cranial magnetic resonance that showed changes suggestive of chronic microangiopathy but no alterations in temporal structures. The patient continued treatment with intravenous acyclovir for 10 days and oral valaciclovir for 11 days when she was discharged. He presented progressive improvement of skin lesions, gait instability and level of consciousness. Two years later she lives alone and she is independent although having an immediate memory impairment as a sequel.

Discussion

Although VZV infection is usually mild in children, adults can present severe complications whose early diagnosis is very important to guide a proper treatment. In addition, this case reminds us of the importance of the examination of skin lesions even if they are not the reason for consultation.

#1405 - Case Report

PERICARDIAL TUBERCULOSIS IN AN IMMUNOCOMPETENT INDIVIDUAL

Mário Bibi, Fani Ribeiro, Joana Monteiro, Joana Laranjinha, Nídia Oliveira, Sofia Jordão, Marta Pereira

ULSM, Porto, Portugal

Introduction

Cardiac tamponade is a medical emergency that can rapidly result in death if not treated. The mortality risk depends on the fast diagnosis and treatment, as well as the cause of the tamponade. In developed countries, Mycobacterium tuberculosis infection rarely presents as pericardial disease (<1%), and when it does, normally it happens in immunocompromised patients. Left untreated, pericardial tuberculosis leads to a median survival time of 3.7 months.

Case description

Twenty-six-year-old man who has been imprisoned approximately for one year before admission. He had a known contact with an individual suffering from pulmonary tuberculosis. He presented in our emergency department (ED) with chest pain, dyspnea and syncope. He also complained of asthenia for 6 months and for the month before he suffered from dry cough, chest pain, fever and anorexia. He had multiple antibiotics for a supposed respiratory infection. A diagnosis of cardiac tamponade was made on the ED, and the pericardial fluid was drained. This fluid was a serohematic exudate, with low ADA. After drainage, the echocardiogram showed signs of constrictive pericarditis. The following investigation also found pulmonary consolidations, cervical and mediastinal adenopathy as well as an endobronchial mass (EM). Acid-fast bacilli smear and nucleic acid amplification testing were made on several clinical specimens (sputum, bronchoscopy, pericardial fluid and tissue biopsy of EM), all negative. Given the clinical gravity and pericardial involvement, a preliminary information of necrotizing granulomas on the EM's biopsy lead us to initiate empiric antituberculous therapy associated with corticosteroids. Mycobacterium tuberculosis was only identified in the mycobacterial culture of sputum and bronchoscopy specimens. A diagnosis of disseminated tuberculosis with pulmonary, pericardial and lymph node involvement was made. No immunocompromised state was found, specifically an HIV infection.

Discussion

Despite the rarity of pericardial involvement by Mycobacterium tuberculosis, especially in an immunocompetent individual residing in a developed country, this diagnosis should not be overlooked if the remaining epidemiological and clinical data suggest this aetiology. The high index of suspicion allows faster diagnosis and treatment initiation, even with initial negative diagnostic results, improving prevention of complications, as constrictive pericarditis.

#1411 - Case Report

A RARE FORM OF EXTRAPULMONARY TUBERCULOSIS

Manuel Toscano¹, Ana Sofia Cunha², Catarina Parente³, Ana Isabel Pedroso¹, Cátia Carmona¹, Armino Ramos¹

¹ Hospital de Cascais, Lisbon, Portugal

² Instituto Português de Oncologia, Lisbon, Portugal

³ Centro Hospitalar Barreiro Montijo, Barreiro, Portugal

Introduction

Tuberculosis (TB) is the second most common fatal disease in the world and remains a major public health problem. In Portugal, in the last 10 years, there has been a 40% decline in its incidence (<20/100.000 inhabitants since 2015), resembling the trend of other European countries. The combination of TB and HIV speeds the progress of both diseases, highlighting the need for appropriate treatment of both conditions. Tuberculous meningitis is a rare form of extrapulmonary tuberculosis, usually caused by hematogenous spread of *Mycobacterium tuberculosis* (MTB), which carries a high morbidity and mortality, especially among co-infected patients.

Case description

We present the case of a 42-year-old female patient with known HIV-1 infection since 2003, and a history of poor adherence to therapy, who presented with a 1-month history of fronto-occipital headache, nausea and malaise associated with low-grade fever for the past 3 days. Physical examination was initially unremarkable, but rapidly ensuing photo/phonophobia, vomiting and neck stiffness were noted as the patient presented progressively more agitated and confused (GCS 9). Blood work revealed mild elevation of inflammatory markers (CRP 1.38mg/dL, WBC of 7090 with 83.6% neutrophilia) and anemia (Hb 10.3 g/dL). Brain CT scan showed no remarkable findings and the cerebrospinal fluid (CSF) examination revealed lymphocytic pleocytosis (WBC count of 450, with 97% MN) with elevated proteins (254 mg/dL) and low glucose (18 mg/dL). Thus, the patient was initially started on ceftriaxone, ampiciline and vancomycin. CSF microscopy was negative for bacteria and MTB and cytology was initially suspicious for malignancy. However, CSF polymerase chain reaction (PCR) for MTB DNA was positive.

The patient was initiated on tuberculostatic treatment, with prompt clinical improvement and ad integrum recovery from the neurological deficits.

Discussion

This severe disease, characterized by nonspecific clinical symptoms, is associated with significant morbidity and a high risk of mortality. As such, a high index of suspicion is warranted since early diagnosis and management are crucial in improving patient outcomes.

Although the detection of MBT in culture of the CSF sample remains the diagnostic gold standard, it has low sensitivity and a high incidence of false negatives. Therefore, molecular testing

(DNA amplification by PCR) now plays an important role in the diagnosis of tuberculosis and was crucial for the timely and appropriate treatment of this patient.

#1418 - Abstract

CATHETER-ASSOCIATED URINARY TRACT INFECTION IN MEDICAL PATIENTS OF PORTUGUESE HOSPITAL: INCIDENCE AND RISK FACTORS

Maria João Lobão^{1,2}, Ana Lúcia Taborda¹, Ana Maria Grilo¹, Carolina Sepulveda¹, Jorge Castro¹, Filipa Taborda¹, Ana Gorgulho¹, Paulo Sousa²

¹ Hospital de Cascais, Cascais, Portugal

² NOVA National School of Public Health, Lisboa, Portugal

Background

Catheter-associated urinary tract infections (CAUTI) are frequent and preventable hospital-acquired infections, which often result in patient morbidity and mortality as well as high costs for healthcare systems. This study aimed to estimate incidence, to identify risk factors and to evaluate the impact of CAUTI in intra-hospital mortality and length of stay.

Methods

A prospective cohort study was conducted in an Internal medicine department of a Portuguese Hospital (93-beds), from October 2017 to June 2018. We considered variables related to the patient (age, sex, Charlson comorbidity Index), admission episode (type, local, principal diagnosis according to ICD-10), bladder catheter (type, procedure local, indications, catheters-days) and outcome (CAUTI, in-hospital mortality and length of stay). We used CAUTI CDC definitions and metrics for infection definition. Risk factors identification was performed using Binary Logistic Regression. To analyse CAUTI association with LOS and Mortality, we used Mann-Whitney U and Qui-Square test, respectively. P value < 0.05 was considered statistically significant.

Results

Data from 2587 consecutively internal medicine ward admissions was analysed. The final study cohort included 267 patients submitted to bladder catheterization. We verified the occurrence of 17 CAUTI during the study period (cumulative incidence: 6.3%). The density incidence rate was 5.7 infections/1000 catheter-days. Although type of admission, length of stay, catheter type and days showed a statistical relation with CAUTI in bivariate analysis, multivariate analysis has demonstrated that the unique independent predictor factor for CAUTI in this cohort was the number of catheter-days (P<0,001; OR 1,05, 95 CI 1,03-1,09). We didn't find a statistically significant association between CAUTI and mortality or LOS.

Conclusion

CAUTI incidence found in this study underscore the importance of

good practices compliance to reduce this nosocomial infection. As the only independent risk factor identified in this cohort was the number of catheter-days, it is very important to consider the early remove of the device as an important part of CAUTI prevention strategy.

#1419 - Case Report

TUBERCULOUS PERICARDITIS - THE DIFFERENCES BETWEEN TWO CLINICAL CASES

Ana Luísa Nunes, Daniela Santos, Jandira Lima, Rui M. Santos, Armando Carvalho

Coimbra University Hospital Centre, Coimbra, Portugal

Introduction

Extrapulmonary tuberculosis occurs in 20% of patients with tuberculosis. Of these, only 1 to 8% present pericardial involvement. It is also known that tuberculous pericarditis occurs in approximately 1 to 2% of pulmonary tuberculosis cases.

Case description

Case 1

A 20-year-old woman with 3 cervical adenopathies and an evening fever for a month has been hospitalized. Previous contact with pulmonary tuberculosis 3 years ago. No changes to the physical examination, in addition to the adenopathies. Analytically: C-reactive protein 3,86 mg/dL and LDH 335 U/L. Normal chest radiography. Negative viral serologies and autoimmunity. Positive tuberculin and IGRA tests. Performed diagnosis of lymph node tuberculosis after histological confirmation. On the 5th day of hospitalization she presented pleuritic precordialgia with dorsiflexion relief. Elevation of myocardial necrosis markers and ST-segment, as well as T-wave inversion from V1 to V4 were observed. Echocardiogram revealed a minor anterior pericardial effusion. These findings were interpreted in the context of tuberculous myopericarditis. High doses of acetylsalicylic acid and tuberculostatic drugs were initiated, with resolution of the symptomatology.

Case 2

A 78-year-old woman is admitted in the emergency room with constant precordialgia that worsens in dorsal decubitus, with 1 day of evolution. Pericardial friction is noticed to physical examination. History of renal nephrectomy due to tuberculosis 20 years ago and isolation of *Mycobacterium tuberculosis* in sputum sample 10 years ago, without further treatment. Analytically: C-reactive protein 22 mg/dL and leukocytosis with neutrophilia. Elevation of ST-segment with superior concavity in DII, DIII and aVF. Chest radiography with increased cardiothoracic index and slight anterior pericardial effusion on V-scan echocardiography. Positive IGRA. No response to broad spectrum antibiotics. Resolution of symptomatology only after initiation of tuberculostatic drugs.

Discussion

Tuberculous pericarditis is a diagnostic challenge with possible therapeutic delay and inherent complications. Above we describe

2 cases of tuberculous pericarditis that affects both a young adult and elderly women with previous contact with different forms of tuberculosis. In the second case it appears as an initial presentation, unlike the first one, since it occurs as a complication during the hospitalization.

#1427 - Case Report

A FULMINANT CASE OF RICKETTSIOSIS IN AN ELDERLY

Marta Braga Martins, Luís Monteiro Dias, Rosa Macedo Carvalho, Céu Rodrigues, Vânia Gomes, António Oliveira Silva

Hospital de Braga, Braga, Portugal

Introduction

Rickettsia infections occur frequently and are a relatively common and treatable cause of fever and cutaneous lesions. Rarely, they develop into potentially fatal clinical entities that require immediate recognition and treatment.

Case description

A 84-year-old woman with type 2 diabetes mellitus and mild dementia was brought to the emergency room with a 5 day history of altered state of consciousness and somnolence, refusing to feed. She referred erythematous small macules and papules, essentially in the trunk, upper limbs, palms and plants, that disappeared when pressed. She had no fever. At admission, a necrotic ulcerated lesion compatible with "tâche noir" was perceptible in the left limb as well as a generalized maculopapular rash. Her daughter said the patient used to spend the afternoons sitting in the garden and that she had been bitten by a "bug" a few days before. Analytically, C reactive protein was 147 mg/L, with leukocytosis and neutrophilia. Brain computed tomography did not reveal acute changes. She was admitted with the diagnostic hypothesis of sepsis secondary to possible zoonosis. Blood cultures and serologies were collected. On the first day, she had fever, progression of the rash and clinical exacerbation, with multiorgan dysfunctions: cardiovascular, with sustained hypotension, hyperlactacidemia, troponinemia rising, requiring aminergic support; respiratory, with pO₂/FiO₂ ratio <200, requiring noninvasive ventilation; hematologic, with consumption coagulopathy, thrombocytopenia and anemia; renal, with oliguria and rhabdomyolysis; and coma. The anti-rickettsia conorii and mooserii antibody titers were negative. Due to the high clinical probability of rickettsiosis, a molecular study was requested for rickettsia sp., whose result was positive. Despite supportive treatment and adequate antibiotic therapy, it evolved unfavorably, with progression of the purpuric rash and the multiple dysfunctions, and she died.

Discussion

The incidence of rickettsiosis has been increasing. In less common cases, the condition may progress rapidly with multiorgan dysfunction, as it occurred in this patient. Mortality is also rare, but in this case the evolution was unfavorable, despite supportive

therapy and treatment directed according to the literature. This clinical case shows the importance of an early diagnosis of this nosological entity, through a careful anamnesis and not underestimating the epidemiological context.

#1434 - Case Report

PERIPHERAL NEUROPATHY IN HIV PATIENT: CONSIDER OTHER ETIOLOGIES

Ana Sá, Vanessa Palha, Narciso Oliveira, Teresa Pimentel
Hospital de Braga, Braga, Portugal

Introduction

A distal painful sensorimotor polyneuropathy is the most common type of HIV associated peripheral neuropathy. It usually develops during late HIV infection, with low CD4 count; it is rare in otherwise healthy seropositive patients. HIV-associated distal painful neuropathy is a progressive disease, which signs and symptoms include decreased deep tendon reflexes at the ankles and decreased sensation in the distal extremities as well as paresthesias, dysesthesias, and pain in a symmetric stocking-glove distribution. These symptoms are generally static or slowly progressive over time, and depending on the severity, may interfere significantly with the patient's daily activities. Co-existent causes, such as neurotoxic drugs or vitamin deficiencies, must be eliminated.

Case description

A 49-year-old man with HIV infection, treated with ritonavir, atazanavir and emtricitabine/tenofovir. Negative viral load and CD4 275/uL. Went to the emergency department due to paresthesias and dysesthesia in the hands and feet with 1 month of evolution. Physical examination with slight motor deficit in the left arm, decreased sensitivity at the extremities and hyperreflexia. Lumbar MRI scan with right postero-lateral protrusion of the disc in L4-L5. Cranial CT scan without changes. Lumbar puncture excluded opportunistic infection. Laboratory studies without abnormal results. He was admitted to the Internal Medicine department with suspected HIV-associated polyneuropathy. Additional studies: cervical MRI showed massive central disc complex (C5-C6) compressing the medullary cord with myelopathy. Diagnosed cervical myelopathy and surgical decompression was done, with tetraparesis recovery.

Discussion

In this case, the presentation with peripheral neurological symptoms and signs were originally ascribed to HIV infection. However, additional investigations confirmed herniated cervical disk. In the HIV infected patient presenting with peripheral neurological symptoms, more than one diagnosis may co-exist and must be excluded. The initial clinical approach of HIV-positive patients should not be different from that of HIV-negative patients. In this patient, an earlier diagnosis could have been made if he didn't have HIV infection as comorbidity.

#1457 - Case Report

A TRAVELING LUNG

Ana Isabel Correia, Mónica Pedro, Helena Garcez, Martinho Fernandes, Luis Tavares, Elvira Camacho, Fátima Campante
Hospital Center Barreiro-Montijo, Barreiro, Portugal

Introduction

Malaria is a mosquito-borne disease caused by a parasite, as the *Plasmodium falciparum*. It is responsible for a significant global public health problem, being endemic in tropical and subtropical regions. Left untreated, may result in potentially lethal complications. The authors present a case of a less frequent complication of malaria.

Case description

An 18-year-old woman presented to our Emergency Department with a five-day history of otalgia, vomiting, diarrhea, myalgia and intermittent fever that persisted even with antipyretics. She attended an urgent care center two days before with the same clinical condition, where antibiotic and nasal corticosteroid spray was prescribed. With a more accurate anamnesis it was possible to know that she had returned 8 days ago from Angola, where she had stayed for about 2 weeks. She admitted that didn't take adequate precaution and failed to use prophylactic drug. On examination, she was febrile after intravenous paracetamol and, with mild edema and cerumen at the left external ear canal. Laboratory evaluation showed anemia, thrombocytopenia, elevation of transaminases and bilirubin. The blood smear and the rapid parasitological diagnostic test were positive for *Plasmodium falciparum*. She was diagnosed with malaria and initiated intravenous quinine and doxycycline. However, her clinical condition got worse over next days, with elevation of inflammatory parameters and of hepatic enzymes, persistent fever, hypoglycemia, anemia requiring transfusion and shortness of breath with hypoxia. A computerized tomography scan of the chest ultimately diagnosed an extensive interstitial pneumonia, with important bilateral pleural effusion. The patient responded well to broad-spectrum antibiotics and was discharged from the hospital after 15 days.

Discussion

There is a lower frequency of pulmonary manifestations as compared to other complications of malaria. However, pulmonary complications are well described in *Plasmodium falciparum*, often occurring a few days after antimalarial treatment, and they shouldn't be neglected. The majority of malaria cases in the developed countries occur in people returning from endemic countries, but the unfamiliarity with malaria may be a problem for the physicians, leading to a delayed diagnosis. Therefore, this case highlights the importance of physicians improving their ability to detect malaria by obtaining a meticulous travel history. The early recognition and effective treatment can greatly improve outcomes.

#1459 - Case Report

SEPTIC SHOCK OF COMPLICATED ORIGIN IN A PATIENT WITH LOW CONCIIOUSNESS LEVEL.

Beatriz Elena Montenegro Puche¹, Antonio Martín Jiménez², Raquel De La Varga Martínez³

¹ Santa María del Puerto Hospital, Puerto De Santa María (cádiz), Spain

² San Carlos Hospital, San Fernando (cádiz), Spain

³ Virgen del Rocio University Hospital, Sevilla, Spain

Introduction

The sepsis and cognitive impairment approach must be focused on the hemodynamic support, as well as the coverage of the possible pathologies that may cause it.

Case description

A 70 year-old woman with hypertension, dyslipidemia, non-anticoagulated paroxysmal atrial fibrillation and Parkinson disease. She refers weakness, stiffness and swallowing difficulty without fever. At physical examination: Glasgow Coma Scale 8/15. BP 80/50 mmHg. 85% oxygen saturation. T^a35.3°C. HR 116 bpm. Cardiorespiratory auscultation: tachiarhythmia, no heart murmur, conserved lung ventilation. Soft abdomen without pain. No meningeal sings.

Blood test: Hb 10 g/dl; 14500/μL leukocytes (89% neutrophils); 61,000/μL platelets. Creatinine 1.2 mg/dl, urea 60 mg/dl, Na 125, K 4 RCP 250 mg/L. Prothrombin activity 63%.

Negative blood and urinary culture. Negative VIH and syphilis serology. Cranial MRI with old and acute mutiple stroke. Abdominal TC-scan: spleen abscess, biliary duct dilatation and bilateral pleural effusion. Echocardiography: non dilated left atrium, left ventricule hypertrophy with preserved ejection fraction and mild aortic stenosis. Transesophageal echocardiography: perforation of posterior veil of mitral valve with two vegetations. Severe mitral regurgitation associated.

Discussion

Differential diagnosis in a patient with septic shock without clear origin and neurological disturbances may result complicated. Firstly it is mandatory to find out whether low conciuosness level is secondary to infection (meningitis, encephalitis or urinary tract so) or to another disease (stroke, neurological disease worsening, tumour, vasculitis...). Then, in case intensive support and antibiotic treatment do not improve patient situation, is important to look for other diagnosis. In this case, despite the patient had no heart murmur, but spleen abscess and persistance acute phase reactants made we keep on searching and treating as endocarditis with a favorable evolution.

#1467 - Case Report

HEART: THE KEY TO A FEVER OF UNKNOWN ORIGIN

Ângela S. Almeida, Bárbara Lima, Margarida Rocha, Jorge Cotter Hospital Senhora da Oliveira, Guimarães, Portugal

Introduction

Fever of unknown origin (FUO) is classically defined as temperature greater than 38.3°C on several occasions for at least 3 weeks, without named cause after hospital workup. Its underlying causes can be infectious, neoplastic, inflammatory and miscellaneous, and there is no standard diagnostic approach to FUO. Myxomas are the most common benign cardiac tumors, but their manifestations can be unspecific, which may delay diagnosis and treatment. Although myxomas are a very rare cause of FUO, they should be considered in its workup, because they have a defined treatment and a good outcome when treated properly.

Case description

A 50-year-old female was admitted to our department due to FUO, with an isolated syncopal episode. Physical examination showed body temperature of 38.5°C, without neurologic, respiratory, cardiac, abdominal or genitourinary findings. Blood, urinary, throat and liquor cultures were negatives, and so were analysis of cerebrospinal fluid and infectious serologies. Cranial, thoracic, abdominal, pelvic and spine CT scans were also negative. Transesophageal echocardiography revealed a large left atrial mass, consistent with myxoma, partially prolapsing into the left ventricle during diastole. The patient was transferred to a cardiothoracic surgery department and the myxoma was successfully removed without complications. The patient was discharged four days after the procedure, without complaints.

Discussion

Being a rare cause, the diagnosis of cardiac myxoma presenting with FUO is often delayed, so it is important to recall it and perform echocardiographic screening, so the condition can be identified and treated promptly. Because most of the times clinical manifestations of myxomas consist in a triad of constitutional symptoms, embolization and intracardiac obstruction, it is imperative to keep this diagnosis in mind as early as possible, considering the risk of thromboembolic events and cardiovascular/hemodynamic involvement. Surgical resection, which has high survival rates, remains the standard treatment to prevent complications and provide a good prognosis.

#1472 - Abstract

CARBAPENEM VERSUS CARBAPENEM-SPARING ANTIBIOTIC IN URINARY TRACT INFECTIONS CAUSED BY EXTENDED-SPECTRUM BETA-LACTAMASE PRODUCING BACTERIA

Margarida Brito Monteiro, Barbara Pedro, Raquel Silva Hospital Prof. Doutor Fernando Fonseca, E.P.E., Amadora, Portugal

Background

The widespread use of beta-lactam antibiotics in our clinical practice has led to the emergence of resistant strains of extended-spectrum beta-lactamases (ESBL) producing bacteria. Due to their

susceptibility, carbapenems are regarded as the drugs of choice in the treatment of these bacteria. However, their widespread use has caused the emergence of resistant strains, posing new challenges in the therapy and infection control. We conducted a study in order to compare the use of carbapenem versus a carbapenem-sparing agent in urinary tract infections (UTI) caused by ESBL producing bacteria.

Methods

A retrospective observational study of a cohort of patients admitted to an internal medicine department with a diagnosis of UTI caused by ESBL producing *Escherichia coli* and *Klebsiella pneumoniae*, between January and December of 2018, was conducted. The clinical, microbiological and therapeutic data were retrieved from patient's clinical records. Statistical analysis was performed using Microsoft Excel 2016®. Pearson's chi-squared test was used for a significant p-value of <0.05.

Results

We assessed the urine samples of 252 patients. The risk factors present to urinary infection caused by ESBL producing organisms were: previous antibiotic use (51.2%); hospitalization in the previous six months (49.6%); diabetes (44.4%); presence of intravesical catheter (26.9%); active diagnosis of cancer (23.8%) and previous UTI caused by ESBL producing bacteria (15.1%). Empirical antibiotic treatment with second and third generation cephalosporins was started in 41.4% of the patients, and 9.5% were treated initially with a carbapenem. After appropriate antibiotic therapy, either with carbapenem or susceptible carbapenem sparing antibiotic, no statistically significant difference was found in the recurrence of ESBL UTI at one month (21.9% in the carbapenem group vs 29.0% in the carbapenem-sparing one, p-value=0.25) or at six months (12.4% vs 8.6% respectively, p-value=0.62). There was no difference in all-cause mortality between the two groups (17.1% in the carbapenem group vs 9.7% in the carbapenem-sparing antibiotic one, p-value=0.13).

Conclusion

In our study, we found no difference between carbapenem and susceptible non-carbapenem antibiotic in the treatment of urinary tract infections caused by ESBL producing bacteria. As carbapenem-resistant strains of bacteria continue to emerge, an alternative to carbapenems in non-life-threatening infections may reduce the antibiotic resistance.

#1478 - Case Report

WHAT TO NOT EXPECT WHEN YOU ARE EXPECTING – A CASE OF INFECTIVE ENDOCARDITIS BY NEISSERIA ELONGATA

Inês Rueff Rato, Maria Ana Canelas, Janine Resende, Daniela Martins-Mendes, Vítor Paixão-Dias

Centro Hospitalar Vila Nova de Gaia/Espinho, Vila Nova De Gaia, Portugal

Introduction

Infective Endocarditis (IE) is an infection within the heart that can be caused by a variety of infectious agents. *Neisseria elongata* is part of the normal human commensal oropharyngeal flora, known to cause sepsis, osteomyelitis and IE in rare cases.

Case description

A 65-year-old male with history of ischemic and valvular heart disease with a mechanic valve and conduit in aortic position since 2013 (Bentall procedure) was admitted to the emergency department complaining of abdominal discomfort, nausea and vomiting since the previous day. He reported a minor dental procedure the week before. On examination he was dehydrated, febrile and hypotensive (BP 89/57mmHg). A grade II/VI systolic murmur was audible on cardiac auscultation and the abdomen was painful at palpation of the right quadrants. Remaining physical and neurological examination was unremarkable. The study revealed: anaemia (Hb 11 g/dL), mild thrombocytopenia (109000/uL), leucocytosis (12400/uL) with neutrophilia and increased C-reactive protein (13 mg/dL). Normal lactate levels, rheumatoid factor and urinalysis. EKG: 3rd degree atrioventricular (AV) block, heart rate of 60 bpm. Abdominal CT: areas of splenic infarction and signs of non-specific colitis of the ascending colon. After blood cultures were drawn, he was started on antibiotics to empirically cover late prosthetic valve IE (ampicillin, flucloxacillin and gentamicin) and was admitted to an Intermediate Care Unit for continuous monitorization and further study. After the development of symptomatic bradycardia a temporary pacemaker was placed and later an epicardial pacemaker, due to persistent rhythm disturbances. The initial transesophageal echocardiogram (TEE) presented no signs of endocarditis or prosthetic valve dysfunction. After *Neisseria elongata* was isolated in blood cultures antibiotic therapy was changed to ceftriaxone, gentamicin and rifampicin. Cardiac CT and TEE repeated one week later confirmed IE with annular abscess. There was a remarkable improvement with negative control blood cultures and a valve replacement surgery was not needed. He was discharged after 6 weeks of antimicrobial therapy.

Discussion

Neisseria elongata is an uncommon cause of endocarditis. To the best of our knowledge, there are less than 25 cases of Infective Endocarditis by *Neisseria elongata* described in the literature. We believe the 3rd degree AV block the patient presented was caused by the periannular extension of the infected valve.

#1479 - Medical Image

A BRAIN INJURY

Marta Filipa Lemos Mendes, Filipa Rodrigues, Isabel Apolinário, Ilídio Brandão

Hospital de Braga, Braga, Portugal

Clinical summary

Male patient, 45 years old. Diagnosis of HIV infection, with abandonment of antiretroviral therapy 3 years ago. Patient went to the emergency service do to for headache and neck pain with 4 days of evolution, blurred vision and gait imbalance to the left side. In the physical examination, was detected left homonymous hemianopathy and decreased strength in the left lower limb. Performed cranial MRI showing “a right lesion expansive cortico-subcortical parieto-occipital with pattern of peripheral contrast uptake and extensive halo of digitiform vasogenic edema”. Given the imaging characteristics and the clinical history of immunosuppression by HIV (CD4 + 157 and Viral Load 5983524), cerebral toxoplasmosis was considered.

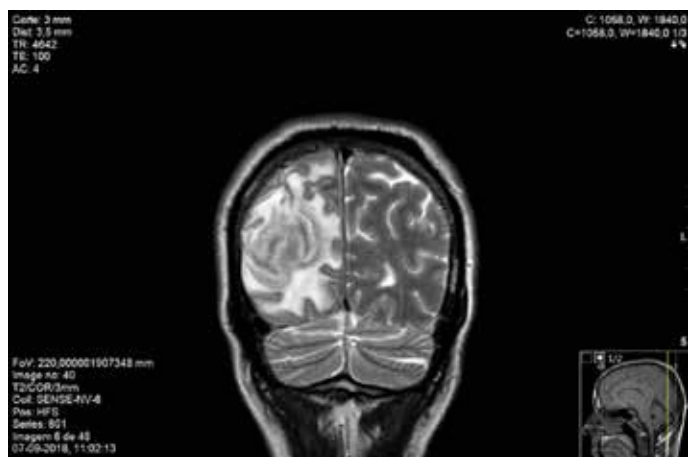

Figure #1479. Lesion intra-axial expansive cortico-subcortical parieto-occipital right with pattern of peripheral contrast uptake and extensive halo of vasogenic edema.

#1480 - Case Report

LYME DISEASE – AN ARTHRITIS CASE-STUDY

Rosa Margarida Cardoso, Jorge Rodrigues, Isabel Silva, Mário Baptista, Luis Filipe Rodrigues, Juvenalia Ribeiro

Hospital de Braga, Braga, Portugal

Introduction

Lyme Disease (LD) is caused by spirochetes, from the genus *Borrelia burgdorferi*, spread by ticks. Clinical manifestations are manifold and arthritis can occur in about 5% of infected patients.

Case description

82-year-old woman with no relevant history or chronic medication. History of migratory oligoarthritic with about 2 weeks of evolution; beginning on the right foot, followed by the right knee with worsening edema, without improvement after

topical non-steroidal anti-inflammatory drugs (NSAIDs). No other symptoms were reported. In the emergency department, she had fever and exuberant inflammatory signs of the right knee. Blood test revealed marked elevation of inflammatory markers and a diagnosis of septic arthritis was made after joint aspiration. An arthroscopic irrigation and debridement was performed and systemic empiric antibiotic therapy with vancomycin and gentamicin was started. Despite that, an arthritis in the right elbow and then left knee occurred during the hospital stay. After a review of recent medical history, she reported an influenza-like illness treated with NSAIDs one week before. The synovial fluid and blood cultures were negative. A broader serological investigation was carried out, and positivity was documented for *Borrelia burgdorferi* antibody IgG (ELISA method, later confirmed by Western blot). She started doxycycline 100mg 2id, which maintained for 30 days, with gradual clinical improvement.

Discussion

The diagnosis of Lyme disease is made by the clinic, with positive serologies, and the IgM and IgG antibodies may persist for years. First-line antibiotic therapy is doxycycline, with a high efficacy rate. The early onset of treatment is associated with a faster and more significant clinical improvement with fewer long-term sequelae.

#1483 - Case Report

NEISSERIA MENINGITIDIS: AN OUTBREAK OR JUST BAD LUCK

Daniela Brito, Ana Rita Abrantes, Lucília Pessoa, Ana Araujo, Tiago Pereira, Nuno Catorze

Médio Tejo Hospital Center, Abrantes, Portugal

Introduction

Neisseria meningitidis (NM) is an exclusively human gram-negative diplococcus that has a wide genetic variety. There are 13 serogroups based on different capsular polysaccharide structures, but only 6 cause most life threatening disease.

Case description

The authors present 3 cases of infection caused by the serotype B NM occurring at the same area and period of time, with a range of clinical presentation and outcome.

Case 1

64-year-old woman, with no relevant personal history. Admitted to the intensive care unit (ICU) with the diagnosis of septic shock. In the first hours of hospitalization, purpuric skin lesions appeared. Due to persistence of the neurological condition, a lumbar puncture (LP) was performed. The cytochemical analysis of the cerebrospinal fluid (CSF) indicated bacterial meningitidis (BM), identifying NM in CSF and blood cultures. There was need for ventilatory support, vasopressors and renal replacement therapy. Although there was regression of purpuric lesions on the trunk and face, the lower limbs showed signs of ischemia, with

later amputation. She had a indolent recovery, with no cognitive sequelae detected.

Case 2

19-year-old healthy man, who was examined in the the emergency department (ED) for abdominal pain and fever. At admission he presented with altered mental status. Blood exams were performed, showing an inflammatory response. On the basis of blood exams results and neurologic exam, a diagnostic LP was performed. The cytochemical analysis indicated BM. Blood and CSF cultures showed NM. He stayed in the ICU for 3 days, with rapid recovery, without sequelae.

Case 3

67-year-old healthy woman. Admitted to the ED for high fever and altered mental status. She evolved with declining mental status, headache and petechial lesions on the thorax. A LP was performed, with the diagnosis of NM infection. She was admitted at the ICU, where she stayed for 3 days. It was not necessary any organ support and she recovered with no sequelae.

The patients were treated with ceftriaxone 4g daily for 14 days. The patients contacts were informed and treated with ciprofloxacin.

Discussion

This disease presents a broad spectrum of manifestations and it's a neurological and clinical emergency that requires prompt recognition and initiation of therapy. The serotype B remains the most common agent, accounting for 90% of cases in Europe. Although our national vaccination plan includes a vaccine for meningitis, the serotype B is excluded.

#1485 - Case Report

HUMAN IMMUNODEFICIENCY VIRUS DIAGNOSIS – A REAL CHALLENGE

Fernando Mané, Ana Sá, Vanessa Palha, Anna Knoch, Maria Teresa Pimentel, Narciso Oliveira, Carlos Capela
Hospital de Braga, Braga, Portugal

Introduction

Early antiretroviral therapy (ART) is key for the control of Acquired Immune Deficiency Syndrome and the morbimortality associated with this condition is well established.

Case description

A 71-year-old man presented to the emergency room with balance disorders and inability to walk. Five days earlier he had developed face asymmetry, headache and sensitive changes in the left side of the body. A month before, he had a 5-minute episode of loss of consciousness associated with involuntary movements, with spontaneous cessation. At that time, he had a normal cranial computed tomography (CT) and an electroencephalogram showing rare epileptiform discharges, so he was given levetiracetam once daily. In the last 3 years, he had history of aphthous stomatitis associated with polyclonal hypergammaglobinemia and 3

recurrent episodes of skin lesions matching the description Herpes Zoster lesions. He had no acknowledged testing for Human Immunodeficiency Virus (HIV) infection.

At admission, neurologic exam was remarkable for psychomotor retardation despite normal consciousness; left homonymous hemianopsia; left tactile extinction; left hypoaesthesia; and left hemiparesis.

Analysis showed anemia (hemoglobin: 9.8g/dL), leukopenia (3000 leukocytes/uL, with 1600 neutrophils/uL and 1000 lymphocytes /uL) and a positive HIV test. Initial cranial CT showed digitiform hypodense lesions, best characterized by magnetic resonance imaging as multiple heterogeneous nodular lesions hyperintense in T2-weighted images associated with exuberant edema, suggestive of cerebral toxoplasmosis. Concurrently, a recent lacunar infarct in the right centrum semiovale was present. We established the diagnosis of cerebral toxoplasmosis associated with a recent ischemic event in a patient with HIV infection. Then we evaluated status of immunosuppression: 5 CD4+ cells/uL and viral load of 798157 copies/mL.

Pyrimethamine and clindamycin were initiated, with significant clinical response and progressive improvement of the neurological deficits. He started ART during the second week of hospitalization without noted side effects.

Discussion

This case report outlines the importance of high suspicion in the diagnosis of HIV infection, regardless of the patient's baseline characteristics and particularly when signs of immunosuppression are present. Timely diagnosis then provides the means for fundamental ART that diminishes both the burden associated with opportunistic diseases and the transmission of the virus.

#1486 - Case Report

INVASIVE PNEUMOCOCCAL INFECTION: ONE AGENT, FIVE DISEASES

Mariana L. S. Magalhães, Priscila Melo, Joana Frutuoso, Mauro Santos, Joana Louro, Teresa Martinho, Manuela Ricciulli, Rosa Amorim
Western Hospital Centre, Caldas Da Rainha, Portugal

Introduction

Pneumococcus is a common cause of bacteremia, in both immunocompetent and immunosuppressed patients. This infection can have different clinical manifestations and prognosis.

Case description

67 years old male, smoker and with an history of alcohol abuse, admitted in the emergency room for altered mental status and cough. On admission, he punctuated 8 points in the Glasgow Coma Scale (GCS), had a tympanic temperature of 39.2°C, rhonchi on the auscultation and a Kernig sign. The blood test showed leucocytosis, hyponatremia and high C-Reactive Protein. The chest X-ray revealed a right lung pneumonia, the head CT scan was

normal and the cerebrospinal fluid analysis showed high count of white blood cells and proteins and a low concentration of glucose. The patient was admitted to the internal medicine ward with the diagnosis of pneumonia and bacterial meningitis under empiric treatment with vancomycin and ceftriaxone. It was identified *Streptococcus pneumoniae* in blood culture. Because of lumbar pain, a CT lumbar scan was performed, suggesting bilateral psoas abscesses and spondylodiscitis, confirmed and characterised with MRI, with need of ultrasound-guided drainage. Further investigation revealed Endocarditis with infection of the mitral valve and consequent severe mitral regurgitation, with 3 episodes of acute heart failure with necessity of diuretics and non-invasive ventilation. The antibiotic therapy was switched to ceftriaxone, ampicillin and gentamicin and later, after the results of the susceptibility test, was changed to penicillin (4 million units every 4 hours). One month later, due to persistent fever, Clindamycin was added to the scheme. Three months after admission the patient had sustained apyrexia, hemodynamic stability, with no pain or altered mental status, and was transferred to Cardiothoracic ward for surgical valve repair.

Discussion

Even though *Pneumococcus* is a common pathologic agent, it can manifest in the most complex manners. Herein, we discuss a case where what seemed to be a straightforward pneumococcal infection, turned into a challenging disease, affecting multiple organs with life-threatening complications, leading to various invasive procedures, the need to multidisciplinary discussions and a long hospital stay.

#1488 - Abstract

CHARACTERISTICS ASSOCIATED WITH MORTALITY IN PATIENTS WITH ANAEROBIC BACTERIEMIA

Francisco Javier Sanmartín Pensado¹, Ariadna Arévalo López¹, Lucía Ramos Merino¹, Laura María Castelo Corral¹, Vanesa Balboa Barreiro², María Rodríguez Mayo³, Dolores Sousa Regueiro¹, Efrén Sánchez Vidal¹, Enrique Míguez Rey¹

¹ Infectious Diseases Unit, Complejo Hospitalario Universitario A Coruña, A Coruña, Spain

² Clinical Research Unit, Complejo Hospitalario Universitario A Coruña, A Coruña, Spain

³ Clinical Microbiology Service, Complejo Hospitalario Universitario A Coruña, A Coruña, Spain

Background

Anaerobic bacteremia (AB) is an important cause of mortality, however, the related risk factors related with it are not clear.

Methods

This is a retrospective study in which all the significant episodes of AB detected between December 2007 and December 2016 in Complejo Hospitalario de A Coruña are analyzed.

Results

A total of 453 patients were identified, of which 146 (32.2%) died during the hospitalization or in the first month after hospitalization, with death related to bacteremia in 76 (16.8%) of them. There is a high mortality rate in those patients with higher comorbidity (OR 1.21, 95% CI 1.12-1.31, $p < 0.001$), who suffer from a neoplasm (OR 2.03, 95% CI 1.36-3.02, $p = 0.001$) and / or take some type of immunosuppressive treatment. It seems that there is a discrete tendency to higher mortality among women (OR 1.29, 95% CI 0.85-1.95, $p = 0.227$), without becoming significant. The diagnosis was made more frequently among the medical services, predominating in the Emergency Department ($p < 0.001$). 42.5% of the deceased had been hospitalized in the previous 3 months on at least one occasion ($p = 0.002$). No differences were found in the length of stay in the ICU or if they had received adequate empirical antibiotic therapy, although adequate control of the focus prevented death ($p = 0.001$). The multivariate analysis confirmed that the highest comorbidity (OR 1.21, 95% CI 1.12-1.31, $p < 0.001$), corticosteroid immunosuppression (OR 2.68, 95% CI 1.5-4.78, $p = 0.001$), recent hospitalization (OR 1.92, 95% CI 1.27-2.9, $p = 0.002$), consumption of previous antibiotic therapy (OR 1.74, 95% CI 1.16-2.62, $p = 0.008$), presentation as septic shock (OR 9.72, 95% CI 5.57-16.95, $p < 0.001$) and admission to the ICU (OR 2.19, 95% CI 1.43-3.35, $p < 0.001$) are independent risk factors for mortality, while adequate focus control seems to be a protective factor (OR 0.43, 95% CI (0.26-0.71, $p = 0.001$).

Conclusion

Mortality in relation to BA is higher in older patients and a high morbidity, especially those who have a neoplasm or are under immunosuppressive treatment, predominantly with steroids. Recent hospitalization and previous antibiotic therapy also seem to be risk factors. The adequate control of the focus stands out as a protective factor.

#1493 - Case Report

A BACK DOOR INTO THE HEART

Gaspar Pereira, Zósima Pinto, Rita Grácio, Carla Falcão, Diana Fernandes

Centro Hospitalar de Leiria, Leiria, Portugal

Introduction

Endocarditis may be a potential marker of occult cancers, specifically *Streptococcus gallolyticus* infection who has been associated with gastrointestinal neoplasia, mostly colonic adenoma or carcinoma.

Case description

A 58-year-old man with a known medical history of chronic venous insufficiency and dyslipidemia presents to the emergency room with fever, nocturnal sweats, myalgias, 8 kg weight loss, petechiae in his hands and feet and malleolar oedema, for the last 3 months. He was previously diagnosed with ferropenic anemia, intestinal polyposis and splenomegaly.

On examination the patient presented with fever, mitral systolic murmur, petechiae of both hands and feet and bilateral malleolar oedema. The lab work showed microcytic anemia, elevated inflammatory parameters, proteinuria and erythrocyturia. An abdominal CT scan documented splenomegaly suggesting a spleen infarct and a clot in the splenic artery. Due to suspicion of endocarditis, a trans-thoracic heart ultrasound was performed and a mobile, echodense structure adherent to the tip of the anterior mitral's valve's leaflet, with asynchronous movement was identified. The patient was started on anticoagulant and empirical antibiotic therapy with vancomycin and gentamicin. Blood culture results were positive for *S. gallolyticus* and antimicrobial therapy was switched to penicillin G according to the antibiotic susceptibility. A transesophageal ultrasound confirmed endocarditis and a 11x3 mm vegetation was identified in the anterior mitral's valve's leaflet, which had perforated and presented a moderate eccentric regurgitant jet. The patient was discharged with a 4-week treatment plan with ceftriaxone 2 g id. At the 6-week follow-up, a transesophageal ultrasound documented a reduction of the mitral's valve's vegetation size whilst maintaining a very eccentric regurgitating jet. Afterwards a colonoscopy with polypectomy was performed revealing a polyp with high-grade dysplasia.

Discussion

Endocarditis is a challenging diagnosis, frequently exhibiting unspecific fluctuating symptoms with low specificity. Then again, the most common cutaneous manifestations are petechiae and these are frequently associated with larger vegetations and a higher number of embolic complications. Also, a *S. gallolyticus* endocarditis should alert us for the possibility of intestinal neoplastic lesions so that an earlier diagnosis and more effective treatment may be implemented.

#1498 - Case Report

INAUGURAL SEIZURE IN ADULT

Andreia Machado Ribeiro, Carla Tonel

Hospital Vila Franca de Xira, Vila Franca De Xira, Portugal

Introduction

Cysticercosis is a disease caused by *Taenia solium*. It is estimated that 50 million people are infected worldwide. Neurocysticercosis occurs when there is involvement of the central nervous system.

Case description

A 36-year-old male, with no relevant personal history or usual medication, presented to the emergency room with tonic-clonic inaugural seizure. He was born in Guinea-Bissau and has been living in Portugal for 1 year. The physical examination showed obtundation, Glasgow Coma Scale 11, with tongue bite, apyretic, no meningism or other neurologic changes.

Laboratory tests revealed a positive serology for human immunodeficiency virus (HIV), with 381 CD4 lymphocytes

and a viral load of 106,200 copies. A head CT scan was performed showing a "13 mm rounded lesion in the left parietal cortiosubcortical region with hypodense content and a regular thin capsule, accompanied by lesional edema; intraparenchymal calcifications are also defined". He also underwent a head magnetic resonance, which revealed "hypointense cystic lesion in T1 and hyperintense in T2; second left frontal subarachnoid injury". Neurocysticercosis was diagnosed. He started therapy with abendazole (10 days), Dexamethasone and Levetiracetam. The patient showed progressive clinical improvement. He was referred to Infectious Diseases consult in order to start antiretroviral therapy.

Discussion

Seizures are the most frequent symptom of neurocysticercosis. In endemic countries, neurocysticercosis is the most common cause of onset seizures in adulthood. Given the globalization, with the increase of tourism and migrations from endemic regions, neurocysticercosis should be a differential diagnosis to take into account in patients with an onset seizure.

#1500 - Case Report

EXTRAPULMONAR TUBERCULOSIS: A DIFFICULT DIAGNOSIS

Andreia Machado Ribeiro, Carla Tonel

Hospital Vila Franca de Xira, Vila Franca De Xira, Portugal

Introduction

The incidence rate of tuberculosis in Portugal is 15/100,000 inhabitants, one of the highest in the European Union. Tuberculosis can affect any organ with pulmonary forms being the most frequent. Extrapulmonary tuberculosis accounts for 20% of the cases.

Case description

Case 1

A 46-year-old female with history of HIV2 infection under antiretrovirals, presented to the emergency room (ER) with a headache for 2 days. She performed a head MRI which revealed 2 right cerebellar lesions and 1 left parietal lesion with contrast uptake. Laboratory results showed 858 CD4 cells. She started Albendazole and Prednisolone for probable neurocysticercosis. Two months later she returned to the ER due to aggravation of the headaches. She underwent a head CT, which revealed dimensional increase of lesions. She was submitted to brain biopsy which identified granulomatous inflammation. The cultural exam was positive for *Mycobacterium tuberculosis*. She initiated antituberculous therapy with clinical improvement.

Case 2

A 44-year-old female presented to the ER with fever and abdominal pain for 2 months. Laboratory tests showed HIV positive serology. Abdominal CT revealed mesenteric adenopathies and intestinal wall thickening, suggestive of enteritis. She started

amoxicillin/clavulanic acid with no improvement of the fever. The complementary study was negative for any other source of infection. She underwent a bone marrow biopsy that showed myelodysplasia. Acid-fast bacilli grew in the myeloculture. Antituberculous drugs and antiretrovirals were initiated with clinical improvement. Disseminated tuberculosis was assumed with intestinal and bone involvement.

Case 3

A 38-year-old female presented to the ER with fever for 2 weeks. Physical examination showed ascites. Abdominal CT revealed destruction of L2/L3 vertebral bodies, moderate ascites. She started Meropenem for osteomyelitis and spondylodiscitis with clinical improvement. One week after discharge, she returned to the ER with right pleuritic thoracalgia. Chest x-ray showed right pleural effusion. A pleural biopsy was performed which revealed granulomatous pleuritic. She started therapy for tuberculosis with pleural, bone and peritoneal involvement.

Discussion

Extrapulmonary tuberculosis diagnosis is a challenge due to multiple clinical presentations, poor access to biological products and low cultural sensitivity. The treatment consists of antituberculous therapy. Early diagnosis and appropriate treatment are essential for a good prognosis.

#1507 - Case Report

HERPES VARICELLA ZOSTER VIRUS MENINGITIS: THE PURPOSE OF A CLINICAL CASE

Nidia Alexandra Oliveira, Catarina Almeida, Catia Figueiredo, Joana Lemos, Alexandra Vaz

Centro Hospitalar de Tondela Viseu, Viseu, Portugal

Introduction

Meningitis is a meninges inflammation and its etiology can be virus, bacteria, fungus or parasite. It might be detected in individuals who show fever, headache, meningism and alteration to state of consciousness, as it represents a potentially serious infection. Therefore, it demands timely treatment and diagnosis.

The annual rate of the herpes varicella zoster (HVZ) virus is of 1.5 to 3 cases per 1000 individuals, causing infection of the central nervous system in 0.2 to 0.5 of the affected individuals.

Case description

71 year old man went to de emmergency servisse (E.S) on 02/25 revealing inflammation in the left eye, medicated with topical azithromycin. On a 03/23 was re-evaluated by ophthalmology initiating topical corticoid. Re-evaluated on 03/31 due to vesicular damage on left ophthalmic field and swelling in the left eye.

The ophthalmic area was diagnosed and treated with oral valaciclovir. Subsequent prostration, unable to walk and visual allucination was brought again to the E.S.

The patient showed signs of prostration, scarce speech, left

periocular and nasal crusty wounds, inflammation of the left eye and terminal rigidity on the nape. Febrile and hypotensive. Analysis shows leukocytosis, neutrophilia and CRP at 2-30 mg/L. Tomography and chest x-ray showed no alterations of severe pathology. Lumbar puncture with clear spinal fluid, 20 leukocytes/mm³ (mononuclear dominance) and amicrobial gram. Positive DNA panel for HVZ. Started aciclovir 10 mg/Kg, EV 8/8h, positive analitical and clinical evolution. Medical release without focal deficits, however, more dependent than before. Magnetic resonance does not reveal encephalitis.

Discussion

The unspecified clinical occurrence associated to the alteration of the state of conscience excludes meningitis. The inicial absence of classical symptomatology leads to divergent diagnosis of this rare identity. This trial reveals the need of a high level of suspicion so that the diagnosis won't be neglectful and the treatment delayed, with potential consequences.

#1515 - Case Report

VISCERAL LEISHMANIASIS: A RARE CASE OF PANCYTOPENIA

Carlos Candeias, Pedro Campelo, Ramiro Lopes, Ana Fortuna, Carlos Cabrita, António Moura, Ana Monteiro

Internal Medicine - Centro Hospitalar Universitário do Algarve, Faro, Portugal

Introduction

Visceral leishmaniasis is an endemic infection in Portugal (PT) where it has become a frequent complication seen in immunosuppressed patients. The clinical picture can be varied, but often includes pancytopenia which can pose a difficult diagnostic challenge, particularly in immunocompromised patients.

Case description

We report the case of a 64 year old female, born in Brazil (BR) but living in PT for the last 20 years, with a known medical history of hepatitis B and rheumatoid arthritis. Her regular medications included prednisolone 10 mg once daily and methotrexate (which the patient stopped taking on her own initiative two weeks before). The patient was admitted in the Emergency Room (ER) due to cough, lethargy and fevers lasting two weeks. Physical examination showed a febrile patient (39°C) with no other significant findings. Laboratory findings showed pancytopenia (hemoglobin 9.0 g/L, leukocytes $\times 10^9/L$ and platelets $74 \times 10^9/L$) and a PCR of 207 mg/dL. Other bloods were unremarkable. She started empirical treatment with ceftriaxone while culture sensitivities were awaited. Further tests showed high ferritin levels (>2000 ng/ml) while non-contrast CT abdomen showed a splenomegaly (150 mm). Serologies, autoimmune panel and blood and urine cultures where normal. With a diagnosis remaining elusive, and being an immunosuppressed patient living in the countryside, we examined the patient bone marrow which revealed leishmaniasis. The

patient completed five days of ceftriaxone until recurrent fevers prompted a change to cefepime. After the leishmaniasis diagnosis the antibiotic was switched to liposomal amphotericin B (4 mg/kg) with a resulting clinical improvement (resolution of complaints and pancytopenia) and the patient discharged, to be followed up in outpatient clinic.

Discussion

Visceral leishmaniasis is one of the most neglected diseases in the world even though it is a potentially lethal infection if treatment is delayed or not instituted. It behaves as an opportunistic infection in immunosuppressed patients and should be included in the differential diagnosis of febrile pancytopenia.

#1519 - Case Report

FROM TUMOR TO A CURIOUS FINDING

Ana Isabel Correia, Mónica Pedro, Carlos Montenegro, Artur Gião, Catarina Lima Vieira, José Vilchez, Martinho Fernandes, Fátima Campante

Hospital Center Barreiro-Montijo, Barreiro, Portugal

Introduction

Acute pancreatitis, an inflammatory process of the pancreas, is a pathological condition frequently admitted to emergency room. The most common etiologies are gallstones and alcohol consumption. The authors present a rare case of acute pancreatitis secondary to *Strongyloides Stercoralis* infection.

Case description

A 39-year-old man from Guinea-Bissau recently in Portugal, with no relevant medical history, denying ethanolic habits, went to the emergency department for a stained-type epigastralgia with irradiation to the dorsal region. On examination was noted an upper quadrants tenderness. Laboratorial evaluation showed elevation of transaminases, amylase and lipase. Abdominal ultrasound showed a gallbladder without lithiasis, confirmed by Abdominal and Pelvic Computed Tomography (CT), which added ectasia of biliary ducts and Wirsung Duct, enlargement and heterogeneity of the second portion of the Duodenum and marked gastric dilation. He was hospitalized with the diagnosis of acute pancreatitis, with negative infecciology and immunology. An upper endoscopy (UE) was performed with biopsy of the duodenum and magnetic resonance cholangiopancreatography was suggestive of ampullary/peripapillary tumor. However, the anatomopathological result of the UE biopsy revealed a duodenal mucosa with numerous parasites, compatible with *Strongyloides Stercoralis*. Treatment was initiated with oral Albendazole 400 mg for 3 days, with a clinical remission achieved.

Discussion

Strongyloidiasis is an infection caused by *Strongyloides Stercoralis*, a parasite transmitted through contact with the infested soil. It has a high prevalence worldwide, being endemic in tropical and

subtropical regions. Many of the hosts are asymptomatic. It may develop gastrointestinal manifestations, such as abdominal pain or vomiting after penetration of the larva into the skin of the individual. The association with acute pancreatitis is rare, with few cases described in the medical literature. Infestation of the ampulla of Vater may explain pancreatitis by *Strongyloidiasis*. The diagnosis can be made by parasitological examination of feces, although with a low sensitivity. Treatment is effective with Albendazole or Ivermectin. The case described also highlights the importance of the biopsy, fundamental for the definitive diagnosis of the case, since the imaging indicated a neoplastic cause. Thus, we must have a high index of suspicion in individuals coming from endemic regions, in order to obtain an early diagnosis and treatment.

#1520 - Case Report

RELAPSING KALA-AZAR WITH GASTROINTESTINAL INVOLVEMENT IN AN HIV CO-INFECTED PATIENT

João Pedro Ferreira Queirós¹, João Fonseca Oliveira², Miguel Nunes², Francisca Martins², Diana Simão², Maria Amaral², Sofia Pinheiro²

¹ Medicina 2.3, Hospital Santo António dos Capuchos, Centro Hospitalar de Lisboa Central, Lisboa, Portugal

² Medicina 2.3, Hospital Santo António dos Capuchos, Centro Hospitalar de Lisboa Central., Lisboa, Portugal

Introduction

Current guidelines regarding the management of relapsing visceral leishmaniasis (VL) in HIV-co-infected patients are scarce. Therapeutic decisions are often based on case series or expert opinion. To the best of our knowledge, liposomal amphotericin B (LAB) is the first line treatment. We present a case of relapsing VL in an HIV co-infected patient despite monthly prophylaxis with LAB.

Case description

54 year-old man with a two-week history of bilateral lower limb edema. He reported dyspepsia, asthenia, anorexia and weight loss during the past 4 years and weighted 52 kg. He denied fever, dyspnea, or night sweats. He reported chronic bland stools.

He had a history of AIDS (CD4 = 160/mm³ despite undetectable viral load), cured hepatitis C, past tuberculosis and relapsing VL currently under monthly prophylaxis with LAB.

On examination, his vitals were normal; he looked severely malnourished and had a much-distended abdomen with no ascites. He had a tender and palpable liver and splenomegaly. He had bilateral lower limb edemas with a positive godet sign up to the groin. The rest of the examination was unremarkable.

Laboratory tests revealed a moderate microcytic anemia (hemoglobin: 8.6 g/L), ferroopenia, severe hypoalbuminemia (15 g/L), an ESR of 84 mm/h and normal liver and kidney function, no hepatic cytolysis or cholestasis, normal levels of alpha-fetoprotein and a normal urinalysis.

An echocardiogram and bronchoalveolar lavage were unremarkable.

An abdominal CT-scan was remarkable for hepatosplenomegaly and countless intraperitoneal and retroperitoneal adenopathies, similar to a previous scan. Marrow aspirate and duodenal biopsies revealed infiltrates with abundant amastigotes compatible with *Leishmania* spp.

He was then treated with diuretics, iron replacement and a combined therapy of miltefosine 50mg bid, atovaquone 750 mg bid and meglumine antimoniate 20mg/kg id for 28 days.

At discharge his edemas had reabsorbed, his serum albumin level was 31 g/L, haemoglobin 10 g/L, was weighting 57 kg and had no dyspepsia or anorexia. He had no significant adverse reactions during his hospitalization.

Discussion

Literature on relapsing VL on patients under LAB prophylaxis is lacking. Antibiotic resistance tests are unavailable in Portugal. Despite the patient's recovery, data is insufficient to make an accurate long-term prognosis. This case draws attention to the need for more research on Leishmaniosis and aims to report a successful response to treatment on a relapsing patient.

#1527 - Medical Image

TUBERCULOUS MENINGOENCEPHALITIS

Monika Dvorakova, Tiago Fiúza, Teresa Bernardo, José António Santana Sousa Costa

ULSLA, Santiago Do Cacém, Portugal

Clinical summary

A 61-year old patient was admitted to an Emergency service with GCS 9 (O3V2M4), trismus and generalized tremors. The first CT scan of the brain was performed showing no acute pathology. Suspecting neuro-infection, lumbar puncture was done followed by an empiric treatment involving antituberculous medication. Nevertheless, the neurological status was deteriorating, leading to paraparesis and stiff neck. In 3 weeks the second CT scan was conducted showing ectasia of the supratentorial ventricular system with obliteration of the cerebral cortical sulci confirming active hydrocephalus. The patient was immediately transported to Neurosurgery department to undergo ventricular peritoneal shunt. Later on, a positive result of alcohol-acid resistant bacilli in liquor was confirmed.

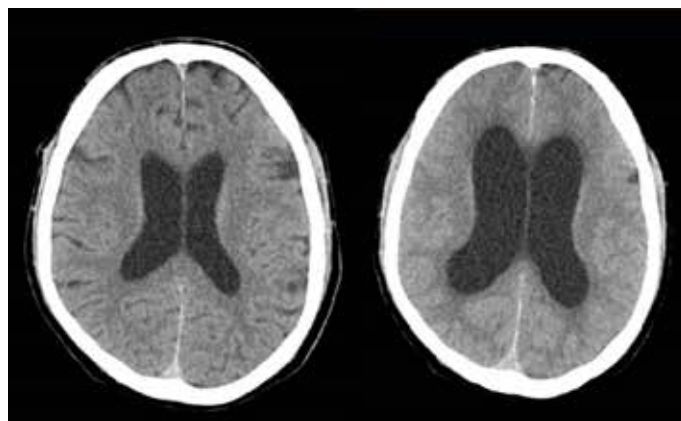


Figure #1527. 1st & 2nd CT scan.

#1530 - Case Report

AN ATYPICAL CASE OF PERITONEAL TUBERCULOSIS IN AN IMMUNOCOMPETENT YOUNG WOMAN

Inês Ladeira Figueiredo, Cristina Maria Duarte, Luísa Fraga Fontes
Hospital Cuf Descobertas, Lisbon, Portugal

Introduction

Tuberculosis is a very prevalent disease in the world, but its incidence had decreased in Portugal in the last few years, specially in immunocompetent patients.

The authors report a case of a young woman with ascitis and fever, without other relevant clinical data and with all complementary tests inconclusive. The diagnosis was made only after therapeutic trial with tuberculostatic medication.

Case description

A 25 years old woman born in Angola, living in Lisbon since 3 months ago, without relevant past history, came to ER with increased abdominal perimeter and fever with 10 days of evolution. Abdominal ultrasound and CT scan revealed voluminous ascitis. Gynecology specialist observed the patient and excluded gynecologic disease. Blood tests revealed mild anemia, thrombocytosis, increased CRP and ESR, hypoalbuminemia and negative β -hcg. During hospitalization she maintained fever (39°C) and increased inflammatory parameters. HIV, hepatitis, VDRL tests and autoantibodies were negative, and IGRA was indetermined (0.39). The ascitic fluid showed increased lymphocytes and ADA, sero-ascitic albumin gradient 1.3, PCR and direct BK both negative. The cytology was inconclusive. We considered two possible diagnosis: spontaneous bacterial peritonitis and peritoneal tuberculosis. We started antibiotherapy with cefotaxime EV. Eight days later, the fever persisted and so she underwent to diagnostic laparoscopy, collecting more ascitic fluid and some tissues (which revealed no granulomes and no neoplastic cells, negative for PAS, Ziehl Nielsen and Grocott). We decided to start therapeutic test with quadruple tuberculostatic medication. Two days later, patient had no fever, with a consistent decrease of inflammatory parameters and no recurrence of ascitis. She was discharged from hospital and two weeks after she came

to outpatient appointment, asymptomatic and with normal values blood tests. Culture in Lowenstein was negative for Mycobacterium tuberculosis, but PCR from the biopsed tissues were positive for an atypical mycobacteria.

Discussion

Peritoneal tuberculosis is an uncommon form of disease presentation in immunocompetent patients, but we must not forget it in differential diagnosis of ascitis. When the tests are inconclusive, we must consider the therapeutic trial with tuberculostatic medication and when a patient had a good response we should not give up about searching for the agent, because the atypical ones are rare but they can be so dangerous as the most studied Mycobacterium tuberculosis.

#1542 - Medical Image

SPONDYLODISCITIS: AN IMAGE

Ana Carlota Vida, Cláudia Lemos, Graça Dias, Maria Da Luz Brazão
Hospital Central do Funchal, Madeira, Portugal

Clinical summary

We report the case of a woman, 60 years old, who went to the ER for a bilateral stabbing lumbar pain with 2 weeks of evolution. Her analytic results showed leucocytosis 15600 μ /L, Neut 89.3% and PCR 160 mg/L. She was admitted with pyelonephritis. Eventually, a MRSA was isolated in her blood cultures. As she maintained an accentuated lumbar pain, a lumbar CT was performed revealing an osteolytic alteration of the L3-L4 somatic regions, with involvement of the subchondral regions, co-existing with a hypodensity of the inter-somatic disc, suggesting Spondylodiscitis of L3/L4. The alterations seen in these images are very typical of this condition and the lumbar region, the most frequently involved. If a high index of clinical suspicion is present, imaging is fundamental to make diagnosis.

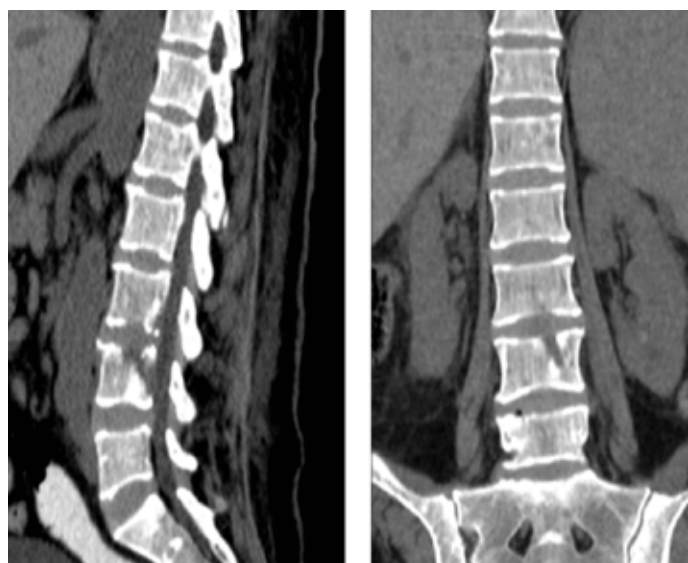

Figure #1542. Spondylodiscitis in lumbar spine - CT images demonstrate osteolytic alterations of L3/L4 segments with irregularities of the plateaus of the vertebral bodies.

#1555 - Case Report

KAPOSI'S SARCOMA IN HIV POSITIVE AND KAPOSI'S SACOMA INFLAMMATORY CYSTOKINE SYNDROME

Thaisy Marques Secco¹, Renata Fachada^{1,2}, Bianca Feldman¹, Rafaela Mamfrim¹, Thales Rizzi¹, Victor Bemfica¹, Raissa De Moraes Perlingeiro³, Marcel Treptow Ferreira³, Hugo Boechat Andrade³

¹ Hospital Municipal Miguel Couto, Rio De Janeiro, Brazil

² Fundação Técnica Souza Marques, Rio de Janeiro, Brazil

³ Instituto Nacional de Infectologia Evandro Chagas, Rio De Janeiro, Brazil

Introduction

Kaposi's sarcoma (KS) is a multifocal angioproliferative neoplasm of viral etiology and multifactorial pathogenesis, characterized by the presence of hyperpigmented skin lesions, which can affect skin and organs such as lung and gastrointestinal tract, presenting a wide variety of clinical manifestations.

Case description

A 30-year-old male from Pará state of Brazil, admitted to the hospital with a report of fifteen days of abdominal distension, lower limb edema and continuous fever (38°C), evolved with dyspnea on minimal exertion. On physical examination, there were erythematous-violet skin nodules mainly on the trunk, cervical lymph node enlargement, painful abdomen diffusely palpation and anasarca. In laboratory tests he presented pancytopenia of evolutionary worsening during hospitalization (hematocrit 14.1%; hemoglobin 4.8 g/dL; leukocytes 4700 uL and platelets 52000 uL) and rapid test for HIV positive, later confirmed with viral load 136,634 and CD4 33. Computed tomography showed bilateral left pleural effusion, ascites and hepatosplenomegaly.

A biopsy of the skin lesions was performed, with the conclusion was SK with positive immunohistochemistry for anti-HHV-8 antibody, and treatment with Paclitaxel for SK disseminated was started. During the course of hospitalization, the patient evolved with respiratory failure, renal insufficiency requiring renal replacement therapy and hemodynamic instability necessitating invasive support and vasoactive drugs. After four cycles of paclitaxel patient presented stability and clinical improvement, but evolved with an important enterorrhagia, hypovolemic shock and death.

Discussion

SK is caused by herpes virus type 8 (HHV-8), related to Acquired Immunodeficiency Syndrome (AIDS). Patients with KS who progress to more severe conditions, specifically the cases that mimic severe sepsis, need ventilatory and vasopressor support due to the development of acute respiratory distress syndrome and hemodynamic instability. Such patients may be faced with Kaposi's Sacoma Inflammatory Cytokine Syndrome (KICS), but, unlike severe sepsis, antibiotics do not provide benefits, and chemotherapy is the treatment of choice. In view of the clinical improvement that occurred in our patient after treatment with paclitaxel, and the non-

diagnosis of bacterial or fungal disease after extensive investigation, we can consider the KICS condition by exclusion.

#1562 - Abstract

SCREENING SEPSIS DURING RAPID RESPOND

Mulham Shikh Hamdon, Toribiong Uchel, Neeharika Ralh, Shubhkarman Dhillon, Mohammad Fityan
Wayne State University, Detroit, United States

Background

Sepsis carries a high mortality rate and thus requires prompt recognition and treatment. In our hospital, we evaluated the efficiency of the rapid response team (RRT) in recognizing sepsis as the reason for rapid response initiation (RRI).

Methods

A single center retrospective study evaluated patient over 6-months duration in which rapid response was initiated. Patients identified as sepsis upon admission were excluded. Patients were evaluated if they met sepsis criteria. The patients who were septic during rapid response were further studied in regards to reason for RRI.

Results

129 patient charts were reviewed, 22 identified as sepsis. Reasons for RRI were as follows: 6/22 had atrial fibrillation with rapid ventricular response (RVR), 5/22 had hypotension, 1/22 had combined atrial fibrillation with RVR, 5/22 had dyspnea with acute hypoxia, 4/22 had chest pain, and 1/22 had acute encephalopathy. 6/22 were identified and managed by RRT as sepsis. Those who were correctly identified had RRI due to hypotension and encephalopathy. 16/22 were septic unidentified and the following complications occurred: 3/16 acute hypoxic respiratory failure (1 required endotracheal intubation), 1/16 acute tubular necrosis, 7/16 transferred to ICU for closer monitoring. Most common reason for missed sepsis was atrial fibrillation with RVR.

Conclusion

In this study, we identified the most common reasons for rapid response initiation and the complications when sepsis went unidentified. During rapid response, RRT should not solely focus on the reasons for its initiation but always have a low threshold sepsis especially when SIRS is positive.

#1563 - Case Report

ERYTHEMA INDURATUM DE BAZIN – A CASE REPORT

Rebeca Martins Natal, Vasco Neves, Pedro Ventura
Local Health Unit of Guarda, Guarda, Portugal

Introduction

Erythema Induratum De Bazin (EIB) belongs to the group of

tuberculides, a subcategory of tuberculosis (TB)-associated cutaneous disorders, a rare entity, which likely represent a hypersensitivity reaction to Mycobacterium tuberculosis (MT) antigens. It classically presents as mildly tender, dull red subcutaneous nodules on the posterior aspect of the lower legs.

Case description

The presented clinical case refers to a 52-years-old female, active smoker (30 pack-year units) with dyslipidemia and chronic laryngitis, without any chronic medication. No previous medical history of TB or pulmonary infections, nor recent contacts with TB patients. This patient was sent to the outpatient clinic because of the presence of multiple pericentimetric subcutaneous nodules on the limbs, dull and slightly tender with remitting-relapsing character with 1 year of evolution. No other symptoms were described. Laboratorial: IGRA positive, without any other change, including negativity for HIV or hepatitis. Biopsy of one of the lesions revealed lobular panniculitis with foci of necrosis and presence of surrounding granulomas, consistent with EIB. Direct and cultural examination for mycobacteria of sputum was negative and thoracic CT showed discrete lesions of centrilobular emphysema, excluding pulmonary TB. The patient was then sent to community pneumological diagnostic center (PDC), where she underwent anti-TB regimen with complete remission of skin lesions.

Discussion

Tuberculides are characterized by: failure to detect MT in direct and cultural examination of the affected tissue; presence of detectable extracutaneous MT infection, positive tuberculin skin test or positive IGRA; histopathology with granulomatous inflammation in skin lesions; frequent resolution of skin lesions with anti-TB therapy. Clinical recognition, histopathology and evidence of MT infection are the key to the diagnosis of EIB. Initial treatment is the same multidrug regimen as for systemic TB followed by a longer maintenance phase, so this patient is being followed at the PDC.

#1582 - Case Report

ACTINOMYCOSIS – DIFFERENTIAL DIAGNOSIS OF A PULMONARY NODULE

Ricardo Reis Veloso¹, Ana Simas¹, Maria Menezes², Ana Silveira¹, Juvenal Morais¹, Ana Alves¹, Mariela Rodrigues¹, Joana Decq Mota¹, Fátima Pinto¹, António Goulart¹

¹ Hospital da Horta, Horta, Faial, Açores, Portugal

² Hospital do Espírito Santo de Évora, Évora, Portugal

Introduction

Actinomycosis is an infection caused by Actinomyces, Gram-positive anaerobic bacteria that colonize the oral cavity. It is characterized by contiguous spread, with the formation of multiple abscesses and sulfur granules, with the last being pathognomonic of this infection. It's more common in male, and the main clinical forms are cervicofacial, thoracic and abdominal, including also pelvic

manifestations, mainly in females. It's rare in developed countries and it's usually associated with poor oral hygiene. Because it has an indolent and infiltrative growth pattern, the differential diagnosis with neoplasms of the affected region is relatively common.

Case description

Male, 69 years old. Smoker (with 70 smoking pack years), with no other known medical history.

Admitted in the emergency department, presenting dyspnea and orthopnea lasting for one week, with no other associated symptoms. The physical examination revealed a reduced peripheral oxygen saturation (88%) and globally diminished breathing sounds along with disperse wheezing on pulmonary auscultation. Blood analysis showed leukocytosis and elevation of C-reactive protein levels. Thoracic radiography showed a perihilar lesion on the right lung.

He was admitted to the Medicine ward with the diagnosis of a respiratory infection.

Thoracic computed tomography (CT) revealed a right inferior lobe lesion with suspicious characteristics. He was observed by a pneumologist, and was submitted to a bronchofibroscopy that showed findings suggesting reactive inflammation. Bronchial aspirate and brushing was obtained during the procedure, as well as a biopsy of the right main bronchus. All the analysis of these biological products turned out negative for the presence of malignant or inflammatory cells.

Imaging reevaluation, with another thoracic CT showed no change in the suspicious lesion, and a transthoracic needle biopsy was obtained. The anatomopathological study revealed findings compatible with Actinomyces infection, with no malignant cells.

The patient started antibiotic treatment with 2g of Amoxicillin twice a day, and was discharged maintaining this treatment.

He returned for an external consultation one month after, with a significant improvement of his clinical state.

Discussion

This case report displays the importance of being aware of uncommon differential diagnosis. In this particular case, the diagnosis was essential to grant the correct therapeutic approach, in a clinical situation with an initial presumptive bad prognosis.

#1583 - Case Report

A TRAUMATIC INFECTION

Joana Silva Marques¹, Giovana Clare Ennis¹, Joana Correia¹, Bruno Barbosa¹, Luis Patrão², Nuno Monteiro²

¹ Centro Hospitalar Tondela-Viseu, Viseu, Portugal

² Centro Hospitalar Tondela Viseu, Viseu, Portugal

Introduction

PubMed search using the terms pyogenic spondylodiscitis identified 33 case reports in the last 10 years, 1 in Portugal.

We report a case of septic shock due to *S. aureus* and pyogenic spondylodiscitis.

Case description

A 57-year-old man went to Emergency Department after trauma, resulting in pain in his upper left limb with functional impotence, hematoma and excoriations in the frontal region and left neck pain. He was discharged with analgesia, rest and cryotherapy. He returned two days later with fever and somnolence.

He had previous history of severe alcohol consumption and mild mental retardation. He did not take regular medication.

On examination, he was somnolent, hypotensive (79/47 mmHg), febrile (39.3°C) and dyspnoeic. Lab work showed C - reactive protein (CRP) 36.68 mg/dL, procalcitonin 19.32 ng/mL, urea 211mg/dL and creatinine 2.8 mg/dL. Chest X-ray and urine test strip were normal. Head Computerized Tomography (CT) had no changes. Cervical and dorsal CT showed posterior osteophytosis of C3-7 with deviation of the medulla, bilateral osteoarthritis with narrowing of C4-5 and C5-6.

He started ceftriaxone and azithromycin with no clinical improvement. Lumbar puncture was performed, and cerebrospinal fluid analysis was compatible with bacterial meningitis, with no microbial development. Antibiotic therapy was adjusted to ceftriaxone 2 g twice a day and ampicillin.

After 48 hours he was awake, with tetraparesis and abolished osteotendinous reflexes, hemodynamic instability and respiratory failure. At this moment he was admitted in the Intensive Care Unit. Thinking in transverse myelitis he made a cervical and dorsal Magnetic Resonance Imaging that revealed C5-C6 spondylodiscitis and C1-7 epidural abscess. Microbiologic study identified Methicillin-Sensible *S. aureus* (MSSA) in secretions, urine and blood. A C5-6 discectomy with epidural abscess drainage and C5-6 arthrodesis was performed and antibiotic was changed to flucloxacillin for 6 weeks.

He had favourable clinical evolution and at discharge he had no fever, improvement of muscle strength with elbow flexion on the left, CRP 4.68 mg/dL and procalcitonin 0.07 ng/mL.

Discussion

Pyogenic spondylodiscitis is often the result of haematogenous spread, 37% of the patients will not have identifiable source and 5% have a history of blunt trauma.

In the case reported we assumed that trauma could trigger haematogenous spread from the skin, causing spondylodiscitis and all its consequences (epidural abscess and meningitis).

#1584 - Medical Image

NECROTIZING PNEUMONIA IN A IMMUNOCOMPROMISED PATIENT

Daniela Marto, Ana Brito, Hugo Inácio, Miguel Sousa Leite, Sofia Mahomed Mateus, Salvador Morais Sarmiento, Andreia Amaral, Dina Rodriguez Pita, Graça Marote, Catarina Salvado
Centro Hospitalar Universitário de Lisboa Central, Lisbon, Portugal

Clinical summary

68 year-old ex-smoker woman with history of metastatic lung

adenocarcinoma (brain, bone and liver), submitted to radiotherapy, and presently treated with immunotherapy (nivolumab) and dexamethasone, admitted to ward with left superior lobe pneumonia.

The thoracic computed tomography documented subpleural apical consolidation areas and several cavitations.

The hypothesis of tuberculosis was ruled out (acid-fast bacilli smear and nucleic acid amplification test were negative in sputum, gastric lavage and bronchoalveolar lavage). Galactomannan antigen was positive (1.8628) in bronchoalveolar lavage and, despite of sterile fungal culture, the diagnosis of necrotizing pneumonia due to *Aspergillus* was assumed.

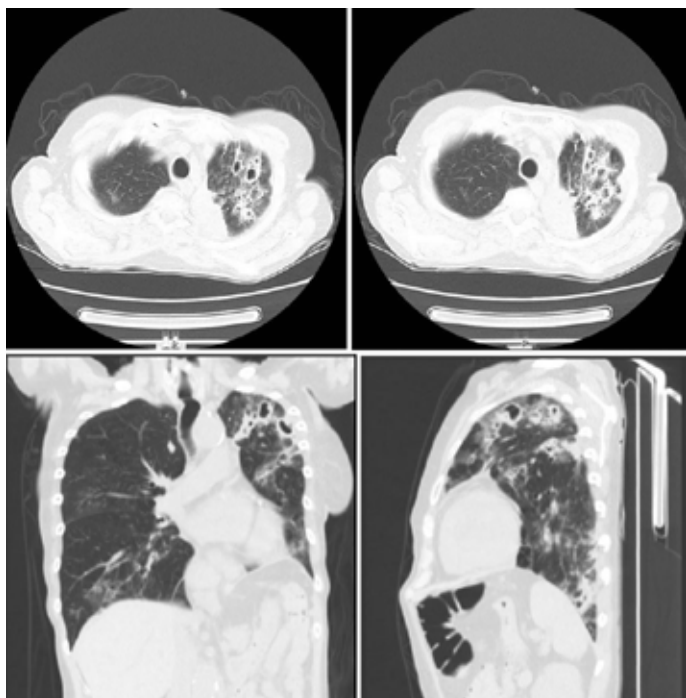


Figure #1584. Thoracic computed tomography: left apical consolidation areas and several cavitations.

#1591 - Case Report

SALMONELLA TIPHYMURIUM PNEUMONIA – CLINICAL CASE

André Aparício Martins^{1,2}, Bárbara Araújo^{1,2}, Elsa Gaspar^{1,2}, Lèlita Santos^{1,2}, Armando Carvalho^{1,2}

¹. Internal Medicine Department, Coimbra Hospital and University Centre, Coimbra, Portugal

². Internal Medicine University Clinic, Faculty of Medicine University of Coimbra, Coimbra, Portugal

Introduction

Gastroenteritis is the most frequent clinical presentation of non-typhoidal *Salmonella* (NTS) infections. However, invasive infections like bacteraemia or extra-intestinal infections are other possible manifestations. These last occur in only 1,8% of the cases and although the lungs are within the more common extra-intestinal locations, the pneumonias caused by NTS as *Salmonella*

tiphymurium (ST) are rare, with few cases reported in literature. A PubMed search revealed 5 case reports of ST pneumonia.

Case description

A 64-year-old white male was admitted in the emergency department complying of productive cough with purulent sputum, myalgias, asthenia and fever within 4 days. He had a past of chronic lymphocytic leukemia (LLC) and smoking habits. He lived in a rural area, contacting with animals and consuming agropecuary products without safety guarantee. On physical examination he had spread wheezes and bibasal crackles predominantly on the right pulmonary field. The arterial blood gas test revealed a type 1 respiratory insufficiency. Analytically he had leucocytosis with neutrophilia and reactive C protein elevation. The chest radiography showed accentuation of bronchovascular markings in the right field, with a homolateral paracardiac infiltrate. Blood cultures were obtained, and the patient was hospitalized with the diagnosis of community acquired pneumonia. He started empirical antibiotherapy with amoxicillin/clavulanic acid and azithromycin. On the second day of hospitalization the blood cultures were positive for ST resistant to amoxicillin/clavulanic acid, with the inherent change to ciprofloxacin. Due to a good clinical and analytical evolution the patient had medical release on the third day, completing 14 days of antibiotherapy in ambulatory.

Discussion

ST is an uncommon etiological agent of pneumonia. However, a high suspicion allied to a complete anamnesis can reveal risk factors to such type of infection. The NTS pneumonias affect predominantly patients with some immunodeficiency grade, like the LLC, or with some previous pulmonary disease, non-presented by this patient. Despite this, his past smoking habits may predispose for subclinical pulmonary diseases. In addition, the contact with animals and the consumption of agropecuary products potentially contaminated are risk factors to NTS infection. The bacteraemia showed by the positive blood cultures is concordant with the hematogenous dissemination as the main physiopathological mechanism for NTS pneumonia.

#1604 - Medical Image

THORACIC ENDOVASCULAR AORTIC GRAFT – THE HIDDEN CULPRIT

Tatiana Costa Pires, Adriana Bandeira, Miguel Gonzalez Santos, Rita Lizardo Grácio, Maria Conceição Neves, Ana Ubach Ferrão, Alcina Ponte

Centro Hospitalar de Leiria, Leiria, Portugal

Clinical summary

J.B. is a 64-years-old man admitted in the Emergency department for decreased urinary output and fever. He was started on antibiotics and admitted to hospital for acute pyelonephritis. After admission, he developed sudden onset dyspnea. The images presented are of the chest CT angiograph taken at the

time. The pleural effusion was a haemothorax but, although the deformity of the thoracic aorta (with an endovascular graft placed previously due to mega aorta syndrome) is outstanding, there was no evidence of active bleeding from this site. From an infection point of view, there was no improvement. Blood and other fluids cultures were repeatedly negative and a wider search for a source of infection yielded no results. The diagnostic of a vascular graft infection was then made.

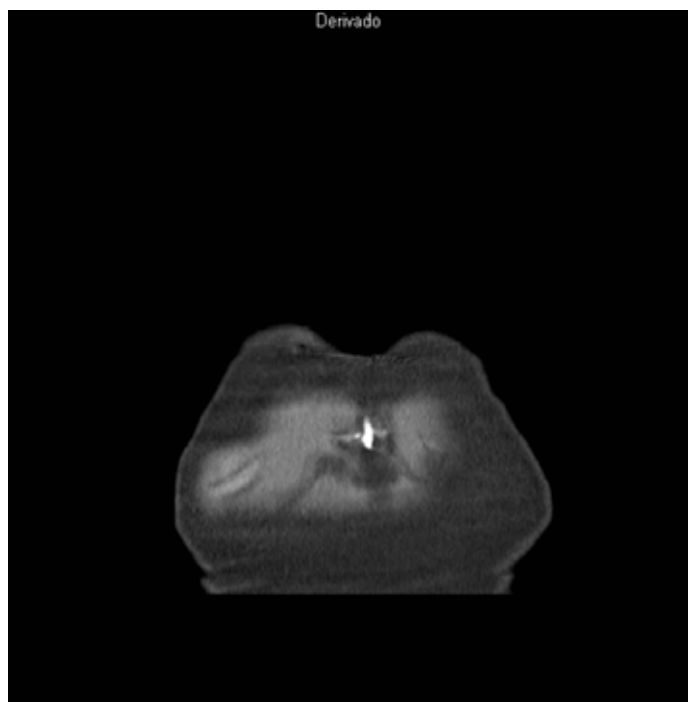


Figure #1604. Chest CT showing left pleural effusion and abnormal thoracic aorta. 3D reconstruction of the aorta (with intravascular graft).

#1606 - Case Report

INFECTIVE ENDOCARDITIS - UNDER SUSPICION UNTIL THE COMPLICATIONS

Maria Margarida Robalo, Emanuel Costa, Joana Sotto Mayor, Sofia Esperança, António Oliveira E Silva
Hospital de Braga, Braga, Portugal

Introduction

Cerebrovascular accidents are one of the most serious complications of Infective Endocarditis (IE), affecting more than 40% of patients with this entity. Early diagnosis and intervention can minimize the long-term morbimortality.

Case description

A 58-year-old man with an aortic mechanical prosthetic valve, was hospitalized for fever of unknown origin, with no other changes to the physical examination. Transesophageal echocardiography (TEE) on the 3rd day of hospitalization revealed no signs of IE. Blood cultures were positive for *Staphylococcus aureus*. Giving the probability of IE in the absence endocardium lesions, treatment

with flucloxacillin, gentamicin and rifampicin was prescribed with a good clinical response on the first 4 days of therapy. At the 10th day of hospitalization, the patient was presented with fever, increased systolic murmur and progressive left hemiparesis. Cranial MRI and CT scan showed multiple infarcts, probably secondary to septic emboli, one of which associated with a massive hemorrhage. TEE confirmed the clinical suspicion: IE of the prosthetic valve, with a 6mm vegetation. Drainage of the hemorrhage was performed without complications. The antibiotic regimen was completed at the hospital and the patient began a functional rehabilitation program, with an excellent evolution of the neurological deficits.

Discussion

Although IE is a rare disease, it has a high morbidity rate and serious complications, such as acute stroke. Therefore, the importance of prompt detection and treatment of IE and its exclusion in patients with cardioembolic stroke and risk factors, always dependent on a high clinical suspicion, is easily understood.

#1608 - Case Report

TOXOPLASMOSIS IN AN IMMUNOCOMPETENT HOST - AN UNCOMMON COURSE

Rita Gamboa Cunha, Mariana Certal, Sandra Tavares, Catarina Costa, Sofia Perdigão
CHTMAD - Hospital de Chaves, Vila Real, Portugal

Introduction

Toxoplasmosis is an infection with a worldwide distribution that is most commonly reported in immunocompromised patients such as human immunodeficiency virus infection, chemotherapy and bone marrow transplant. In immunocompetent patients, *Toxoplasma gondii* is usually asymptomatic (80%), or most commonly present with lymphadenopathy.

Case description

41-year-old Caucasian female without relevant past medical history that usually spends 6 months of the year in Peru and the other 6 in Portugal. She began complaining in March 2017 of fever around 38°C along with cervical and retromandibular painful adenopathy, fatigue, weight loss and loss of visual acuity. The laboratory studies in July 2017 revealed a normal blood count, normal ESR, negative Syphilis, Epstein-Barr virus, human immunodeficiency viruses, Hepatitis C virus and Hepatitis B virus. She did have Anti-Toxoplasma Gondii antibodies IgM of 230 UI/mL and IgM >40. The fever lasted 2 months but the patient maintained complaints of fatigue. Due to an unintended pregnancy the patient performed a new laboratory study in October 2017 which presented with Anti-Toxoplasma Gondii antibodies IgM >700 UI/mL and IgM of 26.59. She was medicated with Spiramycin but decided not to take it since she decided to perform an induced abortion. She lost hospital follow-up. Since then she maintained

complaints of fatigue, weight loss but no fever so she repeated the laboratory studies in September 2018 that revealed Anti-Toxoplasma Gondii antibodies IgM of 637.8 UI/mL and IgM of 10.3. She was referred to an internal medicine consultation and at observation in January 2019 she was conscious, with stable vitals, normal cardiac and pulmonary auscultation and no abdominal alterations. She presented with small lymphadenopathy of the neck and supraclavicular regions. The laboratory studies revealed Anti-Toxoplasma Gondii antibodies IgM of 64.9 UI/mL and IgM of 1.91. The patient presented gradual improvement of the condition.

Discussion

A symptomatic toxoplasmosis in an immunocompetent patient is not common. Most immunocompetent patients have a benign and self-limited course lasting from weeks to months but rarely longer than a year. It is also known that IgG antibodies peak in six to eight weeks and then decline over the next two years and IgM antibodies can persist for several years. In this case the patient remained symptomatic for over a year, with a dragged presentation and a slow decrease in the IgG levels, an uncommon course.

#1619 - Abstract

PROBABILITY OF TARGET ATTAINMENT WITH FLUCLOXACILLIN IN STAPHYLOCOCCUS AUREUS BLOODSTREAM INFECTION: A PROSPECTIVE COHORT STUDY

Stephan Moser, Sophia Rehm, Katharina Rentsch, Vladimira Hinic, Stefano Bassetti, Michael Osthoff

University Hospital Basel, Basel, Switzerland

Background

Methicillin-sensitive *Staphylococcus aureus* bloodstream infection (MSSA-SAB) is associated with considerable mortality despite immediate treatment with β -lactam antibiotics. Contemporary data regarding the pharmacology of flucloxacillin (FCX), a highly protein bound anti-staphylococcal antibiotic, are scarce. The purpose of this study was to document the probability of pharmacological target attainment with standard intermittent bolus administration of FCX using individual minimal inhibitory concentrations (MIC) in patients with MSSA-SAB.

Methods

44 MSSA-SAB patients were prospectively enrolled in a Swiss tertiary care center. Unbound plasma FCX concentrations were measured using a validated LC-MS method at five time points during the first week, and oxacillin MICs of all strains were determined by Etest®. Target attainment (%fT>individual MIC) and associated factors were analyzed.

Results

Median age and SOFA score on admission were 62 years and 3, respectively, and 48% were admitted to the intensive-care unit. The most common diagnosis in MSSA-SAB patients was endocarditis

(21%). Median MIC of *S. aureus* strains was 0.5mg/L. Median mid-dose concentration of unbound FCX was 5 (interquartile range (IQR) 2-20) and 5 (IQR 2-20) mg/L on day 1 and 3, respectively, and median trough concentration was 2 (IQR 1-11), 4 (0.3-9) and 1 (1-5) mg/L on day 1, 3 and 7, respectively.

The probability of minimum, optimal and maximum target attainment at all time points were 93% (50% fT>MIC), 65% (100% fT>MIC) and 32% (100% fT>4xMIC), respectively, and 16% had at least one trough level >20 mg/L (in the potentially toxic range). The unbound fraction showed a wide inter-individual (range 3-65%) but not intra-individual variation, and correlated positively with the SOFA score, lactic acid and respiratory rate, and negatively with renal function and albumin on admission ($p<0.05$). Optimal target achievement was significantly associated with more severe disease (higher SOFA score and lower systolic blood pressure on admission) and impaired renal function.

Conclusion

The unbound plasma fraction of FCX is substantially higher in MSSA-SAB patients than reported for healthy individuals (<10%) in particular in patients with more severe disease. The proportion of patients not achieving the optimal pharmacological target was significant, as was the proportion with excessive FCX concentrations. Therefore, therapeutic drug monitoring of unbound FCX concentrations in MSSA-SAB is desirable.

#1624 - Case Report

CAVITARY LUNG LESION: CASE REPORT

Andreia Coutinho, João Correia Cardoso, Joana Cordeiro Cunha, Violeta Iglesias, Augusto Duarte

Centro Hospitalar Médio Ave, V. N. Famalicão, Portugal

Introduction

The etiological diagnosis of cavitary lung lesions is challenging due to the variety of possible causes, depending on anamnesis, physical examination and evolution. The major causes are infections, cancers and rheumatic diseases.

Case description

Male, 57 years old, history of arterial hypertension, presented with two-week duration cough and hemoptoic sputum, low fever, weight loss (3Kg in 2 months) and anterior right pleuritic pain. He had contacted with a tuberculosis patient. Physical examination was normal. Blood analysis showed inflammatory parameters' elevation (Leucocytosis – 12.24×10^3 u/L, neutrophilia and C reactive protein – 16.46 mg/dL). Chest radiograph showed cavitating parenchymal densification in the right upper lobe and chest CT scan showed a nodule in the apical segment of the right upper lobe with 36 mm, suggestive of either lung cancer or tuberculosis. Five sputum samples were collected, all negative for bacteria or Koch bacillus (direct exam, PCR and cultural). Immunologic study: Aspergillus precipitins were negative, but Aspergillus fumigatus specific IgG was positive (41.7mg/dL).

A bronchofibroscopy was performed, and the bacteriologic, mycological, fungi and cytological analysis of bronchoalveolar lavage were all negative. During hospital admission, he was treated with amoxicillin/clavulanate and had a favourable clinical, analytical and radiological evolution. Chest CT scan after 13 days of admission: large decrease in parenchymal consolidation involving the cavity; now with thin wall, probable relation with inflammatory/infectious lesion in resolution. A lung lesion biopsy was planned but finally not performed due to radiological findings in the second CT scan. The clinical evolution and the results of the exams allowed us to conclude that this was a bacterial superinfection of a cavitory lesion caused by a fungal infection. The patient was asymptomatic at discharged and keeps on surveillance in regularly consults, without any specific treatment.

Discussion

This case stands out the importance of clinical evolution as an essential part in the route of diagnostic investigation and treatment of this patient, despite the initial most probable differential diagnosis.

#1630 - Medical Image

CAVITARY LUNG LESIONS

Tânia Ferreira, Sara Martins, Márcia Cravo, César Vidal, João Borges, Rui Antunes

Centro Hospitalar Universitário do Porto, Porto, Portugal

Clinical summary

47-years old female brought to emergency department with a 6-month history of asthenia, anorexia, weight loss, low-grade fever and cough. On physical exam presented severe cachexia and type 1 severe respiratory failure. Chest X-ray revealed hypertranslucent right hemithorax and multiple hypodense areas on left hemithorax. CT exposed right large cavitations in continuity with pneumothorax; right hilar necrotic/abcedated areas and multiple consolidations on left upper lobe. Admitted at the intensive care unit and started empiric treatment for tuberculosis with a 4-drug regiment but evolved with refractory septic shock with multiorganic failure and died in the first 48h. Acid-fast bacilli bronchial aspirate microscopy, molecular and cultural tests were positive for *Mycobacterium tuberculosis*.

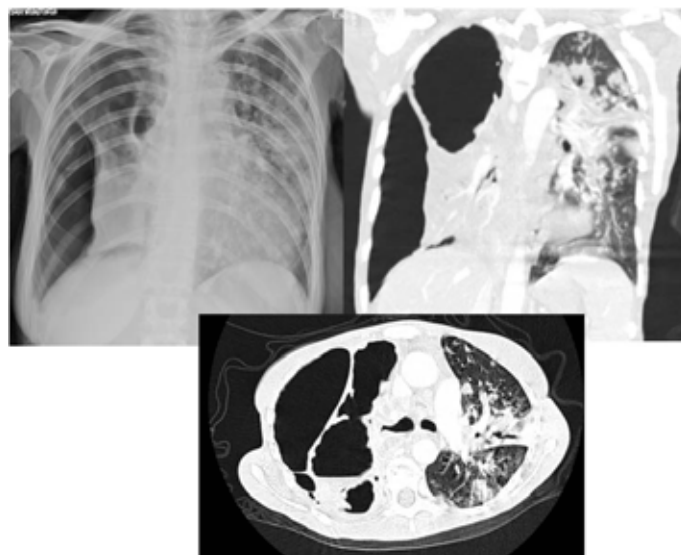


Figure #1630. Cavitory lung lesion.

#1636 - Abstract

PROGNOSTIC FACTORS AND OUTCOME OF HEALTHCARE-ASSOCIATED INFECTIONS IN AN INTERNAL MEDICINE WARD

Eugeniu Gisca, Mário Carlos Amaro, Vilma Lais Grilo, Maria Francisca Delerue

Garcia de Orta Hospital, Almada, Portugal

Background

Healthcare-associated infections (HAI) are acquired during a patient's stay in a hospital or health care facility. It is a major public health problem, has a significant negative impact on prognosis and also on the management of healthcare systems, leading to prolonged hospital stays and higher costs.

The outcome can be significantly different, according to host and microbiological determinants, but it is yet difficult to guide medical approach according to these factors.

We aimed to characterize the HAI of a patient population in an Internal Medicine (IM) ward and assess prognostic factors that could help clinical management.

Methods

Retrospective study in an inpatient population of an IM ward, during a semester of 2018. Statistical analysis of demographic, clinical and microbiological data was performed. Primary endpoint was all-cause mortality and prolonged hospital stay due to HAI.

Results

We included 102 patients, mean age $82 \pm 7,4$ years, 56,8% were female. Most frequent admission diagnosis was cardiovascular (21,6%), respiratory (25,5%) and urological (21,6%) disease. More than half of them (55,9%) had two or more risk factors for immunosuppression, namely age above 65 years (96,1%) and diabetes (39,2%). Nearly half (49%) had two or more external devices, being peripheral vein and urinary catheters the most prevalent, 95,1% and 39,2%, respectively.

The main sources of infection were urinary tract (UT) (59,1%), respiratory (29,5%), gastrointestinal (4,5%) and catheter-associated (4,5%).

Bacteriological identification was possible in 64,4% of cases (gram-negative (GN) bacilli – 53,8%; gram-positive (GP) cocci – 9,1% and GP bacilli – 1,5%), with 25,8% of multidrug resistant bacteria. Large spectrum antibiotics were used in 19,7% of infections.

In-hospital mortality was 13,7%, and 55,9% had a prolonged hospital stay due to HAI.

A statistically significant association was found between UT infections and prolonged hospital stay (OR=2,96 [CI 95% 1,43-6,15] p=0,003). Also, death was 3.57 times more likely in patients with an infection by a microorganism other than GN bacilli (OR=3,57 [CI 95% 1,19-10,75], p=0,017)

Conclusion

Characterization of this high-risk population is essential to define better prevention and treatment strategies. In this population of patients, the identification of GN bacilli was found to be less associated with death comparing to all other cases. Further research is needed characterizing differences in virulence mechanisms between GN and GP bacteria.

#1638 - Case Report

POTT DISEASE - A PROBLEM OF THE PAST IN A NEW CENTURY

Margarida Gaudêncio, Marisa Rosete, Sara Faria, Rui Ferreira, Ivo Barreiro, Isabel Bessa, Amélia Pereira

Internal Medicine Department, District Hospital of Figueira da Foz, Figueira Da Foz, Portugal

Introduction

Tuberculosis is one of the oldest known diseases and one of the leading causes of worldwide infectious disease aetiology. Tuberculous spondylitis or Pott's disease was first described by Hippocrates in 450 BC. It often involves two or more adjacent vertebrae, localized in adults, especially at the level of the dorsal and lumbar spine.

Case description

The case being reported is of a 70-year-old male patient referred to the emergency department for generalized pain, weight loss and asthenia with 2 months of evolution. Physical examination had no changes. Microcytic anaemia (Hb 7,5 g/dL, VGM 75 fl), thrombocytosis of 665,000 and C reactive protein 108 mg/L. The thoraco-abdominopelvic computed tomography (CT) scan revealed the presence of osteolytic fractures in the vertebral bodies of D8-D9 with expansive paravertebral tissue component. He was admitted to the Medical Service for study and began empirically antibiotic therapy with vancomycin and ceftriaxone, as well as, rest in bed and dorsolumbar support. CT scan of the cervico-dorso-lumbar spine, confirming the presence of osteolytic lesion in D9 with soft tissue conglomerate with medullary and radicular

compression, and the possible diagnosis of spondylodiscitis with abscess or secondary lesion was discussed. Septic screening, HIV and hepatitis serology were all negative. The biopsy of the lesion revealed the presence of acid-alcohol resistant bacilli and the isolation of Mycobacterium tuberculosis cultures on Löwenstein-Jensen medium and molecular biology. The patient started therapy with rifampicin, isoniazid, pyrazinamide and ethambutol.

During hospitalization, he had several infections such as sepsis to Klebsiella pneumoniae plus multiresistant Pseudomonas aeruginosa and Cytomegalovirus colitis. He died at the 112th day of internment subsequent to an invasive candidiasis.

Discussion

The current case highlights the importance of considering tuberculosis in differential diagnosis, particularly in spondylitis. It is a disease with a significant number of cases in the past. However, it should not be completely neglected nowadays. The delay in diagnosis is common given the indolent natural history and in the definitive result of the cultural and DNA research.

#1641 - Abstract

DELAYED DIAGNOSIS OF INFECTIVE ENDOCARDITIS IN A JAPANESE TEACHING CARE HOSPITAL

Sho Nishiguchi

Hayama Heart Center, Hayama, Japan

Background

Although infective endocarditis (IE) is known as a severe disease with high mortality, the diagnosis of IE is difficult. We aimed to investigate factors associated with delay in the diagnosis of IE.

Methods

All patients with IE admitted between April 2006 and March 2018 were included. The setting was a Japanese acute teaching care hospital. We used the multivariate Cox proportional hazard model for examining factors associated with delay in the diagnosis of IE. Independent variables included age, gender, activities of daily living, means of transport to medical facilities, Charlson comorbidity index as an assessment of patients comorbidity, chief complain, intravascular prosthesis, fever, shaking chill, hypoxemia, serum C-reactive protein (CRP) concentrations, vegetation on transthoracic echocardiography, caused by staphylococcus aureus, diagnosed by an family physician, and diagnosed by a medical resident.

Results

One-hundred -fifty-five patients with mean age of 70 years were included. The median day to the diagnosis of IE was 5 day with interquartile range, 2-6 days. On multivariate analysis, the time to diagnosis was significantly delayed in patients without fever over 38 degree (hazard ratio [HR], 0.63; 95% confidence interval [CI], 0.392 to 0.997; P=0.048), in patients who did not use by

ambulance (HR, 0.36; 95% CI, 0.199 to 0.666; P=0.001), and in patients with delay in taking blood culture on first visit (HR, 0.24; 95% CI, 0.244 to 0.143; P<0.001).

Conclusion

Delayed diagnosis of IE was associated with patients who attended the medical facility by means other than an ambulance, patients without over 38 degree fever, and delay in taking blood culture on first visit. Physician need to have a heightened awareness of IE, especially among afebrile patients who attended by their foot; this may shorten the day taking the blood culture.

#1642 - Abstract

INAPPROPRIATE USE OF CARBAPENEMS IN THE INTERNAL MEDICINE WARD: IMPACT OF A CARBAPENEM-FOCUSED ANTIMICROBIAL STEWARDSHIP PROGRAM

Antonio Faraone¹, Alice Poggi², Chiara Cappugi³, Lorenzo Tofani⁴, Eleonora Riccobono⁵, Tommaso Gian⁵, Alberto Fortini¹

¹ San Giovanni di Dio Hospital, Internal Medicine Unit, Florence, Italy

² Careggi University Hospital, Florence, Italy

³ Careggi University Hospital, University of Florence, Internal Medicine Unit, Florence, Italy

⁴ Department of Neurosciences, Psychology, Drug Research and Child Health, University of Florence, Florence, Italy

⁵ Department of Experimental and Clinical Medicine, University of Florence, Florence, Italy

Background

Background: Carbapenem consumption is a major driver for selection and spread of carbapenem-resistant Enterobacterales (CRE), which are now hyper-endemic in Italy and other European countries. Antimicrobial stewardship programs (ASP) aim to optimize antimicrobial use and reduce unnecessary prescriptions, in order to prevent the selection of drug-resistant organisms. In May 2016, a carbapenem-focused ASP was implemented at our internal medicine unit, with the aim of specifically limiting the inappropriate use of carbapenem drugs, and ultimately contrast the dissemination of CRE.

Methods

to evaluate the impact of the carbapenem-focused ASP, we realized a before-and-after study, assessing (1) the inappropriateness of carbapenem prescriptions, (2) the proportion of patients treated with carbapenems, and (3) the consumption of carbapenem drugs, respectively in a 1-year pre-intervention (May 2015 – April 2016) and in a 2-year post-intervention period (May 2016 – April 2018). As a secondary objective, we compared the incidence of patients infected by carbapenem-resistant *Klebsiella pneumoniae* (CRKP) and the rate of carbapenem resistance among the invasive isolates of *K. pneumoniae* registered in the same pre- and post-intervention periods.

Results

the rate of inappropriate carbapenem prescriptions declined from 60.7% (65/107) to 29.2% (21/72) and the proportion of patients treated with carbapenems decreased from 2.7% (107/3940) to 0.9% (72/7740). The interrupted time series analysis confirmed a significant change in the rate of inappropriate carbapenem prescriptions (-41.56% per month, p=0.0262) and in the proportion of carbapenem treated patients (-1.82% per month, p=0.0006). Carbapenem use density dropped from 5.2 defined daily doses (DDD) x 100 patient-days to 1.6 DDD x 100 patient-days. The incidence of CRKP infections remained unchanged (29.1 x 100.000 and 28.9 x 100.000 patient-days, respectively before and after the intervention); the percentage of CRKP invasive isolates declined from 36.4% (4/11) to 13.3% (2/15) after the ASP implementation, but the result was not significant (p=0.3478).

Conclusion

the implementation of a carbapenem-focused ASP was effective to rapidly limit the inappropriate and unnecessary use of carbapenem drugs in the internal medicine ward of a medium-sized Italian community hospital. Such effect was sustained during a 2-year post-intervention period and resulted in a significant decrease in carbapenems consumption.

#1662 - Medical Image

PURPLE URINARY BAG SYNDROME: A RARE SIGN OF A COMMON DIAGNOSIS

Jorge Ricardo Rodrigues, Rosa Cardoso, Rita Pereira, Marco Pereira, Manuela Vasconcelos, Margarida Monteiro, António Oliveira Silva

Hospital de Braga, Braga, Portugal

Clinical summary

Purple urinary bag syndrome (PUBS) is a rare and benign clinical presentation, typically associated with urinary tract infections caused by bacteria producers of phosphatase and sulfatase enzymes. It's characterized by the purple discoloration of urinary drainage bag systems triggered by the presence of tryptophan metabolism products in the urine. Tryptophan is metabolized to indole by intestinal bacteria in the gut and converted to indoxyl sulfate in the liver. Then it's catalyzed by bacterial phosphatases and sulfatases to indoxyl, and converted to indigo (blue) and indirubin (red) in the urine, which together create the purple color. The management of PUBS requires treatment of underlying infection, urinary catheters changing and improvement of bowel stasis.

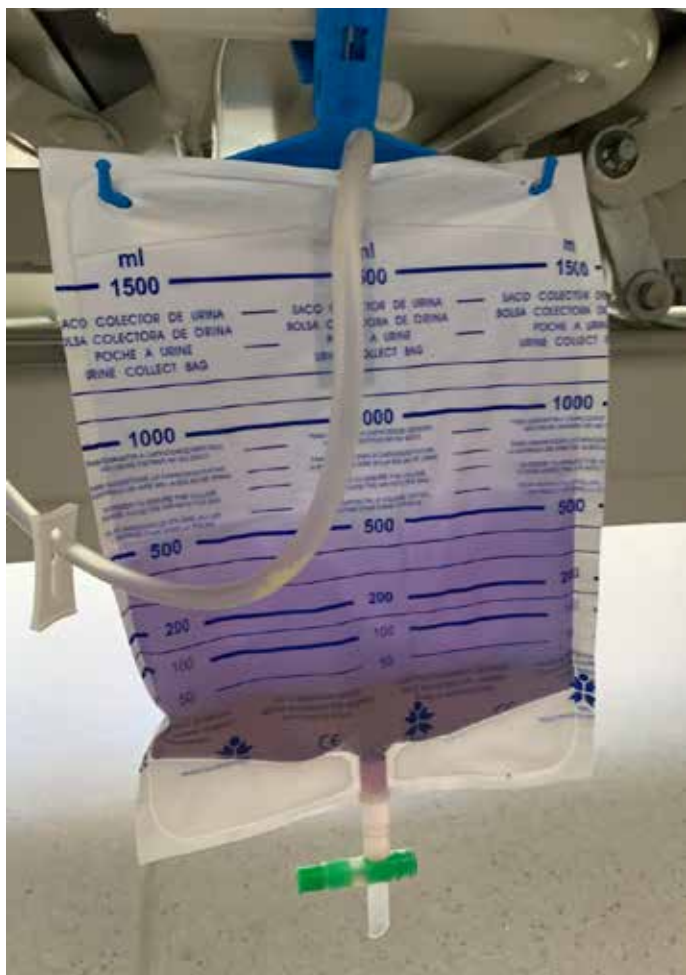


Figure #1662.

#1668 - Case Report

A CASE OF INTRA-CEREBRAL HAEMORRHAGE COMPLICATING HEPATITIS-A VIRUS INFECTION

Pratibha Singh^{1,2}, Shuchi Singh^{1,2}, Saumya Vishnoi^{1,2}

¹ Dr. Ram Manohar Lohiya Hospital, Lucknow, India

² Dr. Ram Manohar Lohiya Institute of Medical Sciences, Lucknow, India

Introduction

Hepatitis A is an acute form of viral hepatitis transmitted by faeco-oral route. It is self-limiting. The prodromal symptoms are systemic and variable. Constitutional symptoms include anorexia, nausea, vomiting, fever and fatigue. Extra-hepatic manifestations of Hepatitis A (HAV) infections are rare.

Intracerebral bleeding is seen occasionally in Hepatitis B and C but we encountered the first case of intracerebral haemorrhage in HAV.

Case description

A 43-years-old female from a disadvantaged risk-prone demographic was admitted with high grade fever and altered sensorium.

There was no cough, vomiting, loose stools, burning micturation or any other focus of infection.

Neither co-morbidities like DM, hypertension, thyroid disease or blood diathesis nor prior signs of trauma or drug intake were seen. Clinical exam noted fever of 102 degree F, 104/min pulse, respiration rate of 20/min and BP at 104/76 mmHg.

Physical examination revealed scleral icterus and altered mental state with asterixes (HE-Stage III).

First lab tests showed raised SGOT, SGPT and no increase in serum ALP levels. PT/INR was 24/1.71. Abdominal ultrasound showed slightly enlarged liver. Other parameters were normal.

The lab tests for viral markers reported IgM anti-HAV +ve but Hepatitis B & C, Dengue NS-1 antigen, IgN, IgG, HIV-1 and 2 were -ve. A CSF examination revealed <5/cu-mm of cells, 45.4 mg% of protein, 104.6 mg% sugar and ADA 2.70/l. India Ink prep tests were -ve.

Patient's condition improved after treatment for acute viral HAV infection with hepatic encephalopathy grade III using broad-spectrum antibiotics and high bowel washes using lactulose.

Subsequent examination showed weakness on right side of the body. Power in right upper limb was 3/5 & 5/5 on the left. It was 3/5 on the right lower limb and 5/5 on the left. Plantar on the right was extensor with brisk reflexes. An MRI brain study with contrast showed signal intensity alterations indicating bleed in fronto-parietal region. MR venography showed prominent venous sinuses with normal flow related enhancements. Bleed was managed with support from neurosurgeon.

Discussion

HCV infection is correlated with increased risk of ICH in young patients. Persistent inflammation causes pathological changes in cerebral arterioles, triggering ICH development. Correlation can also be made with the degree of thrombocytopenia leading to disseminated intracerebral haemorrhage.

In our case, timely detection and management helped us restore the patient's health.

#1670 - Case Report

ENDOGENOUS ENDOPHTHALMITIS BY KLEBSIELLA PNEUMONIAE

Marta Costa, Marlene Sousa, Patrícia Carvalho, Rui Santos, Armando Carvalho
CHUC, Coimbra, Portugal

Introduction

Endogenous endophthalmitis caused by *Klebsiella pneumoniae* is a rare complication of gram-negative sepsis. Most cases of endophthalmitis are exogenous; the remaining result from bacteriemic or fungemic seeding of the eye. Endogenous bacterial endophthalmitis accounts for 2-15% of all cases of endophthalmitis.

Case description

Female, 73-years-old, with history of type 2 diabetes mellitus, arterial hypertension, dyslipidemia, obesity, acute myocardial

infarction in the previous year, chronic stage IV renal insufficiency and bilateral renal lithiasis, carrier of a double J stent. Admitted to the emergency department transferred from a peripheral hospital with diagnosis of urosepsis. At admission, the patient was polypneic and hypotensive (BP: 84/57 mmHg), with no other major changes to the objective examination. Analytically, had creatinine of 4.6 mg/dL, hyperkalemia of 4.9 mmol/L, elevation of C-reactive protein (37.8 mg / dL) and leukocytosis (13,300 μ l). The reno-vesical ultrasound showed non-obstructive bilateral renal calculi. Gasimetrically, she presented with metabolic acidosis (pH 6.9, HCO₃ 14.1 mmol/L, pCO₂ 20.4 mmHg, lactates 1.3 mmol/L) refractory to medical treatment. She underwent a hemodialysis session with good response. Admitted under antibiotic therapy with meropenem. Blood cultures were positive for *Klebsiella pneumoniae*, sensible to meropenem. On the tenth day of hospitalization, the patient presented a painful, red left eye, without improvement with antibiotic eye drops. Endogenous endophthalmitis was diagnosed after evaluation by an ophthalmologist. She underwent mechanical vitrectomy and intravitreal antibiotic therapy with improvement of the condition. No agent was isolated in ocular exudate. The patient had progressive improvement and was discharged oriented to external consultation.

Discussion

The etiology of bacterial endophthalmitis is multifactorial with significant geographic variation, the most common being *Streptococcus*, *Staphylococcus aureus* and gram-negative bacilli. In the majority of described cases, the source of bacteremia was urinary tract infections and liver abscesses. Diabetes mellitus, immunosuppression and intravenous drug use are predisposing factors. The prognosis of this entity, even after immediate treatment, is usually poor, ranging from decreased visual acuity to evisceration or enucleation of the eyeball, so rapid recognition and appropriate treatment is essential.

#1680 - Case Report

PLEURAL EFFUSION IN MYCOPLASMA PNEUMONIAE PNEUMONIA

Maria Bairos Menezes, Carlota Botelho, Vasco Neves, Leila Barrocas, Maria Luisa Corraliza, Conceição Barata
Hospital Espírito Santo, Evora, Portugal

Introduction

Mycoplasma pneumoniae is a common cause of community-acquired pneumonia (CAP) representing about 12% of the etiological pathogens of CAP worldwide. For most patients, the course is mild and recovery is full. A complication such as pleural effusion is rarely reported.

Case description

A 57-year-old woman, elderly care worker, without any relevant medical history, presented at the emergency department with an intense right dorsal pain associated with an eight-day history of

productive cough. The physical examination showed fever and a decreased lung sounds at the left pulmonary base with crepitations. Laboratory results revealed leucocytosis with neutrophilia, type 1 respiratory failure and a mildly elevated C reactive protein. Chest X-ray showed a small left pleural effusion and computed tomography angiography also revealed a 12mm nodule in the right upper lobe with irregular margins. After six days with cephtriaxone and azithromycin to treat a CAP, the patient had a persistent fever, worsening of the left pleural effusion associated with an increase of the inflammatory parameters. Her serum *M. pneumoniae* IgM was positive. The patient had thoracocentesis with drainage of a serofibrinous liquid with Light's criteria consistent of an exsudate. All cultures, including pleural fluid (with at least 6 days of antibiotics), were negative. Pleural fluid cytology revealed reactive mesothelial cells without malignancy. Positron emission tomography demonstrated no evidence of malignancy of the incidental nodule in the right upper lobe. After 14 days of doxycycline, patient showed clinical and imagiological improvement.

Discussion

Patients with pneumoniae are not routinely tested for *M. pneumoniae*. Although polymerase chain reaction-based assays are the test of choice for diagnosing *M. pneumoniae* infection, it has limited availability and high cost. Serology using enzyme immunoassay of paired acute and convalescent sera has been the mainstay of laboratory diagnosis.

In this case, we assumed parapneumonic effusion due to *M. pneumoniae* because of the IgM positive serum and a good evolution after introduction of doxycycline. Patients requiring hospital admission should be tested for the presence of this bacteria, especially if they have pleural effusion.

#1692 - Abstract

RAOULTELLA PLANTICOLA, A NEW THREAT? CASE SERIES

Rui M. Domingues¹, Olga Pires¹, Maria João Regadas¹, Joana Alves², André Santa Cruz^{1,3}

¹ Internal Medicine Department, Braga Hospital, Braga, Portugal

² PPCIRA Department, Braga Hospital, Braga, Portugal

³ Life and Health Sciences Research Institute (ICVS), School of Medicine, University of Minho, Braga, Portugal

Background

R. planticola is a gram-negative, aerobic, non motile bacteria from the enterobacteriaceae family, closely related to *Klebsiella* spp and ubiquitous in the environment. It rarely colonizes humans, and there are just a few cases reported of infection caused by it, most of them being urinary tract infections. Therefore, its role in human disease is still not fully elucidated.

Methods

We searched the database of the Clinical Pathology department of our hospital, from March 2014 to March 2019, and found 44

adult patients with a positive culture of *R. planticola*. All identified cases were fully reviewed.

Results

The 44 positive cultures of *R. planticola* were isolated from urine samples (17), sputum (9), pus (5), bilis (3), skin swab (3), bronchial lavage (3), vaginal secretion (1), peritoneal fluid (1), hepatic abscess (1) and blood cultures (1). The population studied was composed of 48% men and 52% women, with a median age of 76,7 years old. *R. planticola* was the only bacteria present in the sample in 29.5% of patients, was isolated as a second bacteria in 50%, as third bacteria in 11,4% and as fourth bacteria in 9.1% of cultures. *R. planticola* was usually sensitive to all the first-line antibiotics tested, except for ampicillin (tested in 40 cases) to which it was always resistant. After reviewing all patients history and data, we consider that only 7 patients matched our definition of infection due to *R. planticola*: presence of symptoms, reliable microbiology results and adequate treatment with evidence of improval. Three of the infections caused by this pathogen were urinary tract infections, two were respiratory tract infections, one was a post traumatic bacteraemia and one was an acute cholecystitis. All other patients were considered to be colonized by *R. planticola*. Reviewing this case series, no correlation was found between infection and age, gender, diabetes, recent hospitalization, recent use of antibiotics, immunosuppression. No direct mortality was associated with this bacteria.

Conclusion

This is, to date, the biggest case series regarding this bacteria. *R. planticola* can be isolated from any type of sample. In our study, only 16% of cases in which it was isolated caused infection, being susceptible to everyday use antibiotics. We did not find any predisposing factor that can be associated with either active infection or colonization. The prognosis is excellent, as no fatality was directly associated with *R. planticola*.

#1703 - Case Report

MASSIVE STRONGYLOIDES STERCORALIS INFECTION ASSOCIATED WITH ENDOGENOUS HYPERCORTISOLISM IN INTENSIVE CARE - CASE REPORT

Susana Lemos Cabral, Nuno Deveza

Centro Hospitalar e Universitario de Coimbra, Coimbra, Portugal

Introduction

Patients with *Strongyloides stercoralis* infections are usually asymptomatic but massive hyperinfection may occur in patients with diseases associated with abnormal cell-mediated immunity or receiving immunosuppressive therapy, particularly corticosteroids.

Case description

The authors present the clinical case of a 49 years-old man with

history of diarrhea and cramping abdominal pain, generalized edema, petechial rash, melanoderma, cough and dyspnea. He presented hypokalemia and arterial hypertension and was admitted on Endocrinology ward with the diagnostic hypothesis of Cushing syndrome. The next day he presented respiratory failure and bilateral opacities in the chest x-ray. He was admitted to the intensive care unit. He started etomidate infusion to control hypercortisolism confirmed by laboratory findings. The abdominal CT scan revealed liver and duodenal masses. The duodenal biopsy revealed the presence of *Strongyloides stercoralis*. The liver biopsy revealed the presence of small cells neuroendocrine carcinoma. Bronchial washings, gastric aspirations, sputum and stool samples revealed helminthic larvae. He started ivermectin that he took for twenty days (until stool and sputum exams were negative for two weeks).

He was discharged from intensive care unit on day 35 after treatment of several nosocomial infection and an haemorrhagic stroke. He was transferred for pneumonology ward and the PET scan revealed the presence of multiple thoracic, abdominal and bone metastatic disease secondary to pancreatic neoplasm. He died on day 15 on pneumonology ward.

Discussion

Massive hyperinfection with *Strongyloides stercoralis* is an opportunistic infection. This patient's high level of endogenous cortisol may have facilitated infection.

#1704 - Case Report

CASE OF PERITONEAL AND INTESTINAL TUBERCULOSIS

Astrid Paola Hernández, Rudy López

Instituto Guatemalteco de Seguridad Social IGSS, Guatemala, Guatemala

Introduction

Intestinal disease is rare and can be difficult to diagnose because its symptoms and laboratory results are nonspecific. In addition, endoscopic lesions resemble those of other diseases such as Crohn's disease. The endoscopic findings most characteristic of intestinal TB are circular ulcers, small diverticula, and sessile firm polyps. The suspected diagnosis must be confirmed by the presence of caseating granulomas and/or acid fast bacilli¹.

Case description

Male, 27 years old. No family or medical history. He was admitted for abdominal pain of 1 day of evolution, sudden, in the right iliac fossa, colic type, associated with fever. In the physical examination, abdomen with voluntary muscular defense, positive bloomberg signs and peritoneal irritation. Routine laboratories were remarkable and urinalysis normal. HIV negative. They perform appendectomy, which was grayish violaceous and necrotic with mesoappendix; they send to pathology which reports periappendicitis and abdominal wall and omentum with granulomatous reaction with Langhans type giant cells. Then

he was in charge of infectious service and he was treated with antifimics phase I, he discharged hospital. CT scans shows normal. Continue with Phase II antifimics with favorable evolution.

Discussion

We present case of extrapulmonary tuberculosis, atypical peritoneal and intestinal tuberculosis, in a healthy patient. This case is very rare, and it was accidentally found. The treatment is the same as the pulmonary tuberculosis but the challenge is the timely diagnosis.

#1717 - Abstract

HYPERFERRITINEMIA AND GALL BLADDER WALL EDEMA AS PREDICTORS OF SEVERE DENGUE

Basavaprabhu Achappa

Kasturba Medical College, Mangalore, India

Background

Dengue is tropical disease caused by dengue virus. Previously many studies have been done on markers of severe dengue like Immune activation markers, Endothelial activation markers, Biochemical markers and Genetic markers. However currently these markers are not being used to guide patient management because detection methods are expensive, slow or require sophisticated equipment. Hence, our aim was to determine if biomarker serum ferritin, an acute phase reactant and Gall Bladder wall oedema, an early indicator of capillary leakage predict severe dengue

Methods

We conducted a longitudinal study of association between Serum Ferritin levels and Gall Bladder Wall Edema with Dengue Severity in all 133 confirmed dengue patients presenting within 4 days of onset of fever. Serum ferritin levels and gall bladder wall oedema by ultrasound abdomen were recorded on 4th day of fever. Serum ferritin levels more than 500 ng/ml and gall bladder wall oedema more than 3 mm were considered significant. Patients who met WHO criteria for severe dengue (WHO 2009) were classified as severe dengue and patients who did not meet criteria were classified as non-severe dengue.

Results

Among the total patients studied, majority of severe dengue was present in the age group between 41-50 years old and minimum in extremes of age. More males were found to have severe dengue compared to the females. The mean duration of hospital stay of severe dengue patients was observed to be 6-8 days. Hepatomegaly and splenomegaly were present in most of the patients with severe dengue. The mean ferritin among severe dengue patients was 9125 whereas in non-severe dengue patients it was 4271 which shows ferritin to be higher among severe dengue patients. Out of 44 severe Dengue patients, Gall bladder wall edema was present in 39 patients. The patients with high ferritin (>3825) and presence of gall bladder wall oedema have

a positive correlation with severe dengue according to Fischer's exact t test and the p value was significant (0.028).

Conclusion

High ferritin levels and the presence of gall bladder wall oedema of more than 3 mm done during the acute febrile phase (within 4 days of onset of fever) can be considered as predictors of severe dengue later during the course of illness both independently and together

#1719 - Case Report

TUBERCULOSIS IN AN ADALIMUMAB-TREATED PATIENT | A DIAGNOSIS CHALLENGE

João Pedro Abreu, Cristiana Fernandes, Cristina Moreira Marques, Carina Costa Silva, Carla Lemos Costa, Carlos Oliveira Hospital Santa Maria Maior, Barcelos, Portugal

Introduction

Tuberculosis remains a global health concern. The most common form is pulmonary tuberculosis, characterized pathologically by necrotizing granulomas. Studies showed a 10 times increased risk of TB in anti-TNF-treated patients when compared with the respective general population.

Case description

We present a case of a 52 years old female patient, with seronegative rheumatoid arthritis, treated with adalimumab. The patient applied to our emergency department, referring an acute onset fever (39 °C) and right lumbar pain; in the physical examination there were no signs worth being noted; in the laboratorial blood and urine samples, we found elevation of C-reactive protein (CRP), with no other changes. The ultrasound imaging revealed a hypoechoic area in the right kidney suggesting acute pyelonephritis. Blood and urine samples were collected to microbiology, and a Fluroquinolone was started. Epidemologically, there was a recent exposure to a TB patient. 3 days after admission, the patient maintained high fever, increasing inflammatory parameters, and a new onset dyspnoea associated with hypoxemia (no cough or sputum). A thoraco-abdominal CT scan was run, to find a pneumonic consolidation in the posterior segment of the right upper lobe. A bronchofibroscopy was preformed (bronchoalveolar and bronchial lavages), and new blood samples to immunology and microbiology, including Mycobacterium were run; piperacillin/tazobactam was started. The smears and real time PCR for Mycobacterium tuberculosis were negative in both BAL and BL. After 72h of piperacillin/tazobactam, no improvement was noted, a new set of microbiology samples were collected and meropenem and vancomycin were initiated. At the 10th day, since no apyrexia was achieved, a thoracic CT scan was repeated – the consolidation had suffered no change. A pulmonary biopsy was then preformed to reveal a necrotizing granulomatous inflammation. HRZE was initiated, with resolution of the fever.

After 30 days, the bronchoalveolar lavage cultural analysis identified a *Mycobacterium tuberculosis* complex agent.

Discussion

Tuberculosis in immunosuppressed patients is still a major concern and should never be forgotten as a differential diagnosis of pulmonary infections. The immunologic response in this set of patients is not the same as in the general population, representing a challenge to the diagnosis. With this case we aim to enlighten the difficulties in the diagnosis with the tools available to date, and the importance of a clinical history.

#1720 - Abstract

TUBERCULOSIS: A RETROSPECTIVE ANALYSIS OF 3 YEARS

Miguel Achega, Catarina Rodrigues, Margarida Monteiro, Joana Urzal, Fernando Aldomiro

Hospital Prof. Dr. Fernando Fonseca, Lisbon, Portugal

Background

According to the WHO, tuberculosis (TB) is one of the leading causes of death worldwide causing, in 2017, an estimated 1,3 million deaths among HIV-negative people and an additional 300,000 deaths among people living with HIV. In Portugal the incidence rate in 2017 was 15.6/100,000 inhabitants, but in the region associated with our Hospital, the incidence rate is estimated to be 40/100,000.

Methods

A retrospective analysis of case files of all patients admitted to a tertiary Portuguese Hospital between January 2015 and December 2017 was carried out. All patients with a diagnosis of TB, except paediatric patients (<18 years), those diagnosed in outpatient care and readmissions were included. The data collected was: year of diagnosis; age; gender; race; country of origin; location of TB; laboratory and radiologic findings; comorbidities and results.

Results

A total of 240 cases were included: 73 in 2015, 85 in 2016 and 82 in 2017. The mean age was 45.2 ± 6.3 years [18; 90]. With respect to the country of origin, 50% were born in Portugal and 43,8% in African countries, 64,4% were males, and 52% were black. Pulmonary TB was diagnosed in 131 patients (54,6%), extra-pulmonary TB in 63 (26,3%) and disseminated TB in 46 (19,1%). The most common extra-pulmonary locations were pleura, lymph nodes and vertebrae. Apical cavitation was present in 105 patients (43,7%). The diagnosis was established by direct exam of the sputum in 112 cases (46,7%), by PCR in 54 (22,5%) and by positive cultures in a further 41 cases (17,1%). In 33 cases (13,7%) treatment was initiated based exclusively on clinical and/or imaging criteria. HIV infection was confirmed in 65 patients (27,1%), 88,7% of whom were HIV-1 positive. With respect to

comorbidities, 7,9% had diabetes, 5,8% malignant neoplasms, 3,8% chronic renal disease, and 14 patients (5,8%) were on immunosuppressing treatments. In this series the mortality rate was 4.17% (10 patients).

Conclusion

National statistics demonstrate that the incidence rate in Portugal continues to decrease over time, but our data shows no decrease in the number of diagnosis per year. In this series 45.4% presented with some form of extra-pulmonary TB. Another aspect is that a significantly higher rate of co-infection with HIV was present (27.1% vs 10.9% in Portugal and 9% globally). These observations might be explained by two aspects: the low socio-economic status and the large migrant population in our area, mainly from African countries.

#1724 - Case Report

CERVICAL SPONDYLODISCITIS WITH EPIDURAL EMPYEMA: A CLINICAL CASE OF DISTAL PARESIS OF THE UPPER EXTREMITY

Margarida L. Nascimento¹, Pedro Duarte², Filipa Malheiro¹, Alexandra Bayão Horta¹

¹ Hospital da Luz, Lisbon, Portugal

² Hospital Divino Espírito Santo de Ponta Delgada, Azores, Portugal

Introduction

Cervical spondylodiscitis with epidural empyema is a rare but important infection of the central nervous system. The most common cause is *Staphylococcus aureus* and the classical diagnostic triad consists of fever, spinal pain and neurologic deficits. Along with a high level of suspicion, familiarity with its imaging characteristics is the basis for establishing the correct diagnosis, allowing early and focused treatment.

Case description

A 61-year-old woman presented to the Emergency Department with an one-week history of fever (38.6 °C), cervical and right shoulder blade pain, muscle weakness in her right hand and paresthesia in her 4th and 5th fingers. The patient did a dental procedure in the previous month and acupuncture during that week. Physical examination revealed decreased extension strength of her right forearm and hand with diminished amplitude of her fingers' abduction. Laboratory studies showed neutrophilia and elevated c-reactive protein. Cranial computed tomography scan and magnetic resonance imaging (MRI) were performed with no acute alterations. A spine MRI revealed cervical spondylodiscitis (C5-C6), epidural empyema and paravertebral tissue inflammation. She underwent surgical decompression and drainage of pus in large quantity. Empiric therapy with vancomycin, clindamycin and ceftriaxone were started. It was isolated a methicillin-susceptible *Staphylococcus aureus* in the collected pus, so the antibiotic was changed to flucloxacillin. We maintained parenteral therapy for 14 days and patient got better. She was discharge maintaining oral antibiotic for six more weeks.

Discussion

Although spondylodiscitis with epidural empyema is an uncommon disease there is evidence that the incidence may have increased over the last several decades. Part of this increase may relate to the fact that the sensitivity and accuracy of diagnosis have been improved by the use of MRI. In this case the combination of clinical and imagiological data contributed to the appropriate treatment, with a favorable clinical outcome.

#1737 - Case Report

GULLO'S SYNDROME IN AN HIV-POSITIVE PATIENT

Silvia Suárez-Díaz, Carmen Yllera-Gutiérrez, Jessica Rugeles-Niño, Lucía Meijide-Rodríguez, María Folgueras-Gómez, Mauricio Telenti-Asensio

Hospital Universitario Central de Asturias, Oviedo, Spain

Introduction

Gullo's syndrome was described for the first time in 1996 and it also called benign pancreatic hyperenzynemia. It is defined as a persistent elevation of pancreatic enzymes without evidence of pancreatic disease. It may appear sporadically or in a familial form. In our knowledge, it has not been described this entity in patients with HIV-positive patients.

Case description

A 49-year-old, HIV positive woman with an excellent virologic control since 2003, was enrolled in a clinical trial from 2014 to test a new HIV therapy so periodically, she comes to our hospital to complete her follow-up. From this first evaluation, her analyses showed elevated serum levels of amylase and lipase (2-3 times our normal laboratory values). It persisted over time with small fluctuations in serum enzyme concentrations. The patient was asymptomatic at all times. Initially, we suspect a toxic cause, due to the consumption of an herbal preparation to lose weight, but the hyperenzynemia remained elevated once the substance was suspended. Therefore, we performed two abdominal ultrasounds (separated by two years), a thoracoabdominal tomography, and finally an MRI, without any significant finding. No relation was found with the trial therapy, since prior to its inclusion in the study the patient already presented elevated levels of amylase and lipase. Finally, her hyperenzynemia was interpreted as benign and probably compatible with Gullo's syndrome or benign pancreatic hyperenzynemia

Discussion

As in the general population, HIV-positive patients with persistent elevation of pancreatic enzymes must be carefully studied. In the absence of pancreatic pathology, Gullo's syndrome should be considered as a probable cause in our differential diagnosis.

#1739 - Case Report

A CHALLENGING CASE OF SUBACUTE MENINGITIS

Vasco Tiago, Raquel Sousa, Fernando Aldomiro

Fernando Fonseca Hospital, Amadora, Portugal

Introduction

Subacute meningitis is most often caused by *Mycobacterium tuberculosis* or *Cryptococcus neoformans*. More rarely, other infectious agents or even non-infectious conditions can present as subacute or chronic meningitis. A correct diagnosis can thus be challenging at times. A case of subacute meningitis due to such an uncommon aetiology is presented.

Case description

A 23-year-old male patient visited his family practitioner due to a two-week-long history of upper back myalgia and arthralgia, vomiting, febrile sensation, holocranial headache with photophobia and sonophobia, and neck stiffness. He also complained of anorexia and non-quantified weight loss.

He had known history of migraine headache and worked as a butcher in a local slaughterhouse. Two co-workers had been diagnosed with focal brucellosis in the past three years.

He was sent to the Emergency Department (ED) for evaluation and discharged with symptomatic treatment for migraine. Over the next days he returned thrice to the ED with worsening symptoms. A head CT scan and, later, a CT angiography of the cerebral venous system showed no abnormalities. His analytical profile never showed significant changes.

On the fourth visit to the ED, a lumbar puncture (LP) was made. Cerebrospinal fluid (CSF) analysis revealed high protein concentration (359 mg/dL), low glucose concentration (19 mg/dL) and pleocytosis (276/μL) without predominance. He was thus started on empirical treatment for acute meningitis and neurobrucellosis, given the epidemiological data: Ceftriaxone, doxycycline, rifampin, and dexamethasone. There was complete symptom remission over one week.

The CSF Gram stain and culture were negative, as well as capsular antigen detection tests. Thus dexamethasone was stopped. Aetiological investigation was remarkable for positive Rose Bengal test on CSF and positive serum anti-*Brucella* IgG titre > 200 AU/mL. Cultures and PCR for *Brucella* in blood and CSF were negative. Ceftriaxone was stopped at the third week of treatment. A repeat LP showed improvement, but not complete remission. The patient was then discharged with doxycycline and rifampin to be maintained for at least 6 months' duration.

Discussion

Brucellosis is increasingly uncommon in Portugal, even though it is still considered an endemic country. In this case, there was an occupational history crucially pointing to this diagnosis, which was confirmed with serologic testing. Directed treatment led to improvement of symptoms and CSF analysis.

#1748 - Case Report

MULTIPLE BRAIN ABSCESES: A CASE OF SUCCESS

Manuel Serrano Martins, Andre Santos Pinto, Wildemar Costa, Ivone Barracha, Rosa Amorim

Centro Hospitalar do Oeste - Torres Vedras, Torres Vedras, Portugal

Introduction

Multiple brain abscesses are often caused by hematogenous spread of bacteria from a primary source. The incidence of multiple brain abscesses in all intracranial abscesses is about 2 to 15% and carry a mortality rate of 62 to 100%. They are more common in immunocompromised individuals and likely sources of primary infection include cyanotic heart disease, endocarditis, suppurative lung diseases, skin/abdominal and pelvic infections.

Case description

A 74-year-old male who had been hospitalized 2 months before with a urinary tract infection, presented with high fever and mental confusion since 1 week. There was no focal neurological deficit or meningeal signs. Laboratory investigations revealed anemia, leukocytosis, neutrophilia, urine sample non altered, HIV negative. Cerebrospinal fluid analysis revealed >1000 cells/mm³ (93% neutrophils), hypoglycorrhachia and hyperproteinorrhachia. Brain CT showed no lesions. Admitted for iv ceftriaxone for a possible bacterial meningitis. Blood, urine and CSF cultures isolated a *K. pneumoniae* sensitive to ceftriaxone. Body CT was performed showing a left renal abscess and a brain MRI showing ring enhancing lesions in bilateral basal ganglia and bilateral sub-cortical white matter asymmetrically distributed. The diagnosis of multiple brain abscesses with primary kidney infection was confirmed. He was treated with intravenous antibiotics as per the sensitivity and supportive care for 8 weeks. Brain MRI after treatment showed complete resolution.

Discussion

Despite the availability of new antibiotics and new powerful imaging technologies the outcome of brain abscess is still adverse. In this case, the early antibiotic therapy and the fast diagnosis were the 2 predictive factors of treatment response. Important to notice the futility of Brain CT without contrast in the etiological investigation of confusional states in which the stroke is not a likely diagnosis.

#1756 - Case Report

AN UNLIKELY ASSOCIATION TO ERYTHEMA NODOSUM

Dora Lameiras Xete¹, Débora Sousa², Joana Vasconcelos¹, Joana Granada¹, Kamal Mansinho¹

¹ Hospital Egas Moniz, Lisboa, Portugal

² Hospital da Luz, Lisboa, Portugal

Introduction

Erythema nodosum (E.N.) is defined as a form of panniculitis, affecting the limbs as painful erythematous nodules, with

a diameter that ranges from 1 to 20 cm. Prior to cutaneous symptoms, arthralgias, fever and malaise may occur. E.N. is usually a reactive process, being considered a late hypersensitivity response.

Case description

70 years old, female, with a known history of hypertension. The patient presented with a two week history of cutaneous manifestations, with painful and erythematous lesions on the anterior legs. These lesions progressed, in days, both in size and in number, affecting both legs. The patient reported fever (T°38°C), polyarthralgias, loss of appetite and fatigue. No history of travelling, contact with animals or insect bites were reported. Weight loss and night sweating were denied. She reported a history of tonsillitis 15 days prior to hospitalization that was treated with penicillin (single injection) followed by amoxiciline-clavulanic acid. At inspection the patient was febrile (38,4°C). No enlarged lymph nodes were detectable. The lateral and anterior aspects of both legs presented with round, red, papular and painful lesions, with local temperature being increased. A diagnosis of E.N. was presumed. Blood tests were conducted: Hb 11 g/dL; Platelet count 406,000/uL; INR 1.3; White cells count 17,200/uL, Neutrophils 68.7%, CRP 20.8 mg/dL; creatinine 0,78 mg/dL; urea 40 mg/dL; Liver tests were normal; T. pallidum testing was negative; Serologies for HIV, Hep. B and C were negative; Anti-streptolysin O was negative; ADA: 9.1 IU/I; ACE level: 24 IU/L; Serial hemocultures were negative. Urinalysis identified pyuria and positive nitrites; Urinoculture isolated *E.coli*, susceptible to Trimethoprim/sulfamethoxazole. CT thorax scan was normal. The biopsy of the lesions confirmed the diagnosis of E.N. and excluded vasculitis. Due to the elevation of inflammatory parameters, urinary symptoms at the beginning of hospitalization and isolation of *E.coli* in urine, definitive antimicrobial therapy was prescribed.

Discussion

Despite being rare, the constation of E.N. must lead to an aetiological investigation being known to be associated to various pathologies – infectious, autoimmune, medicamentous, among others, with variable frequency. Different causative factors differ in management and prognosis. In this case, urinary tract infection due to *E. coli* seemed to be the cause of E.N., a pathogenic described in the literature as rare, but well documented.

#1766 - Case Report

**A CASE OF PNEUMOCYSTIS JIROVECI
PNEUMONIA WITH CYTOMEGALOVIRUS CO-
INFECTION IN A 66-YEAR-OLD INTUBATED
PATIENT**

Angeliki Tsifi, Sofia Avgeri, Evaggelia Sergi, Stela Stefanova, Apostolos Voulgaridis, Kyriakos Ntorlis, Anastasios Sakkalis, Maria Katsiari

General Hospital of Nea Ionia Konstantopouleio- Patision, Athens, Greece

Introduction

Pneumocystis jirovecii pneumonia is a frequent opportunistic infection in individuals with acquired immunodeficiency syndrome (AIDS), even when patients are not aware of their HIV (Human Immunodeficiency Virus) seropositivity. Cytomegalovirus (CMV) co-infection should also be considered, especially with a T CD4+ cell number lower than 50/mcL and if symptomatic it should be treated accordingly.

Case description

We present a 66-year-old male, diabetic patient with a history of coronary artery bypass graft surgery and two recent hospitalizations due to lower respiratory tract infections. During his last hospitalization the patient was started on empiric antibiotic treatment for pneumonia, but he gradually deteriorated. He was eventually intubated due to acute respiratory failure and transferred to the intensive care unit (ICU). The patient's laboratory analyses revealed lymphopenia, which suggested a possible HIV infection, that was eventually confirmed. A chest CT scan showed pulmonary infiltrates in both lungs and bronchoscopy was performed in order to obtain bronchial cultures. The samples that were collected yielded Pneumocystis jirovecii and the patient was commenced on trimethoprim-sulphamethoxazole intravenously in combination with prednisone. Subsequently, a T CD4+ cell count was requested which revealed 6 cells/mcL. In order to exclude other opportunistic infections, additional tests were performed. The patient was commenced on prophylactic treatment with azithromycin and fluconazole intravenously. CMV treatment with acyclovir was also initiated, since $>1 \times 10^6$ CMV copies were detected in the patient's blood. After being successfully extubated and after being treated for various hospital-acquired infections the patient was referred to an Infectious Diseases specialist in order to commence antiretroviral treatment.

Discussion

When a critically ill patient with acute respiratory failure is diagnosed with AIDS, a thorough work-up needs to be performed in order to diagnose possible opportunistic infections and to treat them accordingly. Additionally, antiretroviral treatment needs to be commenced as soon as possible, so that the best possible result may be achieved.

#1771 - Case Report

**RECURRENT SEPSIS TO KLEBSIELLA
PNEUMONIAE IN A PATIENT WITH BILIARY
HAMARTOMAS**

Maria Beatriz Santos, Magda Garça, Pedro Cota, Joana Carreiro, Paulo Ávila

Hospital of the Holy Spirit of Terceira Island, Angra Do Heroísmo, Portugal

Introduction

Biliary hamartomas or von Meyenburg complexes (VMC) are hepatic tumor-like lesions, related to congenital malformation of ductal plate and are part of ciliopathy spectrum of disorders. The exact pathogenesis of VMC remains unclear and whether it has malignant potential remains controversial. Patients are usually asymptomatic and VMCs are rarely diagnosed clinically. The authors present a unique case of recurrent sepsis in a patient with VMC.

Case description

69 years old male patient, with personal history of ischemic heart disease, chronic liver disease, adrenal incidentaloma, hypertension, diabetes, hyperuricemia and dyslipidemia. The patient had multiple admissions due to bacteremia to ESBL-producing Escherichia coli and Klebsiella pneumoniae, with unknown infectious focus. The CT scan revealed liver with increased dimensions and heterogeneous texture by the presence of multiple calcified lesions, suggestive of granulomas. The subsequent MRI showed several nodular lesions, probable calcifications, the largest with 2.8 cm and morphological alteration of the liver with evident hypertrophy, in relation to chronic hepatopathy.

In view of the findings, the hypothesis of infectious focus in the gallbladder and biliary tract was considered and the patient underwent laparoscopic cholecystectomy, during which several hepatic implants were identified. The histology of these implants revealed calcified biliary hamartomas and the bacteriology confirmed the presence of Klebsiella pneumoniae in the sample. Two months later, the patient was re-admitted with bacteremia to ESBL-producing Klebsiella pneumoniae. Considering the imaging findings and the results of the laboratory studies, it was considered that the focus of the bacteremia was on the biliary hamartomas, which acted as a sanctuary for the persistently identified pathogenic agent. Therefore, the patient fulfilled 21 days of meropenem antibiotic therapy in an attempt to sterilize the cystic content and resolve the recurrent sepsis.

Discussion

VMC consist of multiple, small, well-defined nodular cystic lesions which can be easily confused with metastatic disease of the liver on imaging. Histologically, the lesion consists of cystic dilation of the bile ducts surrounded by abundant fibrous stroma. On the review of the literature, there are multiple case reports of different clinical manifestations of VMC, but very few present recurrent sepsis, as in this case.

#1776 - Case Report

A RIGHTFUL FEELING

Susana Conceição, Diogo Faustino, Rita Pocinho, Inês Costa, Isabel Baptista

Centro Hospitalar Universitário Lisboa Central - Hospital de São José, Lisboa, Portugal

Introduction

A detailed clinical history, including past exposures and relevant epidemiological context is essential on the approach to the patient with fever.

Case description

61-year-old, male, admitted to the emergency room with a 3-day progression of increasing fever, generalized myalgia and asthenia. A veterinarian, he was asked (3 weeks before) to perform an autopsy on a cow, suspected to have died with leptospirosis (several other cows had died previously with the same clinical picture). While doing so, he identified the presence of greatly enlarged and hemorrhagic kidneys, manipulating them rather carelessly, without adequate protection measures. On admission, he was febrile (38.3 C) with mild thrombocytopenia (Platelets 124,000/uL), renal dysfunction (Creatinine 1.43 mg/dL), conjugated hyperbilirubinemia (Total bilirubin 1.44 mg/dL) and marked elevation of C-reactive protein (246 mg/L). No chest x-ray abnormalities, cerebrospinal fluid with normal chemistry and no isolates. Due to the presumptive diagnosis of leptospirosis, he was started on intravenous ceftriaxone with marked clinical improvement and euthermia reached within 48 hours of therapy. There were no blood culture isolates and serology was negative for HIV, hepatitis virus, CMV, Brucella, Borrelia and Leptospira. Repeated testing, 3 weeks after, showed the presence in serum of an anti-Leptospira IgM antibody (detected by microagglutination), confirming the diagnosis.

Discussion

Leptospirosis is a zoonosis with a wide geographical distribution, variable incubation period (ranging from 2 to 30 days) and variable presentation (from a flu-like syndrome to multiorgan dysfunction). It is typically transmitted on exposure to infected products (urine, blood, other tissues, contaminated water), with the spirochete gaining access to the circulation through breaches in the skin or directly through exposed mucosa (conjunctivae; oral; gastrointestinal).

In this case, the patient presented with a mild clinical picture that promptly improved with a timely institution of antibiotic therapy. Within 48 hours fever subsided, with creatinine and bilirubin returning to a normal range. The platelet count was slower to recover, reaching a minimum of 62000/uL that improved and resolved over the following 2 months. This case highlights the importance of a detailed history with past environmental exposures on the approach to a patient with a febrile syndrome.

#1777 - Case Report

UNCOMMON PRESENTATION OF A ZONOTIC DISEASE IN AN IMMUNOCOMPETENT HOST

Ana Valada Marques, Ana Canoso, Miguel Falcão, Tânia Gaspar, Ana Filipa Rodrigues, Isabel Maldonado, Rosa Amorim

Centro Hospitalar do Oeste Caldas da Rainha, Caldas Da Rainha, Portugal

Introduction

Toxoplasma gondii is an obligate intracellular protozoan transmitted to humans by ingestion of cysts in the undercooked meat, ingestion of water or food contaminated by feces with oocysts. It infects up to one-third of the world's population with a higher impact between immunocompromised individuals.

Case description

A 40 years old female, with past history of mastitis in puerperal, went to the emergency service with rhinorrhea, odynophagia, left shoulder pain irradiated to the neck, dyspnea on moderate exertion, pleuritic left hemithorax pain and fever with no time dominance for one week. She was under symptomatic treatment for a suspected flue for two days with no improvement. She refers contact with her pets, a cat and a dog. At clinical examination diminished vesicular murmur over lower left lung. Chest X ray: left pleural effusion. Chest axial computed tomography: ground glass areas in left lung, mediastinal adenopathies and left pleural effusion. Leucocytes 14300/uL, neutrophils 95.3%, reactive chain reaction 43.8 mg/dl, procalcitonin 4.18 ng/ml. Amoxicillin-clavulanate and clarithromycin was started for a community-acquired pneumonia but with no response. Two days later the patient developed cellulitis involving left breast, scalene and sternocleidomastoid muscles, confirmed by neck and thoracic CT and breast ultrasound. Also detected an axillary adenopathy. Fever persisted and cellulitis got worse. Antibiotic spectrum was extended switching to piperacillin-tazobactam but still no response. Negative blood and urine microbiological cultures. Pleural effusion was an exudates, negative microbiological culture, no malignant cells, Aadenosine deaminase 5.4U/L, acid-alcohol resistant bacillus and mycobacterial culture were negative. Negative hepatitis B, C and HIV 1-2 serologies. Breast and thoracic magnetic resonance imaging showed abscesses. Syphilis was discarded. Toxoplasmosis IgM and IgG antibodies were positive. Treatment with sulfadiazine, pyrimethamine and folinic acid was initiated with clinical improvement, cellulitis retrechement and sustained apyrexia a week later.

Discussion

In immunocompetent individuals toxoplasmosis is commonly asymptomatic throughout life but in a few cases it leads to visual impairment and fatal infections. This uncommon presentation described in this case report was a true challenge concerning differential diagnosis and treatment of toxoplasmosis in an immunocompetent patient.

#1785 - Abstract

INFECTIONS IN AN INTERNAL MEDICINE WARD – A RETROSPECTIVE STUDY

Torcatto Moreira Marques, José Sousa, Diogo Antão, Lourenço Cruz, Teresa Ferreira, Valentina Tosatto, Cristiano Cruz, Paula Nascimento, Afonso Rodrigues, André Almeida, Teresa Garcia, Patrícia Cachado, Rita Barata Moura, António Sousa Guerreiro
Hospital de Santa Marta - Centro Hospitalar Universitário de Lisboa Central, Lisboa, Portugal

Background

Infections are a major part of the diseases that lead to admissions in Internal Medicine wards and responsible for great mortality. This study aimed to clarify which were the most prevalent microorganisms responsible for this, site of infection and how their resistance pattern was.

Methods

From all the patients admitted to the Internal Medicine ward of Hospital de Santa Marta of the Central Lisbon University Hospital Centre in 2018, those admitted for infectious causes were selected and clinical data was gathered with patients permission. Hospital related infections were excluded. Sex, age, diagnosis, microbiological agent, isolation site and outcome were gathered in a database. Statistical analysis was done with Microsoft Excel®.

Results

From all patients admitted in 2018 (N = 953), 259 (27.1%) had initial infectious causes. The mean age was 76,1 years and 56.3% (N=146) were female. The infected site was mainly (51.3%, N=133) the respiratory tract, followed by the urinary tract, (28%, N= 74). Abdominal foci were the less representative, 0,7% (N=2). In almost 56% (N= 145) of the cases, a microorganism isolation was possible, 42% (N=62) of the times in urine samples and 22% (N=32) in blood samples. Gram negative bacteria were the leading isolated microorganisms, 60% (N=87), followed by Gram positive, 25% (37) and viruses ~12% (N=17). The most frequent agents isolated were *Escherichia coli*, 18% (N= 48), *Klebsiella pneumoniae* and Influenza species, 6.5% (N=17), *Staphylococcus aureus*, 6,2% (N= 16) and *Streptococcus pneumoniae*, 4.6% (N=12). 7 out of the 48 (14,5%) *E.coli* were extended spectrum beta-lactamase (ESBL) positive and, 10 out of 17 (59%) *K. pneumoniae* were MDR, 6 ESBL+ and 4 were carbapenemase producing bacteria, KPC. More than half (56,3%, N=9) of the *Staphylococcus aureus* were methicillin-resistant. The majority (84%, N=11) of ESBL producing *Klebsiella pneumoniae* were isolated in urine samples and mostly in women. On the other hand *E.Coli*, while most commonly isolated in urine samples and in women, when ESBL+, was more frequent in men (5 vs 2). In total, 13% of all microorganisms were resistant types.

Conclusion

Most infections admitted to this ward were Gram negative related, mostly isolated in urine culture and in women. 13% were potentially multi-drug resistant, mainly *E.Coli* and *Klebsiella*

pneumoniae, and by ESBL production. Only KPC were isolated. There was no association with higher mortality. No cases of penicillin resistant *streptococcus pneumoniae* were recorded.

#1789 - Case Report

A CASE OF ACUTE MENINGITIS BY LISTERIA MONOCYTOGENES

Francisco D'Orey, Rosa Alves, Bruno Sousa, Tiago Judas
Hospital Garcia de Orta, Almada, Portugal

Introduction

Listeriosis is an infection caused by the Gram positive bacteria *Listeria monocytogenes*, normally associated with the consumption of contaminated food products. Although uncommon, this infection normally manifests as a self limiting gastroenteritis. It can, however, have a more severe presentation, ranging from sepsis to meningitis or encephalitis, associated with a high mortality rate.

Case description

I here present a case of an 81 year old male, with a past medical history of atrial fibrillation and treated prostate cancer. He presented to the Emergency Department due to fever, acute mental confusional and disarthria. On the first physical examination he was febrile, conscious but confused. The initial blood tests showed thrombocytopenia and elevation of the inflammatory markers. After exclusion of an acute stroke and cranial hypertension we performed a lumbar puncture which produced a cloudy cranio-spinal fluid (CSF) and raised white cell count. A diagnosis of bacterial meningitis was therefore assumed and we started empirical antibiotic therapy (ceftriaxone, ampicillin and vancomycin). Due to a gradual worsening of his consciousness status he was admitted to the Intensive Care Unit. *Listeria monocytogenes* was latter isolated from blood and CSF cultures and the treatment switched onto directed antibiotic therapy (ampicillin). Although the patient showed a progressive improvement and was discharged he kept some level of cognitive deficit on follow up, e.g psychomotor retardation and mild cognitive impairment.

Discussion

This case highlights an uncommon meningitis with septicaemia, in an immunocompetent patient, by an organism not commonly associated to such clinical picture. This patient had the habit of drinking water from an uncontrolled well and this case also highlights the public health risk of consuming food or drink products which have potential contamination risks.

#1804 - Case Report

REACTIVE ARTHRITIS – DIAGNOSTIC KEY IN MYCOPLASMA HOMINIS PNEUMONIA IN AN IMMUNOCOMPROMISED ADULT

Ana Realista Pedrosa, Sofia Moura, Conceição Barata
Hospital Espírito Santo - Évora, Évora, Portugal

Introduction

Mycoplasmas are the smallest bacteria ever described. These atypical bacteria are not protected by a cellular wall which contributes to a troublesome diagnosis and subsequent treatment. Although *Mycoplasma hominis* commonly colonises the genitourinary tract, extra genitourinary infections have been observed in new-borns, immunocompromised patients and on the postoperative, postpartum and posttraumatic periods. Respiratory tract infections caused by *M. hominis* are very rare.

Case description

In this case report, we describe the steps of diagnosis and treatment of *M. hominis* pneumonia in an immunocompromised patient suffering from a hematologic neoplasia (chronic monocytic leukaemia) – starting on the diagnosis of Community Acquired Pneumonia (CAP) in the Emergency Room (ER), to the discovery and diagnostic inclusion of reactive arthritis, leading to the presumptive diagnosis of *M. hominis* pneumonia and to its aggressive treatment with tetracycline with an excellent outcome.

Discussion

M. hominis can be an underestimated cause of severe pneumonia. This case report points out the crucial rule of reactive arthritis on the diagnostic path.

#1805 - Case Report

SEVERE KAPOSI SARCOMA IN HIV/AIDS PATIENT

Ester Catarina Cabral De Freitas, Odeth Tjikongo, Ana Abreu, Irina Ferreira, Manuela Neto
Clínica Sagrada Esperança, Luanda, Angola

Introduction

AIDS-related Kaposi sarcoma (KS) is the most common cancer occurring in human immunodeficiency virus (HIV) infected individuals and it is etiologically associated with human herpesvirus 8 (HHV-8). In Angola, between 2007-2011, KS was the fifth most frequently reported cancer at the national oncology centre of Luanda and all of the patients were HIV positive. This cancer typically presents with cutaneous disease but can involve visceral organs resulting in significant morbidity and mortality.

Case description

A 38 year old electrician presented to the emergency department with extensive, nodular skin lesions all over his body, getting progressively worse over a 1 year period, associated with B

symptoms. Physical examination revealed peri-orbital oedema, violaceous plaques on the soft palate, violaceous nodules and plaques on face, chest and upper limbs, multiple nodular, ulcerated and exophytic lesions on his lower limbs with severe bilateral leg and scrotal oedema (Figures A and B). Laboratory studies revealed anaemia (Hb 8.1g/dl - reference range 13-15 g/dl), positive test for HIV and a CD4+ count of 44 cells per cubic millimeter (reference range 500-1500 cells/mm³). Upper and lower gastrointestinal tract (GI) endoscopy showed extensive involvement of the colon but minimal involvement of the upper GI tract (Figure C), and skin biopsy confirmed the diagnosis of KS (Figure D). Antiretroviral therapy was initiated, the patient underwent 1 cycle of chemotherapy with doxorubicin and was discharged. One week after discharge the patient presented to the emergency department with episodes of hematochezia, in hypovolemic shock, severe lactic acidosis and anaemia (pH 7.18, lactate 12 mmol/L - reference range 0.5-1 mmol/L, Hb 5.1g/dl). Unfortunately and despite all the resuscitation measures he passed away within hours of admission.

Discussion

Antiretroviral therapy was initiated, the patient underwent 1 cycle of chemotherapy with doxorubicin and was discharged. One week after discharge the patient presented to the emergency department with episodes of hematochezia, in hypovolemic shock, severe lactic acidosis and anaemia (pH 7.18, lactate 12 mmol/L - reference range 0.5-1 mmol/L, Hb 5.1g/dl). Unfortunately and despite all the resuscitation measures he passed away within hours of admission.

#1816 - Abstract

SPONDYLODYSCITIS: A 5-YEAR RETROSPECTIVE STUDY IN A PORTUGUESE PUBLIC HOSPITAL

João Figueira, Maria Inês Xavier Ferreira, Fernanda Paixão Duarte, Fernando Aldomiro
Hospital Professor Doutor Fernando da Fonseca, Lisbon, Portugal

Background

Spondylodiscitis is an infrequent infectious disease whose causative microbiological agents vary according to geographical area. Scientific evidence is scarce as regards to treatment and often empirical therapy is initiated. The objective of this retrospective study was to assess the most prevalent pathogens, antibiotherapy regimens chosen, imaging studies needed for diagnosis, risk factors and presenting symptoms, in a Portuguese hospital serving a heterogenous population including migrants from developing countries.

Methods

Retrospective review of patients treated for spondylodiscitis in a Portuguese public hospital between 2012 and 2017. Forty-two patients were identified and their clinical process studied.

Results

In the population of 42 patients, 28 (66.7%) were males. The mean age was 64.7 years old (maximum 88 and minimum 22). Regarding infected locations, 6 patients had cervical disease, 17 thoracic, 29 lumbar and 3 sacral. Pain was present in 40 patients and fever in 18 patients.

Several comorbidities were gauged: the most common was Diabetes Mellitus (18 patients). Endocarditis was simultaneously diagnosed in 8 patients.

Magnetic resonance imaging (MRI) was the first choice of imaging study in 5 patients whereas 7 patients had a suggestive Computed Tomography (CT) scan and started treatment without performing MRI. In 30 patients CT scan was the first imaging exam, but diagnosis was later confirmed with MRI. In 5 cases MRI showed greater disease extension. In one case, only MRI had evidence of spondylodiscitis.

From a total of 39 blood cultures, 18 (42.9%) were positive. From 18 local tissue biopsies' cultures performed, 6 (33.3%) were positive.

Methicillin-resistant *Staphylococcus aureus* was the most frequent pathogen in blood cultures (8 patients) and *Mycobacterium tuberculosis* was the predominant pathogen in local tissue biopsies (4 patients).

Pathogen directed antibiotic treatment was administered in 22 cases, while 16 patients were treated empirically.

Conclusion

Results confirmed that males are more frequently affected. Lumbar vertebrae were most often involved, as is commonly described in previous studies. Pain is the dominant symptom.

Concerning imaging studies, MRI is almost always required regardless of CT scan results and shows disease extension with greater detail.

The most prevalent pathogens isolated were *Staphylococcus aureus* and *Mycobacterium tuberculosis*. This is most likely linked to the population's heterogenous geographical origins.

#1823 - Case Report

A CASE OF DISSEMINATED MULTI-DRUGS RESISTANT TUBERCULOSIS IN A SEVERELY IMMUNOSUPPRESSED PATIENTS WITH HIV/AIDS

Ester Freitas, Odeth Tjikongo, Ana Abreu, Irina Ferreira, Manuela Neto

Clínica Sagrada Esperança, Luanda, Angola

Introduction

Tuberculosis is one of the leading causes of deaths worldwide. Over the last decade there has been an increase in multi-drug resistant tuberculosis (MDRTB), especially in people living with Human Immunodeficiency Virus (HIV)/Acquired Immunodeficiency Syndrome (AIDS). This increase has been seen in Sub-Saharan Africa, including Angola. This is primarily

due to difficulties with accurate and timely diagnosis, as well as inadequate chemotherapy.

Case description

A 33 year old angolan man, HIV positive since 2016 (WHO-stage IV), poorly controlled under anti-retroviral therapy (CD4 count 71cells/uL, viral load 1,837,635 cp/ml). He presented to the emergency department with ulcerated cervical lymphadenopathy despite completing 6 months of 1st line anti-TB therapy. Computed Tomography (CT) showed cervical abscesses and cutaneous fistulisation, mediastinal lymphadenopathy and appearances consistent with miliary TB. Bronchoalveolar lavage (BAL) fluid was collected for TB polymerase chain reaction (PCR) testing. The patient started re-treatment protocol, as per national guidelines, with 1st line TB drugs and Streptomycin. During the first 2 months of chemotherapy there were significant improvements, although not resolutions, of the cervical lymphadenopathy and ulcers. However, he subsequently developed progressively worsening pulsatile frontal headaches, difficulty in walking, poor coordination, nausea/vomiting over a 2 week period. CT brain excluded gross structural abnormalities; and cerebrospinal fluid (CSF) analysis revealed hypoglycorrhachia (10mg/dl), increased proteins and mononuclear pleocytosis, without *Cryptococcus* and a negative bacterial culture. At this stage the results of BAL confirmed a MDR-TB. Due to unavailability of 2nd line TB drugs the patient was transferred to another institution. After 2 months he returned with a similar clinical picture but with fever and in an acute confusional state. We found that his medication, since discharge, included only moxifloxacin.

Discussion

TB is the world biggest infectious killer and this case is a prime example of the difficulties faced in Sub-Saharan Africa regarding TB management. This patient had considerable risk factors for developing MDR-TB, and the local unavailability of TB-PCR for the early detection of resistance as well as the delay in the establishment of adequate chemotherapy probably altered the prognosis.

#1824 - Abstract

HOSPITAL-ACQUIRED PNEUMONIA IN NON-ICU PATIENTS IN A RURAL GENERAL HOSPITAL

Dimitrios Tsiolpidis, Christina Kotsiari, Palmyra Tsiftsi, Chasan Ali, Asimina Migdalia, Bilal Bilal, Berkay Mollagiousoufoglou, Vasilios Tsipizidis, Theodoros Kostakis, Triada Exiara
General Hospital of Komotini, Komotini, Greece

Background

Hospital-acquired pneumonia (HAP) is a major subgroup of all hospital acquired infections and is associated with high morbidity and mortality. The aim of this study was to determine the prevalence, aetiology and outcome of HAP in non-ICU patients in our medical ward.

Methods

This is a retrospective and descriptive study. We reviewed the medical files of all inpatients fulfilling clinical criteria of HAP, during last three years. Demographical data, co-morbidities, clinical and laboratory findings, pathogens identified and outcome were registered and analyzed.

Results

From a total of 4128 patients, 171 (4.14%) had HAP, 96 (56.1%) male and 75 (43.9%) female, with mean age of 76 ± 8.6 years. The main identified co-morbidities were: Stroke (66.1%), diabetes mellitus (45.6%), malignancy (30.4%), chronic renal failure (26.9%), heart failure (24.6%), chronic pulmonary disease (21.6%) and alcohol abuse (8.2%). Etiologic diagnosis was achieved in 84 (49.1%) patients. Mixed aetiology was considered in 8 (4.7%) cases. The most common isolated pathogens were: Methicilin Resistant Staphylococcus in 32 (18.7%) patients, Enterobacteria (E.Coli, Enterobacter spp., K. pneumoniae) in 29 (16.9%), Pseudomonas aeruginosa in 16 (9.4%), Enterococcus spp in 10 (5.8%), and Acinetobacter baumannii in 6 (3.5%) patients. Complications were observed in 79 (46.2%) cases with respiratory failure in 42 (24.6%) cases, pleural effusion in 18 (10.5%), septic shock in 13 (7.6%), and renal failure in 6 (3.5%) cases. The mean duration of hospitalization was 24 ± 6.7 days. The mortality rate attributed to HAP was 30.1%.

Conclusion

HAP in general wards affects mostly elderly patients with severe underlying diseases and is associated with increased length of hospital stay, morbidity and mortality.

#1829 - Case Report

PERITONEAL TUBERCULOSIS, A CHALLENGING DIAGNOSIS

Dina Rodriguez Pita, Salvador Morais Sarmiento, Andreia Amaral, Hugo Inácio, Daniela Marto, Ana Brito, Miguel Leite, Sofia Mateus, Catarina Espírito Santo, Catarina Salvado

Centro Hospitalar Universitário de Lisboa Central, Lisbon, Portugal

Introduction

Peritoneal Tuberculosis (TB) is a rare form of tuberculosis (1~2%) in developed countries, associated with significant morbidity and mortality. The disease results either from haematogenous dissemination from a primary pulmonary focus or contiguous spread from adjacent organs (small intestine or Fallopian tubes). The most common clinical manifestations include ascites, abdominal pain, and fever, but they are nonspecific and evolve insidiously, mimicking many other diseases, which makes this diagnosis difficult and elusive. Prognosis depends on timely diagnosis and treatment.

Case description

We report a case of a 51-year-old female presenting with weight loss, low-grade fever, abdominal distention and pain, and constipation.

On physical examination, abdominal distension, tenderness and flank dullness were present. Laboratory results revealed a hypochromic microcytic anaemia, normal leucocyte count and elevated sedimentation rate level. An infectious diseases panel was negative apart from the Interferon gamma release assay (IGRA) test which was positive.

Imaging of the abdomen and pelvis revealed ascites, diffuse thickening and micronodular involvement of the peritoneum and involvement of the greater omentum suggestive of peritoneal carcinomatosis. Due to these findings a work up for metastatic cancer with unknown primary site was undertaken, with no conclusive results.

The ascitic fluid revealed 1633 cells/ml, with lymphocytic pleocytosis (1578 mononuclear cells/ μ L; with predominance of T cells), sero-ascitic albumin gradient < 1.1 g/dl, adenosine deaminase (ADA) levels of 53 U/L; cytology was negative for malignancy, no acid-fast bacilli were seen by microscopic exam and TB culture was negative.

A presumptive diagnosis of peritoneal tuberculosis was made and the patient was started on antimicrobial therapy for Mycobacterium tuberculosis, following the same regimen as for pulmonary TB, with clinical improvement.

Discussion

Early diagnosis of peritoneal tuberculosis is a challenge for clinicians, requiring a high degree of clinical suspicion, as consequence of the unspecific clinical presentation and low sensibility of the available diagnostic tests. Definitive diagnosis depends on a positive peritoneal biopsy which is invasive and not always feasible.

A review of the current literature is included, which hopefully will be useful in helping clinicians recognise peritoneal tuberculosis, a potentially curable illness which if left untreated can be fatal.

#1833 - Medical Image

TUBERCULOSIS SEQUELAR CALCIFICATION: AN IMAGE CASE

Helena Freitas Luís, Diogo André, Fabiana Gouveia, José Luís Andrade, Maria Luz Brazão

Hospital Central do Funchal, Funchal, Portugal

Clinical summary

An 84-year-old female with arterial hypertension and pulmonary tuberculosis, 69 years ago, was admitted for acute heart failure due to a low respiratory infection. Patient's chest radiographs revealed a homogeneous hypotransparency in the middle third of the left lung field. Thoracic computed tomography exhibited a large residual paquipleuritic calcifications in the left hemithorax. These findings demonstrate the complications due to the pleural involvement of tuberculosis. Fibrous and calcified formations may lead to the development of empyema several years after acute infection, as well as restrictive respiratory pathology. Thus, despite the long latency period between the acute event and the

development of sequelae, tuberculosis remains a differential diagnosis to be taken into account.

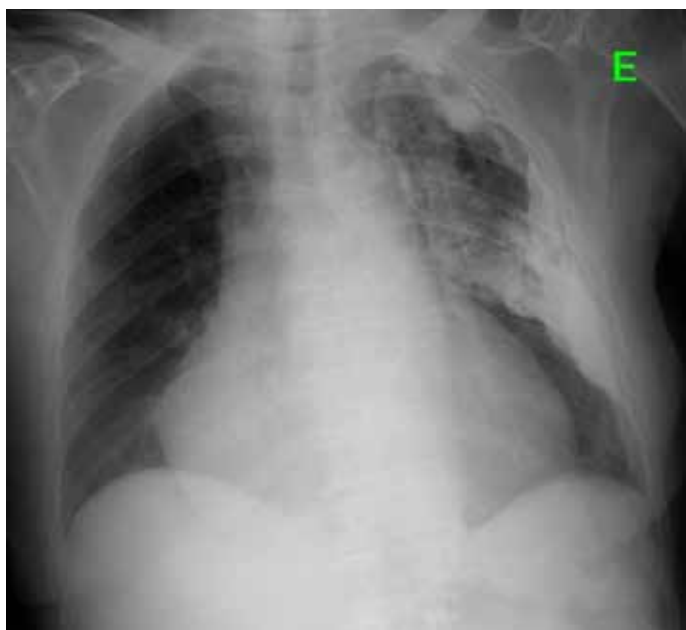


Figure #1833.

#1837 - Case Report

A RARE BUT POTENTIALLY DEADLY COMPLICATION...

Inês Goulart, Ana Bento Rodrigues, Joana Rosa Martins, Manuel Ferreira Gomes, Paulo Cantiga Duarte
Centro Hospitalar Lisboa Norte, Lisboa, Portugal

Introduction

Endometriosis is a condition characterized by the presence of endometrial tissue outside the uterine cavity. More often localized in the pelvic cavity, its symptoms consist of dysmenorrhea, pelvic pain and, sometimes, infertility. It occurs less frequently in other sites such as nasal mucosa, pleura and others. Endometriosis may be the cause of atypical symptoms (eg. hemoptysis). On the other hand, adenomyosis is the invasion of the myometrium by endometrial skin, and may or may not be associated with endometriosis.

Case description

The authors present a case of a 43-year-old woman who came to the emergency department due to fever, hypogastric pain, and increased urinary frequency which had started 2 weeks before. She had been medicated with multiple antibiotics (nitrofurantoin, amoxicillin + clavulanic acid, levofloxacin) without improvement. Laboratory evaluation showed elevated inflammatory parameters (leukocytes 17180/mcL, neutrophils 14890/mcL and C-reactive protein 35.9 mg/dL) but with a normal urine sample. Due to the hypothesis of sepsis caused by gynecological infection, empirical antibiotic therapy with ceftriaxone and metronidazole was started. On the first day of hospitalization, there was clinical

worsening and an abdominal CT was done. The exam showed evidence of a massive, hypodense, nodular formation within the pelvic cavity adjacent to the left uterine appendages with 12.5x12.5 cm. The mass had anechoic and gaseous content so the most likely diagnosis was thought to be infected endometrioma vs tubo-ovarian abscess. There was also a nodular formation, with similar characteristics, but smaller, in the right uterine appendages with no gaseous content inside. Uterine globosity and myometrial heterogeneity, compatible with uterine adenomyosis, was also seen. An urgent surgical procedure was done, with a good clinical evolution afterward. The surgical resection was sent to the pathology department and the final histological diagnosis was endometriosis with multiple abscesses and rupture of left endometrial cysts.

Discussion

This clinical report reinforces the importance of endometriosis in the differential diagnosis of pelvic diseases and inflammatory changes in atypical location in women. Although the etiology of endometriosis has not yet been fully elucidated and, given the absence of a definitive cure, treatment should be directed towards the relief of symptoms, infertility treatment and eventually surgical interventions (to reduce endometriosis' foci).

#1841 - Abstract

FOUR YEARS OF INVASIVE PNEUMOCOCCAL DISEASE – A SINGLE CENTRE STUDY

João Oliveira Rodrigues, Mário Pinto, Diogo Antão, José Sousa, Lourenço Cruz, Ana Teresa Ferreira, Catarina Pires, Valentina Tosatto, Carlos Marques, Rita Gerardo, António Sousa Guerreiro, João Cardoso

Centro Hospitalar e Universitário Lisboa Central - Hospital de Santa Marta, Lisboa, Portugal

Background

Community acquired pneumonia due to *Streptococcus pneumoniae* infection is a common entity with a considerable morbidity and mortality especially in older adults. Invasive pneumococcal disease states the need for isolation of *S. pneumoniae* from a sterile site, eg. blood. Although definitive diagnosis depends on a positive culture from a sterile site, the pneumococcal urine antigen test is approved for the diagnosis as well. We aimed for a descriptive analysis.

Methods

Clinical registries within a 4 year period were reviewed to analyse the population of patients admitted to an internal medicine ward of a tertiary center with the diagnosis of community acquired pneumonia with invasive pneumococcal disease (CAP-IPD).

Results

Between the years 2015 and 2019, 268 cases of community acquired pneumonia were admitted in our ward. The diagnosis of

CAP-IPD was made in 18 patients, either using urine antigen test or blood culture. 11% (n=2) had a negative antigen test. On the other hand, blood cultures were positive on 44% (n=8).

The median age was 78 years old, 28% (n=5) were under 65 years old and two of them were HIV positive. 28% (n=5) were female. The median time of stay was 11 days, the most common radiological pattern was lobar consolidation (n=9) and pleural effusion was concomitant in two patients. The median C reactive protein value was 210.5 mg/L.

Three patients required invasive ventilation during their hospitalization, and three others were needed non-invasive ventilation. Two patients died. In all cases the *S. pneumoniae* identified strain had in vitro sensitivity to the empirical antibiotic therapy prescribed, however the therapy was changed according to the sensitivity test in 17% (n=3) of patients, because it was effective in the other 83%.

Conclusion

This case series shows higher frequency of CAP-IPD patients over 65 years old, which is comparable to other known and larger series. Most diagnosis can be made using urine antigen testing, nevertheless blood cultures are valuable in making a definitive diagnosis of invasive disease and provide information regarding antibiotic sensitivity which allow adequate antibiotic prescription. CAP-IPD is not clearly associated with a distinct radiological pattern. Vaccination against *S. pneumoniae* is widely available and can reduce disease burden.

#1860 - Case Report

SEPTIC EMBOLI – A FEARSOME COMPLICATION

Francisco Lopes Morgado, Bárbara Saraiva, Celestina Blanco Torres, Luís Sanchez, João Correia

ULS Guarda, Guarda, Portugal

Introduction

Septic embolization, despite being a relative uncommon complication, can have a wide array of clinical sequelae. Thus, the internist should have a high level of suspicion when there are multiple risk factors for it such as catheter related infections or even infective endocarditis, prompting adequate treatment as soon as possible.

We present the case of such a patient, where internal medicine played a crucial role in its course.

Case description

A 58-year-old woman is admitted in the emergency room (ER) with recurrent vomiting, diarrhoea, fever and reduced muscle strength for the last 3 days. She has history of colorectal cancer and had an implantable intravenous device (IID). At the examination she had a pale skin, blushing around the IID access and hemiparesis of the right limbs. Complementary study revealed a severe pancytopenia, high levels of C-reactive protein (CRP) and CT-

scan imaging showed signs of acute stroke. Blood cultures for the detection of bacteraemia were taken, IID was removed and large-spectre antibacterial therapy initiated.

In the infirmary the patient had initially clinical worsening under empiric therapy, with persisting fever and increasing levels of CRP. Admission blood cultures were positive for coagulase-positive *Staphylococcus*, while every other culture taken past that point was negative. Transthoracic echocardiography revealed a mitral valve with severe insufficiency and the presence of a vegetation. A CT-scan of the body was also performed which showed signs of tissue infarction of the lung, liver, spleen and kidneys, raising the likeliness of the septic embolization from the infected IID and the mitral valve. Antibacterial therapy was adjusted multiple times and the patient got progressively better under a combined therapy of gentamicin, ceftriaxone and ampicillin, being discharged after 30 days in the hospital, maintaining regular follow-up.

Discussion

As described with this case report, septic embolization is an important cause of morbidity and can even be fatal in hospital care. Because of its wide clinical variety, it can be a hard complication to manage, putting the internist in the most adequate position to treat this kind of patients due to its holistic nature.

One important note about this complication is the fact that antibiotic resistance is progressively growing, making these events more frequent and harder to treat effectively. Thus, our focus must not only be on the treatment but also in the effective prevention of its occurrence.

#1862 - Abstract

ANTIBIOTIC USAGE TRENDS IN AN INTERNAL MEDICINE WARD – A RETROSPECTIVE STUDY

Torcato Moreira Marques, José Sousa, Diogo Antão, Lourenço Cruz, Teresa Ferreira, Catarina Pires, Valentina Tosatto, Tiago Pack, Cristiano Cruz, Paula Nascimento, Afonso Rodrigues, André Almeida, Teresa Garcia, Patrícia Cachado, Rita Barata Moura, António Sousa Guerreiro

Hospital de Santa Marta - Centro Hospitalar Universitário de Lisboa Central, Lisboa, Portugal

Background

Antimicrobial stewardship has become increasingly more important in the more recent years due to the global problem that is multidrug-resistant microbes. Despite this, broad spectrum antibiotics are still used in large scale. The aim of this study was to identify the main classes of antibiotics used and if they were prescribed according to agents' identification.

Methods

From all the patients admitted to the Internal Medicine ward of Hospital de Santa Marta in 2018, those admitted for infectious causes were selected and clinical data was gathered with patients permission. Sex, age, diagnosis, isolation site, empirical

and adjusted antibiotic therapy were gathered in a database. Statistical analysis was done with Microsoft Excel.

Results

From all patients admitted in 2018 (N=953), 259 (27.1%) had initial infectious causes. The mean age was 76,1 years and 56.3% (N=146) were female. The infected site was mainly (51.3%, N=133) the respiratory tract, followed by the urinary tract, (28%, N=74). Abdominal foci were the less representative, 0,7% (N=2). In almost 56% (N= 45) of the cases, a microorganism isolation was possible, 42% (N=62) of the times in urine and 22% (N=32) in blood samples. Gram negative bacteria were the leading isolated microorganisms, 60% (N=87), followed by Gram positive, 25% (37). To treat these infections empirically, mainly 3rd generation cephalosporins were used, amongst which ceftriaxone was the most used, 38% (N=98). Beta-lactams was the second most used group of antibiotics ~40% (N= 103), namely amoxicillin-clavulanate 26% (N=69) and piperacillin-tazobactam 13% (N= 34). Carbapenems (2%), glycopeptides (2.7%), polymyxins (1%), oxazolidinones (0.7%) were spared as empirical treatment as a measure of antimicrobial stewardship of our department. Antibiotics were changed 45 times after the isolation of a specimen and a AST. In this new group, the trend was the same with cephalosporins leading (44%, N=20). More carbapenems were used in this new group, 22% (N=10), specially meropenem (6 out of 10). When in need to treat ESBL producing bacteria, carbapenems were the most used, 38% (N=5), followed by cephalosporins (ceftazidime, cefepime) 23% (N=3). Tigecycline, meropenem, colistin and cefepime were successfully used to treat carbapenemase producing bacteria.

Conclusion

Despite antibiotic stewardship, large spectrum antibiotics are still used a lot when empirically treating infections. Deescalating therapy has to be a concern, as resistant bacteria become more prevalent.

#1865 - Abstract

GEOGRAPHICAL WEIGHTED REGRESSION MODEL TO EXPLAIN THE SPATIAL VARIABILITY OF ZIKA AND CHIKUNGUNYA VIRUS INFECTIONS IN THE REGION OF RECIFE, BRAZIL

Rafael Silva Dos Anjos¹, António Pais-De-Lacerda^{2,3}, Ranyére Silva Nóbrega⁴, Nuno De Sousa-Neves⁵

¹ Universidade Federal de Pernambuco, Brasil, Pernambuco, Brazil

² Serviço de Medicina 2, Hospital de Santa Maria, CHULN, Lisboa, Portugal

³ Faculdade de Medicina da Universidade de Lisboa, Lisboa, Portugal

⁴ Departamento de Ciências Geográficas da Universidade Federal de Pernambuco; Centro de Filosofia e Ciências Humanas, Pernambuco, Brazil

⁵ Departamento de Paisagem, Ambiente e Ordenamento - Escola de Ciências e Tecnologia Universidade de Évora, Portugal CICS.NOVA - Centro Interdisciplinar de Ciências Sociais CE3C - Centre for Ecology, Evolution and Environmental Changes, Évora, Portugal

Background

The conditions related to vector proliferation and arboviruses infections outbreaks are complex and involve both individual and environmental characteristics that vary from place to place being associated with a spatial distribution of the spread of the diseases. It can be argued, therefore, that these epidemiological data constitute a true geographical phenomenon. The use of Geographical Weighted Regression (GWR) is becoming increasingly popular as a way to access and model spatial non-stationary phenomena, with alleged advantages over classical global regression models i.e Ordinary Least Squares (OLS). Medical conditions associated with spatial location are using this type of approach to establish formal reproducible relations with environmental/social covariates with spatial variability. We compared the performance between these two methods (GWR/ OLS), together with variations on spatial informative units, for the definition of the epidemic contamination model with the Zika (ZIKV) and Chikungunya (CHIKV) viruses in the urban area of Recife - Brazil. The analogy between GWR and OLS considered also two types of spatial informative units (census units and 100 meters regular cell matrix).

Methods

This study was carried out in Recife, the largest urban tropical agglomeration of the North/Northeast Brazil Regions (1,637,834 inhabitants). Recife's Health Secretary provided data on Zika and Chikungunya confirmed cases. During 2015-17, 4861 infections were identified (124 ZIKV; 4737 CHIKV). Explanatory variables were grouped into three categories: Social, Environmental and Infrastructures. All these variables were standardised. The comparison between GWR and OLS considered two types of spatial informative units (census units and 100 meters regular cell matrix), where both response and independent exploratory variables were represented exploring the identified risk factors and their relationships with spatial distribution of ZIKV and CHIKV infections in the mentioned area.

Results

Both methods demonstrated the interaction between some factors and the arboviruses spread, being, however, complex.

Conclusion

This study is inherently exploratory in the attempt of establishing a reproducible approach in epidemiological spatial modelling of Zika and Chikungunya virus infections that may also deal with non-stationary characteristics of the studied phenomena, further facilitating a faster clinical detection in situations of foreseeable risk.

#1868 - Case Report

A CASE OF CRYPTOCOCCAL MENINGITIS WITH A FAVOURABLE OUTCOME

Ester Freitas, Odeth Tjikongo, Ana Abreu, Irina Ferreira, Manuela Neto

Clínica Sagrada Esperança, Luanda, Angola

Introduction

Cryptococcus Neoformans (CN) is a ubiquitous fungus that can infect patients with untreated or poorly controlled Human Immunodeficiency Virus (HIV)/Acquired Immunodeficiency Syndrome (AIDS), mainly in the form of Cryptococcal meningoencephalitis. Increased availability of anti-retroviral therapy (ART) has considerably reduced the incidence of Cryptococcal meningitis globally, however in Sub-Saharan Africa it remains a leading cause of mortality amongst HIV/AIDS patients.

Case description

A 43 year old angolan man, with no relevant past medical history, presented to the emergency department with a 5 day history of fever, frontal and pulsatile headache of moderate intensity (7/10 on the pain scale). He received artemisinin-based treatment for malaria falciparum 72 hours prior, with no improvement and developed periods of agitation. On examination he was febrile (38°C), disorientated in time, place and person, Glasgow coma scale score of 14/15, with nuchal rigidity, a positive Kernig's sign and oral candidiasis, with no focal neurology. A rapid diagnostic test for HIV was positive. A Computed tomography (CT) brain showed no significant abnormalities. Cerebrospinal fluid (CSF) analysis revealed hypoglycorrhachia (10mg/dl), high proteins (80 mg/dl), pleocytosis of mononuclear predominance and presence of CN on microscopy with India ink stain. There were also indirect signs of increased intracranial pressure during lumbar puncture. We began treatment of the induction phase with amphotericin B and fluconazol due to the unavailability of flucytosin.

Subsequent blood results showed severe immunosuppression with a CD4+ count of 14 cells/uL and viral load of 284,461cp/ml, hepatitis B co-infection and confirmed CN on CSF culture. The patient completed 14 days of treatment with amphotericin B and was discharged afebrile and with a normal mental state. In follow-up he was initiated on ART 3 weeks after diagnosis with no complications and then completed the consolidation phase with 8 weeks of fluconazol.

Discussion

This has an impact on the survival of these patients, as combination therapy with amphotericin B and flucytosin has been shown to be superior in multiple studies. Poor prognostic factors include abnormal mental state which can reflect the degree of increased intracranial pressure, CSF antigen titer >1:1024 and a low CSF white blood cell count (<20 cel/microl) which demonstrates a poor host response.

#1872 - Case Report

A DIFFICULT SPONDYLODISCITIS

Sérgio Antunes Da Silva, Domingos Sousa, Catarina Jorge, Margarida Viana, Sara Aleixo, Rita Fernandes, Ana Isabel Rodrigues, Diana Reis, Elena Rios, Mário Lázaro
CHUA - Hospital de Faro, Faro, Portugal

Introduction

Spondylodiscitis is the infection of one or more extradural structures of the spine and the most common agents involved are staphylococcus aureus and escherichia coli (E.coli). Its incidence is low, it usually affects adults older than 50 years old and is characterized by its heterogeneous presentation that can hinder the diagnosis.

Case description

Male, 78 years old with personal history of hypertension, dyslipidemia and hyperuricemia was sent to Emergency Ward (EW) due to fall, loss of sphincter control and dysarthria, with no reference to spinal pain. The blood tests results were elevation of inflammatory parameters (leukocytosis - 17200/mm³- and C reactive protein (CRP) - 273mg/dL); chest x-ray showed a consolidation on right lung base; the head CT had no acute changes. Was admitted to the medical ward with the diagnosis of community acquired pneumonia and started empiric antimicrobial therapy (ceftriaxone and azithromycin) that was latter switched changed due to positive blood cultures for E. coli. Despite clinical improvement, inflammatory parameters continued elevated which lead to a new septic screening with positive urine culture for Enterococcus faecium.

Even with a new course of antibiotics, CRP continued elevated (>200 mg/dL) as well as erythrocyte sedimentation rate (>100 mm/hr) and ferritin (>2000 ng/mL) so a computed tomography of thorax, abdomen and pelvis was done (for exclusion of an infeccious/neoplastic foci) which showed a densification of paravertebral planes at the level of T9-T10, suggestive of spondylodiscitis. Latter this diagnosis was confirmed by a spinal MRI.

Discussion

This case report demonstrates how an elevated suspicion is required in order to make a diagnosis of spondylodiscitis, since it is not a straightforward diagnosis. Also, there was an atypical absence of both lumbar pain and risk factors coupled with several intercurrents that furthermore made the diagnosis so challenging

#1875 - Case Report

FOURNIER'S GANGRENE: A RARE DISEASE WITH A COMMON BUT RAPIDLY PROGRESSIVE PRESENTATION

Rita Bizarro¹, Carolina Coelho¹, Angela Ghiletschi¹, Rita Lencastre Monteiro¹, Joana Diogo¹, César Vieira¹, Cátia Carvalho¹, Mariana Medeiros², Rita Camelo², Ana Gonçalves¹, Conceição Loureiro¹

¹ Centro Hospitalar e Universitário de Lisboa Central, Hospital de Santo António dos Capuchos, Lisboa, Portugal

² Centro Hospitalar e Universitário de Lisboa Central, Hospital de São José, Lisboa, Portugal

Introduction

Fournier's gangrene or perineal necrotizing fasciitis is a medical condition with high morbidity. It represents 0,02% of hospital admissions and has a 7.5% mortality rate. It's related to some frequent pathologies such as anorectal fistula/fissure, inflammatory bowel disease, colic diverticulitis or as a consequence of urinary tract trauma caused by long term urinary catheterization.

Case description

Male, 80 years old, with medical history of neurogenic bladder and benign prostatic hyperplasia which led to a 7 year urinary catheterization with recurrent urinary tract infections. The patient was admitted with a diagnosis of cystitis. At the physical exam, the urine was visually concentrated and with high sediment. It was found a large scrotal mass, with hyperaemia, painful with no sign of fistula or pus. The blood test revealed a high white blood cell count (21000 cells) with 90% predominance of neutrophils, C-reactive protein of 265 mg/L and compromised renal function. The urine test was positive for leukocytes (2000 UFC/ml) and negative to nitrites. We started antimicrobial therapy with piperacillin tazobactam assuming long term bladder catheterization and multiple hospital admissions as risk factors. After 5 days, the patient had fever and developed a spontaneous drainage of inguine-scrotal pus. The CT-Scan revealed a large scrotal hernia containing the descending and sigmoid colic segments and also an exuberant, multiloculated purulent collection around the perineal region (involving the anal canal), the prostate gland and also the anterior abdominal wall.

This presentation suggested a Fournier's gangrene. The patient was submitted to surgery where multiple necrotic plaques were excised from the scrotal sac and the purulent material was drained. The hernia was reduced with a resection of the whole sigmoid colon. A colostomy was also placed. There were a posterior bladder perforation and a bacteremia to *Staphylococcus aureus* resistant to methicillin as complications. Vancomycin was added to therapy. There was a good evolution after a long period of hospitalization.

Discussion

With this case, the authors want to emphasize that, although Fournier's gangrene may present as a common infectious perineal pathology, the diagnosis should be fast as this can lead to a fatal outcome. They intend to show the exuberance and extension of its alterations and to review the etiology, therapeutics and complications associated with this pathology.

#1878 - Medical Image

MILIARY TUBERCULOSIS - STILL A REALITY NOWADAYS

Mariana Batista Constante, Ana Rita Barradas, Margarida Fonseca, João Lopes Delgado, Isabel Madruga
Centro Hospitalar de Lisboa Ocidental, Lisbon, Portugal

Clinical summary

A 70-year-old woman with history of ischemic stroke, hypertension and atrial fibrillation goes to the emergency room with fatigue, exertional dyspnea and weight loss. She had been hospitalized 6 months prior due to ascites and diagnosed with cardiac cirrhosis. Her x-ray showed a nodular pattern (2) that was not present before (1), and the CT revealed 'micronodular formations, some coalescent, predominantly centri-lobular' (3), findings compatible with miliary tuberculosis.

Tuberculosis still has a significant incidence in Portugal. Miliary tuberculosis results from its hematogenous dissemination and typically appears in immunosuppressed individuals. Our patient started treatment with adequate antimicrobials and is undergoing a screening of the most common causes of immunosuppression.

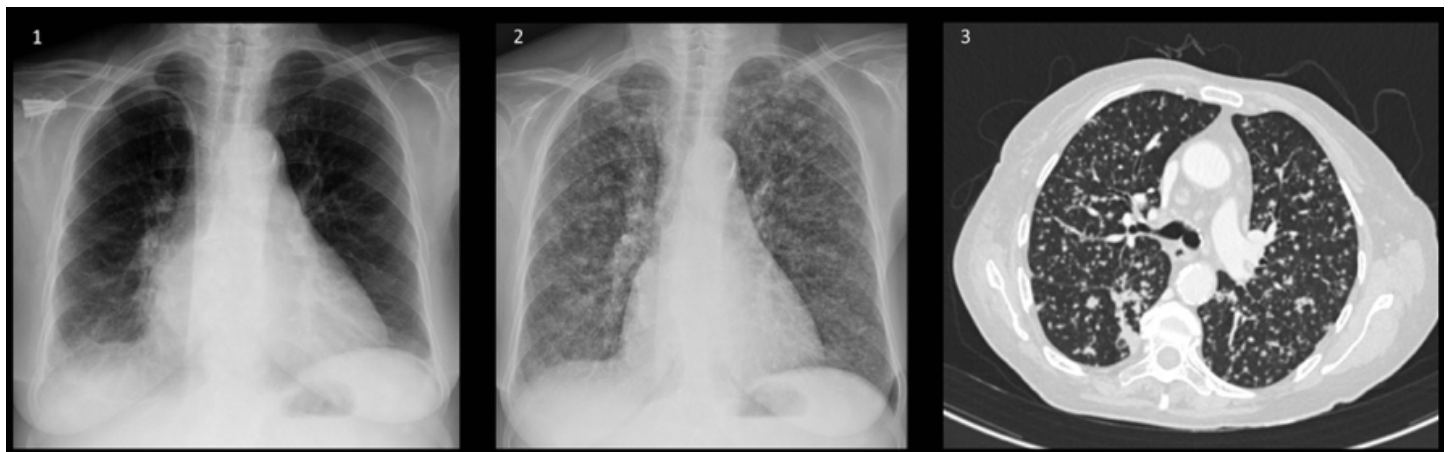

Figure #1878.

#1883 - Case Report

THE GUEST IN THE CAVE

Ana Canoso, Ana Filipa Rodrigues

Centro Hospitalar do Oeste - Unidade Caldas da Rainha, Caldas Da Rainha, Portugal

Introduction

Aspergillus is an inhabitant of soils and found in organic debris, garbage, food, condiments, and plants in process of rotting. Some species are pathogenic for humans, with a large specter of disease symptoms, and generally insidious.

Case description

A 75-years-old male patient with low fever, cough and shortness of breath for three weeks. Moreover referred for the past month anorexia and weight loss of about 5kg. He had no nocturnal perspiration, no haemoptysis, no trips out of the country, no recent insect bites or other adjunctive factors or complaints. He had history of smoking – abandoned for the last 10 years; no other significant history factors. On examination he had diminished pulmonary sound and no other positive findings – namely fever, adenopathies or others. Blood tests evidenced leukocytosis and elevated inflammatory parameters. Chest x-ray showed a filled cavitation in the left superior lobe. Chest CT describes a 4cm cavitation filled with solid content suggestive of aspergilloma. No granulomas found. HIV, hepatitis, Syphilis were negative. Flow cytometry of lymphocyte population normal. Performed bronchofibroscopy – PCR for mycobacterium tuberculosis : negative; bacterial cultures were negative. alactomanan positive; specific IgE for aspergillus positive. After discussion with Pneumology, he was started on antibiotic and anti-fungic therapy under the suspicion of Aspergilloma with bacterial associated infection, and will be posteriorly referred for pulmonary surgery given single aspergilloma lesion.

Discussion

The presence of a pulmonary aspergilloma in immunocompetent patients is mainly reflection of colonization instead of infection. The differential diagnosis can be sometimes challenging and not always easy to achieve. In solitary lesions, without over infection, surgery is the main line of treatment.

#1899 - Case Report

ACUTE PSEUDO-APPENDICITISRenata Oliveira Monteiro¹, Sónia Bastos Moreira²¹ CHVNG/E, Gaia, Portugal² CHUC, Coimbra, Portugal**Introduction**

The presentation of an infectious gastrointestinal disease can mimic other non-infectious pathologies with surgical treatment. The review of symptoms chronology and epidemiological context are crucial to differential diagnosis.

Case description

A female patient with 45 years old appeals to the emergency room with fever, abdominal pain and diarrhea. The fever had begun 2 days ago and the abdominal pain was located at the right iliac fossa, had begun 24h after the onset of fever, was episodic and intense without irradiation, and was relieved by the dejections without any worsening factors. At the same time, she had diarrhea, nausea and anorexia since the beginning of the symptoms. No medical background and usual medication of interest. At presentation she was subfebrile, abdomen was tender to palpation of the right iliac fossa, with rebound tenderness. Blumberg sign was inconclusive. The remaining physical examination was normal. Laboratory data revealed elevation of inflammation parameters. An abdominal ultrasound was not able to visualize the ileocecal appendix or bowel wall thickening. Additionally, an abdominal CT scan was made and showed diffuse wall edema of transverse and descending colon, suggesting colitis. We further asked the patient and she reported consuming homemade unpasteurized cheese 3 days before the onset of the symptoms. There was history of a 31-year-old cousin hospitalized with the same symptoms 1 week before. The faecal multiplex PCR testing detected the presence of Campylobacter and E.Coli shigatoxin producer (STEC). The patient completed 5 days of ciprofloxacin with resolution of the symptoms. She was released with the diagnosis of Campylobacter and STEC gastroenteritis.

Discussion

This case regards the fact that has been reported that the clinical presentation of a Campylobacter acute gastroenteritis can mimic an acute appendicitis. Usually, the first symptom to arise is a fever that is followed by iliac fossa abdominal pain, diarrhea, nausea and anorexia. The incubation period is around 3 days, as this patient reported consuming unpasteurized cheese. The usual sources of infection are handling and consuming undercooked meat, and consuming contaminated water, milk or milk derivatives. Campylobacter colitis usually affects the jejunum and ileum and progressively extends distally. It is debatable if the symptoms are mimicking and appendicitis or if there is a true appendicitis induced by Campylobacter.

#1903 - Case Report

MYCOBACTERIUM TUBERCULOSIS INFECTION OF THE GASTROINTESTINAL TRACT: A CASE REPORT

Rosario Blanco, Rafaela Pereira, Ana Rita Clara, Ana Pimenta De Castro, Mário Lázaro

Centro Hospital Universitário do Algarve, Faro, Portugal

Introduction

Tuberculosis (TB) remains a global health problem despite de availability of antibiotic treatment. Mycobacterium tuberculosis is the principal etiologic agent of human TB and a member of the M. tuberculosis complex (MTC). Additional MTC species that

cause TB in humans and other mammals include *Mycobacterium africanum* and *Mycobacterium bovis*. Despite pulmonary tuberculosis is the most common presentation, the non-pulmonary presentation represents 11-16% of all cases, being 3-4% abdominal tuberculosis, corresponding to a complex disease with nonspecific signs and symptoms.

Case description

A 61-year-old female presented to the Emergency department with complaints of one week progressive abdominal distension and peripheral edema associated dyspnea and fever. Past medical history of Graves disease, beta-thalassemia, arterial hypertension, atrial fibrillation, moderate aortic stenosis, congestive heart failure with preserved left ventricular ejection fraction and pulmonary hypertension, with regular follow-ups in Cardiology and Endocrinology consults. Physical exam showed ascites and bilateral lower limb edema. Blood test revealed exacerbated microcytic hypochromic anaemia, elevated liver enzymes, hyponatremia, elevated C reactive-protein and HIV test negative. Abdominal ultrasound confirmed ascites with splenomegaly and the abdominal computed tomography exhibit enlarged lymph nodes. Examination of the ascitic fluid revealed a cloudy/white appearance with elevated cell count with lymphocyte predominance, serum ADA level within normal range, serum-ascitic fluid albumin gradient 1.13, positive for proteins, negative staining for acid fast bacilli (AFB). A sample was sent to test Polymerase Chain Reaction (PCR) for MTC. After a week there was positive confirmation for MTC and diagnosis of abdominal tuberculosis was established and the patient started anti-tubercular therapy with ethambutol, isoniazid, rifampicine and pyridoxine.

Discussion

TB is an emergent disease and potential life threatening that that could affect any organ. The past medical history and negative AFB and negative ADA in the ascitic fluid as misleading factors, made the assumption of decompensated heart failure easier, but after all, abdominal TB is a great impersonator. The assessment of PCR of MTC was essential to initiate the anti-tubercular therapy optimizing the patient outcome in an early stage.

#1904 - Case Report

TENDINOUS CORD RUPTURE AFTER ENDOCARDITIS

Catarina Nazário Marouço, Ema Leal, Diogo Drummond Borges, Inês Figueiredo, Marília Fernandes, Rita Vieira Alves, Ana Taulaigo, Margarida Antunes, Filipa Lourenço, Ana Lladó, Sara Guerreiro Castro, Heidi Gruner, António Panarra
Hospital Curry Cabral, Lisboa, Portugal

Introduction

Infectious endocarditis (IE) is associated with several complications. Cardiac complications are the most frequent affecting 50% of patients and acute heart failure (AHF) due to

valvular insufficiency is the main cause of death in IE. In moderate to severe AHF, isolated medical therapy is associated with 75% mortality and early surgical valvular repair decreases the mortality rate to <25%, even before a full course of antibiotics.

Case description

A 64-year-old woman with a history of arterial hypertension and dyslipidemia was admitted to the Emergency Department (ER) due to sudden dyspnea at rest, high blood pressure readings and fatigue for less than normal physical activity for 2 weeks. A systolic murmur was detected, grade III/VI in the mitral focus, with axillary irradiation, with negative inflammatory serum markers. A diagnosis of an inaugural episode of AHF due to hypertensive crisis was made. The patient asked for discharge from the hospital against medical advice. Five days later she was taken again to the ER due to myalgia and anorexia. The patient was feverish and hypoxemic, with increased inflammatory serum markers and leukocyturia. She was admitted for AHF due to acute pyelonephritis. Blood cultures at admission were positive for Methicillin-Susceptible *Staphylococcus aureus*. The patient was started on intravenous (IV) flucloxacillin and Transthoracic and Transesophageic Echocardiogram revealed severe mitral regurgitation (MR) with tendinous cord rupture, which, despite the absence of vegetations, was admitted in the context of IE. After a 2-week course of IV flucloxacillin, the patient was discharged given clinical stability, with a further 2-week course of oral flucloxacillin and follow-up by Cardiac Surgery. One week later she presented again to the ER with severe hypoxemia, requiring invasive ventilation for 6 hours. Chest radiography showed bilateral alveolar infiltrates. Acute hypertensive pulmonary edema with respiratory failure was admitted in a patient with severe MR. After clinical stabilization, the patient underwent surgical repair of the mitral valve, without further complications.

Discussion

This case demonstrates the morbidity and unfavorable evolution in severe valvular dysfunction as a complication of IE despite optimized medical therapy, clearly showing the need for early surgical treatment in symptomatic patients.

#1912 - Abstract

ANTIBIOTIC PRESCRIPTION HABITS AND ANTIMICROBIAL RESISTANCE IN URINARY TRACT INFECTIONS IN AN EMERGENCY DEPARTMENT – A RETROSPECTIVE STUDY

Lúis Landeiro, Teresa Gantes Padrão, Nuno Maia Neves, Susana Carvalho Coelho, Pedro Morais Sarmiento, Alexandra Bayão Horta, João Sá
Hospital da Luz Lisboa, Lisboa, Portugal

Background

Proper antibiotic prescription is an essential strategy to prevent antibiotic resistance (AbR). Urinary tract infection (UTI) is probably

the main cause of empiric antibiotic prescription around the world and therefore one of the main reasons for AbR emergency. We analyzed the rate of AbR and the suitability of antibiotic prescription among patients who came to the emergency department (ED) with a suspected UTI.

Methods

We conducted a patient-level, retrospective, cohort analysis of all patients with a positive urine culture at our hospital ED in the period of January to March 2018.

We analyzed the characteristics of the population, namely gender, age, whether it was a complicated or uncomplicated UTI based on the presence of systemic symptoms, as fever, chills, fatigue and flank pain, or a history of recent hospitalization or urinary catheterization.

We evaluated the most common pathogens and their resistance patterns. We further evaluated the rate of inadequate selection of antibiotics regarding personal history, recent antibiotic exposure, clinical severity and the recommended antibiotic options. We considered trimethopim-sulfamethoxazole (TMP-SMX), fosfomicin, nitrofurantoin or amoxicillin-clavulanate (co-amoxiclav) viable first options for the treatment of uncomplicated UTI. Co-amoxiclav, TMP-SMX, broad spectrum cephalosporins, piperacillin-tazobactam and fluoroquinolones (FLQ) were considered viable options in complicated UTI.

Results

Of 601 cases with positive urine culture, 495 (82.4%) were females. The average age of the entire population was 49 years. The most common species isolated were *Escherichia coli* [n=423 (70.4%)], *Staphylococcus saprophyticus* [n=48 (8%)] and *Proteus mirabilis* [n=45 (7.5%)]. Antimicrobial resistances were as follows: co-amoxiclav 21.6%, TMP-SMX 14.6%, FLQ 8.5%. The antibiotic choice was inadequate in 31% of all cases. FLQ were inadequately used in 12.3% of the female patients (n=61), most of them with uncomplicated UTI (n=55). Of the positive isolates, 2.2% were extended-spectrum beta-lactamases producing organisms.

Conclusion

This study of community-related UTI's shows significant AbR rates for commonly used oral antimicrobials. Co-amoxiclav has the highest rate (21.6%), suggesting it should not be used as a first line antibiotic in patients with uncomplicated UTI, in our population. There is an inadequately high prescription rate of FLQ in females with uncomplicated UTI, despite the strong recommendation to avoid its use in Europe.

#1914 - Case Report

WHIPPLE'S DISEASE - A RARE OCCURRENCE

Isabel Martins Cruz, Marina Henriques Mendes, Francisco Torres Pombo, Ana Antunes Ribeiro Sousa, Pedro Lopes, Mari Mesquita
Centro Hospitalar Tâmega e Sousa, Penafiel, Portugal

Introduction

Whipple's disease (WD) is a rare multisystemic infectious disease caused by *Tropheryma whipplei* (TW). The most common symptoms are arthropathy, diarrhoea, abdominal discomfort and weight loss. Although fatal without treatment, adequate antibiotic therapy results in complete remission.

We report a case of a female patient who presented chronic diarrhoea due to WD with intestinal, lung and possible cardiac involvement.

Case description

61 year-old woman with history of hypertension, ischemic stroke, heart failure (HF) with preserved ejection fraction, duodenitis and migratory polyarthralgia, presented to the emergency department with complaints of asthenia, 10Kg weight loss and diarrhoea for the past three months.

On physical examination she was tachycardic, hypotensive and presented abdominal pain.

Blood analyses revealed anemia, leukocytosis and neutrophilia, high c-reactive protein, acute kidney injury, hyponatremia, hypokalemia and hypoalbuminemia.

She was admitted to the ward and started on ciprofloxacin.

During hospitalization a thoraco-abdominopelvic CT scan revealed cardiomegaly, bilateral ground glass opacities and colon distension. The upper and lower endoscopies were unremarkable. Small intestine biopsies revealed positive PAS staining and TW was identified in PCR testing for TW. In order to evaluate pulmonary involvement, a transthoracic lung biopsy was done and confirmed positive PAS staining as well as positive PCR testing for TW. CNS involvement was excluded. Transthoracic and transoesophageal echocardiogram revealed thickness of the leaflets of the tricuspid valve and severe insufficiency, small pericardial effusion and two echogenic pedunculated masses, highly suggestive of thrombi in the left atrium. These disappeared after a period of parenteral anticoagulation, when cardiac magnetic resonance imaging was performed, supporting its thrombotic aetiology.

The patient started on ceftriaxone 2 g daily IV for 4 weeks, with great clinical improvement and then prescribed with oral trimethoprim-sulfamethoxazole twice a day for one year.

Discussion

Our case reflects the multisystemic involvement of WD. Cardiac involvement is a common manifestation in WD and it might present as mitral or aortic insufficiency, pericardial effusion or HF. Although a heart biopsy was not performed the tricuspid valve alterations and pericardial effusion points to cardiac involvement in the setting of WD, as well as the finding of intracavitary thrombi, a presentation not previously described.

#1926 - Medical Image

MILIARY TUBERCULOSIS

André Santos, Lénea Porto, Dora Gomes, Giovanna Ennis, Carolina Ferreira, Elisa Moreira, José Martins, António Correia
CHTV, Viseu, Portugal

Clinical summary

72 years old male patient who presented with asthenia, anorexia, loss of about 7 kgs in 4 months and history of night sweats and some occasional episodes of cough with hemoptysis. The patient denied fever, dyspnea or other respiratory symptoms. The patient had known antecedents of type 2 Diabetes mellitus, hypertension, stage 4 chronic kidney disease and pancytopenia currently in study. At the admission the chest radiography presented with widespread milletlike pathern opacities that raised the suspicion of miliary tuberculosis. The chest CT scan confirmed the presence of countless diffuse infracentimetric solid nodules, reaching all segments of both lungs and several mediastinal adenopathies. Respiratory samples collected by bronchofibroscopy confirmed the presence of M. tuberculosis.

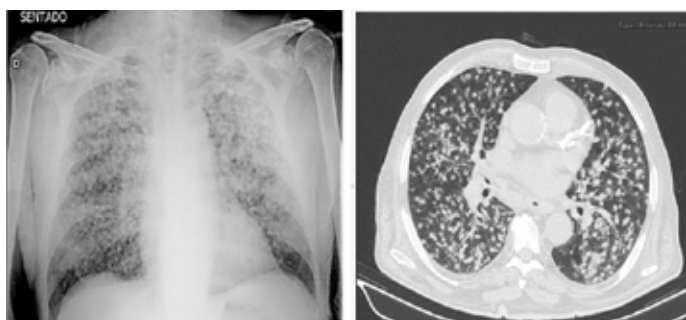


Figure #1926. Chest radiography and chest CT scan.

#1938 - Case Report

TREATMENT OF ACUTE AND SUBACUTE COMPLICATIONS OF SEVERE ACUTE PANCREATITIS WITH CEFTOLOZANO/TAZOBACTAM

Marina Lugarà¹, Stefania Tamburrini², Carolina Bologna¹, Gabriella Oliva¹, Maria Gabriella Coppola¹, Paolo Tirelli¹, Pasquale Madonna¹, Claudio Deluca¹, Anna Guida¹, Nunzia Silvestri¹, Antonietta Desena¹, Cristiana Sellitto¹, Ernesto Grasso¹

¹ UOC Medicina Generale - Ospedale Del Mare - ASL Napoli 1 Centro, Napoli, Italy

² UOC Radiologia - Ospedale Del Mare - ASL Napoli 1 Centro, Napoli, Italy

Introduction

A 61-years-old man, with prior cholecystectomy, referred to our ER for acute abdominal pain, vomiting and fever. Diagnosis of acute pancreatitis was made based on clinical symptoms and laboratory tests (hyperamylasemia, lypasemia, PCR 20, PCT 2, WBC 15,000, AST 70, ALT 80, GGT 50, total bilirubin 2, creatinine 1.5 mg/dl, PA 110/60 mmhg, FC 110, SPO2 94%). CT diagnosis revealed acute necrotizing pancreatitis with intra and extra-pancreatic inhomogeneous non-liquefied fluid.

Case description

The patient was admitted to the General medicine department, antibiotic therapy (meropenem, piperacillin/tazobactam), intravenous fluids and pain control drugs were administered. After 8 hours, severe metabolic acidosis occurred and patient rapidly worsened: pH 7.22, lactate 4 mmol/L, PA 90/60 mmhg, Spo₂ 86%, po₂ 60 mmHg, pco₂ 35 mmHg, FC 110, HCO₃⁻ 15 mmHg, WBC 22.000, PCR 40, PCT 5, creatinine 1.6 mg\dl, HB 10 gr/dl, blood culture were negative. The acute decompensation with hypotension and shock was assumed to be a progression of pancreatitis with complicated potential infection. Oxygen therapy was administered 2/l min, hydration was increased, bicarbonates corrected. CT re-staging after 72 h did not show any significant modifications, there were no CT signs of infections, intra and extra-pancreatic inhomogeneous, non-liquefied fluid appeared more organized, and the necrotic pancreatic areas more delineated. Ultrasound guided drainage was performed: 200 cc of citric liquid were drained, with negative microbiological culture tests. Despite the therapy, the patient was febrile, repeated blood culture were still negative, flogosis indices were unchanged. After 7 days, therapy was modified introducing a new off-label combination of antibiotics: ceftolozano/tazobactam+metronidazole. Patient rapidly improved, and multimodality imaging (CT and MRI) at 4 weeks, showed walled off necrosis (WON) in necrotizing pancreatitis with intra and extra-pancreatic inhomogeneous, non-liquefied components, encapsulated with wall, with small fat globules in the peri-pancreatic collections and still no signs of infection of fluid collections. Despite the initial diagnosis of acute necrotizing pancreatitis, and the significant glandular loss, the patient was discharged with normal pancreatic function and inflammation rates.

Discussion

The new combination of antibiotics (off-label) administered for 21 day, allowed a non-surgical treatment of the patient, and no fluid collections infections occurred.

#1940 - Case Report

COMMUNITY-ACQUIRED METHICILLIN-RESISTANT STAPHYLOCOCCUS AUREUS SEPSIS FOLLOWING INTRAMUSCULAR INJECTIONS: A CASE REPORT

Laura Puceta^{1,2}, Alise Gramatniece^{1,2}

¹ University of Latvia, Riga, Latvia

² Pauls Stradins Clinical University Hospital, Riga, Latvia

Introduction

The incidence of community-acquired methicillin-resistant Staphylococcus aureus (CA-MRSA) infections is increasing globally. We report a case of a severe CA-MRSA infection following intramuscular injections in a previously healthy female.

Case description

A 34-year-old professional dancer presented to the Emergency

Department (ED) with progressing diffuse myalgia and fatigue for seven days. Two weeks ago due to myalgia after intense workouts, she received intramuscular injections of analgesics at home setting. Her past medical history was unremarkable, no prior hospitalizations. On examination she was lethargic, had tachycardia 120 bpm, BP 90/60 mmHg, fever 39.6° C. Laboratory workup revealed a white cell count of 11200/ μ L and a CRP of 268 mg/L. Computed tomography showed multiple abscesses in the thigh, thorax and abdominal wall, also bilateral pleural effusion and septic emboli in both lungs. Antimicrobial therapy with ciprofloxacin and oxacillin was initiated at the ED. Spine MRI was scheduled and identified multiple paraspinal abscesses (Th11 to L2) and abscesses in iliopsoas muscle. Blood cultures were obtained and alerted positive for MRSA. Antimicrobial therapy was switched to Vancomycin. Echocardiography, head MRI and immunological tests were all unremarkable. On the third day of hospitalization, blood cultures came positive for CA-MRSA, resistant to erythromycin, penicillin G, ceftioxin. Numerous incisions and drainage of the abscesses were performed. Within a week, due to the recurrent fever, MRI was repeated and showed additional abscesses in the left upper arm. Furthermore, pyothorax was identified and thoracoscopic drainage using video-assisted thoracic surgery was carried out. Within a month on the follow-up MRI the abscesses were reduced but osteomyelitis in the right femur was noticed. The patient was transferred to the Traumatology Hospital for surgical treatment. After three months' hospitalization, multiple surgeries and antibacterial therapy she was discharged for further rehabilitation. The patient was able to resume physical activities and dancing.

Discussion

We have described a case of CA-MRSA infection progressing to sepsis, multiple abscesses, pyothorax and osteomyelitis after intramuscular injections in a young and previously healthy patient. This case emphasizes the necessity of timely imaging, microbiological diagnostics, surgical drainage and interdisciplinary approach in order to improve patient prognosis.

#1944 - Abstract

PNEUMOCYSTIS JIROVECI PNEUMONIA IN AN INTERNAL MEDICINE SERVICE

Inês Lopes Da Costa, Diogo Faustino, Isabel Baptista
CHULC - Hospital de São José, Lisboa, Portugal

Background

Pneumocystis jirovecii pneumonia (PJP) is a frequent opportunistic infection in patients with Human Immunodeficiency Virus (HIV) infection, with low CD4+ lymphocyte count (<200 cells/ μ L), but is also associated with other factors of immunosuppression like underlying malignancies, organ transplantation and immunosuppressive therapy. In this study we aim to characterize the population of patients with PJP in a ward of internal medicine.

Methods

Retrospective review of the medical records of the patients in a ward of internal medicine, with the diagnosis of PJP, between January 1 st of 2008 and December 31 st of 2018. Demographic, clinical and laboratorial data were collected and analyzed. Data from were compared between the group with HIV and the group with other causes of immunosuppression.

Results

35 cases of PJP were identified (25 males) with mean age of 49.2 \pm 12.4 years; 28 had HIV (type 1) and 7 presented other immunosuppressive conditions. The HIV group had a lower mean age (43.8 \pm 12.4 versus 71.6 \pm 1.9 years) and a shorter mean stay (25.7 \pm 2.2 versus 33.7 \pm 20.6 days). At admission 24 patients presented CD4+ counts <50 cells/ μ L and in 12 cases (44.4%) the PJP lead to the diagnoses of HIV infection with PJP presenting as the first major opportunistic infection. The other group was very heterogeneous and the immunosuppression factors identified were Non-Hodgkin lymphoma (2), Waldenstrom macroglobulinemia (1), oesophagus cancer (1), lung cancer (1), corticotherapy (2) and advanced age (1). A total of 16 patients presented oral and/or oesophagus candida infection. There was no difference in the clinical presentation and both groups were treated similarly (21 days of trimethoprim + sulfamethoxazole and corticotherapy). The condition proved to be an important cause of morbidity - 18 cases (5 in non-HIV group) required admission in an intensive or intermediate care unit due to respiratory failure, and mortality - 9 patients died, 4 in the non- HIV group.

Conclusion

PJP is an uncommon disease, besides its historical association with HIV infection, may be present in patients with other conditions, and should be included in the differential diagnosis. In the literature, there is a difference between the HIV and the Non-HIV infected patients, presenting the latter more aggressive clinical course and higher mortality. Despite the small sample, this study seems to show this tendency.

#1945 - Case Report

CRISES VERSIVAS, MANIFESTAÇÃO DE ENCEFALITE VIRAL.

Jesennia Chinchilla, Sara Nicolau, Dilorom Alimova
Hospital de Santarém, Santarém, Portugal

Introduction

In the United States, herpes zoster occurs in more than 1.2 million individuals annually, causing substantial morbidity. The United States Centers for Disease Control and Prevention estimates that approximately 30% of persons in the United States will experience herpes zoster during their lifetime. Incidence rates progressively increase with age, presumably due to the decline in virus (VZV)-specific cell-mediated immunity. The epidemiology is similar worldwide.

Case description

R.P.C. 74 years old, Caucasian. With a personal history of arterial hypertension.

He started with herpetic dermatitis in the left hemithorax, went to the Emergency Department, was treated with Ganciclovir and Gabapentin. The next day he started with a change in his state of consciousness, so he was taken to the Emergency Department again. The entrance presented the eyes and the head with discreet movements up and to the right. Pupillary dilation. He had right hemicorporal clonias.

Medicated with diazepam and valproic acid in infusion, with which myoclonias and epileptic crisis subsided. Carried out complementary analyzes without significant alterations; Tc EC without ischemic changes. It performed a lumbar puncture that revealed rock-like liquid, proteins 74 mg dL, glucose 80 mg/dl, chlorine 125 mmol/L, 95 leukocytes/ μ L, 92% mononuclear. By the Polymerase Chain Reaction VZV was identified in the CSF. He was hospitalized and empirically started Acyclovir for 15 days, with neurological status recovery.

Discussion

Herpes zoster-associated encephalitis typically presents with delirium within days following the vesicular eruption, but may occur prior to the onset of rash or follow after an episode of herpes zoster. Although VZV encephalitis is a more common complication in immunocompromised patients, it is also seen in previously healthy hosts.

In the cerebrospinal fluid the differential shows a predominance of lymphocytes, although early infection may reveal a predominance of neutrophils. In the latter scenario, a repeated count of CSF cells eight hours later will generally show a change from neutrophils to lymphocytes.

However, when the diagnosis is uncertain, laboratory confirmation is indicated. Diagnostic techniques include the polymerase chain reaction assay (which is the most sensitive test), direct fluorescent antibody testing, and viral culture.

#1955 - Abstract

VISCERAL LEISHMANIASIS IN IMMUNOCOMPROMISED PATIENTS: A DIAGNOSTIC CHALLENGE

Lazaros Sideras, Vasiliki Tsoutsouli, Georgios Sidiropoulos, Christina Chrysanthi Theocharidou, Georgios Charis Paskalis, Georgios Papadimos, Georgios Koursioupas, Konstantinos Gkogkos

Internal Medicine Clinic of G.Papanikolaou General Hospital, Thessaloniki, Greece

Background

Leishmaniasis is a slowly progressing indigenous parasitic disease caused by intracellular protozoan parasites of the genus *Leishmania*. Greece is considered to be an endemic country for leishmaniasis, with visceral leishmaniasis (VL) being

the predominant form and cutaneous leishmaniasis occurring sporadically. The clinical presentation and course of the disease depend on complex interactions between the parasite and host. Visceral leishmaniasis is a potentially fatal infection especially in immunocompromised patients

Methods

We herein report two cases of VL, with the same place of residence and aim to highlight the atypical manifestations of the disease in immunosuppressed hosts that may complicate the diagnosis.

Case Description

Case 1

A 48-year-old previously healthy woman presented to the emergency department with fever up to 40°C, night sweats and shivering for the past fifteen days. The physical examination was notable for enlarged liver and spleen and confirmed by computed tomography of the abdomen. Laboratory investigation showed pancytopenia and increased inflammation markers. The diagnosis of VL was made based on the bone marrow aspiration cytology and confirmed with real time quantitative PCR. Treatment was promptly commenced with liposomal amphotericin B three days after the admission resulting in complete resolution of the symptoms one month later.

Case 2

A 67-year-old man with a history of rheumatoid arthritis under methotrexate was admitted reporting a 7-month history of fever of unknown origin. The patient was evaluated in a private general hospital for fever, splenomegaly and pancytopenia. Laboratory studies showed pancytopenia and hypergammaglobulinaemia. Splenectomy was performed with the suspicion of splenic lymphoma. The histopathological evaluation of the spleen revealed intense lymphoid hyperplasia. The patient was referred to the hematology department for further treatment. Examination of a bone marrow aspirate revealed amastigotes. The diagnosis was confirmed by parasitological blood test with ELISA and real time quantitative PCR. The patient received intensified treatment with liposomal amphotericin B due to immunosuppression. At 6-month follow-up symptoms had resolved with presence of mild splenomegaly.

Conclusion

The exclusion of *Leishmania* infection should be mandatory in the differential diagnosis of unexplained fever, hepatosplenomegaly and/or cytopenia in immunocompromised patients with a history of migration, travel to or residing in endemic areas.

#1960 - Abstract

MYCOBACTERIUM TUBERCULOSIS INFECTION, A DISEASE FROM UNDERDEVELOPED COUNTRIES?

Rui Isidoro, Pedro Vieira, Filipa Leitão, Joana Carvalho, Óscar Matos, Cleopatra Goric, Paula Paiva, Ricardo Rodrigues, Alexandre Louro, Maria Eugénia André

Amato Lusitano Hospital, Castelo Branco, Portugal

Background

Tuberculosis (TB) is an infectious disease caused by mycobacterium tuberculosis (MT) bacteria, it's known as a poverty-related disease which disproportionately affects the poorest, the most vulnerable and marginalized population group. It represents one of the major public health threats, as the cause of death due to infectious diseases worldwide. In the last decade, a declining trend in TB incidence, prevalence and mortality has been observed, although, elimination of the disease at global level is still far away.

Methods

This study aims to collect and characterize patients diagnosed in hospital care with TB infection from 01/01/2016 until 31/12/2018. The clinical information has been collected through patients digital process analysis and the data processing was made with Excel® application.

Results

30 patients were selected, 22 males and 8 females, with ages from 22 to 92 years old and a mean age of 62 years old. All patients had Portuguese nationality. 11 patients had no risk factors known. The diagnosis of pulmonary TB has been made in 26 patients and 4 patients had extrapulmonary TB, all these last cases represent lymphatic system involvement, presented as cervical scrofula. In pulmonary TB infection patients only 9 had all the 3 most common symptoms. The average disease related symptoms duration was 9 weeks. The diagnosis of 21 patients were made through emergency department admission and 9 patients through outpatient department.

Conclusion

Healthcare providers must be concerned with TB diagnosis and management, early diagnosis and adequate treatment is the corner stone for this infection control in the attempt of reducing community transmission and mortality. TB requires a high grade of clinical suspicion, as many patients have atypical manifestations and lack some of the classical symptoms. This study allowed a better population description, indicating that isn't a disease exclusive from the poorest and with a prevalence that still forces us to remind it every time.

#1962 - Case Report

A MISLEADING FORM OF EXTRA-PULMONARY TUBERCULOSIS: ABOUT AN OBSERVATION

Imen Chaabane¹, Raja Amri¹, Sabrine Bachrouch¹, Zayneb Alaya¹, Rabai Ben Hammouda², Ghada Kharrat², Khaled Bouzaidi³, Siwar Sbaihi³, Abir Chaabane⁴, Emna Chalbi⁴

¹ Department of internal medicine HMTM Hospital, Nabeul, Tunisia

² Department of oral and maxillofacial surgery HMTM Hospital, Nabeul, Tunisia

³ Department of radiology HMTM Hospital, Nabeul, Tunisia

⁴ Department of pathology HMTM Hospital, Nabeul, Tunisia

Introduction

The presence of tuberculoid granuloma with caseous necrosis is the most common histological form of tuberculosis. However, the histological aspect may be in a misleading form and cause a diagnostic difficulty

Case description

Mr Y.D, a 20 years-old student without pathological history, presented since three months a progressive back pain without special irradiation. The evolution was marked by the appearance of left cervical swelling treated with antibiotic therapy but without improvement. A month later he consulted emergencies for left cervical adenitis. The physical examination showed an apyretic patient and supraclavicular lymph nodes on the left measuring 5x3 cm, painful on palpation, erythematous, fluctuating and fistulized in the skin. The osteo-articular examination was without particularity. The biological examination revealed an inflammatory syndrome with a sedimentation rate at 70 mm, a C reactive protein at 40 mg/l. The cervico-thoracic CT scan showed a left supra-clavicular mass centered of two collections associated with homolateral sternocleidomastoid myositis, bilateral hilar lymphadenopathy and expansive osteolytic lesions of D4. Medullary MRI showed tissue bone lesions in the vertebral body and pedicle D4. A biopsy of the left supraclavicular lymphadenopathy was made. Histological examination revealed granulomatous lymphadenitis with pseudo-ischemic necrosis. The tuberculin IDR was 15 mm. HIV serology was negative.

the diagnosis of lymph node and spinal tuberculosis in pseudotumoral form was retained. The patient was treated with antituberculosis treatment for 12 months with a good clinical and radiological enhancement.

Discussion

Tuberculosis is characterized by a great diversity of clinical, radiological and histological expression. the pseudotumoral form is rare and it can stimulate a tumor lesion. The second particularity of this case report is the unusual and atypical histological appearance. According to the literature review, only few publications that describe the causal relationship between tuberculosis and pseudo-ischemic necrosis.

What we draw from this observation is that, regardless of the

radiographic image and the atypical results of the histological examination, always think of tuberculosis especially in an endemic area.

#1965 - Medical Image

FOURNIER'S GANGRENE - THE RADIOLOGIC EXUBERANCE OF A RAPIDLY PROGRESSIVE NECROTIZING FASCIITIS

Rita Cebolais¹, Carolina Coelho¹, Angela Ghiletschi¹, Rita Lencastre Monteiro¹, Joana Diogo¹, César Vieira¹, Cátia Carvalho¹, Mariana Medeiros², Rita Camelo², Ana Gonçalves¹, Conceição Loureiro¹

¹ Centro Hospitalar e Universitário de Lisboa Central, Hospital de Santo António dos Capuchos, Lisboa, Portugal

² Centro Hospitalar e Universitário de Lisboa Central, Hospital de São José, Lisboa, Portugal

Clinical summary

The Fournier's gangrene is a necrotizing fasciitis that results from a rapidly progressive polymicrobial infection of the perineum. In this case, the patient was admitted with cystitis and an increased scrotal volume. After 5 antibiotic treatment days, he presented with fever and exuberant purulent scrotal drainage. CT-Scan showed a massive hernia in the left scrotal sac containing the descending and sigmoid colonic segments and also an exuberant, multiloculated collection of the perineal region (involving the anal canal, prostatic gland and anterior abdominal wall). The findings suggested Fournier's gangrene. The authors want to show the radiological exuberance of the lesions and emphasize the importance of a rapid diagnosis due to its fatal outcome.

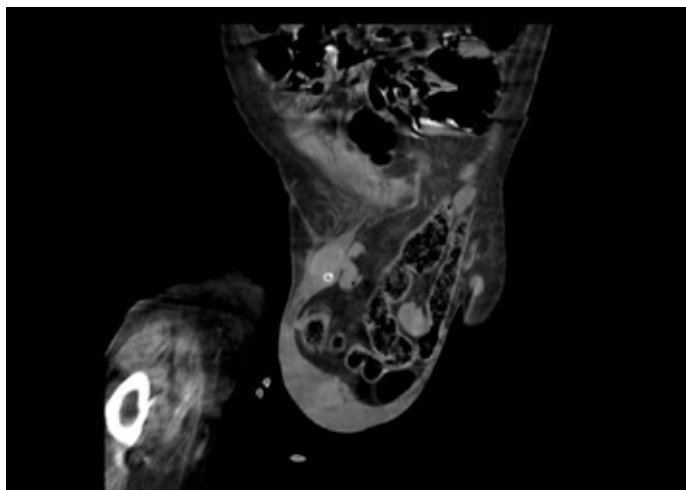


Figure #1965. CT-Scan - Hernia in the left scrotal sac containing the descending and sigmoid colonic segments. Exuberant, multiloculated collection of the perineal region (involving the anal canal, prostatic gland and anterior abdominal wall).

#1988 - Case Report

XANTOGRANULOMATOUS PYELONEPHRITIS - A RARE AND DEADLY FORM OF A COMMON DISEASE

Pedro Madeira Marques¹, Rita Tourais Martins¹, Eduardo Doutel Haghighi¹, José Augusto Barata²

¹ Hospital de Vila Franca de Xira, Povos, Vila Franca de Xira, Portugal

² Hospital de Vila Franca de Xira, Povos, Vila Franca De Xira, Portugal

Introduction

Xantogranulomatous pyelonephritis is a rare form of chronic pyelonephritis with particular clinical, radiological and histological characteristics. We present a typical case of this disease.

Case description

A 67-years-old female patient, with past history of dementia, cerebrovascular disease and type 2 diabetes mellitus, was brought to the Emergency Department with 1 day onset history of nausea, vomiting and asthenia. She was normotensive, with tachycardia, apyretic and the remaining physical examination showed no other abnormalities. Analytically she had hyperlactacidemia, anemia, leucocytosis with neutrophilia, elevated C Reactive Protein, hyperglycemia and acute renal lesion. Urinalysis showed leucocyturia and urine microbiology isolated multiresistant *Escherichia coli*. Directed antibiotherapy with amoxicillin 1 g 8/8h was initiated. In order to exclude complicated urinary tract infection and because after a few days the patient presented with new onset abdominal pain, renal and abdominal echography, and then CT-scan, were requested. They showed several large confluent abscesses, with likely starting point in the right kidney, occupying the entirety of the hepatorenal space and extending to the pelvic and peripancreatic region. Multiple staghorn calculi were observed in the right kidney, with associated obstructive uropathy and atrophy. Percutaneous drainage was performed (isolating multiresistant *Proteus mirabilis*), but the patient eventually needed surgical drainage and nephrectomy. Histological examination showed signs of chronic pyelonephritis and xantogranuloma. Therefore, the diagnosis of xantogranulomatous pyelonephritis was made.

Discussion

Xantogranulomatous pyelonephritis encompasses 1% of all chronic pyelonephritis. It is characterized by the presence of xantogranuloma and is accompanied by the invasion of other organs, such as the liver, lung and intestinal tract organs. Contrary to acute pyelonephritis, its clinical course is often mild and insidious, which makes the diagnosis difficult. It is associated with staghorn calculi and *Escherichia coli* or *Proteus mirabilis* are often isolated. Radiologically it mimics renal cell carcinoma. Because of the high mortality with antibiotic therapy alone, surgical treatment with nephrectomy is required. The patient's past history made clinical symptoms difficult to access, and that may have delayed the diagnosis. This case highlights the need not to disregard mild symptoms, as they may hide a serious disease underneath.

#1989 - Case Report

PULMONARY TUBERCULOSIS WITH MENINGEAL INVOLVEMENT - THE PARTICULARITIES OF A FREQUENT DIAGNOSIS

Rosa Margarida Cardoso, Jorge Rodrigues, Margarida Monteiro, Manuela Vasconcelos

Hospital de Braga, Braga, Portugal

Introduction

Central nervous system (CNS) tuberculosis (TB) include tuberculous meningitis and it's encountered frequently in regions of the world where the incidence of TB is high. Tuberculous meningitis accounts for about 1 percent of all cases of TB and 5 percent of all extrapulmonary disease in immunocompetent individuals.

Case description

41-year-old man with active addiction to alcohol and smoke; past drug-user. Presented at the emergency department with a 3-week evolution of asthenia, anorexia and a productive cough. He had had a recent contact with a patient with pulmonary tuberculosis. He was agitated, with marked cachexia and an incoherent speech. In the pulmonary auscultation he had scattered rales and he presented without focal neurological deficits. A CT-scan was performed and reveal multiple bilateral cavitations in the lung. The blood samples reveal high inflammatory parameters marks and a mild rhabdomyolysis. The bacilloscopy was positive and the human immunodeficiency virus (HIV) I/II was negative. The cerebrospinal fluid (CSF) sample showed increased ADA; pleocytosis, proteinorraquia and glucose consumption. The CSF cultural sample was inconclusive, and the PCR for mycobacterium was negative. He started anti-tuberculous drugs plus dexamethasone in high dose with significant clinical improvement in 48-72h. The lumbar puncture was repeated with similar biochemical and cytological evaluation, and an inconclusive result in Mycobacterium PCR. He was weaned from steroid therapy and discharged at the end of 21 days, referred for follow-up at the Center for Pneumological Diagnosis.

Discussion

Tuberculous meningitis may develop as a complication of primary infection in adults with immune deficiency caused by alcoholism, malnutrition, HIV infection or drugs. The diagnosis can be difficult and consist of CSF examination (elevated protein, lowered glucose concentrations, mononuclear pleocytosis). Cerebrospinal fluid specimens should be submitted for nucleic acid amplification testing whenever possible. Antituberculous therapy should be initiated on the basis of strong clinical suspicion and should not be delayed until bacteriologic proof has been obtained. The clinical outcome depends on the stage at which therapy is initiated. In general, glucocorticoid therapy is warranted for HIV-uninfected patients with convincing epidemiologic or clinical evidence for tuberculous meningitis.

#1991 - Abstract

URINALYSIS SENSIBILITY IN THE DIAGNOSIS OF URINARY TRACT INFECTIONS – A RETROSPECTIVE STUDY IN AN EMERGENCY DEPARTMENT

Luís Landeiro, Teresa Gantes Padrão, Nuno Maia Neves, Susana Carvalho Coelho, Pedro Morais Sarmiento, Alexandra Bayão Horta, João Sá

Hospital da Luz Lisboa, Lisboa, Portugal

Background

Urinary tract infection (UTI) complaints are one of the main reasons for seeking medical care and, therefore, antibiotic prescription. In order to diagnose UTI, supported by the clinical history and physical exam, urinalysis is a complementary test available that is easily accessible and helpful, before the isolation of a specific microorganism in urine culture.

We analyzed the sensitivity of urinary leucocytes, leukocyte esterase and nitrites to diagnose UTI in patients who came to the emergency department (ED) with UTI symptoms and subsequent microbiological isolation in urine culture. Throughout the years, there have been published articles with contradictory reports regarding these results.

Methods

We conducted a patient-level, retrospective, cohort analysis of all patients with a confirmed UTI that initially presented at our hospital ED, from January to March 2018. We excluded patients with asymptomatic bacteriuria (asymptomatic patients with microbiological isolation in urine culture), as well as those who did not get urinalysis, regardless if a urine testing strip was, or not, performed.

Results

Of the 601 patients with microbiological isolation in urine culture, 583 (97%) were confirmed UTIs. The remaining 18 were asymptomatic bacteriuria, which were excluded. Within the group with confirmed UTIs, it was carried out a urinalysis in 504 (86.5%), of which 459 (91.1%) were positive for urinary leukocytes, 483 (95.8%) for urinary leukocyte esterase and only 163 (32.3%) for urinary nitrites.

Within the 163 cases of UTI with positive nitrites in the urinalysis, 133 of them (81.6%) had urine culture positive for *Escherichia coli*. The most frequent microorganisms from the remaining cases were *Klebsiella pneumoniae* [n=16 (9.8%)] and *Morganella morganii* [n=4 (2.5%)]. Within the group of nitrite producing *Enterobacteriaceae* (n=523), the test was positive in only 158 of them (30.2%).

Conclusion

This study of community-related UTIs shows that urine leucocytes and leukocyte esterase have very high sensitivity (>90%), helping on excluding a UTI diagnosis and urinary nitrites does not (approximately 30%). The sensitivity of urinary nitrites in the population analyzed is much lower than the one determined in several other published articles. We consider that other studies are needed to evaluate the specificity of nitrites, in order to confirm it as a valuable tool on the confirmation of a UTI.

#2036 - Medical Image

AN EXUBERANT FORM OF DISSEMINATED HERPES ZOSTER INFECTION IN AN IMMUNOCOMPETENT ADULT

Madalena Sousa Silva, António Carneiro, Isa Silva, Filipa Taborda, Luís Pereira, Ana Paula Antunes, Ana Gorgulho, Margarida Afonso, Sofia Rodrigues, Ana Boquinhas
Hospital de Cascais, Cascais, Portugal

Clinical summary

Herpes zoster infection is frequent in the general population and usually has a benign course. The disseminated form of infection manifests with generalized skin eruption and is associated with severe complications greater mortality.

We present the image of an 89 years old woman who was brought to the emergency department with generalized rash, altered mental status, nausea and vomit. A week before she had been diagnosed with localized herpes zoster.

On hospital admission the remarkable feature on examination was disseminated dermatosis, with plain vesicles on head, face, arms and bullae on torso and abdomen. Acyclovir was initiated and the lesions progressed to disseminated crusted vesicles with some areas with pustule.

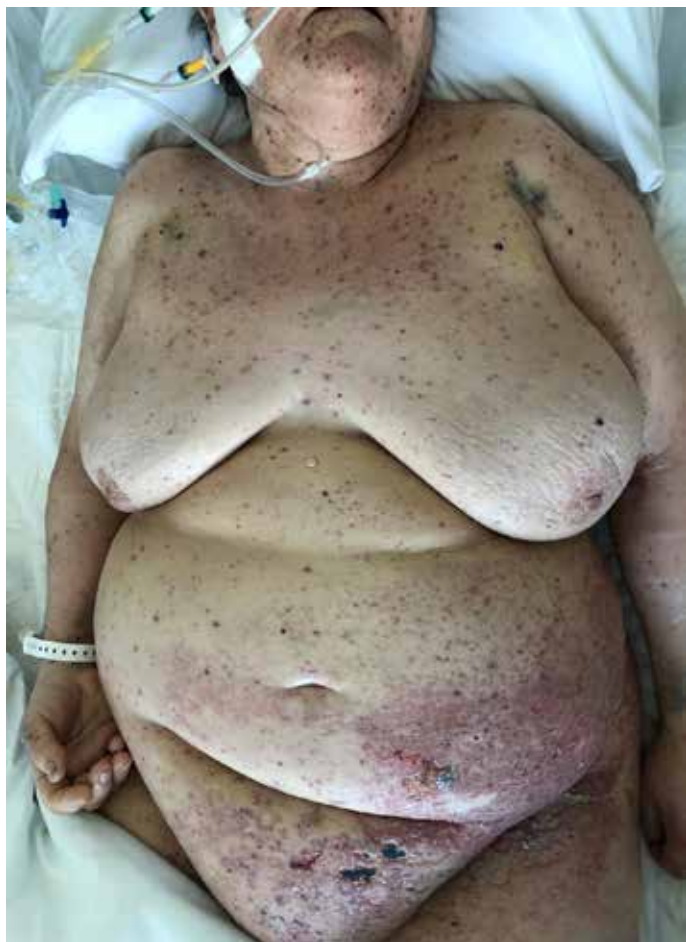

Figure #2036. Disseminated herpes zoster infection.

#2038 - Case Report

SPONDYLODISCITIS: A CHALLENGING DIAGNOSIS IN A TYPICAL CASE OF ENDOCARDITIS

Fábio Rêgo Salgueiro, David Mejias Donaire, Benilde T Barbosa, Armando Carvalho
Centro Hospitalar e Universitário de Coimbra, Coimbra, Portugal

Introduction

Spondylodiscitis (SD) corresponds to an infectious process that strikes the intervertebral disc and contiguous vertebral bodies. Its prevalence is low in adults, but morbidity and mortality are high mainly because of the diagnostic difficulty. The low incidence, insidious course and the high prevalence of low back pain in the general population make an early diagnosis difficult, thus requiring a greater degree of suspicion. The authors describe a clinical case of spondylodiscitis, where the etiological investigation proved to be a challenge. The combination of clinical and imaging data contributed to the correct empirical therapeutic, with a favorable clinical evolution.

Case description

A 76-year-old female patient, partially autonomous for daily living activities (previous Katz index 4/6), with a history of valvular heart disease, pacemaker carrier, obstructive respiratory disease under study, arterial hypertension, kidney chronic disease associated with diabetes mellitus type 2 and fibromyalgia, was admitted to the emergency department for dyspnea, orthopnea and peripheral edema with about one week of evolution.

Analytically, it showed an increase in inflammatory patterns and a chest radiograph compatible with an active inflammatory process, empirically initiating levofloxacin and vancomycin after isolation of multiresistant staphylococcus aureus (MRSA) in blood culture. During her stay the patient showed worsening of her respiratory function and frequent febrile peaks, even under optimized therapy, aggravated by chronically low back pain. A second positive blood culture (MRSA), systolic murmurs, persistence of fever and detection of positive rheumatoid factor raised the hypothesis diagnostic of endocarditis. Patient underwent transthoracic and transesophageal echocardiography, both without evidence of vegetations. Due to the persistence of painful complaints, the patient underwent computed tomography, observing destructive bone lesions in relation to the vertebral bodies D8-D9, assuming SD by MRSA. It was observed by neurosurgery, but without surgical indication, being discharged to comply with rifampicin and linezolid therapy.

Discussion

We report the case of a typical patient with clinic and analytical suggestions of endocarditis, but due to her previous comorbidities camouflaged a spondylodiscite. It has emphasized the relevance of exhaustive physical examination and clinical complains in elderly patients, mainly with chronic pain.

#2043 - Case Report

ORCHITIS DUE TO Q FEVER IN A YOUNG VETERINARIAN

João Eduardo Costa Ferreira Pina Cabral, José Pedro Leite, Diana Gonçalves, Joana Coelho, Pedro Ribeiro
CHUC, Coimbra, Portugal

Introduction

Q fever is a zoonotic infection caused by *Coxiella burnetii* and the clinical presentation can vary between practically asymptomatic to severely ill. The most common presentations are a flu-like syndrome, pneumonia or hepatitis. We report a case of a 34-year-old veterinarian with testicular enlargement which turned out to be caused by Q fever.

Case description

A 34-year-old male came to the emergency department due to weakness, diarrhea and food intolerance. The patient was admitted for correction and monitoring of severely altered liver enzymes and study of etiology.

Relevant medical history includes peptic ulcer secondary to NSAID administration and hepatitis for which he was being studied by the gastroenterology department.

From the initial analysis performed, high ferritin levels (>4000) motivated a HFE gene study which revealed double heterozygote which predisposes to iron overload. No other culprit for the presenting symptoms or altered exams, was found, and the patient was discharged after 5 days with improved bloodwork, and a consultation was scheduled to review pending exams. Meanwhile, *Coxiella burnetii* phase II antibodies came back positive. In the follow-up consultation, the patient had developed unilateral testicular pain and enlargement compatible with orchitis, which he admitted at that point, had actually started developing while still in the hospital, but he had chosen to omit this fact. Doxycycline was prescribed and a new evaluation was scheduled for the next month.

Discussion

Q fever usually presents as a flu-like syndrome with hepatitis or pneumonia. Additional manifestations are varied and includes endocarditis, pericarditis, meningitis, encephalitis or a maculopapular rash. Orchitis is a rare, documented manifestation of Q fever. Eldin et al. say no chronic infection can exist without a focus of infection, suggesting active search and management of said focus. After primary infection is treated, duration of treatment and follow-up should be determined according to risk factors due to the risk of developing persistent infection. This case highlights the extreme importance of a thorough physical examination of the patient. Only endocarditis and vascular infections have cohort studies to help guide clinicians in treatment and follow-up. Other sites of persistent infection should be managed case-by-case, proving to be therapeutic challenges.

#2046 - Case Report

SPINAL PAIN IN AN HEALTHY YOUNG MAN

Carolina Cadório, Alexandra Pousinha, João Barreira, José Barata
Hospital de Vila Franca de Xira, Vila Franca De Xira, Portugal

Introduction

The spondylodiscitis is a spine osteomyelitis. Its incidence has been rising, probably do to the increasing susceptible population as elderly, and the improve of the imaging tests. Yet, this infectious disease is rare, with greater incidence in ages above 50 years old, more prevalent in male gender. Its clinical presentation is unspecific and constitutes a challenge for an early diagnosis and treatment.

The authors expose a clinical case of a 30 years old Caucasian man, immunocompetent, witch initial presentation was thoracic back pain and constipation.

Case description

The atypical presentation began with an intense thoracic back pain that lead the patient to the urgency room. It was excluded cardiac pathology as well as respiratory through radiography and electrocardiogram. The case progressed for constipation and then paraparesis, hypoesthesia of the lower members, urinary retention and erectile dysfunction. He had history of opium addiction, currently not active, and 6 days ago he had suffer a digital traumatic lesion in the right foot and was treated with oral flucloxacillin. To clarify the neurological symptoms he did a magnetic resonance imaging of the dorsal spine revealed an extradural abcess that extended from D4 to D8. The patient underwent decompressive spinal surgery – laminectomy D5-D7 and drainage of the epidural abcess drainage, where was isolated an multissensitive *Staphylococcus aureus*. The patient was treated with intravenous antibiotic according to the antibiotic sensitivity test for 39 days, with imaging control and then oral antibiotic, with neurological improvement. The tests for B and C hepatitis virus, human immunodeficiency virus and syphilis were negative.

Discussion

With this case report the authors want to show that even in an young patient with an healthy immune system with no risk factors (except non-active opium abuse), and unspecific symptoms lead to a late diagnosis and treatment. It's really important a good clinical story as well as an high level of suspicion and a good differential diagnostic to get a correct and early diagnosis.

#2047 - Medical Image

CHRONIC FUNGAL SINUSITIS IN AN IMMUNOCOMPROMISED PATIENT

Cátia Fava Gaspar, Helena Greenfield, Liliana Carneiro
Hospital Pedro Hispano, Matosinhos, Portugal

Clinical summary

The authors present a case of a 76-year-old man, diabetic, with a persistent asymptomatic inflammatory syndrome with anaemia,

elevation of erythrocyte sedimentation rate and generalized lymphopenia with a CD4 count of 134 cel/mcL. Extensive etiologic study was performed and paranasal sinus tomography showed bilateral maxillary, ethmoidal air cells disease with extension to the left sphenoid and frontal sinus with diffuse intra-sinusal calcifications, suggestive of a chronic process. A MRI confirmed the findings suggesting chronic fungal sinusitis as the most certain diagnostic. Endoscopic sinus surgery was not performed after consultation of both neurosurgery and otorrhinolaryngology teams due to high haemorrhagic risk since he was under antiaggregation because of valvular cardiac disease.

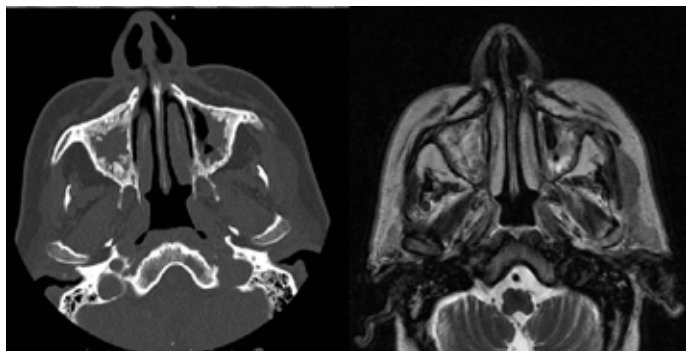


Figure #2047. Paranasal sinus tomography and MRI, suggesting chronic fungal sinusitis.

#2058 - Case Report

LEPTOSPIROSIS – A FARMER’S THREAT

Ana Valada Marques, Miguel Falcão, Sérgio Campos, Tânia Gaspar, Isabel Maldonado, Rosa Amorim

Centro Hospitalar do Oeste, Caldas da Rainha, Caldas Da Rainha, Portugal

Introduction

Leptospirosis is a prevalent zoonotic disease caused by a pathogenic spirochetes of the genus *Leptospira*. Disease in humans is often sporadic, although outbreaks may occur from common source exposures and with higher incidence in the tropics. Various mammals are natural hosts and humans are infected incidentally after animal or environmental exposure.

Case description

A 58 years old male, with past history of dyslipidemia, was admitted at the hospital with pollakiuria, arthralgias, chills and high fever that didn't respond to antipyretics, for three days. He was discharged with symptomatic treatment for a suspected flu. Three days after, he returned to the hospital with the same symptoms. Blood tests revealed thrombocytopenia (nadir 48000/uL platelets), liver cytolysis (AST 205 U/L, ALT 142 U/L), rhabdomyolysis (CK 1279U/L), LDH 300 U/L, hemoglobin 13.5 g/dl, leucocytes 6500/uL with 83% neutrophils, PCR 9.6 mg/dl, without hyperbilirubinemia (Bilirubin (brb) total 0.7, direct brb 0.3, indirect brb 0.4) or kidney dysfunction (urea 53 mg/dl, creatinine 0.91mg/dl). Normal chest x-ray and electrocardiogram. Blood and urine samples were taken for microbiological tests

which were negative. Because it couldn't rule out of Influenza A flu, oseltamivir was started and suspended 2 days later when PCR for Influenzae A in nasal and oropharyngeal swab revealed to be negative. Epidemiologically it was found that the patient was a farmer and worked in a warehouse. He described that sometimes there were mice droppings and urine in vegetable boxes at the warehouse. Given suspected zoonosis, doxycyclin was started. Also, infectious serology tests, including HIV 1 and 2, HBV, HCV, EBV were negative. Brucellosis, rickettsiosis and coxiella were discarded. The patient improved well, with sustained apirexia, resolution of thrombocytopenia and rhabdomyolysis. Antibodies for leptospirosis revealed positive.

Discussion

Leptospirosis usually is a mild to moderate illness. It may manifest as a subclinical illness, self-limited systemic infection or severe and potentially fatal illness with multiorgan failure. An accurate evaluation of the patient searching for typical signs and symptoms allied to epidemiological data is key to an exact diagnose of leptospirosis.

#2067 - Case Report

TUBERCULOUS MENINGITIS IN HIV-NEGATIVE PATIENT WITH ALCOHOLIC CIRRHOSIS

Rita Carneiro Silva, Anusca Paixão, Joana Cunha, Paula Vaz Marques

CHTMAD, Vila Real, Portugal

Introduction

Tuberculous meningitis is the most severe form of tuberculosis, with high mortality and morbidity. Being a less frequent cause of meningitis in low tuberculosis prevalence countries, it usually presents in HIV-positive patients or in patients on immunosuppressive drugs.

Case description

A 56-year-old woman with hypertension, diabetes, alcoholism and alcoholic cirrhosis, presented to the emergency department with severe lumbar pain with abdominal irradiation. The physical examination was unremarkable, without fever or neurological signs. Her laboratory result showed severe thrombocytopenia, hyponatremia, mild altered liver enzymes, bilirubin and RNI, elevated C-reactive protein and normal urine test strip. The spine and abdomen CT revealed discopathy and posterior arthritis; enlarged liver with lobulated surface, and nonspecific lateroaortic adenopathies. She was hospitalized and started ceftriaxone empirically. A brain CT was performed on the first day, due to psychomotor agitation, but only revealed previous cerebellar infarcts. She started treatment for alcoholic withdrawal syndrome but the clinical situation evolved with lethargy and neck stiffness, and a lumbar puncture was performed. Cerebrospinal fluid (CSF) analysis revealed an elevated white blood cell count with relative neutrophil predominance, a slightly reduced

glucose level and elevated total protein level. Gram stain was negative. Polymerase chain reaction (PCR) was negative for most frequent causes of meningitis but positive for *Mycobacterium tuberculosis* complex, diagnosing tuberculous meningitis. The HIV test was negative. An anti-bacillary scheme adapted to hepatic dysfunction and dexamethasone were introduced. Lung CT was normal and there was no evidence of other extrapulmonary manifestations. She kept an unfavorable clinical course, with coma, respiratory alkalosis and hyperlactacidemia, and died on the 8th day of hospitalization. The mycobacteriological culture of the CSF was later known to be negative.

Discussion

This case emphasizes the need for considering tuberculosis as a possible meningitis agent, even in HIV-negative patients and without immunosuppressive drugs, but with other factors risk, such as alcoholism. PCR analysis might be determinant in diagnosis and early treatment, especially in cases that CSF studies are not typical. Late diagnosis leads to high mortality, and previous liver dysfunction implies additional challenge in choosing the best course of treatment.

#2072 - Abstract

INCIDENCE OF ANTIBIOTIC TREATMENT FAILURE IN PATIENTS WITH NURSING HOME-ACQUIRED PNEUMONIA AND COMMUNITY ACQUIRED PNEUMONIA

Mariana Lopes, Gonçalo Alves Silva, Rui Nogueira, João Rocha Gonçalves, Daniela Marado, Dilva Silva, Carlos Athayde, Ana Figueiredo, Jorge Fortuna, Armando Carvalho
Coimbra Hospital and University Centre, Coimbra, Portugal

Background

Patients with health-care associated pneumonia, which includes nursing-home acquired pneumonia (NHAP), are considered to be at higher risk of infection with multi-drug resistant organisms (MDRO) than those with community acquired pneumonia (CAP). However, recent evidence suggests the presence of a single risk factor for MDRO does not accurately predict the need for broad-spectrum antibiotics as the prevalence of MDRO in patients with NHAP is low. The goal of this study was to investigate if there was a difference in the rate of failure of empiric antibiotics between patients with NHAP and CAP.

Methods

All pneumonia admissions to an Internal Medicine Service between April 2017 and April 2018 were included, except patients with HAP. Baseline demographic characteristics, comorbidities, clinical and laboratory markers of pneumonia severity, chosen course of empiric antibiotics and the need to change antibiotic therapy, mortality and readmission outcomes were collected retrospectively and compared between patients from nursing homes and those from the community.

Results

Of the 556 patients included in this study, 243 (43.7%) had NHAP and 313 (56.3%) had CAP. Patients with NHAP were older (Mdn 87.0 years, IQR 83-91 vs 84.0 years, IQR 77-88.5 $p < 0.001$) and more likely to be dependent for activities of daily living (Katz score 0: 67.1% vs 31.0%, $p < 0.001$). They had higher use of antibiotics in the previous 6 months (OR 1.498, 95% CI 1.040-2.158, $p < 0.03$). Patients with NHAP were more likely to experience therapeutic failure (OR 1.583; 95% CI 1.102-2.276; $p = 0.013$). However, when controlled for other factors (age, Katz scale, antibiotic use in the last 6 months), the patient's origin did not predict treatment failure (OR 1.083; 95% CI 0.726-1.616; $p = 0.696$). When considering only patients treated empirically with narrow spectrum antibiotics ($n = 361$, 64.9%), the presence of NHAP remained non-predictive of treatment failure when controlled for age and Katz scale (OR 1,107; 95% CI 0,661-1,854, $p = 0.698$).

Conclusion

The higher rates of antibiotic failure in patients with NHAP were explained by the presence of other risk factors such as comorbidities and older age. NHAP does not require broader-spectrum antibiotics. A combination of clinical and epidemiological factors should be considered when estimating the risk of MDRO.

#2088 - Abstract

SEPSIS-RELATED ANEMIA: DOES IT REALLY HAVE IMPACT IN INTERNAL MEDICINE PATIENTS?

José Pedro Cidade, Inês Fernandes Santos, João Furtado, Francisco Silva
Hospital Egas Moniz, Lisbon, Portugal

Background

Anemia is a common pathological feature in sepsis' patients codifying a multisystemic impact and deteriorating previous clinical conditions. The reduction of serum iron levels, erythropoietin production and increase of intravascular space are some of the appointed mechanisms to the sepsis-related anemia, in ICU patients, during the acute phase of sepsis.

Our study aims to document sepsis-related anemia in internal medicine ward patients and evaluate its correlation to systemic inflammatory magnitude and renal failure.

Methods

In this retrospective study, patients who were admitted to Internal Medicine ward with sepsis diagnosis (using international criteria for sepsis), during a one-year period, were eligible to the study. Further selection excluded patients with hemorrhagic losses, known haematological chronic diseases, transfusion support or iron supplementation in the last 6 months and death during ward stay. Laboratory data from blood samples taken at admission and discharge, were used to test for significant differences.

Results

A statistical significant difference was obtained between the haemoglobin level at admission and discharge dates ($12,46 \pm 1,56$ versus $11,48 \pm 1,50$, respectively, $p < 0.001$). Furthermore, significant difference was obtained between acute protein c seric levels ($10,31 \pm 10,98$ versus $3,04 \pm 2,98$, respectively, $p < 0.0001$) and creatinine levels ($1,25 \pm 0,67$ versus $0,97 \pm 0,44$, respectively, $p < 0.001$) from the same blood samples. However, a Pearson's correlation coefficients between the reductions of haemoglobin concentration and acute protein c or between the reductions of haemoglobin concentration and creatinine were not statistical relevant.

Conclusion

Existence of sepsis-related anemia in Internal Medicine wards was demonstrated, which can further codify deterioration of previous clinical problems and a worse clinical outcome. In spite of an accompanying significant reduction of acute protein c and creatinine seric levels, these markers, that may signal and preclude more serious cases of sepsis, were not good correlators to pinpoint patients with more severe haemoglobin reductions in sepsis-related anemia.

#2094 - Case Report

LISTERIA MONOCYTOGENES AORTIC ABSCESS: A RARE FORM OF INVASIVE LISTERIOSIS

Octavio Arce García¹, Miguel Martínez Lacalzada¹, Jorge Alba Fernández², Lidia Gagliardi Alarcón³, Pablo Borque Sanz¹, Luis Fernando Abrego Vaca¹, Carmen Quereda Rodríguez-Navarro¹

¹ Hospital Universitario Ramón y Cajal, Madrid, Spain

² Clínica Universidad de Navarra, Pamplona, Spain

³ Hospital Universitario Infanta Elena, Valdemoro, Spain

Introduction

Listeria monocytogenes is a facultative anaerobic, non-spore-forming gram-positive, motile rod-shaped bacterium that causes listeriosis. It can be found in soil, water, the gastrointestinal tract of different mammals and is the food-borne pathogen associated with the highest case-fatality rate in the western hemisphere. The spectrum of infection may range from mildly symptomatic gastroenteritis to invasive infection, i.e. chorioamnionitis, bacteremia or CNS involvement (neuroinfection). Localized forms such as osteomyelitis or endocarditis are rare.

Case description

An immunocompetent 76-years-old male with a history of an aortic valve replacement and a Bentall procedure in 2012, presented to the Emergency Department with a 5 day history of pleuritic chest pain, dyspnea, malaise and fever (38°C). Physical examination revealed was unremarkable and a rise in CRP levels and leukocyte count was observed on laboratory tests. Chest X ray revealed mild right pleural effusion and a probable infiltrate

of the right inferior lobe. Blood cultures were obtained and the patient was discharged with a diagnosis of lower respiratory tract infection and was prescribed Levofloxacin. 48 hours later *Listeria monocytogenes* grew on 1/2 blood cultures. The patient was admitted and antibiotic treatment switched to ampicillin plus cotrimoxazole iv. An echocardiogram and thoracic CT-scan were performed, which revealed an aortic abscess surrounding the prosthetic tube. Emergency surgery (prosthetic valve and tube replacement) was performed. The patient gradually improved and was discharged after 6 weeks of antibiotic treatment.

Discussion

Localized forms of invasive listeriosis are rare and associated with different comorbidities (malignancy, alcohol abuse, immunosuppression; etc.). *Listeria monocytogenes* endovascular infections are mainly described in patients with heart conditions or prosthetic devices. Only a hundred cases have been reported worldwide with a mortality of 12-16%. While ampicillin, alone or combined with aminoglycosides has been the most commonly used treatment, the optimal treatment has not been established. The management of localized forms of invasive listeriosis is complex and requires high level of expertise. There is a lack of randomized clinical trials to identify the optimal treatment choices. Here we report a case with favorable outcome with combined (surgical and medical treatment). Further research is needed.

#2096 - Abstract

DIAGNOSTIC CHALLENGES IN AN ACUTE DIARRHEA REHYDRATION CENTER DURING A CHOLERA OUTBREAK POST CYCLONE IDAI IN MOZAMBIQUE

Inês Felizardo Lopes, Ana Paula Cruz, Lurdes Baptista, Nuno Jordão, Laurinda Sumares, Isabel Fernandes, Alexandre Nobre, Fernando Nobre

AMI – Assistência Médica Internacional (International Medical Assistance NGO), Lisbon, Portugal

Background

Natural disasters are known to be possible triggers for diarrheal disease outbreaks, including cholera. However, other types of diarrhea may also increase. After Cyclone Idai left its mark of destruction in the Beira district of Mozambique, an emergency response to the cholera outbreak with different levels of medical care was organized. In our acute diarrhea rehydration center, we triaged patients for the type of diarrhea and level of dehydration to recognize possible cases of cholera, establish the severity of dehydration, define a treatment approach and determine the need for referral to a cholera treatment center or central hospital.

Methods

We performed a prospective observational study based on the clinical files of patients observed in our center for acute diarrhea

during the period from 30 March to the 1 May 2019, in a primary care center in the District of Beira.

Results

We collected data of 1608 patients observed in our center. 1363 were above 2 years old (group 1) and 245 were 2 years or under (group 2).

In group 1, 624 were male and 738 female, with an average age of 23. Of the observed patients, 682 had acute, watery diarrhea that could be compatible with cholera, of those 35% had concomitant vomiting increasing the suspicion of cholera. Most of the cases were treated with plan A or plan B and discharged with oral rehydration salt (ORS) solution. However, 11.3% had severe dehydration requiring IV fluid stabilization, and 27.3% of those severe cases were referred to a cholera reference center. There was 1 death on arrival, a 14-year-old male.

In group 2, 115 were female and 130 males. Despite cholera being an infrequent diagnosis in children under the age of 2 years, 25 had watery diarrhea and 12 had associated vomiting. 4% required IV fluids and 3.3% were referred.

Concerning other types of diarrhea in the two groups, 172 patients (10.7%) had bloody diarrhea, 585 (36.4%) patients had other types of diarrhea and differential diagnosis can be wide. 27 patients had malaria with diarrhea as a symptom.

Conclusion

During a Cholera outbreak the primary goals are to treat and prevent disease transmission. It requires immediate emergency response which must identify suspicious cases of cholera, provide appropriate treatment and patient education, but also to signal suspicious cases to the community-based interventions. However, other types of diarrhea also appear in the triage and sometimes the clinical differential diagnosis can truly be a challenge.

#2102 - Case Report

CHRONICLE OF A KNOWN DISEASE- A CASE OF UNSUSPECTED TUBERCULOSIS

Mariana Simoes, Ana Margarida Monteiro, Viorela Cristea, Maria Sousa Uva, Luiz Menezes Falcão

Hospital Center, Lisbon, Portugal

Introduction

The diagnosis of tuberculosis (TB) and the decision to initiate treatment depend on the integration of epidemiological, clinical, laboratorial and imaging data.

Case description

A 26-year-old woman was referred to an Internal Medicine Consultation (ICM) for recurrent pneumonia in the last 4 months. She had low-grade fever, night sweats, asthenia, weight loss, chronic cough and hemoptoic expectoration, insidious dyspnea and pleuritic chest pain. We found exposure to poultry cages in the domestic environment for 2 years, close contact with a positive bacilliferous

patient 3 years ago and family history of lymphoma and lung neoplasia. She denied TB in the past, other diseases, immunosuppressive therapy, risk behaviors, contact with high risk groups of TB, recent trips/cruises/hotel stays or contact with farm animals. She had been observed 4 times in the ER of 2 hospitals and once in ICM, having been discharged from the latter with the diagnosis of pneumonia by *Chlamydia pneumoniae*. She was treated with 4 antibiotics cycles and did 6 pulmonary X-rays which showed a "towel like" opacity in the right lower lobe. On the clinical examination, it was highlighted: tattooed skin; decreased vesicular murmur on the right lung base, with late inspiratory and expiratory crackles in this location and scattered wheezing; single adenomegaly, with left cervical localization, with 1 cm diameter of hard-elastic consistency, movable in relation to the deep planes, painless on palpation, without inflammatory signs. Given the clinical and epidemiological context and the positivity of direct mycobacteriological examination in sputum samples, bronchial secretions and bronchoalveolar lavage (BAL), the presumptive diagnosis of pulmonary tuberculosis was made and we initiated treatment with anti-bacillar, with subsequent diagnostic confirmation by positive cultures for *Mycobacterium tuberculosis* (bronchial secretions, BAL and bronchial biopsy). Bronchofibroscopy showed alterations compatible with necrotizing bronchogenic TB and thorax CT scan showed an area of alveolar consolidation with aerial bronchogram in the right lower lobe and areas of cavitation inside, plurisegmental parenchymal infiltrates bilaterally, micronodules in the lung parenchyma, mediastinal adenomegalies and right pleural effusion.

Discussion

Reducing the delay of the diagnosis of TB and the number of bacilliferous patients is one of the main challenges in Portugal. We emphasize the pivotal role of the clinical history as a basis for diagnostic guidance.

#2107 - Case Report

WHEN THE ETIOLOGY OF A PURPURA IS NOT WHAT IT SEEMS TO BE...

Mariana Guerra, Daniela Marado, Jorge Fortuna

Centro Hospitalar Universitário de Coimbra, Coimbra, Portugal

Introduction

Fulminant purpura is a medical emergency, of high mortality, requiring rapid diagnosis and treatment. It is a rare syndrome, characterized by disseminated intravascular coagulation and endovascular thrombosis resulting in a characteristic cutaneous purpura. There are different types: neonatal, idiopathic and infectious, the latter being the most common form, caused in most cases by *Neisseria meningitidis*. Despite this, other agents are possible, notably gram-negative bacteria.

Case description

An 84-year-old man was admitted to the ER after falling from his own height, with prolonged sun exposure. He had had a

previous history of laryngeal neoplasia for 10 years, hypertension, dyslipidemia, hyperuricemia and cutaneous psoriasis. He had been on AAS, allopurinol, enalapril and lercanidipine for years without dose changes or recent introduction of new medications. One week prior, he was submitted to a cystoscopy for etiological investigation of bladder polyps. At examination, the patient was conscious, disoriented, febrile (T. 40°C), hypotensive and tachycardic, with maculopapular lesions, with citrus contents with detachment. A geographic and reticulated erythema, with purpuric base, was dispersed throughout the abdomen and the anterior face of the lower limbs. It was neither pruritic, nor painful. There were no lesions on the mucosa. Multiple lesions of psoriasis vulgaris were still widespread, mainly in the lower limbs. Before this, the immediate hypotheses of scalded skin syndrome or staphylococemia were considered. Therefore, aggressive and empirically vancomycin therapy was initiated after septic screening (serum, urine and fluid from the lesions). A cutaneous biopsy was performed and it was evident cutaneous necrosis of the entire epidermis thickness, under which the capillary vessels were congestive and thrombosed. The set was compatible with a vaso-occlusive syndrome of the small vessels, within the spectrum of fulminant purpura. Later, the results of septic screening were obtained, with isolation of *Morganella morganii* in blood cultures. The therapy instituted was changed to gentamicin, maintained for 14 days, with good response.

Discussion

Having the patient underwent a recent urinary intervention, the port of entry was identified and the secondary reaction appeared in a context of fulminant purpura. Although the mortality associated with this infection is high, adequate antibiotic therapy and supportive care allowed the appropriate treatment of this emergency.

#2109 - Case Report

REACTIVE ARTHRITIS ASSOCIATED WITH LYMPHOGRANULOMA VENEREUM

João Borges Rosa, José Abreu Fernandes, Nelson Pedro, Lèlita Santos, Armando Carvalho

Centro Hospitalar e Universitário de Coimbra, Coimbra, Portugal

Introduction

The identification of sexually transmitted diseases can be quite challenging, especially when this topic is not questioned and there are other plausible reasons for the symptoms. This case report intends to demonstrate and discuss these difficulties.

Case description

A 29-year-old male who underwent left varicocele embolization in the beginning of 2019 presented three weeks later to the post-operative follow-up with painful bilateral inguinal lymphadenopathy, days after a single painless penile ulcer which healed spontaneously. He reported no fever, dysuria,

urethral discharge, proctitis, ocular or cutaneous involvement. We started doxycycline 100mg bid empirically without changes. The patient returned to the hospital referring worsening of his symptomatology and bilateral knee arthritis for three weeks. The inguinal ultrasound revealed heterogeneous fluid collection bilaterally. He had had a history of recurrent oral ulcerations for several years with the suspicion of Behçet's disease and a previous diagnostic of hepatitis A and genital warts. When asked about his sexual history, the patient revealed having sex with other men without protection after the surgical procedure. After that, we found serological evidence of recent *Chlamydia trachomatis* infection. Other sexually transmitted diseases were negative. In this context, we assumed reactive arthritis associated with lymphogranuloma venereum. As the previous treatment with doxycycline was ineffective, we started azithromycin 1g orally once weekly for 3 weeks with improvement of the symptoms. Articular manifestations were resolved after corticotherapy.

Discussion

Lymphogranuloma Venereum is a sexually transmitted disease caused by *Chlamydia trachomatis* which in the last decade has been increasing namely in the group of men who have sex with men. Reactive arthritis is a well recognized complication of this urogenital infection. We reported a case of a man with the classical presentation of an uncommon infection but with several confounding factors, thus a complete medical history was fundamental to the right diagnosis.

#2112 - Abstract

EPIDEMIOLOGIC ANALYSIS OF A COHORT OF INTERNAL MEDICINE PATIENTS SUBMITTED TO BLADDER CATHETERIZATION: HOW MUCH SHOULD WE CONCERN?

Filipa Taborda¹, Maria João Lobão^{1,2}, Ana Lúcia Taborda¹, Ana Maria Grilo¹, Carolina Sepúlveda¹, Jorge Castro¹, Ana Gorgulho¹, Paulo Sousa²

¹ Hospital de Cascais, Cascais, Portugal

² NOVA National School of Public Health, Lisboa, Portugal

Background

Urinary tract infections (UTI) are recognized as one of the most frequent healthcare associated infections outside the Intensive Care Unit, the majority of which related to the use of bladder catheters. In order to develop a multimodal CAUTI prevention strategy adapted to our Portuguese internal medicine ward we intend to characterize a cohort of patients submitted to this procedure, determine the incidence of catheter associated urinary tract infection (CAUTI) and make an epidemiological analysis of this nosocomial infection.

Methods

We conducted a prospective cohort study and performed a descriptive analysis. Demographic, clinical, admission and bladder-

catheter related variables were considered. For CAUTI definition and quantification we used CDC criteria and metrics. Data related to infection (etiologic agent, antibiotic, duration of therapy and pattern of resistance) was also collected

Results

The study cohort (n=267) had a median age was 81 years (IQR: [74-87]) and a female:male ratio of 1:1.07 and a median age adjusted ICC of 4 (IQR: [3-5]). More than half of the patients had cardiocirculatory (n=73; 27,3%) or respiratory diseases (n=74; 27,7%) as the main diagnosis. CAUTI cumulative incidence was 6.4% (n = 17) and density incidence rate 5.7 per 1000 catheter-days. The Urinary catheter utilization ratio was 13,9%. Only 4,5% had inappropriately catheter placement. *Escherichia coli* (29.4%, n=5) and *Klebsiella pneumoniae* (23.6%, n=4) were the most frequent CAUTI agents found. Forty-one-point-two percent of all the cultural isolates had a multidrug resistance pattern, including extended spectrum beta-lactamase (ESBL) producing bacteria and extensively drug-resistant (XDR) *Pseudomonas*, imposing the utilization of broad-spectrum antibiotics. Third generation cephalosporins were the most common first antibiotic choice. Median urinary catheter days (7.5 vs 19 days) as well as length of stay (17.5 vs 26 days) and intra-hospital mortality (28.4% vs 41.2%) were superior in patients with CAUTI. Almost 30% of deaths were CAUTI related.

Conclusion

In this study we found a high rate of appropriate bladder catheter placement and a high CAUTI incidence. These findings suggest a problem of compliance to prevention bundles, reinforcing the importance of it in quality improvement initiative to be implemented in the future in this department. Of concern is also the high CAUTI mortality and multidrug resistant agents, highlighting the impact and relevance of these hospital-acquired infections.

#2132 - Abstract

BLOODSTREAM INFECTION IN HUMAN IMMUNODEFICIENCY VIRUS (HIV) PATIENTS

Andreia Margarida Margarida De Matos, Sara Brandão, Eduardo Serra, Eugénia Ferreira

Coimbra Hospital and University Center, Coimbra, Portugal

Background

Most HIV bloodstream infections series are among Asiatic and African people with *Mycobacteria* and disseminated fungal infection predominance. A minority of cases is European and bacterial infection is less frequent. The authors describe a case series of a tertiary Portuguese center.

Methods

Retrospective screening of HIV patients with positive blood cultures admitted to infectious diseases department of a tertiary center from 2009-2016.

Results

from a total of 1631 infectious diseases department admissions, 127 (7.8%) had positive blood cultures (91 patients): 77% men with mean age of 47±14 and women with mean age of 46±12. Nine percent were African. Comorbidities were registered: 55.7% tobacco, 40.5% alcohol, 38.8% intravenous drugs, 31% hepatitis B or C co-infection and 19% with functional impairment. About 22% had ≥1 malignant tumor: 44% lymphoma, 32% Kaposi sarcoma, and 26% non-AIDS defining cancer. Most patients had APACHE-II 10-20pts (mortality rate 15-25%) and 13.4% septic shock. New HIV diagnosis was made in 20 cases (22%), but a total of 36 (40%) had bloodstream infection in the first year. More than 80% were in CDC stage 3, with CD4 lymphocytes count <100 in 46.1% and <10 in 12.4%. HIV-RNA viral log was >5 in 38%. Tuberculosis, cryptococcosis and pneumocystosis were the most common AIDS defining disease. Bacterial infection occurred in 100 cases (78.7%): 18% *Staphylococcus aureus*, 13% *Escherichia coli*, and 12% *Klebsiella pneumoniae*. Respiratory infection was frequent (27%), followed by catheter (15%) and skin infection (11%) but 16% remains unclear. Nosocomial infections occurred in 38% and 32% of community-acquired setting (62%) had healthcare assistance, in the previous 90 days. *Enterococcus* and *Klebsiella* species were most frequent in health-care associated setting. Fungemia occurred in 20 cases (15.9%), 60% due to *Cryptococcus neoformans*. Only 7% had *Mycobacteria* bloodstream infection. Fifteen percent of patients had >1 hospital admission for bloodstream infection. Polymicrobial blood cultures occurred in <3% of patients. Thirty-day mortality rate was 13.5% and 1-year mortality rate was 42.5%.

Conclusion

most HIV bloodstream infections were due to bacteria. A significant proportion of infections were health-care associated and *Enterococcus* species and *Klebsiella pneumoniae* were the most frequent health-care associated bacteria. About 40% of patients had new HIV diagnosis for less than one year.

#2135 - Abstract

CHARACTERISTICS OF PYOGENIC SPONDYLODISCITIS:7-YEARS DATA

Sirine Miri, Maroua Slouma, Rim Dhahri, Leila Metoui, Najeh Boussetta, Nour El Houda Guediche, Sameh Sayhi, Rym Abid, Fayda Ajili, Riadh Battikh, Imene Gharsallah, Bassem Louzir
Military Hospital of Instruction of Tunisi · Internal Medicine, Tunisi, Tunisia

Background

Pyogenic spondylodiscitis is an uncommon but important infection, that can entail major morbidity and may be associated with serious long-term sequelae.

Methods

We retrospectively reviewed 17 cases of spondylodiscitis during a 7-year period (2012-2018).

Results

There were 11 men and 6 women. The mean age was 56. The mean duration of the diagnosis delay was 59 days. Patients reported inflammatory back pain (14 cases), fever (7) and loss of weight (4). Neurological deficit was present in one case. The mean C-Reactive Protein and erythrocyte sedimentation rate were 130 mg/L and 48 mm respectively. The white blood cell count was normal in 8 cases. Spine X-ray, performed in 15 cases showed blurring of the end-plates and decrease in disc space in 6 cases, degenerative signs in 7 cases, scalloping and collapse of the vertebral body in one case and marginal osteophytosis in 6 cases. Spinal magnetic resonance imaging, performed in 16 cases, revealed a high signal intensity on T2-weighted MRI interesting the disk and adjacent endplates (16), epidural space involvement (7) and paravertebral abscesses (10). The most frequent location of spondylodiscitis was lumbar spine (10). Pathogens were isolated in 10 cases. Pathogens has been isolated from blood cultures (5) and bacteriological urine test (2). CT-guided bone biopsy was performed in 5 cases. Histological examination revealed non-specific inflammatory signs. Bacteriological examination detected the pathogens in 3 cases. The portal of entry for pathogens was cutaneous (4), oral (2) and urinary (2). Antibiotic was conducted in all cases with an average duration of 5.2 months. Steroid was associated in three cases: two epiduritis and one spinal cord compression. A surgical abscess drainage was necessary in one case. Evolution was favorable with resolution of the symptoms in 13 cases. 3 patients complained of lower limb paraesthesia. One death occurred because of septic shock. Control MRI was performed in 11 cases showing regression of inflammatory signals and abscess in 9 cases, and persistence of inflammatory signals with epiduritis in 2 cases.

Conclusion

Our study showed that the diagnosis delay remains important in patients with pyogenic spondylodiscitis. It can be explained by the higher prevalence of degenerative back pain that may cloud diagnostic thinking. As in our study, the implicated organism may not be isolated in approximately one-third of patients. In these cases, the etiological diagnosis is established based on clinical, biological, and radiological findings.

#2149 - Case Report

SPONDYLODISCITIS DUE TO MULTIDRUG-RESISTANT AGENT - A THERAPEUTIC CHALLENGE

Andreia M. Teixeira, Carla Pereira Fontes, Ana Mafalda Silva, Samuel Fonseca

Centro Hospitalar Entre Douro e Vouga, Santa Maria Da Feira, Portugal

Introduction

Multidrug-resistant microorganisms are a worldwide public health threat as they are rising in prevalence and are associated with high mortality. Throughout the last years, carbapenems were the last resort antibiotics for resistant bacteria. Carbapenems'

resistance is caused by two main mechanisms: β -lactamase activity and production of carbapenemases classified into class A, B and D (Ambler classification system).

Case description

A 74-year-old man with a recent hospitalization due to a thoracic trauma, without previous antibiotic treatment, presented at the emergency department with prostration, fever and hypotension with no response to fluid resuscitation; blood tests revealed increased inflammatory markers, creatinine of 1.3 mg/dL, leukocyturia and hyperlactacidemia. Hydronephrosis was visible in CT scan. He was diagnosed with septic shock due to lithiasic obstructive uropathy and a double J stent was implanted. Blood cultures were positive for Carbapenemase belonging to class A (*Klebsiella pneumoniae* carbapenemase - KPC). Blood and urine cultures showed KPC resistant to carbapenems with exception of meropenem (MIC 1 μ g/mL) and susceptibility to ciprofloxacin. After 10 days of therapy he maintained fever, high inflammatory markers and positive blood cultures, however negative urine cultures and no genitourinary complication on CT scan. During hospital stay, several blood cultures sets were performed with different antibiogram results, with resistance to ciprofloxacin and progressive higher MIC to meropenem culminating into resistance, so that antibiotic regimen was constantly altered taking into account microorganism susceptibility. Due to antibiotic failure, new sites of infection were searched and several exams performed, though all normal. Towards complain of back pain, a magnetic resonance was done showing signs of spondylodiscitis from D8 to L4 vertebral bodies. At the time of spondylodiscitis diagnosis, the patient maintained bacteremia to KPC only sensible to colistin, fosfomicin and tigecyclin. He recovered well and was discharged home after eight weeks of efficient antibiotic therapy.

Discussion

Spondylodiscitis is a rare infection with grown incidence as population is ageing. It's not uncommon a delay between diagnosis and treatment due to unspecific symptoms and although antibiotic therapy was prompt initiated, KPC imposed a therapeutic challenge as antibiotic regimen is not consensual. Otherwise forgotten antibiotics have their interest restored.

#2154 - Case Report

RECURRENT PNEUMONIA ASSOCIATED WITH AORTIC ANEURYSM

Guilherme Assis, Joana Rua, Daniela Viana, Romeu Pires, Paula Vaz Marques

Hospital São Pedro de Vila Real, Vila Real, Portugal

Introduction

Recurrent pneumonia (RP) is commonly defined as 2 or more episodes within 12 months or 3 episodes altogether with radiographic clearance in between them. The most frequent etiology is considered inappropriate or incomplete treatment.

We present an unusual case of recurrent pneumonia secondary to bronchial obstruction caused by an aortic aneurism.

Case description

73-years-old woman admitted to the emergency room with respiratory symptoms – productive cough, progressive dyspnea, tremor and hemoptysis – less than 24 hours after the last hospital discharge. Background investigation revealed schizophrenia, dementia and the diagnosis of saccular aneurysm of the transverse aortic arch previously treated via thoracic endovascular aortic repair. Despite extensive comorbidities, her recent medical history of four similar episodes over the last 4 months seemed unjustified and exaggerated. Physical examination revealed acute hypoxemic respiratory failure and tachypnoea. Blood tests showed no relevant findings besides d-dimer 5.40 ug/mL and C-reactive protein 1.2 mg/dL. Relevant familiar history was also excluded. CTA excluded pulmonary embolism, leak-suggestive images or signs of bronchial alterations due to local erosion, and described consolidations on the inferior and superior left lobe with associated air bronchogram and thickening of the peribronchovascular interstitium – confirming the diagnosis of RP with overlapping localization of previous episodes – and aneurysm compression over both the left main bronchus and left pulmonary artery, conditioning partial bronchial obstruction. Invasive therapy was disqualified due to the risk of broncho-aortic fistula. Posterior admissions to the ER due to respiratory infection took place after the established diagnosis.

Discussion

RP is associated with several causes. When affecting the same lobes, differential diagnosis may include immunologic impairment, allergy/asthma, hearth failure, structural abnormality, post infective bronchiectasis or bronchial obstruction. When found in community acquired pneumonia, obstruction is frequently correlated with the detection of underlying primary or metastatic lung cancer. However, considering the imaging findings related to the previously diagnosed aneurysm, the association between bronchial obstruction due to vascular compression and the diagnosis of RP can be established.

#2176 - Case Report

PROGNOSIS OF INVASIVE PNEUMOCOCCAL DISEASE AFTER VASCULITIS

Ana Filipa Pires, Ana Areia Reis, Ana Ferreira Pacheco, Teresa Martins Mendes, Zélia Lopes, Mari Mesquita
Centro Hospitalar Tâmega e Sousa, Penafiel, Portugal

Introduction

Invasive pneumococcal disease is a severe infection, confirmed by the isolation of *Streptococcus pneumoniae* from a normally sterile location. *S. pneumoniae* is a major cause of bacteraemia in immunocompetent and immunosuppressed patients. With success of the pneumococcal conjugate vaccine, we see much

less antibiotic resistant pneumococcal infections and prognosis improved

Case description

We present a 36-year-old male, with no known medical history, admitted to the emergency department due to earache, fever and headache. Physical examination was notable for change in state of consciousness (Glasgow Coma Scale 9) without nuchal rigidity. Left otoscopy with evidence of otitis. Normal Brain CT scan. CSF: 176 cells, serum glucose ratio of ≤ 0.4 , proteins 208 mg/dl, gram positive diplococcus. *Pneumococcus* urinary antigen negative. After collecting blood cultures, initiated therapy with dexamethasone and ceftriaxone plus vancomycin. Admitted to ICU due to bacterial meningitis with neurological dysfunction. TT echocardiogram without evidence of endocarditis. HIV, HCV and VDRL negative. Electroencephalography without epileptiform activity. After isolation of *streptococcus pneumoniae* in blood cultures and CSF, vancomycin has been discontinued. The favorable clinical evolution, turned possible the ventilatory weaning. Transferred to the internal medicine ward at sixth day of ceftriaxone. Neurological examination showed paresis of the VI cranial nerve. Identification of *S. pneumoniae* with MIC of penicillin 0.012 mg/L turned possible alteration of antibiotic therapy to penicillin. MRE at 14th day of antibiotics showed focal change of signal mainly involving the right upper parietal lobe cortex and the left temporal lobe, corresponding to the area of cerebritis, ischemic infarction due to infectious alterations and inflammatory signs of blood vessels. Decided to keep antibiotic therapy for 21 days. Reevaluation MRI showed residual perivascular inflammatory changes.

Discussion

Cerebral vasculitis is a life threatening complication of pneumococcal meningitis and can be associated with high incidence of neurological complications. The authors present this case because the early suspect and diagnosis of cerebritis, as complication of invasive pneumococcal disease after occurrence of otitis, low MIC penicillin, and benefit of 21 days of antibiotics, allowed the improvement of neurological lesions. The patient follow-up after discharge, showed resolution of neurological signs

#2178 - Medical Image

PULMONARY TUBERCULOSIS: AN OLD BUT VERY PRESENT DIAGNOSIS

Paula Alexandra Gonçalves Costa¹, Ana Gorgulho², Ana Rita Rodrigues¹, Pedro Tavares¹, Dolores Gomes¹, Alcina Ponte¹

¹ Centro Hospitalar de Leiria, Leiria, Portugal

² Hospital de Cascais, Cascais, Portugal

Clinical summary

A 50-year-old man, active smoker for more than 20 years, presented to the emergency department with a 1-month history of shortness of breath, cough, chest pain, night sweats and weight

loss. On examination he was feverish and pale, with an absence of breath sounds on the upper half of both lungs.

A chest x-ray showed a diffuse and heterogeneous infiltrate with multiple cavitations. A pulmonary computed tomographic showed multiple thick-walled cavities with surrounding lung consolidation in a diffuse pattern in both lungs.

The patient's sputum smear was positive for acid-fast bacilli and he initiated treatment for tuberculosis. The patient continued treatment for 6 months, with a good clinical response, having been released when the sputum smear was negative.

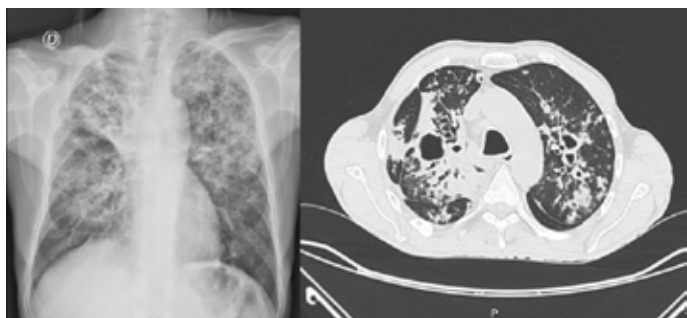


Figure #2178. Bilateral pulmonary tuberculosis.

#2183 - Case Report

CEREBRAL TOXOPLASMOSIS FOR AN HIV DIAGNOSIS AND WITH HIGH CD4 COUNT

Joao Gamito Lopes, Lucas Diaz, Jose Sousa E Costa

Hospital do Litoral Alentejano, Santiago Do Cacém, Portugal

Introduction

Toxoplasmosis is an infection caused by the intracellular parasite *Toxoplasma gondii*. It is the leading cause of focal central nervous system (CNS) disease in HIV patients. An association between low CD4+ count and incidence of Toxoplasmosis is known, mainly occurring in advanced HIV infection and considered an AIDS-defining illness. Nonetheless, it has been reported in HIV patients with CD4+ > 200 cells/ μ L.

Case description

A 31-year-old woman, Brazilian, without previous medical history nor drug habits or addicts, who was admitted to the Emergency Department due to an altered state of consciousness. Physical examination, she was prostrated, with scarce speech, gait difficulty, and febrile. Basic lab panel results were unremarkable. The CT scan showed multiple hypodensities of inaccurate limits (peripheral edema) in supra-tentorial bilaterally location, suggestive of infectious etiology. A rapid test for HIV detection came positive and due to highly suspicious Cerebral Toxoplasmosis empirically treatment was initiated. Definitive serologic test for HIV-1 was confirmatory, although immunologic status revealed a CD4+ count of 224 cells/ μ L. MRI imaging was performed and was also equally suggestive. Two weeks after treatment initiation her neurological status improved. A highly active antiretroviral therapy was then initiated. After three weeks of treatment follow-

up CT showed regression of the several lesions. The antibiotic therapy was maintained until 12 weeks and stopped after complete resolution of the lesion.

Discussion

The decision to initiate the treatment of a patient with suspicious CNS toxoplasmosis should not be delayed. Being a major cause of morbidity and mortality among HIV-infected patients, a count of CD4+ > 200 cells/ μ L should not discourage the start of treatment if suspicion is raised.

#2203 - Abstract

SPINAL BRUCELOSIS: CLINICAL, BIOLOGICAL AND IMAGING FEATURES

Sirine Miri¹, Maroua Slouma¹, Rim Dhahri¹, Leila Metoui¹, Najeh Boussetta¹, Nour El Houda Guediche¹, Sameh Sayhi¹, Rim Abid¹, Faïda Ajili², Riadh Battikh², Imene Gharsallah², Bassem Louzir²

¹ Military Hospital of Instruction of Tunis, Internal Medicine, Tunis, Tunisia

² Military Hospital of Instruction of Tunis, Internal Medicine, Tunis, Tunisia

Background

Brucellosis is a zoonosis that causes a systemic infection and can involve many organs and tissues. The spine is the most common site of musculoskeletal involvement.

Methods

A retrospective study involving 8 patients with spinal brucellosis during the period between 2005 and 2018. We reviewed the medical records of all patients diagnosed with spinal brucellosis.

Results

The mean age of patients was 61 years (4 males, 4 females; age range, 34-85 years). None of the patients was a smoker. None of them was under an immunosuppressive drug. 4 were consuming unpasteurized milk, cheese or other dairy products. The mean weight was 62 kg. The median diagnostic delay was 10 weeks. 4 patients had fever and nightsweats. All patients had inflammatory back pain, four patient had paravertebral muscular contracture, and 5 patients had lumbar stiffness. Two patients had motor weakness. Inflammatory Markers were raised in all cases: the mean of CRP was 63, the erythrocyte sedimentation rate was 48. Wright serology was positive in 7 cases. Rose Bengal test was positive in all cases. The search for brucella DNA by PCR was conducted in one case and came back positive.

Disco-vertebral biopsy was performed in three cases and it showed an inflammatory reaction in one case while it was normal in the other two. Magnetic resonance imaging was performed in 7 cases. The lumbar vertebra was the most frequently involved region 5 cases, followed by thoracic (2 cases) and cervical (1 case). 5 patients had epiduritis. Paravertebral masses and epidural masses were detected in 4 cases. All patients were treated by antimicrobial therapy of brucellosis (median 4.5 months; range,

3-6,5 months). 2 patients were given corticoids in addition, for 1 month. One case of drug toxicity was detected (cytolysis and cholestasis). Surgical treatment by laminectomy was necessary in the 2 cases of spinal cord compression. 6 patients had good clinical and radiological evolution. For both cases with spinal cord compression, one patient maintained walking disorders, the other patient was lost to follow-up. An MRI of control was practiced in 4 cases showing regression of inflammatory signals and disappearance of the collections. CT scan was performed in 2 cases demonstrating signs of bone reformation comprising peripheral sclerosis and osteophytosis.

Conclusion

Spinal brucellosis is easily misdiagnosed, but it is important to achieve an early diagnosis to prevent further complications.

#2206 - Medical Image

DISSEMINATED CUTANEOUS HERPES ZOSTER IN HIV PATIENT

Isabel Borges¹, Grace Staring², Angela Roda³, Paulo Filipe³

¹ Hospital do Divino Espirito Santo, Ponta Delgada EPE, Ponta Delgada, Portugal

² Centro Hospitalar Oeste, Torres Vedras, Lisboa, Portugal

³ Centro Hospitalar Lisboa Norte, EPE, Lisboa, Portugal

Clinical summary

Herpes zoster (HZ) is a reactivation of varicella zoster virus. It's incidence rate is 2-3/1000 person-years and is 10 times higher in HIV patients. We report, a 70 yo woman, HIV positive under antiretroviral therapy. She complains of fever and severe pain on the trunk, cutaneous vesicles and pustules for 7 days. Skin lesions involved the T1 to T4 dermatomes without organ dysfunction. Blood tests, revealed elevation of reative-c-protein, viral load was undetectable and CD4 count 320 cell/ μ L. Disseminated HZ was admitted. At the ward, we started intravenous acyclovir (10 days) and paracetamol (4gr/day) plus pregabalin (150mg/day) for acute pain. Incidence/severity of post herpetic neuralgia is increased in HIV patients and antiviral therapy is indicated. After 1 year, pain remains in 1-2%.

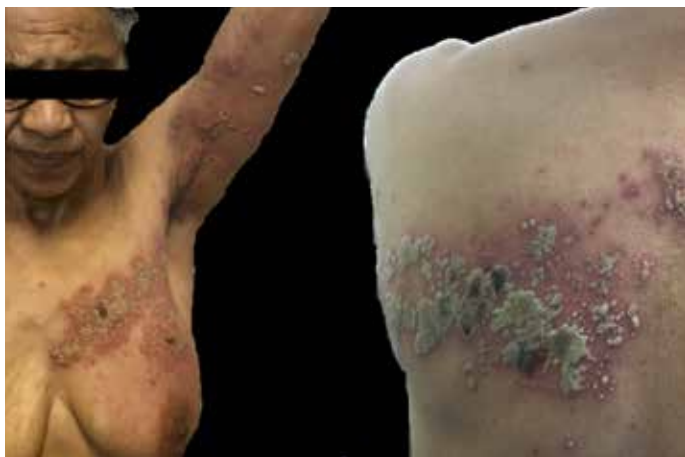

Figure #2206. Disseminated cutaneous Herpes zoster in a HIV patient.

#2221 - Case Report

JUST A BAD HEADACHE

Ana Costa, Olinda Miranda, David Paiva, Filipe Gonçalves, Elisa Torres, Jorge Cotter

Hospital Sra. da Oliveira - Guimarães, Braga, Portugal

Introduction

Herpes virus infections are common in humans. Varicella virus is a neurotropic virus that can reactivate later in life to cause zoster or shingles. Reactivation of latent varicella-zoster virus (VZV) infection most commonly manifests as herpes zoster. Varicella zoster virus meningitis is quite rare in immunocompetent adults. We report a case of an immunocompetent young adult presenting with a severe headache, without fever or skin rash and who was diagnosed with VZV meningitis.

Case description

Male, 21 years old. University student. Athletic - football player. Admitted in the emergency department (ED) with a three-day complaint of holocranial headache, intensity 8/10, with photophobia, nausea and two alimentary vomit episodes. The pain improved (not completely) with analgesics (acetaminophen, ibuprofen, naproxen) and worsened with cephalic movement. The patient also mentioned cervical discomfort with movement. Denied fever, respiratory, skin, gastrointestinal and genitourinary complaints. Denied paresthesia, strength or speech alteration or other complaints.

He had no relevant previous medical conditions, didn't take any medication. Denied smoking habits, but mentioned sporadic alcohol consumption.

ED physical examination without meningeal positive signs.

Blood tests showed no remarkable alterations. A brain CT was done, revealing no acute changes. He was submitted to a lumbar puncture with clear cerebrospinal fluid (CSF), opening pressure of 34 mm H₂O with a positive Queckenstedt maneuver. CSF analysis revealed 980/uL leucocytes with 90% mononuclear, elevated protein count (94,7 mg/dL). Virus panel positive for Varicella Zoster virus (VZV). Acyclovir was initiated.

After the diagnosis was made, the patient confirmed contact with a child with varicella manifestations one month earlier.

The patient remained without any cutaneous manifestation of a VZV.

CSF VZV anti-body and viral load came positive (viral load 20,4 copies/uL).

The patient had positive evolution, without any neurological deficits at discharge.

Discussion

Herpes zoster mainly affects elderly and immunocompromised patients. The typical reactivation occurs by vesicular skin rash along the nerve course, associated with pain and paresthesia. Meningitis is a rare complication of VZV infection

In this case, the patient didn't present skin manifestations or fever, presenting with a severe headache.

#2222 - Case Report

SEPTIC SHOCK AS A COMPLICATED PRESENTATION OF EMPHYSEMATOUS CYSTITIS

David Da Silva Dias¹, Catarina Jorge², Lucy Alves¹, Maria Pilar Perez³

¹ Algarve's University Hospital Centre - Faro Unit, Medical Oncology, Faro, Portugal

² Algarve's University Hospital Centre - Faro Unit, Internal Medicine Department, Faro, Portugal

³ Algarve's University Hospital Centre - Faro Unit, Polivalent Intensive Care Unit, Faro, Portugal

Introduction

Emphysematous cystitis (EC) is a rare presentation of complicated urinary tract infection. It's characterized by the presence of gas between bladder wall and lumen. Incidence is higher in female diabetic patients and clinical presentation varies and may be difficult to diagnose

Case description

A 24-years-old female, history of diabetes mellitus type 1 with 15 years evolution and poor metabolic control. Visited the emergency department with abdominal pain, but no fever, dysuria or gastrointestinal alterations. Patient was conscious, hemodynamically stable and eupneic. No alterations on cardiopulmonary auscultation. Abdomen with small distention, painful at the inferior quadrants, specially in the right side. Analytically, raised C reactive protein(CRP) 115 mg/dL and hyperglycemia 244 mg/dL. Pelvic and renal ultrasound showed a small thickening of appendix. Appendicitis was assumed and appendectomy was performed, but no inflammation was notable on operator piece. 48 hours post-surgery developed fever 38,5°C, macroscopic hematuria and pneumaturia with worsening of abdominal distension and pain. Abdominal plain x-ray presented hyper-transparent areas around the bladder wall, suggestive of EC. Fast deterioration of patient to septic shock was observed with metabolic acidemia and multiorgan dysfunction. Hemodynamic dysfunction, oliguria, increase in serum creatinine to 4 mg/dL and severe hypoxemia were present. Inflammatory parameters were elevated and presence of leucocyturia. Uroculture(UC) was collected and abdomen and pelvic CT scan was performed showing emphysematous lesion of bladder suspicious of rupture by EC versus surgical complication. Vesical rupture was excluded by exploratory laparotomy. Admitted in ICU needing vasopressor support, mechanical ventilation as well as dialytic session. Empiric antibiotherapy with cefepime and gentamycin was started due to clinical severity. *Escherichia coli* was isolated in UC and antibiotic was directed to antimicrobial sensibility test. Favourable evolution was observed.

Discussion

EC usually curses with favourable prognosis, although complications may arise up to 19% of cases. These complications

are specially related to delay in diagnosis and start of antibiotics. This clinical case report represents a diagnostic challenge that postponed the beginning of antibiotherapy, which led to septic shock. Quick start of antibiotics, vesical catheter and better metabolic control improves the prognosis and prevents otherwise avoidable complications.

#2229 - Case Report

ESPONDILODISKITIS: AS FAR AS NATURAL HISTORY GOES

Ema Leal, Diogo Borges, Catarina Marouço, Rita Alves, Madalena Vicente, Filipa Lourenço, Margarida Antunes, Sara Castro, Ana Lladó, Heidi Gruner, António Panarra

Hospital Curry Cabral, Lisboa, Portugal

Introduction

Vertebral osteomyelitis annual incidence has been rising due to increasing rates of bacteremia associated with intravascular devices, aging of the population, increasing number of immunosuppressed patients on either medication, renal replacement therapy, diabetes or HIV infection. The authors present a case that mirrors vertebral osteomyelitis literary description and underlines the need for a multidisciplinary treatment approach.

Case description

A 70-year-old man with 2 weeks progression muscular pain predominantly of the lumbar spine and progressive motor disability of the lower limbs, without fever and no response to analgesic therapy. He had rheumatoid arthritis under corticosteroids therapy and recent suspension of micophenolate de mofetil due to adverse effects; hypertensive heart failure and diabetes and was on dialysis after a renal transplant failure due to analgesic nephropathy. He was admitted to the internal medicine ward for surveillance in light of high inflammatory markers. Vertebral CT scan reported vertebral body collapse of L3, spinal stenosis and radicular compromise L2-L3. Aspirative biopsy and blood cultures confirmed methicillin-resistant *S. epidermidis*. Both TB, brucellosis and fungal infections were ruled out as was infective endocarditis. Due to sepsis, empiric antibiotic was initiated with Vancomycin and ceftriaxone and was later adjusted accordingly with vancomycin, yielding a clinical and analytic response. Evolution was not favorable with MRI showing worsening of vertebral lesions associated with epidural and paravertebral collections L2-L3, extending to psoas muscle. Considering the findings with cord compression and spinal instability, orthopedists were called and surgery was proposed, but clinical deterioration followed and he developed fever, pancytopenia and high inflammatory markers, which prompted the addition of Meropenem into treatment. At 15th day of antibiotic, the patient began presenting recurrent hemodynamic instability, responsive to fluids but conditioning hemodialysis fluids loss. He remained on surgical waiting list for 17 days for high surgical risk and hesitation to perform surgery. He died after 48 days of hospitalization.

Discussion

We present this case to emphasize the importance of a multidisciplinary approach on these conditions, the importance to recognize medical treatment failure and when prompt surgery is warranted to optimize treatment.

#2240 - Case Report

HIV INFECTION - DON'T JUDGE A BOOK BY IT'S COVER

Fábio Murteira, Pedro Oliveira, Nuno Leal, Ana Rita Costa, Margarida Mota, Andreia Seixas, Sara Pinto, Carina Silva, Vítor Paixão Dias

Centro Hospitalar Vila Nova de Gaia/Espinho, Vila Nova De Gaia, Portugal

Introduction

Despite the raising prevalence of people living with human immunodeficiency virus (HIV) infection, diagnosis is often delayed. Data from Portugal at 2017 indicate that at the time of diagnosis 16.0% had an AIDS-defining disease and 53.2% of cases had values of CD4+ cells below 350/ul (in the European Union (EU) this figure is 49% in the general population and 65% of those diagnosed > 50 years old). In Portugal 28.9% of cases were diagnosed after 50 years (highest concentration in this range of the EA). Older patients are usually less frequently tested.

Case description

Female, 72 years old, retired (worked with cork), widow for 27 years. Pulmonary tuberculosis (right lung) at 22 years of age, total thyroidectomy (multinodular goiter), hypertension, dyslipidemia, self-limited episode of hemoptysis 8 years ago (no investigation) and in the last 5 years with various urinary and low respiratory airways infections of mild severity. Six months ago she had new episodes of mild hemoptysis; performed thoracic CT scans that showed massive left cystic bronchiectasis (largest diameter 3.5 cm) - hypothesis of aspergillosis. She carried out a serological study, which showed borderline serum galactomannan assay (0.5, reference value <0.5) and negative aspergillus precipitins; decided not to began treatment, pursuing research.

About 3 weeks after she was hospitalized in the context of lithiasic parotiditis complicated with abscess. A percutaneous drainage was performed and antibiotic therapy started. At admission she also had moderate thrombocytopenia (96.000/ul; in the last 7 years presented mild thrombocytopenia without obvious cause). No other hematological changes.

Due to lowering platelets despite the infectious improvement, virus serologies were requested, with a positive 4^o generation HIV test; CD4+ cells 87/ul and viral load (VL) values 186864 copies/ml. Assumed transmission by heterosexual intercourse with sporadic partners in the last 10 years (she had an HIV negative evaluation 9 years ago). She was discharged from the hospital and began follow-up with antiretroviral therapy and after 4 months maintain clinical stability with CD4+ (223/ul) increase, VL decrease (251 copies/ml) and thrombocytopenia improvement (118.000/ul).

Discussion

This case alerts us to the need to maintain high level of suspicion for HIV infection even in elderly patients and without obvious transmission risk factors. Opportunistic screening should be used for presentations with others recurrent or severe infections.

#2243 - Medical Image

HEPATIC ABSCESS

Ana Costa, Gabriela Pereira, Olinda Miranda, David Paiva, Margarida Rocha, Jorge Cotter

Hospital Senhora da Oliveira - Guimarães, Guimarães, Portugal

Clinical summary

Male, 51 years old. Presented to the emergency department (ED) with a three-week complaints of asthenia, anorexia and weight loss. In the ED evaluation, he presented with a fever. Blood test revealed elevated inflammatory parameters and liver enzymes and coagulopathy. A CT revealed a large liver abscess (14x10 cm). Started ceftriaxone and metronidazole, escalated to piperacillin-tazobactam and metronidazole after 10 days (maintenance of fever). He completed 6 weeks of antibiotic therapy, No infectious agents were isolated.

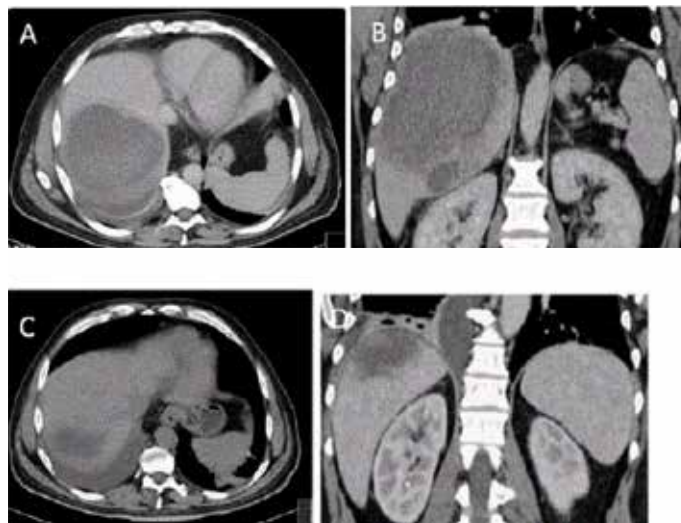


Figure #2243. Panel A-B: CT scan at diagnosis. Panel C-D: after treatment.

#2251 - Case Report

CARDIOPULMONARY SYNDROME BY HANTAVIRUS

Roberto Miguel Cataldi Amatriain, Adel Enrique Escobar Garcia, Luciano Negri, Rocío Alvarez, Nathalie Abreu, Lucas Dolcemelo
Del Carmen Clinic, Zárate, Buenos Aires Province, Argentina

Introduction

The Hanta virus cardiopulmonary syndrome (SCPH) is a viral and zoonotic respiratory disease, being frenetic in Latin America and that can lead to death in only 72 hours of the clinical picture.

The etiological agent belongs to the genus Hantavirus, family Bunyaviridae. The infection is acquired mainly by inhalation of aerosols or contact with excrement or saliva of infected rodents.

Case description

We present the case of a male patient of 34 years of age, worker at the port terminal. Who is admitted with a clinical picture of approximately 9 days of evolution characterized by fever, general decline, inappetence, myalgias, arthralgia, nausea, diarrhea that appears in the last 3 days, accompanied by dry cough and dyspnea.

Discussion

In the course of hours a syndrome of respiratory distress of rapid evolution was established producing respiratory acidosis, hemodynamic deterioration with severe cardiogenic shock that required vasoactive therapy and mechanical ventilatory support with good clinical evolution.

#2253 - Abstract

ANALYSIS OF POST-SURGICAL MENINGITIS CASES ATTENDED IN A THIRD LEVEL HOSPITAL. EVALUATION OF THE MAIN CHARACTERISTICS, MICROORGANISMS AND TREATMENT

Cristina Rodríguez Fernández-Viagas, Juan Martínez Chinchilla, Jesús Riqué Dormido, Miguel Marin Laut, Francisca Maria Guerrero Sánchez, Montserrat Montes De Oca Arjona
Hospital Universitario Puerta del Mar, Cádiz, Spain

Background

Postsurgical meningitis is a rare complication with high mortality. The aim of this study is to analyze the frequency of postsurgical meningitis in our hospital, to detect the most frequently risk factors and to know microorganisms involved and their sensitivity profile to indicate the most accurate antimicrobial therapy to our zone.

Methods

Retrospective and observational study from January 2013 to December 2017. Patients who presented cerebrospinal fluid (CSF) infection after cranial or spinal surgery was included. CSF cultures with microorganism growth without clinical or analytical repercussion were excluded. Type of surgical intervention performed as well as urgent or programmed nature of it were included as study variables, also the implantation of any device, analysis from CSF and blood tests, clinical manifestations, risk factors, microorganisms and their sensitivity and antimicrobial treatment. A descriptive statistic was performed.

Results

50 patients-cohort with a mean age of 52.38 years (56 years, SD 18.65) and Charlson comorbidity index of 2.4 points on average. 12% (n=6) died due to the evolution or related complications,

mostly males with a mean age of 58.67 years and Charlson comorbidity index of 5.16 points. Most frequently symptoms were headache (48.7%), fever (41%), decreased level of consciousness (28.2%), CSF fistula (15.3%), meningeal signs (12.8%), surgical wound infection (12.8%), peritonitis (5.1%), seizures (2.5%), vomiting (2.5%). Surgical interventions most frequently related were ventriculoperitoneal and ventriculoatrial CSF shunts (48,4%), cranial tumor resection (28,2%), thoracolumbar spine interventions -including laminectomy, discectomy, lumbar canal stenosis and spinal tumors (12,8%)- and decompressive craniectomy (5,2%). In most cases (82%) some type of material was implanted, whether external drains, CSF shunts, osteosynthesis material or dural plasties. Microorganisms mainly involved: Gram positive cocci (68%) -S epidermidis most frequently-, gram negative bacilli (66%) -including Pseudomonas (n=5), E cloacae (n=3) and A baumannii (n=5).

Conclusion

Postsurgical meningitis are infrequent in our hospital, with an important mortality rate, although those cases had higher comorbidity index. The most frequently related interventions were CSF shunt and in almost every patient some type of device was implanted. Microorganism most frequently implicated were gram-positive cocci and gram-negative bacilli, with a low rate of antimicrobial resistance.



KIDNEY AND URINARY TRACT DISEASES

#21 - Abstract

THE RELATIONSHIP BETWEEN THE CONCENTRATION OF PLASMA HOMOCYSTEINE AND CHRONIC KIDNEY DISEASE – A CROSS SECTIONAL STUDY OF A LARGE COHORT

Eytan Cohen, Ili Margalit, Elad Goldberg, Tzippi Shochat, Ilan Krause

Rabin Medical Center -Beilinson Hospital, Petach Tikva, Israel

Background

High concentrations of homocysteine are considered a risk factor for developing atherosclerosis and coronary artery disease. The aim of this study was to assess the concentrations of homocysteine in subjects with chronic kidney disease (CKD).

Methods

Data were collected from medical records of individuals examined at a screening center in Israel between the years 2000-2014. Cross sectional analysis was carried out on 17010 subjects; 67% were men.

Results

Significant differences were observed between four quartiles of homocysteine concentrations and estimated glomerular filtration rate (eGFR) - the higher the homocysteine concentration, the lower the eGFR ($p < 0.001$). Mean (SD) homocysteine concentrations in subjects with eGFR < 60 mL/min per 1.73 m² compared to subjects with eGFR ≥ 60 mL/min per 1.73 m² were: 16.3 (5.9) vs. 11.5 (5.5) μ mol/L respectively ($p < 0.001$). These findings remained significant after adjustment for age, smoking status, body mass index, hypertension and diabetes mellitus ($p < 0.001$). Compared to subjects with homocysteine concentrations less than 15 μ mol/L, those with homocysteine concentrations equal and above 15 μ mol/L had a significantly higher odds ratio (95% CI) of having an eGFR < 60 mL/min per 1.73 m²; non adjusted model, 8.30 (6.17- 11.16); adjusted model for age smoking status, body mass index, hypertension and diabetes mellitus, 7.43 (5.41- 10.21).

Conclusion

Plasma homocysteine concentrations are higher in subjects with CKD. This may contribute to an increased risk for developing atherosclerosis and coronary artery disease in these patients.

#38 - Case Report

A RARE ASSOCIATION OF ANTI- GLOMERULAR BASEMENT MEMBRANE ANTIBODY-NEGATIVE, BIOPSY- PROVEN GOODPASTURE DISEASE WITH MYOCARDITIS AND UNUSUAL SKIN LESIONS: A CASE REPORT

Shambaditya Das, Subhasis Neogi, Chirantan Mandal, Ananta Dutta, Niladri Sarkar

Institute of Post Graduate Medical Education & Research, Kolkata, India

Introduction

Anti-glomerular basement membrane disease is a rare small vessel vasculitis that affects the capillary beds of the kidneys and lungs.

Case description

A 24-year-old female with no previous comorbidities presented with a rapidly developing oliguria and hematuria (rapidly rising serum creatinine; red blood cell ,RBC cast, dysmorphic RBC, and subnephrotic range proteinuria in urine suggestive of rapidly progressive glomerulonephritis), cough without hemoptysis (low hemoglobin levels, baseline hemoglobin not available, pulmonary hemorrhage), with chest pain, severe shortness of breath and orthopnea, electrocardiogram had Pan ST-T changes, Trop-i markedly raised, echocardiography shows global hypokinesia-features suggestive of myocarditis). The patient also had nonblanching skin lesions mainly in lower limbs and buttocks (skin biopsy suggestive of "perforating disorder" with no evidence of vasculitis). Antinuclear antibodies, dsDNA, antineutrophil cytoplasmic antibody, MPO, PR3, HBsAg, and anti-HCV were all negative. Complements were normal. Blood cultures showed no growth. Anti-glomerular basement membrane (GBM) was negative. Renal biopsy was done and showed necrotizing and crescentic glomerulonephritis with linear immunoglobulin G staining consistent with anti-GBM disease.

Discussion

There are only few published reports of anti-GBM negative Goodpasture's disease, a clinical situation that causes diagnostic difficulty. To our best knowledge, there reports with acquired perforating dermatosis myocarditis in Goodpasture,implication being volume overload may increase the proneness to alveolar

hemorrhage. Rare constellation of symptoms and organ involvement can occur in Goodpasture and can pose a diagnostic dilemma and have effect on the prognosis due to delayed diagnosis. But no single test can replace accuracy of a good-quality kidney biopsy and a clinical acumen in diagnosing it.

#62 - Case Report

NEPHROTIC SYNDROME DUE TO NONSTEROIDAL ANTI-INFLAMMATORY AGENTS

Zaida Salmón González, Paula Hernández Martínez, Iria Sanlés González, Lara Belmar Vega, Gonzalo Martínez De Las Cuevas, Sara Nieto Martínez

Hospital Marqués de Valdecilla, Santander, Spain

Introduction

Membranous nephropathy (MN) is characterized pathologically by glomerular deposits of immunoglobulinG and complement components along the subepithelial surface of the glomerular capillary wall, increasing glomerular permeability to protein. This manifests clinically as nephrotic syndrome. In 25% of patients, MN occurs as a manifestation of another disorder (rheumatologic conditions, infection, malignancy or drugs).

Case description

88-year-old male, active smoker and COPD. He was admitted for placement of a hip prosthesis due to coxarthrosis. In the immediate postoperative he was treated with anti-inflammatories no steroids (NSAID), presenting acute renal failure. Physical examination showed TA 134/51 mmHg, FC 71 bpm with progressive pitting edema in the lower extremities abdominal wall and pulmonary crackles. Analytically, Creatinine 2.27 mg/dL and glomerular filtration (CKD-EPI) of 25 ml/min/1.73m². At that time, elemental and sediment microhaematuria and proteinuria were observed, with quantification of it in 24 hours of 9g with severe hypoalbuminemia in blood (1.9 g/dL) A kidneys ultrasound was normal. Laboratory parameters, including complete blood count, tumour markers, proteinogram and Bence-Jones proteinuria were within normal limits. C3 (147 mg/dL) and C4 (53.40 mg/dL) were positive. The remainder of serological and immunological studies (ANA, FR, Anti-MBG, Anti-MPO, Anti-PR3) were all negative. The renal biopsy confirmed the diagnosis. Corticoid, diuretics and albumin treatment were started with improvement both clinical and analytic.

Discussion

Membranous nephropathy is the main cause of nephrotic syndrome in adults. NSAID-associated MN is an important but underrecognized secondary cause of MN. MN may occur after a variable but often short duration of NSAID use and generally is not accompanied by systemic allergic symptoms or interstitial nephritis.

#98 - Abstract

BALKAN ENDEMIC NEPHROPATHY-EARLY SUBCLINICAL MANIFESTATIONS OF DISEASE AND PREVENTION OF IMPAIRMENT PROGRESSION OF RENAL FUNCTION

Tamara Lazic Golubovic, Aleksandra Arsenovic

Special hospital for BEN, Lazarevac, Serbia

Background

Balkan endemic nephropathy BEN is a slowly progressive, chronic tubulointerstitial kidney disease, focal disseminated along tributaries of the Danube river in the Balkan countries with familial clustering. The natural course of the disease is characterized by universal development of end-stage renal disease and the frequent development of upper urinary tract tumors.

This study aimed to evaluate effects of preventive measures and treatment on adult offspring of BEN families, in which in previous study was detected a early changes in renal function.

Methods

The study was a prospective-observational follow-up of 65 patients (56.9% men, 43.1% women, mean age 55.9±20.67 years, mean serum creatinine was 113.9±22.89 umol/l, GFR was 108.7±53.9 mL/min/1.73 m²). Some respondents had some tubular function disorders- low urine osmolality 16%, FENa >1% 21.5%, TRP <84% 7.69%, higher elimination of alpha-1 57% and beta-2 MG 38%, proteinuria was represented in 29.23%, 58.46% had a hypertension, 41.73% anemia. During one year, subjects were treated with a hypoprotein and low-sodium diet, iron preparations, recombinant human erythropoietin and antihypertensive agents.

Results

After one year of applied treatment measures, it has been observed that there has been statistically significant correction of anemia, increased osmolality of urine, decrease of fractional excretion of sodium, establishment of blood pressure control and reduction of microalbuminuria. There have been no significant changes in serum creatinine level, alfa 1 and beta 2 microglobulinuria and proteinuria.

Conclusion

Some disorders in the renal function, such as tubular and glomerular mentioned above, are present in adult offspring of BEN families in which it has not developed CKD stage 3-5.

By adequately screening the descendants of families affected by BEN and timely treatment, progression of the disease can be slowed down.

#117 - Abstract

THE PROGNOSTIC VALUE OF AMBULATORY ABNORMAL SERUM CHLORIDE

Boris Shvarts, Tali Shafat, Victor Novack, Yosef S. Haviv, Leonid Barski

Soroka University Medical Center, Beer Sheva, Israel

Background

Chloride is the major extracellular anion, which plays a key role in acid-base balance and body fluids homeostasis. Nevertheless, abnormal chloride levels are often ignored. This population-based study aimed to investigate the prognostic value of chronic serum chloride abnormalities.

Methods

The study population included all adult patients, insured by "Clalit" Health Services, southern district, who underwent at least three ambulatory serum chloride examination during 2005-2016. Clinical and laboratory data were retrieved from patients' charts and computerized databases, including demographics, co-morbidities, laboratory data (inclusive of abnormal chloride levels as pre-defined by the central laboratory) and medication use. For each patient, the period with low (≤ 97 mEq/L), high (≥ 107 mEq/L) and normal (98-106 mEq/L) serum chloride level was calculated, with corresponding sodium and creatinine levels. A Cox proportional hazard ratio model with patient level clustering and robust estimates was used to estimate the mortality risk of hyperchloremic and hypochloremic periods adjusted to possible confounders.

Results

105,655 patients with 664,253 serum chloride tests were analyzed. During a median follow up duration of 10.8 years, 11,694 patients died. Both hypochloremia and hyperchloremia were associated with elevated all-cause mortality risk, after adjusting for age, co-morbidities, serum sodium level and estimated GFR with HR 2.43 (95% CI 2.21-2.68, $P < 0.001$) for hypochloremia and HR 1.11 95% (CI 1.05-1.17 $P < 0.001$) for hyperchloremia. Extreme hypochloremia had a HR of 2.13 (CI 1.22-3.7, $P = 0.008$). Secondary analysis aimed to point the exact chloride cutoff associated with elevated mortality risk, revealed that for the low cutoff, there was a trend of elevated risk for chloride levels even within the "normal" range (HR 2.16 for cutoff of ≤ 98 mEq, HR 1.92 for cutoff of ≤ 99 mEq, HR 1.72 for cutoff of ≤ 100 , HR 1.57 for cutoff of ≤ 101 , HR 1.47 for cutoff of ≤ 102 , HR 1.37 for cutoff of ≤ 103).

Conclusion

Abnormal ambulatory serum chloride levels, primarily hypochloremia, are associated with an increased mortality risk. Based on our findings, we suggest that the optimal chloride serum level is between 105 and 106 mmol/l.

#131 - Case Report

CAN CRYOGLOBULINEMIA TRIGGER ANCA VASCULITIS?

Ivo Cunha, Teresa Santos, Ricardo Pereira

Hospital Pedro Hispano, Matosinhos, Portugal

Introduction

Antineutrophil cytoplasm antibody-associated (ANCA) vasculitis are a rare and heterogeneous group of autoimmune diseases. These vasculitis, pauci-immune, differ from the cryoglobulinemic vasculitis mediated by immune complexes.

Case description

A 79-year-old male with silicosis and chronic alcoholic liver disease, presented with a rapidly progressive glomerulonephritis and pancytopenia. Work-up revealed hypocomplementemia, polyclonal hypergammaglobulinemia, cryoglobulinemia type 3, p-ANCA + and elevated anti-MPO. Renal biopsy revealed a pattern of chronic interstitial nephritis with the presence of reactive follicles (CD3+), with inflammatory vascular lesions, namely fibrocellular growths and arteriolitis phenomena, alterations compatible with pauci-immune vasculitis with predominant tubulo-interstitial manifestation. Treatment was started with corticosteroids and rituximab with improvement of the renal function, decrease of the anti-MPO title and disappearance of the cryoglobulinemia.

Discussion

In this case, renal injury was caused by ANCA vasculitis which etiology remains unknown despite the recognizable risk factor for the ANCA formation (silicosis). The importance of the cryoglobulinemia is not clear, as it could be part of the pathogenesis or just an epiphenomenon secondary to the autoimmune and the liver chronic diseases. Even though this could be case of a two distinct entities in the same patient, it is still possible that some type of interaction between cryoglobulins and ANCAs occurs. The association between ANCAs and cryoglobulins have been questioned without any clear definition of their possible interactions. What seems most obvious, given the basic constitution of both immunoglobulins and the efficacy of rituximab in its treatment, is a possible role of B lymphocytes in the regulation or "deregulation" of the interaction between the two types of antibodies. But the question remains whether the "quiescent" cryoglobulins in the patient in question will have contributed and could eventually be identified as a risk factor for the development of ANCAs and later, for the evolution to a vasculitic process.

#140 - Medical Image TWIN KIDNEYS

Iolanda Oliveira, Sofia Calaça, Mariana Soares, Rui Silva, Carlos Silva

Hospital Espírito Santo - Évora, Évora, Portugal

Clinical summary

A 47-year-old female patient with stage 5 CKD due to autosomal dominant polycystic kidney disease, opted for peritoneal dialysis (PD) in 2017. There was always difficulty in achieving adequate

dialytic efficiency by very large kidneys, which hampered the use of adequate volume in the exchanges, and also a major risk of mechanical complications of abdominal wall, as this patient had (umbilical hernia).

Abdomino-pelvic CT: anteroposterior renal axes are right and left, 21.3 cm and 21.47 cm, respectively, plus umbilical hernia 12.3x4.60x12.3 cm.

In December 2018 and in January 2019, exit site and tunnel infection was presented as well as worsening of the incisional hernia. PD cat dialysis program.

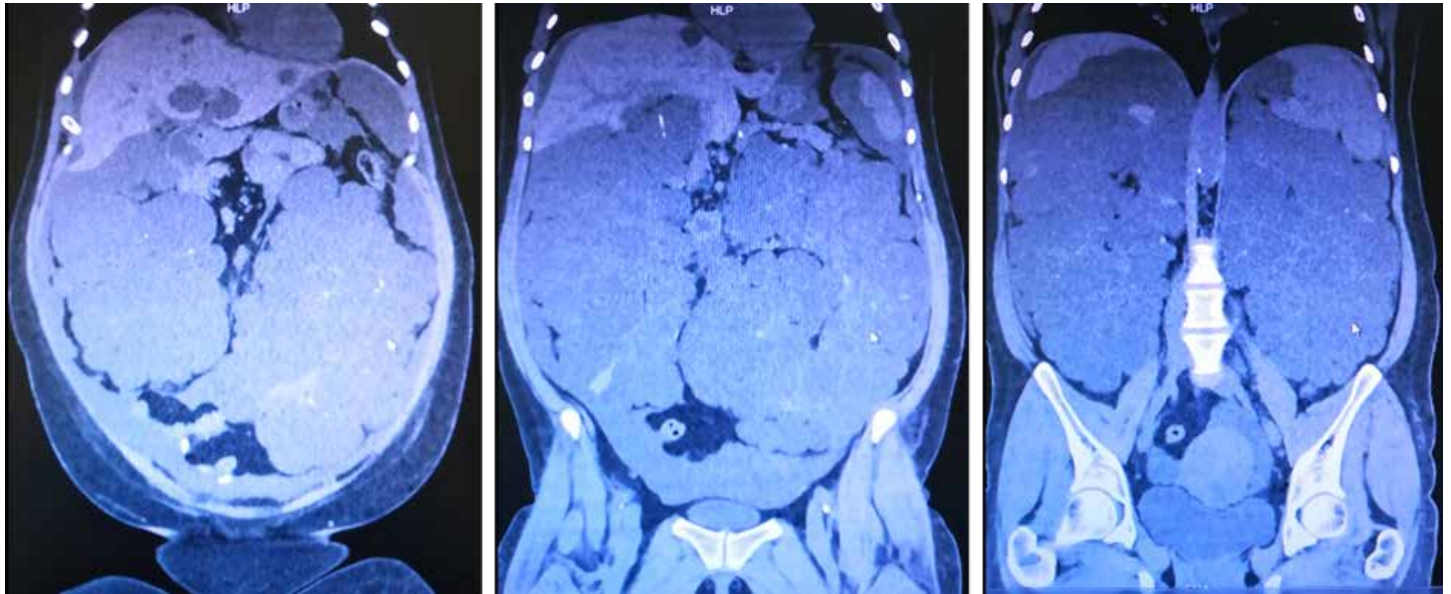


Figure #140. Abdomino-pelvic CT scan.

#350 - Case Report

THE ACTIVE VITAMINE D TREATMENT IS TOTALLY HARMLESS?

Mariana Irina Nechita

CHU Brugmann, Bruxelles, Belgium

Introduction

Patients who had undergone parathyroidectomy, usually receive active vitamin D and a calcium supplement as treatment. Finding the right dose of vitamin D by avoiding episodes of hypo/hypercalcemia or hypo/hyperphosphatemia is a challenge for every practitioner. Indeed, high levels of vitamin D determine an increase in intestinal calcium absorption, which promotes the development of hypercalcemia. This can lead to renal failure, either by direct action of calcium with the installation of renal vasoconstriction, or by the formation of intraparenchymal calcium deposits (nephrocalcinosis) or by urinary tract lithiasis.

Case description

We present you with a case of a young woman who received active vitamin D in the context of iatrogenic hyperparathyroidism, post total thyroidectomy for a goiter with cold nodule. She was presented in Nephrology Department for chronic kidney failure

and hypercalcemia.

The blood sample showed: creatinine: 1.53 mg/dl (normal values: 0.57-1.11); urea: 34 mg/dl (VN:15-39), creatinine clearance (MDRD): 38.1 ml/min, Ca: 2.83 mmol/l (VN:2.10-2.55), Ca corrected: 2.56 mmol/l, P: 1.09 mmol (VN:0.74-1.52), 1,25diOH-vitamin D=94 µg/ml (VN:25-86). The urinary sample showed: Urinary calcium: 11.3 mmol/24h (VN:2.5-7.5), Ca/creatinine ur: 0.315 (VN <0.12), proteinuria: - 150.9 mg/24h (VN <100).

Renal ultrasound showed a normal size kidney without urinary tract dilatation and no lithiasis.

A renal biopsy was performed which showed: renal parenchyma within the normal range, except for the presence of two interstitial calcifications.

By corroborating the clinical, biological and pathological elements, resulted in a diagnosis of nephrocalcinosis.

Discussion

Nephrocalcinosis with renal failure remains one of the most common complications in patients with hypoparathyroidism, but often underestimate. That is explained by the difficulty to correctly titrate the dose of active vitamin D and the absence of the effect of PTH in renal tubular calcium reabsorption, leading to an increase calciuria.

To prevent the onset of nephrocalcinosis or to prevent the progression of renal failure, the dose of calcitriol and calcium should be titrated to obtain a serum calcium concentration between 2.0-2.1 mmol/l and a calcium level <250 mg/24h.

Perhaps, in the future, with the passage of time in ensuring the safety of rPTH, hypoparathyroidism suffering patients shall benefit from this treatment and renal complications related to hypoparathyroidism will no longer occur.

#454 - Abstract

ASSOCIATION BETWEEN PROTEINURIA AND THE RENAL RECOVERY IN PATIENTS WITH ACUTE KIDNEY INJURY

Zorica Dimitrijevic¹, Jelena Randjelovic²

¹ Clinical Center Nis, Clinic for Nephrology, Nis, Serbia, Serbia

² Clinical Center Nis, Clinic for Nephrology, Nis, Serbia

Background

In diabetic or hypertensive patients, proteinuria has long been linked to the development of chronic kidney disease. However, in patients with acute kidney injury (AKI), its utility in predicting the renal outcome is still unknown. The aim of our study was to evaluate the relationship between the renal outcome and urine protein excretion.

Methods

Our study group comprised of one hundred fifty patients with AKI hospitalized during two years period with at least two inpatient serum creatinine measurements. AKI was defined using KDIGO guidelines, and recovery was defined as a hospital discharge serum creatinine less than 1.25 times baseline. We divided patients into AKI recovery group (n=97) and non-recovery group (n=53). Demographics, AKI etiology, hematological and biochemical parameters, and measurement of proteinuria were obtained for all patients.

Results

47.33% were male, the mean age was 65,23 ± 15 years (range 19 - 89 years). Renal non-recovery patients had higher rates of proteinuria (2.44 [IQR 0.0-16.0] compared to recovery group (1.33 [IQR 0.0-11.0] g/L, p<0.001). Proteinuria level and the renal recovery significantly negatively correlated (r = -0.217, p = 0.008). The proteinuria cut-off value of 0.47g/l was a good predictor of renal outcome (sensitivity 66.1% and specificity of 71.8%) with the area under the curve of 0.734 (95%CI: 0.635–0.833, p<0.005).

Conclusion

Proteinuria level might be a valuable prognostic marker for the renal outcome in the patients with AKI.

#498 - Abstract

THE INTEREST OF CORRECTED CALCIUM IN HEMODIALYZED

Zekri Salima, Hanachi Sabah, Sifi Karima, Abadi Nouredine, Benbarek Karima

Laboratory of Biology and Molecular Genetics, University Constantine 3, Constantine, Algeria

Background

Disturbances in calcium levels are not negligible in dialysis patients, and represent an important cause of morbidity and mortality.

The K / DOQI guidelines set target values for serum calcium, which should be maintained between 2.1 and 2.37 mmol / L. In the case of routine clinical interpretation of calcium in dialysis patients, they only recommend the value of total calcium corrected by albumin and the correction regularly proposed in the literature is as follows: [Ca "corrected" (mmol/L) = Ca measured (mmol/L) + 0.020 or 0.025 (40 - albumin (g / L))]; formula (0.020/40) and formula (0.025/40). The aim of our work was to study the influence of albuminemia on changes in serum calcium levels in dialysis patients, to evaluate the value of albumin-corrected calcium in these patients, and corrected calcium level compliance with K / DOQI 2009.

Methods

In the case of routine clinical interpretation of calcium in dialysis patients, they only recommend the value of total calcium corrected by albumin and the correction regularly proposed in the literature is as follows:

[Ca "corrected" (mmol/L) = Ca measured (mmol/L) + 0.020 or 0.025 (40 - albumin (g/L))]; formula (0.020/40) and formula (0.025/40).

Results

Our study included 105 patients at the hemodialysis service level of the Daksi-Constantine Renal Clinic. Includes both sexes (42% female, 58% male), aged between 18 and 86 years, the majority of patients had arterial hypertension (41.90%) followed by diabetes 10.47%, 4.76% Associated hypertension of diabetes, 4.76% other illness and 38.09% for those who did not have a primary problem. In this study the calcium disorders encountered were hypocalcemia with a rate of 48.57% and hypercalcemia 09.52%.

Our hemodialysis patients follow targets based on the clinical recommendations of the KDOQI 2009 guidelines as follows: 76.8% of patients meet targets for calcium and 23.2% do not meet targets. Our results according to the two correction formulas are:

Formula: 0.020/40: 74.28% of patients meets KDOQI 2009 standards and 25.71% do not meet these standards

Formula: 0.025/40: 71.42% of patients meet the standards of KDOQI 2009 and 28.78% do not meet these standards

Conclusion

In conclusion, according to the results given total corrected serum albumin in the IRCT patient brings nothing more than the assessment of uncorrected calcemia. Only the measurement of ionized calcium is reliable when done in good conditions

#513 - Case Report

DABIGATRAN-INDUCED NEPHROPATHY AND ITS SUCCESSFUL TREATMENT WITH IDARUCIZUMAB - CASE REPORT AND LITERATURE REVIEW

Jenan Awesat, Iftach Sagy, Anat Rabinovich, Alan Jotkowitz, Elena Shleyfer, Leonid Barski

Soroka University Medical Center, Beer Sheva, Israel

Introduction

Anticoagulant induced renal injury has been previously described with Warfarin treatment.

In the last decade direct oral anticoagulants (DOAC) were introduced. They included direct inhibitors of factor Xa (rivaroxaban, apixaban, edoxaban) and a thrombin inhibitor (dabigatran). There are isolated reports describing acute kidney injury (AKI) due to the use of DOACs.

Case description

We report a clinical case of an 80-year-old patient recently started on dabigatran for new onset atrial fibrillation. She presented with AKI and hematuria, urine specimen showed RBC casts, and a working diagnosis of anticoagulant nephropathy due to dabigatran was made. During hospitalization she was treated with Idarucizumab with a full recovery of renal function.

To the best of our knowledge, there are 4 published case reports describing kidney injury produced by dabigatran.

Discussion

The use of DOACs is increasing rapidly, with increasing concern about its safety profile and, in particular, its potential harmful effect on renal function. As described in our case, treatment with Praxbind for dabigatran induced kidney injury may be an acceptable management strategy that may obviate the need for urgent dialysis in selected cases by complete reversal of the AKI.

#520 - Medical Image

AN UNVEILED FOCUS – FEVER AND ABDOMINAL PAIN IN A DIABETIC PATIENT

André Maia, Catarina Carvalho, Ana Isabel Barreira, Ana Catarina Maciel, Fernando Salvador, José Ribeiro Eira, Paula Vaz Marques
Centro Hospitalar de Trás-os-Montes e Alto Douro - Hospital de São Pedro de Vila Real, Vila Real, Portugal

Clinical summary

Female, 61 years old, with a history of primary hypertension, dyslipidemia, type 2 diabetes mellitus (DM), chronic pyelonephritis (PN), chronic kidney disease stage G3bA3 and treated right breast neoplasm.

She was admitted for left iliac fossa pain, vomiting and fever. Blood workup showed acute kidney injury stage 2, metabolic acidosis, hyperkalemia, neutrophilia and high C reactive protein. Urinalysis was unremarkable.

Computed tomography (CT) showed left kidney enlargement with emphysematous PN class 3A and a 5.5 cm abscess (Figure). Left percutaneous nephrostomy and ureterovesical catheter were placed. Urinoculture revealed *Pseudomonas aeruginosa* and *Escherichia coli*, with good response to antibiotics. Re-evaluation CT showed abscess resolution and left kidney size decrease.

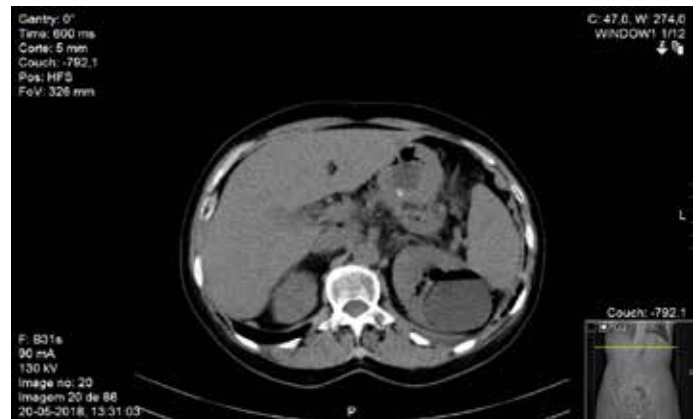


Figure #520. Transverse section of a computed tomography scan showing left kidney enlargement and an abscess with an air-fluid level, in continuity with an area of emphysematous pyelonephritis.

#529 - Case Report

ATYPICAL HEMOLYTIC UREMIC SYNDROME: A FAKE TRAVELERS' DIARRHEA

Christian Oblitas, Almudena Marcelo-Ayala, María Rosa Melero-Martín, Jose María De-Miguel-Yanes

Hospital General Universitario Gregorio Marañón, Madrid, Spain

Introduction

Hemolytic uremic syndrome (HUS), both "typical" (related to Shiga toxin) and "atypical" -aHUS- (related to the activity of the complement system), and thrombotic thrombotic purpura (TTP) present common histopathological features of thrombotic microangiopathies (TMA), endothelial lesions and microthrombi. The classic clinical triad for HUS includes: non-autoimmune hemolytic anemia, thrombocytopenia (absent in up to 20%), and renal failure. For diagnostic purposes of TMA, ADAMTS13 activity should be tested firstly (<5-10% is considered diagnostic of TTP). If levels are over 10%, we should next confirm the presence of the Shiga toxin to characterize "typical" HUS; otherwise, we would be faced with aHUS.

Case description

A 50-year-old woman, with history of splenectomy for hereditary spherocytosis in 2016, was transferred to the Internal Medicine Day Hospital after initial evaluation at the ED. She referred a 10-day history of bloody diarrhea, abdominal pain and fever (39°C) after a short trip to Egypt, treated with ciprofloxacin 500 mg bid for 5 days. On physical examination, BP: 121/60 mmHg, HR: 87 bpm and temperature: 37.7 °C were recorded. There was diffuse pain on abdominal palpation, without guarding. Laboratory tests

showed: hemoglobin 9.8 g/dl, platelets 85.000/ μ l, leukocytes 7.500/ μ l, INR 1.07, fibrinogen 499 mg/dl, glucose 104 mg/dl, ALT 74 U/l, bilirubin 1.6 mg/dl, GGT 17 U/L, creatinine 2.02 mg/dl, lipase 58 U/l, uric acid 7.5 mg/dl, LDH 1113 U/l, and haptoglobin 6 mg/dl (normal 41-165 mg/dl). Blood smear showed 3% schistocytes. A direct antiglobulin test was negative. Imaging tests were normal. ADAMST13 activity was 60%, and microbiological samples were negative.

A diagnosis of aHUS was done, and after 3 plasmapheresis sessions, platelets count and renal function normalized, persisting mild deficiency anemia.

Discussion

Atypical HUS is a rare entity with high morbidity and mortality burden. Its diagnosis remains a clinical challenge and includes a comprehensive approach to establish a primary (alternative route of the complement system) or secondary origin (viruses, Pneumococcus, autoimmune diseases, neoplasms, drugs, or C-cobalamin deficiency). The treatment includes plasmapheresis, and more recently eculizumab, a humanized monoclonal antibody that blocks the activation of the complement membrane attack complex.

In conclusion, we present a case of a woman with aHUS successfully managed with plasmapheresis.

#536 - Abstract

IN-HOSPITAL OUTCOMES IN PATIENTS WITH END-STAGE-RENAL DISEASE (ESRD)

Lukas Hobohm¹, Ingo Sagoschen², Thomas Münzel³, Karsten Keller

¹ Center for Cardiology, Rheinland-Pfalz - Mainz, Germany

² Cardiology I, Rheinland-Pfalz - Mainz, Germany

³ University Medical Center Mainz, Rheinland-Pfalz - Mainz, Germany

Background

We aimed to compare the in-hospital mortality of ESRD patients related to different comorbidities and dialysis procedures in Germany.

Methods

We analyzed data on the patients characteristics, dialysis procedures and in-hospital outcome of ESRD patients based on ICD-code N18.5 in the German nationwide database (source: RDC of the Federal Statistical Office of the federal states, DRG Statistics 2011-2015, own calculations).

Results

Between January 2011 and December 2015, 942,833 cases of patients with ESRD (40.9% females) aged ≥ 18 years were identified and included in this analysis. The case-fatality rate of all ESRD patients in Germany was high (8.8%). Non-survivors were older than survivors (78 [IQR, 71-84] vs 73 [61-79] years, $P < 0.001$) and showed more frequently important comorbidities

including cardiovascular diseases such as heart failure (47.5% vs 26.0%, $P < 0.001$) and coronary artery disease (37.0% vs 32.8%, $P < 0.001$), but also cancer (14.5% vs 6.8%, $P < 0.001$).

In non-survivors, myocardial infarction (8.3% vs. 2.7%, $P < 0.001$), ischemic stroke (3.0% vs 1.3%, $P < 0.001$) and pulmonary embolism (1.7% vs 0.3%, $P < 0.001$) occurred more often compared to survivors. In addition, non-survivors had more often bleeding events such as intracerebral bleeding (1.2% vs. 0.2%, $P < 0.001$), gastro-intestinal bleeding (5.4% vs. 2.0%, $P < 0.001$) and consecutively, received more transfusions of erythrocyte concentrates (33.5% vs. 15.7%, $P < 0.001$) compared to survivors. Non-survivors underwent more often CPR (16.7% vs. 0.6%, $P < 0.001$) than survivors.

Interestingly, the necessity of using hemofiltration as well as hemodiafiltration were both identified as predictors of in-hospital mortality (OR 3.98 [95%CI 3.8-4.2] $P < 0.001$) and (OR 1.26 [95%CI 1.23-1.29], $P < 0.001$) using logistic regression and associated with an increased probability of in-hospital mortality in Kaplan-Meier (log-rank test: $p = 0.001$), whereas the usage of hemodialysis were associated with a reduced risk for in-hospital mortality (OR, 0.84 [95%CI 0.82-0.85], $P < 0.001$)

Conclusion

ESRD patients have a high risk for in-hospital mortality in Germany. Interestingly, while the use of hemodialysis procedure was associated with lower in-hospital mortality, the necessity of hemofiltration as well as hemodiafiltration treatment in ESRD was accompanied by higher in-hospital mortality and thus, different dialysis treatments predicted in-hospital prognosis and might reflecting hemodynamic status of ESRD patients.

#651 - Case Report

AA AMYLOIDOSIS AND RHEUMATOID ARTHRITIS AND PULMONARY EMBOLISM

Cristiana-Elena Vlad^{1,2}, Andreea Florea¹, Laura Florea^{1,2}

¹ Hospital "Dr. C. I. Parhon", Internal Medicine-Nephrology, Iasi, Romania

² Grigore T. Popa University of Medicine and Pharmacy, Internal Medicine-Nephrology, Iasi, Romania

Introduction

Amyloidosis is a clinical disorder caused by amyloid deposition that alter the normal function of kidneys and/or other tissues. Systemic amyloidosis can be classified as primary or secondary (chronic inflammatory diseases, chronic bacterial infections or neoplasms).

Case description

A 51-year-old female with a history of 23-years of rheumatoid arthritis, intermittent treated with DMARDs and NSAIDs was admitted in our clinic for swelling of the feet and ankles. The clinical examination showed lower-extremity edema, livedo reticularis on lower limbs, symmetric polyarthritis, joint deformity in hands and feet. Laboratory tests identified impaired kidney

function(creatinine= 1.97 mg/dl), urinary protein excretion= 9.3 g/24h, hypoproteinemia, hypoalbuminemia, inflammatory syndrome, anti-cyclic citrullinated peptide= 361 UI/ml(normal range<7 U/mL).

Abdominal ultrasound revealed the size of the kidneys within normal limits, while kidney biopsy found amyloidosis (Congo red staining). There were no clinical signs and laboratory findings suggestive of any other type of infectious disease or neoplasm. AA amyloidosis was diagnosed based on clinical, laboratory and anatomopathological findings. Patient was treated with anti-TNF, nephroprotective therapy and anticoagulation, but she has developed a massive pulmonary embolism, which led to her death.

Discussion

Up to 5% of patients with rheumatoid arthritis can develop amyloidosis that usually presents as nephrotic syndrome or proteinuria. The methods used to diagnose amyloidosis include: renal biopsy, rectal biopsy, hepatic biopsy, minor salivary gland biopsy and aspiration of abdominal subcutaneous fatty tissue. Congo red staining technique is the gold standard for histological diagnosis of amyloidosis. Evolution of patients may be unfavorable due to occurrence of thromboembolic complications that may lead to their death.

#701 - Case Report

IATROGENIC METABOLIC ACIDOSIS – A CLINICAL CASE

Miguel Gonzalez Santos, Adriana Bandeira, Diana Castro, Tatiana Costa Pires, Ana Rodrigues, Ana Catarina Santos, Miriam Magalhães, Alcina Ponte

Centro Hospitalar de Leiria, Leiria, Portugal

Introduction

Metabolic Acidosis is an Acid-Base imbalance frequently found in clinical practice. There are several known etiologies for this condition, not all of them necessarily pathological. The authors present here a case of Metabolic Acidosis caused by a commonly used drug.

Case description

A.R. is a 77 year-old male patient with known history of Type 2 diabetes mellitus, hypertension, dyslipidemia, hyperuricemia and renal calculi. Current medications include pitavastatin 2 mg od, acarbose 50 mg bd, carvedilol 25 mg bd, clopidogrel 75 mg od, alopurinol 300 mg od, sitagliptine + metformine 50 mg/1000 mg bd, amlodipine 10 mg od, perindopril+indapamide 8 mg/2.5 mg od. The patient was under review in Pneumology outpatient clinic for suspected silicosis. Incidentally, it was found he had a hyperchloremic metabolic acidosis, for which he was sent to the Emergency Department. Here, the acidosis was corrected with fluids and Indapamide was suspended. He was later reviewed at the Internal Medicine outpatient clinic, where it was found he maintained hyperchloremic metabolic acidosis. He was, therefore, studied as an inpatient.

From the extensive blood and urine tests performed, the main clue found was a negative urinary anion gap, indicating an extra-renal cause for the condition.

Considering the strong diagnostic hypothesis of an iatrogenic cause, the patient's regular medication was, once again reviewed. perindopril was suspended, leading to a resolution of the acid-base imbalance.

Discussion

The etiological diagnosis in a case of metabolic acidosis demands a systematic and well defined approach.

Metabolic Acidosis can be found in about 0.058% of patients under the effect of drugs, having been reported as a side effect of Perindopril in about 1.68% of patients taking this drug.

Therefore, it is demanded of the Internist to be familiar with the more common causes of metabolic acidosis, being also aware and on the lookout for less frequent causes of this imbalance.

#753 - Case Report

LERICHE SYNDROME - A RARE CAUSE OF ACUTE KIDNEY INJURY

Gonçalo Calheiros Cruz, Rita Homem, Rita Gouveia, Aura Ramos
Hospital Garcia de Orta, Almada, Portugal

Introduction

Acute kidney injury is a frequent diagnosis caused by a broad range of etiologies. It has a wide spectrum of severity and can herald great morbidity and mortality.

We present a case of acute kidney injury as a first manifestation of an aortic obstruction.

Case description

A 64-year-old man presented to the emergency department with dyspnea and anuria since the previous day. He denied other symptoms or previous episodes, had no relevant past history besides smoking (50 pack years), no regular follow-up nor medication. On physical examination, blood pressure was 125/90 mmHg, heart rate was 94 bpm. He was polypneic with a respiratory rate of 30 cycles/minute and peripheral oxygen saturation of 99% on ambient air. His skin and mucous membranes were dehydrated. Cardio-pulmonary examination was unremarkable, as was the abdomen inspection. His legs were warm, not swollen. The arterial gasometry showed a compensated non anion-gap metabolic acidosis: pH 7.357, HCO₃⁻ 16.8 Mmol/L, lactates 1.2 Mmol/L. A bladder catheter was inserted with no urine output.

Laboratory studies showed a urea level of 323 mg/dL, creatinine level 11.5 mg/dL, potassium 8.8 Mmol/L.

The patient underwent immediate hemodialysis by a central venous catheter placed in the femoral vein. During the session, worsening of the clinical status was denoted, with dyspnea, bronchospasm, altered mental status and lactic acidosis: pH 7.035, HCO₃⁻ 6.9 Mmol/L, lactate 17.5 Mmol/L. An asymmetry in the blood pressure between the upper (150/91 mmHg) and lower

limbs (75/35 mmHg) was found. Urgent CT scan showed: total thrombotic occlusion of the abdominal aorta immediately after the origin of the superior mesenteric artery superimposed on an aortic and iliac sclerocalcification, prompting an acute occlusion of the left renal artery. The patient had an atrophic right kidney and extensive collateral vessels throughout the abdomen and pelvis. While awaiting transportation to a vascular surgery unit, the patient progressed to cardiorespiratory arrest and passed away.

Discussion

This is a case of an acute-on-chronic aortic occlusion at the level of the renal arteries in a patient with exuberant calcification and collateral circulation, compatible with Leriche syndrome. Occlusion of the left renal artery in a single functional kidney (atrophic right kidney) triggered the anuric acute kidney injury. A high degree of suspicion is mandatory in every atypical acute kidney injury

#755 - Case Report

PROGRESSIVE CHRONIC KIDNEY DISEASE AND UNEXPLAINED HYPERCALCEMIA - A CASE REPORT

Roberto Calças Marques¹, Anabela Malho Guedes¹, Eduarda Carias¹, Mafalda Aveiro², Pedro Leão Neves¹

¹ Nephrology Department, Centro Hospitalar e Universitário do Algarve, Faro, Portugal

² Family Medicine, USF Ossónoba, ACES Algarve Central, Faro, Portugal

Introduction

Hypercalcemia has several known causes, with primary hyperparathyroidism and malignancy concurring to 90% of the cases. Deleterious effects of sustained high calcium levels can lead to deterioration of kidney function. Diagnosis of less common causes can be difficult and treatment should lead to normocalcemia. We report a patient referred to Nephrology due to chronic kidney disease (CKD) with insidious evolution who presented persistent hypercalcemia.

Case description

We present a case of a 69-year-old caucasian woman referred to Nephrology due to progressive CKD. She had a 2-year history of fatigue, anorexia, weight loss and generalized pruritus. Serum calcium level was noted to be persistently elevated, with a peak level of 13.4 mg/dL. Renal function was impaired with a peak serum creatinine (Pcr) of 2.4 mg/dL. BUN ranged from 80 to 93 mg/dL. 25(OH)D was low and 24h urine calcium was within the normal range. Since the PTH level and serum phosphate were normal, the initial hypothesis of secondary hyperparathyroidism was rejected in relation to hypercalcemia. A diagnosis of occult malignancy was suspected. Immunological study showed normal Igs. A thoraco-abdominopelvic CT was performed and it showed bilateral hilar and mediastinal lymph nodes with associated calcifications, some in eggshell. Angiotensin-converting enzyme (ACE) was elevated

at 98 UI/L. The patient underwent bronchoscopy and cytology in bronchoalveolar lavage was normal. Infections were also excluded. With clinical suspicion of stage 1 sarcoidosis with associated mild renal failure she was treated with corticosteroids (1mg/kg/day) with disappearance of constitutional symptoms and led to a gradual fall in calcium levels and partial recovery of renal function. Renal biopsy was considered but cancelled due to atrophic kidneys and amelioration of renal function with normocalcemia. Pcr at the last follow-up was stable at 1.2 mg/dL.

Discussion

Sarcoidosis is a multisystemic, granulomatous disease of unknown etiology. Hypercalcemia can occur in about 10-20% of patients, but it is rarely a presenting manifestation, with clinically significant hypercalcemia happening in less than 5%. The diagnosis without pulmonary symptoms is often a challenging task and should evoke suspicion in non-parathyroid-dependant hypercalcemia. Renal dysfunction could be a consequence of hypercalcemia per se, or of granulomatous infiltration. Early treatment allowed for a gradual clinical and kidney function improvement and normalization of calcemia.

#1212 - Abstract

PREVALENCE OF MULTIRESTANT BACTERIA AND RISK FACTORS IN URINARY TRACT INFECTIONS TREATED BY A HOME HOSPITALIZATION

Enrique Mira Bleda, Ana Fernández-Rufete Cerezo, Antonio Mateo López, Alicia Laso Ortiz, Encarnación Moral Escudero, José Ruipérez Ruiz

Virgen de la Arrixaca University Hospital, Murcia, Spain

Background

Describe the prevalence of multiresistant bacteria in admitted patients to the Home Hospitalization (HH) with the diagnosis of urinary tract infection (UTI) and analyze possible risk factors.

Methods

Retrospective and descriptive research of 64 patients with the diagnosis of UTI, from september 2018 to april 2019, admitted and treated by the HH of a tertiary hospital in Murcia. To get the data we reviewed the clinical histories and urine culture results. Extended-spectrum beta-lactamases producers (ESBL) were considered multiresistant bacteria. The SPSS program was used for the statistic analysis.

Results

64 patients were included with the diagnosis of UTI, 33 women (51.6%) and 31 men (48.4%) with an average age of 69. The average length of stay was 9.7 days. 17.2% (11 patients) carried a bladder catheter at the beginning of de admission and only 1 patient carried suprapubic catheter. 6 patients (9.4%) were carriers of nephrostomy and 5 (7.8%) patients needed intermittent

catheterization at home. In terms of prevalence of the main comorbidities, 25% of patients suffered dementia, 18.8% vascular encephalopathy, 57.8% arterial hypertension, 31.3% mellitus diabetes, 39.1% dyslipidemia, 14.1% heart failure and 28.1% renal insufficiency. The incidence of ESBL producers multiresistant bacteria was 48.4%; when analyzing possible risk factors we found an statistical significant relationship with nephrostomy and intermittent catheterization.

Conclusion

In the last decades, the widespread, indiscriminated and, in many cases, irresponsible use of antibiotics has caused an important increase of the resistances of the microorganisms and the appearance of multiresistant strains. In most cases, these infections require long term administration of intravenous antibiotics, so that HH is a excellent option for treat clinically stable patients at home, to avoid or shorten hospital admission. Multiresistant bacteria were isolated in almost half admitted patients at the HH. This condition was associated with two forms of urinary instrumentation: nephrostomy and intermittent catheterization, but no relationship was found with other comorbidities.

#1272 - Case Report

URACHAL CYST INFECTION: A STRANGER CAUSE OF FEVER AND ABDOMINAL PAIN.

Raquel Jaso Tejera, María Elena Casuso Sáenz, María Teresa Valiente Millán, Miriam Vieitez Santiago, Pablo González Gutiérrez, Laura Gutiérrez Fernández, Ana Isabel González-Torre González, Nuria Díez Herrán, Paloma Sanchez Junquera
Hospital de Laredo, Laredo, Spain

Introduction

Urachus is a fibrous remnant of the embryonic development. It is located into medial line in the space of Reztius. Most of the time, the diagnosis is done in childhood; a third of cases are discovered in the adulthood. Clinical findings are not specific and they can enclose abdominal pain, fever and urinary symptoms. Complications such as infection and malignancy can be appeared. Computed tomography is the best to discover complications of urachal cyst. Surgical excision is the treatment of choice to avoid re-infection and malignancy.

Case description

We present a 85 year old male, he was ex-alcoholic. Medical history disclosed high blood pressure, peptic ulcer and Billroth I operation. He recounts abdominal pain, fever and diarrhea in last months. At presentation, vital signs were unexceptional and he had appropriate tissue perfusion and hydration. On examination his abdomen was tendered in suprapubic area and right iliac space and without palpable masses. Laboratory testing was notable for a white blood cell count of 11,500/ mm³, haemoglobin 9.5 g/dL and hematocrit 28.7%. Test of blood clotting and renal function

parameters being within normal limits, polymerase chain reaction was 20.1 mg/dL. A computed tomography (CT) were requested. Abdominal CT showed an inflammatory mass in the Reztius space measuring 4,3x ,8 cm. Upper borderline bladder had a thickened and slashed area, surrounding fat was thickened. There was not adenopathies.

Blood and urine cultures was taken. Empirical antibiotic therapy with meropenem was started. Fever and abdominal pain disappeared, and PCR became normal. Cultures were negative. Antibiotic therapy was going on two weeks. Urology specialist evaluated the patient and refused surgery at those moment. CT control was request; it was demonstrated no changes. He was discharged for outpatient monitoring in urology consultation

Discussion

Urachal anomalies are unusual. In most cases the diagnosis is done in childhood. Urachal cyst is the most common urachal anomaly in adulthood. There is a wide variety of clinical manifestations; most common is abdominal pain but fever and urinary symptoms can be presented. In adults the diagnosis is a chance discovery in imaging test. Surgical excision is the treatment of choice because urachal cyst does not spontaneous recovery and to avoid malignancy. In our patient, because the age and a good clinical evolution, a conservative approach was chosen. Clinical course will determine if surgical excision is needed.

#1289 - Medical Image

EMPHYSEMATOUS CYSTITIS

Rodolfo Viríssimo Gomes, Isabel Montenegro Araújo, Inês Vieira Santos, Catarina Lameiras, João Gonçalves, João Pacheco Pereira, Manuel De Sousa, António Messias
Hospital Beatriz Ângelo, Loures, Portugal

Clinical summary

We present a 90-year old man with Alzheimer's disease admitted due to a left trochanteric fracture after a fall. He was progressing well after surgery, but had an episode of fever with immeasurable blood pressure and SpO₂ 80%; he had a bulky left thigh hematoma, pronounced signs of poor peripheral perfusion and a diffuse painful abdomen. ABG showed compensated metabolic acidosis with hyperlactacidemia and he had hemoglobin 9,9g/dl and C-reactive protein 45,93mg/dl; abdominopelvic CT revealed vesical wall pneumatosis. He was admitted at the ICU for septic shock from emphysematous cystitis and started meropenem. Despite the measures taken, he passed away the following day. Subsequently, we found it was isolated in all cultures an Escherichia coli ESBL+, a known gas producer bacteria.

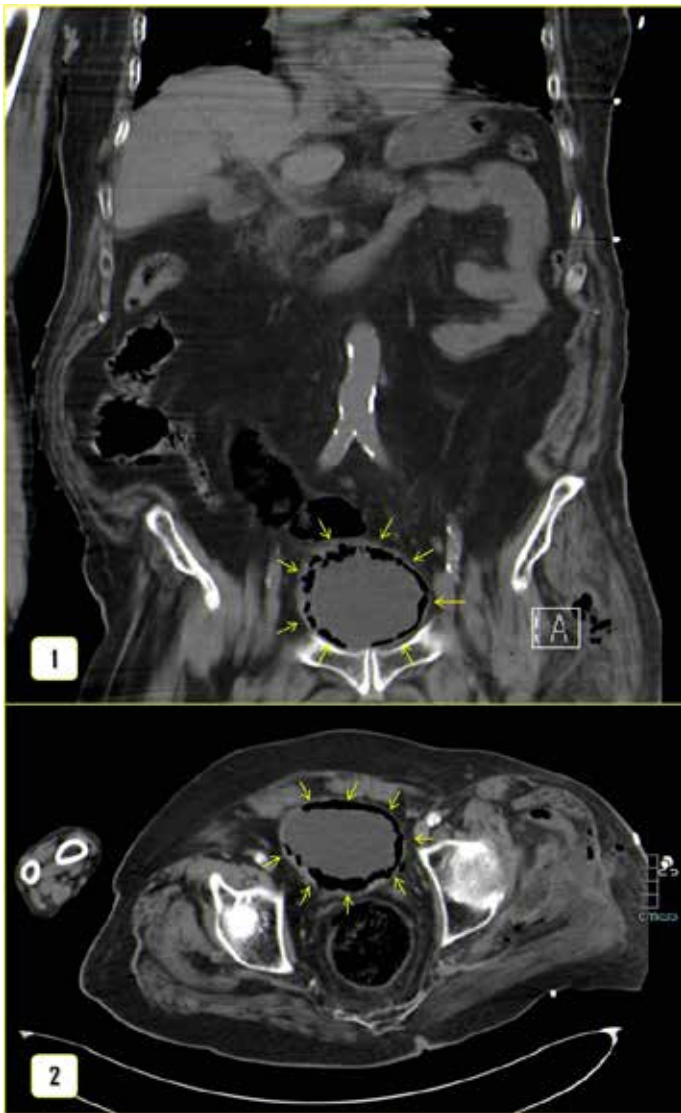


Figure #1289. Panel 1 - Frontal view; Panel 2 - Coronal view; Yellow arrows: air within the vesical wall.

#1451 - Case Report

RAPIDLY PROGRESSIVE RENAL FAILURE OF AN UNCOMMON CAUSE

Diana Ferrão¹, Tiago Alpoim², Guilherme Assis³, Luís Nogueira-Silva¹, Clara Machado-Silva¹, Pedro Ribeirinho-Soares¹, Catarina Pereira¹, Fernando Nogueira¹, José Marques¹, Jorge Almeida¹

¹ Centro Hospitalar e Universitário de São João, Porto, Portugal

² Instituto Português de Oncologia do Porto Francisco Gentil, Porto, Portugal

³ Centro Hospitalar de Trás-os-Montes e Alto Douro, Vila Real, Portugal

Introduction

Small vessel vasculitides are an heterogeneous group of rare, systemic and poorly understood diseases that induce inadequate inflammatory reactions in the wall of small blood vessels. The clinical manifestations are often nonspecific and frequently involve the kidney. When left untreated they can progress rapidly to end stage renal failure.

Case description

A 29-year-old woman, without any priors or usual medication arrives at the local emergency room complaining of asthenia and polyarthralgia of the big joints. She had no notion of any circadian pattern or relation with movement. She was medicated with tramadol and ibuprofen with no improvement of the symptoms. Six months later, she returned to the emergency room with aggravated polyarthralgia and asthenia and reduction of the urinary output in the last three days, accompanied with vomiting. Laboratory tests showed anemia with an hemoglobin level of 7.9 g/dL (cutoff <12.0 g/dL) and an acute kidney injury with a creatinine value of 2.26 mg/dL (cutoff <0.95 mg/dL) and elevated C reactive protein. The patient was diagnosed with rapidly progressive kidney failure of unknown cause and was admitted for further studies. The 24h urine collection showed a proteinuria of 1.56 g/24h with severe serum hypoalbuminemia. The autoimmune panel showed negative antinuclear antibodies with positive anti-neutrophil cytoplasmic antibodies (ANCA) anti PR3 of 139 U/L (cutoff <20 U/L), without complement consumption. The renal biopsy showed crescentic glomerulonephritis. Her kidney function kept deteriorating and she was started on methylprednisolone and cyclophosphamide (CYCLOPS protocol). In the next few days she had an impressive amelioration of the kidney function, hemoglobin level and her general clinical status. She was discharged and six months later she has normal kidney function with a proteinuria of 1 g/24h and undetectable serum autoantibodies.

Discussion

ANCA PR 3 positive vasculitides are uncommon but increasingly recognized causes of rapidly progressive kidney failure. With the appearance of safer and more effective immunosuppressants, the prognosis of this patients has largely improved. The clinical suspicion, prompt diagnosis and subsequent immediate therapy are of crucial importance in the hope for recovery of kidney function and regulation of the inflammatory process.

#1463 - Case Report

LUPUS-LIKE GLOMERULONEPHRITIS PRESENTING AS NEPHROTIC SYNDROME IN AN HIV INFECTED PATIENT WITH VISCERAL LEISHMANIASIS

Lara Câmara, Maria Teresa Piteira, Francisca Martins, Miguel Nunes, Eugénio Teófilo

Centro Hospitalar Universitário Lisboa Central, Lisboa, Portugal

Introduction

Human Immunodeficiency Virus (HIV) infection relates to various nephropathies. The prevalence of co-infections, like visceral leishmaniasis (VL), is higher in people with HIV even after the introduction of combination antiretroviral therapy (cART). Renal damage may be due to the disease, its therapy and hemodynamic disturbances. Lupus-like glomerulonephritis usually presents with significant proteinuria.

Case description

A 43-year old caucasian male was admitted to our ward with bloating, nausea and lower limb edema. He had HIV-infection since 2007 on tenofovir/emtricitabine and darunavir/ritonavir with viral suppression despite a poor immunologic status (CD4+ <100 cells/mm³), Hepatitis C Virus spontaneous clearance in 2014 and a relapsing VL under treatment with liposomal amphotericin B. Hemoglobin (Hb) was 8.7 g/L, white blood cells (WBC) 2.9x10⁹/L, platelets 125x10⁹/L and proteinuria (1980 mg/24h). Biopsies of the upper gastrointestinal tract showed Leishmania. Due to resistance to amphotericin B and nephritic proteinuria, meglumine antimoniate, atovaquone and alopurinol were started, improving WBC and platelets (5.0x10⁹/L and 289x10⁹/L), but with persisting anemia (Hb 8.3g/L). Lower limbs edema worsened and palpebral edema appeared, with decreasing glomerular filtration rate (GFR) (63mL/min/1.73m²), hypoalbuminemia (18.8g/L) and nephrotic proteinuria (3377 mg/24h). Postinfectious glomerulonephritis, infective endocarditis, Systemic Lupus Erythematosus and vasculitides were excluded. Kidney biopsy showed endocapillary proliferation, sclerotic lesions and immune deposits compatible with a lupus-like glomerulonephritis associated to HIV. The cART was adjusted to a decreased GFR to lamivudine and darunavir/ritonavir. One month later, there was a decrease of proteinuria with higher GFR and CD4+ cells. The patient was discharged with miltefosin plus atovaquone.

Discussion

After 56 months of follow-up, he has no proteinuria and GFR is 95mL/min/1.73m², CD4+ count is 665 cells/m³ with normal Hb, WBC and platelets (15.2g/L, 7.0x10⁹/L and 296x10⁹/L). HIV viral load remained suppressed during this period. There is no evidence of VL. Present literature doesn't support the use of pentavalent antimonials for VL in HIV-positive patients due to toxicity and high failure rate, but our case shows that cARV modification together with antileishmania medication had a favourable outcome on renal function as well in improving the immunologic status.

#1468 - Abstract

HYPONATREMIA IN AN INTERNAL MEDICINE WARD

Sara Almeida Ramalho, Sara Franco, João Namora Santos
Hospital Garcia de Orta, Almada, Portugal

Background

Hyponatremia is the most common electrolyte disturbance in clinical practice. However, in Portugal, studies about incidence, characteristics of hyponatremia in different contexts, such as in hospitalized patients, are still lacking. We aimed to study hyponatremia in patients admitted in an Internal Medicine ward over a period of 12 months. We intended to determine the type of hyponatremia, its etiology, clinical features and associated pathologies.

Methods

This is a descriptive, retrospective study. We identified all the patients admitted to our hospital Internal Medicine wards in 2018 with hyponatremia (serum sodium concentration <135 mmol/L). The initial value was corrected for serum glucose level. If the corrected value was normal, we considered it as a pseudo-hyponatremia and those patients were excluded from the analysis. We divided the patients in 3 groups according to the severity of hyponatremia (mild: Na+ 130-134 mmol/L; moderate: Na+ 120-129 mmol/L; severe: Na+ <120 mmol/L). Multiple variables in the 3 groups were studied and data were obtained from patients' clinical files. Statistical analysis was performed using SPSS23 statistical software.

Results

We identified 166 patients admitted in internal medicine ward from January to December 2018. 8 of them were pseudo-hyponatremias and were excluded. The mean age of the 158 patients was 79+/-10.5 years and 62 (39.2%) were male. The clinical diagnosis most frequently associated with hyponatremia were congestive heart failure, pneumonia, cystitis and chronic kidney disease. The group with moderate hyponatremia had the oldest patients (mean age 80+/-9.9 years). Independently of the severity of hyponatremia, patients were mostly euvoletic. In the mild and moderate groups, the majority of patients normalized their sodium value, while in the severe group, hyponatremia was persistent in 63.2%.

At the time of diagnosis, 64% of patients were medicated with some type of diuretic, 17.1% with selective serotonin reuptake inhibitors, 4.4% with sodium valproate, 3.2% with venlafaxine, 2.5% with tricyclic antidepressants and 34.8% with proton pump inhibitors. The in-hospital mortality was higher in the group with severe hyponatremia (18.4%).

Conclusion

Hyponatremia is frequently associated to some of the most common diseases and medications in hospitalized patients and can have prognostic consequences. To achieve a good management of hyponatremia, studying its etiology, duration and severity is crucial. In this context more studies should be performed.

#1469 - Medical Image

XANTHOLOGRANULOMATOUS PYELONEPHRITIS IN POLYCYSTIC KIDNEY

Helena Rodrigues, Catarina Reigota, Rogério Ferreira, Lélita Santos, Armando De Carvalho

Centro Hospitalar e Universitário de Coimbra, Coimbra, Portugal

Clinical summary

A 71-year-old man with a history of polycystic kidney disease came to the emergency department after an episode of lipothymia. He had a history of significant weight loss, anorexia, malaise and night sweats. He denied other symptoms. During the physical

examination he was febrile, and the abdominal examination identified a painless round mass with well-defined borders and approximately 10 cm of diameter in the right flank. Blood tests showed severe anemia (Hb 7.4 g/dL) and leukocytosis. Urine

test showed leukocyturia, but the uroculture was negative. He completed treatment with broad spectrum antibiotics without any improvement. CT was performed and showed findings compatible with the diagnosis of Xanthogranulomatous pyelonephritis.

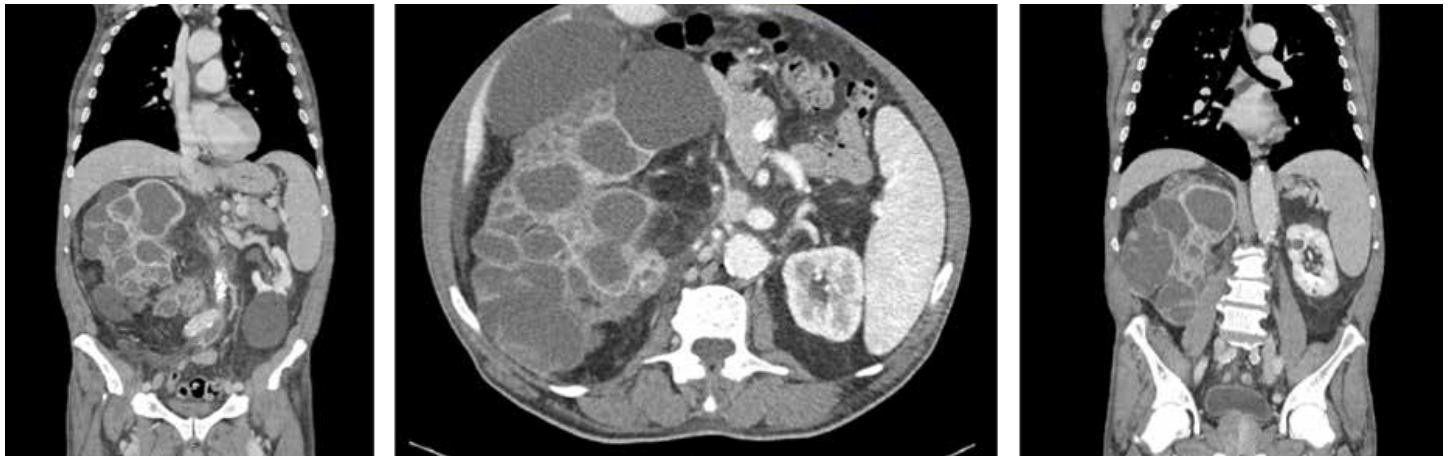

Figure #1469. CT demonstrated an enlargement of the right kidney with multiple cysts (the biggest one with 12 cm, another one with hemorrhagic content), with dilatation of the calyces and some calculus.

#1524 - Case Report

WHEN GENETICS COMES FIRST: A RARE CASE OF HYPOKALEMIA

Inês Ladeira Figueiredo, Cristina Maria Duarte, Fernando Teixeira Costa, Luísa Fraga Fontes

Hospital Cuf Descobertas, Lisbon, Portugal

Introduction

Sometimes symptoms that seems relatively ordinary in some patients, should be considered with more detail in others, specially when we take into account the age at they occur.

The authors present a case of a young man who came to the ER with hypokalemia associated with mild symptoms, which was easy to reverse but difficult to maintain in normal values. With more investigation the team achieved a rare diagnosis which became more obvious when they find out that there was a history of consanguinity in his family.

Case description

A 21-year-old man with consanguineous parents, came to ER with muscle contractures of hands, arms and face with 2 hours of evolution. He had a normal blood pressure and a normal physical exam. Blood tests revealed hipokalemia 2.7mmol/L and hipomagnesemia 1.8mg/dl. During his hospitalization he was submitted to kalemia correction. More investigation revealed a normal thyroid function, normal serum cortisol, a significant increase of plasmatic renin associated with normal aldosterone and ACTH. Despite of the normal urinary ionogram in the occasional urine sample, the 24 hours urine collection showed an increase of sodium, potassium and chloride with a light increase of urinary cortisol. The overnight 1 mg dexamethasone suppression test was normal. Patient also did a renal ultrasound

with no pathological changes. Nephrologist observed the patient and, considering hipokalemia, increase of plasmatic renin and normal blood pressure in a young man with a history of two similar episodes in the past, Bartter syndrome was the most likely diagnosis and the patient was discharged from hospital medicated with oral potassium chloride and indomethacin. The genetic tests were in course.

Discussion

When we are searching for a diagnosis, we need not only to consider the symptoms and clinical presentation, but we also can not forget to collect a complete anamnesis, speaking with the patient and his relatives. Sometimes past clinical history and family history are important to consider different hypothesis, and to achieve the right diagnosis. Here we have a good exemple were genetics comes first specially when we are dealing with young patients.

#1637 - Case Report

MINIMAL CHANGE DISEASE AND ACUTE TUBULAR NECROSIS ASSOCIATED WITH DICLOFENAC USE

Nadezda Sersnova^{1,2}, Aiga Vasilvolfa^{1,3}, Veronika Mesecko^{1,2}, Anna Popova^{1,3}, Viktorija Kuzema^{1,2}, Aivars Petersons^{1,2}

¹ Paul Stradins Clinical University Hospital, Riga, Latvia

² Riga Stradins University, Riga, Latvia

³ University of Latvia, Riga, Latvia

Introduction

Non-steroidal anti-inflammatory drugs (NSAIDs) are widely used to treat acute or chronic pain worldwide. Renal side-effects caused

by NSAIDs can be acute kidney injury (AKI), acute interstitial nephritis, electrolyte and fluid disturbances, papillary necrosis, nephrotic syndrome and chronic kidney disease. We describe a patient with nephrotic syndrome and acute kidney injury due to a combination of minimal change disease (MCD) and acute tubular necrosis (ATN) caused by diclofenac use.

Case description

60-year-old man was admitted to hospital with dyspnea and ankle edema, that occurred approximately 1 month ago. Patient's medical history was unremarkable, except for hip osteoarthritis and arterial hypertension. He used diclofenac 150-300 mg daily for the last 2 months to relief hip osteoarthritis caused pain. On admission serum creatinine was 575 $\mu\text{mol/l}$ (N 62-115 $\mu\text{mol/l}$) with estimated glomerular filtration rate 7.9 ml/min/1.73m³. Urine strip analysis revealed proteinuria 5 g/l, leukocytes and epithelial cells. Estimated 24-hour proteinuria was 12.7 grams. Serum and urine electrophoresis were in normal ranges. Kidney biopsy was performed. Light microscopy showed acute tubular necrosis and glomeruli without histological lesions. Immunofluorescence microscopy negative for immunoglobulin, complement or light chain deposits. Electron microscopy revealed diffuse effacement of podocyte foot processes. Treatment with glucocorticosteroids was started. After 6 weeks partial remission was achieved: serum creatinine level decreased from 575 to 152 $\mu\text{mol/l}$ and estimated 24-hour proteinuria from 12.7 to 1.1 g.

Discussion

There are only a few reports about ATN and MCD with acute kidney injury caused by NSAID use. NSAIDs may cause kidney damage by changing intrarenal hemodynamics or by changing in immunological response. Both mechanisms are associated with arachidonic acid (AA) metabolism. Inhibition of cyclooxygenase (COX) activity lead to decreased renal prostaglandin synthesis and development of renal vasoconstriction which can cause AKI. Moreover, decreased activity of COX may enhance AA metabolism by lipoxygenase pathway, which may cause increased production of leukotrienes leading to activation of T helper lymphocytes. Activated T helpers affect glomerular-capillary barrier and release lymphokines causing nephrotic syndrome. We highlight that NSAIDs should be used with caution because of wide profile of side effects.

#1705 - Case Report

FAMILIAL RENAL GLUCOSURIA (FRG): A RARE RENAL TUBULAR DISORDER

Carolina Paiva, Helena Greenfield, Teresa Santos

Hospital Pedro Hispano, Matosinhos Local Health Unit, Matosinhos, Portugal

Introduction

Familial renal glucosuria (FRG) is a rare renal tubular disorder characterized by persistent isolated glucosuria in the absence

of hyperglycemia. It is caused by mutations in the SLC5A2 gene that codes for the co-transporter SGLT2, which is responsible for tubular reabsorption of the bulk of filtered glucose.

Case description

The authors report the case of a 39-year-old woman with no relevant pathologic history, referred to nephrology consultation due to persistent glucosuria during pregnancy with normal blood glucose levels. The patient was asymptomatic, hemodynamically stable, and presented no objective signs of dehydration. The diagnostic study showed, no changes in fasting glucose, renal function or electrolyte levels fasting glucose 80 mg/dL, HbA1c 5.1%, creatinine 0.7 mg/dL, Na + 140 mEq, K + 4.0mEq, calcium 9.9 mg/dL, phosphorus 2.8 mg/dL; urinalysis with 500 mg/dL of glucose; normal 24 hour renal sodium excretion (120 mEq/24h) and increased glucose excretion (43.41g/4h); normal plasma renin and aldosterone levels (4.0 ng/dL and 1.10 ng/dL respectively). Owing to these results, a genetic study of mutations of the SGLT2 gene was requested. The pathogenic heterozygote variants c.898C>T (p.Arg300Cys) and c.1409T>C (p.Val470Ala) on the SLC5A2 gene were detected. Direct relatives were contacted for genetic counselling and to search for the mutation. The patient was eventually lost to follow-up. This case reports a patient with glucosuria, initially interpreted in the physiological context of pregnancy that persisted over time and was not associated hyperglycemia. These features raised the clinical suspicion of FRG that was confirmed by genetic testing.

Discussion

The authors wish to alert to this rare entity that should be considered in the differential diagnosis of these patients since it has a benign prognosis and does not require specific treatment.

#1742 - Case Report

A NOT SO OBVIOUS CAUSE OF ACUTE KIDNEY INJURY

Sara Cardoso Fernandes¹, Mário Ferraz¹, André Goulart², Catarina Morais¹, João Lopes¹, Eunice Patarata¹, Claudia Mihon¹, António Panarra¹

¹ Hospital Curry Cabral - Centro Hospitalar Universitário Lisboa Central, Lisboa, Portugal

² Hospital Santo Espírito da Ilha Terceira, Lisboa, Portugal

Introduction

Acute kidney injury (AKI) is defined as an abrupt deterioration of renal function. It is a frequent condition in patients with multiple comorbidities. Since AKI has multiple etiologies, the diagnostic approach must be thorough in order to exclude some of the most common precipitants as well as rarer causes.

Case description

The authors present the case of an 87-year-old female with previous history of hypertension, degenerative osteoarthritis and

depression, who was admitted to the hospital with a one-week history of pain in the chest and left arm, aggravated by movement and alleviated by nonsteroidal anti-inflammatory drugs (NSAIDs) therapy. She had no other symptoms or remarkable signs at physical examination.

Laboratory evaluation showed hyperkalemia and increased levels of blood urea nitrogen and creatinine, in a patient with previous normal renal function. Renal ultrasound showed no signs of obstruction. During hospitalization, and in spite of adequate urine output and NSAID sevicion, there was no evidence of renal function recovery. Therefore, she underwent a careful investigation that revealed normocytic normochromic anemia and high erythrocyte sedimentation rate (ESR). Serum protein electrophoresis showed an increased beta 2 fraction. Serum calcium levels were within the normal range. Further investigation noted raised levels of lambda free light chains and kappa/lambda ratio approached zero. Serum immunofixation confirmed monoclonal gammopathy. 24-hour urine collection showed nephrotic-range proteinuria and positive Bence-Jones protein. Bone marrow examination was performed with a marrow plasmocytosis higher than 40%, confirming the diagnosis of lambda free light chains multiple myeloma with poor prognosis (beta-2 microglobulin 22.2 mg/L). No lytic lesions were found in the skeleton radiograph. This case had an unfavourable outcome, since the patient died from pulmonary infection before starting chemotherapy.

Discussion

With this case, we aim to raise awareness for the importance of excluding less frequent causes of AKI, even when an obvious precipitating factor, such as nephrotoxic drugs, is present. Additionally, we describe an atypical presentation of multiple myeloma: one occurring in a female patient without evidence of hypercalcemia (a complication that affects up to 30% of patients) or lytic lesions (which are present in 90% of patients throughout the course of the disease).

#1786 - Case Report

MONOCLONAL GAMMOPATHY OF RENAL SIGNIFICANCE (MGRS): EARLY DIAGNOSE LEADS TO EARLY TREATMENT

Leila Duarte, Mónica Palma Anselmo, João Madeira Lopes
Hospital Santa Maria - CHULN, Lisboa, Portugal

Introduction

In AL amyloidosis, amyloid fibrils are derived from κ or λ monoclonal light chains synthesized by a clonal population of plasma cells in the bone marrow. It can affect almost any organ or tissue, being the kidney the most frequent organ involved, usually presented as nephrotic syndrome. Recently has been described a new entity characterized by organized or non-organized immunoglobulin deposits in the kidney with no bone marrow expression of plasma cells known as monoclonal gammopathy of renal significance (MGRS).

Case description

A 61-year old man, with history of type 2 diabetes mellitus, presented with 3 month complain of significant edema of the lower limbs, increased abdominal size and since the previous two weeks periorbital and upper limbs edema. Additionally, there was a reference of anorexia and 10 Kg weight loss in two months before of lower limbs edema occurred.

The patient presented BP: 84/45 mmHg; HR: 86 bpm, anasarca with non-pitting edema and orthostatic hypotension. There was no palpable adenomegaly nor hepatosplenomegaly.

Blood tests revealed hemoglobin: 14.1 g/dL; WBCs 9260/ μ L; platelets: 538000/ μ L, creatinine 0.7 mg/dL, albumin: 1.6 g/dL, total cholesterol: 325 mg/dL; triglycerides: 406 mg/dL; INR 1,1; aPTT: 27,0"; LDH 235 U/L, CRP: 0,04 mg/dL, NT proBNP: 3378 ng/L. Urine examination showed proteinuria of 19.8 g/24h and λ Bence Jones protein. Kidney biopsy showed amyloid deposits in Congo red-stained in which amyloid has an orange-red appearance under light microscopy, producing apple-green birefringence under polarized light. It was possible to identify λ monoclonal light chain in the glomerulus mesangium, but the search of IgA, IgG, IgM, C1q, C3 and C4 and κ light chain were negative, leading to renal AL amyloidosis diagnosis. Bone marrow examination (aspiration and bone biopsy) didn't show any odd result, not identifying a clonal population of plasma cells. It was possible to reach the diagnosis of MGRS.

The patient did Cy-Bor-D treatment. Symptomatic hypotension was a major issue managed with the use of albumin infusion and high dose IV diuretics until some improvement in edema occurred and able the patient to stand up.

Discussion

Our case of MGRS illustrates the difficulty in managing supportive care treatment. The diagnosis of this entity, in this case with monoclonal λ light chain deposition in the kidney with no bone marrow expression of plasma cells, allows an early treatment, trying to avoid the progression of the hematologic and renal disease.

#1787 - Case Report

STAUFFER'S SYNDROME VARIANT AS A FIRST PRESENTATION OF RENAL CELL CARCINOMA – A CASE REPORT

Diana Vieira Castro¹, Adriana Bandeira¹, Miguel Gonzalez Santos¹, Amália Pereira¹, Mariana Malheiro², Alcina Ponte¹

¹ Centro Hospitalar de Leiria, Leiria, Portugal

² Hospital de Cascais Dr José de Almeida, Cascais, Portugal

Introduction

Renal cell carcinoma is a heterogeneous group that account for 3% of all cancers and it is more common in males with 60-70 years old. The prevalence of paraneoplastic syndromes in renal cell carcinoma is higher than 20% and paraneoplastic manifestations may be the initial clinical presentation in a substantial proportion

of cases. Stauffer's syndrome was first described in 1961 and it is a paraneoplastic manifestation of renal cell carcinoma with hepatic dysfunction (intrahepatic cholestasis) in absence of liver metastases. In this case report, we will discuss a case of a man with Stauffer's Syndrome variant as the initial presentation of Renal Cell Carcinoma.

Case description

We describe a 65-year-old male with a 6-months history of anorexia without weight loss, fatigue, night sweats and occasional pruritus without jaundice. Laboratory tests showed a slight prolongation of prothrombin time and the liver function tests showed an elevated gamma-glutamyltransferase with 236 U/L (normal <55) and an elevated alkaline phosphatase with 695 U/L (normal 30 – 120) - intrahepatic liver cholestasis. Imaging studies and biopsy showed a clear cell Renal Cell Carcinoma without metastasis. Less than one year after right nephrectomy he was diagnosed with bilateral pulmonary metastasis. The patient maintained elevated transaminases.

Discussion

Classically Stauffer's syndrome is characterized by intrahepatic cholestasis, thrombocytosis, prolongation of prothrombin time and hepatosplenomegaly in absence of jaundice. However, some authors consider a variation of Stauffer's syndrome in which patients presented additionally with hyperbilirubinemia, jaundice or, just like our case report, pruritus. This variant appear to have a similar etiology, therapeutic and prognosis. The syndrome's pathophysiology is poorly understood but an association has been made with high levels of inflammatory interleukin-6 and paraneoplastic manifestations in Renal Cell Carcinoma. Usually symptoms and analytical features normalize after tumor surgical resection and the persistence or recurrence of hepatic changes are associated with a persistent disease or metastasis and a worse prognosis.

#1788 - Case Report

PROSTATE CANCER – WHAT A FEVER!

Maria Inês Santos, Marisa Brochado, Helena Vieira Dias

Hospital Distrital de Santarém, Santarém, Portugal

Introduction

Fever of unknown origin (FUO) is one of the most challenging clinical diagnosis in medicine, despite the modern diagnostic tools and advanced therapeutic possibilities.

It is well-know that cancer can cause fever, and malignancy accounts for up to 25% of cases of FUO.

Although FUO is most common in lymphomas and leukemias, it can occur in solid tumors.

Prostate cancer is the second most commonly occurring cancer in men worldwide and the fourth most commonly occurring cancer overall.

Case description

A 50-year-old male, with history of hypertension, comes into the emergency department (ED) complaining of increasing fever and myalgias with 3 days of evolution. He had no other complaints; his physical examination was completely innocent and the exams performed on the ED only showed a slight increase of the inflammatory blood markers.

He was admitted into the Internal Medicine department for investigation. During the first days in the department, even though a large spectrum antibiotic was initiated (doxycycline), the patient kept having fever without any other complaints, physical signs or symptoms. On the sixth day of admission, the fever ceased but the patient started to complain of a painless lump on his left inguinal region. A full study of FUO causes was made (infectious, neoplasms, non-infectious inflammatory diseases and miscellaneous conditions), as well as an ultrasound to the left inguinal region and a lymph node biopsy. All the results were negative with the exception of an elevated PSA level (13.96 ng/mL) on the blood work.

The patient was referred to the Urology department and the digital rectal examination revealed an increased prostate. A prostatic biopsy was made and revealed a Gleason score 7 (3 + 4) adenocarcinoma in 30% of the sample. Computerized tomography scans and bone scintigraphy showed no metastases. Patient was submitted to a successful transurethral resection of the prostate (TURP).

Discussion

A thorough examination and study of a patient with FUO is crucial. In spite of the fact that fever is rare symptom as a presentation of prostate cancer, we should always consider it since it is the second most commonly occurring cancer in men worldwide and the incidence increases with age.

Prostate cancer, in most cases, when diagnosed and treated in its early stages (localized disease) has a 5-year survival rate of nearly 100%.

#1836 - Medical Image

CALCIFIED UTERINE MYOMA – AN INFREQUENT RADIOLOGIC FINDING

Filipa Taborda, Maria João Lobão

Hospital de Cascais, Cascais, Portugal

Clinical summary

A 72-year old woman, with history of recurrent urinary tract infections (UTI), is brought to the Emergency Room with recent complaints of altered mental status, oliguria, groan and food refusal. At the physical examination she presented a Glasgow Coma Scale of 9, hypotension, tachycardia and a stiff, painless, palpable mass in the hypogastrium. Laboratory evaluation showed elevated inflammatory parameters and renal dysfunction, with a pathologic urine sediment. Empiric antibiotic therapy was initiated assuming urosepsis. Abdominal radiogram exhibited a radio-

opaque, rounded image in the pelvis, with a popcorn calcification pattern. The patient had a previous uterine ultrasound suggesting calcified myoma, which should be considered a risk factor for UTI due to possible bladder compression.

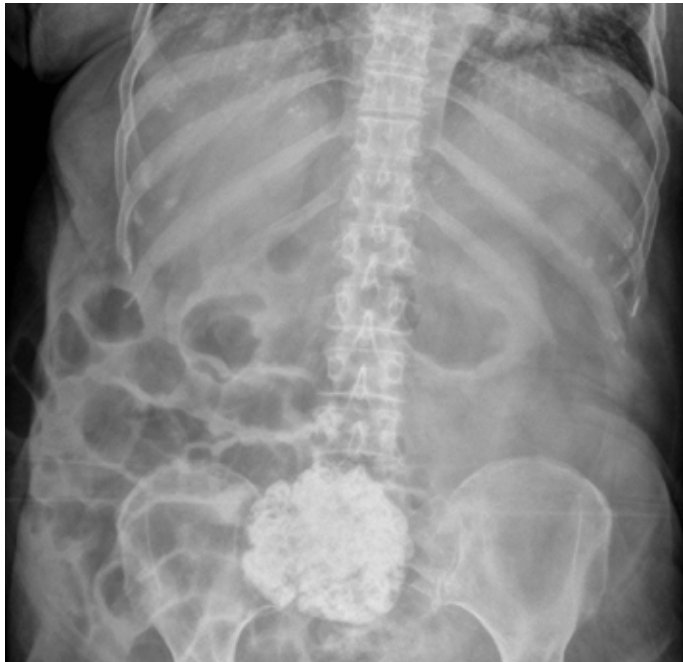


Figure #1836.

#1895 - Abstract

RISK FACTOR ANALYSIS IN PATIENTS WITH OPPORTUNISTIC INFECTIONS AFTER KIDNEY TRANSPLANTATION

Lizete Klavina¹, Kristaps Rancans¹, Ieva Ziedina^{1,2}

¹ Rīga Stradiņš University, Rīga, Latvia

² Pauls Stradiņš Clinical University Hospital, Rīga, Latvia

Background

Opportunistic infections (OI) are a common problem in patients after kidney transplantation due to immunosuppression. These infections can influence patient's morbidity and mortality, therefore it is crucial to consider the most appropriate immunosuppression regimen.

Aim of the research was to assess the frequency and types of opportunistic infections among transplanted patients in association with immunosuppressive therapy.

Methods

This was a retrospective study based on analysis of patient's medical histories from 2010 till 2015. Prevalence of OI was determined. Then patients were divided into 3 groups according to their calcineurin inhibitor (CI) levels (normal, decreased or increased), measured in three consecutive years. The prevalence of OI was determined in association with these groups and leukopenia (leukocytes <4000/mm³). Immunosuppressants were analyzed separately as well. Obtained data were analyzed in IBM SPSS Statistics 24.0.

Results

Data of 106 patients aged 21 to 73 were analyzed. At least one OI was observed in 27 patients (25.5%) that included BK polyoma virus (n=3), Pneumocystis jirovecii (n=3), Candida spp. (n=10), Herpes simplex virus-1 and -2 (n=3), acute Cytomegalovirus (n=10) and Varicella zoster virus infections (n=4). 6 patients (22.2%) had several OI. The age of patients did not show statistically significant impact on the incidence of OI (53.5 ± 2.5 with OI; 49.0 ± 1.3 without OI), p=0.071.

Neither type of CI (cyclosporin or tacrolimus) nor their levels showed statistically significant association with OI. The doses of glucocorticoids and antiproliferative medications were without significant difference among patients (p=0.436 and p=0.184 accordingly).

Prevalence of OI were significantly higher in patients with leukopenia (n=7; 53.8%) than others (n=20; 21.5%), p=0.019. Leukopenia was observed in 13 patients (12.3%), from which all had lymphopenia (<1.0 × 10⁹/l), 12 – neutropenia (<2.0 × 10⁹/l). All the OI cases were observed in moderate, severe or very severe grades of lymphopenia and neutropenia. Patients with mild neutropenia and lymphopenia did not develop OI.

Conclusion

The prevalence of opportunistic infections is not associated with the choice of calcineurin inhibitor or their levels in blood, but with patients' individual reaction to immunosuppressive therapy in the form of leukopenia.

#1919 - Case Report

NEPHRITIC SYNDROME AND ANCA-POSITIVE VASCULITIS – A CASE REPORT

Mariana Silva¹, Cátia Quina¹, Daniela Meireles², Inês Rua¹, José Garcia¹, Teresa Amaral¹

¹ Santa Joana Family Health Unit, Aveiro, Portugal

² Baixo Vouga Hospital Center, Aveiro, Portugal

Introduction

The nephritic syndrome is defined by hematuria, proteinuria and any of the following: edema, hypertension, elevation of creatinine and oliguria. It has a clinical diagnosis, but sometimes a renal biopsy is used. Its causes may be primary or secondary and the treatment and prognosis depend on its etiology. One of the known causes is vasculitis, which triggers an inflammatory process of blood vessels and can be classified according to the presence of antibodies against neutrophil cytoplasm (ANCA). This is usually positive in the microscopic polyangiitis and Wegener's granulomatosis.

Case description

A 77-year-old female, independent, included in a nuclear family, phase VIII of the Duval cycle, middle class, with a history of dyslipidemia and osteoarticular pain and osteoporosis, under atorvastatin 10mg, trazodone 50mg and irregular intake of NSAIDs, without allergies. The patient comes to a "check-

up" appointment in primary health care (PHC) with blood test that shows normocytic normochromic anaemia and creatinine elevation, conditioning renal failure. Objectively, TA 169/96mmHg, with no other changes, such as lower limb edema. Complementary exams were requested, of which urine summary showed hematuria; microalbuminuria of 303.64 mg/L and renal and bladder ultrasound showing renal sinuses with simple vascular interfaces, without other alterations. Due to the presence of nephritic syndrome and the glomerulonephritis hypothesis, ACE inhibitor was started and a Nephrology appointment was requested. After the appointment, the etiologic hypothesis of acute interstitial nephritis to the NSAID was considered and an analytical study was requested, and then hospitalized for an echogenic biopsy. The new blood tests showed increased SV and pANCA positive, thus making more likely the hypothesis of an ANCA vasculitis myeloperoxidase subtype (MPO), awaiting the histological result.

Discussion

Clinical suspicion and objective examination are the family physician's strongest weapons, allowing the detection of nephritic syndrome, avoiding diagnostic and therapeutic delay. This case demonstrates that it is important to demystify the concept of "check-up appointment", encourage people to come to PHC in such a way as to prevent excessive use of unnecessary medication and, if necessary, screening for secondary hypertension and requiring referral hospital care.

#1956 - Case Report

RENAL INFARCTION - AN UNCOMMON ENTITY

Madalena Sousa Silva, António Carneiro, Isa Silva, Luís Pereira, Filipa Tabora, Ana Paula Antunes, Ana Boquinhas
Hospital de Cascais, Cascais, Portugal

Introduction

Renal infarction is an uncommon entity, usually associated to elderly male patients and most commonly caused by cardioembolic phenomena or atheromatosis. High clinical suspicion is essential to the diagnosis that is confirmed by contrast-enhanced CT scan or magnetic resonance imaging with gadolinium. The treatment depends on the cause.

Case description

We present the case of an 84-year-old male with previous history of acute myocardial infarction, hypertension, auricular fibrillation under anticoagulant (AntiXa), and dyslipidemia. The patient was brought to the emergency department with nausea, vomiting and generalized malaise that had started two days before. On admission he was hypertensive and the abdomen was tender on the left quadrants. The complementary study revealed acute renal injury with an eGFR 47 mL/kg/1.72m², an urine analysis with proteinuria (+) and haemoglobinuria (+). He also presented

with hypertransaminasemia and lactate dehydrogenase (LDH) elevation. All the other liver function parameters were within the range of normal. He was admitted under the diagnostic hypothesis of hepatitis. During the hospitalization, he was hemodynamically stable with no remarks on examination but there was cytolysis aggravation with an increasing LDH value. The abdominal ultrasound didn't reveal any significant alterations, so an abdominal angioCT was performed that showed hypoperfusion of the left kidney with oedema of the surrounding tissue that suggested renal infarction. It also emphasized an extensive atheromatous plaque in all the abdominal aorta and renal arteries. The diagnosis of renal infarction was assumed and he repeated an angioCT of the urinary tract that showed occlusion of the posterior branch of the left renal artery by atheromatous plaque. The patient was treated with low weight molecular heparin and then switched to acenocumarol with an improvement on hepatic and renal function.

Discussion

This clinical case emphasizes the importance of this entity, that, not having concrete features either clinically nor laboratorially, it's easily underdiagnosed. It is important to be aware of this entity to properly treat the patient and avoid future complications.

#1999 - Case Report

RENAL ATTR AMYLOIDOSIS OVERLAPPED TO IGA NEPHROPATHY: PRESENT AND FUTURE CHALLENGES

Pedro Vieira¹, Andreia Póvoa¹, Paulo Costa¹, Rita Fernandes¹, Ana Rocha^{2,3}, Andreia Campos^{2,4}, Josefina Santos^{3,4}, José Ramón Vizcaíno⁵, Luísa Lobato^{2,3,4}

¹ Department of Internal Medicine, Hospital Sousa Martins, ULS Guarda, Guarda, Portugal

² Unidade Corino de Andrade, Centro Hospitalar Universitário do Porto, Porto, Portugal

³ UMIB, Instituto de Ciências Biomédicas Abel Salazar, Universidade do Porto, Porto, Portugal

⁴ Department of Nephrology, Centro Hospitalar Universitário do Porto, Porto, Portugal

⁵ Department of Anatomic Pathology, Centro Hospitalar Universitário do Porto, Porto, Portugal

Introduction

Hereditary transthyretin amyloidosis (h-ATTR) is an autosomal dominant disease characterized by multisystem deposition of an ATTR fibrils. Its principal manifestations are neuropathy and cardiomyopathy. Progressive renal ATTR amyloid deposition is associated to proteinuria and kidney insufficiency. IgA nephropathy has been reported in association with AA or AL amyloidosis in a small subset of patients. We report a unique case of IgA nephropathy co-occurring with glomerular ATTR amyloidosis in a young patient heterozygous for the mutation in TTR gene V30M, c.148G>A (p.Val50Met).

Case description

A 28-year-old woman was admitted for renal biopsy motivated by microscopic hematuria and mild proteinuria for the past 2 years; she had difficult-to-treat hypertension. Renal pathology revealed IgA nephropathy. Her mother was deceased at 40's with a history of neuropathy and nephrotic syndrome and a great-aunt had amyloid nephropathy progressing to dialysis at 70's; both were carriers of the TTR gene V30M mutation.

At 34 year-old, eGFR suddenly decreased to 44 mL/min and a second biopsy showed a mesangial proliferative glomerulonephritis associated with IgA deposits, extensive tubular atrophy and glomerular amyloid deposits. One year later, after a full-term pregnancy, kidney function deteriorated and the patient started dialysis. Now, 5 years after evidence of renal amyloidosis, she still hasn't developed other ATTR amyloidosis symptoms, neurophysiological and cardiac studies do not support disease.

Discussion

Recently, adding to liver transplantation, anti-amyloid pharmacological agents were developed to delay neurological impairment in h-ATTR. The TTR stabilizer tafamidis, the siRNA silencer of TTR gene patisiran and the antisense oligonucleotide inotersen, represent approved indications specifically for neuropathy. In this particular case, there is no evidence of neuropathy or cardiomyopathy, which might limit its use.

However, while this patient is a candidate to renal transplant, the usual aggressive progression of ATTR amyloidosis might contribute to a potential renal transplant failure.

Conclusion: In this case, ATTR amyloidosis is limited to the kidney. The IgA nephropathy association brings new challenges for this patient. There is a high unmet clinical necessity for new or combined therapies to treat amyloid nephropathy. In our perspective, the most feasible and conservative approach for this patient would be an isolate renal transplantation followed by tafamidis.

#2024 - Abstract

COMMUNITY ACQUIRED PYELONEPHRITIS IN EMERGENCY DEPARTMENT OF A PRIVATE HOSPITAL IN NORTH PORTUGAL

João Ananias Gonçalves, Rui Barros, Luis Magalhães, Marli Cruz, António Carneiro

Luz Arrábida Hospital, Vila Nova De Gaia, Portugal

Background

Urinary tract infections (UTI) are among the most prevailing infections recurrence to primary care and emergency departments. The infection of the kidney/upper urinary tract is called pyelonephritis, which is a potential severe disease. Population bases studies are lacking.

Methods

Retrospective recollection of clinical and laboratorial data of patients admitted in the emergency department in which a

diagnosis of UTI has been made, between January 1st and July 27th, 2016. Patients with upper UTI was selected. Descriptive analysis of population, microbiology and antibiotic susceptibility has been made.

Results

Of 1356 patients, 824 were confirmed as having an UTI, 128 of these as having pyelonephritis. In the pyelonephritis group 73% were women with average age of 54, and 10% were health-care associated. Urine microbiology analysis was processed in 84%, with a pathogen identified in 64% (n 82). E. coli was the most common (77%), followed by Enterococcus faecalis (5%). E.coli showed high susceptibility to all B-lactams (> 85%) (except ampicillin 63% and 1st generation cephalosporins 42%), quinolones (>85%) and carbapenems (100%). Regarding all pathogens, overall susceptibility rates were 59% for ampicillin, 82% for amoxicilin/clavulanate, 46% for 1st generation cefalosporins, 91% for 2nd and 3rd generation cefalosporins, 90% for quinolones and 96% for carbapenems.

Conclusion

This study shows that the agents causing UTI in the population presenting to our hospital, are Enterobacteriaceae, mainly Escherichia coli. On the other hand, the susceptibility to B-lactams and quinolones was high, with almost all organisms identified being susceptible to the major first line antibiotic options. Considering that most of the patients in this study presented with non-healthcare related pyelonephritis probably shows a good relationship with real community acquired upper UTI in our population in north Portugal. Community bases studies are important and should be repeated periodically and for each region, to allow a more accurate precision in empiric antibiotic prescription.

#2035 - Abstract

COMMUNITY ACQUIRED URINARY TRACT INFECTIONS PRESENTING AN EMERGENCY DEPARTMENT OF A PRIVATE HOSPITAL IN NORTH PORTUGAL

João Ananias Gonçalves, Rui Barros, Marli Cruz, Luis Magalhães, António Carneiro

Luz Arrábida Hospital, Vila Nova De Gaia, Portugal

Background

Urinary tract infections (UTI) are amongst the most prevailing infections referred to primary care and emergency departments. Growing resistance patterns, have become a major problem regarding that empiric treatment is still the standard of care. Most studies in UTI epidemiology are based on laboratory and microbiology records. Data based on real population evaluations are lacking. This study aims to analyse community acquired UTI epidemiology, in patients admitted in our emergency department.

Methods

Retrospective analysis of all patients admitted in the emergency department with the diagnosis of UTI between January 1st and July 27th 2016. We accessed clinical and laboratorial data. Then a descriptive analysis of population, microbiology and respective antibiotic susceptibility was made.

Results

Of 1356 patients, 824 were identified as having an UTI. Most were women (90%; n 742), and the average age was 47. Lower UTI was the most prevalent diagnosis (83%), followed by pyelonephritis 16% and prostatitis 1%. Complicated UTI was present in 3.5% and 2.5% were health-care associated UTI. Urine microbiology analysis was processed in 54% (n 447), with an identified pathogen in 37% (n 305). The most common were *Escherichia coli* (78%), *Staph. saprophyticus* (5.9%), *Proteus mirabilis* (5.6%) and *Klebsiella pneumoniae* (4.3%). *E.coli* showed high susceptibility to all B-lactams (> 90%) (except ampicilin 60% and 1st generation cephalosporins 45%). Overall susceptibility rates were only 57% for ampicillin 88% for amoxicilin/clavulanate and nitrofurantoin, 50% for 1st generation cephalosporins, 93% for 2nd generation cephalosporins, 96% for 3rd generation cephalosporins, 80% for TMP-SMX, 91% for ciprofloxacin and 99% carbapenems.

Conclusion

This study shows that the agents causing UTI in our population, are Enterobacteriaceae, mainly *Escherichia coli*. The susceptibility rate to the major first line antibiotic prescriptions was high. Considering that most of the patients in this study presented with non-complicated, non-healthcare related UTI, this probably shows a good connection with community acquired UTI in our population in north Portugal. Community bases studies are important and should be repeated periodically for each region, allowing a more accurate precision in empiric antibiotic prescription.

#2064 - Abstract

BLADDER CATHETERIZATION IN INTERNAL MEDICINE DEPARTMENT

Luís Teles, Elsa Meireles, Ermelinda Gonçalves, Manuela Alves
Internal Medicine Department Centro Hospitalar de Entre Douro e Vouga,
Santa Maria Da Feira, Portugal

Background

Bladder catheterization is the main risk factor associated with urinary tract infection and it represents the most frequent health care associated infection. Recommendations for urinary catheterization in newly hospitalized patients are inconsistent and unclear. It's estimated that 30% of the vesicle catheters are improperly placed.

The main objective focused on the evaluation of appropriate urinary catheterization and the study was based on clinical records, relatively to bladder catheterization on the admission, during hospitalization and at the discharge time of the internal medicine department.

Methods

Authors studied retrospectively, based on a non-probabilistic sample of accidental type, all patients admitted to the internal medicine department in the sunday residence, from January to December. Were included patients with medical indication of bladder catheterization which was maintained for more than one day.

Results

Results show that from the sample of patients studied (389) were included 158. It was considered that bladder catheterization was indicated in: need for prolonged immobilization (instability of the chest or lumbar spine, multiple traumatic lesions); aid in the healing of ulcers of sacral or perineal region in incontinent patients; obstruction or urinary retention; monitoring urine output in non-cooperative critical patients; strategic situations of fluid challenge in acute renal failure. The average age of the sample was 80.2 years old and 55% were female. Bladder catheterization lasted an average of 3.8 days and 76.3% of the patients had indication for bladder catheterization according to current orientations. At time of discharge 62% of the patients had registration if they maintained bladder catheterization and the principal justification for that procedure.

The prevalence of bladder catheterization was 40.6% and it was adequate in 76.3% of the hospitalized patients. The most inappropriate indication for urinary catheterization was urinary output monitoring in non-critically ill patients.

Conclusion

This study yet it demonstrates an excess of urinary catheterization, it shew an improvement from previous years analyses's. Clinics should pay attention to the careful evaluation of its needs, taking into account the lack of evidence of real benefits and risks inherent to the process.

#2073 - Case Report

HENOCH-SCHÖNLEIN PURPURA: AN UNCOMMON RASH IN ADULT

Carolina Coelho, Joana Diogo, José Jácome, Rita Bizarro, Angela Ghiletschi, Rita Monteiro, César Vieira, Cátia Carvalho, Conceição Loureiro

Hospital Santo António dos Capuchos - CHULC, Lisboa, Portugal

Introduction

Henoch-Schönlein purpura (HSP) is an acute immunoglobulin A (IgA)-mediated disorder characterized by a generalized vasculitis of small vessels. It is characterized by a tetrad of clinical manifestations that vary in presence and order of presentation: palpable purpura; arthralgia and/or arthritis; abdominal pain and renal disease. Only 10% of cases occur in adults (the majority in children), and has male predominance (1.5:1). HSP is usually self-limited, however, adults are at increased risk for severe renal involvement (incidence 45-85%) leading to loss of renal function.

Case description

A 66-year-old male was admitted to the emergency room due to diarrhea and decreased diuresis. He also referred fatigue, dyspnea at rest, along with generalized edema. Upon initial observation he presented a BP 105/55 mmHg, 68 bpm and SpO₂ 98%, afebrile, lip cyanosis and signs of poor perfusion. Chest auscultation revealed crackles in the lower half of the both hemi-thoraces. He was admitted to the Internal Medicine ward with the initial diagnosis of decompensated heart failure. Despite diuretic therapy the patient's clinical situation deteriorated and due to signs of septic shock and he was transferred to ICU. After stabilization and discharge of this unit, he developed a purpuric rash in his right arm, both hands, and concomitant aggravation of renal function. The purpura spread to the neck, face, upper and lower limbs. The urinary sediment showed hemoproteinuria, and on immunological evaluation a profile of increased IgA. He was then submitted to renal biopsy that confirmed by immunofluorescence the granular mesangial and parietal deposition of IgA complexes, which, along with the clinical history of the patient were in favor of the diagnosis Henoch-Schönlein purpura. Immunosuppression was initiated and slight improvement of renal function occurred, however it was not sustained, and hemodialysis was necessary for improvement of fluid balance.

Discussion

Henoch-Schönlein purpura is a systemic vasculitis that is common in children, and usually runs a benign self-limited course. However, in adults, this disease deserves special attention, since it may cause severe renal impairment. Early diagnosis and approach are of undeniable importance. Since this disease is of unclear etiology, we require more data regarding its impact and therapeutic outcome, especially in adults.

#2164 - Case Report

A RARE CAUSE OF RECURRENT PLEURAL EFFUSION

Anilda Barros, Elena Pirtac

Hospital Garcia de Orta, Almada, Portugal

Introduction

Nephropleural fistula is a rare cause of pleural effusion and is typically a result of obstructive uropathy or injury to the kidney or urinary tract.

Case description

The authors present a case of a 63-year-old woman with previous history of hypertension, non-Hodgkin's lymphoma and nephrolithiasis. Admitted to the emergency department complaining of fever, dyspnea and left pleuritic chest pain. Three days earlier with complaints of low back pain medicated with cefuroxime for upper urinary infection.

At clinical examination she was feverish, polypneic and pulmonary auscultation revealed vesicular murmur abolished in the lower 2/3 of left hemitorax.

Analytically she presented elevated inflammatory parameters, renal insufficiency and urinalysis suggesting urinary infection. Chest X-ray showed left pleural effusion in the lower 2/3 and thoracentesis was performed with cytochemical examination of pleural fluid compatible with an exudate. Microbiologic tests of urine and pleural fluid revealed *Proteus mirabilis* for which she initiated directed antibiotic treatment. To exclude obstructive uropathy she underwent imaging exams that confirmed this hypothesis with the associated finding of homolateral renal abscess that was treated with ureteral stenting. Due to recurrence of pleural effusion with refractory respiratory insufficiency she repeated thoraco-abdominal CT scan showing nephropleural fistula that was surgically corrected.

Discussion

We highlight the rarity of nephropleural fistula and the importance of its clinical suspicion in the differential diagnosis of pleural effusion. Surgical correction of injuries may be required.

#2235 - Case Report

A PAIN IN THE BACK: AN ALWAYS TRICKY CASE REPORT

Miguel Trigueiro Rocha Barbosa, Etel Florova, Mónica Silva, Fátima Campante

Centro Hospitalar Barreiro Montijo, Barreiro, Portugal

Introduction

Over eighty percent of the population will experience an episode of back pain at some time during life. Chronic back pain is a common cause of disability in the active population, thus having a substantial economic impact. The possible causes are numerous, what poses an interesting challenge to the physician.

Case description

Woman, 49-year-old, cleaning worker. Medical history of microcytic/hypochromic chronic anaemia, menorrhagia and allergic rhinitis. She attended the emergency department with a clinical history of chronic lower right back pain ongoing for 6 months and previously treated with Etodolac, interpreted as a result of osteoarticular pathology. It was accompanied by a non-intentional weight loss (8 kg, 12.3% of body weight) and nausea. Physical examination: hypotension (91/59 mmHg) as the sole finding. Analytically: haemoglobin 7.9 g/dL, leukocyte count $7.70 \times 10^9/L$, platelets $503 \times 10^9/L$, C-reactive protein 111.8 mg/L. Urine analysis: presence of leucocytes and erythrocytes. The renal ultrasound revealed a large heterogeneous hypoechoic mass occupying part of the two superior thirds of the right kidney, measuring about 7.9x4.5 cm of diameter. Numerous retroperitoneal lymph nodes were identified, the larger ones with 5 cm of diameter. The renal tissue biopsy revealed atrophic renal parenchyma, with focal infiltration by a low differentiated carcinoma. The immunohistochemical study was positive for VIMENTIN, CD10, weakly positive for oestrogen receptors,

and negative for CK7 and CK20. After further imaging studies it was assumed a renal cell carcinoma stage TNM cT2a cN1 M0. The patient underwent first-line chemotherapy with Sunitinib aiming lymph nodes cytoreduction and subsequent evaluation for curative surgery. After two cycles of sunitinib there was an unfavourable disease progression and was decided a therapeutic switch to second-line therapy with Lenvatinib and Everolimus. The patient passed away a few weeks later.

Discussion

Back pain may have multiple aetiologies, which range from common benign causes up to a possible malignant process. It is essential to question the patient about accompanying “red flag” symptoms. This case report enhances the importance of a well-executed anamnesis and a holistic evaluation approach.



ONCOLOGIC AND HEMATOLOGIC DISEASES

#39 - Case Report

POLYSEROSITIS AS A PRESENTATION OF GASTRIC SIGNET-RING CELL ADENOCARCINOMA

Paulo Zoé Costa, Ivanna Ostapiuk, Andreia Póvoa, Pedro Vieira, Orlando Mendes, Maria Inês Sequeira, João Correia
Unidade Local de Saúde da Guarda, Guarda, Portugal

Introduction

Polyserositis is the inflammation with effusion of different serous membranes and is associated with different aetiologies such as autoimmune, autoinflammatory, infectious, endocrine, metabolic, toxic origin, or neoplastic diseases.

Case description

A 43-year-old man with fatigue, unintentional weight loss, anorexia, cough and abdominal pain. He was a smoker and had history of gastric ulcer. After the physical examination, the chest computed tomography (CT) scan was performed and showed a small and multiple-loculated bilateral pleural and pericardial effusion. The thoracentesis and pericardiocentesis were not executed due to this limitation. The upper endoscopy and biopsy shows a diffuse type adenocarcinoma with signet ring cell. Chest-abdominal-pelvic CT scan revealed bone metastasis, hepatomegaly and peritoneal effusion. Thus, can't be removed completely by surgery and palliative chemotherapy was performed. The patient has passed away after several months.

Discussion

Since the polyserositis is associated with different diseases and its diagnosis could be challenging. We want to present this case and discuss about its features due to its wide range of different aetiologies. The lack of a diagnostic algorithm for polyserositis increase the difficulty in discovering the cause, especially when initial investigations do not allow for a clear diagnosis.

Moreover, the signet ring cell carcinoma is a rare form of highly malignant gastric cancers and the infrequency of the disease among the population makes the diagnosis more difficult and the prognosis less favorable.

#63 - Case Report

A MALIGNANT TRANSFORMATION OF GANGLIONEUROBLASTOMA TO NEUROBLASTOMA

Zaida Salmón González, Iria Sanlés González, Paula Hernández Martínez, Fernando Ortiz Flores, Maite Latorre Asensio, Gonzalo Martínez De Las Cuevas
Hospital Marqués de Valdecilla, Santander, Spain

Introduction

Neuroblastic tumors present a wide spectrum of tumors, including the ganglioneuroma, ganglioneuroblastoma and undifferentiated neuroblastoma (NB). Ganglioneuromas are benign tumors, which usually arise from mediastinal or retroperitoneal mass. Exceptionally it can degenerate into neuroblastoma

Case description

A 38-year-old female admitted with lumbar pain in the department of general surgery for the complete removal of sacral ganglioneuroma. Fifteen years after the first operation, the patient admitted with progressive lumbar pain, paraparesis, loss bladder and bowel control. On physical examination TA:160/70, FC:80lpm, suprapubic mass and pain at the sacral region pressure. In the neurological exploration hypoesthesia on perianal region with exalted reflexes. CT and MRI were performed, reporting the presence of voluminous tumor that displacement of abdominal viscera (17x12x12cm), involvement of the sacrum, bone and ganglionic metastasis. Analytically highlight the production of catecholamines (Urine-Noradrenaline 161mcg/day and Adrenaline 127 mcg/day). A biopsy confirms the presence of neuroblastoma. Corticoid, radiotherapy and chemotherapy were started

Discussion

Ganglioneuroma is a slow growing, benign tumor. These tumors are fully differentiated tumors with mature ganglion cells and schwann cells. Ganglioneuromas can remain asymptomatic for a long. Surgical excision is the treatment of choice in the management of symptomatic ganglioneuromas. The malignant transformation of a ganglioneuroma into NB has been sporadically described. In our case it appears after fifteen years. The mechanisms are not clear, some authors propose might be related to both genetic factors and histopathological characteristics. Neuroblastoma

should be considered in the differential diagnosis of the tumors originating in sympathetic ganglia, adrenal gland or other sites in adult patients

#78 - Case Report

PULMONARY EMBOLISM AS PARANEOPLASTIC SYNDROME

Ana Beatriz Amaral, Pedro Duarte, Cláudia Rodrigues, Luís Dias
Hospital do Divino Espírito Santo de Ponta Delgada, Ponta Delgada,
Portugal

Introduction

Venous thromboembolism is associated with neoplasia in about 10-15% of cases. More frequently, it is related to solid neoplasms, namely, lung and gastro-intestinal neoplasms.

Case description

A 65-year-old woman presented herself in the emergency department due to palpitations, productive cough and fever with 1 day of evolution. She also reported dyspnoea with progressive aggravation for the last 3 weeks, coincident with an episode of left thigh phlebitis, medicated with anti-inflammatory drugs, a few days after a long-haul flight. She had a history of paroxysmal atrial fibrillation, obesity and hypertension. On examination she had polypnea, a SatO₂ of 92% in ambient air and was normotensive. She was hypoxemic with hypocapnia. A CT scan of the chest showed a bilateral central pulmonary thromboembolism (PE), and an exuberant mediastinal mass, involving the mediastinal vessels, heart/pericardium, trachea and main bronchi, supraclavicular lymph node involvement and pulmonary parenchyma of the left upper lobe. She started anticoagulation with enoxaparin and was admitted for investigation. An additional CT of the abdomen and pelvis showed the involvement in retroperitoneal thrombosis of the left iliac vein, which extends to the femoral vein, and thrombosis of the right femoral vein. She was submitted to transthoracic biopsy, whose histology showed Diffuse B-cell Non-Hodgkin's Lymphoma (B-NHL). She was transferred to Haematology, having started CHOP chemotherapy.

Discussion

B-NHL mainly affects the elderly. It usually presents as a rapidly growing mass, which can affect several organs. For lymphomas, thrombotic events occur more frequently after initiation of treatment, however, they may occur as a form of presentation, especially in the presence of other risk factors for PE.

#80 - Case Report

MULTIPLE MYELOMA IN YOUNG PATIENT: A CASE REPORT

Priscilla Costa Do Nascimento, Ana Paula De Brito Dias De Brito
Dias, Nadielli Carolina Marques
Federal Hospital of Andaraí, Rio De Janeiro, Brazil

Introduction

Multiple Myeloma (MM) is a malignant lymphoid cell tumor responsible for 1% of cancer deaths in Western countries. It has the second place in the ranking of the most common onco-hematological diseases, being surpassed only by lymphomas. It has an estimated 86,000 new cases and 62,500 deaths a year, accounting for 2% of the world's cancer deaths.

The disease is caused by the proliferation of B cells in the bone marrow (MO), producing and secreting, disproportionately, monoclonal immunoglobulins (Ig), or fragments thereof, called M protein.

Case description

A 24-year-old male, brown, bus driver, resident of Belford Roxo, a native of Rio de Janeiro, was admitted to the Federal Hospital of Bonsucesso with nausea, abdominal pain and oliguria of seven days of evolution. The patient had no known comorbidities.

Physical examination was lucid and oriented, hemodynamically stable, eupneic in ambient air, eucardic, afebrile. Laboratory tests revealed increased nitrogen slag and anemia characteristic of chronic disease. Abdominal ultrasonography showed topical kidneys, of normal dimensions and with preservation of the corticomedullary dissociation. Radiography of the lumbar sacral column revealed lytic bone lesions. The diagnostic hypothesis of MM was investigated. Protein immunoelectrophoresis was performed in which the presence of a monoclonal band against the antisera IgG and kappa light chain was observed, with homogeneous distribution of low intensity against IgA, IgM and lambda light chain antisera, being compatible with monoclonal gammopathy of the IgG type KAPPA. The right posterior iliac crest MO biopsy: about 40% of global cellularity, with 20% of monoclonal (monoclonal) plasmids positive for the kappa light chain. Immunohistochemistry: positivity for CD138 and kappa light chain on plasma cells. Negativity for lambda light chain. Patient evolved in need of dialytic therapy and underwent chemotherapy with bortezomib and cyclophosphamide.

Discussion

MM is an incurable disease. With a high number of plasma cells present in the bone marrow compromising most of the time, individuals from the 50 years of age, male and black. But in the case chosen the patient was 24 years old, male, but with the brown color. Several bone lesions appear in the patient, in some regions such as spine, femur and other localities. Symptoms such as the presence of kidney failure, hypercalcemia among others arise. Important changes have been incorporated into the diagnostic criteria of the MM, changing this scenario.

#89 - Case Report

INGUINAL METASTASIS AS FIRST CLINICAL EXPRESSION OF UNKNOWN ORIGIN MALIGNANT MELANOMA.

Gloria Perez-Vazquez, Carmen Palomar-Muñoz, Isabel Ballesteros-Chaves, Eva Lozano-Loaiza, Esther Rubio-Martin, Carolina Luque-Amado
Punta Europa Hospital, Algeciras, Spain

Introduction

Cancers with an unknown primary tumor are a challenge, both in their diagnosis and in their treatment.

Case description

We report a 52 years old female presenting with rapidly growing painless right inguinal lymphadenopathies. A Body-CT scan showed solid right inguinal mass with diameter of 6x3.5 cm compatible with gross pathological adenopathy. Two other satellite lymphadenopathies and adenopathy of pathological aspect are also associated in the right external iliac chain. Biopsy 3 right inguinal adenopathies with anatomopathological diagnosis melanoma BRAF mutated of 18 isolated lymph nodes. PET is performed with right inguinal hypermetabolic adenopathies suggestive of malignancy. Oncological diagnosis Melanoma pT0pN3bM0 Stage IIIC was performed. Treatment with nivolumab 3 mg/kg is started. One month after the beginning of the treatment, there is an immune-related hypothyroidism that occurs with hypothyroidism, treated with levothyroxine and oral corticosteroids. After control of the table and withdrawal of corticosteroid therapy, control CT was performed with the appearance of two lung lesions in the right lower lobe (5 mm) and small bilateral intrathoracic adenopathies. PET-CT was performed with the finding of small pulmonary nodules in the LID, the largest one (<1 cm) with doubtful pathological uptake, as well as hyalomedastinal adenopathies that, due to their morphometabolic characteristics and bilateral and symmetric distribution, could be of reactive origin, without being able to rule out neoplastic etiology. Treatment was modified to dabrafenib 300 mg/d and trametinib 2 mg/d, but due to poor tolerance to treatment, substitution was made to vemurafenib 1920 mg/d for 28 days and cobimetinib 60 mg/d for 21 days, free of disease until the present time.

Discussion

Cancers with an unknown primary tumor are a challenge, both in their diagnosis and in their treatment. Initially they require a thorough study in search of the lesion that gave rise to it. This particular group of tumors is characterized by early dissemination, absence of clinical signs of the primary tumor and an unpredictable pattern of behavior in both aggressiveness and dissemination, which is why the clinical course is uncertain. Melanomas in particular occur in 3.2% of cases as a hidden primary, are twice as frequent in men and have an increase in their frequency during the fourth to fifth decade of life. The most frequent sites of metastasis are the axillary, cervical and inguinal lymph nodes.

#90 - Case Report

SUDDEN DYSPNEA IN A PATIENT WITH PROSTATE ADENOCARCINOMA.

Gloria Perez-Vazquez, Carmen Palomar- Muñoz, Jose Manuel Gil-Gascon, Isabel Ballesteros-Chaves, Esther Rubio-Martin, Eva Lozano-Loaiza
Punta Europa Hospital, Algeciras, Spain

Introduction

Description of clinical case with low incidence.

Case description

79 years old man, smoker of 20 cig/d, with antecedent of adenocarcinoma of prostata cT2cN0M0, free of disease for 4 years. Emergency department with sudden dyspnea of less than 24 hours, which prevents night rest. Chest X-ray showed a right pleural effusion.

Thoracentesis was performed for cytological study of pleural fluid as well as chest CT. CT showed a right paratracheal mediastinal mass high, dorsal and in contact with the right brachiocephalic venous trunk, producing thrombosis of said vessel and the distal areas of the right axillary vein and right subclavian vein draining into said trunk.

Cytological study of pleural fluid and CT-Guided core needle biopsy of pleural lesion was performed, with the diagnosis of sarcomatoid mesothelioma, desmoplastic variant.

Treatment with low molecular weight heparin at doses adjusted for weight is prescribed, as well as carboplatin-pretemed chemotherapy, performing 44 cycles with disease stability for 3 years.

Bone progression at 3 years of diagnosis, with a second-line scheme with carboplatin and gemcitabine, after six cycles, pleural progression was observed. Third line of treatment with oral vinorelbine without good clinical evolution is offered, dies after 4 years of initial diagnosis.

Discussion

The diagnosis of malignant pleural mesothelioma presents important challenges, given the difficulties of an early diagnosis, it is infrequent that a curative treatment is achieved through radical surgery.

In cases where surgery is not feasible, chemotherapy is proposed combining pemetrexed and platinum compounds, and radiotherapy is reserved for the treatment of pain associated with infiltration.

There are three main pathological types of mesothelioma: epithelial (50% to 70%, which has the best prognosis, since it grows slowly), sarcomatoid (7% to 20%, worse prognosis) and mixed (20% to 35%).

Mesothelioma is more frequent in men over 65 years old, the main cause of this type of tumor is an occupational exposure to asbestos or asbestos. The average survival for a person with mesothelioma is approximately one to two years.

#91 - Case Report

MERKEL TUMOR, CASE REPORT

Gloria Perez Perez- Vazquez, Jose Manuel Gil-Gascon, Isabel Ballesteros-Chaves, Carmen Palomar-Muñoz, Esther Rubio-Martin, Eva Lozano-Loaiza
Punta Europa Hospital, Algeciras, Spain

Introduction

Merkel cell carcinoma or neuroendocrine carcinoma of the skin is a highly malignant uncommon neoplasm, with early regional lymph node involvement and distant metastases. It arises from cells belonging to the neuroendocrine system, therefore presenting a distinct immunohistochemical profile. An early diagnosis and a correct treatment are important to improve the prognosis of these patients.

Case description

70 years old man attended by left suprarotulian subcutaneous nodule, surgical exeresis of tumor of 8.5 cm was realized with posterior locoregional radiation therapy. At first month, 2 lesions of 5 and 7 mm were removed, with diagnosis of "metastasis in transit" and subsequent local radiotherapy. At 4 months, 2 lesions of 3 mm were removed with infiltration by Merkel Cell carcinoma, and locoregional progression at 1 month with lymphatic extension at the inguinal and left external iliac levels.

Surgical treatment is ruled out, starting treatment with avelumab achieving clinical stability for 6 months, with left leg amputation affected after new progression. In spite of CT- body re-evaluation, left anterior superior mediastinal mass was observed. The patient was admitted with acute confusional syndrome of 48 hours of evolution in the context of severe hyponatremia. Despite its correction, the patient died of infectious complications 3 years after the initial diagnosis.

Discussion

Merkel cells are considered as an integrated element within the neuroendocrine system.

The Merkel tumor appears in people with an average age of 70 years, sits on areas exposed to the sun, predominance of the head and neck, the interest of our case is in the existence of an infrequent cutaneous tumor associated with an unusual location, which makes the initial clinical diagnosis of the lesion difficult.

Clinically, it manifests as an indurated or nodule papule, violaceous and painless, not ulcerated, around 1.5-2 cm and months of evolution, it is infrequent with high aggressiveness and a tendency to local recurrence, which requires early diagnosis and treatment. The wide excision is proposed as initial therapy. Regional lymphadenectomy is performed systematically in patients with affected lymph nodes. Radiotherapy is recommended in cases with affected margins or impossible to perform surgery, where it will be applied to the surgical bed and regional lymph nodes. Chemotherapy is used in cases of disseminated disease or local recurrences that have exceeded the maximum tolerated radiation dose.

#132 - Abstract

THE IMPACT OF BETA THALASSEMIA MINOR STATE ON PULSE PRESSURE

Sakir Ozgur Keskek

Adana City Training and Research Hospital, Adana, Turkey

Background

Beta-thalassemia syndromes are characterized by reduced or absent beta globin chain synthesis, resulting in reduced hemoglobin in red blood cells. Beta-thalassemia minor is a common hereditary blood disorder in Mediterranean countries such as Turkey, Greece, and Italy. Subjects with beta-thalassemia minor are usually clinically asymptomatic even though sometimes they have a mild anemia. Pulse pressure that originates from the pulsatile left ventricular ejections is a prominent risk factor for cardiovascular morbidity and mortality. In this study, we aimed to investigate the pulse pressure in subjects with beta-thalassemia minor.

Methods

A total of 76 subjects, 37 subjects with beta thalassemia minor and 39 healthy subjects were included in this cross-sectional cohort study. Hemoglobin electrophoresis, complete blood count, blood pressures, pulse pressures were measured. Pulse pressure was defined as the difference between systolic and diastolic blood pressures. Medcalc V17.4 software program was used for statistical analyses.

Results

The groups were matched in terms of age and sex (36.3±11.3 vs. 35.4±7.0, p=0.655; female/male= 27/10 vs. 25/14, p=0.408). Systolic and diastolic blood pressures were 112.0±10.6 and 71.2±8.6, respectively in the study group while they were 115.7±10.3, 70.1±12.0, respectively in the control group (p=0.129, 0.653). Pulse pressure of the subjects with beta thalassemia minor was lower than the healthy subjects (40.8±8.85 vs. 45.5±8.9 p = 0.02).

Conclusion

Subjects with beta thalassemia minor have low pulse pressure. Hemodynamic variations seen in anemia due to arterial dilatation and decreased blood viscosity may lead to low systolic blood and pulse pressure. Low pulse pressure in subjects with beta-thalassemia minor could afford some protection against cardiovascular diseases.

#135 - Medical Image

MALIGNANT PLEURAL MESOTHELIOMA WITHOUT ASBESTOS EXPOSURE

Daniela Madeira, Patrícia Vasconcelos

Hospital Prof. Doutor Fernando Fonseca, Amadora, Portugal

Clinical summary

A 82-year-old woman was submitted to hip replacement surgery. On the preoperative exams, chest x-ray (Figure A1) revealed some

rounded consolidations on the left, but she refused investigation. 1 year later, was admitted to our hospital with weight loss and malaise. She had a rigid and painful tumor on the left side of the chest. We repeat the x-ray (Figure A2) and made a chest CT (Figure B) that revealed many bulky pleural lesions on the left and some on the right hemithorax. On the biopsy of the subcutaneous tumor was observed neoplastic proliferation with mesothelial differentiation. She denied exposure to asbestos. The staging TC discovered numerous metastases at the bones, diaphragm, pericardium, ganglia and subcutaneous at the left side of the chest. She died on the 25th day of hospitalization.

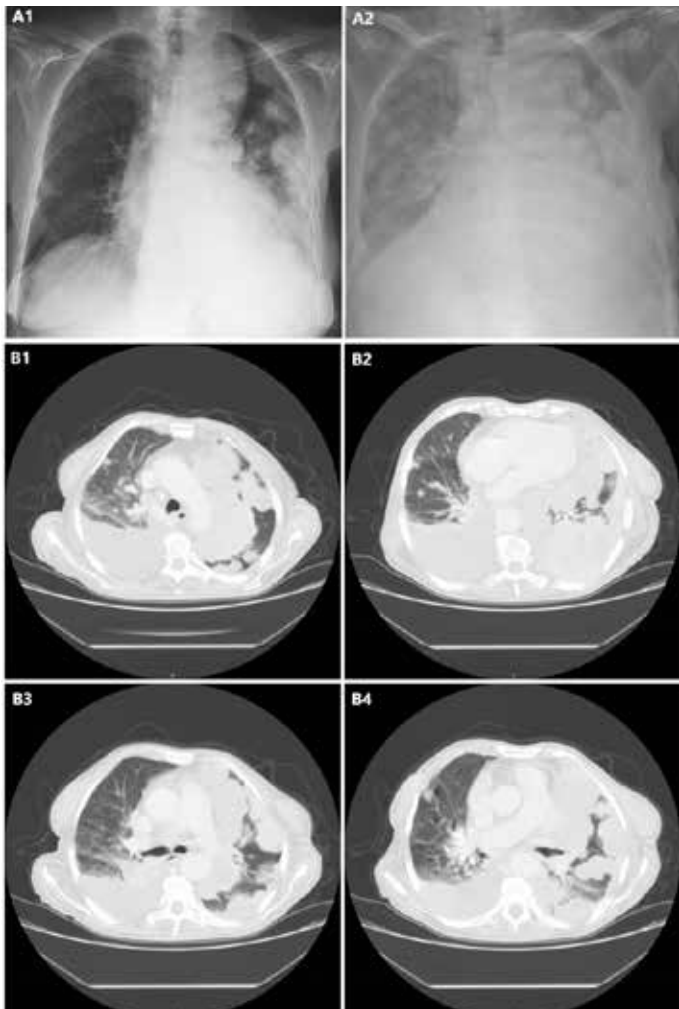


Figure #135. X-ray and CT scan.

#156 - Case Report

FROM HYPOXEMIA TO POLYCYTEMIA: ETIOLOGICAL IMPORTANCE IN THROMBOTIC EVENTS OF REPETITION

Inês Esteves Cruz, Catarina Cabral, Eugénia Silva, Francisco Silva
Hospital Egas Moniz, CHLO, Lisbon, Portugal

Introduction

Polycythaemia is characterized by increased hemoglobin and/or hematocrit concentration. Secondary polycythaemia is

often associated with chronic hypoxemia, with increased renal production of erythropoietin. Common causes include obstructive sleep apnea, obesity with hypoventilation and COPD, smoking and secreting erythropoietin tumors. Hemapheresis is advised when HCT greater than 45%, symptomatology compatible with blood hyperviscosity or at risk of thrombotic phenomena.

Case description

A 72-year-old male with history of hypertension, dyslipidemia, infra-renal abdominal aortic aneurysm (prosthetic 3-year placement), bilateral subsegmentar pulmonary embolism (PE) during procedure, extensive pulmonary emphysema, ex-smoker. Admitted to the ER with deep venous thrombosis of right lower limb and PE with respiratory insufficiency (pO₂ 38 mmHg). Blood analyze: erythrocytes 4.91x10¹²/L, Hb 18.1 g/dL, 54% Htc, VGM 110, 172000x10⁹/L platelets, 1.2 ug/mL D-dimers, 1.68 mg/dL creatinine, 36 ng/mL troponin T, NTproBNP 191 pg/mL. AngioTC: PE in the lobar branch of the right lower lobe and in several segmental branches bilaterally. Echocardiogram TT: dilated right ventricle with normal systolic excursion, very discrete systolic rectification of interventricular septum.

Initiated therapy with enoxaparin and hemapheresis (500 mL). Revealed increased erythropoietin assay (51.9 mUI/mL) and negative JAK2V617F mutation. It showed clinical improvement, with indication for therapeutic anticoagulation with rivaroxaban and O₂ additional.

On consultation, echography confirmed TVP sequel in right femoropopliteia, with virtually complete recanalization. Respiratory function tests performed in previous year, with bronchial and bronchiolar obstruction, no response to bronchodilatation test and marked decrease in alveolar-capillary diffusion capacity. Assumed polycythemia secondary to chronic respiratory insufficiency, being oriented Immunohemotherapy. Given the second thromboembolic event, with secondary polycythaemia, it was decided to maintain chronic anticoagulation.

Discussion

A patient with recurrent thrombotic events, high erythrocyte, hemoglobin and/or Htc values should be hypothesized polycythaemia. In this case, polycythemia secondary to chronic respiratory failure was assumed. We alert about this pathology as a risk factor for thromboembolism. Treatment with hemapheresis in the early stages of the thrombotic event is emphasized in order to reduce the extent and improvement of the prognosis.

#162 - Medical Image

MULTICENTRIC GLIOBLASTOMA - IMAGIOLOGICAL ECCENTRICITY CONTRASTING WITH SILENT SYMPTOMS

Inês Soler Bargiela, Maria João Gomes, Filipa Bordalo Ferreira, Sandra Pinto Alves

Hospital Prof. Doutor Fernando Fonseca, Amadora, Portugal

Clinical summary

We report the case of a healthy and asymptomatic 78-year-old man, who was admitted with epileptic seizures. The cerebral CT scan showed 2 cortical lesions, right parietal and left temporal, being considered as diagnostic hypotheses glial series tumor versus secondary lesions. Subsequently, cerebral MRI confirmed the existence of two large intra-axial lesions (57x34x38 mm and 36x35x21 mm), suggesting primary lesions of the central nervous system glial series, which correspond to a Multicentric Glioblastoma Multiforme.

It should be noted that this glioblastoma multifocality, a rare form of presentation, gives the glioblastomas an even worse prognosis.

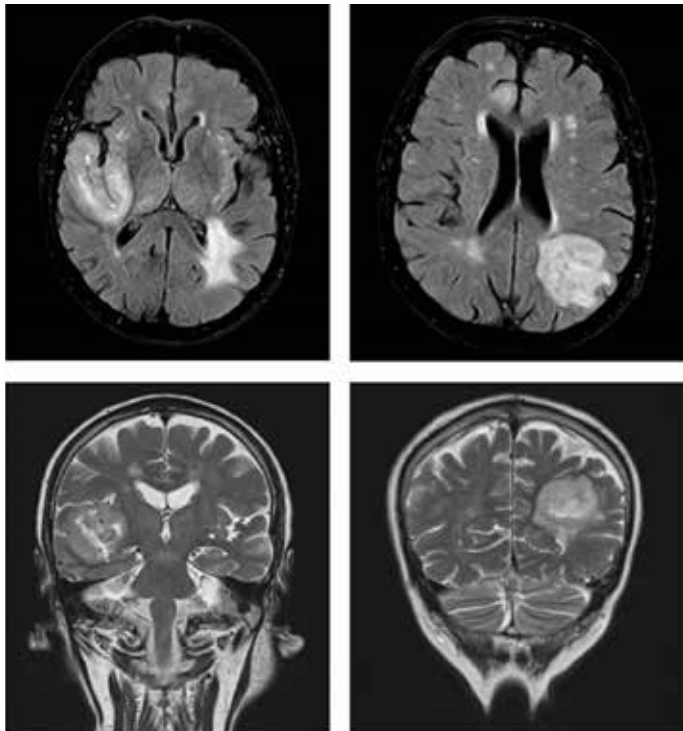


Figure #162. Multicentric Glioblastoma Multiforme in MRI, showing the 2 cortical lesions.

#167 - Case Report

DYSPNEA ASSOCIATED WITH CERVICAL MASS

Miriam Vieitez Santiago¹, Amaia Ukar Naberan², Amelia Asturias Saiz², Arrate Aldama Martin², José Alberto Espinoza Pérez³

¹ Hospital Comarcal de Laredo, Laredo, Spain

² Hospital Universitario Marqués de Valdecilla, Santander, Spain

³ Complejo Universitario Navarra, Pamplona, Spain

Introduction

Ewing sarcoma (SE) was first described by James Ewing as a “diffuse endothelioma of bone” (Ewing 1921). It is a bone neoplasm of high aggressiveness and very sensitive to treatment with radiotherapy. It has a higher incidence in children than in adults. It is considered a “pediatric cancer” (average age of patients is 15 years). It’s extremely rare in adults over the age of 40.

Case description

84-year-old woman with a history of type 2 diabetes; hyperthyroidism with multinodular goiter and breast cancer with bilateral mastectomy in 2015 on hormonal treatment without recurrence.

She attends an internal medicine consultation for dyspnea associated with laterocervical left painful mass that has been growing from 3 months of evolution, associated with weight loss. Physical examination showed a painful stone mass of 5x6x5 cm in the left sternoclavicular junction and a left supraclavicular stone adenopathy of 1x2 cm. There are no pathological findings in analysis.

Biopsy of the mass is performed being a diagnosis of undifferentiated round cell sarcoma compatible with Ewing’s sarcoma.

In chest radiography, mass in left apex is objective. In an extension study, bone marrow involvement is ruled out, but pulmonary involvement is confirmed by contiguity with tracheal deviation. Although the patient has dyspnea, the mass does not affect the airway.

Discussion

Ewing sarcoma is extremely rare in adults over age 40. In 2008 a retrospective analysis of 47 cases was published in a German oncology journal where it is said that age in this case does not lead to worse prognosis, and treatment according to the studies designed for younger patients is feasible and effective.

Primary sarcomas of the chest are very rare. The pulmonary involvement usually associated with Ewing sarcoma is like metastasis; however, in this case it is infiltration of the mass into contiguous tissues.

#169 - Case Report

HYPERFERRITINEMIA A RELATIVELY FREQUENT AND ANNOYING FINDING FOR PHYSICIANS: AN INTERESTING CLINICAL CASE

Lana El Osta¹, Hazem El Osta², Amine Wehbé¹, Sani Hlais¹, Nada El Osta¹

¹ School of Medicine, Saint-Joseph University of Beirut, Beirut, Lebanon

² Medical Oncology, Baylor College of Medicine, Houston, Texas, United States

Introduction

Measurement of serum ferritin is common in general practice, and moderate hyperferritinemia is a relatively frequent and annoying

finding on routine bloodwork. Elevated serum ferritin most often does not reflect a pathogenic hepatic iron overload, and is not regularly related to malignant, serious or rare disease.

Case description

A 40 year-old man was found by chance to have elevated ferritin level (=1600 µg/L) and normal hemoglobin (=14.7 g/100 ml). He is a moderate drinker (10 drinks per week), and has an untreated dyslipidemia. He doesn't take any medication or supplement. Physical exam showed a BMI of 32 and blood pressure of 135/85. A complementary blood test was therefore performed: transferrin saturation normal (=38%); CRP of 0.2 mg/L; seric iron normal; glycaemia 112 mg/dl; triglycerides 290 mg/dl; HDL 32 mg/dl; LDL 125 mg/dl; serum ALT 95 U/L; TSH 1.4 mU/L (normal); and negative serologies.

Since the patient had bullets in the body, MRI was not feasible. An abdominal ultrasound was done and showed a fatty liver overload, without splenomegaly. The patient refused any further evaluation. A diet and physical activity were recommended, and a treatment with fibrate was started. The patient was also advised to stop alcohol consumption.

After 3 months, he lost 5 kgs; His liver blood test was strictly normal; the lipid profile was improved; and the ferritin level dropped to 200 µg/L.

Discussion

The detection of hyperferritinemia is often fortuitous, revealed in results from a laboratory screening or follow-up test. The aim of the diagnostic procedure is therefore to identify its cause and to rule out hepatic iron overload. Transferrin saturation can be an important guide in the diagnostic procedure.

It must be stressed that hyperferritinemia most often does not mean iron overload; and 50% of patients with high ferritin level have several causes simultaneously present. In our patient, the hyperferritinemia is most probably related to alcohol consumption, fatty liver and metabolic syndrome.

Most of the time, clinical findings, several simple laboratory tests, and a simple non-invasive diagnostic procedure are sufficient to determine the cause of high ferritin concentrations. Moreover, it is essential to remember that hepatic iron overload can never be detected by ultrasound.

Hyperferritinemia among people with chronic alcoholism is not proportional to the quantity of alcohol consumed. However, withdrawal of alcohol must be considered.

#171 - Medical Image

BISPHOSPHONATE-RELATED OSTEONECROSIS OF THE JAW: A DEVASTATING COMPLICATION IN CANCER PATIENTS

Lana El Osta¹, Badi El Osta², Amine Wehbé¹, Antoine Aoun³, Nada El Osta¹

- ¹ School of Medicine, Saint-Joseph University of Beirut, Beirut, Lebanon
- ² Medical Oncology, Emory University School of Medicine, Atlanta, Georgia, United States
- ³ Faculty of Nursing and Health Sciences, Notre Dame University, Zouk Mosbeh, Lebanon

Clinical summary

A 78-year-old man presented with a progressive oral pain. The patient has several comorbidities, including a metastatic prostate adenocarcinoma. He developed a stage II osteonecrosis of the jaw following the use of chemotherapy and high doses of zoledronic acid for treatment of secondary bone disease.

Bisphosphonate-related osteonecrosis of the jaw is a rare but potentially destructive complication that adversely affects the quality of life, producing significant morbidity in affected patients, since chewing, speaking, and swallowing can all be considerably and lastingly impaired. Also, its treatment may be a difficult thing to achieve.

This case highlights the importance of implementing effective preventive measures to limit the development of this devastating complication.

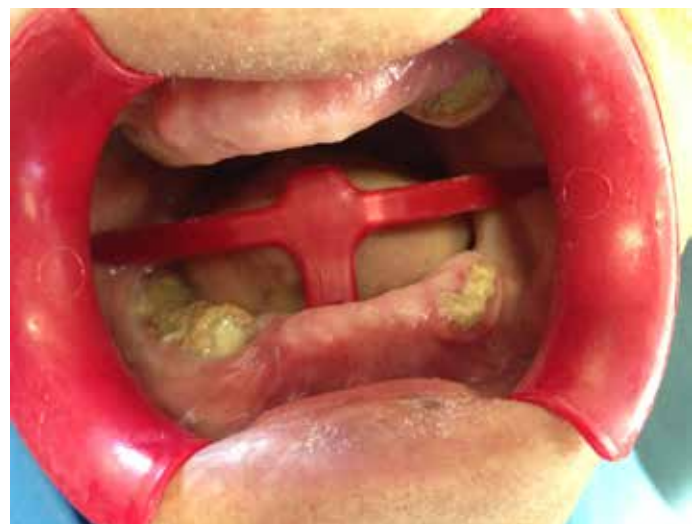

Figure #171. Bisphosphonate-related osteonecrosis of the jaw.

#216 - Abstract

HIP FRACTURE AS A FIRST MANIFESTATION OF CANCER: A COHORT OF PATIENTS IN HOSPITAL CLÍNIC OF BARCELONA TRAUMATOLOGY DEPARTMENT

Anna Aldea, Aina Capdevila, Margarita Navarro
Hospital Clínic de Barcelona, Barcelona, Spain

Background

Hip fractures due to bone metastasis in patients with a prior history of cancer are frequent in trauma wards. However, the prevalence of those fractures in patients with no previous diagnosis of cancer is not well reported. The aim of this study is to evaluate the prevalence of new cancer diagnosis after a pathologic hip fracture and its clinical characteristics.

Methods

This single site descriptive study was conducted in a Spanish teaching hospital. We have retrospectively analyzed all the patients with hip fractures over a period of 10 years (2009-2018) and selected those with metastatic fractures and previous undiagnosed cancers. Epidemiological data, fracture and cancer characteristics were reviewed.

Results

14,193 patients with proximal femoral fracture were admitted during this period. Amongst them, 14 patients (0.1%) were diagnosed with hip fracture secondary to a bone metastasis of a previously undiagnosed cancer.

57% were males with a mean age of 75.35 and a median Barthel Index of 95 points. 28.57% were smokers. Hypertension was the main comorbidity followed by heart arrhythmia in 28.57%.

The main previous symptom was pain (78.57%) and only 14.28% reported constitutional syndrome.

Concerning hip fractures, 64.28% were extracapsular, 21.42% intracapsular and 14.3% diaphyseal. Hip X-ray was always suggestive of pathological fracture, showing lytic bone lesions (78.57%) or mixed lytic and blastic (21.43%).

The localization of the primary tumor was heterogenic: lung (n=4), breast (n=3), prostate (n=2) and kidney, bladder, melanoma, chondrosarcoma and unknown primary localization carcinoma (n=1). During the diagnosis, 71.43% of the patients also presented metastasis, predominantly of the lung (70%), liver (40%), suprarenal gland (30%).

The diagnosis was obtained from the histopathological and immunohistochemical findings in femoral biopsy (85.72%) or in the primary cancer lesion (14.28%).

Half of the patients received palliative care with a one-year mortality of 57.14% (33.3% in-hospital). The rest receive hormonotherapy, immunotherapy and chemotherapy.

Conclusion

Hip fracture in elderly patients is a frequent clinical problem, being its main cause osteoporosis but sometimes it could be

secondary to a bone metastasis. It is important to know the different pathologic x-ray patterns because they are the key to an accurate diagnosis. Moreover, a good clinical report can help in the diagnosis; more than 75% of patients had previously suffered from pain in the hip area.

#222 - Case Report

SYNCHRONOUS DOUBLE PRIMARY CANCER WITH BONE METASTASES : A CASE REPORT

Martim Baltazar Alçada¹, Pedro Manata¹, Rita Aranha², Marina Boticário¹, Aluixa Lozada¹, Catarina Ivanova¹, Maria Filomena Roque¹

¹ Hospital de Santarém EPE, Santarém, Portugal

² Faculdade Medicina Lisboa, Lisboa, Portugal

Introduction

Hypercalcaemia of malignancy (HCM) is an important cancer-related medical emergency. It is a sign of advanced disease and indicates poor prognosis.

Case description

An 55 year-old man was admitted with decreased sensorium and constipation for 4 days, weight loss, and reported no other complaints. He was a heavy smoker and drinker, had an history of laryngeal tuberculosis 4 years ago for which treatment was given for one year and without further follow-up.

The physical examinations showed a tumorous lesion of the neck in relation to the right sternocleidomastoid muscle and to the digital rectal examination an enlarged prostate gland with a nodule of hard consistency.

To the blood tests what stood out was an hypercalcemia of 18.9 mg/dl and a prostate specific antigen of 319.18 ng/ml.

The imaging study by computer tomography showed an invasive, infiltrative lesion, localized at the piriform recess, with 4.5 cm of diameter and multiple osteolytic bone lesions. Both the prostate gland and the hypopharynx lesion were biopsed as well as one bone lesion and the histopathologic result was prostate adenocarcinoma, well-to-moderately differentiated squamous cell carcinoma, extensively necrotic and ulcerated, with "superinfection" by colonies of coccobacilli and the bone lesion metastasis of squamous cell carcinoma.

The hypercalcemia was treated with sodium pamidronate with good results.

He was discharged referred to the oncology clinic.

Discussion

In the context of malignancy there are 3 different mechanisms for the elevation of serum calcium: tumor secretion of parathyroid hormone-related protein (PTHrP); osteolytic metastases; tumor production of 1.25-dihydrovitamin D.

#226 - Medical Image

LUNG CANCER WITH DIFFUSE METASTATIC BRAIN - A SILENT ENEMY

Cátia Ribeiro Santos, Flávia Santos, Cátia Faria, João Santos, Célio Fernandes

Centro Hospitalar de Leiria - Hospital de Santo André, Leiria, Portugal

Clinical summary

A 63-year-old male patient with a smoking history with suspension for about 10 years, was admitted to the emergency department due to dizziness and imbalance with about 3 days of evolution. Neurological examination was not significant. Computed tomography (CT) of the skull revealed several expansive intracranial lesions suggestive of diffuse cerebral metastasis and the chest X-ray revealed a mass in the right upper lobe and multiple bilateral well-defined spherical pulmonary nodules. Subsequently, the patient was submitted to a magnetic resonance of the cranium to confirm the multiple lesions of metastatic nature and CT thorax that revealed a mass in the right upper lobe more than 7 cm. A biopsy of the mass was performed showing an invasive adenocarcinoma of the lung.

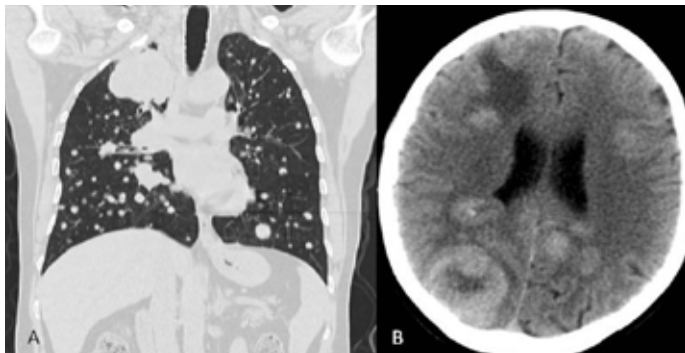


Figure #226. A: Mass in the right upper lobe and multiple bilateral pulmonary nodules; B: Several expansive intracranial lesions (CT scan).

#238 - Case Report

AN UNUSUAL CASE OF RICHTER'S SYNDROME

Filipa Lucas¹, Miguel Alves², Ana Teresa Boquinhas¹, Fredo Renato Roberto¹, Carolina Spulveda¹

¹ Hospital de Cascais, Cascais, Portugal

² ULS Nordeste, Bragança, Portugal

Introduction

Chronic lymphocytic leukemia (CLL) is a mature B-cell neoplasm that usually follows an indolent course.

Richter Syndrome (RS), first described in 1928 by Dr. Maurice Richter, represents the transformation of CLL into a high-grade aggressive lymphoma, typically with the histology of a diffuse large B-cell lymphoma (seen in 85-95% of cases). RS incidence is estimated at between 2-10% of CLL patients and it is associated with a classic switch in histopathology and biology with a poor clinical outcome and short life expectancy (around 8 months).

Case description

We describe the case of an 87-year-old female that had been diagnosed with B-cell CLL 10 years ago and treated with chlorambucil and prednisolone (since 2016). She had low-risk prognostic factors, including mutated IgVH4-39 and 13q14 deletion. She also had a mechanical aortic prosthetic valve, reason why she was under therapy with apixaban. The patient was referred to our department with a one-week history of asthenia, anorexia and melena. She had no complaints of fever, lymphadenopathy, esplenomegaly, night sweats or weight loss.

Initial blood count and biochemistry showed a low hemoglobin level [Hb of 6.6 g/dL (4.0-10.0 g/dL); hematocrit 20.1% (34.7-46%) MCV 94.4 fL (80.0-97.0 fL) and MCH 31.2 pg (26.6-34.0 pg)]; 18×10^3 platelet count ($140-440 \times 10^3$ uL); 5.0 white blood cells/mcL (4.0-6.0 cell/mcL); LDH levels of 453 U/L (240-400 U/L), PCR of 20.94 mg/dL (0.0 - 0.50 mg/dL); urea of 126 mg/dL (17-48 mg/dL), and a creatinine concentration of 2.15 mg/dL (0.50-0.90 mg/dL) with a MDRD of 21.7 mL/min/1.73m².

An endoscopy study showed multiple gastric and duodenal ulcers, some of them with active hemorrhage. Endoscopic hemostasis and sclerosis was performed. Gastric ulcers histologic evaluation showed sheets of large neoplastic B lymphocytes and CD23+, CD20+, Bcl6+, Bcl2+, MUM-1+, EBV+ versus CD5- CD10- immunophenotype consistent with RS. She died 10 days after.

Discussion

In the context of CLL and gastrointestinal ulcer disease, RS is an essential differential diagnosis, associated with a dismal prognosis. Careful monitoring of CLL and an aggressive initial diagnostic strategy may facilitate earlier RS identification, potentially altering the inexorable its course.

#243 - Case Report

IATROGENIC AGRANULOCYTOSIS: ANTI-THYROID & NEUROLEPTIC

Diogo Raposo André, Mónica Caldeira, António José Chaves, Maria Luz Brazão

Hospital Central do Funchal, Funchal, Portugal

Introduction

Iatrogenic agranulocytosis (IA), by non-chemotherapeutic drugs, is a rare adverse event, resulting in a neutrophil count under $0,5 \times 10^9$ cells/L with fever or another suggestive sign of infection.

Case description**Case 1**

A 43-year-old female, with recurrent infections in outpatient practice, manifested oral ulceration, nodular lesion in the right inguinal region with purulent drainage and thyroid nodules, medicated a month ago with methimazole (MM). Her blood count showed polymorphonuclear leukocyte (PMNL) $1,8 \times 10^3$ uL with neutrophils $0,0 \times 10^3$ uL. After completing broad-spectrum antibiotics, the patient was found to have agranulocytosis due

to MM. Normalization of the neutrophil count happened 11 days after the eviction of MM.

Case 2

A 41-year-old male with the schizoaffective disorder, medicated with clozapine (CP), presented with fever and a decreased PMNL count with neutrophils $0,0 \times 10^3$ uL. The patient was hospitalized with neutropenic fever due to neuroleptics that complicated with acute otitis and pneumonia. After broad-spectrum antibiotics and filgrastim were given, a normalization of the neutrophil count occurred by the end of 14 days without CP.

Case 3

A 61-year-old male with bipolar disease, under CP, was referenced to internal medicine consultation due to an asymptomatic leukopenia with neutrophils $1,0 \times 10^3$ uL. After suspending CP, a normal neutrophil count was verified 16 days later.

Discussion

Neutropenia under $0,1 \times 10^9$ cells/L predispose patients to potentially fatal infections. Empiric broad-spectrum antibiotic and hematopoietic growth factors may be helpful in shortening hospitalization and prevent further infectious complications. Not all drugs associated with IA require frequent haematological monitoring, except medication like clozapine, ticlopidine, and anti-thyroids.

#252 - Abstract

RISK FACTORS AND CLINICAL OUTCOMES OF NEWLY DEVELOPED SARCOPENIA AFTER SURGICAL RESECTION FOR GASTRIC CANCER

Beom Jin Kim, Eun Sun Lee, Jae Gyu Kim, Joong-Min Park, Kyong-Choun Chi, Hyun Kang

Chung-Ang University Hospital, Seoul, South Korea

Background

Knowing whether newly developed sarcopenia after surgical resection increases the risk of poor outcomes is meaningful for clinical practice because it may provide new nutritional intervention ideas to achieve better prognosis among patients with GC. However, there is a lack of research on newly developed sarcopenia postoperatively.

Therefore, this study aimed to investigate the risk factors and clinical impact of newly developed sarcopenia after surgical resection on the prognosis of patients undergoing radical gastrectomy for GC.

Methods

The clinicopathological data of 425 consecutive patients with GC who underwent surgical resection were reviewed. Their skeletal muscle mass and abdominal fat volume were measured using abdominal CT.

Results

Forty-two of them (9.9%) were diagnosed with preoperative

sarcopenia. There was no significant difference in the 5-year overall and disease-free survival between preoperative sarcopenic and non-sarcopenic groups. Among the 381 patients without sarcopenia, 48 (12.6%) were diagnosed with newly developed sarcopenia 1 year after gastric resection. The newly developed sarcopenic group showed a higher proportion of women, more undifferentiated tumors, lower hemoglobin levels, lower proportion of alcoholics and smokers, and diabetes mellitus compared with the non-sarcopenic group. They showed more total fat areas and lower visceral fat area/subcutaneous fat area ratio on abdominal CT. There was no significant difference in the 5-year overall and disease-free survival among the non-sarcopenic, newly developed sarcopenic, and sarcopenic groups. Female sex, advanced stage, positive lymph node involvement, and presence of diabetes mellitus were significant risk factors of newly developed sarcopenia after surgery. Preoperative body fat volume and postoperative muscle mass were significantly correlated ($\rho=0.296$, $p<0.001$); however, only BMI was significantly associated with long-term survival.

Conclusion

Although newly developed sarcopenia after surgery did not affect the survival rate, patients with high sarcopenia risks after surgery may require early nutritional support.

#255 - Case Report

WARM AUTOIMMUNE HAEMOLYTIC ANAEMIA COMPLICATED BY ARTERIAL AND VENOUS THROMBOSES

Ela Curcic, Ozrenka Zlopasa, Sara Sundalic, Mia Rora, Radovan Radonic, Ana Vujaklija Brajkovic

University Hospital Centre Zagreb, Department of Internal Medicine, Division of Intensive Care Medicine, Zagreb, Croatia

Introduction

Warm autoimmune haemolytic anaemia (WA-AIHA) is a rare disorder caused by warm autoantibodies directed towards erythrocyte membrane antigens. The diagnosis is confirmed with laboratory findings of haemolysis and serologically with a positive direct antiglobulin test (DAT). Corticosteroids remain the mainstay of treatment, followed by rituximab or splenectomy in the refractory cases. Furthermore, both arterial and venous vascular events, including pulmonary embolism as the most lethal, have been reported in patients with WA-AIHA, raising the question whether patients with WA-AIHA should also receive prophylactic anticoagulation during disease exacerbations.

Case description

A 37-year-old male with no prior medical history presented to the emergency department due to fatigue, palpitations and cola-coloured urine. Laboratory workup revealed severe haemolytic anaemia (haemoglobin 58 g/L, lactate dehydrogenase 1962 U/L, indirect bilirubin 206 μ mol/L, haptoglobin <0.1 g/L) with few

spherocytes on the peripheral blood film. DAT was IgG1 positive, so the diagnosis of warm AIHA was established. Treatment with high-dose methylprednisolone and cyclophosphamide was initiated, but the patient's clinical condition deteriorated, with the development of sensorimotor dysphasia, right arm paresis, abdominal pain and swelling of the left leg. Computed tomography angiography showed partial occlusion of the left middle cerebral artery, while computed tomography of the abdomen revealed multiple infarcts of the kidneys and spleen. Doppler ultrasound confirmed thrombosis of the left popliteal vein. No underlying cause was identified. Rituximab was introduced as a second line therapy, together with low-molecular-weight-heparin, leading to complete serological and haematological remission. Unfortunately, the neurological deficit persisted.

Discussion

We report a case of a young male with idiopathic WA-AIHA of severe onset and uncommon course. The case represents a rare example of both venous and arterial thromboses in a previously healthy individual with no classical risk factors for the venous thromboembolism (Padua Prediction Score 1), pointing towards close association between haemolysis itself and thrombosis. Although the aforementioned relationship is well-known, there are still no defined criteria for the stratification of patients at increased thrombotic risk. Therefore, the institution of the prophylactic anticoagulation in this subset of patients is still mainly clinician, and not evidence-guided.

#258 - Case Report

UPPER EXTREMITY DEEP VEIN THROMBOSIS AS A SIGN OF OCCULT CANCER

Mariana Soares, Iolanda Oliveira, Margarida Massas, Sara Correia, Carmen Corzo, Conceição Barata
Hospital Espírito Santo de Évora, Évora, Portugal

Introduction

The incidence of Upper Extremity Deep Vein Thrombosis (UEDVT) has been increasing, representing 10% of the cases of deep vein thrombosis. The most common affected vessels are axillary and subclavian veins. Cancer represents the third most frequent etiology, right after effort induced thrombosis (Paget-von Schrötter syndrome) and central venous catheterization of the subclavian vein. The association between lower-extremity venous thrombosis and cancer is well-established, and there are some studies starting to recognise UEDVT as a marker of cancer, most frequently lung cancer, representing unfavourable prognostic factor for all-cause mortality in these patients. We present a case of UEDVT, that conduced to the diagnosis of neuroendocrine lung cancer.

Case description

A 57-years-old male presented at emergency department due to oedema and pain of the left upper limb, progressing during the previous month. Besides heavy smoking habits, he had no other pathologic history. The physical exam identified oedema of the left

upper limb, with visible collateral circulation, an axillary adenopathic conglomerate and reduced pulmonary sounds in the lower left hemithorax. The patient was admitted to our service, due to the hypothesis of UEDVT, and started anticoagulant therapy with low molecular weight heparin. The doppler of the left upper limb was confirmatory of thrombosis of the subclavian and axillary veins. The thorax CT identified a nodular structure of 36 mm of the left upper lobe, atelectasis of the left inferior lobe and multiple adenopathies. The axillary adenopathic conglomerate was biopsied, diagnosing lymph node metastasis of neuroendocrine carcinoma of the lung. The staging CT showed no signs of distance metastasis. The patient was referred to the Oncology decision consult, starting treatment with chemotherapy and follow-up at Pneumology consult.

Discussion

UEDVT must be suspected in the presence of obstructive symptoms of the upper limb. The diagnostic investigation must include study of occult cancer, starting with thoracic study, as it is one of the most frequent etiologies. Anticoagulation should start immediately, due to the risk of developing compartment syndrome. Some studies demonstrated an absolute risk of any cancer of 5.4% in the six months after UEDVT, showing the importance of the follow-up, even in the absence of cancer diagnosis at the time of the thrombotic event.

#260 - Case Report

A CASE OF ZOPICLONE OVERDOSE INDUCED METHAEMOGLOBINAEMIA

Ei Ei Phyu, Htet Phyo Than

Nottingham University Hospitals NHS Trust, Nottingham, United Kingdom

Introduction

Methaemoglobinaemia is a condition when iron is oxidised to ferric state. It can be caused by congenital or acquired. There are some common medications and chemicals such as nitrates, nitrites, aniline, dapsone, phenazopyridine, benzocaine and chlorates. Zopiclone is not a common medication, but there are few cases stating that zopiclone can also lead to methemoglobinaemia.

Case description

A 37-year-old lady with past medical history of chronic insomnia who was known to mental health team was taking alprazolam 0.25 OM PRN and zopiclone 15 mg ON PRN. She presented to emergency department 12 hours after staggered drug overdose. She claimed that she took 250 tablets of 15 mg zopiclone over 4-5 hours. There was central and peripheral cyanosis on physical examination. Her oxygen saturation was 89% on room air, but her partial pressure of oxygen according to arterial blood gas was 83 mmHg (11.06 kPa). Given her low oxygen saturation with normal partial pressure of oxygen and her presenting complaint, she was suspected for methaemoglobinaemia. Her methaemoglobin level showed 38.6% after 24 hours of ingestion. Shortly after first dose of methylene blue with high dose oral ascorbic acid, her methaemoglobin level returned to 4.5% and her oxygen saturation

returned to normal. Methaemoglobin level on the following day was 2.6%. She was discharged back to mental health care.

Discussion

There was two cases report (Fung HT, 2008) that methemoglobinemia can be caused by acute zopiclone overdose. In our patient, there were no other identifiable causes except zopiclone, which might be the potential cause of methemoglobinemia. Therefore, our case also suggests that zopiclone overdose can induce methaemoglobinaemia.

Reference

1. Fung HT, e. (2008). Two cases of methemoglobinemia following zopiclone ingestion. - PubMed - NCBI. [online] Ncbi.nlm.nih.gov. Available at: <https://www.ncbi.nlm.nih.gov/pubmed/18259966> [Accessed 17 Apr. 2019].

#264 - Medical Image

RAINDROP SKULL: RARE BUT GOLD

Lília Castelo Branco, Ana Margarida Coelho, Cátia Marisa Loureiro Pereira, Elisabete Pinelo, Eugénia Madureira

Internal Medicine Department, Unidade Hospitalar de Bragança, Unidade Local de Saúde do Nordeste, Bragança, Portugal

Clinical summary

Multiple myeloma (MM) is a neoplastic proliferation of a clonal population of plasma cells, which produces a monoclonal protein. A 77-year-old man presented to the emergency department with 3 months history of fatigue, weight loss, and diffuse bone pain. Laboratory workup revealed pancytopenia, hypercalcemia (12.4g/dL), renal dysfunction, elevated serum IgG (50.61 g/dl) and IgA and IgM suppression. A skeletal survey showed diffuse osteopenia with numerous radiolucent lesions in mandible, sternum, ribs, femurs and on the skull, these with "raindrop skull" appearance (pattern of lytic lesions that resemble raindrops hitting a surface and splashing). Bone marrow biopsy showed increased plasma cells (65%). He was diagnosed with IgG MM and was referred to Hematology after initial management.

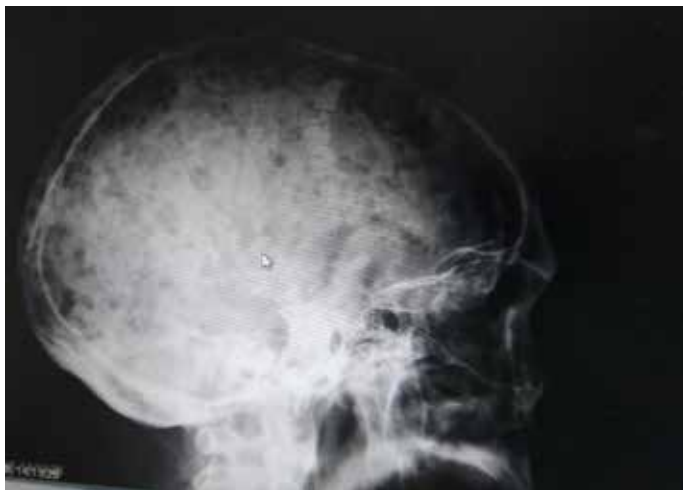

Figure #264.

#270 - Case Report

ACUTE KIDNEY INJURY AS THE INITIAL MANIFESTATION OF BURKITT LYMPHOMA – A HEMATOLOGIC EMERGENCY

Bela Machado¹, Rebeca Brito², Hugo Parreira², Marcos Lemos², Paula Sousa E Santos², Aida Botelho De Sousa²

¹ Internal Medicine Department - Funchal Central Hospital, Funchal, Portugal

² Hematology Department - Hospital Centre of Central Lisbon, Lisbon, Portugal

Introduction

Burkitt lymphoma is classified in 3 subtypes according to epidemiology: an endemic African form occurring mainly in children, a sporadic form affecting young adult caucasians and an immunodeficiency-associated form. They share an identical histology, as well as a male prevalence. Clinical presentation is variable but large tumor masses are typical, frequently exhibiting spontaneous tumor lysis.

Case description

We report the case of a caucasian 60 year-old female, with no history of past diseases, who presented to the emergency room complaining of a low urinary output in the previous 24h. She had no other symptoms and physical examination was unremarkable. Laboratory tests showed leukocytosis (90550/ μ L) with atypical lymphoid cells, acute kidney injury (creatinine 7.6-10 mg/dL, urea 89-211 mg/dL), hyperuricemia (28 mg/dL), a very high lactate dehydrogenase (16533 U/L) and metabolic acidosis. Serology for the human immunodeficiency virus was negative. An abdominal CT scan revealed bilateral renal masses involving renal vessels and multiple lymphadenopathies. Bone marrow examination showed 80% Burkitt cells, t (8;14) positive. The patient was started on renal replacement therapy, hypouricemic therapy (rasburicase) and chemotherapy with hyperfractionated cyclophosphamide, vincristine, doxorubicin and dexamethasone (Hyper-CVAD), with limited hydration due to acute kidney injury. Tumor lysis syndrome developed 48 hours later, with severe electrolytic abnormalities (potassium 7.0mEq/L, calcium 6.5mg/dL, phosphorus 14.4mg/dL), a lactate dehydrogenase of 36577U/L and unbalanced metabolic acidosis. Although the patient was transferred to an intensive care unit for vasopressor, respiratory and dialytic support, she died within 24 hours.

Discussion

Burkitt lymphoma is an extremely aggressive B cell tumor with a very high cellular turn over, often leading to spontaneous tumor lysis syndrome and acute kidney injury, which makes it an hematological emergency. This clinical case intends to highlight the disease characteristics and the importance of early intensive fluid therapy, which in this case was compromised by the acute kidney injury, with a fatal outcome despite early dialysis.

#274 - Case Report

YOUNG MAN WITH ANEMIA - AN UNEXPECTED DISCOVERY

Luciana Faria, Catarina Patronillo, Florisa González, Teresa Pinto
Centro Hospitalar Póvoa de Varzim/Vila do Conde, Vila Do Conde,
Portugal

Introduction

Vitamin B12 deficit is an entity with a wide range of etiologies that imply a very comprehensive diagnostic approach. Given the large reserves, years of inadequate intake or poor absorption are necessary for the onset of symptoms.

Case description

A 42-year-old male with past medical history of gastroesophageal reflux disease, overweight and alcohol abuse (59 g/alcohol/day). He was referred to the emergency department due to severe anemia (hemoglobin 4.7 g/dL). He complained, to, about dry cough with 1 month of evolution, with partial recovery after corticoid and antibiotic therapy. On physical examination he was feverish, pale, with mouth ulcers, without respiratory effort and normal pulmonary auscultation. No adenopathies were palpable. Analytically, macrocytic/hyperchromic anemia was confirmed and showed leucopenia and accentuated anisopoikilocytosis with macrocytes, dacryocytes, elliptocytes, without morphological alterations on leukocytes. The remaining study showed low reticulocyte index, non-immune hemolysis and low vitamin B12 (62.9 pg/mL). No infectious or autoimmune causes were found. CT imaging showed an infectious process in resolution in the right lower lobe of the lung and homogenous hepatosplenomegaly. Upper digestive endoscopy and colonoscopy were performed. Gastric biopsy showed chronic mild gastritis with no signs of activity, with mild atrophy and reactive foveolar hyperplasia. Duodenal biopsy with slight chronic inflammatory infiltrate, preserved architecture and no intraepithelial lymphocytes. Terminal ileum biopsy showed reactive lymphoid nodular hyperplasia. A multifactorial cause of vitamin B12 was assumed: alcohol toxicity and possible contribution of nodular lymphoid hyperplasia of terminal ileum, exacerbated by the infectious process in resolution. In the latest referred, no microorganisms were found. Intramuscular and posterior oral vitamin B12 was administrated and counselling about alcohol withdrawal. Treatment resulted in a total resolution of the symptoms, deficit and cytopenias. Patient was followed and performed a virtual endoscopy that excluded malignant process associated to lymphoid nodular hyperplasia.

Discussion

This is an interesting case because the discovery of nodular hyperplasia has raised doubts about its contribution to vitamin malabsorption in the terminal ileum, and to date no cases have been described. Further this pathology is a precursor of intestinal lymphoma involving the active search in other locations of the gastrointestinal tract.

#284 - Case Report

MEDIASTINIC BULKY MASS

Flávia Marília Ferreira Santos, Sónia Santos, Ana Luísa Albuquerque, Maria João Palavras, Vera Frazão
Centro Hospitalar de Leiria, Leiria, Portugal

Introduction

Chest pain is one of the most prevalent causes of emergency referral. The differential diagnosis is extensive including several life-threatening conditions such as acute coronary syndrome, aortic dissection, pneumothorax, esophageic rupture and pulmonary embolism.

Case description

We present the a case of a 51-year-old male with past medical history of smoking and hemorrhagic stroke in 2015 and consequent vascular epilepsy, sleep apnea, anemia, atrial fibrillation and hypertension. He presented with a 1-week onset of fever (T 39°C), chest pain with nocturnal worsening, non-productive cough and slight edema of the lower limbs. Clinical examination revealed fever (T 38.8°C), rales at the the lower third of both lungs and edema in the distal third of the lower limbs. The electrocardiogram showed a sinus rhythm, without evidence of ischemia. Blood analysis showed leukocytosis and C reactive protein of 150 mg/L. Hb 11.6g/dL, nt-pro-BNP 2460 pg/mL and lactate dehydrogenase 1125 U/L. High-sensitivity troponin was negative. Blood gas analysis showed hypoxemia and hypocapnia. Chest X ray with evidence of mediastinum enlargement conditioning tracheal right-deviation and pleural effusion. It was assumed an inferior respiratory infection with associated heart failure and the patient started B-lactamic antibiotherapy. Chest computed tomography showed a large infiltrative mass in the anterior and superior mediastinum adjacent to the mediastinal vessels and the sternum with 11x7.8 cm. With pericardial effusion and small bilateral pleural effusion. Several Mediastinal adenopathies were reported. The mass showed criteria of a mediastinic bulky mass. Mediastinal mass biopsy was diagnostic of Large B Cell Lymphoma of the germinative line. Staging - Stage II, IPI 1, without bone marrow involvement. The patient started chemotherapy.

Discussion

The authors intend to show with this clinical case the need for a thorough evaluation of the clinical history, clinical examination and results of the complementary diagnostic tests of each patient, to improve accuracy in diagnosis and treatment strategies.

#293 - Case Report

AMILOYDOSIS AND DYSPHAGIA

Nuno Melo, Rita Moça, Filipa Gomes, Jorge Almeida

Centro Hospitalar e Universitário de São João, Porto, Portugal

Introduction

Amyloidosis is a multisystemic disease that manifests in several ways depending on the most affected system. Dysphagia as the first symptom is rare.

Case description

80 years old male, non smoker, with history of hypertension, dyslipidemia and moderate alcohol consumption in the past. Brought to the emergency department with acute dyspnoea and respiratory distress, beginning 6 hours after performing a barium swallow for investigation of a 4 months duration' dysphagia. No history of fever, cough, syncope or thoracic pain. On physical examination, tachypnoea and bronchospasm and hypoxaemia (paO₂: 55 mmHg with fiO₂:21%). Pulmonary X-ray showed barium contrast in the tracheobronchial tree, later aspirated by bronchofibroscope. He was admitted to the general ward with aspiration pneumonitis and dysphagia of uncertain etiology. Recovery of hypoxaemia with corticosteroid therapy. Upper gastrointestinal endoscopy and thoracoabdominopelvic CT excluded intrinsic and extrinsic esophageal structural lesions. A videofluoroscopy confirmed oropharyngeal dysphagia with abundant salivary stasis. MRI excluded brain or spinal cord injuries. Peripheral electromyography showed myopathy and excluded nerve damage. Muscle enzymes were persistently normal, the immunological panel was negative and endocrine myopathy was excluded. Serum immunofixation showed IgA/Kappa monoclonal gammopathy, though protein electrophoresis was normal. Amyloid substance was identified in abdominal fat and muscle biopsy, predominantly amyloid AA but also AL. Skeletal radiography excluded lytic lesions. He was waiting for a bone marrow examination when he had a cardiorespiratory arrest with no recovery. No further characterization of the amyloid substance was requested in face of the clinical outcome.

Discussion

Dysphagia is a common symptom in the elderly with great impact on quality of life and harmful consequences such as malnutrition. The etiological investigation is difficult given the complexity of the swallowing mechanism and multiplicity of causes. Muscle attainment by amyloidosis is common, usually with global weakness. Dysphagia can occur in up to 19% of patients.

#295 - Case Report

THROMBOTIC THROMBOCYTOPENIC PURPURA – AN INDOLENT PRESENTATION

Nuno Melo, João Paulo Caldas, Juliana Bastos, Sofia Pereira, Jorge Almeida

Centro Hospitalar e Universitário de São João, Porto, Portugal

Introduction

Thrombotic thrombocytopenic purpura (TTP) is a thrombotic microangiopathy caused by reduced ADAMTS13 activity. It is a medical emergency and can be fatal if not treated in a timely manner.

Case description

Female, 35 years old. No prior medical history. She was referred to the emergency department for petechiae associated with significant metrorrhagia in the last 2 days. She denied other blood losses, drug consumption, acute diarrhea or other symptoms of infection and arthralgias. No signs of infection on physical examination. On blood analyses, thrombocytopenia (Plt: 25,000/mm³) and mild anemia (Hgb: 11.8 g/dl), without leukocytosis, coagulopathy, renal dysfunction or elevation of inflammatory markers. Abdominal ultrasound excluded splenomegaly. She was discharged to an hematology clinic with the diagnosis of immune thrombocytopenia, medicated with prednisolone 1 mg/kg/day. No recovery at first consultation and progressive worsening of anemia in the following weeks. On blood analyses, reticulocytosis, increasing levels of lactic dehydrogenase, indirect hyperbilirubinemia and decreased haptoglobin. Coombs test and autoimmune panel (ANA, anti-dsDNA, anticardiolipins, Anti-ENA and lupus inhibitor) were both negative. Serologies for Herpes virus, Parvovirus, hepatitis B and C and HIV were also negative. On blood smear anisopoikilocytosis and 3-5 schizocytes per large magnification field. ADAMTS13 assay showed decreased activity, compatible with the diagnosis of TTP. She was admitted to start plasmapheresis associated with steroid therapy (pulse of methylprednisolone 1 g for 3 days followed by prednisolone 1 mg/kg/day) with improvement of anemia and thrombocytopenia. No further blood loss. Renal function persistently normal. She was discharged to the hematology clinic with mild anemia (Hgb: 10 g/dl) and no thrombocytopenia under steroid therapy in a tapered manner. No subsequent relapses. New assay of ADAMTS13 after stopping prednisolone showed normal activity which corroborates the diagnosis of acquired TTP.

Discussion

This case illustrates a more indolent presentation of TTP with no symptoms other than those resulting from thrombocytopenia. Although it is a rare disease, it is a diagnosis that should be taken into account in the differential diagnosis of thrombocytopenia, even in less symptomatic patients.

#314 - Case Report

PAINLESS ELBOW EDEMA: AN INTERESTING CASE OF A RARE LYMPHADENOPATHY SITE

Aggeliki Georgopoulou¹, Christos Sifarikas¹, Aristeidis Tsakanikas¹, Ioannis Legakis¹, Evangelos Fragiadis², Maria Mylona¹

¹ 1st Department of Propaedeutic & Internal Medicine, Laiko General Hospital, Athens University Medical School, Athens, Greece

² 1st University Department of Urology, Laiko General Hospital, Athens, Greece

Introduction

Epitrochlear lymphadenopathy (EL) is believed to be associated with various distinct infectious and non-infectious etiologies such as tuberculosis, cat-scratch or HIV disease, autoimmune disorders such as rheumatoid arthritis or sarcoidosis and rarely with solid organ malignancies (upper limb melanomas, lung or breast cancer) or lymphomas (both Hodgkin and non-Hodgkin' s). Herein we present an interesting case of a patient with painless right elbow edema and a concomitant underlying lung cancer.

Case description

A 85-year old Caucasian man, current heavy smoker (>160 pack-years), with a history of chronic obstructive pulmonary disease and a resected bladder adenocarcinoma under hormonal treatment , was referred to our outpatient clinic due to progressive worsening of painless right elbow edema without erythema for the last ten days, with no history of trauma in the affected anatomic area. He was afebrile and physical examination was unremarkable apart from diffusely decreased breath sounds and wheezing. Blood chemistry revealed mildly elevated inflammation markers. He underwent a right elbow/forearm ultrasound and triplex, which revealed two enlarged epitrochlear lymph nodes ~1.5x1 cm and 0.9x0.5 cm respectively and absence of thrombosis. He was initially treated with a 5-day antibiotic therapy of moxifloxacin 400 mg x1 per os with no clinical response. The patient' s full body CT scan revealed a metastatic to the liver and thoracic spine lung cancer, while his lymph node biopsy showed malignant infiltration from lung adenocarcinoma. The patient died before receiving chemotherapy.

Discussion

EL is a rare entity and an unusual site of lymphadenopathy, which should not be underestimated. Clinicians and ultrasound operators are usually not adequately familiar with the anatomic and pathologic aspects of the epitrochlear lymph nodal station and this is mainly because in clinical practice the axilla is commonly considered the primary lymphatic target of all disorders (inflammatory, cancerous, etc.) involving the upper extremity. The examination of epitrochlear nodes should therefore form part of the routine physical assessment of any ill patient, especially when malignancy is highly suspected.

#326 - Medical Image

CRIZOTINIB ASSOCIATED WITH GROUND-GLASS OPACITY PATTERN OF INTERSTITIAL LUNG DISEASE

João Costelha¹, Manuel Magalhães²

¹ Unidade Local de Saúde do Alto Minho, Ponte De Lima, Portugal

² Centro Hospitalar do Porto, Porto, Portugal

Clinical summary

The field of oncology has entered an era of molecularly targeted therapy. Compared with cytotoxic chemotherapy, agents such as Crizotinib, an oral tyrosine kinase inhibitor, offer the promise of improved outcomes with fewer toxicities. However, these agents often target multiple pathways, it is important to recognize both on-target and off-target effects so as to anticipate and treat toxicities that arise. In the medical image presented are visible extensive areas with depolyzed glass densification and thickening of interlobular septa with diffuse alveolar damage, findings compatible with a toxic pneumonitis in a patient treated with Crizotinib for a relapsing lung adenocarcinoma. Crizotinib' s interstitial lung disease, although rare, can occur at any time and requires close monitoring and treatment.

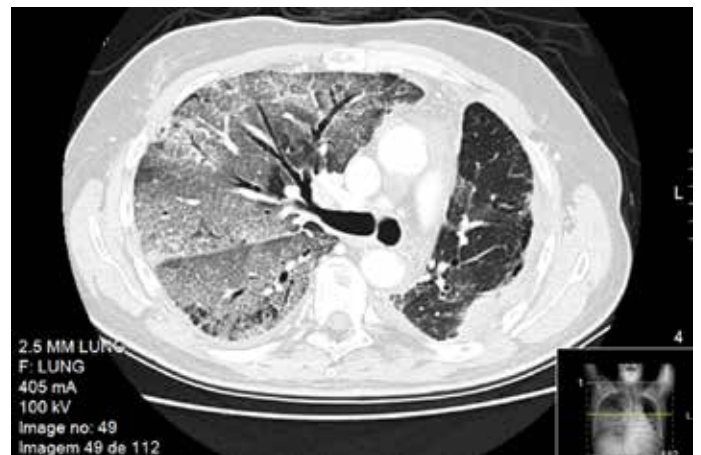

Figure #326.

#335 - Case Report

HERPES ZOSTER AND OCCULT CANCER: A TRUE LINK OR DETECTION BIAS?

Raquel Rodrigues Santos, Carolina Paiva, Helena Greenfield, Mariana Taveira

Hospital Pedro Hispano, Matosinhos, Portugal

Introduction

Herpes zoster (HZ) is a dermatologic manifestation caused by varicella-zoster virus that becomes active after being latent in the sensory ganglia and dorsal nerve roots. The prevalence of HZ is higher in immunocompromised patients including those with cancer. However, the value of HZ diagnosis as a marker of occult cancer remains unknown.

Case description

The authors present the case of a 67 year-old man with no relevant past history. He was hospitalized for herpes zoster of the right hemiface with extension to the right eyelid and scalp. No other symptoms were reported and the remaining physical examination was normal. The patient was treated with a 14 day course of acyclovir for HZ with improvement of cutaneous lesions. An investigation was carried out to search for potential causes of immunosuppression that predispose to HZ. Infectious and immunologic causes were excluded. The study to rule out neoplastic causes of immunosuppression included a normal PSA, an innocent abdominal ultrasound and a chest radiography that showed a hypotransparency in the peripheral region of the right hemithorax. A thoracoabdominopelvic computed tomography was performed and revealed a spiculated solitary nodule in the periphery of the middle lobe of right lung. Biopsy of the nodule was compatible with pulmonary adenocarcinoma. The staging did not find secondary lesions and the patient was treated with surgery.

Discussion

Many studies have attempted to understand the link between HZ and early stage cancer with inconsistent results. This raises the question of whether cancer screening for patients with HZ is cost-effective.

In this case, the patient had no risk factors for malignancy other than his age but the investigation lead to the diagnosis of lung cancer in an early stage influencing its prognosis. More studies are needed to clarify the relation between HZ and cancer, the underlying mechanisms behind this potential link and which patients affected by HZ benefit from a more extensive study to detect occult malignancy.

#341 - Case Report

PRURIGO NODULARIS

Mafalda Ferreira, Ana Rita Nogueira, José Eduardo Mateus, Sofia Brazão, Helder Esperto, Manuel Teixeira Veríssimo, Armando Carvalho

Centro Hospitalar e Universitário de Coimbra, Coimbra, Portugal

Introduction

Paraneoplastic pruritus may manifest before or during the course of a hematological disease, being present in about 30% of Hodgkin's lymphomas and, although rare, may be associated with solid tumors. It is not due to infiltration or compression by the tumor and usually regresses after treatment of the underlying disease.

Case description

A 42-year-old woman was hospitalized for widespread lymph node enlargement and generalized severe pruritus for the past six months, without relief or apparent precipitating factors. She had multiple ulcerated and escorted cutaneous lesions, sparing the back. There were no lesions on the mucosa, acarine

ridges or scabiotic nodules. She had also several episodes of pyelonephritis with hydronephrosis secondary to extrinsic obstruction due to adenopathy/tumor invasion of the ureter, with need of nephrostomy. Ureter cytology and bone biopsy allowed the diagnosis of Hodgkin lymphoma (Ann Arbor Stage IVB, IPS of 3) to be established and chemotherapy was started with ABVD.

After two cycles there was a partial hematological response. However, she maintained severe pruritus that motivated multiple admissions to the ED, with consultations by internal medicine, haematology, dermatology, neurology and psychiatry. She was mainly medicated with psychotropic drugs but maintained pruritus with impairment of sleep pattern and mood.

After stabilization of the underlying disease, treatment with phototherapy (PUVA) showed mild improvement after each session. Four months after the diagnosis she developed acute pyelonephritis complicated by severe sepsis and died.

Discussion

The magnitude of pruritus had significant consequences on the quality of life of the patient with further deterioration of emotional and cognitive state.

There are few studies that prove pharmacological efficacy in this type of pruritus. It is usually observed that it disappears with the treatment of the underlying disease, and it is generally necessary to add symptomatic pharmacological treatment. Some studies have shown results with UV therapy in systemic diseases and T-cell lymphoma, yet there is no evidence in systemic lymphoma.

#344 - Abstract

STUDY OF IRON DEFICIENCY ANEMIA IN INTERNAL MEDICINE CONSULTATION

Susana Vicente Rodrigues¹, Diego José Gudiño Aguirre², Maria Yolanda Torres Barroso¹, Pedro Laynez Cerdeña¹, Jose Alejandro Medina Garcia¹

¹ Servicio Medicina Interna, Hospital Universitario Nuestra Señora De La Candelaria, Santa Cruz De Tenerife, Spain

² Servicio Medicina Interna, Hospital Universitario Nuestra Señora De La Candelaria, Santa Cruz De Tenerife, Spain

Background

Anemia is one of the pathologies with special relevance for Internal Medicine Services. The most frequent causes of anemia in patients treated by Internal Medicine, both at the hospital and consultation, are iron deficiency and anemia associated with chronic disorders.

Aims: To analyze the most frequent causes of iron deficiency anemia in patients evaluated in Internal Medicine consultation, the prescribed treatment, the characteristics of the affected population, and the most profitable tests for the etiological diagnosis.

Methods

Descriptive study of 6 months duration in the patients with a diagnosis of iron deficiency anemia studied in a high resolution

consultation of Internal Medicine through the consultation reports, which presented the diagnosis of anemia to study. A data collection protocol was made that included demographic characteristics of the patients, analytical data, diagnosis and treatment.

Results

This series included 127 patients, of whom 81 (63.77%) were women and 46 (36.22%) men, with an average age of 70.1 years. The most prevalent symptom was asthenia, followed by gastrointestinal symptoms, especially hemorrhagic externalization. The patients had come to the consultation sent from: emergencies, primary care, hospitalization plant and internal medicine consultations. In total, the mean of hemoglobin was 7.4 mg/dL. During the study of iron deficiency anemia it was considered secondary to digestive losses in 93 patients (73.22%) of which 6 (6.45%) were digestive cancer and 87 (93.54%) other digestive causes of which the most frequent were the angiodysplasias that were electrocoagulated with argon. 24 patients (18.89%) the cause was gynecological, 6 patients with a history of bariatric surgery (4.72%) and 4 patients with poor intakes (3.14%). Of all the patients, 12 (9.44%) will need chronic intravenous iron for non-treatable causes. After the diagnosis, the indicated treatment was: oral iron in 29 (22.83%) patients and intravenous iron in 98 (77.16%) patients. During the study we had 3 adverse reactions (2.7%) to iron treatment.

Conclusion

The majority of the patients in our series were women referred from the Emergency Services and Primary Care, which had hemoglobin < 7.4 g / dl to which they were performed gastroscopy and colonoscopy, were diagnosed with iron deficiency anemia due to digestive losses and they required treatment with intravenous iron in its majority.

#347 - Case Report

FEVER, ANEMIA AND SPLENOMEGALY: WHO IS THE LEAD?

Chiara Ferrante, [Andrea Pizzuto](#), Eloise Beggiato, Simona Maria Sipari Merlo, Antonio Casella, Giuseppe Montrucchio

AOU Città della Salute e della Scienza di Torino - Università degli Studi di Torino, Torino, Italy

Introduction

Fever, splenomegaly and anemia are common findings in a clinical setting with a wide spectrum of etiologies. It is important to establish a correct cause-effect relation.

Case description

We reported a case report of a 36-years-old male presented with fever and left quadrant pain. He had two previous hospitalizations for the same reason with negative investigations (including bone marrow and peripheral blood smears). At admission: hepatosplenomegaly (spleen size 20 cm); Hb 11.8 g/dL, WBC

3220/μL, PLT 150000/μL, PCR 128 mg/L, LDH 1075 U/L, normal bilirubin level and liver function. Infectious and onco-hematologic exams were negative. Although we observed a clinical improvement without antibiotic therapy, hemoglobin level remained low. After further investigation a non-autoimmune hemolytic anemia was found. We performed the osmotic fragility tests (Pink test, AGLP) with clear evidence of spherocytosis, also showed in the new blood smear test.

Discussion

Fever and splenomegaly were the most striking signs, whilst the mild anemia was interpreted as alongside laboratory finding. At first we deemed an hemolytic etiology unlikely due to absence of hyperbilirubinemia and previous blood investigations results. When the diagnosis of hemolytic anemia was made, spherocytosis seemed improbable due to the normal MCHC value. The two osmotic fragility tests however, performed according to international guidelines, proved the spherocytosis. Eventually, we established the correct cause-effect relation: fever (likely viral) as the trigger event for hemolysis, splenomegaly as secondary to spherocytosis and hepatomegaly caused by the increased splenic blood inflow.

#379 - Case Report

ANTIPHOSPHOLIPID SYNDROME AND HODGKIN'S LYMPHOMA - WHAT'S THE RELATIONSHIP?

[Andreia Filipa Tavares](#), [Micaela Manuel](#), [Alexandra Castro](#)
CHEDV, Santa Maria Da Feira, Portugal

Introduction

In recent years the association between lymphoma and antiphospholipid syndrome (APS) has been reported. Both are pro-coagulant factors, which when present simultaneously increase the thrombotic risk of the patient. Lupus anticoagulant (ACL) is the antibody most frequently found in cases of APS and lymphoma. The negativity of ACL, after successful treatment of lymphoma, proves the relationship between the two.

Case description

A 57-year-old man, with a history of essential hypertension and deep venous thrombosis of the right lower limb after knee arthroscopy in May 2017, that had completed 5 months of hypocoagulation. Referred to the internal medicine consultation for arterial thrombosis of the right eye in March 2018. In the anamnesis, inflammatory rhythm lumbar pain were noted, with no other symptoms, including no symptoms B. The physical examination showed: hard, painless nodule with 3cm of greater axis, palpable in the left cervical region.

From the analytical study, we could highlight the following: prolonged activated partial thromboplastin time, 2 positive ACL assays (6 weeks interleaved) and persistent high sedimentation rate and C reactive protein. The remaining autoimmunity, viral and metabolic study were negative.

Computed axial tomography showed partial thrombosis of the vena cava, cervical and mediastinal adenomegalies, lytic lesions at the level of the iliac and lumbosacral spine, with a pathological fracture of L4; without hepatosplenomegaly. PET (positron emission tomography) confirmed the presence of hypermetabolic adenomegalies, with the same uptake of FDG-F18 in bone lesions. An excisional biopsy of the cervical ganglion was proceeded, whose pathological anatomy was shown to be Hodgkin's disease, a classical variant, subtype nodular sclerosis.

The diagnosis of APS was assumed, probably secondary to Hodgkin's lymphoma. The patient started hypocoagulation with enoxaparin at a therapeutic dose and is currently being treated with chemotherapy, with good response and evolution.

Discussion

This case demonstrates an unusual presentation of Hodgkin's lymphoma, in association with antiphospholipid syndrome, emphasizing the importance of the exclusion of secondary causes related to the latter.

#390 - Case Report TOO LATE?

Fábia Cruz, Rita Correia, Sandra Martin, Maria Eugénia André
Unidade Local de Saúde de Castelo Branco, Hospital Amato Lusitano,
Castelo Branco, Portugal

Introduction

As doctors we want to do as much as possible for our patients. But when the patient arrives too late, the feeling of disability is devastating. And then our fight against time begun.

Case description

Woman, 67 years old, independent, hypertensive controlled that came to the emergency department for paresthesia, upper limbs weaknesses and progressive tiredness associated to unspecific speech changes and memory loss in the past week. During the observation, we found slight erasure of the right labial commissure, muscular strength 5/5 in all muscles and aphasia expression. Analytically, we found hypercalcemia (11.08 mg/dl), hypophosphatemia (4.80 mg/dl) and parathyroid hormone decrease (6.60 pg/ml). Urinalysis without changes. Computed tomography (CT) of the head revealed "extensive area of vasogenic edema in the left cerebral hemisphere parenchyma, a small nodular lesion at the front head with signs of mass effect with regional sulcal deletion and partial collapse of the left ventricle and contralateral midline deviation. Suggestive changes of secondary deposits from neoplastic origin". Magnetic resonance imaging from the head revealed multiple millimetric lesions occupying intra-axial space across the 2 hemispheres surrounded by vasogenic edema with mass effect over the left ventricle which determines compatible lesions with metastases. For the primary lesion recognition, a CT to thorax-abdomen-pelvis was done that revealed millimetric dispersed nodular formations

across the 2 hemithorax that suggests metastatic lesions; pleural metastasis and left kidney voluminous intraparenchymal lesion making prociidence in the renal contour, that measures 76x83x94 mm, with heterogeneous enhancement compatible with primitive lesion. Patient was further assigned to Urology.

Discussion

This case demonstrates the endocrine changes and brain metastases as first manifestations of advanced renal tumor. The referred symptomatology (paresthesia, weakness and tiredness) favors hypercalcemia (probable bone metastasis) with further development of secondary hypoparathyroidism and then hyperphosphatemia; aphasia expression, memory loss and erasure of the right labial commissure are suggestive of local involvement from the brain metastases. Patient never demonstrated symptoms of kidney disease and urinalysis didn't reveal any changes. Renal cancer and metastases presented an insidious evolution, however its manifestations were late but quickly progressive.

Will it be... too late?

#414 - Case Report GUMS, SKIN AND BLOOD MAKE THE DIAGNOSIS

Patrícia Varela Ramos, Ana Isabel Oliveira, Madalena Paulino, Ana Palricas, Ana Nunes, José Barata
Vila Franca de Xira Hospital, Vila Franca De Xira, Portugal

Introduction

Manifestations of acute myelomonocytic leukemia may result from tumor or from paraneoplastic syndrome. The presence of gingival hyperplasia and skin lesions should increase suspicion for this entity.

Case description

A 52-year-old man with a history of obesity class III, arterial hypertension and hyperuricemia, went to the Emergency department with complaints of asthenia, anorexia, feverish and erythematous cutaneous lesions with 2 days of evolution. He also reported loss of 6 kg in 4 weeks.

At physical exam: temperature 38.2°C, BP 188/99 mmHg, pulse 99 ppm; gums hyperplasia in the lower jaw. On lower limbs presented with circular ecchymotic lesions with central crust, not pruritic; at the left one lesion with 1.5cm in diameter, at the right two lesions about 3 cm and 2 cm.

Laboratory test revealed anemia (Hb 12.8 g/dL), leukocytosis (41 500 μ l) with monocytes (27,390 μ l); thrombocytopenia (59,000 μ l); LDH (392 IU/L). Elevated creatinine (1.8 mg/dl), hypokalemia (2.81 mmol/L) and elevated CRP (2.93 mg/dL).

Chest x-ray showed a nodular image in the right perihilar region. The patient was admitted on Internal Medicine ward with suspicion of lymphoproliferative disorder.

Laboratory tests revealed decrease in folic acid (2.8 ng/mL) and transferrin (119 mg/dl), increased ferritin (1680 ng/mL); seric

protein electrophoresis revealed hypoalbuminemia (49.8 g/dL), slight increase of beta 2 (7.6 g/dL) and gamma globulins (23.8 g/dL), without monoclonal peaks. The peripheral blood smear showed 9% of blasts, many dysplastic monocytes, neutrophils and myelocytes.

Thoraco-abdomino-pelvic computed tomography revealed: hepatomegaly 21 cm and splenomegaly 16 cm.

The myelogram and bone biopsy were compatible with acute myeloid leukemia with 70% blasts sudan-black positive, FLT3 / ITD, NPM1, t(9;22) and 11q23 all negative.

He was transferred to the Hematology department and started chemotherapy with idarubicin and cytarabine.

Discussion

Cutaneous involvement occurs in up to 13% of patients with leukemia, more frequent in acute myelomonocytic leukemia with predominance of monocytic or myelomonocytic component. In these, gingival hyperplasia is also more common due to the infiltration of leukemic cells. Hypokalemia is a frequent laboratory finding in this subtype of leukemia, usually corrected after chemotherapy.

The recognition of clinical findings conjugated with the laboratory findings allows a suspicion of diagnosis and treatment, favoring the prognosis.

#417 - Case Report

PRIMARY MYELOFIBROSIS, A CAUSE OF ANEMIA AND CONSTITUTIONAL SYNDROME, SOMETIMES FORGOTTEN

Begoña Guerra Pérez¹, Juan Mora Delgado², Josefa Jiménez Arjona²

¹ Family Medicine, General Hospital of Jerez de la Frontera, Jerez De La Frontera, Spain

² Internal Medicine, General Hospital of Jerez de la Frontera, Jerez De La Frontera, Spain

Introduction

Chronic myeloproliferative neoplasms are a group of pathologies characterized by the clonal expansion of hematopoietic precursor cells and the consequent neoplastic production of mature cells of different lineage, with varying degree of maturation. It is very common to overlap with other more prevalent pathologies such as colorectal cancer, prolonging the diagnosis.

Case description

Male, 67 years old, without known allergies to drugs, ex-smoker, drinker of 1 glass of wine and beer daily, diabetes mellitus type 2 diagnosed 12 years ago, polymyalgia diagnosed 4 years ago without current treatment. He has undergone surgery for umbilical herniorrhaphy and parapharyngeal abscess. Her home treatment prior to the visit was metformin 850 mg/24 hours, ranitidine 150 mg/12 hours, oral iron, betahistine 16 mg, bimatoprost 120 mg. The patient consulted on several occasions to the emergency

service between June and July 2018 for asthenia and loss of 6 kg in two months. Two red blood cell concentrates were transfused and derived without study of anemia to external consultations of Internal Medicine for study.

During the study, the persistence of normocytic anemia was observed. In the biochemistry, elevation was observed in alkaline phosphatase (223U/L) and PCR (45 mg/L). Abdominal ecography: splenomegaly. The colonoscopy revealed a granular lateral extension of large size in the cecum and ascending colon of 4-5 cm compatible with colorectal cancer. Surgical treatment was decided, performing hemicolectomy, without adjuvant treatment. Thus, he re-entered the Internal Medicine Service. An echocardiogram was requested, showing a severely dilated left ventricle with severe ventricular dysfunction, severe aortic insufficiency due to aortic annulitis.

During admission, a family member informed us that the patient's father had died of leukemia after 8 years of evolution. Hematology was consulted and bone marrow aspiration and biopsy were performed, visualizing population of atypical megakaryocytes without abnormal increase in blasts CD34+, concluding in the diagnosis of myeloproliferative neoplasms type chronic myelofibrosis.

Discussion

Facing a constitutional syndrome with asthenia and weight loss, with normochromic normocytic anemia, associated with splenomegaly, it is necessary to think about possible myeloproliferative syndrome, since the rapid establishment of treatment in these patients is crucial to improve the prognosis which by itself it is usually bad.

#419 - Abstract

FEBRILE NEUTROPAENIA – 3-YEAR EXPERIENCE OF A DISTRICT HOSPITAL

Margarida Mouro¹, Marcelo Aveiro², Mariana Leal², Tatiana Rodrigues², Rosa Jorge²

¹ Infectious Diseases Department, Baixo Vouga Hospital Centre, Aveiro, Portugal

² Internal Medicine Department, Baixo Vouga Hospital Centre, Aveiro, Portugal

Background

Febrile neutropaenia (NF) is defined as an oral temperature of >38.3 °C or two consecutive readings of >38.0°C for 2h and an absolute neutrophil count of <0.5×10⁹/l, or expected to fall below. Currently, it's one of the most serious and frequent complications of chemotherapy (ChT).

Methods

A descriptive, retrospective observational study of patients followed at a district hospital, over a 3-year period, with diagnosis of NF was conducted.

Results

There were one hundred cases of NF, diagnosed in 93 patients. These were predominantly male (54%) with a median age of 65.8 [24-90] years, 75% of whom were hospitalized (median of 9 [3-80] days). Patients were mainly admitted (92%) via the emergency department. Among the 89% previously diagnosed with cancer, 25.8% of them had distant metastasis and 95.5% were currently under ChT. The most common types were breast cancer (25.8%) and lymphomas (21.3%), followed by lung and colorectal cancer (12.3% each). The mean neutrophil count at admission was $374.9 \times 10^9/l$, and at discharge $5543.0 \times 10^9/l$, with 66% of patients being administered G-CSF, 53% of whom at the admission day. Blood cultures were collected in 91% and urine cultures in 79% of cases, with 25% of patients presenting some microbiological isolate. Only 13% started antibiotics in the first hour of admission and more than half in the first 4 hours, mostly with carbapenems (38%), piperacillin/tazobactam (29%) or a 3rd generation cephalosporin (21%). The presumed focus of infection was respiratory in 52% of patients, followed by abdominal/gastrointestinal (13%) and urinary (11%). Eighteen percent had no identifiable focus. About 60% of patients exhibited relevant comorbidities, mainly cardiovascular disease (16%). At admission, 23% had renal insufficiency, 9% hepatic insufficiency and 5% both. Mucositis was observed in 15%. Eighty eight percent of the patients were submitted to isolation measures. Regarding outcomes, 19% died and 6% were transferred to another hospital. Mortality was associated with a higher mean age ($M=73.32$ vs. $M=64.07$; $p=0.005$) but not with cardiovascular disease, comorbidities, distant metastasis, mucositis or microbiological isolation.

Conclusion

Almost all patients with NF had cancer, with the vast majority under ChT. About 2/3 of the patients were prescribed G-CSF. Antibiotherapy initiation was delayed in most cases. Older age seems to be the most relevant risk factor associated with mortality in this group of patients.

#474 - Abstract

METASTASIS DESCRIPTION IN 227 PATIENTS WITH BREAST CANCER IN COLOMBIA

Jonnathan Rueda¹, Guillermo Andrés Herrera¹, Daniela Reyes¹, Jose Fernando Lozano¹, Daniel Giovanni Romero¹, Jesus Solier Insuasty^{1,2}

¹ Industrial University of Santander, Bucaramanga, Colombia

² Insuasty Oncología e Investigaciones SAS, Bucaramanga, Colombia

Background

Breast cancer positions as the primary type of cancer that affects women in Colombia. Describing individuals with advanced disease allows identifying some factors that influence the course of care for these patients. The objective of this study is to describe de sociodemographic, clinical and pathological characteristics

of women in stage IV breast cancer in two reference oncology centres in eastern Colombia.

Methods

Data coming from two oncology centers during the period 2010 - 2017 was analyzed descriptively. Including central tendency, univariate, bivariate measures and comparisons of proportions with Chi-square ($p < 0,1$) were assessed.

Results

We included 227 patients with a diagnosis of metastatic breast cancer. 88%(165) of the patients were classified as invasive ductal cancer, the mean Ki67 was 30% and the luminal A subtype was present in 41% (68). The average age at diagnosis of cancer and metastasis was 53.7 and 55.9 years respectively. The mean time between events was 2.2 years. 45% (84) of the patients had debuted with distant cancer in the first consultation with the oncologist. The frequency order of metastasis sites was: 1. bone (43%), 2. lung-pleura (20.4%) and 3. liver (10.7%). Moreover, there was metastasis in skin, ganglia and brain in 7% each. Most of the patients presented 2 different metastasis at the end of the observation, and non-ductal variants were associated with metastasis from the first consultation, and high histological grade was associated with death during follow-up ($p 0.05$).

Conclusion

This is the first description of metastatic breast cancer behavior in a Colombia. The ductal variant, luminal A, high grade, high proliferative index and bone metastasis were the most common characteristics found in women included in this study.

#482 - Case Report

FATAL METASTASES

Maria Inês Marques, Rita Nortadas, Rita Passos Coelho, Sara Ramalho, Letícia Santos

Hospital Garcia de Orta, Almada, Portugal

Introduction

Spontaneous hepatic hemorrhage is a rare but potentially fatal condition which results from a breach in the hepatic parenchyma that occurs without an external cause. This is usually a consequence of an underlying condition that causes impaired integrity of the hepatic parenchyma and vasculature. Most patients present with non-specific symptoms, so imaging exams as computed tomography have a crucial role for diagnosing. If not rapidly identified and left untreated, might quickly progress to hemorrhagic shock and death.

Case description

We present the case of a 43-years-old male diagnosed with colon cancer with multiple liver metastases two months before and receiving palliative chemotherapy for the past two weeks. He was admitted to the emergency department with abdominal pain and

shortness of breath. Physical examination revealed obtundation, jaundice, tachycardia and hypotension, polypnea although with peripheral oxygen saturation of 99% while breathing ambient air and severe diffuse abdominal tenderness with muscular defense. Arterial blood gas analysis showed metabolic acidosis with hyperlactacidemia. Laboratory studies revealed low hemoglobin level and elevated transaminases, lactate dehydrogenase and inflammatory markers. The abdominal computed tomography revealed multinodular hepatomegaly with ruptured lesions and hemoperitoneum. For the purpose of reducing intra-abdominal pressure, a paracentesis was performed, evacuating over 1500 ml of blood. Admitting hemorrhagic shock and after a multidisciplinary team discussion, it was decided to implement only comfort measures. The patient died a few hours after admission.

Discussion

Spontaneous hepatic hemorrhage is easy to miss because of the unspecific initial symptoms. Several aetiologies are identified but only a few cases of ruptured hepatic metastasis can be found in the literature, unfortunately, all of which dying shortly after the diagnosis.

#489 - Case Report

A CASE OF TOO MUCH PLATELETS

Carolina Vasconcelos Barros, Mariana Gomes, Carolina Morna, Bela Machado, Helena Luís, Mariana Bilreiro, Teresa Faria, Luz Brazão

Hospital Central do Funchal, Funchal, Portugal

Introduction

Essential thrombocytosis (ET) corresponds to a chronic, non-reactive myeloproliferative disease in which the sustained increase in megakaryocyte proliferation causes an increase in circulating platelets predisposing to thrombotic events. Approximately 6,000 cases of ET are diagnosed per year.

Case description

A 78-year-old caucasian woman with a history of arterial hypertension and deep venous thrombosis of the left lower limb a year ago, current non-hypocoagulated, went to the emergency department with sudden dyspnea with two days of evolution, without reference to fever, chest pain or cough. At the observation presented conscious and oriented, with hypertensive profile, tachycardic and polypneic (peripheral oxygen saturation of 82%) with signs of reduced peripheral perfusion. Arterial gasimetry showed hypoxemia and hypocapnia with poor response to oxygen therapy. Analytically highlighting elevation of D-dimers and cardiac biomarkers, as well as thrombocytosis. Electrocardiogram was compatible with sinus tachycardia and chest radiography did not present with any acute pleuroparenchymal lesions. The patient scored 2 at the Wells Score and so underwent an angiotomography-thoracic, compatible with bilateral high-

risk Pulmonary Embolism (PE), class V in the Severity Index of PE, echocardiography showed discreet dilatation of the right cavities and moderate pulmonary hypertension, and the patient was admitted for study. The inspection included the study of thrombophilias which was negative, doppler ultrasonography of the lower limbs without thrombi, thoraco-abdominal-pelvic tomography, gynecological and mammary examination without alterations. Analytically for maintaining marked thrombocytosis > 750,000/ μ L, it was performed a bone marrow medulogram and biopsy whose morphological aspects were compatible with essential thrombocytosis. A genetic study showed a mutation of the JAK2 gene, thus assuming this as the cause of PE, initiating hydroxyurea and maintaining anticoagulant medication.

Discussion

Approximately 30% of patients with ET are asymptomatic at the time of diagnosis. The rest present vasomotor symptoms or complications of thrombotic or hemorrhagic events, and may also have pulmonary hypertension. Thrombocytosis maintained with a thrombotic event should be evaluated more deeply.

#492 - Case Report

HEMOPHAGOCYTIC LYMPHOHISTIOCYTOSIS: A RARE AND FATAL DIAGNOSIS

Marli Cruz, Rui Barros, António Carneiro

Hospital da Luz Arrábida, Vila Nova De Gaia, Portugal

Introduction

Hemophagocytic lymphohistiocytosis (HLH) is characterized by a dysregulated activation of the immune system, usually triggered by infection, neoplasia or autoimmunity. The mortality rate is extremely high due to the aggressive course of the disease and the difficulty in establishing an earlier diagnosis.

Case description

An 80-year-old woman, with past medical history of diffuse large B-cell lymphoma in 2012, and follicular lymphoma in 2016, in complete remission after R-CHOP chemotherapy and rituximab, respectively, presented in the emergency department for high-grade fever, hypersudoresis and malaise, in the past 15 days. Laboratory evaluation was notable for pancytopenia (Hb 7 g/dL, leukocytes 660/ μ L, neutrophils 370/ μ L, PLT 67000/ μ L), ALP 192 UI/L, gGT 176 UI/L, DHL 2300 UI/L, CRP 12.68 mg/dL, ferritin >40000ng/mL, triglycerides 337 mg/dL, D-dimers 2388 ng/mL and fibrinogen 67 mg/dL. Protein-electrophoresis failed to show any suspicious clonal patterns. The abdominopelvic CT showed retroperitoneal lymph nodes <1cm and enlarged spleen (17cm in craniocaudal length). Immunophenotyping of bone marrow identified aberrant CD4+ T cells phenotype (CD3 -/+, CD5+) (13%) of unknown significance. Bone biopsy revealed trilineage dysmyelopoiesis without hemophagocytosis or other findings suggesting lymphoproliferative disease. CMV and EBV

DNA were undetectable. Blood and urine cultures were sterile. The diagnosis of HLH was made according to the HLH-2004 criteria (fever, splenomegaly, pancytopenia, hypertriglyceridemia and hyperferritinemia). Etoposide and dexamethasone were started from the 9th day.

Initially the patient's condition improved impressively as well as the laboratory parameters (Hb 8.4g/dL, leukocytes 1450/ μ L, neutrophils 1010/ μ L, PLT 88000/ μ L, PCR 0.11mg/dL and ferritin 7703ng/mL), however two months after the diagnosis, she relapsed with rapid clinical deterioration and death.

Discussion

The initial diagnostic hypothesis of lymphoma relapse, given the patient's medical history, wasn't confirmed. The delayed diagnosis and consequently delayed treatment eventually contributed to the poor outcome. In this case, none of the other usual triggers was found, namely CMV or EBV infection, autoimmune disease or immunosuppression.

Despite the multitude of symptoms, HLH should always be suspected in patients presenting with febrile syndromes of unknown etiology and marked elevation of serum ferritin, since only earlier diagnosis and treatment can contribute to a favorable outcome.

#495 - Case Report

DYSPHAGIA: A CASE REPORT AND DIFFERENTIAL DIAGNOSIS ASSESSMENT

Paulo Zoé Costa, Ivanna Ostapiuk, Andreia Póvoa, Pedro Vieira, Orlando Mendes, Maria Inês Sequeira, João Correia
Unidade Local de Saúde da Guarda, Guarda, Portugal

Introduction

Dysphagia is a subjective sensation of difficulty or abnormality of swallowing. This condition is commonly caused by various diseases. The symptoms can be divided into two main categories: oropharyngeal and esophageal dysphagia. Moreover, dysphagia can lead to pneumonia, malnutrition, dehydration and increased mortality.

Case description

A 52-years-old man with progressive dyspnea, cough with purulent sputum and posterior chest wall pain for about 3 months. Three weeks before the admission, the patient complained of anorexia, weight loss, hoarseness and dysphagia to liquids and solids. He was a heavy smoker and drinker.

On examination, respiratory rate was 20/min, normal oxygen saturation and "dry" crackles on auscultation.

The chest computed tomography (CT) scans shows infiltrative mass on posterior mediastinum which involved esophagus and both main bronchus, with destruction of carina, obliteration of right inferior lobar bronchi and necrotic mediastinal and abdominal adenopathies, that suggests malignancy and it cannot define the emergence of the tumor.

The upper endoscopy (EGD) with biopsy shows esophageal squamous cell carcinoma and the flexible bronchoscopy reveals stenosis of middle inferior of the tracheal with necrotic tissue, measuring 7 mm in diameter that bronchoscope cannot be passed beyond.

The patient admitted to a palliative care unit. The tracheal stent was placed unsuccessfully and he went to palliative chemotherapy. Also, percutaneous endoscopic gastrostomy tube was inserted. After 1 month, he passed away.

Discussion

This poster aims to address the main differential diagnoses. In this case, the main complaints are dysphagia and the primary site still unknown until further investigation is carried out.

There are many factors involved. Basing on clinical symptoms, it could be caused by extrinsic pressure or intrinsic structural lesions. Therefore, CT scan is important to exclude extrinsic lesions and EGD to determinate intrinsic lesions.

It is interesting to note, where the tumor is emerged from, because in this instance, it could either be esophageal, pulmonary, or even extrinsic causes like sarcoidosis or lymphoproliferative disorders. Moreover, it has impact on treatment option.

For these reasons, the diagnosis is challenging, since it is hard to begin with and further investigation is needed until the final diagnosis is made.

Finally, the dysphagia and tracheal stenosis forces the patient to remain in the hospital due to risk of asphyxia and aspiration pneumonia.

#552 - Medical Image

COLLAPSED LUNG

Maria J Piteira, Ana Bernardo, Susana Escária, Vasco Neves, Sara Correia, Maria Luisa Corraliza, Maria Conceição Barata
Hospital do Espírito Santo de Évora, Évora, Portugal

Clinical summary

70-year-old Caucasian men, smoker, presents with 4 months of progressive dyspnea and asthenia. Chest X-ray, postero-anterior, in orthostatism, presented total white-out of right hemithorax, deviation of airway and mediastinum to the right, compatible with collapsed right lung. In bronchofibroscopy there was vegetation with complete filling of the main right bronchus. The result of the microscopy obtained was moderately differentiated and infiltrating adenocarcinoma, presenting areas of necrosis.

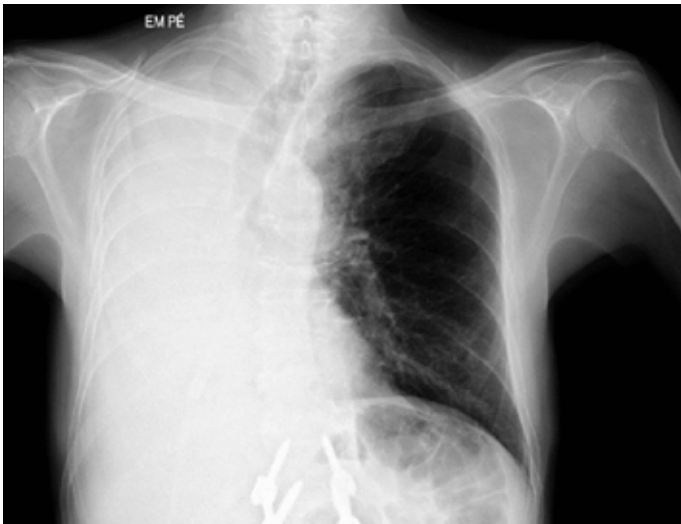


Figure #552. Chest X-ray with right pulmonary atelectasis.

#564 - Case Report

AN ATYPICAL PNEUMONIA

Margarida Brito Monteiro, Raquel Silva, Bárbara Pedro
Hospital Prof. Doutor Fernando Fonseca, E.P.E., Amadora, Portugal

Introduction

Multiple myeloma (MM) is characterized by the neoplastic proliferation of plasma cells, and it accounts for 1% of all neoplasms diagnosed. The plasma cells proliferate in the bone marrow, resulting in osteolytic lesions, osteopenia and pathologic fractures. The peak of incidence is in the 7th decade of life and less than 10% of the patients are under 50 years old. It usually manifests through bone pain and systemic signs, as weakness and fatigue.

Case description

A 54-year-old black male, with a history of spinal surgery in 2010 after a car accident, was admitted in the Emergency Room (ER) complaining of myalgias, non-quantified fever and productive cough five days prior. In the first evaluation in the ER, a mass of bone consistency in the anterior border of the right axilla was found. The patient noticed the mass had been growing for the last three months, but he never sought medical attention. The blood work showed increased inflammatory parameters and influenza A positive test. An well defined bone density image on the right lung was seen in the chest radiography. The patient was diagnosed with an influenza pneumonia with superimposed bacterial infection. Antibiotics and antivirals were started, and the patient was admitted to the internal medicine ward for etiological study of the mass. He had no anemia, a normal calcium and PSA levels; Beta-2 microglobulin was slightly elevated and Bence-Jones protein was negative. Thoracic CT revealed multiple lesions in costal arches, the largest one at the 5th right rib, with bone expansion and cortical rupture; on the left side, there was a lesion on the first rib of 41x33mm. There was also a slight consolidation of the pulmonary parenchyma in the right lower lobe, compatible with

pneumonia. A monoclonal gammaglobulin peak was found in the serum protein electrophoresis; serum immunofixation confirmed monoclonal component of IgG Kappa type. Bone marrow aspirate demonstrated 6% of plasma cells. Skeletal radiography and abdominal CT confirmed multiple osteolytic bone lesions in the proximal femurs, pelvis, vertebral column and lower costal arches. The patient started treatment with bortezomib assuming an IgG Kappa MM.

Discussion

The authors portray this as an atypical case of MM, presenting only with a palpable osteoclastic mass and without pain, in spite of several osteolytic lesions. The diagnosis of myeloma implies a high level of clinical suspicion, since symptomatology may be absent and laboratory analysis normal, even in advanced disease.

#566 - Case Report

A COMPLEX CASE OF PANCOAST SYNDROME AND HORNER'S SYNDROME

Filipa Sofia Silva, Margarida Neto, Pedro Carreira, Sónia Serra
Setúbal Hospital Center, Setúbal, Portugal

Introduction

Pancoast syndrome usually results when a malignant neoplasm of the superior sulcus of the lung (typically lung cancer) leads to destructive lesions of the thoracic inlet and involvement of the brachial plexus and cervical sympathetic nerves (stellate ganglion). Most pancoast tumors are squamous cell carcinomas or adenocarcinomas. Only 3-5% are small cell carcinomas.

Case description

A 61-year-old male, current smoker (44 pack years), went to the Emergency Department complaining of pain in left shoulder, with a year of evolution, which was associated with a decreased of strength and hypoesthesia in the left upper limb, with one month of evolution. He complained to anorexia and weight loss, corresponding to 15% of his body weight, in the last year. Objectively he presented: anisocoria (miosis in left eye), left palpebral ptosis (suggestive of Horner's Syndrome) and a decreased in the vesicular murmur in the left hemithorax. Serum analysis showed anemia of chronic disease. Chest radiography showed an hypotransparency on the left apex, with contralateral deviation of the mediastinum, and computed tomography of the thorax confirmed the space occupying lesion (SOL), apparently proliferative, with 95 by 69 mm, involving surrounding vascular structures. The hypothesis of Pancoast Syndrome was admitted. Patient was submitted to bronchofibroscopy, transthoracic needle aspiration and staging exams, and no other neoplastic lesions were observed. Cytopathology results of SOL suggested a little differentiated carcinoma, not excluding the possibility of being a secondary lesion. In this case, the lung cancer was a T4NxMx. Patient started metronomic vinorelbine and pain control therapy. There were seen some improvements in well-being, appetite

control (without any future weight loss) and left palpebral ptosis. Four months after the initial diagnosis, patient remains in follow-up on an Oncology appointment.

Discussion

In patients with disseminated lung cancer, medical treatment is required for palliation and treatment of symptoms arising from paraneoplastic syndromes. Some studies have shown that median survival is usually only 6,4 months when patient has T4 disease. In this case, a quick diagnosis was the key to improve the quality of life of our patient.

#577 - Case Report

AGGRESSIVE MYXOINFLAMMATORY FIBROBLASTIC SARCOMA - A DIFFICULT DIAGNOSIS IN AN ELDERLY PATIENT

Sofia Gomes Brazão, Ana Luisa Correia, Pedro Botelho Alves, Ana Filipa Correia, José Bernardes Correia, José Pereira Moura, Armando Carvalho

Coimbra Hospital and University Center, Coimbra, Portugal

Introduction

Myxoinflammatory fibroblastic sarcoma is a rare low-grade tumor of uncertain origin that most often occurs in adults. It characteristically affects distal extremities, commonly involving the subcutaneous tissues. It has a propensity to recur locally, but rarely, it can be aggressive and even metastasize. It often presents as a painless mass within the subcutaneous tissue that can be confused with benign lesions. In most cases, surgical resection with wide margins can be curative with low local recurrence; however, patients should be followed up closely after resection of the tumor.

Case description

We report a case of an 89-year-old woman that was admitted in our internal medicine ward with the diagnosis of pyelonephritis. She was bedridden due to intense osteoarticular pain with several years of evolution, but with no cognitive impairment. During hospitalization, and despite improving from pyelonephritis, she reported pain in the right tibial region that did not improve with analgesic therapy. A careful physical examination was performed and a soft tissue mass of about 7 cm with inflammatory signs was found in the right tibia. According to the patient, the mass had about 1 month of evolution. At first, the patient attributed it to an insect bite. However, the mass remained persistent, initially painless but later presenting with sharp pain. No constitutional symptoms were reported. At the 15th day of hospitalization, the mass was bigger, so soft tissue ultrasonography was performed revealing a lobulated, heterogeneous and hypoechogenic mass with vascularity in the Doppler study, measuring at least 8 x 3.5 cm at the larger axes. A fine needle aspiration biopsy was performed, and the histological exam revealed a pretibial myxoinflammatory fibroblastic sarcoma. Chest-abdomen-pelvis CT for staging

revealed multiple synchronous metastases (lung, liver, spleen and left iliopsoas muscle). The case was discussed at a multidisciplinary meeting and the patient was referred to an orthopaedic specialist.

Discussion

This case describes a very rare sarcoma with unusual multiple synchronous metastases. Internal medicine is a holistic specialty equipped to deal with simple or more complex diagnoses. The correct evaluation of patient complaints and a careful physical examination may lead to rare entities like the one described. This case also emphasizes the importance of multidisciplinary discussion for better orientation of the patient.

#587 - Case Report

IN THE RIGHT PLACE AT THE RIGHT TIME: RESULT WAS ADENOCARCINOMA OF THE LUNG IN EARLY STAGE (A LIFE WAS SAVED) - CASE REPORT

Paulo Ferreira¹, Vanessa Machado¹, Cristina Ramalho¹, Hilda Freitas², Natalia Oliveira², Antonio Cabral²

¹ TrofaSaude Hospital Braga Centro, Braga, Portugal

² TrofaSaude Hospital Braga Sul, Braga, Portugal

Introduction

The diagnosis of lung cancer is primarily based upon evaluation of individuals with symptoms. Screening for lung cancer was not previously recommended because chest radiography and sputum cytology had not been shown to reduce mortality from lung cancer. However, prospective, single-arm, observational studies have shown that a large percentage of lung cancers detected by computed tomography (CT) screening are early-stage tumors, which have a favorable prognosis.

Adenocarcinoma is the most common type of lung cancer in contemporary series, accounting for approximately one-half of lung cancer cases.

Case description

The authors describe a clinical case of a 89 years old men, autonomous, with a medical history of squamous cell carcinoma of the larynx (cured),hypertension and benign prostatic hyperplasia. Ex-smoker about 30 years before. He woke up in the morning with dizziness, posterior cervical pain and hypertension. Subsequently, at the middle of the morning, we became with constant left chest discomfort, maintained, and that made he came to our hospital. He went do emergency room because chest discomfort with about 4h of evolution. Cardiologist evaluated patient and suggested myocardial perfusion scintigraphy. At the 2th day of internment maintains complaints of generalized non-specific malaise and dizziness. In spite of rx thorax without changes of the pulmonary parenchyma, and despite the criticisms regarding the need for additional examination, it was decided to perform Torax CT:” In the lower right lobe an irregular nodule of about 20mm is identified and should be biopsied”. Myocardial perfusion scintigraphy was

normal. Was made a biopsy of the pulmonary nodule. Result of lung nodule biopsy revealed malignant neoplasm-adenocarcinoma. He became at orientation of Oncology. Verified localized disease – was made Radiotherapy (RT) for curative purposes (stereotactic RT at the lesion of 2 cm of the lung). He remains alive, and asymptomatic.

Discussion

In a country and in a world where the need for cost-related examinations is often questioned, this seems to be an example of what to spend now, which means saving later: the detection of early adenocarcinoma of the lung avoided the enormous expenses incurred with carcinomas; but above all, saved a life.

#595 - Case Report

CEREBRAL LESIONS IN PATIENT WITH BRAIN TOMOGRAPHY 3 MONTHS BEFORE NORMAL - CASE REPORT

Paulo Ferreira¹, Vanessa Machado¹, Cristina Ramalho¹, Hilda Freitas², Natalia Oliveira², Antonio Cabral²

¹ TrofaSaude Hospital Braga Centro, Braga, Portugal

² TrofaSaude Hospital Braga Sul, Braga, Portugal

Introduction

Brain metastases must be distinguished from primary brain tumors, infectious processes, progressive multifocal leukoencephalopathy, demyelination, paraneoplastic phenomena, cerebral infarction or bleeding, and effects of treatment such as radiation necrosis. Biopsy should be performed when the diagnosis of brain metastases is in doubt.

Case description

The authors describe a clinical case of a 74-year-old man, independent, with right lower limb revascularization and left carotid endarterectomy before, hypertension, insulin-dependent diabetes 2, ischemic cerebrovascular and coronary disease, chronic kidney disease stage III of NFK, Multifactorial anemia, benign prostatic hyperplasia. He was admitted at emergency department due to lipothymia. According to the family, there were similar episodes in the days prior to admission. He was afebrile, hemodynamically stable. TC EC: "intraaxial expansive lesion". Was made Cranial Magnetic Resonance, which favors the hypothesis of probably secondary neoplastic lesion but could not exclude primary neoplasia/lymphoma. He became medicated with dexamethasone and levetiracetam. Other exams were performed, including: chest CT, abdomen and pelvis, and cervical ultrasound without changes; full body positron emission tomography documented only the known injury; echocardiogram without masses or vegetations; immunophenotyping of peripheral blood and tumor markers – normal. He performed electroencephalogram that revealed changes suggestive of space-occupying structural lesion and potentially epileptogenic. It was intended to biopsy the brain. At the request of the family, for economic reasons,

transfer was performed to Public Hospital. 3 months before, after stumbling in the bathroom he presented traumatic brain injury. Was made brain TAC at that time, that was without lesion occupying space.

Discussion

Despite CECT 3 months before admission without lesion occupying space, the patient already presented exuberant brain lesion on CT of the admission. The adequate exhaustive study in these situations proved to be negative. Under these circumstances, the lesion biopsy was to be performed. The authors intend to show, on the one hand, the importance of the differential diagnoses of brain lesions and, on the other hand, the limitation of the medicine: in spite of clinically no previous neurological alterations and normal EC CT scan 3 months later the appearance of brain lesions, of probable neoplastic etiology.

#597 - Case Report

VASO-OCCLUSIVE PHENOMENA OF SICKLE CELL DISEASE + HEMOLYTIC ANEMIA + PNEUMONIA OF RIGHT LUNG + RESPIRATORY FAILURE – CASE REPORT

Paulo Ferreira¹, Vanessa Machado¹, Cristina Ramalho¹, Hilda Freitas², Natalia Oliveira², Antonio Cabral²

¹ TrofaSaude Hospital Braga Centro, Braga, Portugal

² TrofaSaude Hospital Braga Sul, Braga, Portugal

Introduction

The major acute complications in Sickle cell disease (SCD) include acute vaso-occlusive pain, stroke, acute chest syndrome, renal infarction, dactylitis or bone infarction, priapism, venous thromboembolism. Episodes of acute pain are a type of vaso-occlusive events in SCD. Vaso-occlusive events may mask other life-threatening complications. These complications may present with pain, but they require additional evaluations and treatments in addition to analgesia for pain, in order to avoid missing a potentially serious complication.

Case description

The authors describe a clinical case of a 22 years old man, Natural of Angola, medical student at University in our city, with a medical history of SCD and congenital heart disease, medicated with folic acid. He came to the Emergency room because severe pain of sudden onset in the abdominal and lumbar region associated with severe arthralgias; self-medicated with metamizole and ibuprofen without improvement. Laboratory studies: Hb 10.3 NcNc; Gb 24800; PMN 49.8% PMN; Linf 45.1%; platelets 518000; PCR <5; DHL 578; bil total 2.4; computer tomography pulmonary and abdominal angiography: "discrete fibroadrenal images at the bases". Was necessary analgesic including morphine. At the hospital he had multilobar pneumonia and became treatment with long-spectrum antibiotic therapy, oxygen therapy, and bronchodilator therapy. Blood test evolution showed: Hb 8.3;

leukocytes 23780; ferritin 13654; LDH 5753; FA 366; Brb T 3.98 /indirect 2.35. D-dimers 23829. Fibrinogen 573. He went to the Intermediate Unit. It was decided to perform blood transfusion and initiate hydroxyurea. There was progressive clinical improvement with established therapy. He was discharged asymptomatic. It was reassessed in consultation, remaining asymptomatic and medicated with hydroxyurea and folic acid.

Discussion

Vaso-occlusive phenomena and hemolysis are the clinical hallmarks of SCD. Vaso-occlusion results in recurrent painful episodes (previously called sickle cell crisis) and a variety of serious organ system complications that can lead to life-long disabilities and even death. The variety of differential diagnoses associated with recurrent symptomatology, possible complications, and initial clinical worsening in a 22-year-old are a challenge that is rewarding when we are able to solve the problem to the patient. The only approved therapies to prevent pain episodes in SCD are hydroxyurea and pharmaceutical grade L-glutamine.

#617 - Case Report

GOOD'S SYNDROME IN YOUNG WOMEN - AN UNSUAL PRESENTATION

Sandra Dias Rebelo, Ruben Duarte Ferreira, Susana Lopes Silva, Isabel Fernandes, Ana Tornada

Centro Hospitalar Lisboa Norte - Hospital de Santa Maria, Lisboa, Portugal

Introduction

In patients with recurrent infections, especially in young adults, immunodeficiency investigation is mandatory. Classically, when it manifests as hypogammaglobulinemia associated with thymoma, it is known as Good's Syndrome. This is a rare syndrome, manifested clinically by bacterial infections and other opportunistic agents (fungi and viruses) and autoimmune manifestations, particularly myasthenia gravis and cytopenia, most often after the 4th or 5th decades of life. The most characteristic immunological alterations are the decrease in the frequency of B-cells, sometimes <1%, CD4+ T-cell lymphopenia and inversion of the CD4+/CD8+ ratio.

Case description

We illustrate this syndrome with the case of a 38-year-old woman with recurrent urinary infections with 6 months of evolution, refractory to several cycles of antibiotherapy without identification of any agent, who was admitted for pyelonephritis and acute diarrhea. She also had a significant weight loss, above 10% of the body mass index. The investigation revealed opportunistic infection of *Clostridium difficile* and *Campylobacter jejuni* as the cause of diarrhea. The pyelonephritis had no agent identified (bacteria, fungi, parasites and mycobacteria). Thoracic radiography unveiled a 9 cm mediastinal mass whose histology and further imaging revealed invasive thymoma B1 of adjacent soft tissues (lung, pericardium and superior vena cava (SVC)). Hypogammaglobulinemia, IgA and IgM deficiency, as well as

deficits in the production of antibodies specific for polysaccharide antigens were also observed. Extended immunophenotyping of peripheral blood lymphocytes showed a decrease in the frequency of memory B-cells with immunoglobulin switch and in the CD4+/CD8+ T ratio by CD8+ T expansion.

After opportunistic infections were addressed, the tumor was submitted to surgical resection with SVC reconstruction (Masaoka 3, pT3N0) and adjuvant radiotherapy. In this context, and because she had frequent infectious events replacement therapy was initiated with immunoglobulin G intravenously.

Discussion

In this case of Good's Syndrome it is highlighted the young age of presentation and the rapid progression from the onset of recurrent infections to the identification of the thymoma. Good's syndrome is associated with high mortality, therefore diagnostic suspicion and multidisciplinary therapeutic approach are essential to improve prognosis and also prevent opportunistic infections.

#622 - Case Report

THE EAT-PLATELET BACTERIA

Victor Mato, Eduardo Fernández, Álvaro Alejandro, Sergio Moragón, Cristina Ausín, Victoria Sampedro, María Victoria Villalba

Hospital General Universitario Gregorio Marañón, Madrid, Spain

Introduction

We present the case of a 63 year-old female hospitalized because of clinical findings of multiple haematomas, petechiae and oral bleeding in the context of low platelet count.

Case description

A 63 year-old female with previous history of hypertension, asthma, eosinophilic pneumonia and lymphocytic colitis presented to the emergency department with multiple haematomas widespread around the body, petechiae and oral bleeding in the last two days, without any other clinical finding or anything relevant in the anamnesis. The laboratory tests showed severe thrombocytopenia (2000/microL), without any other alteration in the rest of hematologic, biochemistry or coagulation parameters. Platelet levels were normal in a laboratory test made a few months before. An urgent peripheral blood smear was made that confirmed severe thrombocytopenia but didn't show any other alteration. The patient was admitted to our hospital for further study and it was started treatment with glucocorticoids and intravenous immunoglobuline, as the main suspicion was the existence of immune thrombocytopenia (ITP).

During the admission, we made a complete diagnostic evaluation. The autoimmunity tests, vitamins, hormones levels and serologies were negative. The chest x-ray and the abdominal ultrasonography were normal. We went in depth in the anamnesis and she told us important epigastric pain in the last months, so we decided to made an upper endoscopy where we find chronic gastritis and

positive test for *Helicobacter pylori*. Then we decided to treat the *H. pylori* infection with omeprazole, amoxicillin, clarithromycin and metronidazole during 14 days. Progressively, the haematomas and petechiae evolved favorable, and the levels of platelets raised until a normal level (378000/microl). The patient was discharged after 10 days with glucocorticoid descending instructions and the treatment against *H. pylori*. 6 months after discharge, the patient was evaluated in medical consultation. She was asymptomatic and the platelet levels were normal.

Discussion

We present the case of a woman with secondary ITP due to *H. pylori* infection. Many studies shows that a large percentage of patients with succesful eradication of *H. pylori* achieve pletelet levels recovery and some guides establish the recomentadiion for screening *H. pylori* in all patients with ITP. In our case after *H. pylori* eradication, the patient achieve complete platelet response.

#626 - Case Report

PERNICIOUS ANEMIA - AN UNCOMMON CAUSE OF HEMOLYTIC ANEMIA

Magda Sofia Silva, Francelino Ferreira, Rúben Reis, Anneke Joosten, Ana Paula Pona, Laurinda Pereira, Fátima Campante
Centro Hospitalar Barreiro Montijo, Barreiro, Portugal

Introduction

Hemolytic anemia is an uncommon presentation of vitamin B12 deficiency, which typically manifests as macrocytosis and pancytopenia. The most common cause of this vitamin deficit is pernicious anemia, a chronic autoimmune atrophic gastritis characterized by atrophy of the body and the stomach floor, and the presence of autoantibodies against parietal gastric cells and/ or against the intrinsic factor.

Case description

We present the case of a 35-year-old woman who reported 1 week history of anorexia, asthenia, muscle weakness, easy fatigue and jaundice. Analytically she had pancytopenia (leukocytes $2.3 \times 10^9/L$, platelets $78 \times 10^9/L$ and hemoglobin 5.8 g/dL with mean globular volume 92 μL). The morphological study of the blood reveled macroovalocytes, dacryocytes, ovalocytes, schistocytes and hypersegmented neutrophils. Remaining study resulted in low reticulocytes, normal iron kinetics, unconjugated hyperbilirubinemia, haptoglobin <8 mg/dL, vitamin B12 <83 pg/mL and folic acid 12.1 ng/mL. Abdominal ultrasound with spleen of dimensions at the upper limit of normality. The electrophoretic profile of hemoglobins was normal, Coombs direct and indirect negative, and absence of glucose 6 phosphate dehydrogenase deficiency. Myelogram revealed erythroid and megakaryocytic hyperplasia. Intrinsic factor antibodies were positive, and the anatomopathological study of gastric mucosal biopsies revealed chronic atrophic gastritis of autoimmune etiology. She underwent intramuscular vitamin B12 treatment with progressive clinical and analytical improvement.

Discussion

This case illustrates an etiology of hemolytic anemia poorly described in the literature. Intramedullary hemolysis resulting from ineffective erythropoiesis, with abnormal and fragile red blood cells, is a possible pathophysiological mechanism. Rapid diagnosis and appropriate treatment are critical, since vitamin B12 deficiency anemia can result in severe haematological and neurological complications.

#631 - Case Report

MALIGNANT PLEURAL EFFUSION: ONLY ONE?

Teresa Medeiros¹, José Brito-Silva², Ana Lisa Lima¹, Sofia Moreira-Silva¹

¹ Department of Internal Medicine, Hospital Pedro Hispano, Matosinhos Local Health Unit., Matosinhos, Portugal

² IPO Porto, Porto, Portugal

Introduction

Pleural effusion is a common complication in cancer patients and is often a sign of advanced disease with high morbidity and mortality. The tumors most frequently associated are lung, breast and lymphoma, constituting about 75% of the cases, followed by gynecological cancer and mesothelioma.

Case description

We present a case of a 77 year old woman with a prior history of hypocoagulatedatrialfibrillation,asthmaandahistoryofintracystic papilloma of the right breast, benign disease, removed with free margins the year before. She was admitted for dyspnea for great efforts, with 1 month of evolution, without infection signs. She had a mild hypoxemia and right pleural effusion of medium volume, having performed thoracocentesis that revealed an exudate with predominance of mononuclear cells and pleural biopsy whose histological exam showed carcinoma cells with estrogen positive receptors. The mammogram revealed irregular lump in the left breast, with microcalcifications and its biopsy showed invasive ductal carcinoma. It was evaluated by gynecology for presenting heterogeneous endometrial thickening in computerized axial tomography. Then, they performed endometrial biopsies that returned negative but since we still suspected of cancer we did a pelvic magnetic resonance also. This last exam confirmed the thickening and heterogeneous endometrium with neoplastic characteristics, suggestive of neoplasia confined to the first half of the endometrium and an enlarged to the right ovary, with complex cystic lesion of suspicious characteristics. She presented refractory pain and dyspnea difficult to control, with the need of successive therapeutic thoracentesis to symptomatic control, as well with increase of opioids without significant improvement. The patient eventually died 2 months after the onset of the symptoms before receiving a targeted systemic therapy.

Discussion

Synchronous malignant tumors constitute approximately 1% of all cases of cancer, the most frequent is multifocal proliferation in one organ. The involvement of more than two organs is rare, with few cases described in the literature. In this case we have a confirmed breast carcinoma, whose presentation was a pleural effusion, suspecting there was also a gynecological cancer despite its negative histology.

#641 - Case Report

SUPERFICIAL THROMBOPHLEBITIS AS AN EARLY MANIFESTATION OF HEMATOLOGIC CANCER

Marta Parra, Gemma Sais, Laia Lopez, Montserrat Mauri, Josep Antoni Capdevila, Ramon Boixeda, Peter Reth, Gabriela Alexandra Casinos, Raquel Aranega, Carlos Lopera, Laura Pacho, Paula Fernandez, Aleix Serrallonga, Mariela Plenc, Celina Suarez, Angela Felip

Hospital de Mataró, Mataró, Spain

Introduction

A 63-year-old woman consulted on Dermatology explaining a 9 months history of nodular and inflammatory dermic lesions, grouped annularly and serpigiously mainly at the lumbar and sacral regions, with livedo at the feet and erythromelalgia.

Case description

Blood tests showed elevated levels of platelets (1.239.000/ μ L), hemoglobin (12g/dL) and LDH (804 UI/L). The differential diagnosis of the lesions was of superficial migrans thrombophlebitis, annular granuloma, panniculitis or vasculitis, and the first suspected diagnosis was a paraneoplastic syndrome, probably secondary to a chronic myeloproliferative syndrome.

Discussion

The skin biopsy was compatible with migrans thrombophlebitis. Abdominal ultrasound showed an accessory spleen, and the bone marrow biopsy showed a myelofibrosis, also detecting the V617F mutation in the JAK2 tyrosine kinase gene. Therefore, she started treatment with Hydroxycarbamide, Alopurinol and Aspirine, and was followed up by hematology department, with stability of the disease for the next 5 years.

#649 - Abstract

SUPPORTIVE CARE FOR MULTIPLE CHRONIC CONDITIONS (MCC) IN CANCER OUTPATIENTS: AN EMERGING AREA OF INTEREST FOR YOUNG INTERNISTS

Cristina Gabara-Xancó, Ignacio Grafia-Perez, Jesus Aibar, Adrian García-Villa, Alfons López-Soto, Aleix Prat, Carme Font

Hospital Clinic of Barcelona, Barcelona, Spain

Background

The growing number of older cancer patients with multiple chronic conditions (MCC) represent a challenge in daily clinical practice in oncology.

The aim of this study was to assess the burden of comorbidities and reasons for consultation in cancer outpatient visits.

Methods

Prospective compilation of demographic data, MCC and reasons for consultation of consecutive cancer outpatients visited during 1 month (January 2019) as part of internship rotation (MIR program). The study was performed in the Daycare Cancer Clinic (DCC) which is led by a senior internist. The Student's t and the Chi-square tests were used for statistical analyses.

Results

A total of 205 consecutive visits were made involving 154 patients (53.2% women; mean age 64.8 years; range: 33-87) with 57% of patients over 65 years. The most common types of tumours were: breast (20.8%), lung (19.5%), biliopancreatic (12.3%) and urological (10.4%). Cancer was metastatic in 66.2% of the cases, and 75.9% were receiving active anticancer therapy. Concomitant MCC were present in 69.5% of cases (36.4% one, 20.1% two and 13% three or more). The most frequent MCCs were: cardiovascular risk factors (48.7% of patients), respiratory conditions (19.5%) and heart disease (18.8%). The presence of MCC was more frequent in men (84.7% vs 56% in women; $p < 0.05$) and in those older than 65 years (88% vs 44% in < 65 years; $p < 0.001$).

The most frequent symptoms for consultation were respiratory (20.8%), gastrointestinal (16.2%) and fever (13.6%). 33% of the consultations were not related to the neoplasm or the treatment. Only 8.4% of the patients required intervention by the oncologist in addition to care provided by the internist. The rate of unscheduled visits was 55.8%.

After consultation, 72.7% of the patients were discharged with their usual follow-up, 20% were followed in the DCC until resolution of the acute problem, 4% required hospitalization, and 3.2% were referred to the emergency room. The rate of emergency room visits the following week was 10.4%.

Conclusion

The management of MCC and unscheduled visits as part of the continuum of daily supportive care in cancer outpatients is an emerging area of interest to be considered in the training of young internists. The integrative and polyvalent role of the internist can be key for the optimal management of cancer outpatients with associated MCC and/or unscheduled conditions covering an area of expertise that complements the cancer-specific therapeutic approach led by the oncologist.

#657 - Case Report

72-YEAR-OLD FEMALE PATIENT WITH HYPEREOSINOPHILIC SYNDROME: A CASE REPORT

Eduardo Luis Peñaloza Martínez, Marta Bacete Cebrián, Guillermo Soria Fernández-Llamazares, Cristina Llamazares Mendo, María Mercedes Ferreiro-Mazón Jenaro, María Gómez Antúnez, Francisco Galeano Valle, Jorge Del Toro Cervera, Pablo Demelo Rodríguez

Hospital General Universitario Gregorio Marañón, Madrid, Spain

Introduction

Hypereosinophilia is defined as ≥ 1500 eosinophilic/Microl in two blood test analysis (separated at least one month) and/or with confirmation of tissue infiltrate by eosinophils. Hypereosinophilic syndrome is characterized by both ≥ 1500 eosinophilic/Microl and organ damage attributed to Eosinophilia although the cause is known

Case description

72-year-old female patient with a previous history of high blood pressure, valve aortic insufficiency, acute eosinophilic pneumonia treated with long-cycle corticoids two years before actual presentation and chronic kidney disease. She came at emergency room referring asthenia, progressive dyspnea, cough and profuse sweating without fever, cutaneous rash in lower and upper limbs, perioral edema, intense itching. No new drugs or changes in her current treatment was observed. Bilateral (bibasal) rales was found on her physical examination, without any other alterations (including skin and oral cavity). Blood test analysis revealed 15,000 leukocytes/ μ l, 2300 eosinophils/ μ l, acute on chronic kidney injury, chest X-ray without alteration. Total IgE 3964 UI/l. Negative autoimmunity. Blood smear: mature eosinophilia. Positivity serology for *Strongyloides stercoralis* (SS) (IgG and IgM), the rest of the test were negative (including Body-CT)

Discussion

The hypereosinophilic syndrome can be divided into three categories according to the cause of the expansion of eosinophils: Primary or neoplastic (e.g. eosinophilic leukemias, lymphoid neoplasms and solid tumors), secondary or reactive (e.g. Helminths: SS, *Toxocara* between others, drugs reactions, autoimmune diseases, Churg-Strauss syndrome or chronic eosinophilic pneumonia).

SS is endemic in rural areas (tropic and subtropic), sporadically can develop in temperate climate areas (southern Europe).

S. stercoralis penetrate directly into the skin after soil contact or water contaminated by human feces. The females of the larvae produce eggs that are eliminated by the feces after 3-4 weeks, it has the possibility of completing its cycle within the human host (self-infection). Although self-infection is controlled by the immune system, small levels of self-infection make it possible to survive in the organism for decades (asymptomatic). Mild symptoms are at the gastrointestinal, cutaneous and pulmonary level. Serology

should be performed for *Strongyloides* in all patients, Systemic corticoids should be avoided, it can trigger a hyperinfestation syndrome. Ivermectin and Albendazole are therapeutic options.

#658 - Medical Image

AN EXPLOSIVE CONDITION

Inês Moreira¹, Hugo Oliveira², Jorge Machado², Matilde Salgado², Alexandre Vasconcelos²

¹ Instituto Português de Oncologia Francisco Gentil, Porto, Portugal

² Unidade Local de Saúde de Matosinhos, Hospital Pedro Hispano, Matosinhos, Portugal

Clinical summary

The authors present the case of a 50 year old woman with Lynch syndrome diagnosed with ovary and endometrial adenocarcinoma in 2016. She underwent hysterectomy plus bilateral adnexectomy and initiated chemotherapy with carboplatin and paclitaxel. A good initial response to treatment was obtained, with disease regression. In July 2018 disease progression was observed, with metastatic lesions in the liver, lymph nodes and an extensive cystic mass arising from the peritoneum that protruded to the abdominal wall, leading abdominal pain, anorexia and nausea. Palliative chemotherapy with doxorubicin was prescribed, with poor response and increase in abdominal mass dimensions. The patient's general condition deteriorated and symptoms worsened. She died two months after disease progression was noted.

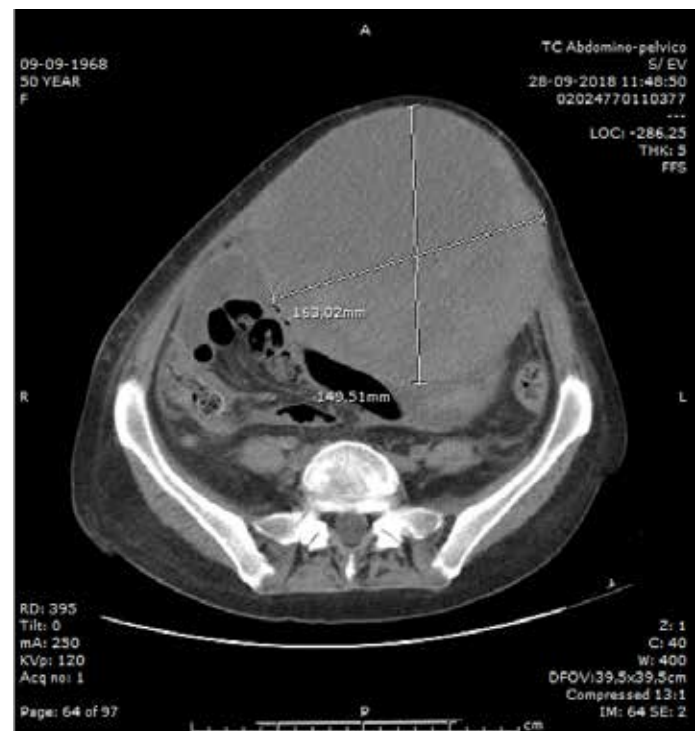


Figure #658. Metastatic cystic mass arising from the peritoneum with protrusion to the abdominal wall measuring about 163x150 mm.

#661 - Case Report

BILATERAL PLEURAL EFFUSION AS FIRST MANIFESTATION OF WALDENSTRÖM'S MACROGLOBULINEMIA

Afroditi Roumpou, Christos E Lampropoulos, Ioanna Papaioannou
Argolidos General Hospital, Nafplion, Greece

Introduction

Waldenström's macroglobulinemia (WM) is a lymphoproliferative disorder with bone marrow infiltration by B-lymphocytes and plasma cells. Clinical manifestations are related to organ involvement (B-symptoms, pancytopenia, lymphadenopathy, hepatosplenomegaly) and IgM paraprotein (amyloidosis, hyperviscosity syndrome, cryoglobulinemia, peripheral neuropathy). Other organs may rarely be involved.

Case description

An 80-year old female presented dyspnea and fatigue the last 10 days. Her medical history included atrial fibrillation and hypothyroidism. Lung auscultation revealed decreased sounds at lower lung fields bilaterally. The rest of examination was normal. Laboratory investigation showed anemia (Hb=8.6g/dL), high ESR (144mm/h), LDH (484U/L) and protein (11.3g/dL, 4.1g/dL albumin). Chest x-ray and CT showed bilateral pleural effusions without lymphadenopathy, parenchymal lesions or pulmonary embolism. Fluid analysis revealed an exudate (2.400 cells) with monoclonal lymphocytes and negative culture. Serum immunofixation revealed monoclonal IgM globulin (3.42g/dL) with kappa light chains. Bone marrow biopsy showed extended infiltration (80%) with monoclonal small B-lymphocytes and plasma cells (normal karyotype). Rituximab was started with restoration of anemia and disappearance of pleural effusions. Two years after diagnosis, the patient remains stable without pleural effusion relapse.

Discussion

WM is a rare (3.8/million person-years) plasma cell disorder with monoclonal gammopathy (IgM immunoglobulin). The commonest symptoms are fatigue, bleeding predisposition, frequent infections, hepato/splenomegaly, lymphadenopathy, hyperviscosity syndrome (IgM >4g/dL, ocular/hearing problems, epistaxis, neurological symptoms) or cryoglobulinemia (ulcers, purpura, peripheral neuropathy). Extramedullary involvement is very rare. Lung involvement is 3-5% of these cases. WM diagnosis requires ≥10% bone marrow infiltration with malignant lymphocytes and IgM monoclonal gammopathy in serum. B2-microglobulin and albumin are important for prognosis. Mean survival is 3-10 years depending on risk factors: age >65 years, hemoglobin ≤11.5 g/dL, platelets ≤100.000/mL, β2-microglobulin >3 mg/L, monoclonal IgM >7 g/dL, extramedullary involvement, 6q genetic deletion, trisomy 4. Asymptomatic patients do not require therapy. Rituximab, alone or in combination with other agents (alkylating agents, purine analogues, bendamustine, proteasome inhibitors, bortezomib) is the preferred treatment.

#682 - Case Report

GIANT CELL ARTERITIS, FIRST MANIFESTATION OF BLADDER CANCER: A NEW CASE REPORT

Maroua Mrouki^{1,2}, Youssef Gharbi^{1,2}, Yosra Cherif^{1,2}, Amal Baya Chatti^{1,2}, Fatma Ben Dahmen², Meya Abdallah^{1,2}

¹ Tunis El Manar University Faculty of Medicine of Tunis, Tunis, Tunisia

² Regional Hospital Ben Arous, Internal Medicine Department, Ben Arous, Tunisia

Introduction

Giant cell arteritis (GCA) and polymyalgia rheumatic (PMR) are very common inflammatory rheumatologic disorders in persons aged over 50 years. Several previous cases reports suggested an association between cancer and GCA as paraneoplastic phenomenon. We describe a new observation of CGA/PMR in which the diagnosis of GCA permitted the diagnosis of bladder cancer.

Case description

A 73-year-old patient followed up for hypertension, chronic renal failure and coronaropathy presented with 4-week history of asthenia, headache refractory to analgesia, scalp tenderness, jaw claudication, proximal myalgia and weight loss of 10 Kg over the previous month.

Physical examination showed poor medical condition, normal blood pressure, shoulder and pelvic girdle pain without muscle weakness and bilateral absence of temporal artery pulse.

Ophthalmological examination was normal.

Laboratory tests revealed systemic inflammation: elevated C reactive protein (160 mg/l) and erythrocyte sediment rate (63 mm at the first hour) with hyper alpha 2 (12.5 mg/l).

Although ultra sound of external carotids and temporal arteries was normal and temporal biopsy showed medial calcific sclerosis, the diagnosis of GCA and PMR was suspected and the patient was treated with 30 mg/day of corticosteroid.

Headaches, scalp tenderness, shoulder and hip girdle pain rapidly improved after 2 weeks of corticosteroids, CRP and ESR decreased and the patient gained weight confirming the diagnosis of CGA/PMR.

Regarding the initial important weight loss, an abdominal ultrasound was performed and revealed prostatic hypertrophy without repercussions on the upper urinary tract and a bladder wall tumor.

Cystoscopy and endoscopic resection were performed and pathology revealed grad 2 papillary urothelial carcinoma pT1 G2 and the patient received BCG therapy and corticosteroids were tapered on 18 months.

Nearly 3 years after BCG therapy and corticosteroids, the patient fully recovered: no headaches, jaw claudication, nor muscles tenderness and for his bladder tumor, pelvic ultrasound showed no sign of recurrence.

Discussion

Although previous cases reports suggested that GCA/PMR might occur as a paraneoplastic phenomenon, epidemiological studies remain controversial about the increased incidence of cancers among patients with GCA/PMR. The most reported cancers were skin cancers and hematologic disorders. Urothelial bladder cancer has never been reported in patients with GCA/PMR.

#683 - Case Report

ABDOMINAL PAIN... WHAT DANGERS DOES IT HIDE?

Maria Silva, Maria Palavras, Filipa Alçada, Anton Vasin, Célio Fernandes

Centro Hospitalar de Leiria, Leiria, Portugal

Introduction

Essential Thrombocythemia (ET) is a Philadelphia chromosome myeloproliferative neoplasm, also called negative BCR-ABL, in which there is an uncontrolled increase in the production of megakaryocytes in the bone marrow (BM) with consequent peripheral thrombocytosis. It leads to thrombo-hemorrhagic events that are the major cause of morbidity and mortality. Not being specific to this pathology, half of these patients have JAK2 mutation. The diagnosis includes the detection of megakaryocytic hyperplasia in BM, as well as the exclusion of systemic causes capable of elevating platelets. There is no curative treatment, only agents capable of reducing platelet count and prevention of thrombohemorrhagic complications.

Case description

Male, 68 years old with rheumatoid arthritis under methotrexate and prostate tumor. He applied to the Emergency Department for epigastric and left flank pain. No masses were palpable. Analytically, leukocytosis 18,000 leu/ul; monocytosis 4200 mon/ul; platelets 879,000 pla/ul and Hb 14.2 g/dl. Abdominal and pelvic tomography showed "hypodensity of the entire middle and lower splenic third, in relation to an extensive area of splenic ischemia, associated with arterial and splenic vein thrombosis." A genetic study of thrombophilias was performed, initiating enoxaparin with resolution of complaints and imaging improvement, with partial reperfusion of the ischemic zones at the 6-month control. The medulogram indicated "myeloid line with >10% of dysplasia, 2% of blasts, normal phenotype monocytes and alterations suggesting reactive neutropoiesis with JAK2V617F+" and bone biopsy was suggestive of myeloproliferative syndrome of the type T. He was found to be homozygous carrier of the MTHFR 1298C mutation and PAI-15G / 4G heterozygote. For the purposes of differential diagnosis, the BCR-ABL fusion gene was investigated, resulting negative.

Discussion

The authors intend to discuss the importance of the differential diagnosis of thrombocytosis, alerting to the importance of less frequent diagnoses that follow these changes.

#702 - Case Report

THROMBOTIC THROMBOCYTOPENIC PURPURA – A NEOPLASTIC EMERGENCY?

Mariana Oliveira, Luís Dias

Hospital Divino Espirito Santo, Ponta Delgada, Ponta Delgada, Portugal

Introduction

Thrombotic microangiopathy (TMA), in the form of thrombotic thrombocytopenic purpura (TTP), is a known and severe, but rare, complication of cancer patients. It occurs in association with chemotherapy or in disseminated disease, most often in association with gastric adenocarcinomas.

Case description

We describe the case of a 59-year-old man, with a history of gastric adenocarcinoma, who underwent total gastrectomy in 2013. Currently undergoing restaging due to gastric stump recurrence. He was admitted with haematemesis, jaundice, abdominal pain and thrombocytopenia (34,000 uL), and 1 pool of platelets was transfused. The patient returns days later with maintenance of complaints, asthenia, anorexia and mechanical type lumbar pain, without new episodes of blood loss. Anaemia (Hb 5.2g / dL), Alkaline phosphatase 1303 U/L, gamma glutamyl transferase 13 U/L, lactate dehydrogenase 1372 U/L, Total/Direct bilirubin 6.12/1.80 mg /dL, C-reactive protein 38.6 mg/dL. Normal renal function. Blood cultures and uroculture were then collected, which proved to be negative, and empirically initiated ertapenem. Patient presented with reticulocytosis in the blood smear, 3.2% schistocytes and red cell population dimorphism. Patient received 2U GV and new pool of platelets. Vitamin B12 titration <83 pg/mL, having initiated cyanocobalamin supplementation. Ferritin 37,192 ng/ml. Tumor markers: CEA 32.3 ng/mL and CA-125 84.3 U/mL. Despite multiple transfusions, the patient maintained anaemia and thrombocytopenia, which worsened with deterioration of the neurologic state (coma) and oliguric renal failure, and died in D6 of hospitalization.

Discussion

The diagnosis of TMA is based on clinical suspicion, recognition of microvascular thrombosis, haemolysis and platelet consumption, and characterization of the blood smear. Early recognition of this entity and chemotherapy seem to be decisive for its resolution and prolongation of survival, and plasmapheresis does not appear to have benefits in cancer patients. These patients have an extremely poor prognosis, with reported survivals from days to weeks.

#708 - Case Report

A CASE OF PANCYTOPENIA - THE IMPORTANCE OF A SYSTEMATIZED APPROACH

Juliana Magalhães, José Pereira, Teresa Vilaça, Inês Antunes, Ivone Barracha, Rosa Amorim

Centro Hospitalar do Oeste - Unidade de Torres Vedras, Torres Vedras, Portugal

Introduction

Pancytopenia is a frequent manifestation in clinical practice, associated with multiple pathologies, and may be classified as central if there is a decrease in hematopoietic cells in the bone marrow (BM) or peripheral if there is a peripheral decrease in hematic cells with cellularity of normal BM. The prognosis depends on the etiology and the most serious pathologies include aplastic anemia, hemophagocytic syndrome and acute leukemias.

Case description

We present the case of a 76-year-old woman with a history of hypertensive cardiopathy, multinodular goiter and occlusion of the left retinal vein, which recurs to the ED due to asthenia, anorexia, palpitations, malleolar edema and nocturnal hypersudoresis with two weeks of evolution. She reported a recent case of acute gastroenteritis, having been treated with ciprofloxacin.

On the observation, she was pale, dehydrated, feverish, heart auscultation with tachycardic tones, pulmonary auscultation without alterations, painless abdomen and without organomegalies and bilateral edema to the knees.

Analytically, she had normocytic and normochromic anemia, leukopenia with relative lymphocytosis and thrombocytopenia, ESR 115 mm/s, LDH 624 U/L, creatinine 1.06 mg/dL, urea 78 mg/dL, CRP 25 mg/dL, urinary sediment without changes. Chest X-ray without acute pleuroparenchymal lesions. She was hospitalized for fever and pancytopenia. Empirical antibiotic therapy was started with piperacillin-tazobactam, later changed to meropenem directed to MDR E.coli isolated in urine culture. Progressive apyrexia but persistence of hematological alterations was observed. An analytical study was performed with negative viral serologies for EBV, CMV, HIV, normal B12 vitamin and folic acid, serum and urinary Immunoelectrophoresis unchanged and body CT that only documented a spiculate nodular lesion in the left inferior lobe of 10 mm, with difficult approach for guided biopsy. She performed myelogram and bone biopsy, which confirmed acute myeloid leukemia with maturation (M2) and was transferred to the Hematology Service. He immediately started chemotherapy (IDA and CAR) and is currently in complete remission.

Discussion

This case shows the importance of a general and systematic approach to the diagnosis of the etiology of pancytopenia. Although initially the most likely hypotheses were infectious or drug-related, the persistence of hematological changes led to

further investigation that allowed the diagnosis of acute myeloid leukemia and its timely treatment.

#722 - Case Report

ERYTHROCYTOSIS PRESENTED AS A SEIZURE

Filipa Sousa Gonçalves, Nina Jancar, Mariana Simões, Patrício Aguiar, José Luís Ducla Soares

Centro Hospitalar Universitário Lisboa Norte, Lisbon, Portugal

Introduction

Erythrocytosis is often an accidental finding in routine blood tests. However, its clinical presentation is heterogeneous, including fatal complications. It is a condition with multiple possible etiologies and a challenging differential diagnosis.

Case description

A 86-years old female patient with previous diagnosis of hypertension, type 2 diabetes mellitus, dyslipidaemia, mitral and aortic valvular heart disease, multifactorial heart failure with preserved systolic function, chronic kidney disease stage G3a (KDIGO) and hypothyroidism, presented with hypertension, dyspnoea and tiredness for progressively smaller efforts, orthopnoea, paroxysmal nocturnal dyspnoea and lower limb edema. The initial evaluation showed erythrocytosis (haematocrit 55%), thrombocytopenia (73000/uL), NTproBNP 3308 pg/mL, mixed alkalosis without respiratory failure and a normal P50 and chest X-ray with right pleural effusion.

She was admitted due to decompensated heart failure in a hypertensive setting and erythrocytosis of unknown etiology. In the first hours of hospitalization, she presented a generalized tonic-clonic seizure, with about 1 minute of duration and spontaneous recovery. The cranial CT-scan revealed diffuse spontaneous densification of the dural and deep venous system, aspects in probable relation with elevation of the hematocrit, so it was admitted a seizure due to hyperviscosity syndrome. In this context, she performed phlebotomy (500 mL), without recurrent seizures.

Myelogram and bone biopsy were performed but had no pathological features, the JAK-2 gene mutation was negative and erythropoietin levels were within the reference values, which allowed the exclusion of secondary erythrocytosis.

Given the clinical stability, she was discharged, continuing the etiological investigation in the outpatient clinic.

Discussion

Although often asymptomatic, most clinical manifestations of absolute erythrocytosis are related to increased blood viscosity, causing a decrease in capillary blood flow, resulting in tissue hypoxia and thrombosis. This involvement of the microcirculation occurs at the brain level and is responsible for the neurological manifestations of erythrocytosis, such as behaviour changes, ataxia and visual changes. Seizures are a very rare initial manifestation of this condition, but it demands a particular approach, being

crucial a prompt identification and careful management of the erythrocytosis.

#727 - Medical Image

PROSTATIC CANCER? A SURPRISING DIAGNOSIS

Maria João Gomes, Inês Bargiela, Ana Sofia Ventura

Hospital Professor Doutor Fernando Fonseca, Amadora, Portugal

Clinical summary

The authors present a case of a 86-year-old male patient with

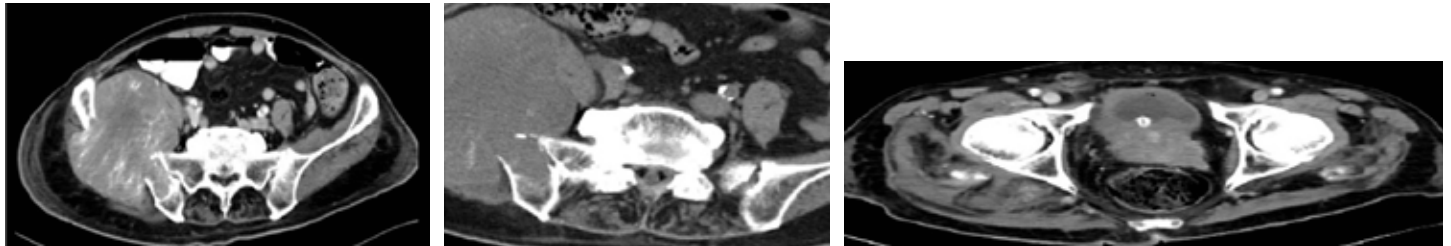


Figure #727. Right sacroiliac mass; heterogeneous mass of the prostate gland.

#729 - Case Report

PULMONARY EMBOLISM AS A PRESENTING MANIFESTATION OF CEREBRAL GLIAL TUMOR

Youssef Gharbi^{1,2}, Maroua Mrouki^{1,2}, Yosra Cherif^{1,2}, Amal Baya Chatti^{1,2}, Fatma Ben Dahmen², Meya Abdallah^{1,2}

¹ Tunis El Manar University Faculty of Medicine of Tunis, Tunis, Tunisia

² Regional Hospital Ben Arous, Internal Medicine Department, Ben Arous, Tunisia

Introduction

Cerebral gliomatosis (CG) are a group of rare infiltrative tumor entity of the brain whose prognosis is reserved. thromboembolic event (TE) as a presenting manifestation of this entity is exceptional excluding the post-operative context.

Case description

A 53-year-old man presented with respiratory distress secondary to a pulmonary embolism (PE). Chest CT scan showed several micronodules without any malignant feature, Abdominopelvic ultrasound showed hypertrophy of the prostate and cervical ultrasound was normal. Tumor markers (AFP, ACE, CA 19-9 antigen, PSA) were normal. The patient was treated with heparin and anti-vitamin K drugs. Three weeks after the diagnosis of PE, he was admitted to the emergency room for generalized convulsions without trauma or fever. Laboratory tests were normal and brain imaging showed cerebral gliomatosis. He was treated with corticosteroids 20 mg/day and valproic acid. A stereotaxic biopsy to determine the phenotype of the CG could not be achieved. The patient died 18 months after the onset of the diagnosis in a context of intracranial hypertension.

weight loss, low back pain and urinary retention who presented with hypercalcaemia (12.4 mg/dL). The laboratory tests showed raised erythrocyte sedimentation rate (54 mm) and prostate-specific antigen 15 ng/mL. The lumbar spine computerized tomography (CT) showed a right sacroiliac osteolytic mass with 115x89 mm with destruction of the right iliac bone and sacrum wings S1 to S3. The thoraco-abdominopelvic CT revealed a neoplastic lesion of the prostate with left seminal vesicle and bladder floor invasion, pulmonary and infra-diaphragmatic lymph node metastasis with an extensive soft-tissue involvement of right iliac bone and the left ischium-pubic branch. Histopathological examination revealed prostatic undifferentiated carcinoma.

Discussion

The association between venous thromboembolic diseases and neoplasia is widely established however the discovery of a cerebral gliomatosis as neoplastic etiology of the VTE is rare. Indeed, the thromboembolism events are common in the postoperative period in cerebral neoplasia and specifically in glial tumors. TE accidents associated with these pathologies are generally attributed to the postoperative context, corticosteroid treatment or the chemotherapy. This observation is particular by the occurrence of the VTE as a first manifestation of the disease.

#740 - Case Report

EVERY LITTLE HELPS

Miguel Martins, Francisca Martins, Sara Marote, Mariana Silva
Centro Hospitalar de Lisboa Central, Lisboa, Portugal

Introduction

The study of a ischemic stroke (cerebrovascular accident) in a young patient compels us to exclude less common diagnoses. And sometimes there are no other clinical symptoms to help...

Case description

A 44-year-old male presented to the emergency department of our hospital with sudden loss of strength in the right upper limb and difficulty in diction during a football match. A diagnosis of ischemic stroke, caused by occlusion of the left middle cerebral artery was made. After a short hospitalization, with complete recovery of the hemiplegia and dysarthria, he was discharged for follow-up in consultation.

In his first appointment, 10 days after the stroke, the patient

denied new episodes. He reported occasional nocturia (2/night) and pricking sensation in the lumbar region after periods of intense exercise. He denied palpitations, dyspnea, cyanosis, musculoskeletal pain, fever, gastric transit changes, visible blood loss, aquagenic pruritus or erythromelalgia. His body mass index, blood pressure and blood sugar levels were within normal values. His pulse was regular and rhythmic. He worked as an engineer in a city. He was married, but he had no siblings. He denied smoking or alcoholic habits, as well as other drugs. He had an active lifestyle, and a complete and balanced diet, with low intake of fat and salt. His medical history was unremarkable. His father died at 60, after a stroke. An electrocardiogram showed a sinusoidal rhythm, with a heart rate of 66 beats per minute. A transthoracic echocardiogram didn't find valvular disease, ventricular thrombosis or patent foramen ovale. An echo-doppler of neck vessels found no signs of vessels stenosis. LDL and HDL cholesterol, and LDL/HDL ratio were normal. Mutations for thrombophilias weren't found. Antiphospholipid antibodies were negative. Due to persistent thrombocytosis with ~ 600,000/L platelets, with no morphologic changes, and familial history of cerebral vascular disease at young age, a JAK2 mutation test was required and found to be positive.

Discussion

The absence of criteria for other myeloproliferative syndromes and the presence of large megakaryocytes in the myelogram confirmed the diagnosis of essential thrombocythemia (ET). There are few reported cases of ET with mild thrombocytosis that manifests itself as an isolated ischemic stroke. However, this case demonstrates that even slight increases in platelets are not negligible and should lead the physician to rule out myeloproliferative syndrome.

#763 - Case Report

HYPERVISCOSITY SYNDROME IN AN IGG/LAMBDA MULTIPLE MYELOMA PATIENT: A CASE REPORT

Carlos Rodrigues, Andreína Vasconcelos, Gisela Fernandes, João Fonseca
CHBV, Aveiro, Portugal

Introduction

Multiple myeloma (MM) is a monoclonal neoplasm derived from the clonal proliferation of a single plasma cell. Hyperviscosity syndrome (HS) complicates the natural course of about 2-6 % of myeloma patients and results from the plasma accumulation of immunoglobulins, mostly IgM. IgG myelomas only associate with HS in circa 3 % of the cases, and the IgG3 subclass depicts the highest tendency to aggregate. They correlate with various neurologic deficits, mucosal bleeding and retinopathy.

Case description

A 70 years old man was sent to the emergency room due to a constitutional syndrome evolving over the past 2 months, with

history of severe asthenia and anorexia, marked weight loss and rapidly progressive dementia. Apart from properly medicated diabetes, dyslipidemia and arterial hypertension, the remaining clinical record was irrelevant. The patient carried pre-admission brain and full body CT-scans that identified osteolytic lesions along several bones (confirmed by bone scintigraphy). At physical examination, he was conscious, but extremely confused and agitated, hemodynamically stable and with active hemorrhage of the gums. Post-admission study revealed normocytic normochromic anemia, elevated serum IgG (7600 mg/dL) and lambda light chains (2040 mg/dL), and a kappa/lambda coefficient of 0.01, and prompt the bone marrow study that confirmed MM diagnosis by identifying 15 % medullary plasmacytosis. Fundoscopy identified bilateral retinal vascular dilation and tortuosity with retinal hemorrhages compatible with HS. The patient underwent 2 sessions of plasmapheresis and started targeted chemotherapy with cyclophosphamide, bortezomib and dexamethasone with positive improvement of his mental and functional status and resolution of the hemorrhagic lesions. Later the serum viscosity confirmed the diagnosis of HS. He now keeps treatment at outpatient hospital and the disease has stabilized.

Discussion

IgG-associated HS is a rare entity whose diagnose requires awareness and elevated clinical suspicion. Neurologic alterations should always prompt the search for HS, whose treatment encompasses a relatively simple procedure with potential positive impact on MM prognosis and patients' wellbeing. Viscosity measurements are not required to initiate therapy, if the index of suspicion is high and the clinical presentation is typical. However patients should have a sample sent to confirm the diagnosis.

#766 - Case Report

A RARE PRESENTATION OF PRIMARY SPLENIC ANGIOSARCOMA

Alba Bergas-Farrés, Francesc Escrihuela-Vidal, Olga Capdevila-Pons, Xavier Corbella-Virós
Hospital Universitari de Bellvitge, L'Hospitalet De Llobregat, Spain

Introduction

Primary splenic angiosarcoma is an aggressive malignancy with a high metastatic rate and poor outcome.

Case description

An 81-year-old woman complained of fatigue. Study showed microcytic anemia and acute phase reactants, endoscopic studies were normal. CT scan showed 2 splenic cystic lesions with signs of active bleeding. Splenectomy was performed with no histological evidence of malignancy. Two months later she suffered an extensive left hemothorax. A chest tube was placed with no malignant cells or microorganisms found in pleural fluid. Anemia developed and a hematic collection was detected in the surgical site. Two subcutaneous masses developed in the left posterior thorax in

close relationship with the scar of the chest tube, with similar radiological characteristics to splenic cysts. Positron emission tomography showed metabolic activity in all masses. Ultrasound-guided biopsy was performed with no evidence of malignancy. A whole mass was surgically excised. Histological examination led to the diagnosis of splenic angiosarcoma. Oncological treatment could not be started and the patient was discharged home with palliative follow-up.

Discussion

Primary splenic angiosarcoma has a very low incidence and differential diagnosis should include benign splenic hemangioma and malignant lymphoma. Fine-needle aspiration cytology has been shown useful but surgical biopsy or excision may be needed. Average survival time accounts for less than 6 months after diagnosis. Mitotic cell count, large tumor size and metastatic disease at diagnosis are independent factors of bad prognosis. Splenic tumor rupture enables peritoneal dissemination and hematogenous spread. Splenectomy is the first treatment option; chemotherapy and local radiotherapy have been used. We report a case of splenic angiosarcoma in a patient with hemothorax and subcutaneous masses after splenectomy. An extensive hematological, infectious, and autoimmune study was performed. Fine-needle aspiration was inconclusive. Surgical excision was needed to achieve the final diagnosis. We suspect an accidental splenic rupture occurred during the spleen excision surgery, thus easing hematogenous and local spread of the tumor. In conclusion, primary splenic angiosarcoma should be considered when diagnosing spleen masses, and histological analysis of fine-needle aspiration or surgical samples may be the key test to perform an early diagnosis and consider treatment options.

#769 - Case Report

INCIDENTALLY DETECTED MEDIASTINAL MASS: A CASE REPORT

Rosário Eça¹, Raquel Mesquita¹, Bruno Mendes¹, Pedro Duarte Mesquita¹, Cláudia Janeiro¹, João Alves Teixeira¹, Inês Santos¹, Sara Valente Da Costa²

¹ Centro Hospitalar Lisboa Central, Lisbon, Portugal

² Faculdade de Ciências Médicas da Universidade Nova de Lisboa, Lisbon, Portugal

Introduction

Different types of mediastinal masses can be encountered as radiological images in symptomatic or asymptomatic patients. One of neoplasms in the mediastinum is the neuroendocrine carcinomas (NECs), which is a rare disease.

Case description

This report describes a 66-year-old man, heavy smoker, who had been suffering for 6 months of chronic cough, weight loss, anorexia, as well as 1 week of dysphonia prior to his admission. Chest radiography (CR) and CT were abnormal, with the later

revealing a large heterogeneous mediastinal mass and possible distant metastasis. Immunohistochemical study was positive for AE1/AE3, CD56, chromogranin A and synaptophysin. This turned out to be a high-grade carcinoma, later diagnosed as a poorly differentiated neuroendocrine carcinoma, small cell type.

Discussion

Mediastinal masses are most often diagnosed as incidental imaging findings on CR, commonly used as the initial imaging modality. Most often than not, these masses are detected at a later stage, just like in the case reported of an NEC. The diagnosis of a NEC requires a combination of pathological and immunohistochemical examinations. Chromogranin A and synaptophysin are the main diagnostic markers of NEC, being chromogranin A highly specific and synaptophysin a broad-spectrum marker of neuroendocrine cells. In the case reported, the tumour was positive for chromogranin A and synaptophysin which is consistent with the reports in the literature. CD56 has a high sensitivity with more than 90% positivity in NEC, but a weak specificity.

A multidisciplinary approach is recommended for the evaluation and treatment of NEC owing to its potential for invasion and metastasis. Surgery complemented with chemotherapy and radiotherapy might alleviate the symptoms and prolong survival, although due to delayed diagnosis, the patient was only liable for palliative care and died a few weeks later.

This case is reported with the intention to bring into light the effect of delayed diagnosis of NEC.

#778 - Medical Image

DIZZINESS IN A SMOKER, A CASE OF LUNG CANCER

Magda Joana Garça, Maria Beatriz Santos, Paulo Ávila

Hospital of the Holy Spirit of Terceira Island, Angra Do Heroísmo, Portugal

Clinical summary

A 66-year-old male patient, smoker, with a 5 days history of dizziness and anorexia. Chest X-ray revealed three lung masses (right panel). Patient was hospitalized for symptomatic control and clinical study. Thoracic CT: "parenchymal mass (62x53 mm) on the lingula and medial left lobe extending to the hilum and pleura; a nodular lesion on the right upper lobe, irregular contours; and a nodular lesion (50x47 mm), lower right lobe, cavitate with thickened walls" (left panel). Brain CT revealed a lesion suggestive of metastasis.

Bronchoscopy with a bronchial biopsy was essential for the diagnosis: squamous cell carcinoma.

Lung cancer is the world's leading cause of cancer death. The risk of cancer is directly proportional to the number of cigarettes smoked per day and the duration of chronic smoking.

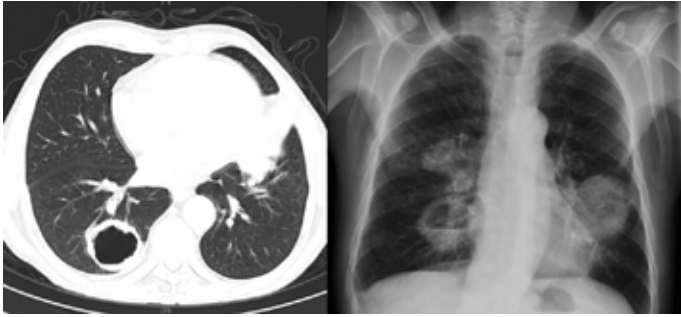


Figure #778. Left: Thoracic TC scan. Right: X-ray.

#784 - Case Report

DIFFUSE LARGE B-CELL LYMPHOMA: A COMPRESSIVE RETROPERITONEAL MASS

Daniela Viana, Círia Sousa, Anusca Paixão, Natália Lopes, Bruno Mesquita, Marisol Guerra, Paula Marques

Centro Hospitalar de Trás Os Montes é Alto Douro, Vila Real, Portugal

Introduction

Diffuse large B-cell lymphoma (DLBCL) is the most common non-Hodgkin's lymphoma (NHL), constituting about 25% of NHL. The most common presentation is a fast-growing symptomatic mass, usually nodal enlargement in the neck or abdomen. B-symptoms are present in only 30% of the cases, and approximately 60% are advanced.

Case description

We describe the case of a 40-year-old man with history of low back pain radiating to the right leg for the previous 6 months. He went to the emergency department (ED) day 18/09 with right testicular swelling with 5 days of evolution and was discharged with symptomatic treatment and referral for posterior ultrasound evaluation.

He returned to the ED day 29/09 with left inguinal swelling. A reducible inguinal hernia was assumed and surgery was scheduled. A new microcytic and hypochromic anemia with hemoglobin (Hb) of 11.9 g/dL was identified in the general practitioner for which oral iron was started, without further investigation.

Due to worsening anemia, he was referred to the Internal Medicine (IM) office on 17/12, in which a marked edema of the left lower limb and anuria was detected, with 8 and 1 day of evolution respectively, as well as an abdominal mass of ill defined contours in the right flank and a hydrocele.

The abdominal computed tomography (CT) showed a large retroperitoneal mass, measuring 9.5x17x16cm involving the large abdominal vessels and visceral branches, with multiple thrombosis; lumbar ureters with moderate bilateral hydronephrosis; hepatomegaly, osteolytic lesions in L4-L5 and probable peritoneal carcinomatosis. He was admitted to the IM ward with the suspicion of lymphoproliferative process or sarcoma. In the complementary study we emphasize cranioencephalic CT with osteolytic lesions of probable secondary nature; Endoscopy with a very friable neof ormation in the proximal jejunum and a gastric biopsy that

showed LDGCB. The Patient started chemotherapy day 11/01 with cyclophosphamide, vincristine and prednisolone.

Discussion

In this case report we are turning our attention to an atypical presentation of LDGCB, with nonspecific complaints that may present as confounding factors. Besides, we shed light on the importance of the etiological study of anemia, especially in young male adults. Remembering that the patient should always be evaluated as a whole, collecting a complete medical history and physical examination in every appointment, because the highly aggressive nature of this lymphoma necessitates timely diagnosis and intervention.

#796 - Case Report

REACTIVATION OF CHRONIC HBV INFECTION IN A PATIENT UNDERGOING IMMUNOTHERAPY

Maria Bachlitzanaki¹, Emmanouil Kontopodis¹, Andreas Antonakis², Melina Kavousanaki², Nikolaos Simseridis¹, Emmanouil Saloustris¹, Ioannis Drositis¹, Nikolaos Androulakis¹

¹ Oncology Department, Venizeleio General Hospital, Heraklion Crete, Greece

² A' Internal Medicine Department, Venizeleio General Hospital, Heraklion Crete, Greece

Introduction

Although hepatotoxicity is a common adverse reaction of Immune Checkpoint Inhibitors (ICIs), there are limited data for HBV infection reactivation. Herein we present a case of chronic HBV infection reactivation in a female patient with metastatic cervical cancer undergoing immunotherapy with pembrolizumab.

Case description

A 56-year-old female patient was diagnosed with locally advanced squamous cell cervical cancer 10 years ago and received chemoradiotherapy followed by total abdominal hysterectomy and bilateral salpingo-oophorectomy. At the time of diagnosis, the patient was an HBV carrier [HBsAg(+), anti-HBcore(+), anti-HBcore-IgM(-), anti-HBs(-), anti-Hbe(+)] without the clinical presentation of active hepatitis B as the liver function tests were normal (viral load not available) and therefore no antiviral treatment was administered. 5 years after the diagnosis, the patient presented with pleural and lung metastases and the cancer recurrence was histologically confirmed through pulmonary biopsy and subsequently multiple regimens were used (paclitaxel, carboplatin and bevacizumab, gemcitabine, vinorelbine, paclitaxel and carboplatin again), with no liver function disorder. On April 2018, after the expression of PD-L1 (positivity 1%) detected on pleural metastasis biopsy, the patient was treated with pembrolizumab 200 mg every 3 weeks and the disease remained stable. During the 5th cycle, liver function disorder was observed (SGOT 109 U/L, SGPT 147 U/L, γ GT 48 U/L, ALP 65 U/L, LDH 259

U/L, bilirubin 0,5 mg/dL) with no liver failure signs. Serum HBV-DNA level (through real time PCR method) measured $4,84 \times 10^4$ IU/mL. As a result, entecavir (0,5 mg 1x1 per os) was administered and liver function tests normalized within 2 weeks. Concurrently, immunotherapy with pembrolizumab was not postponed and after the administration of 6 more cycles, no further liver dysfunction was observed.

Discussion

Considering liver function disorder in patients receiving ICIs therapy, viral hepatitis infection should be excluded and therefore HBV/HCV testing would be useful before treatment inception.

#799 - Case Report

PORTAL VEIN THROMBOSIS SECONDARY TO OCCULT POLYCYTHEMIA VERA

Anton F. R. Gameiro, António Robalo Nunes, Paula Guerra, Estela Mateus, Fátima Fernandes
Hospital dos SAMS, Lisbon, Portugal

Introduction

Portal vein thrombosis (PVT) is an uncommon finding in non-cirrhotic patients. The underlying etiology in this scenario is challenging, unfolding a large number of differential diagnosis, including hypercoagulable states, autoimmune disease and myeloproliferative disorders.

Case description

A 75-year-old female, previously diagnosed with mild chronic anemia, due to iron and folic acid deficiency, and Hashimoto's thyroiditis; presented with ascites, abdominal pain and weight loss. CT scan and MRI revealed portal and superior mesenteric vein thrombosis with cavernous transformation, marked ascites and normal liver parenchyma structure. The initial diagnostic approach was directed to hypercoagulable states, neoplastic and autoimmune diseases, which were excluded. After an accurate review of the patient's previous clinical history, with anemia at present, we identified a short period of laboratorial erythrocytosis six months before the clinical onset. It was confirmed the presence

of V617F JAK2 mutation, low levels of EPO and a hypercellular bone marrow, meeting polycythemia vera diagnostic criteria, based on World Health Organization classification. The patient is currently on anticoagulation therapy with recanalization of the superior mesenteric vein, preserving cavernous transformation in the portal vein, as expected, after three months.

Discussion

Myeloproliferative disorders are associated with systemic prothrombotic states and are a less frequently identified cause of PVT. Polycythemia vera is distinguished clinically from the other myeloproliferative disorders by the presence of an elevated red blood cell mass. This case provides an intricate case, as it represents an improbable diagnosis for PVT in an anemic patient, with chronic iron and folic acid deficiency, masking an underlying polycythemia vera.

#804 - Medical Image

SYMPTOMATIC HYPOCALCAEMIA IN THE CONTEXT OF OSTEOLASTIC LESIONS

Marília Santos Silva, Alexandre Vasconcelos

Hospital Pedro Hispano - Matosinhos Local Health unit, Matosinhos, Portugal

Clinical summary

An 89-year-old man with a history of prostatic disease, with refusal of biopsy 2 years before, and 6 months of progressive apathy and dependency, was brought to the emergency department because of refusal to eat and cough in the previous week. Analytically of note: hypocalcemia (0.68 mmol/L), elevation of alkaline phosphatase (732 U/L) and C reactive protein, normocytic normochromic anemia (8.1 g/dL) and thrombocytopenia ($114000/\mu\text{L}$). Computed tomography identified a pneumonia with pleural effusion and diffusely sclerotic bone lesions compatible with prostatic metastatic cancer, hypothesis supported by a prostate-specific antigen of 284 ng/mL. Vitamin D was low and parathyroid hormone was raised. After antibiotic treatment, further apathy amelioration was seen with hypocalcemia correction.

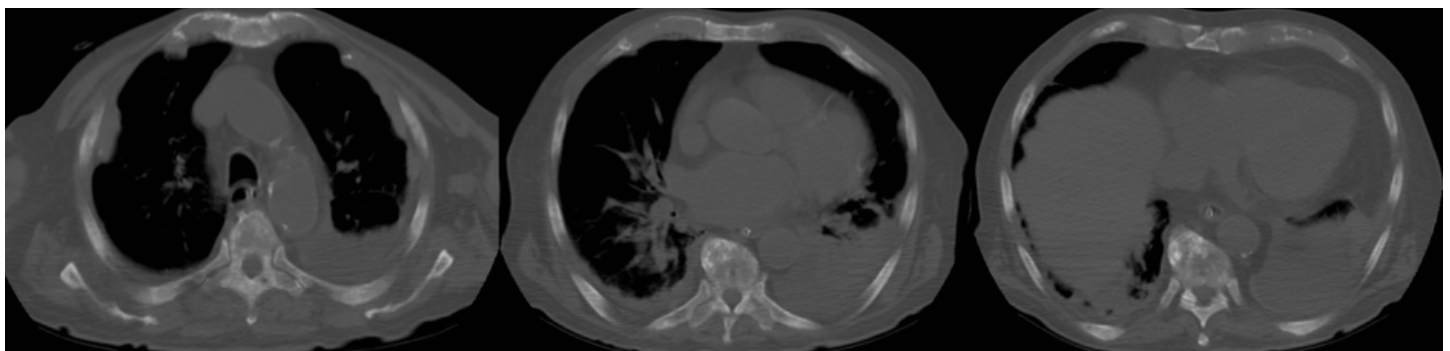


Figure #804. Pneumonia with pleural effusion and diffusely sclerotic bone lesions.

#813 - Case Report

KAPOSI SARCOMA IN A NON-HUMAN IMMUNODEFICIENCY VIRUS (HIV) PATIENT: AN INTERESTINGLY CASE REPORT

Mariana Certal, Rita Cunha, Adelaide Moutinho, Catarina Costa, Sandra Tavares

Centro Hospitalar de Trás-os-Montes e Alto Douro, Chaves, Portugal

Introduction

Kaposi sarcoma (KS), one of the acquired immune deficiency syndrome defining condition, is a rare multi-focal vascular tumor involving skin and other organs that is rare in non-immunosuppressed patients.

Case description

Our patient was a 89-years-old male with past medical history of arterial hypertension, vesicular lithiasis and benign prostatic hyperplasia. He was admitted to the medical service with a history of violaceous lesions in the limb, with no other complaints. On further enquiry, there was no history of fever, diarrhea, or weight loss. There was no history of any drug intake prior to the onset of lesions, blood transfusion or intravenous drug abuse. On general examination, he was hemodynamically stable, afebrile, cardiac and pulmonary auscultations were normal. Dermatological examination showed violaceous lesions with asymmetric edema in the palm of the left hand, lower lip, on the inner face of the right knee suggesting KS. Oral cavity was normal. Results of laboratory investigations revealed the following: normal complete blood count, renal function and liver function tests, and sedimentation rate of 62 mm. Interestingly, HIV serology was negative. CMV and toxoplasmosis were IgG positive and IgM negative, and HCV was negative. The histological examination of biopsy fragment showed skin almost completely occupied by a nodular lesion with characteristics of KS, which in the immunohistochemical study performed reveals cellular elements staining for CD34, Podoplanin (D2-40) and HHV-8.

Discussion

We present the case report of a male patient who came to our clinic presenting violaceous lesions in the limb and, despite laboratory tests revealed negative serology for HIV, histopathology examination after lesion excision was compatible with KS. The diagnosis of KS was made based on clinical presentation and histopathological examination, and this clinical case shows that, despite primary KS is rare, it may occur in immunocompetent patients.

#821 - Case Report

LOOKING THROUGH THE HEART!

Cátia Costa Oliveira, Isabel Durães Campos, Carla Pires Rodrigues, Paulo Medeiros, Carlos Galvão Braga, Luís Dias, Cristina Ângela, Catarina Vieira, Herlander Marques, Alberto Salgado, Jorge Marques

Hospital de Braga, Braga, Portugal

Introduction

Amyloidosis represents a large spectrum of systemic diseases. Heart failure may be its first sign.

Case description

A 67 years old woman with a previous history of hypertension, atrial fibrillation (AF) and known severe concentric hypertrophy (more pronounced at the interventricular septum) with moderate pulmonary hypertension and diastolic dysfunction of the left ventricle (LV) resorted to the urgency service for weight loss, asthenia and dyspnea for minor efforts. Her physical examination was innocent. Her ECG showed AF and low voltage in limb and precordial leads. Patient was admitted at the Cardiology Department for investigation. A new TTE revealed fast progression of the hypertrophic pattern (IVS 26 mm, and posterior wall 18 mm) with a rest outflow tract gradient of 18 mmHg; free right ventricular wall was also hypertrophied with 12 mm and a type II diastolic dysfunction was present. A complete investigation for ventricular hypertrophy and constitutional syndrome was done. CMR demonstrated preserved biventricular systolic function, LV hypertrophy with septal predominance (24 mm) with elevated myocardial mass indexed to body mass (114 g/m²) and late diffuse subendocardial gadolinium enhancement. (99m) Tc -DPD scintigraphy was negative for ATTR; Anderson-Fabry disease was excluded by genetic testing. Blood analysis revealed a normocytic/ normochromic anemia and a disproportional ratio of free light immunoglobulin chains K/λ, with a predominance of lambda chains. β₂-microglobulin was also elevated. 24 hours urine analyses were normal. The hypothesis of non-secretor multiple myeloma (MM) with light chain immunoglobulin amyloidosis (AL) was then admitted. The patient underwent bone marrow and salivary gland biopsies which confirmed MM and deposition of amyloid, respectively. The FISH analyses demonstrated a deletion of RB1 gene on 13q14.3 sequence and of TP53 on 17p13.1, both associated with a poorly prognosis in MM. The patient was referred for oncology where she is currently undergoing chemotherapy for MM and AL amyloidosis.

Discussion

This case reflects the diagnostic work-up in the presence of a hypertrophic LV pattern as well as the importance of high clinical suspicion and early diagnosis. While AL amyloidosis occurs in isolation, 10% of patients with multiple myeloma develop systemic AL amyloid with cardiac involvement. The distinction between these entities is not only semantic, but has extremely important prognosis and therapeutic considerations.

#827 - Abstract

PREDICTORS OF NEOPLASIA IN PATIENTS WITH ACUTE PULMONARY EMBOLISM

Ana Ribeiro¹, Inês Guerreiro², Helena Magalhães², Sara Coelho², Sara Ferreira¹, Emanuel Araújo¹, Paulo Bettencourt³, Patrícia Lourenço¹

¹ Department of Internal Medicine, São João University Hospital Center, Porto, Portugal

² Department of Medical Oncology, Portuguese Oncology Institute of Porto, Porto, Portugal

³ Department of Internal Medicine, CUF Porto Hospital Center, Porto, Portugal

Background

Acute pulmonary embolism (PE) can occur as a manifestation of an underlying neoplasia. Also, a previously unknown neoplasia is sometimes diagnosed after an acute PE. The identification of a group of patients with elevated probability of having an unknown neoplastic condition underlying PE was never performed. We aimed to determine predictors of occult neoplasia in patients hospitalized with acute PE.

Methods

We retrospectively analysed a cohort of patients hospital admitted with acute PE between 2006 and 2013. Patients were excluded if they had <18 years, when venous embolism was of veins other than the pulmonary veins, when the embolism was considered chronic and if there was no image confirmation of acute PE. Patients' demographic data, acute PE characteristics and laboratory data were abstracted from the records. Patients were grouped according to the concomitant diagnosis of a neoplastic condition: patients with known concomitant neoplasia, patients in which a neoplastic condition was diagnosed during acute PE admission or in the following 2 years and patients with no known neoplasia during all the patients follow-up. Predictors of concomitant neoplasia were determined using a logistic regression analysis. Multivariate models were built.

Results

We studied 562 patients admitted with acute PE. Median age was 72 years and 219 (39.0%) were men. In almost 40% patients the PE was of central arteries and in over 60% presented with bilateral PE. PE was considered idiopathic in 47.7%. Median dimmers level was 7.98 (3.30-14.99) ng/mL. In 126 (22.4%) patients there was a known active neoplasia and in 47 (8.4%) a neoplastic condition was diagnosed after the diagnosis of acute PE. Three-hundred and eighty nine patients remained neoplasia-free during the 2 years follow-up. Elevated D-dimers were independently associated with known concomitant neoplasia and were the only independent predictor of posterior neoplastic condition: per each 5ng/mL increase in D-dimmers the OR of uncovering a yet unknown neoplasia was 1.09 (95% CI: 1.01-1.17); for patients with D-dimers >15.0 the OR was 2.01 (1.05-4.18).

Conclusion

Elevated level of D-dimers in patients with acute PE are independently associated with concomitant neoplasia whether known or yet to uncover. Patients with D-dimmers >15 have a 2 fold higher risk of being diagnosed with a neoplastic condition in the upcoming 2 years. The value of D-dimers may help clinicians identify a group of patients with higher risk of concomitant neoplasia.

#838 - Case Report

WHEN METASTATIC HEPATOCELLULAR CARCINOMA MEETS VIRUS C AND CRYOGLOBULINEMIA

Carlos Rodrigues, Andreína Vasconcelos, Leonor Naia, Margarida Eulálio, João Fonseca
CHBV, Aveiro, Portugal

Introduction

Hepatocellular carcinoma (HCC) develops in approximately 1-4% of hepatitis C virus (HCV)-infected patients, compromising their therapeutic options and affecting their prognosis. Although modern therapeutics allow HCV eradication in almost all cases, ethical concerns regarding eligibility for treatment in HCC patients emerge, mostly because of their shortened median life expectancy. Cryoglobulinemia is a manifestation of HCV infection, present in 5% of the infected. Being an autoimmune manifestation, its treatment in oncologic patients is difficult, as its cornerstone involves immune suppression.

Case description

A 79-year-old male was admitted in the emergency room (ER) with complaints of severe asthenia, anorexia and dyspnea, increased circumferential volume of the abdomen and exuberant edema of the inferior limbs, all progressing over the past three weeks. He had history of metastatic HCC (Child-Pugh A; MELD 10; PS 0) under palliative treatment with Sorafenib with documented tumor shrinkage, and of non-treated HCV infection. Following admission, the patient developed a nephrotic syndrome with fever and palpable purpura on the inferior limbs, whose biopsy was inconclusive for vasculitis, but type II cryoglobulins were detected in serum. Subsequent renal biopsy depicted membranoproliferative glomerulonephritis mediated by immune-complexes, compatible with cryoglobulinemic vasculitis, and prompt the multidisciplinary team to direct the patient for a high dose short-term steroid treatment. There was a progressive clinical improvement, with normalization of renal function. Unfortunately, he died 2 weeks later of a healthcare-associated pneumonia.

Discussion

This case illustrates the importance of extensive investigation to reach a proper diagnosis of cryoglobulinemia vasculitis. The absence of specific guidelines, and the inaccessibility of

most centres to the new high priced HCV treatments result in asymmetries in clinical practice and consequently in treatment outcomes. This patient was undertaking palliative chemotherapy for his HCC with good response, and the unexpected development of vasculitis in the context of his HCV infection urged a decision on whether to approach viral infection or simply control the immune process. Teams' decision acknowledged current expertise in the field; however only the accumulated clinical experience of the coming years will bring the knowledge to homogenize clinical approach for these patients and potentially solve this ethical concern.

#840 - Case Report

LOCALIZED HODGKIN'S LYMPHOMA PRESENTING AS A STERNAL MASS

Bruno Cabreiro, Ana Ponciano, Cláudia Diogo, Tiago Pais, Catarina Faria, Joana Leite, José Leite, Célio Fernandes

Department of Internal Medicine, Centro Hospitalar de Leiria, Leiria, Portugal

Introduction

Sternal tumour lesions are rare. They present either with gradual formation of a palpable mass overlying the sternum or localized pain, or both. Metastatic lesions are the most prevalent. However less prevalent causes include inflammatory processes, primary malignant tumours or even benign lesions. Sternum is a rare site of Hodgkin's lymphoma (HL) and is usually misdiagnosed.

Case description

We present the case of a 32-year-old otherwise healthy male that presented unspecific chest pain lasting for 1 year in the xiphoid appendix. Several tests were performed at general practice that were unremarkable and the patient was diagnosed with anxiety and started mirtazapine. However, there was no improvement and in the last 6 months he noticed swelling over the anterior chest wall that worsened with physical activity and fatigue. He denied weight loss and fever, but noticed night sweats. Clinical examination was unremarkable except for his chest revealing a midline swelling of approximately 6x5cm in size originating from sternal manubrium. On palpation, swelling was fixed, firm and non-tender with smooth margins with slight overlying erythema. Chest echography reported a soft tissue mass with 6x5 cm. Blood tests just revealed elevated sedimentation rate 44 mm. Chest computed tomography showed an anterior mediastinal soft tissue mass (76x46 mm) with bone invasion and lytic manubrium which was confirmed by magnetic resonance. There was no lymphadenopathy described. Mass biopsy was performed and confirmed the diagnosis of HL.

Discussion

HL is typically a systemic disease with involvement of multiple lymph nodes, usually painless and with cervical location. Extranodal presentation is unusual and seldomly encountered in clinical practice. Spleen, liver, lungs, skin and genitourinary tract

are the most frequently reported extranodal presentations. Bone involvement is usually associated with advanced disease. Isolated sternal involvement in HL is extremely rare and usually involves males in their third decade.

#844 - Case Report

DYSPNOEA OF RESPIRATORY ORIGIN: THE IMPORTANCE OF DRUGS

Irene García Fernández-Bravo, Lucía Ordieres Ortega, Sergio De Santos Belinchón, María Jesús Granda Martin
Hospital Gregorio Marañón, Madrid, Spain

Introduction

Programmed death-ligand 1 (PD-1) is an Immune checkpoint inhibitor (ICI) of active T lymphocytes that regulates apoptosis inhibiting their response by negative feedback. Nivolumab is an antibody against PD-1 that enhances inactive T-cells against neoplasms as non-small cell carcinoma, melanoma, Hodgkin lymphoma and urothelial cancer. The appropriate length and possible side effects of this treatment are unknown. Immune reactions have been described, such as secondary pneumonitis 3 months after the beginning of the treatment.

Case description

A 79-year-old man with a diagnosis of stage IV lung epidermoid carcinoma since 2015, currently in complete remission. He received several cycles of chemotherapy with Cisplatin, Vincristine, Carboplatin, Aprepitant and finally three cycles of Nivolumab, commencing eight months before present hospital admission.

There is a previous hospital admission due to pneumonia in the left upper lobe without microbiological affiliation that improved after antibiotherapy and corticosteroids.

He arrived to the emergency room with a chief complaint of 2-day fever and slowly progressive mild dyspnea. Physical examination was normal except for crackles in the right upper lobe. Blood tests showed Leukocytes 12.40 10E3/μL, fibrinogen 815 mg/dL, C-reactive protein 215 mg/L, procalcitonin 0.3 μg/L and creatinine 1.83 mg/dL. A chest radiography showed infiltration in the right upper lobe, and he was admitted with diagnosis of right bronchopneumonia under empirical treatment with meropenem, which he completed for a week.

He presented a torpid evolution during admission despite adding voriconazol. A complete microbiological study was negative, including a polymerase chain reaction for *Aspergillus* and *Mycobacterium tuberculosis* on bronchoalveolar lavage. A thoracic computerized tomography showed a superior right alveolar opacity with distortion of the bronchial tree of inflammatory character. The autoimmunity panel was negative.

The final diagnosis was cryptogenic pneumonitis, probably secondary to prolonged treatment with nivolumab. Dyspnoea was resolved one month after introduction of corticosteroids.

Discussion

The adverse immune effects related to Nivolumab, such as cryptogenic pneumonitis, are associated with an increased mortality. More studies are needed to better understand its underlying mechanism. Corticosteroid therapy is the most common treatment, with a subsequently increased risk of opportunistic infections, in addition to a risk of tumor relapse.

#856 - Case Report

A RARE CUTANEOUS NEOPLASM - CASE REPORT

João Correia, Miguel Costa, Melanie Barata, Elena Suarez, Vítor Paixão Dias

Centro Hospitalar de Vila Nova de Gaia/Espinho, EPE, Vila Nova De Gaia, Portugal

Introduction

Cutaneous Merkel cell carcinoma (MCC) is a rare and aggressive neuroendocrine tumor of the skin, that mostly affects older people, predominantly males. It is more common in light and sun-damaged skin and has a propensity for local recurrence and regional lymph node metastases.

Case description

An 84-year old woman with previous diagnosis of hypertension and senile dementia was sent to the emergency department due to worsened right leg pain and bilateral asymmetric leg edema (more pronounced on the right side) since the previous month.

On physical examination (PE), multiple hard and smooth erythematous nodules with a maximum diameter of 10 cm were observed, with a purulent drainage on the right leg.

Laboratory studies revealed a normocytic normochromic anemia, elevated CRP and acute kidney injury. An abdominal ultrasound was performed, showing left hydronephrosis without an identifiable cause. This was confirmed on abdominal Computed Tomography (CT), which also showed bilateral lymphadenopathies in retroperitoneal, inguinal and iliac locations.

She was admitted to the internal medicine ward for 11 days to complete intravenous antibiotic therapy, wound care, improve renal function and undergo further studies of the imagiological findings. A biopsy of the cutaneous nodules was performed, which pointed towards a diagnosis of Merkel cell carcinoma. Due to the patient's advanced age and high degree of dependence, no further invasive diagnostic or treatment procedures were made. The patient was discharged to her nursing home with wound care treatment, analgesic therapy and palliative care.

Discussion

The authors present this case as a reminder that MCC should be considered as a differential diagnosis when encountering a rapidly growing lesion on sun-exposed sites.

Due to the aspecific clinical features of MCC, this cancer is often confused with other skin neoplasms. As such, pathological

examination is critical to reaching a correct diagnosis, and a biopsy of the lesion was performed, indicating a diagnosis of MCC.

Although most patients diagnosed with MCC present with skin-limited disease, lymphadenopathies were found on the abdominal CT performed, probably indicating disease progression.

The rare incidence of MCC justifies reporting this case and emphasizes the importance of a multidisciplinary approach in the diagnosis and treatment of these patients.

#873 - Case Report

GASTRIC CANCER INITIALLY PRESENTING AS PARAPARESIS OF THE LOWER LIMBS

Daniela Antunes, João Cardoso, Carla Pinto, Carla Melo, Augusto Duarte

Centro Hospitalar Médio Ave, Famalicão, Portugal

Introduction

Gastric cancer frequently spreads to the regional lymph nodes, liver and lungs following surgery or late in the clinical course. Bone metastasis is usually recognized as parallel disease recurrence following surgery or progression during follow-up, and occurs in the late stage of the disease. Initial (or simultaneous) presentation of bone metastasis, particularly in asymptomatic gastric cancer, is extremely rare.

Case description

The authors present a case of a 65-year-old woman presents to the emergency department with a five-month history of muscular weakness and reduced sensitivity in lower limbs and constipation. The past medical history revealed papillary thyroid carcinoma about 35 years ago.

On physical examination, there was a decrease in muscular strength, grade 2 in the left lower limb and grade 3 in the left upper limb, level of sensitivity in D3, aquiline and patellar reflex abolished and Babinski sign bilaterally.

Laboratory findings indicated normochromic normocytic anemia with hemoglobin 11.5 g/dL, thrombocytosis of 459,000/uL, leukocytosis 11,810/uL with neutrophilia (91.8%) and hypersegmented neutrophils, elevated C reactive protein (7.32 mg/dL), ionogram and renal function were normal.

This patient was submitted to urgent radiotherapy with slight improvement of the deficits.

She performed magnetic resonance imaging of the neural axis, that showed a infiltrative lesion centered on the body of D3, with an exuberant associated soft tissue component, infiltrating the vertebral body, destroying the posterior wall, expanding the posterior pedicle and arch to the left, the anterior aspect of the canal, deforming the medulla laterally and mainly to the left, still infiltration of the posterior superior slope of the body of D4 and posterior inferior of D2 a massive retroperitoneal conglomerates of lymph nodes.

Histopathological examination showed adenocarcinoma metastasis. A gastrointestinal endoscopic examination was

performed, and a proliferative mass was found in the antrum. Multiple biopsies were taken, and the histopathological results were tubular (intestinal) adenocarcinoma.

Discussion

In summary, the present case indicates that gastric cancer exhibits a variety of clinical features with regard to bone metastasis, particularly in the initial clinical presentation of the disease. In addition, the case indicated the importance of the detection of potential gastric cancer in patients with an initial presentation of bone metastasis.

#874 - Abstract

WEIGHT VARIABILITY IN A COLOMBIAN BREAST CANCER RETROSPECTIVE COHORT

Jonnathan Rueda Lara¹, Daniela Reyes Cadena¹, Guillermo Andrés Herrera Rueda^{2,1}, Nathalia Andrea Martínez Moreno¹, Carlos Enrique Alvarado De La Hoz¹, Andrés Julián Amaya Marshall¹, Jesús Solier Insuasty Enríquez^{1,3}

¹ Universidad Industrial de Santander, Bucaramanga, Colombia

² Internal Medicine Department, Universidad Industrial de Santander, Bucaramanga, Colombia

³ Insuasty Oncología e Investigaciones S.A.S, Bucaramanga, Colombia

Background

Breast cancer is the most frequent and prevalent malignant tumor in Colombian women, it represents worldwide 16% of female cancer, besides that, body weight changes such as obesity have become a public health issue that have been related to the appearance and evolution of breast neoplasms. The objective of this study is to describe the variability of weight in women with breast cancer undergoing treatment and establish its relationship with the recurrence of the disease in the 48 months after treatment.

Methods

Descriptive retrospective cohort study with non-probabilistic convenience sampling of women with stage IIIB breast cancer with positive progesterone and estrogen receptors, negative Her-2/neu, treated with surgery, chemotherapy, radiotherapy and hormone therapy in two reference oncology centers in northeastern Colombia during 2005 to 2015. Central tendency, univariate, bivariate analysis and comparison of proportions with Chi-square was performed ($p < 0.05$).

Results

1660 clinical records were reviewed, of which 74 patients met the inclusion criteria. At the start of the follow-up, 52 years was the mean age, and the average weight and BMI was 67kg and 26.9, respectively; stands that no woman presented low weight, in fact, 68% of them were overweight. Moreover, no woman was classified as underweight at the end of the follow-up despite the treatment, actually increasing the number of patients in the

overweight group ($p < 0.05$). A possible relationship between the occurrence of metastasis and the weight variability subgroup was identified. The analyzes are expected to be completed by the end of the spring of 2019.

Conclusion

The intermediate analysis shows a trend of weight gain of this population and its possible relationship with the appearance of metastasis at the end of the observation. This is the first type of study that analyzes the variability of weight in women with breast cancer in Colombia, it is expected to serve as a platform for future scientific studies in this area.

#875 - Case Report

SPLENOMEGALY - ABOUT A CLINICAL CASE

Daniela Antunes, Maria Vilela, Ana Lima Silva, Carla Pinto, Augusto Duarte

Centro Hospitalar Médio Ave, Famalicão, Portugal

Introduction

Diffuse large B cell lymphoma (DLBCL) is the most common subtype of non-Hodgkin lymphoma in all countries and all age groups. DLBCL accounting 25% of all non-Hodgkin's lymphomas (NHL). DLBCL is commonly diagnosed in the sixth decade of life, with the majority of patients being diagnosed at an advanced stage of the disease.

Case description

The authors present the case of a 78-year-old man with a history of dyslipidemia and prostate adenocarcinoma treated in 2016 with radiotherapy. He presented to the Emergency Department (ED) with acute pain in the left hypochondrium with 3 weeks of evolution, intensity 9/10 on the international pain scale, without irradiation, associated with nausea, vomiting, asthenia, evening-fever and night sweats.

Physical examination showed fever (38.5°C), palpable spleen mass 12 cm below the left rib cage and bilateral gynecomastia. Laboratory findings normochromic normocytic anemia with Hemoglobin 10.1g/dL, leukocytes 6070/uL, thrombocytopenia of 107,000/uL, confirmed on peripheral blood smear, hypersegmented neutrophils, erythrocyte sedimentation rate 57 mm. He presented vitamin B12 (288 pg/mL), folic acid (9.70 ng/mL), ferritin 675 µg/L, iron 10 µg/L, vitamin D-25-hydroxy 6.0 ng/mL, albumin 2.5 g/dL, lactic dehydrogenase 293 IU/L, total proteins 5.2 g/L, elevated C reactive protein 24.48 mg dL. Serologies for human immunodeficiency virus, hepatitis B, hepatitis C and Epstein Barr, Leishmania and Leptospira were negative, with uroculture and amicrobial blood cultures.

A thoracic-pelvic-abdominal computed tomography revealed a splenomegaly with a 9 cm solid lesion and heterogenic mass, suspected of neoplastic lesion and conglomerate lymph nodes in the celiac region, inter-aorto-cava, left lateral aortic location and next to the splenic hilum, forming a 6 cm agglomerate.

Histopathological anatomy of celiac lymph nodes revealed diffuse large B-cell lymphoma with activated B cell phenotype. The patient was discussed with Clinical Hematology.

Discussion

This case is relevant for the unusual presentation of DLBCL, which arises with spleen mass. Approximately 40% of DLBCL originates from extra-nodal sites.

In cases of spleen mass, DLBCL should be considered in the differential diagnosis.

The purpose of this paper is to report a rare occurrence of DLBCL and to demonstrate the importance of making this diagnosis early. DLBCL is fatal if left untreated, but with timely and appropriate treatment, approximately two-thirds of all patients can be cured.

#878 - Case Report

WALDENSTRÖM'S MACROGLOBULINEMIA AND MALT LYMPHOMA: A RARE RELATIONSHIP

Francisco Pombo, Hugo Pinheiro, Marina Mendes, Pedro Lopes, Ana Andresa, Teresa Mendes
Centro Hospitalar do Tâmega e Sousa, Penafiel, Portugal

Introduction

Waldenström's macroglobulinemia has a rare but known relation with MALT lymphoma. In this case we report one patient who had a synchronous diagnosis in the context of bilateral parotiditis.

Case description

We report a case of a 70-year old patient, without relevant past medical history, presenting to the emergency department with painful bilateral parotid swelling and submandibular adenopathies noticed the week before. She also reported asthenia, anorexia, weight loss (9 kg in the last three months) and marked symptoms of xerostomia and xeroftalmia. The complete blood count revealed pancytopenia with normal peripheral blood smear. A parotid ultrasound showed accentuated dimensional prominence of the parotid glands revealing a regular contour and diffusely heterogeneous ecostructure. The workup included a broad laboratory assessment, revealing the presence of monoclonal IgM protein and free lambda light chains, as well as high beta-2 microglobulin (9.20 mg/L). Thoraco-abdominopelvic CT scan showed supra and infra-diaphragmatic adenopathies and splenomegaly. Then we performed a parotid gland biopsy which revealed the presence of small lymphocytes and lymphoepithelial lesions with morphological and immunohistochemical aspects compatible with extranodal marginal zone B cell lymphoma (MALT lymphoma). Bone marrow biopsy showed hypercellular marrow with a B-cell lymphoid neoplasm involvement (32%), suggestive of lymphoplasmocytic lymphoma.

Even though there was an initial suspicion of concurrent Sjögren's syndrome, immunological analysis and minor salivary gland biopsy were both negative, excluding this diagnosis. Sarcoidosis

and chronic infections, such as tuberculosis, HIV, EBV, CMV, adenovirus, HCV and the mumps virus were excluded as well. Treatment with rituximab was initiated with great clinical improvement.

Discussion

Non Hodgkin lymphomas correspond to 25% of all head and neck cancers, with parotid involvement in MALT lymphoma being a rare but typical occurrence in females. It is commonly associated with chronic infections and Sjögren's syndrome, which were not confirmed in this case. There is a known connection between MALT and lymphoplasmocytic lymphoma, even though the mechanisms for this are not yet clear. Both share similar immunohistochemical patterns. The possibility of tumor differentiation from its localized form towards the systemic one has been hypothesized.

#884 - Case Report

CANCER, A HYPERCOAGULABLE STATE - A CASE REPORT

José Teixeira Francisco, Vanessa Pires

Centro Hospitalar de Trás-os-Montes e Alto Douro - Hospital de S. Pedro, Vila Real, Portugal

Introduction

Cancer has been recognized as a "hypercoagulable state". Besides de cancer itself, the occurrence of thromboembolic events in a cancer patient is one of the most common reasons of death.

Case description

We present a case of a 77-year-old woman with a medical history of hypertension, diabetes and dyslipidemia that came to our emergency department with dorsal pain, anorexia and asthenia with a three-week evolution. Physical examination just revealed a mild hepatomegaly. After a first battery of exams that showed only elevated d-dimers, a computed tomography (CT) scan was performed. It demonstrated bilateral pulmonary embolism and a several nodular lesions in both lungs and liver, suggestive of metastatic disease. Given this, the patient was hospitalized and anticoagulation with low molecular weight heparin at therapeutic doses was initiated. After further imagiological exams, upper gastrointestinal endoscopy, colonoscopy, bone scan and a liver biopsy of one of the nodular lesions, we diagnosed a cholangiocarcinoma in an advanced stage with lung, liver and bone metastasis. While hospitalized, and despite the anticoagulation, the patient suffered two ischemic strokes with only 9 days apart, in different cerebral artery territories which led to extended cerebral damage. After this, her neurological condition progressively got worse. Regardless all the efforts, the patient end up dying by the day 30.

Discussion

The prognosis of a cholangiocarcinoma in an advanced stage is very poor but it can be even worse with thromboembolic events

associated, affecting our treatment strategies. That's what happened with our patient who died after recurrent cancer related stroke. The purpose of this case report is to remind us that these diseases and its complications could happen fast and dramatically and leave us without any options, except giving our patients a comfortable ending.

#887 - Abstract

A TWO YEAR RETROSPECTIVE STUDY OF BONE MARROW EXAMINATION IN A STATE GENERAL HOSPITAL

Bogdan Kachan¹, Soraia Proença Silva², Joana Carvalho³, Óscar Matos¹, Ricardo Rodrigues², Rosa Silva³

¹ ULSCB / EPE, Castelo Branco, Portugal

² Amato Lusitano Hospital, Castelo Branco, Portugal

³ Department of Internal Medicine, Castelo Branco, Portugal

Background

Bone marrow examination (BME) is an essential investigation for the diagnosis and management of many disorders of the peripheral blood (PB) and bone marrow (BM). The aspirate and trephine biopsy (TB) specimens are complementary and when both are obtained, they provide a comprehensive evaluation of the BM. The final interpretation requires the integration of PB, BM aspirate and TB findings, together with the results of supplementary tests, such as immunophenotyping (IPT) or cytogenetic analysis by fluorescence in situ hybridization (FISH). The indications for BME have widened to include many conditions in haematology, internal medicine (IM), and oncology.

Methods

Retrospective study of 213 patients who underwent to BM aspiration from 2017 to 2018. They were analyzed with regard to age, gender, requesting department, clinical indication, sample characteristics, the final result of myelogram and IPT of BM.

Results

The patients median age was $66 \pm 14,1$ years old and 51% were male. The majority of samples (96.7%) were obtained by sternal puncture. In only 7 patients (3.3%) it was necessary to perform a TB of the posterior iliac crest. It was an inpatient procedure in 30% of patients and an outpatient procedure in 70% of patients. From all techniques 81% were executed by IM doctors. The most frequent clinical indications were: cytopenias (36%), unexplained anaemia (17%), suspected multiple myeloma (MM) (13%) and cytos (12%). It is important to refer that only 47% of the samples were representative of BM. The most prevalent myelogram results were myelodysplastic syndromes (SMD) (16%), anaemia (13%) with prevalence of iron deficiency and leukaemias (10%). From IPT of the representative samples of BM, 56% of those revealed a normal result and 44 % were diagnosed with reactive hematopoiesis (17%), SMD (11%), lymphomas (8%), chronic leukemias (8%), acute leukemias (4%) and MM (6.6%). Regarding

non-representative BM specimens (mainly due to hemodilution), the most frequent pathologies were SMD and chronic B-cell lymphocytic leukemia. From all data analyzed 8% were done by FISH technique.

Conclusion

The authors report that is crucial to perform a BME only when there is strong indication for it and it must be well performed, in a accordance with Guidelines of International Council for Standardization in Hematology. It is also important to mention that IPT of BM contributed to diagnosis accuracy and increment, specifically in regards to lymphopoiesis.

#894 - Case Report

VICISSITUDES OF IMMUNOSUPPRESSIVE THERAPY

Vera Seara, Susana Marques De Sousa, Marta Rafael Marques, Sónia Da Costa Fernandes, Cristina Marques, Teresa Pinto CHPVVC, Vila Do Conde, Portugal

Introduction

Adalimumab is a monoclonal, anti-TNF alpha antibody used in the treatment of rheumatoid arthritis.

Case description

The authors report the case of a 70-year-old patient with seropositive rheumatoid arthritis, diagnosed 14 years ago and treated with adalimumab for 13 years. After a routine chest x-ray, a medium volume pleural effusion was identified and adalimumab was suspended. There was also evidence of a large abdominal mass in the left hypochondrium with hard-elastic consistency and painful to palpation.

She was admitted to the hospital with dyspnea and generalised abdominal pain. A CT scan was performed, which showed a bilateral pleural effusion, with metastatic implants and a large mass in the left kidney (14x11cm) with splenic and diaphragmatic invasion.

Diagnostic thoracentesis revealed the pleural fluid had characteristics of exudate, with an anatomopathological examination showing the presence of undifferentiated malignant neoplasia.

With a probable diagnosis of renal carcinoma with T4N1M1 staging, she was referenced for evaluation and orientation in oncology clinic.

The patient evolved quickly and unfavorably. Before a renal biopsy, that would allow the definitive diagnosis, could be performed, the patient general state deteriorated and resulted in her death.

Discussion

The use of biological drugs has allowed a great advancements in the treatment of several diseases, however these are not exempt from side effects. The consequent immunosuppression can potentiate the appearance of several neoplasias.

The most likely diagnosis of undifferentiated renal carcinoma is a high-grade, aggressive neoplasm with a poor prognosis. The report of renal neoplasms associated with the use of biological agents, namely adalimumab, is rare.

#896 - Case Report

OVERCOMING THE LABEL OF TERMINAL DISEASE: TWO CASES OF ACUTE CHOLECYSTITIS

Yolanda De Sá Pereira, Jorge Silva Ferreira, Bernardo Maria, Joao Coutinho, Luis Costa, Maria Joao Gomes

Centro Hospitalar Universitário Lisboa Norte, Lisbon, Portugal

Introduction

Acute cholecystitis is a rare but well-recognized complication of targeted molecular chemotherapy. However, in the patient with metastatic cancer, under antialgic therapy, the usual clinical manifestations of cholecystitis may be mitigated. Here we present two clinical cases of patients with advanced stage cancer under targeted therapy, whose diagnosis of cholecystitis was delayed by 48 hours. Both patients underwent surgery, with a 12-month survival rate in one case and over 21 months in the second.

Case description

Case 1

61 year old, female, diagnosed with clear cell adenocarcinoma of the kidney with bone and lung metastasis, medicated with sunitinib. The patient presented with diffuse abdominal pain and was admitted to the medical ward for palliative comfort measures. At clinical examination she had a fever, hypotension and pain at decompression in the right hypochondrium. Laboratory findings showed no leukocytosis, but marked elevation of C-reactive protein (36.2mg/dL) and elevation of cholestasis parameters. Ultrasonography and abdominal CT scans later revealed lithiatic cholecystitis complicated with abscess of the gallbladder wall. As the expected prognosis of survival was over 12 months, she underwent cholecystectomy, and was discharged. She passed away twelve months later.

Case 2

71 year old, male, diagnosed with a neuroendocrine tumor of the pancreas, with liver metastasis, under antineoplastic therapy with lutetium. He presented with abdominal pain and an abdominal ultrasound showed a thin-walled gallbladder with multiple gallstones, suggesting pain of oncological origin. Laboratory findings showed leukocytosis and neutrophilia, C-reactive protein of 33.3 mg/dL, acute renal injury and elevation of cholestasis parameters. 48 hours later with installation of shock and anuria, a new ultrasound showed perforation of the gallbladder, with signs of associated peritonitis. He underwent cholecystectomy and today is still active in public life.

Discussion

Certain types of molecular therapy such as sunitinib, due to

its biliary excretion, increase the incidence of hepatic-biliary disease and may lead to acute cholecystitis. When this occurs in patients with advanced neoplastic disease, it may have atypical clinical manifestations, leading to a delay in diagnosis. Surgical intervention should be considered, as shown by the clinical cases exposed, in patients with an estimated survival of more than 12 months, overcoming the prejudice associated with the oncological condition.

#933 - Medical Image

THE BLAME IS ON THE LUNG

Daniela Neto, Salomé Marques, Gabriela Pereira, Cristina Silva, Helena Sarmiento, Jorge Cotter

Hospital Senhora da Oliveira, Guimarães, Portugal

Clinical summary

A 61-year-old male presented to the Emergency Department because of nausea and vomiting with several weeks of evolution, with no other symptoms. He underwent abdominal computed tomography where were documented three large hypodense focal liver lesions, retroperitoneal adenopathies and a hypodense lesion in the right adrenal gland suggesting an evolutionary lesion. Subsequently, a biopsy of one of the liver lesions was performed and revealed that this lesions were metastasis of small cell lung carcinoma.

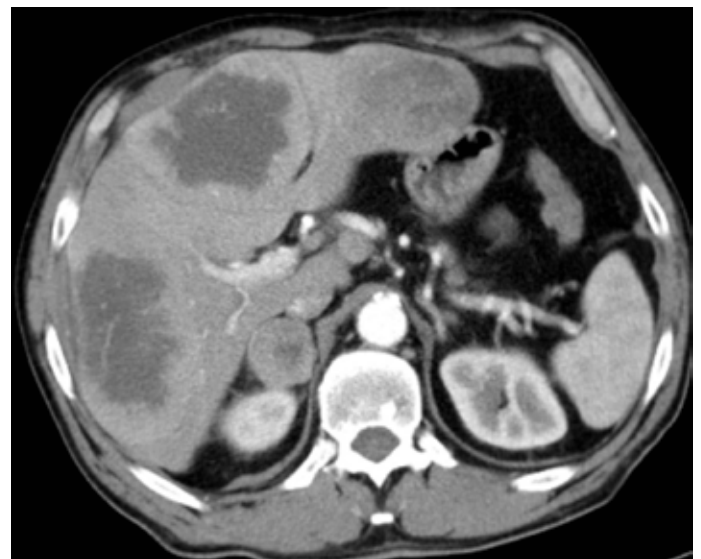

Figure #933. Axial cut on Abdominal CT showing the metastatic lesions.

#935 - Abstract

CANCER DIAGNOSIS IN AN INTERNAL MEDICINE WARD – A CASE SERIES

Lucy Alves, Júlio Teixeira, Pedro Martins Dos Santos, Sérgio Gonçalves, António Veiga E Moura

Centro Hospitalar Universitário do Algarve, Faro, Portugal

Background

As seen throughout Europe, there has been an increase in the incidence of cancer in Portugal which causes a major healthcare, social and economic impact. This increase is due to many factors such as an increase in life expectancy and behavioural risk factors (smoking, physical inactivity, obesity, excessive alcohol intake). Cancer is nowadays the 2nd cause of death in Portugal and it is expected it will become one of the leading causes of hospitalization in the future.

Methods

Retrospective analysis of the patients hospitalized in an Internal Medicine ward from January-December 2018, that were diagnosed with any type of solid or hematologic cancer. Analysis of the cause of hospitalization, time between admission and diagnosis, destiny and mortality after diagnosis.

Results

Of all the patients hospitalized in the internal medicine ward, 69 were diagnosed with cancer. The mean age of the patients was 70.3 years (minimum 23, maximum 102) and the majority were men (n=43). The main cause of admission was investigation of constitutional symptoms (weakness, anorexia and involuntary weight loss) in 53.6%, followed by neurologic symptoms (20.3%), pulmonary embolism (5.7%) and infection (5.7%). At the time of diagnosis 49.2% of the patients did not present metastasis, notwithstanding, in the group of patients that had metastasis 14.5% presented multiple areas of metastization. About 30.4% were hematologic and 69.5% were solid tumour cancers, of which 22.9% were carcinomas of unknown primary site. The mean time between admission and diagnosis was 23.2 days. Once diagnosed, the mean time until the first evaluation by an oncology related specialty (Medical Oncology, Haematology, Pneumology, Urology or Palliative Care) was 11.5 days. After diagnosis 20.2% of patients were referred to Medical Oncology, 24.6% Haematology, 17.4% Palliative Care and the rest to specialties such as Pneumology and Urology. Of the total of patients selected, 30 patients died during the first trimester after diagnosis, 6 died in the subsequent months and 33 are still alive.

Conclusion

Internal Medicine plays a crucial role in the investigation and diagnosis of cancer and, therefore, should be alert when evaluating patients with cancer risk factors and suggestive symptoms. The articulation between the various specialties responsible for diagnosis and treatment, should be improved so that the diagnosis is made as soon as possible, enabling these patients to the best optimal care.

#990 - Case Report

CHRONIC PRURITUS AS THE INITIAL PRESENTATION OF MEDIASTINAL GREY ZONE LYMPHOMA

Ana Maria Gonçalves, Carlos Ramalheira, Sara Irina Almeida, Rita Dutschmann, João Machado

Hospital Professor Doutor Fernando Fonseca, Lisbon, Portugal

Introduction

Mediastinal grey zone lymphoma (MGZL) is a rare entity with intermediate features between classical Hodgkin lymphoma (cHL) and diffuse large B-cell lymphoma (DLBCL). Standard management guidelines for patients with MGZL are not yet available, primarily due to its recent identification, and challenges in diagnosis.

Case description

A 27-year-old woman with a history of generalized pruritus, for the past 3-years, presented in the emergency room with a mass in the right supraclavicular area. She also referred papulonodular lesions in the lower limbs for the past 6 months, and dry cough. There were no weight loss, fever or night sweats. She had severe pruritus, resistant to multiple treatment attempts. On physical examination she had a right supraclavicular mass, with 5x5cm, painless and with rubbery consistency. In the lower limbs were numerous erythematous papulonodular lesions. There were no significant alterations on blood tests, except a lactate dehydrogenase level of 282 U/L and alkaline phosphatase: 169 U/L. Chest radiography revealed a large anterior mediastinal mass. CT scan of the chest and abdomen confirmed a cluster of adenopathies in the anterior and upper mediastinum. Skin biopsy of the papulonodular lesions was compatible with prurigo nodularis, and excisional biopsy of the supraclavicular adenopathy matched with a Grey Zone Lymphoma, unclassifiable with intermediate features between classical Hodgkin lymphoma and diffuse large B-cell lymphoma. A PET scan confirmed the tumour location in the cervicomediastinal transition, right supraclavicular region and mediastinum, establishing the disease in stage IIA. The patient started treatment with R-CHOP with significant pruritus relief, and mass reduction.

Discussion

MGZL has few cases described in the literature, due to its new recognition and paucity clinical data. It's more frequent in males, in the third and fourth decades, with B symptoms and presents in early stages of the disease. Conversely, our case presented in a young woman, without any B symptoms and with long-term pruritus as a paraneoplastic sign. Chronic pruritus as well as prurigo nodularis, are well known paraneoplastic manifestations, often seen in HL patients, in this case, they were the first sign of an occult neoplasm. Chronic pruritus always should require a systematic diagnosis approach initially and throughout time, particularly in patients with severe and untreatable cases.

#1012 - Abstract

MULTIPLE MYELOMA: 4 YEAR REVIEW IN A INTERNAL MEDICINE WARD

Bruna Nascimento, Ana Garrido Gomes, Carolina Nunes Coelho, Marta Guisado Orantos, Iuliana Cusnir, Bruno David Freitas, Maryna Telychko, Stela Calugareanu, Diana Vital, Sandra António
Hospital de Santarém, Santarém, Portugal

Background

Multiple myeloma (MM) accounts for 1% of all cancers and 10% of all haematological malignancies. The median age at diagnosis is 72 years. Clinical presentation of the disease varies greatly. The signs and symptoms are nonspecific and may include bone pain, fractures, anaemia or renal insufficiency. Diagnosis is based on detection of the monoclonal component M by serum or urine protein electrophoresis and evaluation of bone marrow plasma cell infiltration. Median survival is approximately 5 to 7 years. Objectives: To characterize cases of newly-diagnosed MM during hospitalization in an Internal Medicine (IM) ward.

Methods

We considered all patients with in-hospital diagnosis of MM in a IM ward between January 2014 and July 2018. Through revision of clinical electronic data, we evaluated the following variables: age, sex, cause of admission to the hospital, diagnosis, type of myeloma, treatment and mortality.

Results

We obtained 13 cases with in-hospital diagnosis of MM. The median age of the patients in the study was 80.1 years. Seven patients were men (53.8%). Anaemia was the most common clinical finding, present in 53.8% of patients (n=7). Acute kidney injury was present in 46.2% (n=6). The M protein type was IgG in approximately 92.3% of patients (n=12), IgA in 7.7%. The light chain distribution was as follows: kappa light chain in 84.6%, lambda light chain in 15.4%. Prognosis was evaluated using the International Staging System (ISS). ISS Stage III was found in 84.6% of patients. Direct treatment of myeloma was performed in 12 patients, in majority of cases with bortezomib, cyclophosphamide and dexamethasone. The in-hospital mortality was 7.7%, with a global mortality to date of 46.2%.

Conclusion

In the studied population, the mean age was higher than expected (72 versus 80.1 years). Most of the patients were in a late stage of the disease, while literature indicates that only 10% of patients are ISS III at the time of diagnosis. Symptoms at presentation were nonspecific, so an elevated grade of suspicion is necessary for a precocious diagnosis. Knowing the population of an IM ward may lead to earlier diagnosis, and subsequently, better outcomes.

#1018 - Case Report

CHYLOTHORAX, A RARE ENTITY – CASE REPORT

Olinda Lima Miranda, Ana Lúcia Mendes Costa, Magda Costa, Filipe Gonçalves, Jorge Cotter
Hospital Senhora da Oliveira, Guimarães, Portugal

Introduction

Chylothorax is defined by lymph accumulation in the pleural space, caused by the passage of lymph from the thoracic duct into the pleural cavity. In the macroscopical examination the fluid has a milky appearance and analytically triglyceride (TG) levels are above 110 mg/dL. Chylothorax can be congenital, traumatic and non-traumatic. The non-traumatic causes include neoplastic and inflammatory diseases.

Case description

An 86-year-old woman, with personal background of hypertension, dyslipidemia and osteoarticular pathology, was admitted in our emergency department with two week symptoms of asthenia, nausea, abdominal distension and pain. She also reported dyspnea for moderate efforts that had started the week prior in her medical examination, pulmonary auscultation had a decreased vesicular murmur in the lower 1/3 of the right hemithorax and decreased transmission of vocal sounds. Abdomen was globose, tympanic at percussion, soft and depressible, with slight pain in the palpation of the hypogastric area and right iliac fossa, without palpable masses or signs of peritoneal irritation. Analytically no significant alterations were found. In the thoracoabdominopelvic CT, "right pleural effusion, moderate to large (...) and contralateral mediastinal deviation (...) Retroperitoneal infiltrative mass, hilar and infra-renal, and mesenteric, contiguously surrounding large retroperitoneal vessels, the pancreas, duodenum and bilateral hilar structures bilaterally, with 12.5 cm of axial axis (...) peritoneal effusion, of small to moderate volume". Thoracocentesis was performed, with aspiration of milky pleural fluid, with exudative characteristics, according to Light criteria, with a predominance of mononuclear cells (97%) and TG 1469 mg/dL. She was admitted to our inpatient unit. A biopsy of the left retroperitoneal lesion was performed, under CT control, with 3 fragments collected for anatomopathological study. The patient was discharged 2 days after this procedure and 5 days later the result was known - follicular non-hodgkin lymphoma - and the patient was referred to Hemato-oncology.

Discussion

If chylothorax is present in a patient without risk factors for a traumatic cause, a neoplastic cause must be suspected. Non-Hodgkin's lymphoma is one of the possible causes of chylothorax, due to the obstruction of the thoracic duct by hematogenous dissemination. The other neoplasms are less frequent.

#1068 - Abstract

**LYMPHOPROLIFERATIVE DISEASE
SYNCHRONOUS WITH A SOLID TUMOR –
CASE SERIES**

Catarina Fernandes, Filipa Moita, Maria Gomes Da Silva
Instituto Português de Oncologia de Lisboa Francisco Gentil, Lisboa,
Portugal

Background

Patients with a newly diagnosed neoplasm usually undergo extensive diagnostic/staging procedures, during which the investigation of atypical findings can lead to the diagnosis of a synchronous tumour.

Our aim was to define the incidence of synchronous non-hematological tumours (SNHT) in patients with newly diagnosed lymphoproliferative disorders (LPD) and to determine their impact in the outcome of these patients.

Methods

A retrospective analysis of 708 consecutive patients referred to our institution with a confirmed diagnosis of a LPD between 2017 and 2018 was conducted.

Within this cohort, patients with a concomitant diagnosis of a non-hematological malignancy within a two month interval were identified and selected for review.

Results

A total of 17 patients with SNHT were identified, giving an overall incidence of synchronous tumours of 2.4% (17/708).

Chronic lymphocytic leukemia was the most common lymphoproliferative disorder, usually diagnosed in the context of lymphocytosis detected during the initial staging of the non-hematological tumour.

Gastrointestinal cancer was the most common SNHT (29.4%), followed by lung cancer (23.5%), thyroid cancer (17.6%), skin and genitourinary cancer (both with an incidence of 11.8%) and oropharyngeal cancer (5.8%).

The median age of the patients with SNHT was 72 years old, in contrast with patients with isolated lymphoproliferative disease, who had a median age of 64 years old ($p = 0.0820$).

Only three patients required treatment for both malignancies – all the patients underwent surgical resection of the SNHT prior to the start of treatment for the LPD.

Two patients died (2/17; 11.8%), both due to progression of SNHT, 9 and 12 months after the initial diagnosis. In the subgroup of SLP patients without SNHT, the mortality rate was 6.5% (45/691).

Conclusion

Even though the incidence of synchronous tumours is low, given the implications that an early diagnosis of a secondary cancer can have regarding treatment decisions and overall prognosis, a low threshold for further investigations in case of discordant results during staging procedures is mandatory.

The management of synchronous tumours is challenging,

particularly when it involves to potentially curable diseases that require rapid initiation of treatment.

The higher age of patients with SNHT further adds to the challenges of treatment, given their higher incidence of comorbidities and reduced tolerance to more intensive strategies.

#1096 - Medical Image

PEPPER POT SKULL

Maria Del Carmen Hernandez Murciano, Elena Del Carmen Martinez Canovas, Ignacio iniesta-Pino Alcázar, Lia ferraro, Vicente David De La Rosa Valero, Ana Martin Cascon, Francisco Javier Hernandez Felices, Monica Martinez Martinez, Carlos Baguena Perez-Crespo, Gabriel Puche Palao
Reina Sofia General Hospital, Murcia, Spain

Clinical summary

This image shows well defined and small lithic multiple areas in the lateral radiograph skull, varying in shape and size, involving the skull vault and base. This image is classically called as “pepper pot skull”. These images associated to weight loss, anemia (Hb 5.1 g/dL), renal failure (Cr 2.72), hypercalcemia (Ca 22.1 mEq/L) and IgA kappa monoclonal peak allowed us to diagnose IgA multiple myeloma. Similar lytic lesions were found in other bones such as vertebrae, proximal humerus and femur or ribs, following the axial skeleton predilection of myeloma.

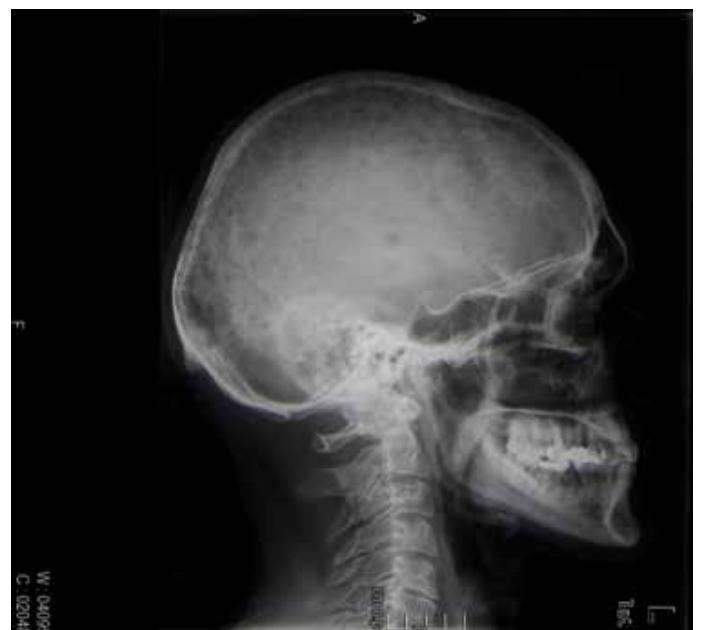

Figure #1096. Diffuse lytic lesions giving classical “pepper pot skull” appearance.

#1105 - Case Report

ASTHENIA IN A DISABLED PERSON, AN EXTREME PRESENTATION OF A COMMON DISEASE

Alexandra Esteves, Ana Catarina Carvoeiro, Joana Couto, Paula Felgueiras, Diana Guerra, Carmélia Rodrigues

Unidade Local de Saúde do Alto Minho, Viana Do Castelo, Portugal

Introduction

Asthenia is a common nonspecific complaint with a broad differential diagnosis, requires a systematic approach often demanding laboratory or imaging studies. People with disabilities face multiple barriers in accessing healthcare, usually related to situations of either poverty or social exclusion, which alone increase the likelihood of ill-health.

Case description

We present a 49-year-old blind and deaf woman with a congenital cognitive deficit. She had a history of heavy menstrual bleeding since puberty disregarded by her caregivers, without any kind of contact with a healthcare provider in the last decade. Progressive asthenia, anhedonia and anorexia were noted over several weeks, initially still able to perform most activities of daily living, later becoming bedbound. It was then when a primary care physician was first approached. Laboratory studies showed an extreme microcytic anaemia with a serum haemoglobin level (Hb) of 1.7g/dL. Patient was referred to the Emergency Department where she presented accompanied by her caregivers walking on her own and denying any symptoms. Physical examination was unremarkable, except for extreme pallor and mild tachypnoea. The initial Hb measurement was confirmed, blood smear revealed microcytic red blood cells and severe iron deficiency was recorded without any signs of associated haemolysis. Blood analysis of vitamin deficiencies, serum electrolytes, blood gas, lactate, cardiac enzymes, liver enzymes, renal function and an electrocardiogram were performed also showed no significant changes. A pelvic ultrasound revealed multiple uterine myomas. She received 5 units of red blood cells over a two-day period, started intravenous iron supplementation and was later admitted to the Gynaecology ward where she underwent a hysterectomy and bilateral oophorectomy. She was discharged on the 13th day of admission without any sequelae or postoperative complications, with a Hb of 11g/dL. Follow-up 3 months later showed no recurrence of anaemia.

Discussion

Anaemia is a common cause of morbidity and mortality globally, affecting up to 29% of non-pregnant women worldwide. Nevertheless, severe anaemia with Hb inferior to 2 g/dL is extremely rare in an outpatient setting and only few case reports have been described. This case illustrates the physiological adaptive mechanisms to chronic anaemia, only possible by an insidious installation and a blatant lack of access to healthcare.

#1106 - Case Report

BACK PAIN AND PARESTHESIAS UNRESPONSIVE TO TREATMENT, WHAT TO THINK?

Ana Oliveira, Inês Cunha, Filipa Santos, Diogo Costa, Sónia Chan, Álvaro Ferreira

Centro Hospitalar do Porto, Porto, Portugal

Introduction

Pain related with the musculoskeletal system affects 33% of the adult population and it is responsible for 29% of absenteeism in the workplace. The main sites of musculoskeletal pain are low back pain, neck pain and omalgia, and it can be related with bone, tendons or muscle disease, nerve compression or even be a referred pain.

Case description

A 52-year-old woman, with history of smoking and spontaneous pneumothorax, went to the emergency department four times in three months because of musculoskeletal pain non trauma related, always with a normal physical examination, being interpreted as musculotendinous pain.

She presented with back pain with irradiation to the left upper limb, which got worse over time, and became persistent and unresponsive to therapy (paracetamol, thiocolchicoside, ketoprofen, cyclobenzaprine, diclofenac, etoricoxib, pregabalin and tapentadol). It progressed with development of paresthesia and monoparesia of the left upper limb, associated with ptosis and myosis on the left eye. There were no other symptoms.

In the diagnostic approach, there wasn't alterations in the analytical study; in computed tomography it was identified a mediastinal mass of 13 cm of greater axis with aortic, subclavian, vertebral and left common carotid artery involvement; there were hilar and paratracheal adenopathies and also litic cervical (C6-C7) and dorsal (D1 to D2) lesions with pathological fractures in D1 and D2. It was performed a transcutaneous lung biopsy whose histological study revealed a pulmonary invasive adenocarcinoma with acinar pattern, positive for CK7. Tumor markers were positive for CEA 25ug/L and CA 72.4 ug/L.

During hospitalization, the patient was involved in a multidisciplinary approach (Internal Medicine, Palliative Care, Oncology, Orthopedics, Pneumology and Interventional Radiology), being discharged after 10 days of hospitalization with controlled pain, diagnosis of inductor adenocarcinoma and Pancoast Syndrome.

Currently, she is on chemotherapy with pembrolizumab, with palliative intent.

Discussion

Adenocarcinomas account for 40% of lung neoplasms and occur mostly in smokers. The most frequent clinical manifestation is cough and dyspnea and only 3% -5% of the cases are manifested as Pancoast syndrome. With this case, the authors intend to recall the importance of pain refractory to therapy and that 3% -5% of pulmonary adenocarcinomas manifest with referred pain and paresthesias.

#1124 - Case Report

INTRACARDIAC THROMBOSIS AS A RENAL TUMOR DEBUT

Mario Salcedo¹, Sergio Palacios-Fernandez², Paula Aledón¹, Esther García¹, Francisco Javier Salcedo Aguilar³

¹ Hospital Universitario y Politécnico La Fe, Valencia, Spain

² Hospital Clínico Universitario San Juan, San Juan De Alicante, Spain

³ Hospital San Pedro, Logroño, Spain

Introduction

An 85-year-old man with a history of controlled hypertension with triple therapy and prostate adenocarcinoma that received radio and hormonal therapy, free of disease for 8 years.

The patient was referred to the hospital due to renal failure of indeterminate duration and exertional dyspnoea with lower extremity edema of two weeks of evolution. Optimal water intake was assured and diuresis had not qualitative or quantitative alterations. No other symptomatology added, no recent modifications of the pharmacological therapy.

Case description

On physical examination, only bilateral tibiomaleolar edema with fovea (II/IV) was observed without other pathological findings.

In the complementary tests performed at admission, there were the next pathological findings: creatinine 3.1 mg/dl, potassium 6 mEq/l, proBNP 1063 pg/ml, and anodyne haemogram and haemostasis. The urine analysis showed proteinuria >500 mg/dl.

Transthoracic echocardiography and abdominal ultrasound were requested. The echocardiogram revealed a mass of intermediate ecorrefringence that penetrated from the inferior vena cava into the right atrium (size: 5x2cm), it could be a thrombus or a tumor mass. Therefore, an urgent thoracic-abdominal CT angiogram was requested that showed a right renal mass (5x5x6 cm) in the lower pole and hilar lymph nodes and a extensive tumoral thrombosis with a mixed component of the right renal veins, inferior vena cava and right atrium with almost total occupation of the light of them, secondary to right renal neoplasm (T3c N1 M0).

After a multidisciplinary approach (with cardiac surgery, urology and oncology), a palliative management was agreed with the patient because of his medical and sociofunctional baseline condition as well as the advanced stage of the oncological disease.

Discussion

Renal carcinoma is a pathology that can present a large amount of symptoms and signs, with an unpredictable clinical course. It hinders the diagnostic process in many cases. This means the diagnosis is reached when the tumor is already at an advanced stage.

The presented case is an atypical way of presentation: renal tumor with cardiac extension. In up to 10% of cases these tumors invade or compress the venous system, complicated with intraluminal thrombus; but less than 7% and 1% affect the inferior caval vein and cardiac cavities, respectively.

#1125 - Medical Image

MASSIVE THROMBOSIS SECONDARY TO RENAL TUMOR

Mario Salcedo¹, Sergio Palacios-Fernandez², Paula Aledón¹, Esther García¹, Francisco Javier Salcedo Aguilar³

¹ Hospital Universitario y Politécnico La Fe, Valencia, Spain

² Hospital Clínico Universitario San Juan, San Juan De Alicante, Spain

³ Hospital San Pedro, Logroño, Spain

Clinical summary

An 85-year-old man with hypertension was referred due to renal failure of indeterminate duration and exertional dyspnoea with lower extremity edema of two weeks of evolution.

A transthoracic echocardiography (Figure 1) revealed a mass of intermediate ecorrefringence that penetrated from the inferior vena cava into the right atrium (size: 5x2 cm). Therefore, an urgent thoracic-abdominal CT angiogram (Figure 2) showed a right renal mass (5x5x6 cm) in the lower pole with hilar lymph nodes and an extensive tumoral thrombosis of the right renal veins, inferior vena cava and right atrium with almost total occupation of the light of the referred vessels. The final diagnosis was renal neoplasm with an extensive tumoral thrombosis (T3c N1 M0).

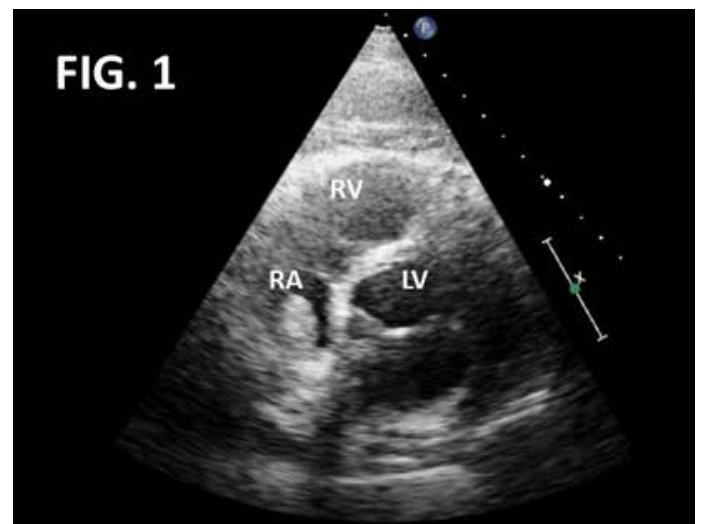


Figure #1125. FIG. 1: transthoracic echocardiography (apical view).

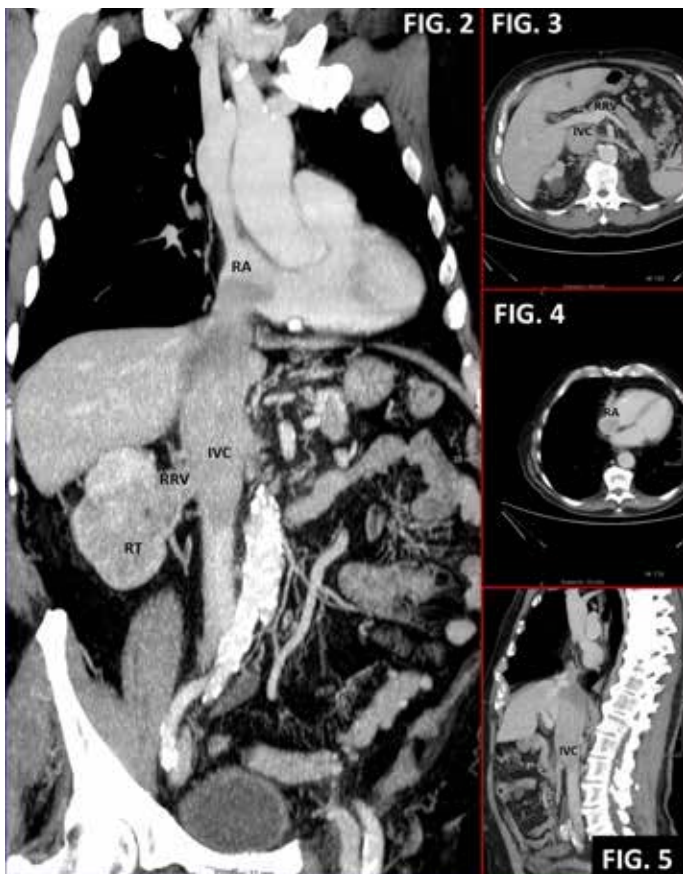


Figure #1125. FIG. 2,3,4 & 5: thoracic & abdominal CT angiogram
 RA: right atrial - RV: right ventricle - LV: left ventricle - RRV: right renal vein - IVC: inferior vena cava - RT: renal tumor.

#1130 - Case Report

WHAT IT SEEMS, IT IS NOT ALWAYS TRUE...

Salomé Marques, Daniela Neto, Magda Costa, Vítor Macedo Silva, Sofia Xavier, Clarisse Neves, Emília Lopes, Jorge Cotter
 Hospital Senhora da Oliveira, Guimarães, Portugal

Introduction

Testicular tumors are the solid neoplasms that most commonly affect individuals between the ages of 15 and 35, and the vast majority are germ cell tumors. They usually present as painless edema or nodule in one of the testicles and there may be painful complaints or sensation of weight located in the lower abdomen, perineal or scrotal region. However, the initial symptoms may correspond to the symptomatology associated with metastatic disease.

Case description

26-year-old male, smoker, with no relevant medical history and no usual medication. He was referred to the ER by his family doctor after performing an abdominal ultrasound (US) due to abdominal discomfort. The US showed an enlarged liver, discrete intrahepatic bile duct ectasia, biliary dilatation, and numerous pericellular, hepatic, periaortic, common iliac and mesenteric adenomegalies forming conglomerates in the lomboartiac region.

The hypothesis of lymphoproliferative process was suggested. As for signs and symptoms the patient reported a weight loss of 15.3% of the body surface and unusual periods of constipation of 1-3 days, but denied other complaints. At the ER there was an elevation in transaminases, physical examination revealed a palpable left supraclavicular adenomegaly, a thoraco-abdomino-pelvic CT confirmed the adenomegaly conglomerate.

During hospitalization, the patient developed jaundice, acholia and choloria, maintaining abdominal pain with dorsal decubitus worsening and increasing of transaminases, bilirubin, amylase and lipase serum levels. Abdominal CT showed hepatic and main bile ducts dilatation worsening due to compression and it was necessary to perform an endoscopic retrograde cholangiopancreatography. From the etiological study carried out: myelogram was normal; β -hCG and AFP were negative; scrotal US showed small testicles with innumerable microcalcifications and an exuberant translucent testicular microlithiasis. Excisional biopsy of the larger left supraclavicular adenomegaly revealed a malignant germ cells metastasis, namely embryonal carcinoma. The patient was transferred to the care of Oncology. He is now undergoing chemotherapy with BEP regimen with good response.

Discussion

This case has proven to be a diagnostic challenge given the distinct form of presentation. With this case we also intend to show the importance of maintaining a critical look at the diagnostic results that are being obtained, as well as to highlight the need for an open thinking methodology about the symptoms.

#1150 - Case Report

DIFFUSE LARGE B-CELL LYMPHOMA – CASE REPORT OF AN UNCOMMON PRESENTATION

Sara Magno, Rudi Fernandes, Raquel Rosado E Silva, João Machado

Hospital Professor Dr Fernando Fonseca, Amadora, Portugal

Introduction

Diffuse large B-cell lymphoma (DLBCL) is the most common type of B-cell lymphoma and frequently presents as a rapidly growing mass involving one or more lymph nodes. Bone marrow is involved in 10-20% of cases, especially in advanced disease, and renal involvement is uncommon.

Case description

We present the case of a 68-year-old woman with severe axial-predominant bone pain, fever, anorexia and involuntary weight-loss of 18% of body weight over the course of 11 months. Upon physical examination, the patient was febrile, emaciated, anicteric and did not present enlarged lymph nodes, liver or spleen. Palpation of axial skeleton and hips was painful. There were no other significant changes on physical examination; neurological examination was normal. Laboratory work-up revealed anaemia (Hb 6.8mg/dL), thrombocytosis (platelets $816 \times 10^9/L$), markedly

elevated serum lactate dehydrogenase (LDH) (2585 U/L) and ferritin (1319 ng/mL) and normal haptoglobin (568 mg/dL). Thoracic, abdominal and pelvic CT-scan showed no enlarged lymph nodes or other changes, except for a heterogeneous 12mm right renal mass. Cervical, thoracic and lumbar spine CT-scans showed yellow ligament thickening; there were no lytic or blastic lesions. Thoracic spine-MRI suggested diffuse neoplastic bone marrow involvement. PET-CT showed diffuse abnormal bone activity throughout the axial skeleton, skull and femurs; there was no abnormal renal activity. Bone marrow biopsy was performed, which revealed massive medullary infiltration and associated necrosis; immunohistochemistry was compatible with germinal-centre DLBCL. Renal mass biopsy was concordant with bone marrow biopsy. The patient was transferred to a haematology centre and was started on R-CHOP chemotherapy.

Discussion

Despite being the most common type of B-cell lymphoma, uncommon presentations of DLBCL present a diagnostic challenge. Our patient presented with no enlarged lymph nodes and no hepatosplenomegaly, but rather with B-symptoms and extensive bone marrow and renal involvement. This case report draws attention to the fact that, in the face of B-symptoms and markedly elevated LDH without haemolysis, clinical suspicion of lymphoproliferative disease should be high.

#1172 - Case Report

THE RAPID EVOLUTION OF A MISDIAGNOSED DISEASE: AN AGGRESSIVE LUNG ADENOCARCINOMA.

Rui Seixas, Ana Fernandes, David Duran, Armindo Ribeiro, José Sousa E Costa

Unidade Local de Saúde Litoral Alentejano, Santiago Do Cacém, Portugal

Introduction

Making the correct diagnosis and treatment in a timely manner can sometimes be difficult. Such is the case of a young woman wrongly diagnosed with a stroke due to septic emboli. In a short period she became progressively worse and died without ever knowing the true diagnosis.

Case description

A 54-year-old woman, with a clinical history of arterial hypertension and post-surgical hypothyroidism, was admitted in the Emergency Room (ER) due to paresthesia across the tongue, chin and right arm with progressive worsening for the last 15 days. She had a dental infection 15 days before the admission that had been treated with amoxicillin and clavulanic acid. When evaluated she showed hemiparesis of the right arm and right homonymous hemianopsia. Blood test results showed a discrete elevation of the C-Reactive Protein (CRP) and marked elevation of the lactate dehydrogenase (LDH) of 1697 UI/L. The computerized tomography scan (CT-scan) revealed a very small

left frontal subcortical hypodensity. Blood cultures were collected and she was admitted in the nursery with the diagnosis of septic embolic stroke. A CT-scan of the jaw was made which revealed osteolytic lesions compatible with osteomyelitis of the mandible and empirical treatment with ceftriaxone 2g 12/12h was began. In a few days the patient worsened with fever, total loss of vision, paralysis of the right part of the body, fever and prostration. A full body CT-scan showed new ischemic strokes in the parietal, temporal and occipital lobes bilaterally as well as a large mass of 7 centimeters in the lower lobe of the left lung. She was transferred to an intermediate care unit and antimicrobial therapy with meropenem was started. Blood cultures were negative. Biopsy of the jaw lesion was made. 17 days after the admission, the patient was blind, very little reactive to external stimuli and too weak to continue treatment and was transferred to the palliative care unit where she passed away 2 days later. The bone biopsy lesion result was available on the day she died which showed to be a metastasis of a lung adenocarcinoma rapidly growing and aggressively spreading.

Discussion

The evolution and progression of this patient's lung cancer was too fast to allow the correct diagnosis and treatment. This clinical case is important to remind us that daily reevaluation of the patient and our own clinical reasoning is crucial when treating the patients so that the true diagnosis can be made in timely manner.

#1177 - Case Report

ATYPICAL THROMBOSIS – A NEOPLASM PRELUDE

Vânia Mendes Junqueira, Joana Carneiro, Ana Valada Marques, Ana Corte-Real, Joana Sequeira, Fransico San Martin

Centro Hospitalar do Oeste - Hospital de Caldas da Rainha, Caldas Da Rainha, Portugal

Introduction

Venous thromboembolism (VTE) manifests mostly with thrombosis of the lower limbs or as pulmonary embolism. An atypical localization should raise the hypothesis of a non-benign cause.

Case description

A 77 years old man presented at the hospital due to swelling of both upper limbs and worsening dyspnea in the last month. He had a personal history of chronic bronchitis due to smoking, high blood pressure and alcoholism. At the physical examination, apart from the edema of both upper limbs he also had diminution of the vesicular murmur on both inferior hemithoraxes. The blood gases revealed hypoxemia and hypercapnia. The value of D-dimer was 415 ng/ml, with no other abnormal findings in the analytics. A chest CT angiography was performed identifying thrombosis in the superior cava vein and in the right subclavian vein, an expansive and irregular process in the Baretz space and

a bilateral pleural effusion. Anticoagulation with enoxaparin was started and further studies were made. The search for inherited and acquired thrombophilia was negative, as well as ACE, IGRA, HIV and syphilis' screening. We couldn't perform thoracentesis, so a bronchofibroscopy was made showing no macroscopic abnormalities. The microbiological study, the research of mycobacteria and the cytological analysis of the bronco-alveolar lavage was also negative. At last, a TC of the abdomen and pelvis was described as normal. In this way, the patient was discharge with a follow-up appointment scheduled, continuing the anticoagulant therapy with apixaban. A month after, the patient presented again at the emergency room with abdominal pain and anorexia. He was icteric and the analytics showed hepatic cytolysis and cholestasis. An abdominal ultrasound revealed a nodular heterogeneous mass in the head of the pancreas, compatible with a primary neoplasm, unresectable. A biliary prosthesis was introduced with palliative intention and the patient died a few weeks after.

Discussion

The pancreatic tumor is one of the most commonly neoplasms related to VTE. Patients with tumors are at high risk for VTE, but the last one can precede the diagnosis of a malignant disease several months before. In this way, a differential diagnosis and a regular follow-up of these events are extremely important.

#1183 - Case Report

IT'S NOT ALWAYS WHAT IT SEEMS: A CASE REPORT

Joana Dias Antunes, Diogo Abreu, Filipa Batista, Ana Figueiredo Costa, Luísa Loureiro, Amélia Pereira

Hospital Distrital da Figueira da Foz, Figueira Da Foz, Portugal

Introduction

The diagnosis of an additional primary neoplasia in patients with past cancer history and prior anticancer therapy it is not easy to establish and is usually interpreted as a development of metastases from the first cancer. However, it's important not to forget that it could also be part of a second malignancy. Cancer survivors are vulnerable to the development of new malignancies due to numerous factors like cancer predisposition syndromes, environmental exposures and late therapy effects. The authors report the case of a man with a history of rectal adenocarcinoma whose recent follow up exams showed suspicious signs of neoplasia, which turned out to be follicular non-Hodgkin's lymphoma.

Case description

A 64-years-old man was presented with a 2 years history of abdominal pain, constipation and melenes. His colonoscopy revealed a hemorrhagic and ulcerative mass with stenosis, from 35 cm of the anal margin. It was staged and it turned out to be adenocarcinoma T4b N0 M1a - stage IV. The patient went to surgery and chemotherapy and since then he took exams with

regularity at the oncology consultation. After 6 years of follow up, his computed tomography revealed fat densification along the root of the mesentery with multiple adenopathies. Signs of loco regional relapse were not evident. He took a positron emission tomography that showed some inguinal hypermetabolic adenopathies. New studies showed lumbar aortic and inguinal adenopathies. These findings were not suggestive of recurrence of its rectal neoplasia, so it was decided to perform a biopsy of an inguinal adenopathy, the results of which turned out to be follicular non-Hodgkin's lymphoma. The bone marrow and bone biopsy also revealed lymphoma infiltration. As a consequence, the patient went to chemotherapy.

Discussion

Patients with past cancer history may be vulnerable to the development of a second primary maligned neoplasia. This case is a reminder of how imperative it is to recognize these situations. Even in suspected cases of relapse malignancies it's important to perform the adequate investigations because of its implications on therapeutic strategies. Also it is essential to recognize that some patients are at risk of developing multiple primary malignancies and so should have longer follow up. In addition, the impact and toxicity of previous therapies needs to be better evaluated, as late therapy effects can make patients vulnerable to new maligned neoplasia.

#1186 - Case Report

DIFFUSE IDIOPATHIC PULMONARY NEUROENDOCRINE CELL HYPERPLASIA (DIPNECH): A CLINICAL CASE

Adelaide Pereira Alves, Margarida Carmo Dias, Ana Barroso

Centro Hospitalar de Vila Nova de Gaia/Espinho, Vila Nova De Gaia, Portugal

Introduction

Diffuse idiopathic pulmonary neuroendocrine cell hyperplasia (DIPNECH) is a rare disease with only about 100 cases reported in the literature. This condition is often found accidentally in a surgical specimen, is easily missed and needs careful observation.

Case description

A 61-year-old female without smoking history. Past medical history of obesity, arterial hypertension and diabetes mellitus. The patient was referred to a pulmonology clinic because of dry cough and progressive dyspnea for about one year. She presented wheezing in pulmonary auscultation. Functional respiratory evaluation showed mild obstructive ventilatory pattern. Chest radiography was normal, but computed tomography showed three pulmonary nodules (one of 16 mm in lower left lobe and two of 7 and 9 mm in lower right lobe). The nodule of 16 mm was biopsied and compatible with typical carcinoid tumor of the lung. The nodule of 9 mm was also biopsied and showed features of well differentiated neuroendocrine lesion. DOTANOC PET-

CT showed no increased expression of somatostatin receptors. Bronchoscopy showed no endobronchial lesions. No other lesions were found during tumor staging. The patient underwent right inferior lobectomy and left inferior lobectomy through video-assisted thoracoscopic surgery, without complications. Histology of surgical specimens showed several nodules with expression of CD56, cromogranine and sinaptofisine, <2 mitoses/2 mm², no necrosis and Ki67 expression of 5%. In the remaining parenchyma it was observed neuroendocrine cell hyperplasia and several tumorlets. It was assumed the diagnosis of typical carcinoid, tumorlets and DIPNECH. The patient did not present criteria for adjuvant therapy and has been kept under surveillance for almost one year.

Discussion

DIPNECH is considered a precancerous lesion of lung neuroendocrine tumor by WHO Classification. It is believed that DIPNECH, tumorlet and carcinoid are different stages of the same lesion and for this reason they often coexist in the same lung specimen. DIPNECH typically occur in elderly, female and nonsmoking population. This entity is often accompanied with chronic airway inflammation, mimicking asthma. We present this case because of its rarity and to warn that persistent symptoms suggestive of asthma may actually be associated with DIPNECH.

#1187 - Case Report

OLIGOMETASTATIC NON-SMALL CELL LUNG CANCER - AN EXCEPTION TO METASTATIC DISEASE

Adelaide Pereira Alves, Inês Sucena, Margarida Carmo Dias, Sérgio Campainha, Ana Barroso

Centro Hospitalar de Vila Nova de Gaia/Espinho, Vila Nova De Gaia, Portugal

Introduction

Non-small cell lung cancer (NSCLC) has a metastatic presentation in a significant proportion of patients. Systemic therapy may improve survival, but in most cases progression occurs in a short time. An exception to this rule is oligometastatic NSCLC, in which aggressive treatment of locoregional disease and oligometases has shown good results in terms of local disease control, progression-free survival and overall survival.

Case description

We present three cases of lung adenocarcinoma, with metachronous oligometastases (all EGRF and ALK negative).

Case 1

Man, 52 years old, with adenocarcinoma pT2bN2M0, treated with lingulectomy followed by chemotherapy (platinum and vinorelbine) and adjuvant radiotherapy. Two years later, the patient presented recurrence of the disease with a single brain lesion undergoing surgical excision, holocranial radiotherapy and four cycles of chemotherapy (platinum and pemetrexed). He has

been under surveillance for three years and without evidence of relapse.

Case 2

Man, 59 years old, with adenocarcinoma pT1bN0M0 treated with lobectomy. One year later, tumor recurrence with a single brain lesion, submitted to surgical excision, holocranial radiotherapy and four cycles of chemotherapy (platinum and pemetrexed). He is currently without evidence of recurrence for two years.

Case 3

Male, 63 years, with adenocarcinoma pT3N1M0 treated with lobectomy and chemotherapy (platinum and vinorelbine). Five years later, progression with bilateral metastasis of the adrenal glands. The patient was treated with bilateral adrenalectomy, initiation of replacement therapy with hydrocortisone and four cycles of chemotherapy (platinum and pemetrexed). He has been without evidence of relapse for two years.

Discussion

In the three cases presented, the treatment of the oligometastasis through the complete surgical resection and chemotherapy, with or without consolidation radiotherapy, allowed to reach excellent results, which is in agreement with the published evidence in the literature. The authors intend to alert the need to invest, diagnose, re-stage and treat radically patients with metachronous oligometastasis.

#1191 - Case Report

LEFT TROCHANTER FRACTURE AS THE PRESENTATION OF DIFFUSE LARGE B-CELL LYMPHOMA

Adriana Girão^{1,2}, Rui Pina^{1,2}, Rui M. Santos^{1,2}, Armando Carvalho^{1,2}

¹ Centro Hospitalar e Universitário de Coimbra, Serviço de Medicina Interna, Coimbra, Portugal

² Clínica Universitária de Medicina Interna, Faculdade de Medicina da Universidade de Coimbra, Coimbra, Portugal

Introduction

Diffuse large B-Cell lymphoma (DLBCL) is the most common type of non-Hodgkin lymphoma. The first symptoms are commonly swelling of the lymph nodes with pathological fractures (PF) being a rare presentation.

Case description

A 77-year-old woman was hospitalized with a 3-month history of proximal left leg pain and swelling, and development of progressive limited motion in the last month after she suffered a left trochanteric fracture. At the time of presentation, she had pain and severe swelling of the whole left leg, without fever, fatigue or weight loss. She underwent X-ray screening which revealed cortical rarefaction, raising suspicion of an infiltrative bone lesion. An ultrasonography was performed revealing three hypoechoic and heterogeneous nodular formations, the biggest one with 35x30mm adjacent to the common femoral

vein suggestive of necrosed adenopathy, in favor of a primary epidermoid tumor. Left iliac enlarged ganglia were also noted. An articular computerized tomography (CT) was performed revealing a large bone lesion with cortical and small trochanter destruction with bone detachment. The blood work only revealed an elevated LDH. As for the physical exam, she had edema of the whole left leg, with pain to palpation of a left inguinal mass. An 18F-FDG PET/CT revealed volumous hypermetabolic osteolytic lesion of the left femur, with massive involvement of the soft tissues, compatible with a high activity neoplasm. Bone, left inguinal and abdominopelvic ganglia metastization was noted. An ecoguided ganglia biopsy and the pathological examinations suggested a diagnosis of diffuse large B-cel lymphoma, activated B-cell type. Immunochemical results showed CD20+, Bcl-2 +, Bcl-6 +, MUM-1+, CD-10 -, CD-3 -, vimentin- and Ki67% + (>80%). According to the Ann Arbor staging the patient was a stage IV and revised International Prognostic Index (r-IPI) 3. She was proposed for chemotherapy with rituximab, cyclophosphamide, doxorubicin, vincristine and prednisone (R-CHOP). She received four cycles of R-CHOP and three cycles of rituximab with no clinical response to treatment and imagiologic evidence of progression of disease with a Deauville score of 5. Hospice care and palliative chemotherapy was initiated and the patient died 6 months after the diagnosis.

Discussion

The peculiarity of the present case lies in PF as the initial presentation and they are usually due to bone damage by the tumour. PF are an independent, adverse prognostic event in patients with DLBCL.

#1196 - Case Report

MM: MALIGNANT MYOEPITHELIOMA OR MULTIPLE MYELOMA?

Filipa Bordalo Ferreira, Rita Nunes Rodrigues, Inês Soler Bargiela, Maria João Gomes, Sara Vilas-Bôas, Sandra Pinto Alves
Hospital Prof. Doutor Fernando Fonseca, Lisboa, Portugal

Introduction

Malignant myoepitheliomas (or myoepithelial carcinomas) are rare salivary gland neoplasms which primarily arise from the parotid gland followed by the minor salivary glands, the latter most frequently in the palate. These tumors follow an aggressive course with common distant metastases namely to the bone. They exhibit various histological patterns, including plasmacytoid myoepitheliomas which should prompt differential diagnosis with plasmacytomas. Plasmacytomas are plasma cell neoplasms that are most commonly found in the bone marrow, but may also affect the nasal cavity and paranasal sinuses. These tumors may precede multiple myeloma or they can be a manifestation of this disease.

Case description

The authors present the case of a 46-year-old male of African descent with a recent diagnosis of malignant myoepithelioma

of the minor salivary glands with extensive bone metastases on imaging studies. The histological diagnosis was made through a biopsy from an ulcerated mass of the hard palate. The laboratory results showed a normocytic normochromic anemia (hemoglobin - 10 g/dL), mildly elevated erythrocyte sedimentation rate (58 mm), serum creatinine of 6,57 mg/dL and serum calcium of 11,2 mg/dL. The CT scans revealed a 4,5 cm neoformative lesion centered on the maxillary sinus, extending to the right side of the palate, as well as multiple lytic bone lesions in the skull, clavicles, sternum, ribs, all segments of the spine, humeri, femurs and the iliac bones. Integrating the findings of multiple lytic bone lesions, renal failure of unknown cause, anemia and hypercalcemia, the diagnosis of multiple myeloma was considered. Further laboratory testing revealed no M component nor increased immunoglobulin count, but an increased serum and urine free kappa light chain (and markedly elevated free light chain ratio) and the presence of Bence Jones protein. The histological material was revised and showed a population of plasma cells (CD138+) diagnostic of plasmacytoma. Therefore, the diagnosis of kappa light chain multiple myeloma with a maxillary plasmacytoma was established. The patient was started on high dose chemotherapy.

Discussion

This case illustrates the importance of integrating all findings on a broad clinical context even in the presence of a previously established diagnosis. What seemed to be a disseminated salivary gland neoplasm was actually a multiple myeloma, which is a completely distinct clinical entity with its own treatment and prognosis.

#1202 - Case Report

FROM HIP PAIN TO CRANIAL METASTASIS: A LATE DIAGNOSIS

Mariana Silva Santos, Daniela Luz Silva Rodrigues, António Cardoso, Fátima Campante
Centro Hospitalar Barreiro-Montijo, Barreiro, Portugal

Introduction

Prostate cancer is one of the most common cancers in men around the world. Currently in developed countries, most prostate cancer cases are identified by screening in asymptomatic men.

Case description

We report a case of a 67 years old african male that went to the Emergency Room because of an intense pain in his left hip, irradiating to the thigh and leg that had been aggravating for the last 6 days. The patient also referred he had lost about 10Kg during the previous month unintentionally, and denied any other symptoms. The patient was from Guinea Bissau and had arrive to Portugal 3 weeks prior, therefore, there were no clinical records referring to the patient. According to the patient, there was no relevant past medical history and the patient was under no medication except for painkillers. At physical examination, we found left hip pain

with palpation and positive left Lasègue's sign, and there were no signs of deep venous thrombosis. At neurological examination, we found right eye ptosis and non-reactive mydriasis, as well as diminished sensitivity in the right side of the face. Blood tests revealed anemia (Hb 7.5g/dL) and alkaline phosphatase (AP 4369UI/L, normal range <150UI/L) elevation, but normal calcium levels. Lumbar and cranial CT scans were performed. The lumbar CT scan identified blastic lesions in the sacrum, ilium and in several vertebrae, and the cranial CT scan identified a space occupying lesion in the sellar region. The total PSA was 1066.5ng/mL (normal range <4ng/mL) and free PSA was >30. A prostate biopsy was performed, revealing prostate adenocarcinoma Gleason score 7 (3+4). The thoraco-abdominopelvic CT scan revealed no other suspicious lesions. The cranial MRI suggested the space occupying lesion was either a meningioma or a pituitary macroadenoma, and identified a lesion in the right greater wing of the sphenoid. The bone scintigraphy showed multiple bone metastasis, both in the axial and appendicular skeleton.

Discussion

Most prostate cancer-related deaths are due to advanced disease. Due to screening, only 5% of the prostate cancer diagnosis have distant metastasis. Death rates have been globally decreasing; however, they remain higher in black men and prostate cancer tends to be more aggressive and progressive in that race.

#1225 - Case Report

PRURITUS AS A WARNING OF HODGKIN LYMPHOMA

Frederico De Almeida Garrett Soares Da Silva¹, Maria Inês Simões¹, Helena Rita¹, Luisa Arez²

¹ Centro Hospitalar Universitário do Algarve - Unidade de Portimão - Serviço de Medicina 3A, Portimão, Portugal

² Centro Hospitalar Universitário do Algarve - Unidade de Portimão - Serviço de Medicina, Portimão, Portugal

Introduction

Hodgkin lymphoma is a proliferative disease of B cells characterized by the presence of Reed-Sternberg cells. It represents 15-20% of all lymphoma cases. 25-50% of patients presents with B symptoms, and the most common clinical manifestation are painless adenopathies. Chronic pruritus is defined as itch lasting for more than 6 weeks, in association to internal malignancy and in particular lymphoproliferative disease.

Case description

We present the case of a 62 years old man, with history of swelling of the parotid gland and generalized pruritus, both with 6 months of progress. Before hospital admission for study of constitutional symptoms, he had been recently submitted to two lymph node incisional biopsies (axillary and cervical). At first evaluation, he presented generalized sero-hematic self-provoked skin lesions due to scratching from generalized pruritus, palpable cervical,

supraclavicular and axillary adenopathies and paresia of the lower limbs. The laboratory tests on admittance revealed normocytic and normochromic anemia with an Hb 9.8g/dL, with leukocytosis 14.200/μL and neutrofilia 83%; 495.000/μL platelets, PCR of 228 mg/L and positive neurospecific enolase tumor marker.

A CT scan revealed a 54x23 mm mass eroding the D1 vertebra and invading the medullar canal. Multiple cervical adenopathies (including intra-parotidian), mediastinal, left axillary, intramammary, splenic, retroperitoneal and inguinal.

After negative cytologic and anatomopathological results from multiple adenopathy incisional biopsies, an excisional biopsy of an axillary adenopathy confirmed the diagnosis of Hodgkin Lymphoma - sclerotic type CD30+ a CD15+.

The patient passed way days after the confirmation of the diagnosis due to septic shock.

Discussion

Paraneoplastic pruritus is defined as that happening before or throughout the natural progression of an oncologic disease. Pruritus of lymphoma is the common example of paraneoplastic itch and can precede other clinical signs by weeks or months. Not being the most common form of presentation, especially isolated, it can be a diagnostic challenge, which may delay the start of directed therapy.

The incongruence in cytologic and anatomopathological results from several specimens, as well as an atypical evolution of the clinical condition contributed for the diagnostic delay.

#1244 - Case Report

ATYPICAL PRESENTATION OF A HYPEREOSINOPHILIC SYNDROME - A CASE REPORT

Inês Lopes Da Costa¹, Maria Isabel Casella², Francisco Martins Do Vale², Pedro Brogueira², José Poças²

¹ Centro Hospitalar Universitário de Lisboa Central - Hospital de São José, Lisboa, Portugal

² Centro Hospitalar de Setúbal - Hospital de São Bernardo, Setúbal, Portugal

Introduction

Hypereosinophilic syndromes (HES) represent a rare group of disorders characterized by a sustained overproduction of eosinophils, causing tissue infiltration leading to organ damage. Despite having multiple aetiologies, the majority are idiopathic (75%). We report a case of a patient presenting with an abdominal eosinophilic tumour.

Case description

A 46-year-old man was admitted to the emergency room with right inguinal and lumbar pain, pruritus and subcutaneous nodules in the lower extremities, with one-week presentation. Given the pain, elevated inflammatory parameters and CT-scan showing inflammatory signs in the lower right quadrant

extending to the right inguinal region, an abdominal abscess was suspected, and the patient was initially given antibiotics. Due to clinical deterioration, an exploratory laparotomy was performed, identifying a right paravesical solid tumour and another similar mass in the greater omentum. The biopsy showed an eosinophilic infiltrate with eosinophilic vascular lesions. Laboratorial data showed eosinophilia (8.3×10^9), not present at admission, a bone marrow aspirate with 28% of eosinophils, with normal immunophenotypic study of both peripheral and marrow blood, findings suggestive of HES. Parasitological, viral and fungal tests were negative, auto-immune and allergic causes were excluded, which lead to the diagnosis of idiopathic HES. Other clinical findings suggestive of HES were identified, such as neurologic (peripheral polyneuropathy) and pulmonary involvement (alveolar infiltrates). Corticosteroid therapy was initiated and the patient showed clinical improvement and was discharged after 44 days. The patient was kept on steroids for 7 months, with total symptom remission.

Discussion

HES commonly cause dermatologic and pulmonary symptoms, gastrointestinal involvement may be present in 14% of the patients, and a presentation as a gastrointestinal tumour is very rare. The symptoms are non-specific and the diagnosis implies exclusion of other important causes of eosinophilia, such as infectious, allergic, neoplastic and drug related. As the case shows, an organ biopsy may be crucial to the diagnosis, particularly because neoplastic diseases must be excluded. The prognosis is favourable with proper therapy.

#1247 - Case Report

CARDIAC ANGIOSARCOMA

Francisca Martins, Joana Ferrão, Inês Canha, Lara Câmara, Miguel Martins, António Mesquita, Miguel Nunes, Rui Malheiro
Centro Hospitalar e Universitário Lisboa Central, Lisboa, Portugal

Introduction

Primary cardiac angiosarcoma is an extremely aggressive disease that is often unnoticed in an initial assessment due to its rarity and broad range of symptoms. In the absence of surgical treatment mean survival is 4 months and whilst partial or complete surgical resection are the preferred treatment modalities, these are merely palliative.

Case description

We report the case of a 36-year-old African female that presented to our emergency department with complaints of palpitations and restlessness. She denied prior similar episodes or any symptoms suggesting cardiac disease. She had a medical history of malaria, allergic rhinitis and chronic hepatitis B in non-replicative phase. The admission electrocardiogram revealed atrial flutter with a heart rate of 140 bpm but physical examination was unremarkable. She was started on a beta-blocker and low molecular weight

heparin (enoxaparin 1 mg/kg).

Blood tests revealed elevated d-dimers (2217 pg/L) and the chest x-ray showed an increased cardiothoracic ratio. Due to the raised suspicion of pulmonary embolism a CT angiography of the chest was performed. The scan excluded pulmonary embolism but revealed a 28x28 mm mass adherent to the right atrium, infiltrating the wall at the atrioventricular junction.

The patient was admitted to cardiac intensive care and a biopsy was obtained percutaneously. Whilst awaiting pathology results, the patient developed dyspnoea and lower gastrointestinal bleeding. She was not deemed fit for endoscopic assessment so a full body CT scan was performed and anticoagulation was stopped. The scan identified multiple lesions suggestive of secondary dissemination to the lungs, liver, ovaries and lymph nodes.

The biopsy revealed an angiosarcoma with positive vimentin, CD34 and CD31 markers, and negative S100 and actin markers. The Ki67 expression was 70%. The case was discussed within a multidisciplinary team that, due to the overwhelming burden of disease, decided to transfer the patient to the ward and start palliative care. The clinical status aggravated dramatically with thrombotic complications and invasion of the pulmonary and central nervous systems.

Discussion

May this case enhance clinical awareness of this aggressive disease and enrich the knowledge of its clinical manifestations in the literature, so that treatment can be started in the earlier course of the disease and increase the quality of life

#1249 - Case Report

DYSPHAGIA AS FIRST MANIFESTATION OF A RARE PROSTATE CANCER

Rita Lencastre Monteiro, Rodrigo Leão, Cesar Vieira, Cátia Carvalho, Joana Diogo, Carolina Coelho, Angela Ghilechi, Rita Bizarro, Sebastián Parente, Cristina Lima, Conceição Loureiro
Hospital Santo António dos Capuchos, Lisboa, Portugal

Introduction

Prostate cancer is the second most prevalent cancer in males. In 10% of the cases the disease is already spread by the time of initial diagnosis and during 2018 it was responsible for 29,430 deaths worldwide.

Case description

We report the case of a 78-year-old man, caucasian, with prostate adenocarcinoma diagnosed 4 years before, Gleason 6, with no extra-prostate involvement, which was under vigilance with a stable PSA (5 ng/ml). He was admitted to emergency department due to non-selective and progressive oropharyngeal dysphagia and dysarthria with a month of evolution accompanied by constitutional symptoms. Neurological examination revealed dysarthria and inability to perform protrusion of the tongue. Cranioencephalic computed tomography (CT) had no alterations

and thoracoabdominal CT described multiple nodes located in the pulmonar tissue, liver and spleen, peritoneal carcinomatosis signals and osteolytic foci involving dorsal vertebrae, sternum and ribs. He was observed by the ENT specialist that excluded visible lesions. Pelvic CT showed a proliferative prostatic space occupying lesion and numerous osteoblastic lesions. Tumor markers revealed a decrease in PSA 1ng/ml and NSE 201ng/ml. Cranioencephalic magnetic resonance had multiple metastatic cerebellar lesions as well a space conflict with the lower cranial nerves. An echo-guided liver biopsy was conducted and described infiltration by small cell carcinoma (SCC) CD 56 (+) TTF1 (+) and an index Ki-67 of 95%.

Discussion

This was a challenging diagnosis because prostate SCC is a rare entity and generally presenting symptoms are urinary retention and LUTS. The average age at diagnosis is 67 years and paraneoplastic syndromes are also rare. It comprises less than 1% of prostatic cancers, it's very aggressive and associated with obscure prognosis (median survival of 7 months) due to the frequent presence of advanced disease (90%) at diagnosis. The origin of SCC is controversial but in most cases, is associated with adenocarcinoma. The clinical behaviour is characterized by extensive local disease, low PSA levels and large metastatic burden (lymph nodes, liver, bones and abdominal cavity). The diagnosis is based on histologic features and so biopsy is strongly recommended. Chemotherapy is the standard approach. Given its aggressiveness it would be important to develop new biomarkers for early diagnostic, however it is difficult to carry out studies due to the small number of cases.

#1256 - Case Report

NEW-ONSET DIABETES IN THE ELDERLY: PRESENTATION OF INTRADUCTAL PAPILLARY MUCINOUS NEOPLASIA

Rita Lencastre Monteiro, Rodrigo Leão, Carolina Coelho, César Vieira, Cátia Carvalho, Joana Diogo, Rita Bizarro, Angela Ghiletschi, Sebastián Parente, Cristina Lima, Conceição Loureiro
Hospital Santo António dos Capuchos - CHULC, Lisboa, Portugal

Introduction

The significance of intraductal papillary mucinous neoplasms (IPMN) of the pancreas has increased in the last decade as the quality of the imaging studies improved. Corresponds to 1% of pancreatic pathology and 3% of pancreatic gland neoplasms with a higher prevalence between the 6th-7th decades, without a predominance for sex and without any defined risk factors. IPMN are ductal epithelial tumours characterized by dilation of the pancreatic duct due to mucus production, anatomically are subdivided into lesions from the pancreatic main duct, branch ducts or both, leading to different prognosis. The majority of patients are asymptomatic and the main manifestations are non-specific such as abdominal pain and acute pancreatitis. A more conservative approach has been preferred given the indolence of the lesions

Case description

84-year-old man, caucasian with hypertension and Alzheimer's dementia. Admitted to the emergency department due to acute confusional status and erratic speech. The examination revealed time disorientation, pain in the right hypochondrium, small inguinal adenopathies and capillary glycaemia of 400 mg/dl. Blood tests found leucocytosis (31,000 86% neutrophilia), PCR 141 mg/L. Chest x-ray was normal and cranioencephalic computed tomography (CT) showed microangiopathic leukoencephalopathy and multiple lacunar ischemic lesions. The patient was hospitalized and remained asymptomatic, hyperglycaemic and with no fever. Blood and urine cultures were negative. Given the abdominal discomfort, CT showed cystic dysmorphia of the pancreas and extramural macronodularity and CA 19.9 was 45 U/ml. The cholangiopancreatography by nuclear magnetic resonance described all the pancreatic parenchyma replaced by multiple cystic formations and Wirsung dilation of 8mm in the distal transition corresponding to mixed IPMN. As multidisciplinary decision and with the patient, a conservative therapeutic attitude was chosen maintaining periodic imaging surveillance of the lesion

Discussion

While the association between Diabetes Mellitus (DM) and pancreatic adenocarcinoma is well recognized, it's importance in IPMN isn't well defined. The presence or development of DM may be a marker of malignant progression and may warrant aggressive surveillance since DM was associated with significantly higher risk of high-grade dysplasia and had 7-fold higher risk of invasive carcinoma. This case serves to emphasize the role of new-onset diabetes as a warning sign that can lead to early detection and treatment.

#1260 - Medical Image

HYPERVISCOSITY SYNDROME AND MULTIPLE MYELOMA

Diana Leite Gonçalves, José Pedro Leite, João Pina Cabral, Cristina Martins, Luís Francisco
Centro Hospitalar e Universitário de Coimbra, Coimbra, Portugal

Clinical summary

A 63-year-old woman presented to the emergency room due to low back pain, fatigue and weight loss with 6 months duration. Her husband reported apathy and confused speech lasting 2 weeks. On examination she had gum bleeding (A) and pallor. Laboratory tests revealed hemoglobin 5.7 g/dL, hypercalcemia 3.34 mmol/L, total protein value of 153 g/L and hypoalbuminemia 21 g/L. She had a "raindrop skull" radiography (B) and a lumbar CT scan showed numerous osteolytic lesions (C). Due to hyperviscosity syndrome (HVS) she did emergent plasmapheresis. HVS is an oncologic emergency that presents with neurological deficits, visual changes and mucosal bleeding. It can be caused by paraproteinemias. A bone marrow biopsy confirmed the diagnosis of Multiple Myeloma IgG Kappa. She died 2 months after diagnosis.

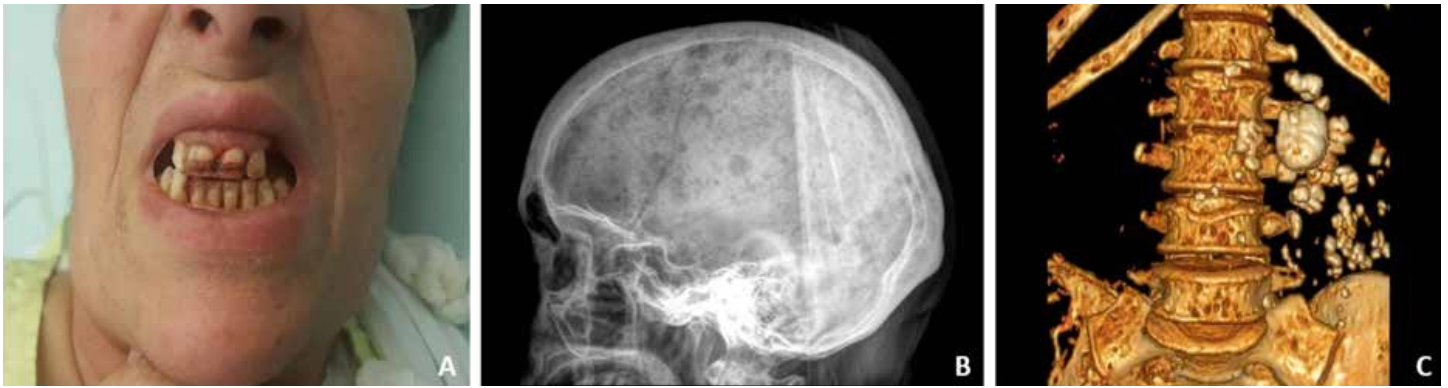


Figure #1260. Gum bleeding (A), “raindrop skull” radiography (B) and lumbar CT scan showing numerous osteolytic lesions (C).

#1277 - Case Report

INTRAHEPATIC CHOLANGIOCARCINOMA MIMICKING ACUTE HEPATITIS

Tatiana Costa Pires, [Adriana Bandeira](#), Miguel Gonzalez Santos, Rita Lizardo Grácio, Zósima Pinto, Ana Ubach Ferrão, Alcina Ponte
Centro Hospitalar de Leiria, Leiria, Portugal

Introduction

Cholangiocarcinomas are malignancies of the biliary duct system with an average incidence of 2-6 cases per 100.000 people per year. Jaundice is usually the main clinical feature. Hepatitis and hepatic cytolysis are not typical presentations of this condition.

Case description

A.C. is an 85 year-old woman who was seen in the Emergency Department by the Surgical Team due to abdominal pain, jaundice, nausea and vomiting.

Her physical examination was unremarkable except for pain on palpation of the right hypochondria and the evidence of cutaneous jaundice.

Preliminary blood tests revealed mixed hyperbilirubinemia (Total bilirubin 66.7 mg/dl with direct bilirubin 21.5 mg/dl and indirect bilirubin 17.5 mg/dl), moderately elevated CRP (94.2 mg/L) and elevated ALT and AST (720 U/L and 294 U/L). An abdominal ultrasound wielded no abnormal findings.

In light of these results, she was transferred to the care of the Internal Medicine team for etiological study of acute hepatitis. She was admitted to hospital.

Further tests, including viral serological markers (for HIV, HCV, HBV, EBV, CMV) were all negative. Further imaging was pursued and the patient underwent an abdominal CT scan which revealed a “hypodense right lobe formation with 48x38mm dimensions causing intrahepatic right biliary tract ectasia in relation with hepatic tumor, probable cholangiocarcinoma”. This diagnosis was confirmed by MRI cholangiopancreatography which further revealed locally advanced unresectable disease as well as probable lymph node metastasis.

After discussion with the Surgical Team she was referred for palliative care.

Discussion

The incidence of intrahepatic cholangiocarcinoma is increasing. Complete surgical resection is the only potentially curative treatment option, but unfortunately, most patients present with unresectable or metastatic disease at diagnosis.

In this case in particular, the diagnosis was further delayed by the presence of analytical markers of hepatic cytolysis and the absence of imagiological evidence of a lesion. Indeed, the low sensitivity of ultra-sound in this specific subtype of tumor is well known, indicating the need for pursuing other imaging methods.

The difficult diagnosis due to an atypical presentation of the disease in this case is proof of the important role Internal Medicine plays in any multidisciplinary team, namely in its ability to diagnose the most diverse conditions.

#1282 - Case Report

MULTIPLE MYELOMA: A DIAGNOSTIC CHALLENGE

Marta Baptista Freitas, José Marques, Luísa Viveiros, [Marta Ferreira Patacho](#), Jorge Almeida

Centro Hospitalar e Universitário de São João, Oporto, Portugal

Introduction

Multiple Myeloma (MM) is an hematologic malignancy of older adults, more frequent in men, that affects about 160.000 people/year worldwide. MM is a neoplastic proliferation of plasma cells producing a monoclonal immunoglobulin. It is clinically suspected in the presence of hypercalcemia, renal failure, anemia and bone lesions (CRAB features) due to the clonal process.

The authors present a clinical case of a not so evident clinical presentation of MM.

Case description

A 74-year old woman, with hypertension, anemia and Alzheimer’s disease (1 year from diagnosis; marked decline in autonomy and mental state in the last 3 months - ECOG 4); was observed at the Emergency department due to prostration and dyspnea, no history of fever. Blood tests showed normocytic normochromic anemia, no leukocytosis, thrombocytopenia, CRP 51.5mg/L and

normal renal function. Arterial blood test revealed hypoxemic respiratory insufficiency. No relevant alterations on chest radiography. The patient was admitted in the Internal Medicine Department with a respiratory tract infection and started treatment with amoxicillin/clavulanate. Additional study showed no iron deficiency (TS 19%, increased ferritin, normal folic acid and B12 vitamin), high erythrocyte sedimentation rate and LHD; hypoalbuminemia; normal count of total proteins, calcium and thyroid function. A computed tomographic angiography of the chest excluded pulmonary embolism, pneumonic consolidations, but revealed fracture of several bilateral costal arches and signs of bone rarefaction.

After that, MM was suspected and the following study was performed: skeleton survey (diffuse osteopenia, lithic lesions; T12, L1 and L2 compressive fractures); immunological study (increase IgG 3920 mg/dL, free kappa chains 1210 mg/dL and β 2-microglobulin 7540ug/L); serum protein electrophoresis (abnormal pattern: 38,4% band in the gamma region); immunofixation (monoclonal gammopathy IgG/kappa) and urine test (increased free kappa chains). Sternal myelogram examination showed 40% of plasmocytes, abnormal population of plasma cells: CD38+, CD138+, CD19-, CD56 +, CD45-, monoclonal kappa (additional markers: CD28-, CD27-, CD117 +, CD81-), compatible with MM.

The patient was treated with glucocorticoid and bisphosphonate to symptoms' management.

Discussion

In this case the late diagnosis of MM affected the treatment choice and the global prognosis of the patient.

Then it is very important to investigate MM when CRAB features (or some of them) are present.

#1292 - Case Report

A 79-YEAR-OLD WOMAN WITH ALTERED MENTAL STATUS

Sara Gomes, Sara Santos, Kelly Lopes, Teresinha Ponte, Filomena Carneiro, Fatima Campante

Centro Hospitalar Barreiro Montijo, Barreiro, Portugal

Introduction

Vitamin B12 deficiency is associated with a wide range of symptoms and forms of presentation, including hematological, gastrointestinal, neurological, and psychiatric abnormalities. It occurs frequently (> 20%) among elderly people, but it can often go unrecognized because the clinical manifestations can be subtle.

Case description

79-year-old woman, with a history of hypertension treated with indapamide 2.5mg q.d. and psoriatic arthritis; no previous limitation or previous history of dementia. She was admitted with an acute confusional state, disorientation, changes in speech and gait worsening in the last 24 hours. The patient was hemodynamically

stable, normoglycemic and afebrile. Neurological exam revealed psychomotor slowing, inability to follow complex orders, aphasia and bilateral lower limb strength reduction (grade 3/5). The first head CT (computed tomography scan) showed no ischemic, hemorrhagic or expansive changes. Stroke was considered a probable diagnosis and the patient was hospitalized. Clinical investigation, which included a complete blood count revealed pancytopenia with anisocytosis, macrocytosis and some macrothrombocytes: hemoglobin 10.9 g/dL (12-15 g/dL); mean corpuscular volume 116 fL (83-101fL); mean corpuscular hemoglobin 39 pg (27-32fL), leukocyte count, $3.7 \times 10^9/L$ ($4-10 \times 10^9/L$) and platelet count $93 \times 10^9/L$ ($150-400 \times 10^9/L$), associated with a B12 deficiency <83pg/mL (187-883pg/mL), and normal folic acid. Anti-parietal cell and anti-intrinsic factor antibodies were also identified. The patient refused an upper endoscopy during hospitalization. CT scan was repeated but once again clear. Treatment with intramuscular vitamin B12 was initiated, resulting in progressive clinical improvement and the patient was discharged with a follow-up consultation in Internal Medicine. At the 6-month re-evaluation the patient was clinically well, without any neurology manifestations and with normalized vitamin B12 values.

Discussion

In the differential diagnosis of acute/subacute neurological events, besides cerebrovascular diseases, we must consider other possible etiologies, such as the reversible causes of dementia, which includes vitamin deficiencies. Even though acute stroke is frequent in this population, it is crucial to investigate beyond the probabilities. In this case, the laboratory confirmation of vitamin B12 deficit, with no other identified etiology, and the gradual neuropsychiatric recovery after replacement therapy, confirmed the diagnosis.

#1298 - Case Report

NOT JUST ANOTHER HEMATURIA

Inês S F Da Silva, Beatriz Valente Silva, Marco Lopes Pires, Ana De Matos Valadas, Daniel Costa Gomes

Centro Hospitalar Universitário Lisboa Norte, Lisboa, Portugal

Introduction

Waldenström Macroglobulinemia (WM) is a rare disorder that affects predominantly elderly caucasian males. It consists of a lymphoplasmacytic lymphoma in the bone marrow with an IgM monoclonal gammopathy. Patients can develop symptoms related to infiltration of the hematopoietic tissues or related to monoclonal IgM in the blood. 23% of patients report bleeding at presentation and anemia can be seen in 40% of patients. The goals of WM treatment are to control symptoms and prevent end organ damage since it cannot be cured with current therapies.

Case description

A caucasian 84-year-old male presented with hematuria. Previous medical history: nonvalvular persistent atrial fibrillation

and normocytic normochromic anemia for at least 3 years. Medications: apixaban, bisoprolol, vitamin B12 and folic acid. He reported spontaneous gross hematuria with clots which started 10 days before. No other symptoms. Normal ultrasound image of kidneys and bladder. Laboratory findings: Hb 8.7 g/dL; HT 25.8%; MCV 82.1 fL; MCH 27.8 pg; white-cell count 7330 /mm³ (48.5% neutrophils; 46.4% lymphocytes); iron 29.2 µg/dL; ferritin 113 ng/mL; folic acid >20 ng/mL; vitamin B12 611 pg/mL; blood protein 6.6 g/dL; albumin 2.5g/dL; beta2-microglobulin 9.89 mg/L; Serum protein electrophoresis had monoclonal increase in the gamma region with a single narrow peak 2 g/dL; serum quantitative immunoglobulins and light chains: IgG 656 mg/dL, IgM 3580 mg/dL, Lambda 585 mg/dL; serum immunofixation: IgM lambda monoclonal gammopathy; urine immunofixation detected lambda bence jones protein. A bone marrow biopsy was performed: 64% of the bone marrow sample demonstrated infiltration by lymphocytes and lymphoplasmacytic cells that expressed CD19+/CD5-/CD79b+/CD20+/CD200+/CD43-. From clinical and laboratorial findings we can assume WM.

Discussion

Anemia is a common laboratorial finding and this patient had a known anemia for years that could be multifactorial given his ambulatory medication. Hematuria could be related to apixaban or to a genitourinary tract lesion but persisted after stopping apixaban and ultrasound was normal. In this case anemia and hematuria were a common finding of a rare clinicopathologic entity. Considering its presentation in the 70th decade of life, in spite of being a rare disease, a greater clinical suspicion is needed, as WM can transform into a more aggressive disease. Although no curative treatment is available, some therapies can be used to control symptoms.

#1306 - Case Report

A RARE CASE OF IDIOPATHIC AUTOIMMUNE HEMOLYTIC ANEMIA WITH RETICULOCYTOPENIA

Ana Rocha Oliveira, Gisela Ferreira, Marcelo Sousa Aveiro, Carolina Amado, Mariana Silva Leal, Carla Matias
Centro Hospitalar do Baixo Vouga, Aveiro, Portugal

Introduction

Autoimmune Hemolytic Anemia (AIHA) is characterized by an increased destruction of erythrocytes by anti-erythrocytes autoantibodies. Its incidence is unknown and it can be idiopathic (iAIHA 50%) or secondary to drugs, infections, autoimmune or malignant diseases. When it is not accompanied with compensatory reticulocytosis, iAIHA has a poor prognosis.

Case description

68-year-old woman, admitted for astheny and jaundice. History of dyslipidemia treated with statin. No history of other drugs consumption. At physical examination she presented icteric sclera

and pale skin. Laboratory tests: Hb 5.3g/dL, VGM 106 fL, HGM 36.4pg, reticulocytes 26x10E9/L, indirect hyperbilirubinemia, elevated LDH and decreased haptoglobin. Positive Coombs test. Peripheral blood smear: no significant changes. Immunological and virological studies were negative. Seric protein electrophoresis showed monoclonal band and immunofixation showed lambda light chain precipitation. Bone marrow aspiration and biopsy: erythroid hyperplasia. Flow cytometry: without changes. Paroxysmal nocturnal hemoglobinuria clone not observed.

Treatment was very difficult: She had no response 18units of packed red blood cells, 22 days of prednisolone 1 mg/kg/day, 2 days of intravenous human immunoglobulin 1 g/kg/day and 4 doses of Rituximab at 375 mg/m². She then escalated dose of prednisolone to 2 mg/kg/day, started azathioprine that was tapered until maximum dose (250mg 2id), and began epoetin beta (EPOB) 30.000 twice weekly, with concurrent folic acid 5mg.

At the 36th day of hospitalization, she began to show a modest improvement in Hb level, having been discharged at 65th day of hospitalization with Hb level of 9.5g/dL. At this point, we started to decrease steroid dose. She then developed myelotoxicity and hepatotoxicity which led to azathioprin withdrawal and subcutaneous administration of filgrastin, with stable levels of Hb. In the following appointment, patient was diagnosed with profound venous thrombosis (PVT) of right lower limb, for which she started therapeutic low molecular weight heparin (LMWH) and stopped EPOB. Now, she has Hb level of 14.4g/dL, with prednisolone 40mg id and therapeutic LMWH.

Discussion

With this case we want to highlight the difficulty of successfully treating a patient with iAIHA with reticulocytopenia. Note that there are no guidelines that fully support a particular approach in this setting, and that with the chosen treatment options came serious adverse events, that were managed and solved completely.

#1316 - Case Report

COLD AUTOIMMUNE HEMOLYTIC ANEMIA IN SOUTHERN PORTUGAL

Eduarda Alves, Conceição Viegas, Carlos Godinho, Mário Lázaro
Centro Hospitalar Universitário do Algarve, Faro, Portugal

Introduction

Autoimmune hemolytic anemia (AHA) is a rare disease and it is classified according to the reactivity temperature of antibodies to erythrocytes. In cold AHA, autoantibodies bind to erythrocytes at temperatures between 4 ° -18 ° C, which may lead to erythrocyte aggregation in the bloodstream and, when the complement system is activated, haemolysis occurs.

Case description

Woman, 34 years old, caucasian, with global developmental delay and ataxic syndrome, daughter of consanguineous parents. Interned in the Internal Medicine service, due to easy fatigue with

a week of evolution that hinders small efforts, notion of skin pallor. At admission: overweight, pale skin and mucous membranes and icteric conjunctive. Generalized hirsutism and grade II systolic murmur at auscultation. Blood tests with Coombs direct and indirect positive test; Reticulocytocytosis; Anisocytosis and macrocytosis; LDH greatly increased; hyperbilirubinemia, with consumption of complement. Streptococcus group A positive test. Initiated prednisolone 1 mgr / kg / day and folic acid, with increased hemoglobin values. The blood count was always obtained after the blood was heated. The diagnosis of cold hemolytic anemia was assumed. He was discharged with corticosteroids at weaning and normalized values of hemoglobin, haptoglobin and LDH.

Discussion

Most AHAI patients present with mild anemia, however, in the winter months, there may be worsening of anemia and acute hemolysis. One of the frequent causes is the infectious one, appearing the symptoms two to three weeks after the beginning of the infection. In this type of AHAI, protection against cold is a priority, but corticotherapy may be started. It can be concluded that patients with AHAI present a chronic disease with periods of remission and recurrence.

#1327 - Case Report

A RARE CAUSE OF A COMMON COMPLAINT

Luís Monteiro Dias, Marta Braga, Vânia Gomes, Céu Rodrigues, Herlander Marques, António Oliveira E Silva
Hospital de Braga, Braga, Portugal

Introduction

Bone pain is a very common symptom in medical practice. Several causes are reported, such as arthritis, fractures, infection, ischemia, excessive use or even neoplasms.

This case reports a cause of persistent and debilitating bone pain, and the importance of an early diagnosis.

Case description

A 59-year-old male with past history of chronic lumbar pain secondary to spinal stenosis presented to the Emergency Room with aggravated complaints of the lumbar pain, and sacral and left rib cage pain, evolving over several weeks, refractory to analgesics. He also referred a total weight loss of 5 kg during the previous weeks. A lumbar computed tomography scan showed lytic lesions across multiple lumbar vertebrae and an infiltrative lesion in the right sacrum wing.

The patient was admitted in Internal Medicine to undergo further complementary exams. An IgG/Kappa peak was identified with a raised Kappa/Lambda ratio (5.97). No renal dysfunction, anemia or hypercalcemia was identified. A full body scintigraphy was performed and revealed a high pyrophosphate capture on the lumbar vertebrae, right sacroiliac joint, right acetabulum, right sacrum wing, second and ninth right ribs and on the eight left rib. Biopsy of the right sacrum wing infiltrative lesion revealed a plasmacytoma.

The patient was discharged and further workup was performed in Oncology department. Myelogram revealed no abnormal plasmacytes. An OncoFISH for Multiple Myeloma was performed and found at (4;14) IgH/FGFR3 rearrange in 23% of cells. Positron emission tomography scan showed multiple lytic lumbar, rib cage, scapular, ischial and femoral metabolically active lesions suggestive of multiple myeloma. The diagnosis of concomitant IgG/Kappa multiple myeloma was performed.

Specific treatment was initiated with both radio and chemotherapy.

Discussion

This case reports a patient with a multiple myeloma and plasmacytoma at younger age of onset than usual. Multiple myeloma and isolated plasmacytoma are diseases of older adults, with a median age of diagnosis of 66 and 55 years old, respectively. There is no cure for this group of diseases but with new treatments the median survival increased from 3 to more than 6 years in the last 20 years. The cytogenetic abnormalities present in this patient are considered of intermediate risk on the Revised International Staging System. According to it, a median overall survival is expected between 43 and 83 months.

#1344 - Medical Image

SALT AND PEPPER APPEARANCE OF THE SKULL IN A 59 YEARS OLD CAUCASIAN FEMALE PATIENT WITH MULTIPLE MYELOMA

Sofia Mahomed Mateus, Ana Brito, Daniela Marto, Hugo Inácio, Salvador Morais Sarmiento, Miguel Leite, Andreia Amaral, Dina Pita, Catarina Salvado

Centro Hospital Universitário Lisboa Central, Lisboa, Portugal

Clinical summary

Female, 59 years old, caucasian.

Presented to Emergency Department with a pathological rib fracture previously diagnosed in a thoracic computed tomography. Started with fatigue, lost of weight (6Kg) and generalized myalgias, one month ago. Admitted to the hospital for further investigation. The blood workup revealed hemoglobin 6.9 g/L, good renal function, total proteins count 124.3 g/L, Corrected Calcium 5.6 mg/dL and a monoclonal peak of IgA of K light chains (A) in protein electrophoresis. Skeleton X-ray showed typical salt and pepper lesions (B). Multiple lytic bone lesions were seen in femoral and humeral X-rays.

Bone biopsy and myelogram confirmed the diagnosis of multiple myeloma.

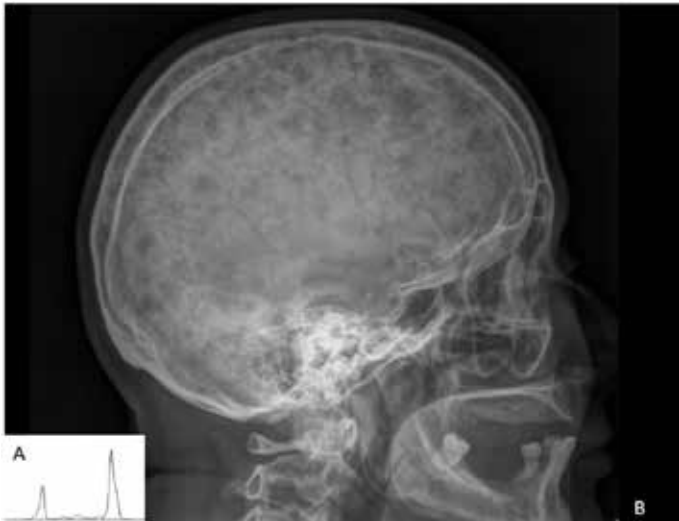

Figure #1344. Myeloma Multiple in 59 years old caucasian female patient. Panel A: monoclonal peak in protein electrophoresis. Panel B: skull x-ray showing typical salt and pepper lesions.

#1350 - Case Report

MASSIVE PERICARDIAL EFFUSION AS THE FIRST MANIFESTATION OF LUNG ADENOCARCINOMA

Couto Couto, Vicencia Ribeiro, Dolores Canário, José Duarte
Hospital Garcia de Orta, Almada, Portugal

Introduction

Pericardial effusion can be the first sign of a variety of systemic disorders. Cardiac tamponade is a less common situation and represents a medical emergency.

Case description

We present the case of a 66 year-old caucasian female, born in Mozambique with previous relevant history of smoking (30 units pack per year), hypertension and dyslipidemia, medicated with atorvastatin, ramipril and amlodipine. She had two first grade siblings with lung cancer: her father died at the age of 70 and her sister at the age of 50 years-old.

She was admitted in the emergency department complaining of dry cough worsening in the last month associated with right pleuritic chest pain, dyspnea and fatigue for mild efforts. She performed a thoracic X-ray revealing a right inferior hypotransparency and right pleural effusion and a thoracic CT confirming a moderate bilateral pleural effusion (32mm) needing further investigation with diagnostic thoracocentesis. The fluid analysis showed an exudate bloody fluid, negative for cancer cells, with ADA value in the normal range.

During hospitalization, she developed a progressive dyspnea, orthopnea and fatigue. She was diagnosed with cardiac tamponade and she was submitted to emergent pericardiocentesis. The fluid analysis revealed an exudate with negative malignant cells in the cytological exam. She underwent further exams for clarification. The thoraco-abdomino-pelvic CT showed a 6 cm heterogeneous mass at the inferior right lung extending to the ipsilateral pleura

and hilum, with suspicious hilar malignant adenopathies. The FDG-PET-CT was consistent with a malign right inferior pulmonary lesion with ipsilateral hilar metastasization. The bronchofibroscopy rendered a biopsy that revealed a lung adenocarcinoma. The cancer was classified as a clinical lung cancer stage IV (T3N3M1a). There was not enough material for PDL-1 characterization and she was submitted to a transthoracic aspirative biopsy waiting for PDL-1 and other molecular markers. Meanwhile she started carboplatin and paclitaxel based-chemotherapy, having the last imaging exams revealed a tumoral response with a lung mass shrinking after three cycles, until a stage Ib (T2aN0M0). She has been proposed for curative cancer surgery.

Discussion

The pericardial effusion with cardiac tamponade is a rare presentation of lung cancer on stage IV. The hematic fluid suggests the diagnosis. However a differential diagnosis has to be made with other malignancies and pulmonary tuberculosis.

#1351 - Case Report

GAMMOPATHY WITHOUT A GAMMA SPIKE

Ana C. Sousa, Francisco Dias Cláudio, Rita Ribeirinho, Tiago Tribolet De Abreu
Hospital Espirito Santo, Évora, Portugal

Introduction

Despite its relatively low frequency, multiple myeloma (MM) represents the second most common hematologic neoplasm. Its classic presentation includes hypercalcemia, renal lesion, anaemia and bone lesion (typically referred to as CRAB). Protein electrophoresis of the serum (SPEP) is essential for the diagnosis. Nonetheless, there might be some atypical results which should be valued accordingly.

Case description

A 65-year-old man was sent to the emergency room with a three-month-long lower back pain. An ambulatory lumbar Computerized Tomography showed multiple vertebral osteolytic lesions and a collapsing fracture of the fourth lumbar vertebrae (L4). The blood panel showed normocytic anaemia (haemoglobin of 7.6g/dL), thrombocytopenia (138000/ μ L), acute kidney injury (creatinine of 9.69mg/dL) and hypercalcemia (13.5 mg/dL). The SPEP revealed two monoclonal spikes, one in the beta one (β 1) region, and the other in the beta two (β 2) region with the immunofixation describing a monoclonal gammopathy IgG-lambda as well as Bence-Jones Lambda. The bone marrow aspirate confirmed the diagnosis of MM by revealing the presence of 54% of plasma cells due to a IgG-lambda clone. Initial approach included vigorous hydration without appropriate response and need for renal replacement therapy (conventional haemodialysis), as well as bisphosphonates, radiotherapy directed at L4, and chemotherapy with bortezomib and dexamethasone. His admission was complicated with a respiratory infection treated with antibiotics and an antifungal.

Discussion

Regardless of its clear presentation with CRAB, the SPEP was rather atypical. Frequently the IgG appears in the gamma region, while in this case it appeared in the $\beta 2$ region. Moreover, a second spike in the $\beta 1$ region represented the free light chains (FLC) which are not represented in a normal SPEP. However, having excluded the other proteins present in the $\beta 1$ region, FLC are the likely cause of the second spike. Therefore, this case report highlights the importance of other clinical and analytical clues, despite the absence of the typical gamma spike. Furthermore, this enhances the need for critical examination of the different SPEP spikes, keeping in mind that a $\beta 2$ region spike might not be related with an IgA gammopathy.

#1354 - Medical Image

BULKY MEDIASTINAL MASS

Ana Figueiredo Albuquerque, Maria João Palavras, Flávia Santos, Juliana Silva, Helena Carrondo, Célio Fernandes
Centro Hospitalar de Leiria, Leiria, Portugal

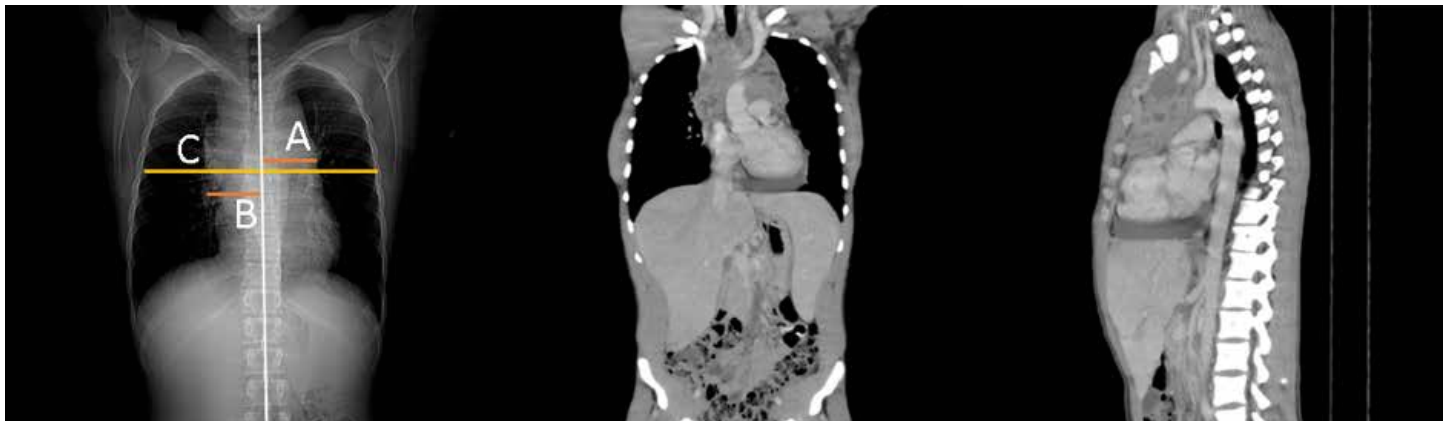


Figure #1354. Bulky mediastinal mass with vessel entrapment. $[(A+B)/C = (66.36+64.59)/274.29 \text{ mm} = 0.61]$.

#1363 - Case Report

MENINGEAL CARCINOMATOSIS AS THE PRESENTING SYMPTOM OF AN OCCULT ADENOCARCINOMA

Vilma Salgado¹, Ana Cardoso¹, Dúlio Passos¹, Nuno Boura Jacinto¹, J. Meneses Santos², Rui M. M. Victorino²

¹ Department of Internal Medicine II, North Lisbon University Hospital Center - Santa Maria Hospital, Lisbon, Portugal

² Medicine II University Clinic, Faculty of Medicine - University of Lisbon, Lisbon, Portugal

Introduction

Meningeal carcinomatosis is a rare complication of advanced metastatic cancer where malignant cells from a distant solid tumor infiltrate the meninges. Only a small percentage of patients are diagnosed with this condition in vivo, most of which have coexisting brain metastases. The most common solid tumors to metastasize to the meninges are breast, lung cancer and melanoma. Fewer cases are reported from gastrointestinal malignancies.

Clinical summary

The authors present the case of a 20-year-old male presented to the ER with a 2-week evolution of dyspnea, low grade fever, night sweats and a loss of 2 kg.

The blood analysis revealed $0.5 \times 10^3/\mu\text{L}$, Hb 10.1 g/dL, fibrogen $>700 \text{ mg/dL}$, sedimentation rate elevation 62 mm and C Reactive Protein of 196.2 mg/L. In the thoracic X-ray there was evidenced of mediastinum enlargement and the thoracic computed tomography revealed a large infiltrative mass in the anterior mediastinum (14x5.4 cm) with mediastinal vessels entrapment. The final diagnosis was a classical Hodgkin lymphoma (nodular sclerosing form).

A bulky mass is defined as a mediastinal mass which has a maximum width equal to or greater than 1/3 of the internal transverse diameter of the thorax and in this case was greater than 1/2.

Case description

A 30-year-old caucasian male, with no prior medical history nor trauma, presented with holocranial headache evolving for two weeks. The month prior to hospital admission he suffered from lower limb pain, nausea, vomiting, diarrhea and a 15 kg weight loss. He had a (normochromic normocytic anemia 10.3 g/dL and thrombocytopenia $110 \times 10^6/\text{L}$), and prolonged aPTT. Brain CT scan showed a bilateral fronto-temporo-parietal subdural collection causing a mass effect with middle line deviation to the left. After emergent correction of the coagulopathy, the collection was drained, exiting a xanthochromic liquid, incompatible with acute hemorrhage. A bone biopsy showed adenocarcinoma metastases with immunostaining properties of colorectal origin. Due to neurologic deterioration the patient required a second neurosurgical intervention. Two thickened Dura samples were collected, which were also suggestive of adenocarcinoma metastases from colo-rectal origin. Toraco-abdomino-pelvic CT scan was inconclusive to determine primary origin. The patient died 14 days after admission, before diagnostic colonoscopy and autopsy was not authorized by next of kin.

Discussion

The authors report a rare presentation of an advanced metastatic colo-rectal malignancy in a young patient. Meningeal carcinomatosis is a rare condition that commonly progresses rapidly and its extremely poor prognosis makes it important to make an early diagnosis.

#1369 - Case Report

PARANEOPLASTIC SYNDROME: ABOUT A CASE

Miguel Alexandre Alves, Sergio Alves, Tiago Ceriz, Jorge Poço ULSNE, Bragança, Portugal

Introduction

Paraneoplastic Syndrome (PNS) is characterized by a set of signs and symptoms that occur with a neoplastic event. These manifestations, such as the state of hypercoagulability, are related to the degree of activity neoplastic disease.

Case description

A 66-year-old female, autonomous, with a history of left breast neoplasm, submitted total left mastectomy, goes to the Emergency Department after sudden installation of diplopia, vomiting and imbalance. At the neurological examination, she presented a right braqueal hyposthesia. CT cranial scan reveals a discrete right anterolateral cerebellar hypodensity. During hospitalization, was made a cranial MRI, that showed in the right cerebellar hemisphere a peri-centimeter vascular sequelar. Complementary study (EcoTT, Carotid and vertebral echo Doppler, ECG) without changes. She began treatment with estatina and antiagregant. She was discharged with the diagnosis of Transient ischemic attack (TIA). Three weeks later, the patiente starts a discrete diplopia right facial asymmetry and ataxic gait. The MRI reveals lesion in the left thalamic nucleus compatible with small acute lacunar infarction. Study immunological and for thrombophilias negative. She was medicated with statin, double ntiaggregation (Aspirin + clopidogrel). One month later started adjuvant chemotherapy; on that day, begins with dysarthria, diplopia, right hemiparesis and hemihipostesia right. The cerebral MRI aimed at a restriction focus in the center of the left thalamus translating of. It was decided to delay the chemotherapy until it stabilized the patient. She was discharged to a Continuing Care Unit taking statin, aspirin and started anticoagulation with NOAC. Four months later she started diplopia and right hemiparesis with homolateral hemipostesia. Cerebral MRI reveals focus of restriction in the medial strand of the stalk ceright ventricle. Further study, including genetic study of Fabry's disease and PET without changes. She kept previous medication. Currently the patient is in a Unit of Continuing Care with follow-up Stroke and with favorable evolution.

Discussion

Interpreted as PNS, we want to highlight the importance that neoplastic processes deserve as the genesis of systemic complications, such as the hypercoagulability, which may be more harmful than the neoplasia itself.

#1384 - Case Report

AFTERALL IT WASN'T ONLY CONSTIPATION

Francisco Chambel Belém, Artur Costa, João Silva, Juliana Sá, Eduardo Carvalho, Maria Do Céu Evangelista, Margarida Ascençao, Leopoldina Vicente Centro Hospitalar Universitário Cova da Beira, Covilhã, Portugal

Introduction

Peritoneal carcinomatosis is an intraperitoneal dissemination consequence of certain malignancies, which is not originated from the peritoneum itself.

Generally, is a late stage manifestation of several gastrointestinal malignancies including appendiceal, colorectal, and gastric cancer. Associated with a poor prognosis and limited treatment options. The presence of ascites is one of the first indicators, seen in up to 70% cases.

Case description

We present a case of 64-years-old Spanish male, who resides in Spain, but was in Portugal on vacation, that went to Emergency room for constipation with 15 days of evolution associated with abdominal pain.

It is a patient with a history of hypertrophic cardiomyopathy and hypocoagulated atrial fibrillation. Never did endoscopic study and had no history of familiar malignancies.

The patient was calm, with normal vital parameters and normal cardiopulmonary auscultation.

The abdomen was globulus but depressible, with pain on palpation of all quadrants, without palpable masses and a positive ascitic wave signal.

Point-of-care abdominal ultrasound shown a large amount of ascitic fluid and abdominal Rx with towel opacity in all quadrants. Blood test with normal renal and hepatic function, normal pancreatic enzymes and increased CRP of 6.14 mg/dL.

We performed an abdominal paracentesis, with analysis of the ascitic liquid with highlight for an increased mononuclear cells of 2819, negative culture after incubation period and presence of neoplastic cells in ascitic fluid with positive cytology for malignant adenocarcinoma.

Serum ascite albumin gradient was inferior to 1,1g/dL, compatible with peritoneal disease causing the ascite.

The abdominal CT with contrast showed an apparent peritoneal carcinomatosis.

Given the stability of the patient and and the severity of the diagnosis, he asked to be transferred to his local hospital in Spain. The patient was promptly accepted and transferred with all relevant clinical information.

In Spain the patient underwent endoscopy and colonoscopy that revealed adenocarcinoma located in the colon.

A multidisciplinary team is setting the best therapeutic strategy for the patient.

Discussion

The alliance between an exhaustive physical examination and the use of technology and diagnostic tests were key to a fast diagnosis. This case reflects the need for cooperation between European hospitals, since patients travel regularly between countries.

Efficient communication is essential, in order to better care of our patients.

#1388 - Case Report

SEIZURES IN PATIENT WITH COLON CANCER

Isabel M Ríos Holgado, Magdalena Martín Pérez, Rocío Rojas Lorence

Hospital Punta de Europa, Algeciras (Cádiz), Spain

Introduction

A 73-year-old woman with stage IV colorectal cancer and liver involvement treated with folfox (oxaliplatin, 5-FU and folinic acid) and bevacizumab, was seen in the emergency department because of weakness, nausea and vomiting. In the waiting room she presented a generalized tonic-clonic seizure.

Case description

When she was attended, she has no fever, her blood pressure was 119/95 mmHg, with a pulse 100 beats/min and the respiratory rate was normal. The physical examination revealed loss of consciousness with a Glasgow Coma Scale of 8/15 (E2V2M4) and the head CT showed no acute pathology. The woman was hospitalized and given levetiracetam.

Enhanced MRI scan showed poorly defined, hyperintense in T2 and FLAIR lesions in the white matter of bilateral posterior cerebral hemispheres, parietal and frontal lobes and cerebellum, without contrast enhancement. These imaging findings are characteristic of reversible posterior leukoencephalopathy syndrome (RPLS) associate to chemotherapy, specifically to bevacizumab. Chemotherapy was stopped. After 72 hours, she was lucid and could answer questions correctly, but she has muscle weakness of the lower limbs.

Control MRI of the brain after seven days showed disappearance of the lesions. Several days later, the patient continued neurological improvement, but she developed liver failure because of progression of liver metastasis and died.

Discussion

RPLS is a rare clinical and radiological disorder associated with hypertension and use of immunosuppressive medication. Bevacizumab is a monoclonal antibody that inhibits the angiogenesis of tumours by specifically blocking vascular endothelial growth factor. The pathogenesis is poorly understood,

in cases related to immunosuppressive therapy, the cerebral edema is probably due to cytotoxicity.

The symptoms include epilepsy, headache, visual disorder, paresis, nausea and altered mental functioning. Fortunately, most people recover neurological symptoms after discontinue or decrease the doses of offending agents. Despite RPLS is a uncommon disease, clinicians must suspect this entity in oncological patients with neurological symptoms who receive chemotherapy.

#1389 - Case Report

MALIGNANT HYPERCALCEMIA IN PREGNANCY, AN EPHEMERAL PASSAGE

Jorge Silva Ferreira, Yolanda De Sá Pereira, Soraia Lobo-Martins, Maria João Gomes, Rita Teixeira De Sousa

Centro Hospitalar Lisboa Norte, Lisboa, Portugal

Introduction

Hypercalcemia in pregnancy is associated with significant materno-fetal morbidity and mortality, although in most cases it is related to primary hyperparathyroidism, a usually benign condition. More rarely, it results from the presence of pr-PTH-producing tumors (squamous cell carcinoma, carcinoma of the breast, kidneys, bladder, colorectal, lymphomas and placental tumors), vitamin D-producing tumors (lymphomas and dysgerminomas of the ovary) and lytic bone metastases.

Case description

31 year old female, 33 weeks pregnant, presented with lower back pain refractory to painkillers, and associated with non-selective anorexia and weight loss. At clinical examination, she presented with a diffusely painful uterus, and symmetrical malleolar edema. Laboratory findings compatible with normocytic normocytic anemia, neutrophilic leukocytosis, creatinine 2.07 mg/dL, corrected calcium 18.1 mg/dL, and C reactive protein 9.66 mg/dL. she was admitted to a medical ward for the correction of hypercalcemia, with no clinical or laboratory improvement after intense intravenous hydration and diuretic therapy. Given the risk of administration of bisphosphonates to the fetus, cesarean section was performed, during which bilateral ovarian masses were found and biopsied. Zoledronic acid was administered with standardization of calcemic values. The study of calcium metabolism revealed PTH 8.1 pg/mL, pr-PTH 9.2 pmol/L (<1.3 pmol/mL). Body CT scans that showed mass in the right breast with smaller anexed solid masses, and enlarged ganglia in the jugular-carotid and axillary space. Bone scintigraphy revealed multiple lytic lesions compatible with secondary lesions. Breast biopsy revealed type 3 tubular adenocarcinoma, triple negative. Hormonal therapy and chemotherapy were initiated with palliative intent. The patient died about 1 year after her daughter was born.

Discussion

This case is unique due to the diagnostic difficulties of malignant hypercalcemia in a previously healthy pregnant patient presenting

with lower back pain, a common complaint in the last trimester of pregnancy, noting that calcium dosing is not part of the routine evaluation. Previous gestational ultrasonography did not show lesions of the ovary, suggesting that the pregnancy itself enhanced the spread of the cancer that presented with ovarian, bone and nodal metastasis. Also at discussion is the hypothesis that the relative state of immunosuppression induced by pregnancy contributed to the severity of the presentation.

#1390 - Case Report

ACUTE STROKE IN A YOUNG WOMAN AS A MANIFESTATION OF MULTIPLE MYELOMA

Alda Tavares¹, Vasco J. Barreto², Catarina Ala Baraças³, Joana Dos Santos⁴, Fátima Braga¹, Carlos Sottomayor¹

¹ Department of Medical Oncology, Hospital Pedro Hispano, Matosinhos Local Health Unit., Matosinhos, Portugal

² Department of Internal Medicine, Hospital Pedro Hispano, Matosinhos Local Health Unit., Matosinhos, Portugal

³ Department of Radiology, Hospital Pedro Hispano, Matosinhos Local Health Unit., Matosinhos, Portugal

⁴ Department of Pathologic Anatomy, Hospital Pedro Hispano, Matosinhos Local Health Unit., Matosinhos, Portugal

Introduction

Stroke of undetermined cause has been reported in as many as one-third of young stroke patients. Multiple Myeloma (MM) is an unlikely cause of stroke and it is related to the hyperviscosity syndrome and thrombophilia. We report the case of a young woman with a diagnosis of MM preceded by acute stroke.

Case description

A 48-year-old woman presented to the emergency department in April 2016 due to ischemic stroke in the territory of the right posterior cerebral artery without identified risk factors. Cardioembolism and cervicocephalic arterial dissection, autoimmune and infectious aetiology were excluded. Hypogammaglobulinemia and anemia (hemoglobin 10g/dL) were the only abnormal findings.

In the following months, the patient presented pan-hypogammaglobulinemia (IgM e IgA <25 mg/dL, IgG 484 mg/dL) and hypoproliferative anemia (8.4 g/dL), hypercalcemia (11 mg/dL) and sedimentation rate of 75 mm/1h. No history of recurrent infections neither evidence of solid neoplasm.

She presented in September 2016 with rapidly progressive paraplegia and sphincter dysfunction. No lesions on dorsolumbar spine computed tomography, but with a posterior compressive epidural lesion at D8 level documented by magnetic resonance. She was submitted to decompressive laminectomy, followed by radiotherapy, without improvement of the deficits. Investigation: plasmacytoma with IgG heavy chain expression; medullary plasmacytosis (10-12%) with excretion of lambda chains; urinary excretion of lambda chains; negative peripheral blood immunoelectrophoresis; and partially consolidated bilateral

costal fractures. Therefore, the diagnosis of MM was performed, and she underwent induction chemotherapy with thalidomide and dexamethasone. She presented recurrent serious infections secondary to marked hypogammaglobulinemia, requiring monthly treatment with intravenous immunoglobulins. She developed deep vein thrombosis (DVT) and pressure ulcers secondary to paraplegia. Unfortunately, she died in March 2018 in the sequence of urosepsis.

Discussion

The authors describe a case of stroke in a young woman, concomitant with hypogammaglobulinemia and anemia, that culminated in spinal compression syndrome and finally in the diagnosis of MM with negative peripheral blood electrophoresis. After reviewing the case, we consider anemia, hypogammaglobulinemia and hypercalcemia were already manifestations of MM. Like DVT, stroke could be a manifestation of prothrombotic state secondary to MM.

#1396 - Case Report

DON'T UNDERESTIMATE A COUGH

Virginia Visconti, Andre Fernandes, Ismenia Oliveira, Jose Lomelino Araujo

hospital Beatriz Angelo, Loures, Portugal

Introduction

A chronic cough is one lasting over eight weeks, and up to 40% of European population have reported this symptom at some point. There is a plethora of causes.

Case description

The authors present the case of a healthy 33-year-old man admitted to the emergency room with an irritative, nocturnal cough, and wheezing over 2 months. Symptoms had exacerbated the week before, accompanied by fever, profuse perspiration, moderate effort dyspnea, pleuritic left thoracalgia. Loss of 8% body weight over the past 3 months. On examination, sub febrile, tachycardic, pale, eupneic, with no palpable peripheral adenopathies. Laboratory results showed anemia, normal leucocytes, C-reactive protein 15 mg/dl, HIV negative. Past infection for Epstein-Barr. Hemocultures were Negative. Chest radiography evidenced a widened mediastinum, with no pleuro-pulmonary alterations. Computed Tomography revealed important mediastinic and right hilar adenopathies, leading to a reduced right inferior lobar bronchus, as well as celiac and splenic adenopathies, suggestive of a lymphoproliferative disease. Due to lack of peripheral adenopathies he underwent bronchofibroscopy with bronchial lavage (Negative Ziehl-Neelsen stain) and ecoendoscopy, with lymph node needle biopsy. The cytological report documented disperse lymphocytes, with isolated cells with Reed-Sternberg morphology, but the immunocytochemical study with CD 15 and CD 30 was inconclusive. During hospitalization, a peripheral supraclavicular adenopathy became evident, was biopsied and the diagnosis of Hodgkin lymphoma was confirmed.

Discussion

Hodgkin lymphoma is a B cell lymphoma which generally presents with a palpable, nontender peripheral adenopathy, but may present with B-symptoms, as in this case. Accurate diagnosis is important as early treatment is imperative.

#1400 - Medical Image

RACCON EYES - A CLUE TO SYSTEMIC AMYLOIDOSIS

Ana Hipólito Reis, Susana Costa, Fátima Franco

UTICA - Serviço de Cardiologia, Centro Hospitalar Universitário de Coimbra, Coimbra, Portugal

Clinical summary

Amyloidosis is a manifestation of several systemic entities, consisting in pathological extracellular deposition of insoluble fibrillar proteins. It is rare and high index of suspicion is crucial for diagnosis. We report a case of systemic amyloidosis, with cutaneous, cardiac, gastrointestinal and neurological attainment, unique as it presented first with nail dystrophy and thrare "raccoon eyes". This latter discriminative feature should raise suspicion of systemic amyloidosis, as there are few clinical entities in the diferencial. Occurrence of periorbital ecchymosis reflects vascular fragility secondary to amyloidosis. The patient evolved with restrictive cardiomyopathy and severe heart failure. Amyloid substance in identified in endomyocardial, intestinal and cutaneous biopsies.

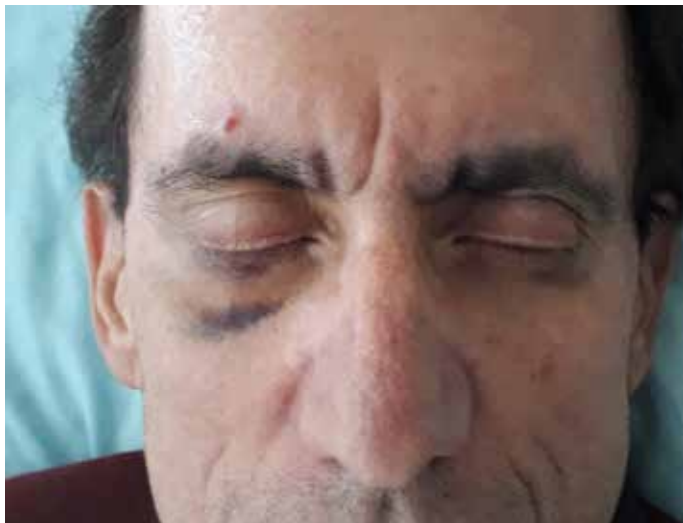

Figure #1400. Periorbital ecchymosis, reflecting vascular frailty secondary to amyloidosis.

#1409 - Case Report

THE PNEUMONIA THAT HAS BEEN REVEALED... NEUROENDOCRINE CARCINOMA OF LARGE LUNG CELLS

Marisa Brochado, Maria Ines Santos, Helena Dias

Internal Medicine Department, Hospital Distrital de Santarém, E.P.E., Santarém, Portugal

Introduction

Neuroendocrine carcinoma of large lung cells is a rare type of lung carcinoma. At initial presentation, 40% of patients are in stage IV. A gloomy prognosis is assumed, with a 12-month survival rate of 27%. Higher incidence in males, high age groups and smokers should be noted.

Case description

Male patient, 58 years old. Relevant personal history of HT, DM type 2 NIT, former smoker. He went to the Emergency Department for a non-productive cough, sudden worsening dyspnea and swelling of the right cervical region with a few weeks of evolution. He was hospitalized for probable acquired pneumonia in the community.

Discussion

In the internment, a mass was observed on the right antero-external face of the neck, and an etiological diagnosis was initiated. Ultrasound of soft parts of the neck "...latero-cervical swelling corresponding to adjacent nodules..."; chest CT and neck "...exuberant right mediastinal mass, surrounding the right common carotid, with inferior extension to the middle mediastinum and right pulmonary hilum... pre occlusive stenosis of the superior vena cava... occlusion of the right pulmonary artery... bronchial stenosis main right... "; of the histological, anatomopathological study and staging "...neuroendocrine carcinoma of large cells of the lung stage IV". during hospitalization, the patient developed a superior vena cava syndrome with resolution after corticotherapy and radiotherapy. He initiated chemotherapy with cisplatin and etoposide associated with radiotherapy.

Conclusion

Although the majority of telemetric radiographic correlations associated with respiratory failure with an adjacent infectious process are community-acquired pneumonias, they should always arouse interest when the patient's physical examination is not innocent. The neuroendocrine carcinoma of large lung cells, because it is uncommon compared to other histological types, is considered to be a diagnosis of exclusion and should not be neglected by its reserved prognosis and exuberant symptomatology.

#1410 - Case Report

DIFFUSE LARGE B-CELL LYMPHOMA: A CASE REPORT

Marisa Brochado, Maria Ines Santos, Helena Dias

Internal Medicine Department - Hospital Distrital de Santarém, E.P.E., Santarém, Portugal

Introduction

Diffuse Large B-cell Lymphoma is the most common type of non-hodgkin's lymphoma (HNL), occurring at a frequency of 30% of NHL cases. It has a particular incidence in more advanced age groups, with a mean age of 60 years. There are no unequivocal risk factors for this type of lymphoma.

Case description

Male patient, 56 years old, with personal history of colorectal surgery, by volvo, about 2 years before. He applied to his doctor for adynamia and cutaneous pallor with evolution of one week associated with gastrointestinal transit with dark stools. Unexplained weight loss, 7kg in 30 days. In sustained apirexia. Referred to the emergency department for loss of 7 grams of hemoglobin within 2 months.

Discussion

The objective examination should be paleness, splenomegaly and axillary adenopathies. The following diagnostic exams were performed: analytically with monocytosis, increased beta2-microglobulin, increased CA 125; digestive endoscopy with gastric ulcer, Dieulafoy lesion and H. pylori positive. CT thoraco-abdomino-pelvic "voluminous soft tissue injury from the great curvature of the stomach with infiltration of the tail of the pancreas and vasous splenic". Medulogram "hyperplasia of the erythroid series". Medullary biopsy with histochemistry "non-specific rectal aspects, without evidence of infiltration by neoplasia". Excisional ganglion biopsy compatible with diffuse large B-cell lymphoma. PET-CT study compatible with lymphoproliferative disease.

Conclusion: More than 50% of cases of NHL present initially with extra-ganglionar involvement; however, although very aggressive, it is a pathology potentially curable by chemotherapy.

#1435 - Case Report

ONCOCYTIC THYROID CANCER AND JAK2 MUTATIONS – AWARENESS FOR THE RISK IN POLYCYTHEMIA VERA

Henrique Cabrita Rodrigues¹, Catarina Rodrigues², Filipe Alçada Silva³, Ana Furão Rodrigues², Rui M. M. Victorino⁴, António Pais-De-Lacerda⁵

¹Specialist trainee in Respiratory Medicine, Internal Medicine Department 2, Hospital de Santa Maria, Centro Hospitalar Lisboa Norte, Lisboa, Portugal

²Specialist trainee in Internal Medicine, Internal Medicine Department 2, Hospital de Santa Maria, Centro Hospitalar Lisboa Norte, Lisboa, Portugal

³Medical graduate, FY¹. Internal Medicine Department 2, Hospital de Santa Maria, Centro Hospitalar Lisboa Norte, Lisboa, Portugal

⁴Full Professor of Internal Medicine, Faculty of Medicine, University of Lisbon; Director Internal Medicine Department 2, Hospital de Santa Maria, Centro Hospitalar Lisboa Norte, Lisboa, Portugal

⁵Senior Consultant physician in Internal Medicine, Internal Medicine Department 2, Hospital de Santa Maria, Centro Hospitalar Lisboa Norte, Lisboa, Portugal

Introduction

Polycythemia vera (PV) is a myeloproliferative neoplasm characterized by increased red blood cell production and haemoglobin (Hg) level. JAK2 V617F mutation is identified in more than 95% of patients. There is more than twice the risk of PV after

parathyroid adenoma. The risk of evolution to myelofibrosis or acute myeloid leukaemia is high but an increased risk of developing solid tumours or lymphoid neoplasms has been also reported.

Case description

A 72-year-old woman, with a history (10 years earlier) of parathyroidectomy for adenoma, and treated regularly for hypertension, was observed for deep vein thrombosis, headache and generalized pruritus. Laboratory evaluation revealed erythrocytosis (6,50x10¹²/L; Hg 16.9 g/dL; haematocrit (Htc) 54.3%) with low serum erythropoietin (<1 IU/L). JAK2V617F mutation was positive, confirming a diagnosis of PV. Treatment with 3 phlebotomies (3/3 weeks) led to a Htc of 40,5%, with iron deficiency (30 µg/dL) induced anaemia. Six months later, the appearance of anorexia with involuntary weight loss (12 kg/2 months) originated a full investigation (evolution of the disease? / development of another malignancy?). An innocent myelogram (normocellular marrow, with reduced iron storage) excluded leukemic transformation or myelofibrosis. Atrophic chronic gastritis with Helicobacter pylori infection was detected by endoscopy, and following antibiotic treatment an immediate weight gain (6 kg/3 months) was observed. Thyroid hormone levels were normal, but the cytology of a cold nodule in the right thyroid lobe revealed a cystic neoplastic lesion suggestive of non-differentiated thyroid carcinoma. Total thyroidectomy was performed, and histology revealed a lesion that could correspond to an oncocytic tumour, with marked nuclear alterations and areas of necrobiosis. It was not possible, however, establishing its malignancy (oncocytic cell carcinoma) since it was not observed any capsular fragment.

Discussion

In this case, we could find some of the relationships (already known) between PV and other diseases (past parathyroid adenoma, H. pylori infection). Furthermore a new lesion developed (without the interference of any chemotherapy), which could be related to "a common risk factor" - JAK2V617F mutation. Thus, in PV patients, besides being important to be alert for a potential haematological transformation, we must monitor the possible development of cancers including those of the thyroid gland.

#1439 - Case Report

FOLLOWING THE SIGNS ON THE SKIN

Francisca Beires, Danay Perez, Ivo Cunha
Hospital Pedro Hispano, Matosinhos, Portugal

Introduction

Paraneoplastic syndrome (PS) arise from the production of cytokines and hormones provoking organ or tissue damage at locations far from the site of the primary tumor or its metastasis.

Case description

A 66 year old woman, non-smoker, worker of the canning industry, with a familiar history of neoplasia (5 close relatives) presented

with a 2 month history of fatigue, anorexia and a weight loss of 10 kg, associated with cough with mucoid sputum. No dyspnea, thoracic pain or fever were reported by the patient. She had no contacts with known tuberculous relatives.

Nausea and occasional vomiting were also reported, non related to ingested foods. No other gastrointestinal.

Non-pruriginous but painful petechiae initiated 2 days before admission on both legs. She denied arthralgias, myalgias, Raynaud phenomena, xerostomy, xerophthalmia or ulcers.

On physical examination, she presented with diminished pulmonary sounds on the left pulmonary field. Petechiae were noted up until both thighs with oedema until both knees. No adenomegalies were palpable.

Summary analyses showed a hyponatremia, as well as a normocytic normochromic anemia with a ferropenic component, with elevated inflammatory parameters and thrombocytosis.

She underwent a CT-scan, which revealed left pleural effusion, with atelectasia of the left inferior lobe, as well as nodular hypocaptant lesions on the left lung and pleura suggestive of metastasis and a nodule on the right adrenal gland with 1,8cm. Thoracocentesis showed a predominance of mononuclear cells (64%) without malignancy.

She underwent bronchofibroscopy and pleural biopsy revealing an adenocarcinoma of unknown origin (positive CK7, CEA and PD-L1; negative TTF1, napkin, CD20, CDX2, RE, calretinina and WT1). Two mutations on the HER-2 gene were described, with ultrasonography and mammography being normal. Admitting lung adenocarcinoma she started pembrolizumab. Regarding the probable PS, viral serologies, immunologic study, ANCA, complement, immunoglobulins and cryoglobulins were negative.

Discussion

PS is frequently associated with lung cell carcinoma. Manifestations of leukocytoclastic vasculitis are rare form of PS, being lung carcinoma one of the most prevalent malignancies associated with this condition. It is attributed to tumor-associated circulating antigens, causing complement fixation and inflammation.

This case was particularly interesting because medical help was only sought due to the purpuric lesions which unmasked a more serious disease.

#1445 - Case Report

LEPTOMENINGEAL CARCINOMATOSIS IN COLORECTAL CANCER: CHALLENGING DIAGNOSIS AND POOR PROGNOSIS

Diogo João Silva, Rute Brás Cruz, Joana Cancela

ULSM-Hospital Pedro Hispano, Matosinhos, Porto, Portugal

Introduction

Leptomeningeal carcinomatosis is a rare form of leptomeningeal neoplastic involvement, occurring in up to 8% of solid tumors and up to 15% in hematologic malignancies. Most cases are due to breast or lung adenocarcinoma and rarely from colon. Clinical

presentation is nonspecific due to multifocal involvement, being common findings related to cranial and spinal dysfunctions or meningeal irritation.

Case description

An 81 years-old autonomous woman presented to the emergency department with one-week evolving behavioral change with confuse slowed speech, reduced lower-limb muscle strength and progressive autonomy loss. History of right hemicolectomy due to colon adenocarcinoma (pT4aN2bR0) in 2018, denying adjuvant chemotherapy. At presentation, space-time oriented with mildly slowed speech. Hours after developed aggressive behavior, visual hallucinations and decreased consciousness. CT cerebral scan was normal and lumbar puncture revealed normal opening pressure, cloudy cerebrospinal fluid, pleocytosis with mononuclear cell predominance, reduced glucose and high-protein level. She was empirically started on antibiotics (ampicillin) and microbiologic plus cytologic analysis were performed. The former was negative but the latter showed the presence of adenocarcinoma cells, establishing the diagnosis of leptomeningeal carcinomatosis. Cerebral magnetic resonance imaging showed bilateral periventricular hyperintensity with changes in the cerebrospinal fluid after contrast enhancement. Facing the poor prognosis and progressive global deterioration, palliative symptomatic care was performed and the patient died two weeks after admission.

Discussion

Incidence of leptomeningeal metastases is slowly rising, most likely related to better imaging studies, therapeutic regimens and supportive care. Diagnosis remains a challenge, often requiring entire neuroaxis MR imaging and cytologic analysis. Despite systemic and local control of the primary tumor, the prognosis is still poor with overall survival from 2 to 4 months. This case illustrates the diagnostic challenge, lack of effective treatment options and poor prognosis associated with leptomeningeal carcinomatosis.

#1450 - Medical Image

A ZYGOMATIC METASTASIS OF CHOLANGIOCARCINOMA

Mónica Silva, João Gramaça, Fernanda Martins, Filomena Carneiro, Fátima Campante

Centro Hospitalar Barreiro Montijo, Barreiro, Portugal

Clinical summary

A 64 year-old-woman presented with epigastric pain irradiating to the back, associated with emesis. Lab workup revealed an increased bilirubin (4.6 mg/dL), ALP (1002 UI/L), AST (522 UI/L) and ALT (577 UI/L). Abdominal-pelvic MRI showed a mass in the right hepatic lobe measuring 86x83 mm, with signs of infection. Further evaluation of tumour markers showed increased CA 19.9 (275613 U/mL).

The patient underwent a course of antibiotic with clinical

improvement, but maintaining increased serum levels of cholestasis biomarkers. The patient underwent liver mass biopsy, which showed cholangiocarcinoma. Due to pain on a lump in the malar region, it was performed a maxilo-facial CT scan that showed a mass on the right zygomatic arch, with later histological confirmation of being a metastasis.

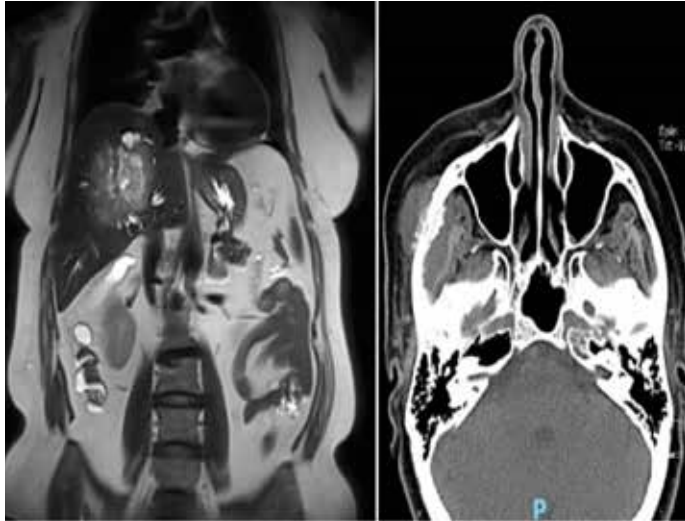


Figure #1450. Zygomatic metastasis of cholangiocarcinoma.

#1454 - Case Report

AN UNUSUAL CAUSE OF ASCITES

Anilda Barros, Rita Homem, Maria Garcia, Catarina Araújo, Vanda Spencer

Hospital Garcia de Orta, Lisboa, Portugal

Introduction

Malignant mesothelioma is a rare tumor, with an estimated incidence of 0.2 to 3 cases per million inhabitants per year. Pleural involvement is the most frequent, occurring at the peritoneum in only about 30% of the cases. Malignant peritoneal mesothelioma (MPM) is more prevalent in males (2:1). Given the inespecificity and the indolent nature of its symptoms, its diagnosis is often late, being frequently diagnosed between the fourth and sixth decades of life.

Case description

The authors present the case of a 55-year-old fisherman with a history of hypertension, type 2 diabetes, dyslipidemia, ischemic heart disease and diffuse atheromatous disease. Former smoker and moderate alcoholic habits. The patient reported previous and prolonged exposure to asbestos, namely in a warehouse where he kept the fish.

Admitted to the Emergency Department due to an increase in abdominal volume of 1-year evolution and worsening in the last month.

Upon physical examination good general status, afebrile, presence of tensioned ascites. No abdominal masses, palpable adenomegaly or stigmas of associated chronic liver disease were found. No

jugular engorgement, pulmonary stasis or significant peripheral edema.

Paracentesis was performed and cytochemical analysis of ascitic fluid revealed a serum-ascites albumin gradient of 1.3 g/dL with high cellularity (400 cells) predominantly polymorphonuclear cells (60%); cultural examinations were negative and histopathological studies showed neoplastic cells with adenocarcinoma morphology. Thus, additional exams were performed, namely transrectal prostatic ultrasound, thoraco-abdomino-pelvic CT scan, upper digestive endoscopy and colonoscopy, with no other alterations suggestive of neoplasm.

The case was discussed at a multidisciplinary meeting of Digestive Oncology and the patient performed exploratory laparoscopy which revealed multiple peritoneal implants whose biopsies documented MPM of the epithelioid type.

He was proposed for peritonectomy and intraoperative intraperitoneal chemotherapy and forwarded to a referral center.

Discussion

MPM's pathophysiology is still poorly understood. Several studies point its strong association to asbestos exposition, with a disease latency period of about 20 to 30 years and the neoplastic risk is directly related to duration and the intensity of exposure.

#1456 - Case Report

SIMULTANEOUS BILATERAL SECONDARY SPONTANEOUS PNEUMOTHORAX: ATYPICAL COMPLICATION OF MALE BREAST CANCER

Diogo João Silva¹, Ana Raquel Teixeira², Rita Oliveira², Inês Chora

¹ ULSM-Hospital Pedro Hispano, Matosinhos, Porto, Portugal

² Instituto Português de Oncologia, Porto - IPO Porto, Porto, Portugal

Introduction

Spontaneous secondary pneumothorax (SSP) occurs in relation to pre-existent pulmonary disease, being pulmonary obstructive lung disease and pulmonary parenchyma infections the main causes. Neoplastic diseases, either primary of the lung or metastatic, rarely lead to spontaneous pneumothorax. Simultaneous bilateral spontaneous pneumothorax (SBSP) is a rare condition, comprising 1,9% of all SSP.

Case description

A 79-year-old man with a past history of left ductal breast carcinoma (T2N2Mx, GIII, B2 negative, RE positive) undergone radical left mastectomy with axillary dissection in 2010 and adjuvant chemotherapy, radiotherapy and hormone therapy with 5 years follow-up without progression. In 2018, after evaluation of anterior leg pain, lung, pleural and bone metastases were documented. Bone biopsy confirmed the presence of breast cancer metastases. Despite chemo and radiotherapy with palliative intent, disease progression was observed and a different line of treatment with hormone therapy was started. In February 2019, the patient presented to the emergency department with

progressively worsening dyspnea in the last month, severely cachectic, with polypnea and pulse oximetry (IF O2 21%) of 95 %. No history of trauma or recent thoracentesis. Breath sounds were absent bilaterally, on the bottom third, with normal cardiac sounds. Chest radiograph revealed a simultaneous bilateral pneumothorax, of small volume on the right lower third and of medium volume on the left lower third. Therapeutic thoracentesis was performed, chest tube placed and the patient admitted for further medical treatment. Despite the best medical care and symptomatic relief provided, the patient died five days after admission.

Discussion

This case report illustrates a rare and fatal complication of male breast cancer pleural metastases. When cancer-related, SBSP is mainly associated with Hodgkin's lymphoma, lymphangioliomyomatosis, mesotheliomas and osteosarcomas with pleural metastases. Management with chest tube drainage is defined by the etiology and size of the pneumothorax. If larger than 1-2 cm or due to underlying lung disease, insertion of a chest tube is advised. Despite rare, SBSP is a potentially fatal complication for patients with lung/pleural metastases or under chemotherapy

#1464 - Case Report

SEVERE APLASTIC ANEMIA AS FIRST MANIFESTATION OF HODGKIN LYMPHOMA

Patrícia Rosinha¹, Gisela Ferreira², Bárbara Leal¹, Cláudia Rosado¹, João Calhau¹, Rosa Jorge¹

¹ Internal Medicine Department, Baixo Vouga Hospital Center, Aveiro, Portugal

² Hematology Department, Baixo Vouga Hospital Center, Aveiro, Portugal

Introduction

Hodgkin Lymphoma (HL) is a potentially curable lymphoma with an estimated incidence of 2.7/100,000 habitants in Europe. Its association with Aplastic Anemia (AA), extremely rare in the light of the state-of-art, is an adverse prognostic factor for which the best therapeutic approach is still unknown.

Case description

57-year-old male was admitted to the Emergency Department of Baixo Vouga Hospital Center with tiredness, lower gastrointestinal bleeding and spontaneous hematoma formation in the last 2 months. Physical examination: pale skin, petechiae, hematomas, right axillary swelling. Hemogram: hemoglobin 5.8 g/dL, VGM 130 fL, HGM 42 pg, neutrophils $1.36 \times 10^9/L$, platelets $1 \times 10^9/L$, reticulocytes $26 \times 10^9/L$. Peripheral blood smear: pancytopenia, no remarkable morphologic changes. Other tests were normal: indirect bilirubin, LDH, coagulation, folic acid, vitamin B12, ferritin, thyroid/renal/hepatic function, IGRA, serologies, autoimmunity and angiotensin converting enzyme.

Computerized tomography of neck/chest/abdomen/pelvis:

lymphnodes on laterocervical, right supraclavicular and right axillary regions with 5.7x3.6 cm; 3.6x12.6 cm and 3.7x2.4 cm. Biopsy of the lymphnode at the right axillary region: HL, subtype nodular sclerosis (NSHL).

Bone marrow biopsy: severe hypocellularity of 3 cell lineages. Normal bone marrow aspirate, flow cytometry and caryotype. Positron emission tomography: splenic infiltration by malignant lymphoma.

At this point, patient was diagnosed with AA secondary to NSHL, Ann-Arbor stage IIISE-B.

After knowing he had a lymphoproliferative disorder, our first intervention was to begin steroid therapy in an attempt to rise platelet count and begin chemotherapy, however, patient maintained severe and symptomatic thrombocytopenia, needing blood support (erythrocyte+platelets) in a daily basis. In fact, he suffered a gradual worsening of the clinical situation and was transferred to Oporto Hospital Center 36 days after admission. He maintained steroid therapy + blood support and began thrombopoetin analogs, however, he died of hemorrhagic stroke a few days later.

Discussion

Hodgkin lymphoma treatment continues to evolve, however there are still disease subsets where the prognosis is very dismal and there are no effective therapeutic strategies. Because of the severe and symptomatic thrombocytopenia, the patient wasn't capable of performing chemotherapy directed to the neoplastic cell clone which was responsible for it in the first place.

#1466 - Case Report

T-CELL LYMPHOMA AS A CAUSE OF ABDOMINAL PAIN AND ASCITIS SECONDARY TO LIVER TUMORAL INFILTRATION

Tiago Valente, Fani Ribeiro, Marcelo Aveiro, Pedro Neto, Gorete Jesus

Baixo Vouga Hospitalar Centre, Aveiro, Portugal

Introduction

It has been reported that T-cell Lymphomas can rarely present with ascites. It is generally thought that ascites results from peritoneal membrane infiltration by tumor cells and usually cytologic and immunohistochemical studies have a high diagnostic yield.

Case description

Male, 69 years old, with a past medical history of Polycythemia Vera under treatment with hydroxyurea and periodic phlebotomies, admitted in the urgency room with a 1 week history of abdominal pain and progressive abdominal distension with months of evolution. In the initial evaluation the patient had a dull abdomen at percussion, with mild tenderness at palpation. Moreover, there was a palpable mass with more than 1cm in diameter at the right inguinal region. Blood workup showed thrombocytopenia and increased coagulation times, LDH and total bilirubin, with albumin at the lower limit of normal.

Abdominal ultrasound revealed hepatosplenomegaly, infiltrative liver lesions and multiple lymphadenopathies. A paracentesis was performed showing a serum-ascites albumin gradient >1.1 , without malignant cells. The lesion in the inguinal region was biopsied, showing infiltration of T-cells. The final diagnosis of T-cell Lymphoma was made, stage IV-B of Ann Arbor, IPI 4, with diffuse hepatic infiltration. He was started on CHOP (cyclophosphamide, hydroxydaunorubicin, oncovin and prednisolone). As side effects of treatment, after 4 months the patient developed spontaneous bacterial peritonitis, which was treated successfully with empirical antibiotic therapy and albumin. 10 days later, the patient had a varicella-zoster virus reactivation and pancytopenia with neutropenia.

Discussion

We present a rare case of a peripheral T-cell lymphoma clinically manifesting as ascites. Cytologic and immunophenotypic analysis of ascites has been described as an important test for the diagnosis of lymphomas. In this case the mechanism of ascites formation seems to be related to portal hypertension secondary to tumor cell infiltration of liver parenchyma, which may result in a negative cytologic result as there may be no peritoneal involvement. This case also illustrates the treatment's dangerous side effects related to immunosuppression highlighting the need for a close follow-up and surveillance of these patients.

#1471 - Case Report

SUCCESSFUL USE OF VENO-ARTERIOUS EXTRACORPOREAL MEMBRANE OXYGENATION IN AN ADULT WITH SICKLE CELL DISEASE AND SEVERE ACUTE CHEST SYNDROME

Raquel Torres, Adriana Iriarte, David Berbel, Alba Bergas, Antoni Riera-Mestre, Xavier Corbella
Hospital Universitari de Bellvitge, Hospitalet De Llobregat, Spain

Introduction

Acute chest syndrome (ACS) is defined as appearance of new radiographic pulmonary infiltrate along with fever, respiratory symptoms and hypoxia in patients with sickle cell disease (SCD).

Case description

A 22-year-old African-American man with heterozygous SCD was admitted to our hospital because of a sudden onset of fever, chest pain and severe acute respiratory failure. Chest radiography showed a new pulmonary infiltrate and laboratory test revealed intravascular hemolysis. Blood cultures were obtained and empiric antibiotic therapy was initiated. His condition quickly worsened, requiring endotracheal intubation and mechanical ventilation. Echocardiography showed pulmonary hypertension and severe right ventricle dysfunction. Pulmonary thromboembolism was suspected and fibrinolytic therapy was administered.

The patient's cardiopulmonary status got worse and a new echocardiogram revealed severely depressed biventricular

function and persistence of pulmonary hypertension. A thoracic-abdominal CT scan was then performed, showing a small thrombus in subsegmental pulmonary artery and ischemic colitis. A diagnosis of ACS with pulmonary thrombus and vaso-occlusive crisis was made. Two red blood cell (RBC) exchange transfusions were performed, and hydroxyurea therapy was started. Despite intensive treatment, the patient persisted with cardiorespiratory compromise and veno-arterious extracorporeal membrane oxygenation (VA-ECMO) was installed during 10 days. The patient was discharged after 3 months.

Discussion

Almost half of SCD patients experience ACS, most of them with homozygous SCD. In such patients, main causes of ACS are pulmonary infection, fat embolism and pulmonary infarction. Pulmonary embolisms have been reported in patients with SCD related to hypercoagulable state. Clinical management includes pain treatment, hydration, antibiotic therapy, respiratory support and RBC exchange transfusion.

On the other hand, ECMO is used in patients with severe respiratory and cardiac failure not responding to conventional therapy. Venovenous ECMO for management of ACS complicating SCD has been described in pediatric patients; however, there is scarce available literature regarding the use of VA-ECMO in adults. Our case reports the successful therapy with VA-ECMO in an adult patient with SCD complicated by life threatening ACS.

#1474 - Case Report

DEADLY SPOT - ATYPICAL METASTATIC MELANOMA

Diogo João Silva¹, José Brito Silva², Ana Hipólito Reis¹, Joana Santos¹, Rui Môço¹

¹ ULSM-Hospital Pedro Hispano, Matosinhos, Porto, Portugal

² Instituto Português de Oncologia, Porto - IPO Porto, Porto, Portugal

Introduction

Melanoma constitutes one of the most aggressive cancers able to metastasize to multiple sites like lungs, liver, lymph nodes and bones. Regardless of the primary tumor size, melanoma cells have specific features, such as the high capacity to evade the immune system and specific mutational landscape that promote dissemination. Secondary hepatic malignancies are 18-40 times more common than primary tumors in Western countries, being the digestive tube the most common primary site and melanoma contributing to less than 1%.

Case description

An 82-year-old cognitively preserved woman, living alone in a low-income neighborhood, presented to the emergency department with one-year evolving constitutional syndrome, recent onset of right upper quadrant abdominal pain and scattered painless ecchymosis in the torso. Past history of a melanocytic nevus on the fifth finger classified as junctional nevus after biopsy in 2012, without vertical

progression and melanoma-like at dermoscopy in 2019. Mild cachexia, disseminated subcutaneous ecchymotic nodules, and painful nodular hepatomegaly were observed at presentation. Cervico-toraco-abdominal CT-scan documented an hepatic parenchyma with multiple nodular images, enlarged lombo-aortic and mesenteric lymph nodes. Biopsy of one hepatic nodule revealed a small cell malignant neoplasia positive for Melan A and HMB45 and negative for S100 and CAM5.2 which favored melanoma metastasis. Regarding performance status, comorbidities and disease progression, after multidisciplinary discussion it was decided to offer symptomatic palliative care. The patient evolved with hepatic insufficiency and encephalopathy, being oriented to a Palliative Care unit for end-of-life care.

Discussion

We present a rare case of multimetastatic melanoma, whose presentation at diagnosis was painful metastatic hepatomegaly with cutaneous dissemination. Skin metastases are a frequent event in the clinical course of malignant melanoma being classified as “satellitosis”, “in-transit” and “distant”. The incidence of malignant melanoma in Europe varies from 3-5/100 000/year in Mediterranean countries with a disparity in mortality-to-incidence ratio between Western and Eastern European countries. Suspicious lesions follow the “ABCD rule”: asymmetry, border irregularities, colour heterogeneity, dynamics. Recommendations for stage IV multimetastatic melanoma are still under discussion with multiple approaches to different molecular targets.

#1476 - Case Report

ACUTE KIDNEY INJURY AS THE FIRST SIGN OF MULTIPLE MYELOMA

Ângela S. Almeida, Anabela Carvalho, José Soeiro, Ussumane Embaló, Jorge Cotter

Hospital Senhora da Oliveira, Guimarães, Portugal

Introduction

Multiple myeloma belongs to a spectrum of diseases ranging from monoclonal gammopathy of unknown significance (MGUS) to plasma cell leukemia and it is characterized by a malignant proliferation of plasma cells derived from a single clone and a consequent overproduction of monoclonal protein (M component). Organ dysfunctions and symptoms are a product of the tumor and the host response to its products and includes renal failure (25-50% of all patients), normocytic normochromic anemia (approximately 80%), bone fracture or pain, hypercalcemia, proteinuria, among others. The diagnosis requires marrow plasmacytosis higher than 10%, M protein in serum and/or urine and myeloma related end organ damage. Treatment consists in systemic therapy to control the progression of myeloma and supportive care to prevent morbidity from the complications.

Case description

A 76-year-old male presented with 4-week history of dyspnea,

asthenia and loss of appetite. One week before the admission he was first observed by his family doctor who transferred him to our department after noticing acute kidney injury (creatinine 4.9mg/dL; usual creatinine: 0.57mg/dL). Hospital laboratory tests showed also normocytic normochromic anemia, and abdominal CT scan revealed enlarged kidneys consistent with medical nephropathy. Subsequent studies included new serum and urine assessment that detected an M component IgG/kappa in both samples, plus increased levels of β 2-microglobulin (7.9mg/L) and proteinuria (8.5g/24h). Bone marrow aspiration revealed 15.3% of plasma cells and complete skeletal radiography identified multiple lytic lesions. At this point, towards a multiple myeloma scenario, the patient was transferred to the hemato-oncology department to proceed with treatment and follow-up.

Discussion

The exact etiology of MM has not been determined yet, but it has been suggested that both genetic and environmental causes, and even chronic inflammation status, have a role in it. The single most powerful predictor of survival is β 2-microglobulin, which, along with serum levels of albumin, establishes the three-stage International Staging System (ISS) to predict survival. Adequate therapy may extend survival and improve quality of life, although the major causes of death remains progressive myeloma, sepsis, renal failure and therapy-related myelodysplasia.

#1489 - Case Report

COLD AS ICE - LARGE B CELL LYMPHOMA

Francisca Beires¹, Denise Magalhães¹, Carolina Tintim¹, Raquel Ortigão², Sara Dias¹, Joana Sofia Santos¹, Vasco Barreto¹, Nidia Oliveira¹

¹ Hospital Pedro Hispano, Matosinhos, Portugal

² IPO do Porto, Porto, Portugal

Introduction

Cold agglutinin disease (CAD) is an autoimmune haemolytic anemia, resulting from the binding of antibodies with an I/i antigen. The vast majority of cold agglutinins are IgM, although other subtypes have been reported. CAD can occur in the setting of an underlying viral infection, autoimmune disorder or lymphoid malignancy, being referred as secondary syndrome. CAD without any trigger is denominated primary.

Case description

We present a case of a man, aged 77, former smoker, with hypertension and dyslipidemia, who was admitted in the hospital with constitutional symptoms, being diagnosed with a retroperitoneal mass with artery involvement namely aortic, celiac, mesentery and renal. During the hospitalisation, he developed anemia, requiring multiple transfusions without significant improvement. Afterwards he underwent left orchidectomy and was discharged of the hospital. He maintained symptoms of asthenia and fatigue, returning back to the hospital one month after.

On admission, he was hemodynamically stable, pale and his sclerotics were icteric. Analysis showed a macrocytic, normochromic anemia with 4.9 g/dL. A broader analysis was performed showing a normal level of B12 vitamin and folate, an increased iron saturation, as well as lactate dehydrogenase (470 U/L), bilirubin 4.2 mg/dL, with an indirect dominance (2.6 mg/dL), diminished haptoglobin (<8 mg/dL) and normal transaminases. Coombs test was positive with IgM, C3c and C3d (3+) positive, reticulocyte count was 15% and the peripheral blood smear had anisocytosis, polychromasia and stomatocytes.

He started corticoid pulses and underwent a whole CT body scan with no other adenopathies, beside the mass with 17x16.5x10 cm and a nodule of the right adrenal gland of 2.5cm.

After a couple of days, the result of his orchidectomy arrived and he was diagnosed with large B cell lymphoma and started 1mg/kg corticoid, as well as cytoreductive chemotherapy with CVP, due to the size of his mass. Until this day, he underwent 3 cycles of CVP, with progressive improvement of the anemia.

The diagnosis of a haemolytic anemia due to cold antibodies was reached, most probably a cold agglutinin disease, although the titer of agglutinin was unavailable.

Discussion

CAD accounts for 15% of autoimmune haemolytic anemia with an estimated incidence of 1 in 10 million. 75% of CAD is associated with malignancy, predominantly lymphoplasmacytic lymphoma. This is a case of a rare CAD associated lymphoproliferative disease, namely large B cell lymphoma.

#1495 - Case Report

SYNCHRONOUS TUMORS: LUNG CANCER AND MULTIPLE MYELOMA

Andreia Machado Ribeiro, Carla Tonel, José Manuel Lourenço
Hospital Vila Franca de Xira, Vila Franca De Xira, Portugal

Introduction

Advances in oncology have led to an increasing survival rate with a risk of development of multiple primary malignant tumors. This term defines 2 or more concomitant malignancies with different histologies or origins; the incidence rate ranges between 0.4 and 21%. Synchronous tumors happen when the second neoplasm is diagnosed less than 6 months after the first one.

Case description

A 64-year-old man with history of hypertension, dyslipidemia, smoking and bipolar disorder, presented with decreased urine output. On physical examination he was lethargic, afebrile and hypotensive. Laboratory investigations showed hemoglobin 10.4 g/dL; leukocytosis 14200x10⁹/L; CRP 13.2 mg/dL and creatinine 2.1 mg/dL. He started amoxicillin/clavulanic acid due to sepsis with urinary starting point.

On the 2nd day of hospitalization, he presented left lower limb edema. Doppler ultrasound revealed deep venous thrombosis;

anticoagulation with Enoxaparin was initiated.

The complementary study showed immunoelectrophoresis and 24 hour urine compatible with monoclonal gammopathy of IgG lambda light chains. Bone biopsy revealed infiltration by well-differentiated plasma cells that occupied 75% of the hemopoietic marrow, and an adenocarcinoma suggestive of pulmonary origin. He performed a body CT scan which revealed a right neoplastic lesion involving the pulmonary artery and pulmonary bronchi; pulmonary thromboembolism of the right pulmonary artery; multiple adenopathies; bilateral solid nodules suspected of secondary lesions; mild bilateral pleural effusion; several osteolytic lesions in the vertebral bodies, scapula and sacrum, suspected of metastatic lesions.

Given the advanced stage of the disease, the patient was offered Palliative Care. There was progressive worsening of the general condition, and the patient died. Material for EGFR mutational study was sent for additional research due to the rarity of the case. The patient's daughter was referred to Oncology Pneumology.

Discussion

Multiple myeloma patients are at increased risk of developing other neoplasms, with incidence ranging from 5.5% to 8%. Solid tumors are more common than hematologic tumors.

The association between multiple myeloma and lung adenocarcinoma is extremely rare, with only a few cases described. There are no recommendations for treatment. The therapeutic plan should be individualized and discussed by multidisciplinary teams. Prognosis is poor, with very low survival rates, as evidenced in this case.

#1504 - Case Report

MYCOSIS FUNGOIDES: T-CELL NON-HODGKIN LYMPHOMA AS A RARE COMPLICATION

Carlos Candeias, Pedro Campelo, Ramiro Lopes, Ana Fortuna, Carlos Cabrita, António Moura, Ana Monteiro
Internal Medicine - Centro Hospitalar Universitário do Algarve, Faro, Portugal

Introduction

Mycosis fungoides (MF) is a form of T-cell lymphoma of the skin typically slowly progressive and chronic. The condition can pose a diagnostic challenge, mainly due to the atypical initial clinical presentation, and non-specific histopathological changes. The exact cause of mycosis fungoides is not known.

Case description

We report the case of a 69 year old female who was admitted to the Emergency Room (ER) due to progressive exanthema, pruritus and lymphadenopathy over a period of three months. The patient's medical history showed a hysterectomy several years ago (due to uterine myoma) and, most importantly, a mycosis fungoides diagnosis by skin biopsy since 2015 which was not followed up.

Physical examination revealed a non-febrile patient (37.5°C), with a pruritic and scaly cutaneous exanthema covering the whole body. She also had widespread lymphadenopathy, particularly in the inguinal regions where nodes measured above 5cm. Laboratory findings showed a leukocytosis (14000) with neutrophilia of 80% and an eosinophilia of 3.9, PCR 100 mg/dL and an LDH of 645 U/L. Other biochemistry results were in the normal range. The patient has a histopathology report of a skin biopsy made in 2015 after a dermatology appointment due to an erythematous skin lesion in her left armpit. Post-contrast CT of the chest, abdomen and pelvis showed multiple areas of lymphadenopathy and a positive Methicillin-resistant *Staphylococcus aureus* was grown in blood cultures for which eight-day course of flucloxacillin was commenced. Due to the possibility of nodal T lymphoma, a lymph node biopsy was performed that was compatible with T-cell non-Hodgkin lymphoma (T-cell NHLs) (CD3 +, CD5 +, CD20 -, CD10-). Over the next twenty days, the patient was treated with Ultraviolet B phototherapy, RAMET CADE and topic corticoids with no positive clinical response. Due to rapid clinical decline, chemotherapy was not initiated and the patient died at home three weeks later.

Discussion

The patient had no follow-up since the diagnosis of Mycosis fungoides in 2015, and only sought medical help in a later stage of the disease (lymph node involvement and extensive skin disease) which we know has a poorer prognosis. MF is incurable but the follow up is essential to the management of the disease not only to maximize periods of remission and stable disease but also to prevent disease progression and preserve quality of life. Treatment, therefore, is considered palliative for most patients.

#1525 - Medical Image

ACQUIRED ESOPHAGEAL-PULMONARY FISTULA IN A PATIENT WITH SYNCHRONOUS NEOPLASIA

Diana Adrião, Raul Neto, Sofia Florim, Marta Basto, Paula Castelões

Centro Hospitalar Vila Nova de Gaia/Espinho, Vila Nova De Gaia, Portugal

Clinical summary

A 56-year-old male patient with locally advanced hypopharyngeal and esophageal squamous-cell carcinoma was treated with induction chemotherapy followed by bioradiotherapy. He presented to the emergency department with acute dyspnea after a radiotherapy session. Clinical examination revealed severe cachexia and acute hypoxemic respiratory failure, with elevated inflammatory markers on laboratory tests.

Chest radiograph suggested a pulmonary cavitation and a computed tomography showed:

- Extensive cavitary lesion involving the apical and posterior segments of the right upper lobe;
- A fistulous communication between with the esophagus and lung parenchyma.

Due to extensive comorbidity, with pulmonary sepsis and severe malnutrition, it was decided not to undergo invasive procedures.

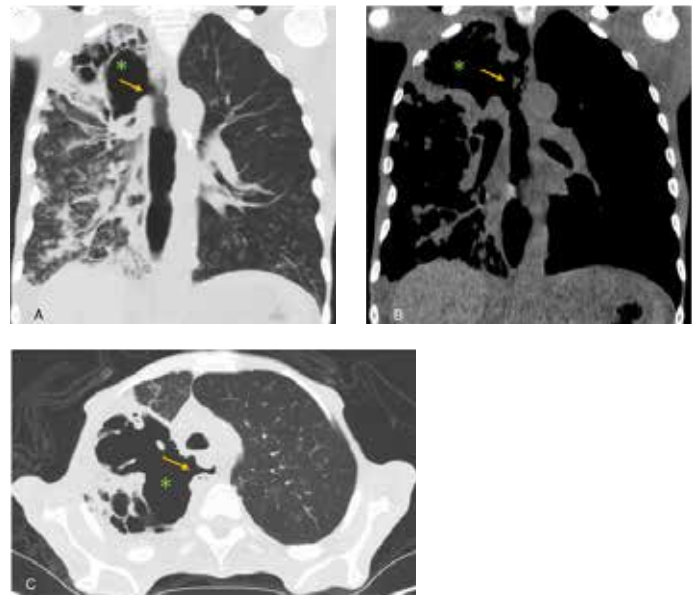


Figure #1525. Coronal (A, B) and Axial (C) CT scan shows a fistula tract between the right lateral wall of the esophagus (arrow) and the cavitated lung parenchyma (asterisk).

#1531 - Case Report

APLASTIC ANEMIA - ON THE PURPOSE OF A CLINICAL CASE

Ilídio Brandão, Marta Filipa Lemos Mendes, Filipa Rodrigues, Isabel Apolinário, Herlander Marques
Hospital de Braga, Braga, Portugal

Introduction

Aplastic anemia (AA) is a rare and potentially fatal disease that requires a detailed evaluation, being a diagnosis of exclusion. The diagnosis of AA is, generally, based by the association: pancytopenia, low reticulocyte count and hypocellular bone marrow (BM), in the absence of cellular dysplasia or BM fibrosis.

Case description

Female, 40 years old. No pathologies or relevant family history. Medicated with oral contraceptive. Patient went to the emergency service due to petechial lesions in the lower limbs (LL) with 2 days of evolution. She reported episode of epistaxis, spontaneous ecchymosis and menorrhagia for 3 months. Furthermore, LL edema and arthralgias of large and small joints with morning stiffness for 11 months. No constitutional symptoms and without recent drug intake. In the admission, had skin paleness and petechiae in LL. Analyzes: Hb 4g/dL (Macrocytic/Hyperchromic), 2300leukocytes, 27000 platelets; peripheral blood smear: rare schizocytes, without blasts; VitB12: 197 pg/mL, Fe kinetics and normal folic acid: reticulocytes 3.1%; EPO 652 mU/mL; ESR 123 mm/h; LDH 296 U/L, haptoglobin <8 mg/dL, negative Coomb test; protein electrophoresis, serum/urinary immunoglobulins,

B2 microglobulin within normal range, as well as renal function, hepatic, thyroid and coagulation factors. Negative viral serologies. Study of autoimmunity with complement consumption. Urinary sediment: 25-50 erythrocytes/field. TC scan and upper GI endoscopy without alterations; gastric biopsy with “chronic gastritis associated H.pylori”. The myelogram and bone biopsy showed moderate triangular linear hypoplasia without blasts and the immunophenotypic study of the medullary aspirate revealed BM suggestive of medullary aplasia. Flow cytometry was performed, which identified PNH clone in 38% neutrophils, 49% monocytes and 6% erythrocytes, The patient started therapy for H. pylori eradication and VitB12 supplementation; remained clinically and hemodynamically stable, with no need for transfusion support. After exclusion of Myelodysplasia, Acute Leukemia and secondary causes of Bone Marrow Failure, Idiopathic AA of intermediate risk was considered. The patient performed allogeneic transplantation, uneventfully.

Discussion

The differential diagnosis between myelodysplastic syndrome, PNH and acute hypoplastic leukemias is difficult. Furthermore, small PNH clones can be detected in 50% of AA patients, and PNH may represent an AA “continuum” several years after analytical recovery, requiring clinical surveillance.

#1536 - Medical Image

RETROAURICULAR MASS

Virginia Visconti, Eunice Oliveira, Adriana Watts, Ismenia Oliveira, Jose Lomelino Araujo, Fernando Goncalves
Hospital Beatriz Angelo, Loures, Portugal

Clinical summary

Lymph nodes, bones, lung, liver, and peritoneum are the most common sites of metastasis from urothelial carcinoma. Cutaneous metastases from primary genitourinary malignancies are rare and very few cases of skin metastasis from urothelial carcinoma have been reported in the past.

The authors present the case of an 82 year old man with history of stage IV urothelial carcinoma (lung metastasis), observed in the emergency room due to a retroauricular mass. Fine needle aspiration cytology was performed, confirming a cutaneous metastasis.

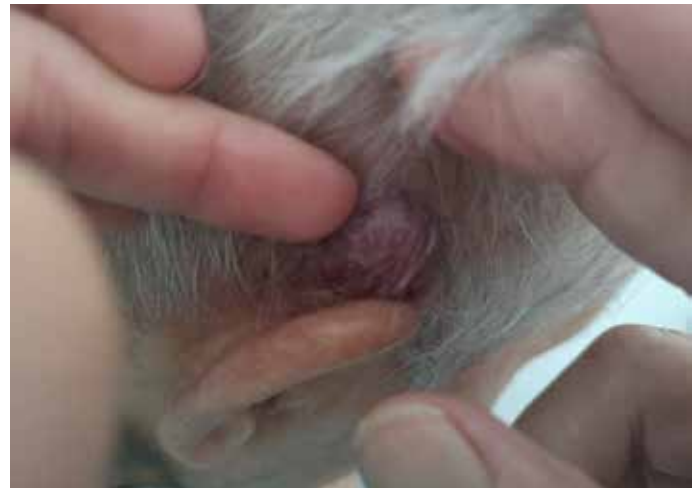

Figure #1536.

#1539 - Case Report

STEALTHY ADENOCARCINOMA – AN ATYPICAL PRESENTATION

José Brito-Da-Silva¹, Diogo J. Silva², Joana Dos Santos³, Ana Hipólito-Reis⁴, Rui Môço⁴

¹ Department of Medical Oncology, IPO-Porto, Porto, Portugal

² Department of Medical Oncology, Hospital Pedro Hispano, Matosinhos Local Health Unit, Matosinhos, Portugal

³ Department of Pathological Anatomy, Hospital Pedro Hispano, Matosinhos Local Health Unit, Matosinhos, Portugal

⁴ Department of Internal Medicine, Hospital Pedro Hispano, Matosinhos Local Health Unit, Matosinhos, Portugal

Introduction

The frequency of lung cancer continues to increase in current days, being a leading cause of cancer death among both women and men. In most cases, patients with lung cancer present with advanced disease; pleural involvement (often accompanied by a malignant pleural effusion) confers a poor survival. Clinically, these effusions can cause dyspnea and cough, but approximately one-fourth of patients with pleural metastases are asymptomatic. Radiographically, findings are nonspecific in order to distinguish metastatic carcinoma and pleural primary disease.

Case description

A 57-year-old woman, with 1-year evolving constitutional symptoms but active (she worked for almost 40 years with exposure to asbesthos), presented to the hospital after a rib cage trauma. The chest x-ray showed no fractures but rather a “white lung” on the contralateral side (left). CT scan showed a loculated pleural effusion with ipsilateral pleural thickening. A thoracocentesis was performed, being the effusion compatible with an exudate. She was admitted for further evaluation.

A thoraco-abdomino-pelvic-CT scan was performed, showing a diffuse nodular pleural thickening on the left lung, with pulmonary nodules and multiple adenopathies (subpleural, diaphragmatic and axillary). Effusion cytology was negative for malignant cells on two

different samples, and a first pleural transthoracic biopsy showed representation of an adenocarcinoma but with an inconclusive immunohistochemical study. Bronchofibroscope showed no endoluminal lesions but signs of extrinsic compression of the left inferior lobar bronchus were present. A second pleural biopsy was performed: immunohistochemical findings (negativity for calretinin, CK5/6, CK20 and CDX-2; positivity for CK7, Napsin-A and TTF-1) were compatible with a mucin-secreting pulmonary adenocarcinoma. The patient started folic acid supplementation in order to begin systemic treatment briefly.

Discussion

In metastatic non-small cell lung cancer, treatment strategies must take multiple factors into account; nonetheless, systemic therapy should be offered to all stage IV patients with good performance status. Therapeutic decisions should be discussed within a multidisciplinary team.

On a final note, it is essential to maintain a critical clinical reasoning, having in mind that obvious presentations of a particular disease may be atypical manifestations of a different pathology.

#1540 - Case Report

WHEN A COMMON CLINICAL SIGN BECOMES A RARE DIAGNOSIS

Alexandra Briosá, Andre Esteves, Despina Argyropoulou, Ana Broa

Hospital Garcia de Orta, Lisboa, Portugal

Introduction

Ascites is considered a frequent cause of admission to the emergency department. Although liver cirrhosis is the main cause of ascites, in rare cases, this may be secondary to malignancy, such as ovary, stomach, pancreas and colon, or may even have a primary etiology.

Case description

69 years old male, retired from commercial activity, with a known personal history of hypertension, slight consumption of alcoholic beverages. No active smoking habits or history of known environmental exposure.

He came to medical attention due to complaints of abdominal volume increase associated with weight loss (7 kg) and dyspepsia, with two months of evolution.

At admission he was hemodynamically stable with no fever or palpable adenomegalies. A presence of a large non-tense ascites was evident.

The patient brought an ambulatory transthoracic echocardiogram and colonoscopy that showed no alterations. A thoraco-abdominopelvic CT was performed that revealed not only massive ascites, but also an important peritoneal thickness. Blood samples showed the presence of mild a hypochromic/microcytic anemia (hb 10.8 g/dL) and thrombocytosis (platelets 823,000). Viral serologies, autoimmunity panel and tumor markers were all negative.

A diagnostic paracentesis was performed. The cytological examination of the abdominal liquid was suggestive (but not diagnostic) of neoplastic etiology, emphasizing the presence of mesothelial cells. Upper digestive endoscopy excluded the presence of gastric neoplasia. Subsequently, abdominal magnetic resonance imaging allowed the exclusion of other primary foci, as well as the presence of liver lesions.

Given the high suspicion of primary peritoneal neoplasm, an ultrasound guided peritoneal biopsy was performed, which confirmed the diagnosis of epithelioid malignant mesothelioma. The patient was referred to oncology consultation.

Discussion

Primary malignant mesothelioma is a rare neoplasm originating in mesothelial cells, especially pleura and peritoneum. The diagnosis has been linked to toxic exposure to industrial pollutants, especially asbestos. Its insidious course and non-specific clinical presentation often lead to a late diagnosis, conferring a reserved prognosis.

#1541 - Case Report

GASTROINTESTINAL STROMAL TUMOUR AS A CAUSE OF PULMONARY THROMBOEMBOLISM

Renato Silva, Carolina Sepulveda, Margarida Afonso, Alexandra Pupo, Vander Sabino, Nuno Melo, Filipa Lucas

Cascais Hospital, Lisbon, Portugal

Introduction

Cancer is a major risk factor for the development of venous thromboembolism (VTE), however, the direct association between a gastrointestinal stromal tumour (GIST) and VTE remains unclear.

Case description

We report the case of a 57-year-old male patient who presented with a one month history of weakness and shortness of breath on exertion associated with unquantified weight loss and skin pallor. The patient had stopped smoking 15 years ago and he had no recent history of immobilization. He was admitted to the hospital to study his severe anaemia (hemoglobin 5.4 g/dL). Upper endoscopy was performed, showing an enlarged lesion with 2 erosions localized in the gastric body. Endoscopic ultrasound revealed a stromal tumor with regular borders. The lesion was biopsied and the anatomopathologic study of the sample confirmed a GIST. A chest computed tomography (CT) scan revealed bilateral filling defects consistent with pulmonary thromboembolism (PTE). An abdomen-pelvic CT scan was also performed to evaluate the extension of the tumor, showing a solid 43 mm lesion in the gastric body, with no perigastric adenopathies or metastasis. Autoimmunity and thrombophilia tests were negative. During hospital admission he was treated with weight-adjusted enoxaparin but after discharge he was treated with a direct oral anticoagulant (DOAC) for 40 days while waiting for surgery. Despite the risk, the partial gastrectomy was performed with good outcome. Eight days after surgery,

treatment with enoxaparin was discontinued and a DOAC was restarted. The complete evaluation of the patient did not reveal any associated risk factors for thrombosis, other than GIST, suggesting it was the primary cause. After a 3 months follow-up he had no evidence of recurrence of both the GIST and PTE.

Discussion

The most common clinical manifestations of GIST are gastrointestinal (GI) bleeding and a persistent or recurrent abdominal pain, but there is a significant percentage of GIST that remain asymptomatic and are discovered incidentally. The coexistence of PTE needing anticoagulation and bleeding gastric GIST requiring resection presented a management issue. Although, it is recommended that low-molecular-weight heparin be used over vitamin K antagonists or DOACs to prevent VTE recurrence in patients with cancer in several guidelines, new data does suggest that DOACs may be a reasonable alternative despite its risk for bleeding in patients with GI cancer.

#1544 - Medical Image

CUTANEOUS INVOLVEMENT IN ANGIOIMMUNOBLASTIC T-CELL LYMPHOMA

Catarina Ribeiro Pereira

Hospital Prof. Doutor Fernando de Fonseca, EPE, Lisboa, Portugal

Clinical summary

A 56-year-old woman presented with a pruriginous maculopapular skin rash on the trunk and limbs as well as low grade fever. On clinical evaluation, painless lymphadenopathies were found and further work-up was done. A biopsy was performed and histopathology revealed Angioimmunoblastic T-cell lymphoma.

In this rare and aggressive lymphoma, skin manifestations with non-specific histopathological features can precede other clinical manifestations by several weeks. Three weeks after presentation she developed a daily vespertine fever, night sweats and started treatment with good haematological response. This case demonstrates that inclusion of lymphoproliferative diseases in the differential diagnosis of nonspecific maculopapular dermatitis can have important prognostic implications.

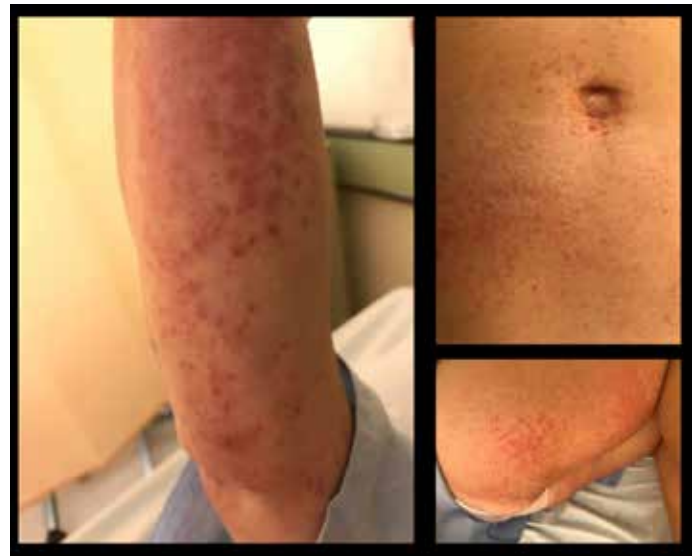

Figure #1544.

#1548 - Case Report

WHAT IS BEHIND ANEMIA?

Ana Carlota Vida, Cláudia Lemos, Graça Dias, Maria Da Luz Brazão
Hospital Central do Funchal, Madeira, Portugal

Introduction

Megaloblastic anemia is characterized by macrocytosis and is associated with morphological alterations in erythroid precursors. Its pathogenesis is more frequently associated with vitamin B12 (B12) and folate deficiency which can be caused by poor dietary habits, gastric or intestinal mal-absorption, hemolytic anemia and others.

Case description

We report a case of a male, 21 years old, with history of epilepsy, medicated with Valproate, who went to the ER presenting with dizziness and epigastric pain. At observation, he was pale and tachycardic. His analytic results revealed: macrocytic anemia (Hb 5.0 g/dL, Hematocrit 14.7%, VCM 110.5 fL, RDW 18.8%) and thrombocytopenia (80,000/ μ L). PBS: neutrophil hypersegmentation, anisopoikilocytosis, presence of macrovalocytes and dacryocytes; Iron 22 μ g/dL, Ferritin 690 ng/mL, Folate <0.60 ng/mL and B12 115 pg/mL.

His dietary habits were very unbalanced, with poor ingestion of animal protein. He had no history of macroscopic blood loss. This was interpreted as megaloblastic anemia caused by B12 and folate deficiency. He had a blood transfusion, initiated supplementation and was admitted to hospital.

From his auto-immune study we highlight: Anti-parietal gastric cells, Anti-intrinsic factor, Anti-neutrophil cytoplasmic antibody, ASCA IgG and IgA, Anti-nuclear and Anti-dsDNA antibodies, Coombs direct test and serologies (HBV, HCV, HIV) were all negative; thyroid function tests were normal.

His abdominal ultrasound and his upper digestive endoscopy were normal; however, his duodenal biopsies exhibited alterations

suggestive of chronic gastritis caused by a *Helicobacter pylori* (HP) infection.

He started HP eradication, and was scheduled for follow-up, while maintaining a daily folate and iron supplementation and biweekly with cyanocobalamin. His follow-up exams displayed a positive evolution (Hb 12 g/dL, VCM 96.8 fL, folate >20 ng/mL, B12 115pg/mL, Iron 38 µg/dL, ferritin 338 ng/mL).

Discussion

In this case, we presented a young male with multifactorial anemia, in the context of B12 and folate deficiency caused by a poor diet and chronic gastritis motivated by HP. Valproate is also a possible contributor for the deficiency of Folate, as this association is described in literature. Despite being more frequent at this age, no auto-immune diseases were found. With this case we intend to demonstrate the importance of investigating anemia, due to its many causes and the need to identify them so as to proceed to their treatment.

#1558 - Case Report

SKIN MANIFESTATION, WARNING OF SEVERE SYSTEMIC DISEASE

Jesennia Jesenni Chinchilla, Mohsen Rostami

Hospital de Santarém, Santarém, Portugal

Introduction

A favorable diagnosis depends essentially on anamnesis and a thorough physical examination. A cutaneous finding may mobilize an investigation to detect other systemic diseases, which should be identified by most physicians.

Case description

M.P.P. 82 years old, male, Caucasian, rural worker, retired. AP: Negative, does not perform usual medication. Consultation with the emergency department for a non-pruritic erythematous cutaneous lesion in the anterior and posterior thorax of 2 weeks of evolution; consulted the attending physician and was given deflazacort 6 mg twice daily, and bilastine. No improvement and consultation again with generalized tiredness in the last 3 days and feeling of loss of muscle strength in the lower limbs. At physical examination without adenopathies, without organomegaly, without neurological or bony alterations.

Reviews: Hb 11.0 g / dL, Hto 32.3%, VCM 102.9 fL, Leukocytes $4.26 \times 10^9 / L$, Neutrophils $2.81 \times 10^9 / L$, Blasts 0.77 x Platelets 51000, VPM 12.7 fL

Scrubbing peripheral blood:

Erythrocyte series: anisocytosis and poikilocytosis marked with some dacryocytes, no hypochromia. No erythrocyte inclusions are observed but the presence of erythroblasts is emphasized. Granulocytic series: Left deviation is observed, with signs of dysgranulopoiesis. It is observed a population of cells corresponding to blast cells, with high nucleus/cytoplasm ratio, heterochromatin presence of nucleoli, marked cytoplasmic

basophilia, irregular nuclear and cytoplasmic contour, without granulation (Lymphoma cells?). Platelets: platelet anisocytosis and giant platelets. Patient was hospitalized for complementary studies,

Discussion

Sézary syndrome consists of a type of cutaneous T-cell lymphoma. On the whole, T-LCC are not as rare as previously thought, with their frequency being at least identical to that of Hodgkin's disease.

It is characterized by exfoliative erythroderma, intense pruritus, polyadenopathy and presence in the peripheral blood and cutaneous infiltrate of atypical mononuclear cells. He is suspicious of this syndrome in cases of persistent skin lesions that do not heal with the usual treatment. Clinically, S.S. can be confused with other diseases in which erythroderma occurs, such as psoriasis and seborrheic dermis.

#1573 - Case Report

TOW RARE PARANEOPLASTIC SYNDROMES THAT ALLOWED EARLY CANCER DIAGNOSIS

Ana Simas, Ricardo Veloso, Maria Menezes, Ana Silveira, Juvenal Morais, Mariela Rodrigues, Joana Mota, Rui Suzano, Fátima Pinto, António Goulart

Hospital da Horta, E.P.E., Horta, Portugal

Introduction

Oposoclonus myoclonus syndrome (OMS) is little known in adults but when occurs we need to think that is possible that the patient has an underlying neoplasm. The presence of antibodies anti-RI at cerebrospinal fluid confirms the diagnosis of OMS.

Dermatomyositis is a systemic inflammatory myopathy that affects mostly the striated muscle and manifests by muscular weakness and typical skin changes. This myopathy is associated to a high incidence of neoplasm therefore, these patients need a tight and regular vigilance.

The authors consider that these cases should be exposed by its rarity and to a better knowledge and characterization of these entities.

Case description

A 49-years-old female was sent to medical consultation with a sudden clinical picture of vision and walk changes. The physical examination revealed unintended multidirectional ocular movements with facial, axial and appendicular myoclonia and ataxia. Initial complementary exams (turaco-abdominal-pelvic computerized tomography, thyroid and breast ultrasounds, mammography, and cranial magnetic resonance) didn't reveal any alteration to justify these symptoms. Cerebrospinal fluid had positive antibodies anti-RI. Later on, was requested positron emission tomography that revealed a solid retroareolar nodular lesion at the left breast and anomalous catchment at the left axillar apex that suggested breast cancer with ganglionar

metastasization. The breast magnetic resonance and biopsy confirmed a ductal invasive cancer ganglionar metastasization. The symptoms improved five months after the treatment begun.

A 37-years-old male was sent to medical consultation with clinical picture of palpebral edema and purpura erythema mostly periorbital and facial with three months of evolution, with generalized myalgias, muscular weakness and occasional dysphagia. The physical examination revealed palpebral edema, purpura erythema in periorbital and nasal areas, in the neck, upper body, shoulders and elbows. The chest computerized tomography showed a solid mass at the right lung apex, the biopsy and histology confirmed lung cancer with possibility of curable treatment.

Discussion

These case reports show the importance of the knowledge about the paraneoplastic syndromes and its recognition. As well as the relevance of deeply investigating possible neoplasms in order to achieve better diagnosis.

#1574 - Case Report

WHAT HIDES BEHIND AN UNSTABLE ANGINA

Viktor Malyarchuk, Carolina Pereira, Diana Carvalho, Daniela Meireles, Jorge Henriques

Centro Hospitalar do Baixo Vouga, Aveiro, Portugal

Introduction

Multiple Myeloma is the second most frequent hematological malignancy, although it only represents around 1% of all cancers. It is characterized by the proliferation of monoclonal immunoglobulin producing plasma cells. The symptoms and signs are related to the plasma cell infiltration of the bone or renal lesion related to the excess of free circulating light chain, resulting usually in anemia, bone pain, elevation of serum creatinine or hypercalcemia.

Case description

A 74 years old woman, with a history of normocytic and normochromic anemia of unknown etiology with a recent normal endoscopic study, ischemic cardiomyopathy disease and hypertension, type 2 diabetes treated with insulin, dyslipidemia and overweight. The patient presented to the emergency department with a chest pain, which she describes as a heaviness that radiates to the left arm and back, which lasted more than 10 minutes and alleviated with sublingual nitroglycerine, as well as dyspnea and nocturnal paroxysmal dyspnea. At admission she was hemodynamically stable, without pallor, well hydrated and had basal crackles. Rest of the physical examination was normal. Analytically she had anemia with hemoglobin of 7.5 g/dL, myocardial necrosis markers were normal. After a transfusion of 1 unit of red blood cell and stabilization of her clinical condition, she was transferred to the internal medicine unit. The further evaluation showed maintained anemia with hemoglobin of 9.5g/dL, Fe²⁺ 29 ug/dL, transferrin saturation of 12.61%, ferritin 90

ng/mL, EP monoclonal band at the beta2 region of 3.01g/dL. Immunological study: IgA 4950 mg/dL; light kappa chains 207 mg/dL, kappa/lambda coefficient 4.93; Beta-2 microglobulin 5790 ng/mL. Urinary EP was normal. Bone marrow: 12.6% clonal plasma cells IgA/K. Establishing a diagnosis of Multiple Myeloma IgA/K. Her skeletal X-ray showed lytic lesions of the skull, humerus, and right iliac. She began three-drug regimen of bortezomib-melphalan-prednisolone.

Discussion

We present this case as an example of how important a simple analytical parameter such as EP can be of extreme importance in the evaluation of anemia, especially in older adults, and can lead to a fast diagnosis of a disease, that if delayed can have a very negative impact in its prognosis.

#1576 - Medical Image

GASTROINTESTINAL STROMAL TUMOR

Ana Simas, Ricardo Veloso, Maria Menezes, Ana Silveira, Juvenal Morais, Mariela Rodrigues, Joana Mota, Fátima Pinto, António Goulart

Hospital da Horta, E.P.E., Horta, Portugal

Clinical summary

A 53-years-old female without relevant personal antecedents was admitted at emergency with a subacute clinical picture of asthenia, weight loss, vomits, anorexia and abdominal pain at the right side. The physical examination showed a globose abdomen with pain at palpation of the right side and apparent abdominal mass. The abdominal computerized tomography revealed a large mass that occupied all the anterior quadrants of the abdomen, with mass effect. The biopsy revealed a gastrointestinal stromal tumor.

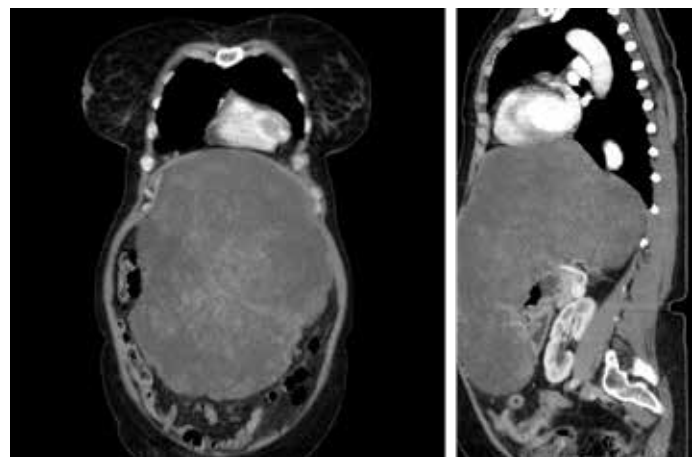


Figure #1576. Computed tomography of the gastrointestinal stromal tumor.

#1577 - Case Report

PRECORDIAL PAIN AS A PRESENTING SYMPTOM OF THYMOMA

Ana De Matos Valadas, Tiago Sepúlveda Santos, Inês Sf Silva, Maria Leonor Araújo Carvalho
Centro Hospitalar Lisboa Norte, Lisboa, Portugal

Introduction

Thymoma is a rare tumor, corresponding to 20% of the mediastinum neoplasms. Most occur in patients between 40 and 60 years of age, with a similar incidence in men and women.

Case description

We present the case of a 45-year-old female patient with a past medical history of arterial hypertension and anemia in the context of blood loss due to uterine leiomyoma. She was admitted at the emergency department for a three-month course of precordial pain with bilaterally shoulder irradiation, increasing in supine position and with exertion, with associated palpitations. She denied dyspnoea, lower limb oedema, fever, myalgias, nocturnal sweating and weight loss. Clinical examination revealed tachycardia and absence of pain on palpation of the chest. Laboratorial tests showed Hb 9.2 g/dL, leukocytosis 12,370 cells/ml, thrombocytosis 452,000 cells/ml, CRP 25 mg/dL, troponin T 4 ng/dL and d-dimers 2,31 µg/ml. Chest X-ray showed mediastinum enlargement, cardiomegaly and deletion of the right cost-phrenic angle. Electrocardiogram with tachycardia (HR 122 cpm) and PR segment depression in DI. Angio-CT revealed a 23mm thick pericardial effusion in the right anterolateral topography, with thickening and enhancement of the pericardial leaflets, suggestive of pericarditis. In addition, it showed a right paracardiac mass with 4x3 cm with soft tissue density, lobulated contours and cleavage plane with the pericardium and adjacent structures. The patient was admitted in Internal Medicine ward, having received ceftriaxone and metronidazole (for possible bacterial pericarditis) and indomethacin, with negative microbiological results and clinical improvement. She performed an echocardiogram showing a non-dilated left ventricle with no changes in segmental contractility and with preserved ejection fraction (60-65%), with moderate circumferential pericardial effusion. She underwent thoracoscopy with total removal of the mass. Histologically it was compatible with a thymoma B1 with areas of thymoma B2, which infiltrated the capsule and adjacent adipose tissue, without angioinvasion. Pericardial biopsy revealed mild fibrinopurulent inflammation, with no neoplastic tissue. Subsequent to the intervention the patient presented symptomatic improvement.

Discussion

This case report intends to underline the importance of the differential diagnosis in the initial approach of pre-cordial pain, mimicking other pathologies that raise some diagnostic doubt, namely acute coronary syndrome and pulmonary thromboembolism.

#1579 - Abstract

CANCER ADMISSIONS IN AN INTERNAL MEDICINE WARD

Salvador Morais Sarmiento, Miguel Sousa Leite, Hugo Inácio, Ana Brito, Daniela Marto, Andreia Amaral, Sofia Mateus, Dina Pita, Marta Moitinho, Catarina Salvado

Centro Hospitalar e Universitário de Lisboa Central, Hospital de Santo António dos Capuchos, Lisbon, Portugal

Background

Cancer is one of the leading causes of death in the world. As it affects an increasingly older population with multiple comorbidities, it is a main issue in the medical wards. In order to understand the particularities and susceptibilities of patients with cancer, we aimed to describe the cases of solid organ malignant neoplasms admitted in an internal medicine inpatient service.

Methods

We reviewed the medical records of all the subjects admitted in an internal medicine ward with 30 beds over the course of one year. The following criteria were applied to define the target population: patients suffering from active, malignant, solid organ neoplasms, present on admission or newly diagnosed (readmissions were also considered for statistical purposes). Exclusion criteria included benign or hematologic neoplasms, neoplasms in complete remission, and masses without a definitive diagnosis. We collected data on patient demographics, tumor characteristics, causes of admission, and the outcome of the hospital stay.

Results

786 admissions were analyzed, 13% of which fulfilled the inclusion criteria (n=100). The medium age of this group was 77 years old and 89% were female (the bulk of the beds in this ward were reserved for female patients). The most common types of neoplasms were gastrointestinal (35%) and breast cancer (16%). In 58% of the cases, the neoplasms were already metastasized. The majority of these patients were admitted through the emergency department due to infectious complications (35%) or refractory symptoms (32%). The hospitalization period was longer than in the general population. 62% of the subjects were already in palliative phase and 52% had an intervention of the palliative care team. The mortality rate was higher than in rest of the population (17% versus 9%).

Conclusion

The described data suggest that the internal medical ward is widely used for symptom control and terminal care in advanced cancer patients. Admissions are often lengthy and unscheduled, resulting in patients' death or palliative care referral in about half of the cases. The impact of cancer care imposes a reflection on the management of these patients, namely concerning the skills required by the medical teams (both in the infirmary and in the emergency department) and the articulation with the palliative

care units, in order to provide a dignified answer to the problems that arise in the end stages of the disease.

#1581 - Case Report

WARM AGGLUTININ AUTOIMMUNE HAEMOLYTIC ANAEMIA IN A 62 YEARS OLD MAN: A CASE REPORT

Ricardo Gomes, Isabel De La Cal Caballero, Ana Patrícia Gomes, José Proença, Leopoldina Vicente
Internal Medicine Service - Centro Hospitalar Universitário Cova da Beira, Covilhã, Portugal

Introduction

Haemolytic anaemia is defined as a decrease in circulating red blood cells due to their pre-mature destruction by intrinsic or extrinsic processes that can be inherited and acquired conditions, acute and chronic processes, and mild to potentially life-threatening severity. Autoimmune haemolytic anaemia (AIHA) signs and symptoms are nonspecific and common to all types of anaemia. The clinical syndrome seen with AIHA of the warm-antibody type varies greatly with the amount and effectiveness of the causative antibody.

Case description

A 62 years old male reached the emergency service complaining of asthenia, dyspnoea on exertion, dry cough and dizziness for about 2 weeks. He referred episodes of brownish urine without dysuria, fever or other complaints. No history of blood transfusions. He presented skin paleness, jaundice and the blood tests with Hb: 8.0 g/dL Htc 22% Mild polychromasia and spherocytosis, LDH: 1030 IU/L Platelets 166,000. Total bilirubin 3.2 mg/dL (indirect: 2.57). Normal urine II test. He was hospitalized and after 48h presented Hb 6.8 g/dL without blood losses. We began prednisolone 60 mg/day after collecting serological tests. Abdominal echography found mild hepatomegaly (NASH). Absent biliary pathology. Spleen 14 cm long. The blood tests were negative for virus and bacteria, but revealed complement C3 134 mg/dL, C4 2mg/dL, haptoglobin <10mg/dL. Direct antiglobulin test (DAT) positive (IgM +; C3c+, C3d+). Cryoglobulins, paroxysmal nocturnal haemoglobinuria, vasculitis, ANAs, ANCA and antiphospholipid studies were negative. Thyroid function, erythrocyte sedimentation rate, serum immunoelectrophoresis and immunofixation were normal. Myelogram showed erythroid hyperplasia. After 3 days with oral corticoids, due to aggravating anaemia (Hb 6.2 g/dL LDH 1708) we opted for a dose increase to 100 mg/day. At leave, after 19 days of oral corticoids the patient presented Hb: 9.7 g/dL with a good clinical and analytical recovery.

Discussion

Laboratory findings indicating haemolysis include increased indirect bilirubin, LDH and decreased haptoglobin. The diagnosis of warm agglutinin AIHA is based upon detection of antibody and/or complement components, usually by the direct antiglobulin

test. Treatment was instituted with oral glucocorticoids, first line agents and we opted for an increase to 100 mg/day because we considered the maximum of 1.5 mg/kg/day. We also used low doses of folate once chronic haemolysis can lead to folate deficiency.

#1596 - Abstract

CHARACTERISTICS OF THE ADMITTED POPULATION OF CANCER PATIENTS IN GREECE AND REASON OF THEIR ADMISSIONS : A SINGLE INSTITUTION EXPERIENCE

Aikaterini Aravantinou Fatorou, Despoina Moschou, Olga Benopoulou, Dimitris Ziogas, Spyridon Bouros, Panagiotis Diamantopoulos, Amalia Anastasopoulou, Panagiotis Kouzidis, Irene Eliadi, Frosso Konstantinou, Helen Gogas, Michael Samarkos
First Department of Internal Medicine, Laikon General Hospital, Medical School, National and Kapodistrian University of Athens, Greece., Athens, Greece

Background

Cancer is among the leading causes of morbidity and mortality. As a result, it places a heavy burden on Health Systems. General Hospitals in Greece receive a comparatively large burden, due to lack of palliative care institutions. We have studied the prevalence and characteristics of hospitalizations of cancer in an Academic Internal Medicine Department.

Methods

We have conducted a prospective cohort study in the 1st Department of Internal Medicine, an Academic Department of Laikon General Hospital, from 1 March 2018 to 28 February 2019. We have included all patients with an ICD10 primary admission code of solid tumor. Patients with hematological malignancies were not included. We have recorded patients' characteristics, the reason and the type of admission, type of cancer treatment during hospitalization, and outcome. Two independent reviewers validated the data. The categorical variables are presented as proportions and the 95% CIs were estimated by the modified Wald method.

Results

Patients with any type of solid malignancy represented 14.97% (95%CI: 13.34-16.76) of admissions, in accordance with our previously published data. During the study period, we have recorded 344 admissions of 250 individual patients. There were 57 patients (16.57%, 95%CI: 13.00%-20.88%) who were admitted more than once. Melanoma was the most commonly detected (34.88%, 95%CI: 30.04%-40.06%), followed by breast cancer (13.37%, 95%CI: 10.15%-17.40%), and pancreatic cancer (7.8%, 95%CI: 5.41%-11.22%). Cancer patients were admitted for palliative care in 29.94% of admissions (95%CI: 25.34%-34.99) while 20.35% of them (95%CI: 16.42%-24.93%) died during hospitalization. The leading reason for admission was the presence

of complications either by cancer (61.92%, 95%CI:56.68%-66.89%) or by administered anticancer therapy (14.8%, 95%CI:11.44%-18.99%). 28.49% of hospitalized patients (95%CI: 23.97%-33.48%) underwent at least one invasive procedure. Admission was characterized urgent in 83.72% (95%CI: 79.43%-87.26%) of cases.

Conclusion

Cancer patients represent a large percentage of admissions in an Internal Medicine Department. Although cancer patients need to be hospitalized in Medical Departments for treatment or management of complications, almost 30% of hospitalization in our Department were for palliative care. Lack of palliative care institutions places an extra burden in Internal Medicine Departments. Establishment of such institutions is necessary for the appropriate care of cancer patients.

#1597 - Case Report

HEMOLYTIC ANEMIA AS A WARNING SIGN OF GASTROINTESTINAL NEOPLASIA

Juliana Chen Xu, Dolores Vazquez, Vera Seara, Gonçalo R. Mesquita, Angela Coelho, Gert-Jan Van Der Heijden, Teresa Pinto CHPVVC, Póvoa De Varzim, Portugal

Introduction

Malignant neoplasia have seldom paraneoplastic syndrome displays, affecting endocrine, neurological, mucocutaneous and/or hematological systems.

Acquired premature red blood cell (RBC) destruction in a previously healthy patient, will analytically demonstrate increase reticulocyte count and index, specially in the beginning, increased bilirubin and lactate dehydrogenase (LDH), decreased haptoglobin and anisocytosis.

Case description

85-year-old man. With history of benign prostatic hyperplasia, atrial fibrillation, hypertension, dyslipidemia and cholangitis.

Patient was taken to the emergency department due to syncope while seated at breakfast, with spontaneous recovery, without head injury. On examination, patient had one measurement of low arterial tension.

Analytical alterations were exhibited: hemoglobin (Hb) 6.2 g/dL, mean corpuscular volume 116.8 fL, RBC distribution width 20.0%, reticulocyte count 15.63% and index 6.81%, potassium 5.3 mmol/L, LDH 1386 U/L, total bilirubin 3.82 mg/dL, conjugated bilirubin 0.30 mg/dL, haptoglobin <10 mg/dL, C-reactive protein 4.79 mg/dL, positive direct (DAT) and indirect Coombs test, and peripheral blood smear with marked anisocytosis and polychromasia. The DAT showed a 4+ reaction with monospecific anti-IgG and it identified a probable autoantibody "e" that might explain the RBC hemolysis. Specific blood bag with the least incompatibility was made available in case of need.

Patient initiated corticosteroids and was hospitalized.

Immunologically, it presented rheumatoid factor of 17.50 IU/gL and immunoglobulin A with 501 mg/dL. Serologies presented previous immunization against EBV and CMV. On abdominal echography, there were 4 hyperechogenic hepatic nodular lesions and on thoraco-abdomino-pelvic CT, there were 8 hepatic hypodense nodules sizing from 10-40 mm of probable secondary nature and a heterogeneous spiculated lesion in the center of the mesentery with 25x26 mm and suspected to be a neoplastic lesion. Biopsy demonstrated epithelial phenotype neoplasia, not otherwise specified. After stabilization, the patient was discharged with Internal Medicine and Palliative Care consultations.

Discussion

We aim to revise the paraneoplastic syndrome presentations, more specifically hemolytic anemia, its diagnostic tools and typing characteristics, in order to provide the most suitable treatment. This case allowed us to understand the delayed therapeutic effect of corticosteroids, taking at least 14 days to demonstrate results when facing critical Hb levels.

#1605 - Case Report

PRIAPISM – CASE REPORT OF A SIDE EFFECT

Joana Liz Pimenta¹, Nuno Dias², Patricia Chow Liu¹, Emanuel Cadavez¹, Silvia Duarte¹, Ines Grilo¹, Katia Ladeira¹, Rosa Gomes¹, Miguel Barbosa¹

¹ Centro Hospitalar de Trás-os-Montes e Alto Douro, Vila Real, Portugal

² Centro Hospitalar de S. João, Porto, Portugal

Introduction

Priapism as a result of Low-Molecular-Weight Heparin (LMWH) treatment has been proposed. The pathophysiology is not fully understood and there are very few published cases of LMWH-induced priapism. The implication of this event is such that it is an emergency. As more cancer patients would be under thromboprophylaxis or treatment, LMWH-induced priapism may increase in this population.

Case description

51-year-old male with a medical history of left frontal oligodendroglioma (diagnosed in 2005) and a deep vein thromboembolism in 2017. The patient was on current medication with tinzaparin 10,000 U daily, phenytoin 100 mg daily, levetiracetam 100 mg twice a day, prednisolone 10 mg daily and temozolomide 225 mg/day for 5 days, in cycles of 28/28 days. Without drug allergy or other relevant medical history.

At the end of May 2018, the patient was presented at the emergency department with a painful erection lasting 38 hours. He has not had phosphodiesterase inhibitors nor other drug outside his usual medication. At the physical exam he presented a penile erection, soft gland and no ischemic signs. The penile blood gas analysis revealed a pH of 6.7 and pO₂ of 3 mmHg, all other laboratory exams were within normal range. He went through emergent surgical treatment with lavage with saline solution

and phenylephrine, without success, followed by shunt (Al Ghorab). After surgery the erection was resolved without signs of compartment syndrome, but presented fibrosis of the cavernous body. At the moment patient is under surveillance and is aware of his irreversible clinical condition.

The only known risk factor for the ischemic priapism was the use of LMWH. Since this event the patient is no longer under LMWH and he had no other episodes of ischemic priapism.

Discussion

More study to understand pathophysiology is needed for better treatment and prevention. The prompt recognition of this uncommon side effect may decrease its morbidity.

#1609 - Case Report

FEVER OF UNKNOWN ORIGIN: A DIAGNOSIS AGAINST ALL ODDS

Maria Margarida Robalo, Emanuel Costa, Joana Sotto Mayor, Sofia Esperança, António Oliveira E Silva

Hospital de Braga, Braga, Portugal

Introduction

Fever of unknown origin (FUO) remains one of the most difficult challenges in medicine with a long list of causing disorders.

Case description

A 29-year-old man with a history of mesenteric thrombosis, non-lithiasic pancreatitis and autoimmune disease (hepatitis, internal ear involvement, probable vasculitis) under immunosuppressive therapy, was admitted to the hospital with a 3-week history of fever, significant weight loss, anorexia, night sweats and abdominal pain. There was a progressive increase in inflammatory markers and worsening anemia, with no changes on autoimmune screen, cultures and serological tests. CT revealed an enlarged liver with several hypodense lesions suggestive of liver abscesses and hepatic hilar adenopathies. Empirical antibiotic therapy was started at the 2nd week after admission and drainage of the lesions was unsuccessfully attempted. The entire etiological study of the lesions was negative. In spite of the empiric broad-spectrum antibiotherapy and suspension of the immunosuppressors, there was an evident clinical deterioration. Cholangio-MRI and PET-CT confirmed the liver changes and verified an increased number of lesions. After 1 month of hospitalization and no successful treatment, a biopsy was performed. Histology revealed an adenocarcinoma probably of biliary origin. The patient was admitted to the Oncology department for chemotherapy.

Discussion

A detailed medical history and physical examination often lead to directed laboratory and imaging tests that may reveal the diagnosis of a FUO. In this case, given the fever in an immunocompromised young patient, the infectious diseases were first to be excluded and antibiotherapy was initiated as soon as the suggestion of liver

abscess by imaging techniques. With the rapid deterioration of the patient, the diagnosis had to be questioned and further study had to be performed. Neoplastic fever is the most common cause of non-infectious pyrexia and against all odds it came to be our final diagnosis.

#1621 - Case Report

DIFFUSE LARGE B-CELL LYMPHOMA – AN INCIDENTAL DIAGNOSIS

Raquel Bastos Plácido¹, Tiago Valente², Fani Ribeiro², Ana Rafaela Araújo², Gisela Ferreira², Gorete Jesus²

¹ USF Beira Ria - ACeS do Baixo Vouga, Gafanha Da Nazaré, Portugal

² Centro Hospitalar do Baixo Vouga, Aveiro, Portugal

Introduction

Diffuse large B-cell lymphoma is the most common subtype of non-Hodgkin lymphoma and accounts for 30-40% of all cases. The annual incidence is approximately 16.5 per 100,000 people per year, with a slightly higher incidence in men and caucasians. The median age of diagnosis is 67 years old. At the diagnosis, more than half of the patients has some extraganglionic involvement. The locations more often involved are the gastrointestinal tract and bone marrow, although almost any organ can be affected.

Case description

The authors report a case of a 57 years-old man, with medical history of high blood pressure, hyperurecemia and dyslipidemia. The patient went to the hospital urgency care, with symptoms of right renal colic. He had no fever and the analytic control showed no changes. A renal ultrasound ecography was requested and it revealed “a lesion of 100x66x52 cm at the left side of bladder, on external iliac topography, suggestive of adenopathy”.

The patient was admitted to the hospital internment for study and a symptomatic review was made: he related a non intentional 3 kg ponderal loss in 3 months. He denied any other constitutional symptom. At the physical examination, non peripheral adenopathy was found.

A thoraco-abdomino-pelvic CT was solicited and it confirmed a “pelvic expansive lesion of 93x82x59 cm, with adjacent small ganglionic formations, setting the hypothesis of adenopathic conglomerate”. A biopsy was realized. The immune phenotyping and pathologic anatomy were consistent with diffuse large B-cell lymphoma. Towards these results, the patient was referenced to Hemato-Oncology consultation. He is now under R-CHOP chemotherapy.

The patient realized an echocardiogram, which was normal. A bone marrow biopsy, an endoscopy and a colonoscopy were requested. The results are not still available.

Discussion

In this case, there was no evidence of cardinal manifestations of the disease. So, it consists on an incidental diagnosis, which is more frequent each time, because of the easier access to complementary

diagnosis methods, in particular, image techniques.

In this report, the authors would like to point out the importance of an holistic evaluation and comprehension of the patient and his medical condition and the need to be always prepared to deal with any clinical situation.

#1649 - Case Report

WHEN IRON SUPPLEMENTATION UNVEILS THE TRUE PICTURE

Luis Reis De Almeida, Vera Salvado

Central Lisbon University Hospital Centre, Lisboa, Portugal

Introduction

Chronic proliferative disturbances of myeloid lineage may have insidious presentation. In early stages, mild non-specific symptoms are common with unapparent clinical picture.

Case description

We present a case of a 41-year-old black female, with history of arterial hypertension (recent diagnosis), anxiety disorder, and anaemia in the past (that was previously related to abundant menses). She presented with symptoms of fatigue, episodic headache, and acral paraesthesia involving hands and wrists with an estimated 3 month-course and gradual worsening. At that time, under oral contraceptive, she had 4 day-menses with normal flux and no other blood loss sources were identified. The initial clinical examination was unremarkable, apart from uncontrolled blood pressure. Laboratory workup presented erythrocytosis ($7.32 \times 10^{12}/L$) and thrombocytosis ($625 \times 10^9/L$), with normal haemoglobin (13,6 g/dL) and haematocrit (44.6%); profound microcytosis and hypochromia was confirmed in peripheral blood smear (PBS). Reticulocyte count (1,27%) had high immature fraction (30%). Iron profile had low ferritin and transferrin saturation (4.4%) with elevated transferrin soluble receptor (9,8mg/L). In order to study potential haemoglobinopathy, parenteral iron supplementation was given (iron-sucrose), with transient improvement in symptoms that relapsed in few weeks. After supplementation, erythrocytosis ($8.24 \times 10^{12}/L$) and thrombocytosis ($783 \times 10^9/L$) escalated, as well as haemoglobin (15.8 g/dL) and haematocrit (50.6%), with similar PBS findings and iron metabolism levels. Haemoglobin chromatography showed no abnormalities, arterial blood gas confirmed normal oxygen saturation and EPO assay presented suppressed appropriate levels. Mutation for JAK2-V617F tested positive.

Discussion

In a young female, myeloproliferative syndromes like polycythaemia vera can be hidden by menstrual blood loss, which maintain a temporary control as the disease evolves. In this case, iron supplementation provoked a burst in JAK2 clone, which unveiled haemoglobin/hematocrit levels highly suspicious. As the symptoms could be very unspecific, poliglobulia with microcytosis must trigger specific studies for haemoglobinopathy (thalassemia trait) and myeloproliferative disorders in order to accurate diagnosis.

#1650 - Case Report

LYMPHOPROLIFERATIVE SYNDROME WITH PLEURAL EFFUSION

Rafael Nascimento, Diogo André, João Miguel Freitas, Luz Brazão
Hospital Central do Funchal, Funchal, Portugal

Introduction

The authors present a rare case of pleural effusion secondary to a lymphoproliferative syndrome.

Case description

A 82 years old female is admitted in the emergency room with dyspnea and loss of weight that started three months before. In the clinical exam she was stable and despite not having any trouble breathing she had no breath sounds were listened on the right lung and several supraclavicular adenopathies were easily palpable.

Blood work did not reveal any abnormal results but the chest x-ray showed a significant pleural effusion. The patient was admitted in the Internal Medicine Department with the suspicion of a pleural effusion secondary to a neoplasia.

During hospitalization the patient was submitted to a thoracentesis in which the pleural fluid was serohematic but didn't have malignant cells. Pleural biopsies were negative to malignant cells and thoracic CT-Scan did not show any lesions or masses suggestive of neoplasm. The patient was then submitted to a medullar puncture which revealed bone marrow lymphoid hyperplasia which in conjunction with the immunophenotyping was suggestive of lymphoproliferative syndrome. The patient was submitted to an excisional biopsy of the supraclavicular adenopathies with the histology revealing a lymphocytic lymphoma.

Discussion

The authors present an atypical cause of pleural effusion secondary to lymphoproliferative syndrome, demonstrating the importance of the Internal Medicine nowadays in diagnosing diseases with atypical presentations.

#1653 - Case Report

POSTRENAL RENAL FAILURE WITH TRANSIENT BILATERAL URETHRAL OBSTRUCTION CAUSED BY DIFFUSE LARGE B-CELL LYMPHOMA (DLBCL); CASE REPORT.

Taro Okabe, Manabu Izumi

Saiseikai Utsunomiya Hospital, Utsunomiya-City, Japan

Introduction

Diffuse large B cell lymphoma (DLBCL) is the most common histologic subtype of non-Hodgkin lymphoma (NHL). Its clinical course is always one way. Without chemotherapy, the patients with DLBCL are difficult to improve.

Case description

80 years old women. Several days before, she had been admitted another hospital diagnosed as aspiration pneumonia and treated with standard antibiotics. Despite of adequate therapy, she felt into severe systemic edema and oliguria, thus, she transferred to our hospital. Laboratory data (BUN/Cre/K 91.3/8.44/5.5) indicated acute renal failure and required emergency hemodialysis (HD). Systemic computed tomography (CT) without contrast media revealed large mass at para-aortic lesion obstructed bilateral urethra and caused hydronephrosis. HD improved some of her systemic edema, but never improved oliguria. So, we decided to change strategy from aggressive care to palliative medicine. Fifth day after, we can recognize her massive urine output, unexpectedly. Soon, she recovered her normal renal function. Follow up CT with contrast media revealed regression of mass size and improve of hydronephrosis. She also recovered her consciousness and transferred original hospital. After four weeks, she felt into conscious disturbance and transferred our hospital again. This time, we could recognize massive pleural effusion, and we could diagnose her as B-cell lymphoma with cytodiagnosis of it. We only could give her palliative medicine. 10 days after, she died. Finally, she diagnosed as DLBCL with result of autopsy.

Discussion

It's rare that DLBCL cause urethral obstruction and hydronephrosis. Furthermore, its obstruction was improved without chemotherapy. We presented with some prior case report and speculation.

#1655 - Case Report

A RELAPSED HODGKIN'S LYMPHOMA

Rafael Nascimento, Diogo André, João Miguel Freitas, Luz Brazão
Hospital Central do Funchal, Funchal, Portugal

Introduction

The authors present a relapsed Hodgkin's lymphoma in a 30 years old man.

Case description

A 30 years old man with a history of Hodgkin's lymphoma in the childhood and smoking habits is admitted to the emergency room with complaints of fever and night sweats which started two weeks before. The man also referred losing 3 kilograms in the last month.

The patient was clinically stable but presented with an isolated painless lymph node, located in the submandibular region, with an elastic consistence measuring about 3 centimeters. Suspecting a relapsed Hodgkin's lymphoma the patient was admitted in the Internal Medicine Department.

During hospitalization we excluded infectious causes and the medullar puncture was normal. A CT-Scan of the neck showed conglomerates of adenopathies predominantly in the right side

of the neck, involving the lymph nodes around the submandibular gland. An excisional biopsy of the dominant lymph node was performed in which the histology was compatible with classic Hodgkin's lymphoma.

After making the diagnosis the patient started on ABVD scheme (Adriamycin, Bleomycin, Vincristine and Dacarbazine), after 4 months the PET-Scan showed no evidence of disease.

Discussion

The authors present a relapsed Hodgkin's lymphoma in a young patient, highlighting the importance of a good clinical history and exam.

#1657 - Case Report

A CASE OF KAPOSI'S SARCOMA IN AN IMMUNOCOMPETENT

Mariana Lessa Simões, Nina Jancar, Filipa Gonçalves, Patrício Aguiar, José Luís Ducla Soares

Centro Hospitalar Universitário Lisboa Norte - Hospital de Santa Maria, Lisboa, Portugal

Introduction

Kaposi's sarcoma (KS) is a vascular malignancy with four main clinical variants identified: classical, African-endemic, immunosuppressive drug-related and acquired immunodeficiency syndrome (AIDS)-related. Before the AIDS epidemic, 10% of cancers in Central and West Africa were attributed to African-endemic KS.

Case description

26-year-old afro-caribbean man, born and living in Cape Verde, transferred to Portugal with a one-year history of a maculopapular rash of the hands and feet (characterized by violaceous nodules), associated with pruritus, oedema and pain. He complained also of pain in the right tibiotarsal joint, causing limited function, and episodes of perceived fever without circadian predominance. Physical examination revealed skin desquamation, a maculopapular rash and oedema of the hands (palm and dorsal aspect) and sole of feet, but without other cardinal inflammatory signs. Laboratory studies revealed microcytosis, elevated sedimentation rate (35 mm/s), iron metabolism compatible with chronic disease (ferritin 568 ng/mL) and negative auto-immunity study. Serology for hepatitis A and B virus indicated past infection and serology for human immunodeficiency virus type 1 and 2 was negative. Differential diagnosis included tibiotarsal arthritis, mycetoma, other deep fungal, bacterial or atypical mycobacterial infections and neoplasms, such as lymphoma or Kaposi sarcoma. Ultrasound of the right tibiotarsal joint revealed a large hypoechogenic and heterogeneous formation throughout the length of the anterior tibial tendon, with doppler signal associated, and subcutaneous cellular tissue oedema; these findings, however, were not confirmed on MRI. IGRA, microbiology and mycology studies were all negative and skin biopsies gave us the diagnosis

of Kaposi's sarcoma; human herpes virus-8 serology was positive. The patient was later referred to Oncology Department to start chemotherapy with pegylate liposomal doxorubicin.

Discussion

Due to the immigration of individuals from Africa, the variant of African-endemic KS, not related to AIDS/immunosuppression, must be considered from the beginning. Moreover, we must also have a high index of suspicion, because the erythematous or violaceous nature of the patches or nodules is not easy to observe in black skin, making the diagnosis difficult.

#1658 - Case Report

LYMPHEDEMA AS AN INITIAL PROSTATE CANCER MANIFESTATION

Beatriz Samões, Mariana Fidalgo, Sofia Pereira, Manuela Sequeira
Centro Hospitalar de Vila Nova de Gaia e Espinho, Vila Nova De Gaia,
Portugal

Introduction

Prostate cancer is one of the most prevalent cancers among men worldwide. At the time of the diagnosis, clinical symptoms are rarely present - only 6% present with metastatic cancer, bone pain being the most common symptom.

Case description

A 61-year-old male presented to the ER with severe edema and pain affecting both lower limbs and genitalia. Additionally he had a painful mass in the left groin, first noticed 3 days earlier. A month before, he presented to the ER with stranguria and suprapubic pain and was started on silodosin.

He had vascular risk factors (arterial hypertension, obesity and active smoking) and a personal history of transient ischemic attack. He was chronically medicated with esomeprazole, lisinopril and aspirin.

At presentation he had a BP of 135/75mmHg, HR of 85bpm and no fever. Normal cardiac auscultation. Pulmonary auscultation: bilateral scattered wheezing and basal crackles. Abdomen was large but painless. Lower limbs with exuberant bilateral edema, erythema, superficial bullae and clear exudate; no signs of ischemia. Left inguinal region: painless 4cm mass, mobile, with elastic consistency.

Blood work with no significant alterations.

EcoDoppler of the lower limbs with no signs of deep or superficial venous thrombosis.

Given recent urinary tract symptoms and the presence of a mass in the inguinal region, an abdominal CT scan was ordered: enlarged prostate (transverse diameter: 6 cm) with irregular contour, multiple adenopathies (lateroaortic, peri-celiac, periliac, obturator and mesorectal) and sclerotic bone lesions in the left iliac, left sacral wing and L3 vertebral body suggestive of secondary etiology.

Prostate-specific antigen: 929,60ng/mL.

Patient was admitted for intravenous antibiotic therapy and additional study.

Bone scintigraphy revealed several lesions suggestive of osteoblastic bone metastasis.

Prostate biopsy confirmed the diagnosis of prostate acinar adenocarcinoma (Gleason Score 10) with perineural invasion.

He was started on GnRH antagonists (goserelin) and is being evaluated for potential chemotherapy with docetaxel and abiraterone.

Discussion

In developed countries, the main cause of lymphedema is malignancy or its treatment. Lymphedema and erysipelas as an initial prostate cancer manifestation are rare - estimated incidence of lymphedema related to prostate cancer is only 4%. However, when treating a male patient for bilateral lower limb lymphedema, neoplastic causes should always be excluded, given their high morbidity and mortality.

#1660 - Medical Image

PYODERMA GANGRENOSUM ASSOCIATED WITH FOLLICULAR BREAST CANCER

Miguel Silva

Hospital Pedro Hispano, ULSM, Matosinhos, Portugal

Clinical summary

We present the case of an 88 year-old woman, without any relevant past medical history, with bilateral painful leg skin lesions that progressed rapidly over 3 days, with pruritus, blistering and ulceration.

Had elevated leucocytes, ESR of 105 mm/s and CRP 80 mg/L. Rheumatoid factor, ANA, ANCA's and anti-phospholipid Ab were negative.

There was no evidence of arterial or venous vascular disease.

Incisional and border skin biopsy showed only ulceration with unspecific lymphocyte infiltration.

Was started on 60 mg/day of prednisolone and the lesions responded very well. A mass on the left breast was eventually diagnosed and the histology revealed a follicular carcinoma. The lesions recovered completely with steroid therapy and didn't recur after hormonal palliative treatment was started.

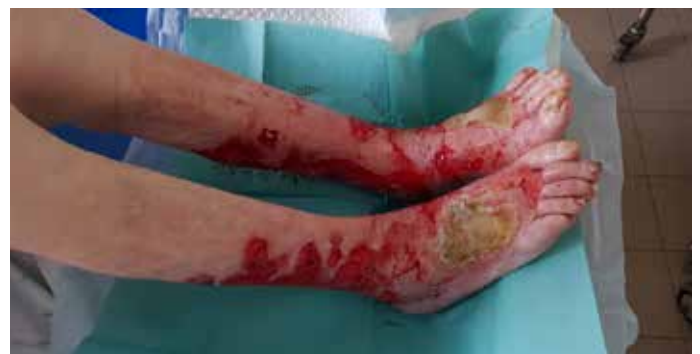

Figure #1660.

#1664 - Case Report

NEW MOTHER DIAGNOSED WITH MULTIPLE MYELOMA

Maria Inês Gonçalves¹, Vasco Pinto Neves², Paula Perestrelo¹,
Gonçalo Miranda¹, Rosa Ballesteros¹, Leopoldina Vicente¹

¹ Hospital Center of Cova da Beira, Covilhã, Portugal

² Local Health Unit of Guarda, Guarda, Portugal

Introduction

Multiple myeloma (MM) is a cancer of plasma cells, a type of white blood cell typically responsible for producing antibodies. Often, no symptoms are noticed initially. When advanced, bone pain, bleeding, frequent infections, and anemia may occur. MM is a disease of older adults – median age at diagnosis is 66 years; only 10 and 2% of patients are younger than 50 and 40 years, respectively.

Case description

Woman of 35 years old goes to Urgency Room with abdominal and back pain with 1 week evolution. She also refers weight lost. She is a new mother of a 3 month old baby that has been treated for an anemia since the pregnancy with oral iron. After giving birth, the anemia became severe, not justified by the bleeding during childbirth, with the need of blood transfusion. After discharge, the new mother kept the need of blood transfusion and endovenous iron.

In the urgency episode we scheduled blood samples to evaluate iron deposits and protein electroforesis within 2 weeks. The analitic results revealed a high blood protein level, motivating further tests during hospital stay – preliminar results revealed a IgG peak and Kappa light chains.

We were unable to withdrawn medular blood from the sternum for thick content, therefore colecting a bone sample from right iliac crist.

The clinical situation deteriorate suddenly with hipoxemia and hipocapnia, bradycardia and D-dimers elevation, suspecting pulmonar thromboembolism. At this point the patient was transfered to Intensive Care Unit. An urgent echocardiogram revealed the tipical findings of pulmonar thromboembolism, so fibrinolisis was performed. Despite all efforts, the patient started an acute major bleeding from the puncture sites, gum and vaginal bleeding. A few hours later the patient died.

Discussion

Although rare, multiple myeloma can affect young adults and this case alerts to the importance of investigate what we sometimes consider obvious, like an anemia in the pregnancy or post-partum.

#1666 - Case Report

ATRIAL FIBRILLATION AS AN ATYPICAL PRESENTATION OF MALIGNANT LUNG DISEASE

Diogo Faustino, Isabel Baptista

Central Lisbon University Hospital Centre - S. José Hospital, Lisbon,
Portugal

Introduction

Lung cancer as a secondary cause of atrial fibrillation is reported in literature, most commonly associated with paraneoplastic phenomena or as a complication following surgical resection. Reports of atrial fibrillation due to local tumor invasion of the atria are uncommon.

Case description

66 year-old man, heavy smoker with no other previous medical history. Admitted to the emergency room with progressive dyspnea (unable to tolerate moderate effort) and pleuritic left chest discomfort that lasted for 5-10 minutes and subsided spontaneously. He had an arrhythmic, quick pulse (100-110bpm) with the following ECG showing a previously unknow atrial fibrillation, without signs of ischemia. The remainder diagnostic workup didn't reveal any obvious cause for this arrhythmia (normal ions, thyroid and cardiac biomarkers). Echocardiography showed no atrial dilation and a preserved ejection fraction with no segmental wall motion abnormalities. Chest X-ray showed ill-defined opacities on the aortopulmonary window but an otherwise normal lung parenchyma. He was started on a beta-blocker and anticoagulant and was referred to an outpatient consultation. There, despite an appropriate heart frequency control, he wasn't feeling any better and complained of a progression of his symptoms, with worsened dyspnea on exertion and pain. On auscultation he had a diffuse attenuation of the vesicular murmur on the left hemithorax which prompted the request for further imaging. He was always very dismissive of his health, despite worsening symptomatology, and it took some time for him to undertake the requested examinations. Subsequent chest x-ray (approximately 3 months after the initial episode) showed a white-out left lung, with the following CT scan revealing an exuberant mass (8x6 cm), loosely triangular in shape, extending from the aortic arch to the lower left auricle and completely obliterating the left main bronchus. There were also many distant metastasis, namely mediastinal, celiac, retroperitoneal and hepatic. Samples obtained via bronchoscopy were compatible with small-cell lung carcinoma. He ended up passing away at home, shortly after.

Discussion

We assume the origin of the fibrillation as secondary to a local atrial invasion by the tumor. Case reports on this association are infrequent. This case also highlights the typical fulminant course of small-cell lung carcinoma, with reported median survival rates ranging from 2 to 4 months without treatment.

#1672 - Case Report

FROM DEPRESSION TO MULTIPLE MYELOMA: A CASE REPORT

Patrícia Daniela Pinheiro Paiva¹, Telma Brás Alves², Ricardo Ambrósio Rodrigues², Ana Rita M. Gomes³, Joana Isabel Félix Paixão², Ana Cristina Martins², Diana Gonçalves², João Gonçalves², Leonor Aleluia², Fátima Silva², Ana Figueiredo², Armando Carvalho²

¹ Department of Clinical Pharmacology, Coimbra Hospital and University Center, Coimbra, Portugal, Coimbra, Portugal

² Department of Internal Medicine, Coimbra Hospital and University Center, Coimbra, Portugal, Coimbra, Portugal

³ Department of Cardiology, Coimbra Hospital and University Center, Coimbra, Portugal, Coimbra, Portugal

Introduction

Multiple myeloma is an hematologic neoplastic disease characterized by the proliferation of immunoglobulin producing plasma cells. Most commonly presents itself with symptoms related to bone infiltration by plasma cells, such as bone pain, pathological fractures or anemia. It may also present with non-specific symptoms such as fatigue, malaise or others.

Case description

A 67-year-old women presented to the emergency room (ER) with localized lumbar pain, she had a recent diagnosis of major depression with visual hallucinations accompanied by asthenia, loss of appetite and weight loss (13% weight reduction in 7 months), which were initially associated with the depressive syndrome. Blood work in the ER showed macrocytic anemia with an hemoglobin of 4.9 g/dL, it also revealed an increase in sedimentation rate (58 mm), creatinine (3.11 mg/dL) and serum calcium (3.44mmol/L).

Immunofixation showed monoclonal proteins of lambda light chains and gamma heavy chains. Full body CT showed significant cardiomegaly, slight bilateral pleural effusion and countless osteolytic lesion throughout the axial skeleton. On the suspicion of cardiac amyloidosis abdominal fat biopsy was performed revealing lambda chain deposits.

Bone biopsy showed a bone marrow with 90% invasion by multiple myeloma.

She was later discharged with regular follow up consultations by hematology and started treatment with bortezomib + dexamethasone + cyclophosphamide.

Discussion

Clinical depression is a very common condition nowadays, making it a reality that we all need to be aware of in our practice. This case shows the importance of integrating all our patients complaints, and not dismissing common symptoms like depression as isolated conditions, which could have an underlying organic cause.

#1677 - Case Report

ORBITAL MASS: ATYPICAL PRESENTATION OF FOLLICULAR LYMPHOMA

Catarina Lizardo Cruz, Ricardo Pinto Sousa, Rita Mendes

Hospital Egas Moniz, Lisboa, Portugal

Introduction

Follicular lymphoma is the second most frequent type of non-Hodgkin's lymphoma in adults. It is characterized by an indolent course with patients usually presenting with an already disseminated lymph nodal disease at the time of diagnosis. Extra-nodal involvement occurs in 25–40% of cases, it may have multiple manifestations and sometimes mimic other organ-related pathologies. Differentiation between disseminated lymph nodal disease involving an extra-nodal site and primary extra-nodal disease is challenging. Primary extra-nodal disease usually presents acutely with a rapidly growing mass and systemic B symptoms. Conversely, disseminated lymph nodal disease has a more indolent course and nonspecific signs and symptoms, hence delaying its diagnosis and consequently its treatment.

Case description

We report a case of 85-year-old women who presented to Emergency Department of Ophthalmology with pain and acute reduction of visual acuity of the left eye for the past week. On examination, except for a relative afferent pupilar defect of the left eye, the neurological examination was unremarkable. Computed Tomography findings showed a large expansive lesion, defined as intra and extra-conical, occupying the orbital apex and projecting into the optic foramen. She was then referred to an Internal Medicine consult and, when questioned, revealed non-selective anorexia and weight loss (22%) since 2 years. A thorough systemic examination revealed a large augmentation of the right parotid gland and multiple soft, palpable, but painless, adenopathies of the left jugular chain and right submandibular aspect. Biopsy of the left jugular conglomerate was performed and immunohistochemical studies revealed a non-Hodgkin's lymphoma composed of small lymphoid cells in a follicular pattern, positive for CD 20 and BCL 6. The patient was then referred to the Hematology Department and initiated treatment with chemotherapy, small reduction of the multiple masses was observed after 3 cycles.

Discussion

Reduction of visual acuity as a form of presentation for follicular lymphoma is uncommon and mandates extensive work up and differential diagnosis. We bring awareness to the importance of recognising atypical forms of presentation for non-Hodgkin's lymphomas. As well as the essential role of a complete physical examination and thorough history taking of the patient.

#1688 - Medical Image

SPLENIC LYMPHOMA: AN UNCOMMON DIAGNOSIS

Maria Inês Vicente^{1,2}, Alexandre N. Fernandes¹, Ana Paula Antunes, Tânia Strecht¹, Catarina V. Oliveira¹, Jana Zelinová¹, Inês Rossio¹

¹ Hospital de Cascais, Cascais, Portugal

² IPO Lisboa, Lisboa, Portugal

Clinical summary

A 78-year-old male with type 2 diabetes and heart failure was admitted in the emergency room with fatigue, nocturnal paroxysmal dyspnea and malleolar edema. The physical examination showed diminished breath sounds on the left pulmonary base. Chest X-ray and CT scan confirmed the presence of a left pleural effusion with mediastinal deviation to the contralateral side and a solid mass on the spleen suggestive of metastatic process. A diagnostic thoracentesis was performed which was compatible with an exudate without neoplastic cells identified by flow cytometry. Cultures were sterile. Biopsy of the spleen was performed and it was positive for primary splenic diffuse large B-cell lymphoma, which is a rare type of lymphoma, corresponding to less than 1% of all non-Hodgkin's lymphoma.

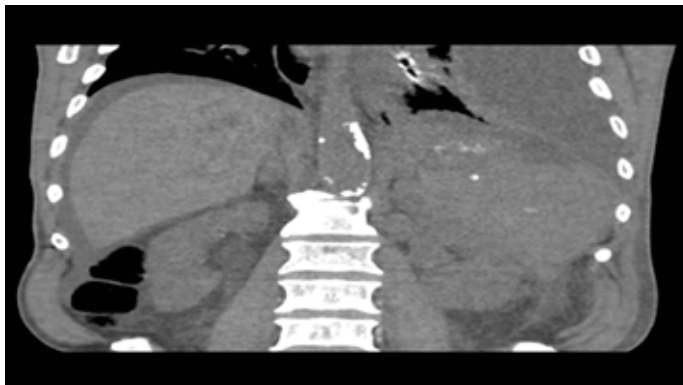


Figure #1688.

#1710 - Case Report

RARE PRESENTATION OF LEPTOMENINGEAL CARCINOMATOSIS SECONDARY TO URETHELIAL CARCINOMA RELAPSE

Miguel Silva, Daniela Carvalho

Hospital Pedro Hispano, ULSM, Matosinhos, Portugal

Introduction

Leptomeningeal carcinomatosis is a rare but dire complication of metastatic cancer. Its occurrence is extremely rare in the setting of urethelial carcinoma. A high index of suspicion is necessary to make the diagnosis and a simple CSF cytology can be confirmatory.

Case description

We present the case of a 77 year old man that presented to the emergency department with an altered mental state preceded by

4 days of insidious confusion and bizarre behavior. He had a history of an urethelial carcinoma of the left ureter that was treated with radical cistoprostatectomy about 5 months before admission. The surgical specimen had primarily revealed undifferentiated carcinoma, but also focal areas of neuroendocrine and sarcoma differentiation. Pathological stage was pT3N0G4,LO,V0,Pn0,R0. There was no evidence of distant metastatic disease at the time and it was then decided to only monitor recurrence of the disease. At admission he had a fluctuating GCS (11-14), however the remaining physical examination was unremarkable. Head CT was unremarkable. He had a clear fluid lumbar puncture with 19 leucocytes (mostly mononuclear cells) with normal proteins and blood glucose. Blood workup at the time was unremarkable. The patient was started on iv levetiracetam, ceftriaxone, ampicillin and acyclovir. His neurological state fluctuated over the course of the next 3 days, even with increasing doses of levetiracetam and valproic acid. No EEG was performed at this point. Brain MRI was unremarkable. Microbiological studies were negative. Further deterioration of conscience to a GCS of 5 prompted emergent entubation, sedation and ICU admission. An EEG showed activity suggesting non-convulsive status epilepticus. A decision was made to start burst-suppression therapy with propofol and midazolam. A repeat lumbar puncture, this time with a cytological study, revealed isolated neoplastic cells with positive cytokeratin CAM5.2, suggesting carcinoma metastasis. The patient evolved unfavorably within the next 48h with further deterioration of consciousness and refractoriness to anti-convulsive treatment and culminating in a decision to withdraw life support.

Discussion

A positive CSF cytology is the gold standard and establishes the diagnosis of leptomeningeal carcinomatosis and shouldn't be discarded in the evaluation of a patient with a history of cancer.

#1711 - Case Report

ISOLATED CONGENITAL ASPLENIA - A RARE DIAGNOSIS

Sofia Dinis Ferreira, Cláudia Lemos, André Mendonça Vieira, Mónica Caldeira, Miguel Homem Costa, Maria Luz Brazão, Fernando Aveiro

Hospital Central do Funchal, Funchal, Portugal

Introduction

Asplenia, or absence of spleen, can occur in several contexts. It is usually associated with splenectomy or functional diseases. Congenital Asplenia is a rare condition that mostly occurs in the context of specific malformations. In contrast, isolated congenital asplenia (ICA) is extremely rare, with fewer than 100 cases described in the literature. Most cases present in the first years of life, usually due to systemic infections/sepsis, caused by encapsulated bacteria, which are the most virulent in this group of patients. Few cases are diagnosed in adulthood. This case report concerns the diagnosis of ICA in an asymptomatic adult patient.

Case description

DJNLT, female, 36 years-old, referred to the consultation for persistent leukocytosis and thrombocytosis. She had history of allergies and no reported splenectomy. No significant changes on physical examination. Analytically, leukocytosis and thrombocytosis was confirmed, as well moderate anisopoikilocytosis and some red blood cells with Howell-Jolly bodies. Screening of hemoglobinopathies was negative. The Abdominal-pelvic CT did not identify spleen and Abdominal MRI confirmed the absence of spleen, as well as no infarcted spleens, splenosis or alterations of organ rotation. The study was completed with myelogram, which was normal, and transthoracic echocardiogram that excluded congenital heart diseases.

Discussion

Congenital asplenia is more associated with other abnormalities, the most common being the Ivemark syndrome, characterized by visceral heterotaxia, with duplication of the right side organs and absence of the left side ones. The ICA is extremely rare. A recent study estimated that the prevalence of this pathology is 0.51/million births. Contrary to the other causes of asplenia, the diagnosis of ICA becomes a challenge due to the absence of other abnormalities. The clinical presentation is heterogeneous. These individuals have an increased susceptibility to invasive infections, with high mortality despite treatment. Although presenting with mild non-specific symptoms, they may have a rapid clinical decline, with septic shock and disseminated intravascular coagulation. The diagnosis can be confirmed by the identification of Howell-Jolly bodies in the erythrocyte membrane in the blood smear and by the absence of spleen in the imaging tests. These patients may benefit from some specific preventive actions like vaccination and the immediate empirical treatment of febrile episodes.

#1713 - Case Report

A 76-YEAR-OLD MAN ADMITTED FOR THE STUDY OF A LEFT LOWER LIMB LESION SUGGESTIVE OF DVT: NOT EVERYTHING IS WHAT IT SEEMS

Patricia Rubio-Marin¹, M^ª Del Carmen Montañes Guimera², Juan Mora¹

¹ Hospital Universitario de Jerez, Jerez De La Frontera, Spain

² Universidad de Cádiz, Cádiz, Spain

Introduction

Sometimes in medicine it is difficult to make an accurate diagnosis. In the case of metastases of known primary tumors, routine biopsies are not usually performed, assuming the origin in that tumor. But sometimes there are synchronous tumors that explain the bad clinical evolution with the treatment.

Case description

A 76-year-old male with a history of prostate adenocarcinoma with pulmonary metastases treated with hormonal block. He was

admitted to internal medicine with the suspicion of DVT. He had an increase in the perimeter of the left leg, more evident in the thigh, and pain for several days. The D dimer was high, an x-ray of the left thigh showed a 25 cms round mass with well-defined and bright edges. Doppler was performed, which ruled out DVT and an MRI study was completed in which a rounded mass suspected of liposarcoma was observed. The study was completed with a body-CT in which pulmonary metastases had increased in size. Metastasis biopsy was compatible with liposarcoma. The patient was referred to a specialized center for excision of the mass and chemotherapy treatment.

Discussion

Liposarcomas are derived from adipocyte precursors, they are found within soft tissue sarcomas, they are of mesenchymal origin. They are less than 1% of all cancers. The location in adults are the extremities and retroperitoneum. They produce a compression of the neighboring tissue and form a pseudocapsule. The spread is hematogenous, predominantly to the lung. Metastases are frequent in high-grade sarcoma. 80% of the metastases are pulmonary. The treatment is surgery and radiotherapy, chemotherapy if there is metastasis but it is not well established. The prognosis depends on the size of the tumor, the presence of metastasis and the histological type.

#1733 - Case Report

MONOCLONAL GAMMOPATHY OF RENAL SIGNIFICANCE

Hugo Inácio, Susana Gonçalves Pereira, Filipa Cardoso, Paulo Barreto, Catarina Salvado

Centro Hospitalar Universitário de Lisboa Central, Lisbon, Portugal

Introduction

In 2012, the International Kidney and Monoclonal Gammopathy Research Group introduced monoclonal gammopathy of renal significance (MGRS) to describe the hematological pathologies producing monoclonal immunoglobulin associated with acute kidney lesions.

Case description

We present a case of a 79-year-old Caucasian woman, admitted with a 4-day onset of diarrhea and fever, complaining of tiredness, hard to control blood pressure (BP), lower limbs edemas and distal paresthesias for the previous 2 months. Additionally, type 2 diabetes mellitus diagnosed 15 years ago. Blood analyses with laboratory parameters suggested infection and acute kidney injury. Gastroenteritis was assumed and treated empirically with ciprofloxacin.

In line with this, the complementary study revealed exclusion of acute heart failure (BNP 150 pg/mL and transthoracic echocardiogram with good global systolic function and no segmental contractility alterations); and chronic disease anemia was detected through the iron study, without gastrointestinal

losses; antiglobulin direct test was negative. Due to acute kidney injury with urinary sedimentation revealing hematuria, it was performed a 24-hour urine study that showed nephrotic proteinuria (4.3 g/24h). Autoimmunity study ruled out vasculitis and renal ultrasound revealed no sign of medical nephropathy. Therefore, serum protein electrophoresis showed a monoclonal peak in the gamma region - IgM kappa (IgM 3.24 g/L, free kappa chains 174 mg/L, K/L ratio 9.16), with C4 consumption (0.04 g/dL). Type II mixed cryoglobulinemia with monoclonal IgM and polyclonal IgG was positive, with negative viral serologies. With the pre-diagnosis of lymphoproliferative disease, a full-body CT scan was performed showing no relevant findings, and bone biopsy documented 3% of monoclonal plasmocytes. Kidney biopsy showed membranoproliferative glomerulonephritis and subendothelial and endocapillary deposits of IgM and kappa light chains, without amyloid substance. We concluded a diagnosis of MGRS, with mixed cryoglobulinemia and peripheral neuropathy. The patient underwent a 6 cycle systemic therapy with rituximab, cyclophosphamide and dexamethasone, improving anemia, peripheral edema, kidney function, and BP control. The peripheral neuropathy remained, but with good response to gabapentin.

Discussion

MGRS is a rare nosological entity, especially when associated with negative HCV mixed cryoglobulinemia, whose early diagnosis and therapy are essential to avoid irreversible organ damage.

#1734 - Case Report

SPINE METASTASIS AS AN INITIAL PRESENTATION OF GASTRIC ADENOCARCINOMA

Carla Falcão, Rita Grácio, Gaspar Pereira, Pedro Neves Tavares, Catarina Duarte Santos, Diana Fernandes, Alcina Ponte
Centro Hospitalar de Leiria, Leiria, Portugal

Introduction

Metastatic spread to the spine is common in advanced stages of cancer but sometimes they emerge as the initial presentation. Usually the most common primary tumors that lead to bone metastasis are prostate, breast, kidney, lung and thyroid cancer. A literature review reports an incidence of bone metastasis in only 5% of the gastrointestinal cancers and an even more infrequent incidence of bone metastasis as the initial presentation.

Case description

An 82-year old woman with a medical history of arterial hypertension and dyslipidemia, was admitted in the ER complaining of pain in the inferior limbs with progressive worsening in the last 4 months. She also mentioned a fall with lumbar trauma 3 years before. A lumbar CT-scan was performed and identified a diffused diminished bone density and multiple osteolytic lesions in the lumbar vertebrae of greater extension

at L3, with a collapsed fracture of the vertebral body and lesion of the adjacent paravertebral and epidural soft tissues creating a moderated spinal stenosis. She was admitted to the ward for analgesic and conservative treatment and for investigation purposes. Several medical exams were performed in order to determine the primary tumor. The whole-body CT-scan identified a 25x25 mm nodular lesion in the posterior segment of the right upper lobe of lung. Anatomopathological analysis of the trans tracheal cytologic aspiration of the lung lesion was inconclusive for malignant cells, as well as the bronchoalveolar lavage results. Thyroid ultrasound revealed a diffuse heterogeneous thyroid parenchyma and some hypoechogenic nodules with 17mm wide on the left lobe and 15 mm wide on the right lobe. No malignant cells were found at the cytology aspiration biopsy. The gastric endoscopy revealed a small ulcer in the pyloric antrum that was biopsied and anatomopathological analysis confirmed a gastric adenocarcinoma diagnosis. No other metastasis or tumors were found in the additional follow-up. Initial treatment was discussed at a multidisciplinary meeting and with the patient, having she refused invasive treatment and accepted only palliative radiotherapy.

Discussion

The gastric adenocarcinoma as the primary tumor diagnosed in this patient was unexpected, as she had no history of gastrointestinal symptoms, anemia, lymph nodes enlargement or even cachexia. This case report is a warning for the importance of a prompt and thorough search for the primary tumor in patients initially presenting with spine metastasis.

#1738 - Case Report

SYNCOPE, AN UNEXPECTED CAUSE – CASE REPORT

Inês Manique¹, Mariana Popovici¹, Mário Ferraz¹, Paolo Iacomini¹, André Goulart², Jorge Fernandes¹, Matilde Fraga¹, Ana Raquel Pinto¹, Ana Pereira¹, Ana Rodrigues¹, António Panarra¹

¹ Hospital Curry Cabral, Lisboa, Portugal

² Hospital de Santo Espírito da Ilha Terceira, Angra Do Heroísmo, Portugal

Introduction

Syncope is a common cause of hospital admission, especially in the elderly. The rapid identification of its causes which although reversible, can constitute fatal events, justifies the need for hospitalization. The importance of the presented case lies in the diagnosis of two common causes for syncope (aortic stenosis and anemia), one of which has an unexpected etiology: macrocytic anemia in the context of 5q Syndrome.

Case description

72 years old female admitted to the hospital after two episodes of syncope with prodromes and history of tiredness to moderate efforts for six months. At physical examination paleness and aortic systolic murmur III/VI throughout the pre-cord stand out.

Initial investigation showed hemoglobin 7,4 mg/dL with Mean corpuscular volume (MCV) of 120 fL without other cytopenias. The patient was hospitalized to complete the syncope study. From this study we highlight the Ecocardiogram that revealed aortic valvular area 0.7 cm² (severe aortic stenosis) that coupled with the presence of symptoms supported surgery indication, performing implantation of aortic bioprosthesis.

In the investigation of macrocytic anemia folic acid and B12 vitamin deficiency were excluded. The study of bone marrow showed hipocellularity, 2% blasts, micromegakaryocytes with hypolobated nuclei; dysplastic changes of erythroid precursors with a cytogenetic analysis making the diagnosis of 5q syndrome.

Discussion

This case revealed an unexpected etiology of anemia – 5q-Syndrome. 5q-Syndrome accounts for 10% of the cases of myelodysplasia (MDS), with less than 10% chance of evolving to Acute Myeloid Leukemia (AML). It is more common in females with a median age of 65–70 years. Anemia is usually macrocytic, platelet counts are normal or elevated, and there may be a modest leukopenia. Blood smears may show macrocytosis and <1% blasts. Bone marrow is usually hypercellular, and shows micromegakaryocytes with mono- or hypolobated nuclei; erythroid precursors may show dysplastic changes; blasts are <5% and show no Auer rods. This syndrome is a MDS form associated with good prognosis. This case highlights the need for a thorough study of anemia etiologies, to provide the best care for our patients.

#1759 - Medical Image

STUDY OF A MASS IN THE LOWER LEFT LIMB

Patricia Rubio-Marin¹, M^a Del Carmen Montañes Guimera², Juan Mora³

¹ Hospital SAS de Jerez, Jerez De La Frontera, Spain

² Universidad de Cádiz, Cádiz, Spain

³ Hospital Universitario de Jerez, Jerez De La Frontera, Spain

Clinical summary

A 76 year-old male was admitted to internal medicine with the suspicion of DVT. He had an increase in the perimeter of the left leg, more evident in the thigh, and pain for several days. The D dimer was high, an x-ray of the left thigh showed a 25cms round mass with well-defined and bright edges. Doppler was performed, which ruled out DVT and an MRI study was completed in which a rounded mass suspected of liposarcoma was observed. A biopsy confirmed the diagnosis.

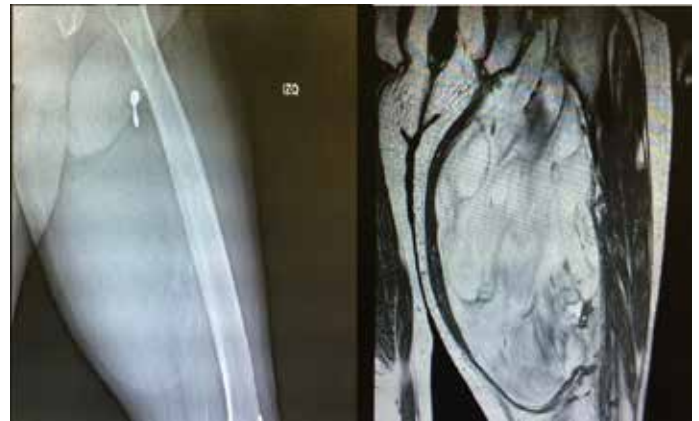

Figure #1759. Left: X-ray of the left thigh. Medial femoral cortical recession and apparent line of calcification surrounding the lesion in all its periphery. Right: MRI. Mass of large size: craniocaudal diameter of 30 cm, AP of 12.8 cm and transverse of 12.7 cm. Pattern of heterogeneous signal of adipose predominance, with presence of multiple internal tracts of irregular morphology. Compatible with: LIPOSARCOMA.

#1763 - Case Report

OCCURRENCE OF ESOPHAGEAL MALIGNANCY IN A YOUNG WOMAN WITH PLUMMER VINSON SYNDROME

Unnikrishnan Bhaskaran, Basavaprabhu Achappa

Kasturba Medical College, Mangalore, India

Introduction

Plummer-Vinson is a rare condition commonly seen in middle aged women and presents as a classical triad of dysphagia, iron-deficiency anemia and esophageal webs. In India there is not much reporting of the disease. The etiology of the disease is not clearly known however the most accepted etiological factor is Iron deficiency. Due to the iron deficiency the enzymes which are dependent on Iron are depleted leading to myasthenic changes in the muscles involved in swallowing and the atrophy and formation of esophageal webs. Plummer Vinson syndrome is known to be a risk factor for the occurrence of the squamous cell carcinoma of the Upper gastrointestinal tract. Though the occurrence is rare, risk factor of 3-15 per cent of patients with Plummer-Vinson syndrome, mostly women between 15 and 50 years of age, has been reported to develop esophageal or pharyngeal cancer. The cause for predisposing to malignancy is unknown but it is believed to be due to the chronic inflammation, fibrosis and epithelial changes that occur during disease may lead to malignancy. Other factors such as genetic, environmental and immunological factors may also be important. Amongst the malignancy, most common are those of hypopharynx especially of lower part i.e. postcricoid region. It is rare to find cases of esophageal malignancy.

Case description

32 year old female presented with fever, cough, pain abdomen, weight loss and generalized weakness for one month. Upon examination, patient was febrile and had tachycardia. There

was pallor with presence of angular stomatitis and glossitis. Per abdomen examination revealed tender hepatomegaly. Complete blood count showed patient having anemia with Hemoglobin of 8.2 gm/dl, peripheral smear showed microcytic hypochromic anemia. Barium swallow was done which showed esophageal webs. Gastro-duodenoscopy showed post cricoid web with esophageal tumor. A biopsy from the tumor gave a picture of squamous cell carcinoma. USG Abdomen showed Hepatomegaly with multiple heteroechoic lesions in the liver. USG guided FNAC showed Liver metastasis.

Discussion

Plummer Vinson is a rare condition which is seen in middle aged women and presents with classical triad of dysphagia, iron-deficiency anemia and esophageal webs. Mostly, disease can be treated with Iron supplementation and dilatation to relieve the dysphagia. Syndrome has potential to cause malignancy of Upper GI and hence proper evaluation is important. Women in this age group presenting with above features should be evaluated with endoscopy.

#1791 - Case Report

WHAT COMES AFTER ACUTE PULMONARY OEDEMA... VASCULITIS!

Pedro Leite Vieira, Rui Isidoro, Filipa Leitão, Joana Carvalho, Catarina Reis Santos, Alexandre Louro, Paula Paiva, Maria Eugénia André

Amato Lusitano Hospital, Castelo Branco, Portugal

Introduction

Cryoglobulinemia (CRY) syndrome is a systemic disease caused by the deposition of immune complexes containing cryoglobulins in the small and medium vessels. CRY is classified in three types, frequently associated with infection, malignancy or autoimmune diseases and mostly asymptomatic. Although CRY rarely presents as vasculitis, when it occurs, it is important to identify and treat it timely.

Case description

71-year-old man with history of fleeting purpuric lesions on lower limbs (LL) in the past 3 years, chronic anaemia, chronic heart failure, atrial fibrillation (AF) hypocoagulated and arterial hypertension (AH) was admitted to emergency room with dyspnoea, supine intolerance, hypoxemia and AH grade 3. He also referred haematuria and hemoptotic sputum during last month. On physical examination he had AH grade 3, AF with 156 bpm, cyanosis, signs of respiratory distress, crackles, bimalleolar oedema and non-palpable purpuric lesions on LL. Laboratory tests showed mixed acidaemia on arterial blood gas, haemoglobin 8.9 g/dL, creatinine 2 mg/dL, BNP 1075 pg/mL and hematuria with dysmorphic erythrocytes. Proteinogram: monoclonal IgM Kappa peak; cryoglobulins IgM kappa positive. Negative for BHV, CHV and HIV. Computer Tomography showed pleural, pericardial effusions and signs suggesting pulmonary

oedema or alveolar bleeding. Renal biopsy revealed cryoglobulinemia with membranoproliferative glomerulonephritis associated with immunocomplexes. Initially treated with methylprednisolone 1g/day with partial response but, due to the recrudescence of the clinical condition, assuming probable autoimmune disease, it was started EURO-LUPUS cyclophosphamide protocol and plasmapheresis. Despite all the efforts, the patient developed sepsis with pancytopenia and *P. aeruginosa* bacteraemia related with dialysis catheter and death was inevitable. Autoimmunity study showed IgM 6.71 g/L, slight hypocomplementemia, rheumatoid factor IgM and IgA positive and bone marrow aspiration was compatible with Waldenström's macroglobulinaemia (WM), but only were obtained after patient death.

Discussion

The presented case meets the diagnostic criteria of type I CRY, associated with WM, in which the Ig component is a monoclonal IgM. Due to multisystemic organ damage, namely lung and kidney, the prognosis is frankly worst. Therefore, knowledge of these rare, potentially fatal, but treatable entities is crucial in order to treat them timely and avoid poor outcomes like death.

#1795 - Medical Image

RACCOON EYES: THE DIAGNOSIS BEHIND

Denise Magalhães, Joana Martins, Joana Simões, [Danay Peres](#)
Hospital Pedro Hispano, Matosinhos, Portugal

Clinical summary

A 73-year-old woman presented with a 2 year history of periorbital ecchymosis and hyperpigmented lesions on her fingers. Serum protein electrophoresis and immunoelectrophoresis revealed a monoclonal IgG/lambda gammopathy. Bone marrow biopsy showed 15% of plasma cells. Abdominal fat biopsy was positive for amyloid staining. There were no lytic bone lesions, no anemia, and blood calcium and renal function were normal, so a diagnosis of AL amyloidosis was made. Echocardiography was suggestive of heart involvement. She started chemotherapy and achieved complete hematologic response and her skin lesions improved. AL amyloidosis has a poor prognosis when detected at an advanced stage. Raccoon eyes are present only in a minority of patients and should be recognized promptly.

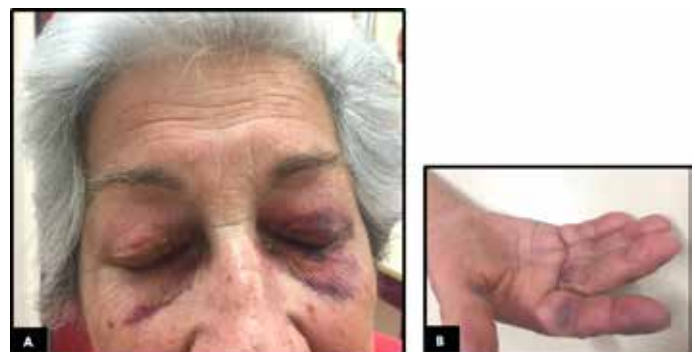

Figure #1795.

#1796 - Case Report

PROSTATE CANCER WHEN YOU SUSPECT?Marta Vilaça¹, Catarina Trigo², Diogo Pereira¹, Rui Moçô²¹ Hospital Pedro Hispano, Matosinhos, Portugal² ULSMatosinhos, Matosinhos, Portugal**Introduction**

Prostate adenocarcinoma is one of the most commonly diagnosed neoplasms. Usually patients report complaints related to the urinary tract, such as obstruction to urinary flow due to tumor growth. At an advanced stage, when distant metastasis has occurred, patients usually experience bone pain. The present case reports a challenging diagnosis of prostate cancer, with atypical presentation.

Case description

Man of 75 years, followed in external consultation of Urology by episodes of hematuria. In vesical ultrasound with apparent thickening at the bladder base, it was decided to perform a transurethral resection (TUR), which occurred on July 12, 201 without interurrences. Intra-operatively without neoformative lesions of the bladder mucosa but with effort bladder. Bladder neck tightened by what was done resection ad minimum of prostate. In the histological examination, lesions of fibromy glandular hyperplasia and chronic prostatitis, with no signs of malignancy.

The patient was referred to the Emergency Department on August 21, 2018 for a period of 4 weeks of asthenia and fatigue for aggravated fatigue associated with episodes of lipothymia with orthostatism without loss of consciousness. He also referred to a constitutional framework with a 2-month evolution, with a weight loss of 10 kg and bone pain in the lumbosacral region, with several months of evolution.

At admission to the ED, with new bicitopenia, normocytic and normocytic anemia (hemoglobin of 9.5 g/dL) and thrombocytopenia of 64,000/ μ L, not present in an analytical study performed 4 months earlier. There was also a significant elevation of alkaline phosphatase (2777 U/L), with an increase of 5 nucleotidase, without hyperbilirubinemia, and a much increased LDH. Thoraco-abdominal CT revealed osteo-condensing lesions at the level of the axial skeleton. PSA, with a value of 825.19 ng/mL, was dosed. He performed a prostatic biopsy that identified Acinar-type invasive adenocarcinoma, combined Gleason grade: 4+3=7; prognostic group (WHO 2016): grade 3. Performed bone scintigraphy that suggests disseminated bone metastasis with axial and appendicular skeletal involvement. Prostate adenocarcinoma was assumed with spinal involvement and symptomatic treatment was proposed.

Discussion

This clinical case is presented because it demonstrates the diagnostic complexity of a prostate cancer. In addition, although a RTU was previously performed, the amount of prostatic tissue removed in this case was minimal, not allowing identificat

#1799 - Case Report

IATROGENIC INDUCED PANCYTOPENIA: THE IMPORTANCE OF DRUG INTERACTIONS.

Jorge Ricardo Rodrigues, Rosa Cardoso, Manuela Vasconcelos, António Oliveira Silva

Hospital de Braga, Braga, Portugal

Introduction

Colchicine is a well-known cause of bone marrow toxicity in the literature, with blood cell counts remaining depressed for several weeks.

Case description

An 81 years old male patient, with a history of atrial fibrillation, heart failure with preserved ejection fraction of valvular etiology, having recently undergone a bioprosthetic aortic valve replacement, tricuspid valve repair and ascending aortic endarterectomy, was discharged from the cardiothoracic surgery ward with warfarin od, aspirin 100 mg od, furosemide 40 mg od, losartan 100 mg od, spironolactone 25 mg od, pantoprazole 20 mg od, atorvastatin 40 mg od and colchicine 1g od. Two months after the surgical intervention, the patient is referred to the emergency department with complaints of diarrhea in the last month, accompanied by unquantified weight loss, anorexia, asthenia, nausea and food vomiting. On physical examination, he was hemodynamically well, emaciated, anicteric and with dehydration signs. Blood test revealed pancytopenia with microcytic and normochromic anemia, acute kidney injury (urea/creatinine 293/2.6 mg/dL) and rhabdomyolysis (total CK 2685U/L, myoglobin 15283ng/mL). He was admitted to the internal medicine ward to proceed etiological study. Colchicine and atorvastatin administration was stopped. Fecal microbiological study, blood cultures, viral serology (HBV, HIV, CMV, EBV, Parvovirus B19, HSV I and II) and immunological study were all negative. Thyroid function was normal. The iron study revealed elevated ferritin (1208 ng/mL) with decreased total iron fixation capacity (177 ug/dL), serum iron (48 ug/dL) and 27% transferrin saturation, with normal folic acid and vitamin B12 concentrations. Reticulocyte production rate was 2,8%. Upper gastrointestinal endoscopy and total colonoscopy were also normal. Transthoracic echocardiogram revealed good overall right and left ventricular function. During the hospital stay the patient presented pancytopenia, acute kidney injury, rhabdomyolysis and progressive symptomatic resolution.

Discussion

In this patient, the interaction between colchicine, atorvastatin and spironolactone may have enhanced the clinical picture, since atorvastatin and colchicine coadministration may increase the risk of myopathy, as both are myotoxic. Also, spironolactone blocks P-glycoprotein function, enhancing colchicine absorption as well as decreasing its excretion. These interactions are well described in the literature where they are classified as major.

#1809 - Case Report

UNUSUAL PRESENTATION OF EBV-ASSOCIATED NON-HODGKIN LYMPHOMA WITH ANTIPHOSPHOLIPID ANTIBODIES AS COAGULATION INHIBITORS

Mário Ferreira, Marta Fonseca, Sara Magno, Catarina Melita, Lílíana Fernandes, Zélia Neves, João Machado
Hospital Prof Doutor Fernando Fonseca, Lisboa, Portugal

Introduction

Antiphospholipid (aPL) syndrome and non-Hodgkin lymphoma (NHL) association has been described, although with diverse clinical and laboratory presentation. We report a case of histological transformation of NHL that presented as positive aPL antibodies.

Case description

78-year-old woman, treated for Follicular Lymphoma with complete remission 20 years ago.

Twelve months prior to the current episode, routine lab tests revealed unexplainedly elevated PT, aPTT and INR between 2-5, despite normal liver function.

Six months later, she was hospitalized presenting asthenia, fever and weight loss.

Physical examination was negative for palpable adenopathies. Thoracoabdominal CT revealed de novo voluminous splenomegaly and multiple mediastinal adenopathies, which EBUS guided biopsy was negative.

Blood tests revealed normal platelet count, PT 44.9s ec, INR 4.1, aPTT 81.4 sec, D-dimer 5619 µg/L and low fibrinogen 1.4 g/L.

Hemoculture, myeloculture and main viral serologies, except for EBV, were negative.

Serum analysis showed low activity of factors II, V, VII, VIII, IX. No response to vitamin K was observed. Mixing study failed to normalize PT and aPTT, suggesting the presence of inhibitors for both intrinsic and extrinsic pathways.

Immunoelectrophoresis revealed monoclonal IgM lambda spike of 1157mg/dl and marked IgA and IgG hypogammaglobulinemia.

Positive IgM for anticardiolipin and antiβ₂-glycoprotein I was found. The lupus anticoagulant (LA) assay was strongly positive, admitting an IgM paraproteinemia with LA activity.

Of note is the absence of hemorrhage, making DIC hypothesis less likely, or thrombotic events with negative abdominal doppler ultrasound.

Immunophenotyping revealed monoclonal B lymphocytosis and high-intensity lambda chains expression. Bone marrow biopsy provided definitive diagnosis of infiltrative diffuse large B-cell lymphoma associated with EBV.

The patient started chemotherapy evolving with poor clinical outcome.

Discussion

Autoantibodies acting as acquired inhibitors of coagulation are often associated with malignancies. Cases of intrinsic and extrinsic

pathway involvement, with such number of factors affected are remarkably rare.

Our case, together with the main suspicion of NHL, confirmed by bone biopsy, presented several months before with abnormal PT and aPTT. Exhaustive workup revealed positive aPL antibodies along with monoclonal IgM lambda.

We emphasize this unusual presentation of NHL related to aPL syndrome in association with rare monoclonal IgM with LA activity.

#1810 - Case Report

CASE REPORT: A 53 YEAR-OLD MAN WITH LYMPHADENOPATHIES, PLEURAL EFFUSION AND DYSPNEA

Fabiana Santos Muñoz, Mariana Ramos Martins

University Hospital Center São João (Centro Hospitalar Universitário de São João), Porto, Portugal

Introduction

Malignant pleural effusions (PEs) are the second leading cause of exudative effusions and is seen in up to 10% of Non-Hodkin Lymphoma (NHL) at diagnosis.

Lymphadenopathies, beside being a common sign of lymphoproliferative disorders, it can also be present on infectious diseases like mononucleosis and tuberculosis or autoimmune diseases like Systemic Lupus Erythematosus (SLE) and sarcoidosis.

Case description

A 53-year-old man was admitted to the ER with dyspnea. On physical examination the patient presented with tachycardia, polypnea, hypoxemia and an absent murmur on the right hemithorax with whizzing on the left hemithorax, multiple adenomegalies and hepatosplenomegaly. Analytic exams showed microcytic anemia, elevated inflammatory markers, elevated Beta-2 microglobulin, angiotensin converting enzyme (ACE) within the normal range and were negative for HIV. The X-ray showed a white out lung on the right hemithorax, consistent with PE with passive lung atelectasis. The CT showed hepatosplenomegaly, a mediastinic conglomerate (49x39cm) and multiple axillary, jugular, supraclavicular, celiac and lombo-aortic lymphadenopathies. The placement of a tunneled pleural catheter was performed with drainage of a sero-hematic pleural fluid with criteria of an exudate, pH 7.25, glucose of 73 mg/dl, ADA 41U/L and B lymphocyte predominance in the immunophenotyping. Blood, urine, pleural fluid and sputum cultures (bacteriologic and micobacteriologic) were negative. Due to daily pleural fluid drainage ~600-700cc, a bronchofibroscopy was performed, which showed bilateral patent airway and an inconclusive cytology of the product obtained by TBNA. Fine-needle aspiration for cytology was compatible with B lymphoma and showed an abnormal population of T-cells.

Discussion

Lymphoma is a relatively frequent etiology of malignant PEs, yet the real prevalence of PEs in lymphoma patients is inconsistent

and their prognostic significance conflicting, probably due to the heterogeneous grouping of lymphoma subtypes and populations studied.

However, serous effusions due to malignancy including lymphoma are frequently symptomatic, and in case of pleural space, may be the presenting sign of cancer. Thus, a timely diagnostic approach and immediate onset of targeted treatment become of great importance in order to reduce symptoms and improve the quality of life of these patients.

#1817 - Case Report

HHV-8-POSITIVE HIV-NEGATIVE MULTICENTRIC CASTLEMAN DISEASE – A CASE REPORT

Maria Teresa Brito, José Cunha Marques, Ana Filipa Amador, Ricardo Moço Coutinho, Ana Carmo Valente, Ana Ribeiro, Paula Dias, Jorge Almeida

Internal Medicine Department - Centro Hospitalar e Universitário de São João, Porto, Portugal

Introduction

Castleman disease (CD) describes a heterogeneous group of lymphoproliferative disorders. Clinically it is divided in a localized form, which presents as a mass or swelling (Unicentric disease), and a multicentric type (MCD) characterized by fever, anemia, lymphadenopathy, hepatosplenomegaly and with a more aggressive behaviour; and subclassified according to the presence of Human Herpesvirus-8 (HHV-8). MCD accounts for 25% of cases; in HHV-8 positive group, more than half are in the context of human immunodeficiency virus (HIV) infection.

Case description

A 74-year old male had a previous history of anemia, trombocitopenia and bilateral axillary adenomegaly with inconclusive study (including bone marrow and lymph node biopsies) and clinical improvement after a corticotherapy cycle. Two years later he was admitted to the hospital due to weight loss, asthenia, anorexia and maculopapular rash in the trunk and back. His blood tests revealed pancytopenia (hemoglobin 7.7g/dL, leukocytes 2.55 and platelets $41 \times 10^9/L$), elevated erythrocyte sedimentation rate and C-reactive protein, hypoalbuminemia and hypergammaglobulinemia. Serologies for HIV, cytomegalovirus e Epstein-Barr virus were negative. Computed tomography revealed generalized lymphadenopathy (the largest lymph node with 25x18mm), small pleural effusion and splenomegaly. Bone marrow biopsy only found reactive changes. A lymph node was excised and histology revealed characteristics of multicentric Castleman disease associated with HHV-8. HHV-8 viral load was 3.8×10^4 copies/mL (4.5 log). He started treatment with prednisolone 1 mg/kg/day and rituximab 375 mg/m²/week. He presented a poor response to therapy with worse performance status, transfusion-dependent anemia and evolution to multiorgan dysfunction and death 3 weeks after treatment onset.

Discussion

HHV8-positive HIV-negative MCD is a rare disorder with a pathogenetic mechanism that seems to involve dysregulated cytokine activity, which causes systemic inflammatory symptoms and lymphadenopathy. Its treatment remains uncertain. As CD20 is variably expressed by HHV-8 infected cells, anti-CD20 monoclonal antibody, rituximab, seems to be a promising treatment for HHV8 positive MCD patients; however the response to treatment is highly variable. MCD is a disease with a poor prognosis with a 5-year mortality estimated in 35%; the HHV8 positive HIV negative subgroup has the more aggressive course.

#1818 - Case Report

AMYLOIDOSIS: THE CHALLENGE

Beatriz Porteiro, Mariana Costa, Filipa Nunes, Whine Pedro, Rodrigo Moraes, Marinela Major

Hospital Professor Doutor Fernando da Fonseca, Lisboa, Portugal

Introduction

Waldenström's macroglobulinemia (WM) is a uncommon disease (2% of all hematologic malignancies) characterized by a lymphoplasmacytic infiltration of bone marrow and elevated serum immunoglobulin M (IgM). The diagnosis requires a bone marrow biopsy. Hepatosplenomegaly and lymphadenopathy occurs in a minority of patients. Amyloidosis can rarely occur along with WM (3%) and should be considered in patients with concomitant lambda (λ) light chain in serum.

Case description

A 78-year-old woman had a 6-month history of weakness, anorexia, and weight loss with multiple urinary tract infections. She was hemodynamically stable, sub-febrile (T37,9°C) and dehydrated. Laboratory studies showed anemia (Hgb 6.8 g/dL), creatinine 2.52 mg/dL, proteinuria 1824.83 mg/24h, low serum albumin 2.62 g/dL, elevated serum IgM (1866.8 mg/dL) and free lambda light chains (70.57 mg/dL), serum immunoelectrophoresis showed a monoclonal band, which was confirmed to be immunoglobulin M λ at immunofixation. Imaging studies revealed multiple enlarged lymph nodes, hepatomegaly, pleural and pericardial effusions, kidneys had normal size; on echocardiogram changes in relaxation, pericardium thickening and a diminished global longitudinal strain were evident. Bone marrow biopsy was performed; a lymphoplasmacytic infiltrate was evident with immunophenotype suggesting WM diagnosis. The patient started rituximab, cyclophosphamide, and dexamethasone therapy. Her renal function had been worsening (maximum creatinine 6,11 mg/dL) and she was proposed for hemodialysis initially with good response. A kidney biopsy was performed and the diagnosis of amyloidosis was done.

After a follow-up time of one month despite therapy her disease progressed; she presented at the hospital, vomiting with oligoanuria and anasarca and she ended up dying.

Discussion

This case reports a patient with WM and concomitant systemic amyloidosis – AL diagnosis. She had renal and cardiac involvement; a kidney biopsy was central for the diagnosis - showed classic Congo red stain with apple green birefringence at polarized light microscopy. In these patients nephropathy seems to have an adverse impact on survival, specifically when renal function declines after WM treatment.

#1839 - Case Report

PERNICIOUS ANEMIA WITH ATYPICAL PRESENTATION

Anilda Barros, Rita Homem, Maria Garcia, Vanda Spencer
Hospital Garcia de Orta, Almada, Portugal

Introduction

Pernicious anemia (PA) is a subtype of megaloblastic anemia characterized by the malabsorption of vitamin B12 due to intrinsic factor (IF) deficiency. In most cases it originates from the autoimmune attack of gastric parietal cells where the IF is produced, being more frequent among people with northern Europe ancestry. The clinical spectrum includes hematologic and neurologic manifestations.

Case description

We present the case of a 48-year-old melanodermic man with moderate alcoholic habits, with no other relevant clinical history. Hospitalized for investigation of anorexia, asthenia, adynamia and paresthesias of the limbs with 2 years of evolution.

Physical examination showed conjunctival pallor, scleral icterus and distended abdomen with no palpable organomegaly; upon neurologic exam signs of symmetric peripheral neuropathy were found.

Analytically he presented pancytopenia and severe macrocytic anemia with concomitant signs of hemolysis. Lower levels of vitamin B12 and IF deficiency were posteriorly identified and direct Coombs test was positive. He performed a bone marrow evaluation documenting a markedly megaloblastic erythroid hyperplasia. Additional exams excluded the presence of malignancy or other autoimmune disorders. He was treated with parenteral cyanocobalamin and physical rehabilitation resulting in total hematologic and partial neurologic recovery.

Discussion

The authors highlight a rare presentation of PA as hemolytic anemia secondary to vitamin B12 deficiency. A classic complication of chronic severe PA is subacute combined degeneration of spinal cord which may lead to severe and irreversible damage. Although neurologic improvement often occurs over a longer period of time some may be irreversible depending on the severity and duration of the deficiency.

#1840 - Case Report

HEMOLYTIC ANEMIA AS INITIAL PRESENTATION OF DIFFUSE LARGE B-CELL LYMPHOMA. CASE REPORT

Marta Mendes Valentim¹, Catarina Moreira Neto¹, Ana Gameiro¹, Aluixa Lozada²

¹ Internal Medicine Department, Hospital Distrital de Santarém, Santarém, Portugal

² Anatomic Pathology Department, Hospital Distrital de Santarém, Santarém, Portugal

Introduction

Autoimmune manifestations are frequent in lymphoproliferative disorders. Many lymphomas are responsible for the production of autoantibodies, generating manifestations typically described in systemic autoimmune diseases, most of which are associated with non-Hodgkin lymphomas.

Case description

A 77-year-old woman with history of hypertension, diabetes and dyslipidemia; presenting with asthenia with 1 month of evolution was admitted. Physical exam showed right inguinal adenopathy and a left inguinal adenopathic conglomerate with stony consistency and adhered to deep planes.

Analytically: hemoglobin 5.9 g/dL, VGM 100 fL, RDW 17.5%, leukocytes 7.0x10⁹/L; neutrophils 79.3%, platelets 212x10⁹/L, reticulocytes 9.9%, urea 43.1mg/dL; creatinine 0.8 mg/dL; Na +133 mEq/L; K+4.6 mEq/L; bilirubin total 2.3 mg/dL; direct bilirubin 0.7 mg/dL; AST 39 U/L; ALT 12 U/L; LDH 576 U/L; PCR 1.37 mg/dL; B2 microglobulin 3900 ug/L, IgG 1165 mg/dL, IgA 249 mg/dL, IgM 60 mg/dL, C3 103 mg/dL, C4 20 mg/dL; ferritin > 2000ng/mL; B12 469 pg/mL; folates 4.0 ng/ml; iron 112 ug/dL; transferrin 169 mg/dL; haptoglobin <10 mg / dL, Coombs positive. Plasma protein electrophoresis: inflammatory pattern. Autoimmune study just a positive ANA 1/640. Blood smear: Anisopoikilocytosis, some target cells are observed, some dacrocytes, polychromilia, rare spherocytes. Myelogram: no infiltration. CT body scan: Numerous adenopathies in the following location: diaphragmatic, retroperitoneal, lateral-aortic, attached to external bilateral iliac vessels, hepatic wire, adjacent to the celiac trunk and bilateral inguinal area, suggesting a lymphoproliferative disease. PET-scan showed: Supra and infra-diaphragmatic adenopathies with avidity for FDG.

Incisional biopsy of the adenopathic conglomerate revealed: Non-Hodgkin's Lymphoma B, CD20 and CD30 positive, whose profile is suggestive of Diffuse large cell B-cell lymphoma (DLCLB). Initially the patient was unresponsive to corticosteroids therapy, which made us associated Cyclophosphamide until get the histological confirmation. After obtained it, R-CHOP was started.

Discussion

The diagnosis of an AIHA makes it necessary to discard a secondary cause of the disease. We present this case because of the rarity of the initial presentation of a DLCLB, poorly described in the literature, and cause of the difficulty of management.

#1842 - Medical Image

LUNG ADENOCARCINOMA MIMICKING THE RADIOGRAPHIC FEATURES OF MILIARY TUBERCULOSIS

Mafalda Ferro Teixeira, Tiago Barroso, Joana Caetano, José Delgado Alves

Hospital Professor Doutor Fernando da Fonseca, Lisboa, Portugal

Clinical summary

A healthy, non-smoker, 65 year-old woman presented to the emergency department with progressive dyspnea, non-productive cough, fatigue, anorexia and weight loss in the last month. Physical examination was unremarkable except for polypnea and cachexia. The chest X-ray (A) revealed a miliary pattern and the CT scan (B) showed a diffuse micronodular pattern, raising the suspicion of miliary tuberculosis. A bronchofibroscopy with lung biopsy was performed. Pathological examination showed pulmonary adenocarcinoma. Cultures of bronchial secretions and polymerase chain reaction for *M. tuberculosis* were negative. Staging revealed stage IV lung adenocarcinoma with brain, pleural and pericardial metastases (note cardiac silhouette enlargement on X-ray and pericardial effusion on CT scan – arrows).

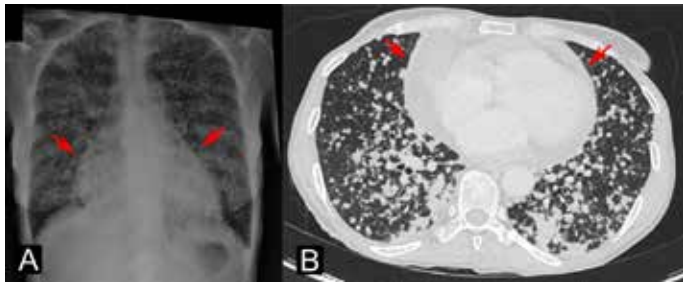


Figure #1842.

#1867 - Case Report

IMMUNE RECONSTITUTION INFLAMMATORY SYNDROME AS A CAUSE OF ARDS IN A NEUTROPENIC PATIENT

Maria Teresa Boncoraglio¹, Margarida Viana², Marília Silva², Diana Fernandes², Tatiana Salazar², Raquel Calisto², Adriana Alves², Luisa Guerreiro²

¹ Hospital Santa Maria Maior, Barcelos, Barcelos, Portugal

² Unidade Local de Saude de Matosinhos, Matosinhos, Portugal

Introduction

The immune reconstitution inflammatory syndrome (IRIS) is well characterized in the HIV-infected population. It has also been described in HIV-uninfected patients recovering from chemotherapy-induced neutropenia. IRIS is an exuberant and dysregulated inflammatory response to invading microorganisms. It manifests itself when a rapid restoration of host immunity from an immunosuppressed status towards a proinflammatory state occurs. This shift of host immunity produces a symptomatic disease with a paradoxical worsening of the patient despite adequate treatment.

Case description

The authors present a case of a 72 year old man with a history of large B cell lymphoma who was admitted with the diagnosis of febrile neutropenia after the first cycle of R-CHOP. He presented with pancytopenia - platelets 27000/uL, leukocytes 130/uL, neutrophils 100/uL, lymphocytes 30/uL and haemoglobin 11 g/dL. Granulocyte-colony stimulating factor and empirical antibiotic therapy were started on admission with piperacillin/tazobactam administered after blood cultures collection. Because fever persisted after 5 days antibiotics were escalated to meropenem and vancomycin.

The patient developed oral and genital herpetic blisters and the polymerase chain reaction for Herpes Virus simplex (HVS) 1 and 2 in the blood was positive. He was treated with intravenous acyclovir.

After 5 days, on par with the recovery of the peripheral leukocyte cell count (300/uL of lymphocytes) the patient developed progressive respiratory failure with no clear cause. Computed tomography revealed condensation of both upper lobes, suggesting acute respiratory distress syndrome (ARDS), accompanied by an increase of inflammatory markers.

There was no need for intubation, with fever and respiratory failure gradually improving in 7 days.

The diagnosis of HVS infection was assumed, probably due to chemotherapy-induced lymphopenia, complicated by immune reconstitution syndrome, expressed in the form of ARDS.

Discussion

The management of IRIS in non-HIV immunocompromised hosts is still unknown, the most common treatment is corticosteroids. Given the risk of corticosteroid-associated infection in immunosuppressed patients and the side effects of corticosteroids, only supportive measures were instituted. An expectant attitude might be the best approach at least in selected patients.

#1869 - Case Report

CUTANEOUS ANGIOSARCOMA MASQUERADING AS EQUIMOSIS

Ana Isabel Oliveira¹, Ana Pidal¹, Zara Soares¹, Helena Valente², Susana Ribeiro², Marta Quaresma¹, Patrícia Ramos¹, Sofia Cruz¹, José Barata¹

¹ Hospital de Vila Franca de Xira, Vila Franca De Xira, Portugal

² Unidade de Longa Duração e Manutenção ABEI, Vila Franca De Xira, Portugal

Introduction

Cutaneous angiosarcoma (CA) represent one of the rarest soft tissue neoplasms, comprising less than 1% of all sarcomas. Is highly malignant tumor vascular endothelial cells, that most often affects the elderly and has a very poor prognosis. Is a great clinical masquerader, mimicking a variety of benign and malignant tumors and reactive process. Histopathologically diagnosis is difficult, so many lesions require immunohistochemical studies, CD31 is the best marker.

Case description

Male, 81 years old, with a history of arterial hypertension; type II diabetes mellitus and ischemic stroke with hemorrhagic transformation that after hospital stay was referred to a long-term care unit. In this unit, after months of hospitalization, the patient showed an ecchymotic type skin lesion, with poorly defined limits in the right peri-orbital region. In one week, the lesion reached twice the initial size. The patient was referred to the Dermatology where the lesion was evaluated and biopsied, which proved to be inconclusive. About one month later, a new anatomopathological study was carried out, the analysis of which described a skin fragment with proliferation of small capillary vessels that permeate the collagen of the dermis and subcutaneous cellular tissue. He also described the existence of thin capillary vessel proliferation with immunohistochemical markings positive to CD31. In conclusion, the sample analyzed revealed the diagnosis of idiopathic CA. Axial cranioencephalic tomography was performed due to convulsive seizure, but the episode was not secondary and was interpreted as vascular epilepsy. He also underwent computed tomography (CT) of the chest, abdomen, and pelvis with no evidence of metastatic lesions. He was referred for a head-neck oncology visit, which, towards the patient's comorbidities and the rapid evolution of the lesion, was only indicated for palliative radiotherapy in case of hemorrhagic phenomena. The lesion had a rapid progression and the patient died 3 months after its appearance.

Discussion

CA of head and neck is a great mimicker with many presentations, like a hematoma.

Histologically angiosarcoma has variable features. Thus, a definitive diagnosis by histopathology may not always be possible. In such cases, immunostaining for markers will help. In our patient CD31 was positive favouring the diagnosis of a high-grade AC.

We would like to report this case for its rarity and to emphasize the relevance of clinical findings for suspicion and diagnostic referral.

#1877 - Abstract

PULMONARY THROMBOEMBOLISM AND CANCER: A SIX-YEAR OVERVIEW OF AN INTERNAL MEDICINE DEPARTMENT

Diana Neto Silva, Francisca Saraiva Santos, Gonçalo Mendes, Margarida Madeira, Daniela Brigas, Alexandra Gaspar, Eugénio Dias, Clara Rosa, Ermelinda Pedroso

Centro Hospitalar de Setúbal, Setúbal, Portugal

Background

Pulmonary thromboembolism (PTE) is a frequent diagnosis in the Internal Medicine department. About 20% of all PTE are associated with cancer. Cancer increases the risk of venous thromboembolism (VTE) in 3-6.5 times, when comparing patients with no cancer. Among VTE, PTE is the second most frequent cause of death in cancer patients. Certain types of cancer are associated

to higher risk of thrombosis which increases when patients are undergoing treatments. Data on tumor-specific PTE predictors is still controversial as well as the strategies to prevent these events.

Methods

A retrospective analysis of all the patients with the diagnosis of PTE, according to WHO – International Classification of Diseases (ICD), (codes 415.1 (ICD9) and I2699 (ICD10)), was performed, considering cases between January 1st 2013 and December 31st 2018 in Internal Medicine ward. Data was analyzed in order to determine the incidence of PTE associated with cancer diagnosis and identify the cancer type associated.

Results

A total of 215 patients with PTE were identified. The mean age was 70.8 years old (min: 20 and max: 99). Most of the patients were female (n=141) representing 65,6% of all the patients. 42 cases of cancer associated diagnosis (19.53%) were identified. Among them, 37 had a previous diagnosis of cancer and, in 5 cases, PTE was the first clinical sign that lead to cancer diagnosis. Gastrointestinal (GI) cancer was the most frequent type of cancer (n=12), with 8 cases of colorectal cancer, followed by breast cancer (n=7) and lung cancer (n=6). 11 patients were treated with chemotherapy, 6 of these have been treated in the past and 5 of these were under ongoing treatment at the time of the event. 16 were under anticoagulation 11 with warfarin and 5 with enoxaparin

Conclusion

There is a significant proportion of cases of PTE associated with cancer. The prevalence in our Internal Medicine ward was 19.53%, which corroborates the current standard of knowledge. The most frequent type of cancer was located in GI organs, supporting the association between type of cancer and risk of thrombosis. Currently, there are scores, such as ONKOTEV, which are promising tools that may help us to decide about primary prophylactic anticoagulation in cancer patients. Afterwards, we could apply it in our patients and verify its impact on the morbidity and mortality. However, we also identified cases of PTE under prophylactic anticoagulation, which might suggest that further investigations on its efficiency are warranted.

#1880 - Case Report

PARANEOPLASTIC AUTOIMMUNE HEMOLYTIC ANAEMIA IN OVARIAN CANCER

Margarida Gaudêncio, Sara Faria, Marisa Rosete, Ivo Barreiro, Joana Antunes, Maria Rosário Marinheiro, Isabel Bessa, Amelia Pereira

District Hospital of Figueira da Foz, Figueira Da Foz, Portugal

Introduction

Paraneoplastic autoimmune haemolytic anaemia is a well-known phenomenon in patients with haematological malignancies, but it is relatively rare in solid tumours. In an analysis of solid tumour

cases with this paraneoplastic syndrome, the vast majority were secondary to lymphoma, lung, renal and colorectal cancer. However, this kind of anemia associated with ovarian cancer is extremely rare.

Case description

The case being reported is of an 82-year-old female patient that was referred from

Gynaecological consultation to the emergency department for anaemia with haemoglobin of 6.9 g/dL and worsening fatigue with 15 days of evolution. She denied any bleeding, dizziness, dyspnoea and chest pain. There was personal history of hypertension and dyslipidaemia. She was medicated with losartan 50 mg. The physical examination only showed mild conjunctival pallor. The laboratory results revealed haemoglobin of 6.9 g/dL, MCV 98 fL and RDW 15.6%. Further tests showed incompatibility ABO, LDH 570 IU/L, haptoglobin of 10 mg/dL, total bilirubin 0.64 mg/dL, reticulocyte of 4,1%, positive direct Coombs' test and a peripheral blood smear showing rouleaux and spherocytes all suggesting warm autoimmune haemolytic anaemia. Serology of Toxoplasmosis, Rubella, Cytomegalovirus, HIV, Hepatitis B and C were all negative. Anti-DNA ds 113 IU/mL (<15), with remaining negative autoimmunity. CA 125 441,80 U/mL (<35).

An eco-Doppler transvaginal scan from the Gynaecological consultation revealed hypoechoic adnexal mass.

Computed tomography scan also confirmed the presence of mixed right adnexal lesion with poorly defined limits accompanied by loculated ascites and implants which is suggestive of ovarian cancer with peritoneal carcinomatosis. The patient did not approve making a biopsy. She was treated with oral corticosteroids in a dose of 1 mg/kg. One week later, the Hb and reticulocyte count have improved.

Discussion

Even without histopathologic study, the diagnosis of stage IV ovarian cancer was assumed based on imagiological findings.

Paraneoplastic syndromes that have been described associated with ovarian cancer classified by system included neurological, connective tissue, haematological, dermatologic and endocrine systems.

Autoimmune haemolytic anaemia was initially reported in a benign dermoid cyst of the ovary in 1938, following that the association was described in a patient with pseudomucinous cystadenocarcinoma in 1945. Subsequently, a few cases have been reported on the literature.

#1890 - Case Report

WHEN IT IS NOT JUST A FEVER – LAW OF SERIES OF HEMATOLOGIC MALIGNANCIES

Teresa Tomásia Silva, Luís Vicente, Hugo Costa, Adriana Quitério, Rafaela Pereira, Rosario Blanco, Tiago Branco, Ana Baptista, Mário Lázaro

Centro Hospitalar Universitário do Algarve - Hospital de Faro, Faro, Portugal

Introduction

Fever is a frequent motive of admission in the emergency departments (ER), and the complexity of the differential diagnosis is a challenge. The authors demonstrate a series of cases of fever with different characteristics associated with cytopenia, that turned out to be related with different diseases of the same spectrum.

Case description

Case 1

Man, 80 years-old, antecedents of atrial fibrillation, hypocoagulation with apixaban, admitted in the ER with a 3-day fever and generalized pruriginous macular rash. Presence of multiple adenopathies. Serum analyses revealed normocytic normochromic anemia, normal white blood cell count, and 12% reactive lymphocytes on the peripheral blood smear. With the suspension of apixaban, the rash resolved. Underwent ganglionic excision, revealing a T-cell non-Hodgkin lymphoma.

Case 2

Man, 57 years-old, admitted in the ER with a 3 months history of peri-anal fistulae with abscess, under his fifth cycle of empiric antibiotherapy, started with complaints of matinal fever, asthenia and weight loss (6 Kg) for the past 2 weeks. Serum blood analyses and peripheral blood smear showed pancytopenia e 1% blasts with progression to 31% in 4 days, diagnostic of Acute Leukemia.

Case 3

Man, 73 years-old, with a history of fever for 1 day associated with asthenia e anorexia for weeks. Blood serum analyses showed severe pancytopenia. Medullary studies and immunophenotyping of peripheral blood revealed acute myeloid leukemia.

Case 4

Man, 86 years-old, undetermined anemia for 1 year, sent to the ER by his general practitioner with history of pancytopenia, fever, weight loss, asthenia and anorexia. In the ER, bilateral adenopathies and tibial petechiae. Serum protein electrophoresis demonstrated a homogeneous spike-like peak in a focal region of the gamma-globulin zone, due to IgM. Peripheral blood immunophenotyping confirmed lymphoplasmacytic lymphoma.

Discussion

Hematologic malignancies are to be kept in mind when thinking about the differential diagnosis of febrile syndrome. Their presentation can be with a variety of signals and symptoms. Early diagnosis is of the uttermost importance, and it has influence in the prognosis. Clinical history and peripheral blood smear take great part in the diagnosis.

#1900 - Case Report

ISOLATED PLEURAL EFFUSION AS FIRST CLINICAL MANIFESTATION OF FOLLICULAR LYMPHOMA

Guilherme Sapinho^{1,2}, António Donato³, Marta Sousa^{4,5}, João Meneses Santos^{4,5}, Rui Victorino^{4,5}

¹ Serviço de Hematologia e Transplantação de Medula, Hospital de Santa Maria, Centro Hospitalar Universitário Lisboa Norte, EPE, Lisbon, Portugal

² Laboratório de Genética, Instituto de Saúde Ambiental (ISAMB), Faculdade de Medicina, Universidade de Lisboa, Lisbon, Portugal

³ Serviço de Oncologia Médica, Hospital de Santa Maria, Centro Hospitalar Universitário Lisboa Norte, EPE, Lisbon, Portugal

⁴ Serviço de Medicina II, Hospital de Santa Maria, Centro Hospitalar Universitário Lisboa Norte, EPE, Lisbon, Portugal

⁵ Clínica Universitária de Medicina II, Faculdade de Medicina, Universidade de Lisboa, Lisbon, Portugal

Introduction

Pleural effusion complicates up to 30% of Hodgkin lymphomas and around 20% of non-Hodgkin lymphomas, mainly the T-cell subtype. Among B-cell neoplasms, diffuse large cell lymphoma shows the highest frequency, followed by follicular lymphoma. Although it is a common complication in the course of the disease, pleural effusion is only rarely reported as an isolated presenting feature of follicular lymphoma. We present one of such cases.

Case description

A 73-year old women was admitted due to a 1-week history of non-productive cough, dyspnea and fatigue. No fever, chest pain, weight loss or night sweats were reported. At examination she had dullness and abolished breath sounds over the lower right hemithorax. No lymphadenopathies, hepatosplenomegaly or ascites was noted. Blood gas test found PaO₂ 71.1 mmHg, PaCO₂ 41.5 mmHg and oxygen saturation 95.1%. Hemoglobin was 12.8 g/dL, leucocytes 8900/μL, platelets 221000/μL, lactate dehydrogenase 242 U/L and C reactive protein 2.90 mg/dL. Human immunodeficiency virus serologies were negative. Chest radiography revealed an opacity of the right lower lobe. The diagnosis of community acquired pneumonia with parapneumonic pleural effusion was admitted and empirical antibiotherapy was started. Upon radiographic worsening of the pleural effusion, the patient was submitted to thoracentesis and exudative pleural fluid with neoplastic cells was drained. Computed tomography revealed bilateral pulmonary embolism and multiple lymphadenopathies, including mediastinal, mesenteric and retroperitoneal lesions. Pleural fluid cytology first revealed CD20+ cells and the mesenteric mass biopsy identified a follicular lymphoma (CD20+, PAX-5+, CD79a+, bcl-2+, CD10+, bcl-6+, CD3-, CD5- and cyclin D1-). Pleurodesis and chemoimmunotherapy were performed. After an 8-month follow-up she remains asymptomatic and adenopathy regression was noted.

Discussion

Lymphoproliferative disorders should be considered among differential diagnosis of pleural effusion. Pleural effusion

mechanisms in lymphomas include primary pleural effusion, thoracic duct compression, venous obstruction and pleural infiltration, which seems to be the most relevant mechanism in this case. The case presented here highlights the possibility of pleural effusion as primary clinical manifestation of follicular lymphoma.

#1907 - Case Report

SÉZARY SYNDROME: A CASE STUDY OF CUTANEOUS T-CELL LYMPHOMA

Rosario Blanco, Rafaela Pereira, Ana Rita Clara, Ana Pimenta De Castro, Mário Lázaro

Centro Hospital Universitário do Algarve, Faro, Portugal

Introduction

Sézary syndrome (SS) is an aggressive leukemic variant of cutaneous T-cell lymphoma (CTCL), clinically characterized by the presence of erythroderma, with or without lymphadenopathy and atypical T cells (known as Sézary cells) present in the peripheral blood. SS and mycosis fungoides are the most common subtypes of CTCL, however SS is much more symptomatic, has a lower potential for remission, and lower expected survival.

Case description

A 90-year-old male patient sent from the Emergency department to an Internal medicine consult for hypotension and skin rash after being treated symptomatically numerous times. As past medical history he had diabetes mellitus type 2, arterial hypertension and prostate hyperplasia. This patient presented a 3 months-course of extensive pruritic erythematous rash, feverish sensation, profuse sweating, weight loss and cervical, axillar and inguinal lymphadenopathies. Peripheral blood test showed leukocytosis of 2,450/L and lymphocytosis of 13,800/L (64.3%) characterized as reactive and with a prominent nucleus. Computed tomography scan revealed multiple axillar and inguinal lymphadenopathies. Inguinal lymph node excisional biopsy revealed an altered architecture by a diffuse pattern of lymphocytes (CD3+, CD5+, CD4+, CD2-, CD7-, CD8-, CD20-, BCL6-, PD1-, CD10-, EBER-, TdT-) and dispersed CD30+ cells, consistent with T-cells lymphoma. Bone marrow biopsy was also consistent with T lymphoproliferative disease with abnormal T cells and positive phenotype for CD3/CD5/CD2/CD4 and negative for CD7/CD8/CD26/CD56. With all of the above, the diagnosis of Sézary syndrome was established and the patient was sent to a specialized Oncology-Dermatology Department.

Discussion

The initial onset of CTCL often is difficult to diagnose because of its similarity to many other non-malignant cutaneous pathologies. In the presence of a erythroderma, we should keep in mind SS as part of the differential diagnosis. The authors also would like to mark the importance of skin biopsy in cases where there is a cutaneous involvement, although it was not performed in this case, usually provides a great amount of information.

#1908 - Case Report

CONCOMITANT MGUS AND AA AMYLOIDOSIS – A RARE ASSOCIATION?

Ana Filipa Batista, Rui Ferreira, Joana Antunes, Marisa Rosete, Diogo Abreu, Sónia Campelo Pereira, Amélia Pereira
Hospital Distrital da Figueira da Foz, Coimbra, Portugal

Introduction

Monoclonal gammopathy of undetermined significance (MGUS) is an asymptomatic premalignant disorder, defined by a serum monoclonal immunoglobulin concentration <3 g/dL and a proportion of plasma cells in the bone marrow of $<10\%$ in the absence of end-organ damage. On the other end, amyloidosis is a rare condition characterized by deposition of abnormal protein filaments into extracellular tissue. There is an established relation between both multiple myeloma and MGUS and L chain-type amyloidosis (AL), whereas there is no association with amyloid A (AA) amyloidosis, classically associated with sustained chronic inflammation.

Case description

The authors present the case of a 67-year-old male, presented to our Internal Medicine Consultation with a 1-year history of bilateral palpebral edema and nasal stuffiness associated with rhinorrhea that worsened by night and improved during the day. Any other symptoms were denied. There was no history of personal or family relevant diseases. Clinical examination was normal, except for bilateral palpebral and nasal edema. He was prescribed antihistamine and topical corticoid, with no relief. Further investigation included a cranial magnetic resonance imaging, that only showed an inflammatory polyp. Serum protein electrophoresis showed a single narrow peak, later characterized as IgG/kappa monoclonal paraprotein and the marrow biopsy revealed a 0.4% proportion of plasma cells. There was no evidence of other organs' involvement, thus confirming MGUS. As primary amyloidosis posed as a potential diagnosis, we performed a direct biopsy of the eye-lid, which confirmed the presence of amyloid deposits. Amyloid typing was positive for AA amyloidosis. The patient was then referenced to a specialized consultation and he is currently under surveillance.

Discussion

Even though the etiology of AA amyloidosis was not totally clear, based on the lack of a status of chronic inflammation other than the one caused by the MGUS itself, it definitely raises awareness for the importance of the immunostaining of amyloid, as this particular type may be frequently overlooked, as most assume the direct association between MGUS and AL amyloidosis.

#1917 - Case Report

IFOSFAMIDE-INDUCED PARTIAL FANCONI SYNDROME AND THE ROLE OF POTASSIUM-SPARING DIURETICS

Federica Parlato, Pedro Silva Gaspar, Rita Limão, Margarida Andrade, Sandra Braz, Rui Victorino
Centro Hospitalar Universitário Lisboa Norte, Lisbon, Portugal

Introduction

Ifosfamide (IFX) is an alkylating antineoplastic prodrug used to treat a variety of solid tumors and with well known renal toxicity, ranging from tubulopathy to acute renal failure. IFX-induced proximal tubulopathy has been reported in less than 5% of patients being relatively common in children but rare in adults. IFX toxic metabolite chloroacetaldehyde is believed to induce proximal renal tubular dysfunction which can cause partial or full Fanconi Syndrome (FS) characterized by impaired tubular reabsorption of aminoacids, glucose, phosphate, urate and/or bicarbonate.

Case description

A 41-year-old black woman with locally invasive sarcoma of the right femur was admitted because of severe hypokalemia (1.8 mmol/L) and a 3-day history of generalized weakness, vomiting and constipation. Sarcoma had been diagnosed 1 year earlier and the patient received neoadjuvant chemotherapy (5 cycles of IFX and doxorubicin) and radiation therapy to the right thigh. She had multiple previous hospitalizations, since first IFX administration, due to severe hypokalemia which was attributed to gastrointestinal losses. On clinical examination she presented hypotensive, dehydrated and had reduced bowel sounds. Blood tests showed normal glycemia, elevated serum creatinine (2.44 mg/dL), hyponatremia (134 mm/L), hypophosphatemia (1.1 mg/dL), hypomagnesemia (1.8 mg/dL), hypouricemia (1.0 mg/dL) and normal serum pH and bicarbonate (25.1 mmol/L). Her urine pH was 6 and a 24h urine collection showed elevated excretion of glucose (22.5 g) and proteins (1 g). The established diagnoses were partial FS and intestinal dysmotility due to severe hypokalemia. Intravenous fluid hydration, electrolyte replacement and potassium sparing diuretic were provided. Serum bicarbonate remained normal and the lowest serum creatinine was 1.73 mg/dL. Once kalemia normalized, the patient was discharged on oral potassium supplements and spironolactone. IFX was stopped and, a month later, the patient underwent tumor resection surgery.

Discussion

FS is a serious underreported condition and an often missed diagnosis. During IFX treatment, close serum and urine monitoring is required for early tubulopathy detection. Recovery of tubular function depends on IFX withdrawal but it can take months and be incomplete. There is no definitive treatment other than IFX withdrawal and electrolyte repletion. This patient was successfully medicated with spironolactone, in order to prevent further potassium secretion in the distal tubule and collecting duct.

#1927 - Case Report

AN UNUSUAL CASE OF SPLENIC MARGINAL ZONE LYMPHOMA AND NONBACTERIAL THROMBOTIC ENDOCARDITIS

Alda Tavares¹, Vasco J. Barreto², Cristina Gavina³, Joana Dos Santos⁴, Catarina Ala Baraças⁵, Fátima Braga¹, Alexandra Mesquita¹, Carlos Sottomayor¹

¹ Department of Medical Oncology, Hospital Pedro Hispano, Matosinhos Local Health Unit., Matosinhos, Portugal

² Department of Internal Medicine, Hospital Pedro Hispano, Matosinhos Local Health Unit., Matosinhos, Portugal

³ Department of Cardiology, Hospital Pedro Hispano, Matosinhos Local Health Unit., Matosinhos, Portugal

⁴ Department of Pathologic Anatomy, Hospital Pedro Hispano, Matosinhos Local Health Unit., Matosinhos, Portugal

⁵ Department of Radiology, Hospital Pedro Hispano, Matosinhos Local Health Unit., Matosinhos, Portugal

Introduction

Nonbacterial thrombotic endocarditis (NBTE) is a rare condition that is characterised by sterile deposition of thrombi and fibrin on undamaged heart valves. It is more commonly seen in chronic inflammatory states and it is associated with a high incidence of thromboembolic events. We report the case of an old woman with an inaugural diagnosis of splenic marginal zone lymphoma (SMZL) and NBTE.

Case description

An 81-year-old woman, with hypertension and prior stroke with no sequelae, presented to the emergency department in March 2013 due to an altered state of consciousness. She presented a constitutional syndrome and anaemia with 3 months of evolution. At admission, she had a febrile peak, cardiac murmur and palpable splenomegaly; haemoglobin of 5.9 g/dL, with a positive Coombs test and slightly elevated lactic dehydrogenase. Vegetations were documented on the aortic valve (the biggest with 6x11 mm). Empirical antibiotics were given. Splenomegaly of 19 cm of greater axis and retroperitoneal lymphadenopathies were also found. Peripheral blood immunophenotyping and bone biopsy findings were compatible with SMZL. Multiple and sequential blood cultures were sterile. Tests for the human immunodeficiency virus, cytomegalovirus, Epstein-Barr virus, Hepatitis B and C viruses, Q fever and Brucella species were negative. So, we assumed SMZL on stage IVB, associated with autoimmune haemolytic anaemia (AIHA) and NBTE. Prednisolone 1 mg/kg/day was initiated, with gradual clinical and analytical improvement, and then anticoagulation and chemotherapy with R-CVP (rituximab, cyclophosphamide, vincristine and prednisolone) were started. By 2014 she had no evidence of illness. In 2016 she had a clinical recurrence (constitutional syndrome and fever) and positive immunophenotyping. She was unfit to chemotherapy, so she underwent splenectomy in October 2016. Now, she is 87 years old, and she presents asymptomatic and with good performance status.

Discussion

The authors describe an uncommon case of SMZL in stage IV, in which the initial manifestation was a NBTE (without thromboembolic event) and AIHA – a rare combination. A high index of suspicion is needed when a clinician is faced with a patient who has cardiac vegetations and persistent negative blood cultures. Controlling the underlying disease and systemic anticoagulation are the most important factor in the treatment of NBTE. Despite the severe and relapsing presentation, this elder patient already has a long survival since diagnosis.

#1929 - Case Report

A RARE CASE OF EXTRANODAL NON-HODGKIN LYMPHOMA

Marta Cerol, Natália Teixeira, Ana Vera Cruz, Margarida Pereira, Marta Beja, Rita Paulos

Hospital Distrital de Santarém, Santarém, Portugal

Introduction

Non-Hodgkin lymphoma is a group of malignant neoplasms derived from B cell progenitors, T cell progenitors, mature B cells, mature T cells or natural killer cells. It usually presents with lymphadenopathy and systemic complaints, the latter associated with more aggressive disease, but 10 to 35% will have primary extranodal disease at diagnosis, the most prevalent being the testis, bone and kidney.

Case description

We present the case of a 75-year-old female patient with a history of depressive syndrome who presented to the emergency department with two-month complaints of diarrhoea and weight loss. She had made an abdominopelvic computerized tomography in ambulatory that showed ascites and densified areas in the peritoneum compatible with peritoneal carcinomatosis. Abdomino-pelvic MRI confirmed the other findings. The observation was unremarkable except for an increase in the abdominal perimeter and the palpation of a mass of petrous consistency in the left flank. The patient chose to be investigated in the ambulatory setting. A computerized tomography biopsy to the peritoneal densified area showed chronic inflammatory infiltrate. As the patient clinical condition progressively worsened, with prostration, leg oedema, constipation and urinary obstruction, needing placement of bilateral urgent nephrostomy, the patient was admitted to the hospital for further study. Considering the high suspicion of a neoplastic disorder, a second peritoneum infiltrate biopsy was ordered which showed CD20, CD3 and Bcl6 positive cells, with a Ki-67 expression of 100%. The histologic diagnosis of non-Hodgkin diffuse large B cell lymphoma was made. A gynecologic evaluation was ordered, the ultrasound evaluation was unremarkable and the colposcopy showed the presence of nodular formations in the upper third of the vagina, the biopsy of which was positive with the same cells of the peritoneal biopsy. After the diagnosis, as the patient status deteriorated, treatment with CHOP was initiated. Despite the initiation of chemotherapy, the patient condition worsened and she died two days after the first treatment.

Discussion

The presentation with primary gynecologic lymphoma with retroperitoneal and epiploon infiltration is rare. This patient presented with an aggressive high proliferative index disease with prolonged systemic complaints and an International Prognostic Index of 5, which classified her disease as having a bad prognosis.

#1941 - Case Report

SILENT KILLER - A CASE OF A RARE DISEASE WITH A RARE PRESENTATION

Pedro Madeira Marques¹, Luís Val Flores²

¹ Hospital de Vila Franca de Xira, Povos, Vila Franca de Xira, Portugal

² Hospital de Vila Franca de Xira, Povos, Vila Franca De Xira, Portugal

Introduction

The blastoid subtype of Mantle Lymphoma is one of the most aggressive forms of lymphoma. In this work we present one case of this disease with an atypical presentation.

Case description

Male patient, 75 years old, with known past history of paroxysmal atrial fibrillation, arrived at our Emergency Department with a two months history of orthopnea and paroxysmal nocturnal dyspnea. Objectively he was hemodynamically stable, with a peripheral oxygen saturation of 85%, with an emaciated appearance. Cardiac and pulmonary auscultation revealed arrhythmical cardiac sound but no signs of stasis. He had also peripheral edema. Analytically he had lymphocytosis (6810 cells/uL) and radiologically an enlarged mediastinum and left pleural effusion. Echocardiogram was normal. CT-scan showed multiple supra and infradiaphragmatic adenopathies and also splenomegaly, suggesting lymphoproliferative disease. Cytobiological exam of the pleural effusion was positive to exudative liquid, having also 16179 leucocytes, 15147 of which were mononuclear cells. Ganglionic biopsy revealed blastoid subtype of mantle cells lymphoma. The patient's clinical status declined within a few weeks, with multiorgan failure, and he died shortly afterwards.

Discussion

The blastoid subtype of mantle cells lymphoma is a rare variant of this lymphoma (10% of all mantle cells lymphoma, which itself constitutes 3-10% of all non-Hodgkin lymphomas). It affects the lymphatic ganglia, the reticuloendothelial system and bone marrow. The patients usually present themselves with fever, night sweats and weight loss. The blastoid subtype is more aggressive than the normal variant, and usually it is non-responsive to chemotherapy. In this case the patient had no past history of lymphoproliferative disease symptoms, and he survive two months without any therapeutics for this disease. We therefore call to attention the importance of a quick diagnosis and therapy initiation to try to reduce the very high morbimortality of this disease.

#1974 - Case Report

AN UNUSUAL TYPE OF PERNICIOUS ANEMIA – A CASE OF VITAMIN B12 DEFICIENCY WITH NEGATIVE AUTO ANTIBODIES

Ricardo Pereira, Ana Catarina Emídio, João Tavares, Inês Oliveira, Carolina Palma, Hugo Casimiro, Beatriz Navarro, Mário Parreira, Ermelinda Pedroso

Centro Hospitalar de Setúbal - Hospital São Bernardo, Setúbal, Portugal

Introduction

Pernicious anemia (PA) is a megaloblastic anemia resulting from vitamin B12 deficiency due to lack of intrinsic factor, in most cases secondary to autoimmune destruction of parietal gastric cells.

Case description

A 62-year-old man consulted his primary care physician with complaints of malaise, weakness, anorexia and weight loss of 7kg (10% of his body weight). A complete blood count was performed which revealed a severe macrocytic anemia (hemoglobin 3.9 g/dL and mean corpuscular volume 124 fL), leukopenia and a mild thrombocytopenia; the patient was sent to the emergency room. On physical examination he was pale, had a fever (38°C), tachycardia accompanied by a systolic heart murmur and evidence of congestive heart failure with peripheral edema. The peripheral blood smear revealed anisopoikilocytosis, oval macrocytes, hypersegmented granulocytes, and dacrocytes. In further laboratory evaluation there was a markedly elevated lactate dehydrogenase and total and indirect bilirubin, as well as a low haptoglobin. In the presence of macrocytic anemia and hemolysis additional testing was performed such as the measurement of serum cobalamin which was severely reduced. The intrinsic factor antibodies as well as parietal cell antibodies were both negative. An upper endoscopy revealed an atrophic gastritis of the gastric fundus.

Treatment was initiated with subcutaneous vitamin B12 and a quick rise in hemoglobin levels was observed, accompanied by a high reticulocyte count. The patient reported a marked improvement of his symptoms and the laboratory exams reverted back to normal ranges. Given the response to the therapy, the characteristic laboratory and upper endoscopy findings, despite the antibodies being negative, the diagnosis of PA was made and he was discharged medicated with cyanocobalamin.

The patient was evaluated periodically in an outpatient setting being asymptomatic ever since with laboratory exams within the normal range. Even though the thyroid function was normal, given the association of PA and thyroid disease, the patient was tested for thyroid peroxidase antibody which was positive. An ultrasound was then performed which revealed non-toxic nodular goiter.

Discussion

This case illustrates the rare occasion in which PA presents with negative parietal cell antibodies (10% of the patients with this disease).

#1983 - Case Report

ACUTE MYELOID LEUKEMIA - A FATAL DIAGNOSIS

Rosa Margarida Cardoso, Jorge Rodrigues, Margarida Monteiro, Manuela Vasconcelos
Hospital de Braga, Braga, Portugal

Introduction

Acute Myeloid Leukemia (AML) is a hematological neoplasm that can present with a broad spectrum of clinical manifestation.

Case description

74-year-old woman. Presented to the emergency department with two days of diffuse abdominal pain and melena. She reported asthenia, anorexia and weight loss with two months of evolution. At admission she had fever and was pale, hypotensive and tachycardic. Blood samples reveal a severe pancytopenia, high inflammatory parameters markers and an acute renal injury. Chest radiograph showed a right lower nodular opacity. The upper endoscopy was normal and the peripheral blood smear showed no evidence of circulating immature cells. A diagnosis of pneumonia with febrile neutropenia was made and she started broad-spectrum antibiotic therapy. Urinary antigens for *Streptococcus pneumoniae* and *Legionella*, and HIV I / II was negative. An unfavorable evolution was seen during the hospitalization, with increase respiratory failure and need for non-invasive ventilation and invasive ventilatory support (PaO₂ / FiO₂ ratio <100). A diagnosis of Acute Respiratory Distress Syndrome was made. A worsening pancytopenia without clinical improvement was seen despite support therapy with red blood cell transfusion, platelets and granulocyte colony stimulating factor (G-CSF). Myelogram and bone biopsy were performed, showing 52% of myeloid line blasts with dysplastic phenotypic traits of neutrophils and erythroid line (suggestive of AML secondary to myelodysplastic syndrome). After multidisciplinary discussion was decided that the patient did not have the conditions to start AML treatment. She died in the 13th day of hospitalization.

Discussion

The AML diagnosis should be weighed against patients with evidence of unclarified cytopenia and related symptoms. If it's untreated, it can be rapidly fatal, as in the case described. The prognosis depends on individual factors, such as the age of the patient and their comorbidities.

#2001 - Case Report

ESSENTIAL THROMBOCYTHEMIA PRESENTING AS A DIGITAL ISCHEMIA

Maria Inês Ribeiro, Maria Margarida Cunha, Melanie Ferreira
Hospital Garcia de Orta, Almada, Portugal

Introduction

Essential thrombocythemia (ET) is a rare myeloproliferative blood disorder, characterized by an overproduction of platelets.

Janus kinase 2 (JAK2) mutation is present in approximately 65% of patients. The clinical course of ET is marked by episodes of haemorrhage or thrombosis, although, the majority are asymptomatic. The major risk factors for thrombosis are age (>60 years), history of previous thrombotic episodes, presence of cardiovascular risk factors or JAK2 mutation. Cytoreductive therapy with hydroxyurea, anagrelide or interferon alfa are effective in preventing thrombosis in high-risk patients with ET.

Case description

A 68-year-old woman, with a medical history of smoking habits (15 pack-year) and hypertension diagnosed only 1 month before, was admitted with pain and cyanosis of the second right toe, associated with intermittent claudication during the last month. Initial therapy included high dose statin and anti-thrombotic therapy with low dose aspirin, assuming possible atherothrombotic cause. To determine the possible cause, blood tests were ordered showing slightly elevated platelet count of 600x10⁹/L (normal 130-400x10⁹/L); normal cholesterol levels and fasting glucose; automimmune and thrombophilia testing was negative; cardiac embolization was excluded by transesophageal echocardiography; blood cultures were negative for systemic infection; chest, abdomen and lower limbs computerized tomography angiography was performed without significant arterial or atherothrombotic disease. On postadmission day 8, worsening of symptoms with digital ischemia of second right toe, warranted urgent amputation of that toe. New blood tests ordered revealed an increasing platelet count peaking at 1000x10⁹/L. Due to persistence of thrombocytosis, initially considered reactive, a genetic study was performed for the ET (JAK2, myeloproliferative leukemia virus oncogene and calreticulin mutations), revealing positive JAK 2 V617F mutation. Cytoreductive treatment with high doses of hydroxyurea was initiated, with normalizing platelet count and symptoms. The dose of hydroxyurea was later tapered. After 1-year follow-up, platelet count has normalized with no further thrombotic or haemorrhagic events.

Discussion

Digital ischemia can be caused by several pathologies, some of which are rare, such as myeloproliferative diseases.

#2004 - Case Report

PRIMARY CHEST WALL NON-HODGKIN LYMPHOMA IN AN IMMUNOCOMPETENT PATIENT WITHOUT PREVIOUS PLEURAL DISEASE

Federica Parlato, Manuel Silvério António, Guilherme Sapinho, Margarida Andrade, Sandra Braz, Rui Victorino
Centro Hospitalar Universitário Lisboa Norte, Lisbon, Portugal

Introduction

Malignant chest wall tumors usually arise from metastases or local invasion from adjacent malignancies. With respect to primary

malignant tumors, lymphomas are very uncommon, representing less than 2% the cases, and are typically associated with chronic inflammatory pleural disease. Diffuse large B-cell lymphoma (DLBCL) is the most common subtype. We herein present a case of primary chest wall lymphoma in a patient with no history of pyothorax.

Case description

A 75-year-old man, with unremarkable medical history, presented with a recent growing upper left anterior chest wall mass, dyspnea at rest and fatigue. Physical examination showed an hard painless chest wall mass, measuring 10x8 cm, associated with collateral venous circulation in the upper third of the anterior left hemithorax and edema of homolateral upper limb. On clinical examination, breathing sounds were decreased in the left hemithorax and bilateral cervical and supraclavicular adenopathies were palpated. Blood tests revealed normal blood count, elevated lactate dehydrogenase (799 U/L) and negative HIV 1 and 2 antibodies. Computed tomography (CT) scan revealed a chest wall heterogenous mass measuring 16x14x8 cm, in the anterior-inferior aspect of the left hemithorax, and a large left pleural effusion. The mass extended to the homolateral axillary region, causing partial destruction of the fourth rib, and into the chest cavity causing partial incarceration of great mediastinal vessels. The CT scan showed marked reduction of left brachiocephalic venous trunk lumen, mediastinal and supra-clavicular enlarged lymph nodes and multiple lung nodules suggestive of metastases. A biopsy of the thoracic mass was done and histopathology revealed diffuse lymphoid proliferation of large cells with vesicular nucleus and prominent nucleoli. Immunohistochemistry showed the tumor cells to be strongly positive for CD20, bcl-2, bcl-6 and mum-1 and weakly positive for C-myc and negative for CD10 and Epstein-Barr virus-Encoded RNA (EBER). The patient was diagnosed chest wall DLBCL, non-germinal center subtype, clinical stage IV and immunochemotherapy (R-CHOP) was initiated.

Discussion

Primary chest wall lymphoma, occurring in immunocompetent patients without history of chronic tuberculosis or pyothorax, is a clinical rarity representing less than 1% of extra-nodal lymphomas. Biological and clinical characteristics of these lymphomas are still poorly understood and the disclosure of new cases will allow a better understanding of the disease.

#2007 - Medical Image

HEPATIC TUMOR INVADING INFERIOR VENA CAVA AND RIGHT ATRIUM

Telmo Borges Coelho, Mariana Brandão, Maria Alves, Paula Ferreira, Manuela Sequeira, Vitor Paixão Dias
Centro Hospitalar Vila Nova de Gaia Espinho, Vila Nova De Gaia, Portugal

Clinical summary

We present the case of a 72-year-old man with a history of excessive alcohol consumption and chronic liver disease.

The patient presented with an increase in the abdominal perimeter and generalized edema. He was hypotensive, jaundiced with high volume ascites.

During investigation very high alpha-fetoprotein was detected.

Magnetic resonance imaging showed of a 7 cm hepatic nodule with invasion of the inferior vena cava and right atrium, suggestive of hepatocarcinoma/cholangiocarcinoma.

The patient was discussed at an oncological group and proposed for liver biopsy for therapeutic decision but would eventually die due to worsening of his general condition.

The authors highlight this case for the extent tumor invasion, recalling the importance of an early diagnosis.

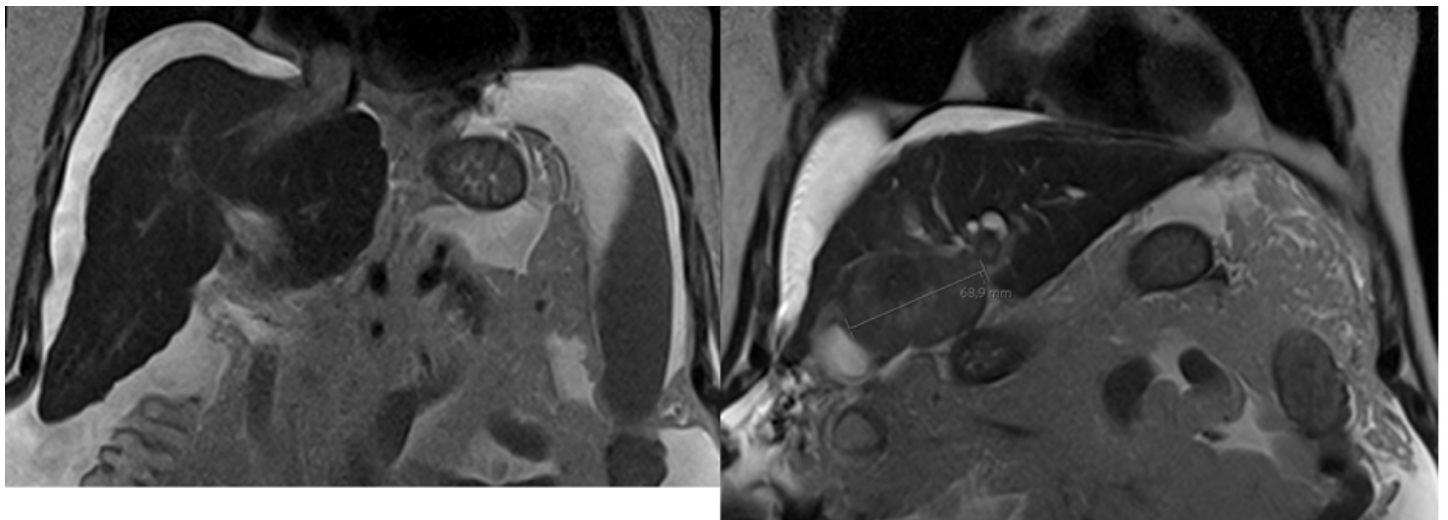


Figure #2007. Hepatic nodule with invasion of inferior vena cava and right atrium.

#2012 - Abstract

CASE SERIES OF PAGET-SCHROETTER SYNDROME IN NORTH OF GRAN CANARIA

Aída Gil-Díaz, Yolanda Raquel Castellano-Nogales, Eduardo González-Aragón, Jose María Robaina-Bordón, Dolores Pérez-Ramada, Héctor Rosario-Mendoza, Aicha Alaoui-Quesada, Yonay Ramírez-Blanco, Alicia Conde-Martel

Hospital Universitario de Gran Canaria Dr. Negrín, Las Palmas De Gran Canaria, Spain

Background

The Paget-Schroetter syndrome (PSS) in the context of upper extremity deep venous thrombosis (UEDVT) is an uncommon condition affecting young, healthy adults, in which secondary post-thrombotic syndrome can be a complication with major implications. The best treatment option remains controversial.

Methods

We performed an observational prospective study of all UEDVT diagnosed in our hospital during last 10 years. We collected the clinical characteristics, location of the UEDVT, treatment received, complications, sequelae and recurrences. We analyzed the association of PSS between categorical variables with Chi-square or Fisher test.

Results

66 patients were diagnosed of UEDVT, 14 of them were due to PSS (21.2%). There were 3 women (21.4%) and 11 men (78.6%), with an average age of 35.57 years old (SD 7.21, range 24-50). Comorbidities measured by Charlson index had an average of 0.57 points (SD 1.6). Average BMI was 24.48 (SD 3.02). All PSS occurred in outpatients. D-dimer was measured in 64.29% of them. 78.6% of PSS fulfill intermediate probability Wells criteria of DVT. The main location of DVT was in the subclavian vein (85.7%). All patients received initial treatment with LMWH during an average of 10.92 days (SD 6.1) and oral anticoagulation with acenocumarol during an average of 8.07 months (SD 3.65). Fibrinolysis was performed in 3 patients (21.4%). During the follow-up 2 patients (14.3%) developed recurrence of DVT in the clinical form of ipsilateral UEDVT, receiving surgical treatment. 6 patients developed the composed event of residual DVT, recurrence and major bleeding. PSS was associated with age below 43 years (RR 6.37, IC95% 1.46-26.32, $p=0.02$), Charlson index ≤ 1 point (RR 3.90, IC95% 1.19-12.66, $p=0.012$), Wells intermediate probability (RR 5.43, IC95% 1.69-17.54, $p=0.001$), D-dimer ≤ 1 (RR 1.21, IC95% 1.21-20.58, $p=0.017$), hemoglobin > 13 gr/dl (RR 4.32, IC95% 1.32-14.18, $p=0.008$), TTR control $> 60\%$ (RR 2.49, IC95% 1.01-6.14, $p=0.043$), fibrinolysis treatment (RR 3.75, IC95% 1.73-8.13, $p=0.038$) and no significant tendency to present residual thrombosis ($p=0.063$). There was no association with recurrences or post-thrombotic syndrome or bleeding complications.

Conclusion

PSS is more common in our series in young male patients with low comorbidity. Conservative treatment is the rule in our center,

receiving fibrinolysis low rate of patients. However there were neither more post-thrombotic syndrome nor residual venous thrombosis compared to UEDVT of other causes.

#2019 - Case Report

LYTIC BONE LESIONS IN A PATIENT WITH HEPATOCELLULAR CARCINOMA, MULTIPLE MYELOMA AND CHRONIC HEPATITIS B VIRUS INFECTION – A CHALLENGING CASE

Federica Parlato, Pedro Silva Gaspar, Manuel Silvério António, Guilherme Sapinho, Margarida Andrade, Miguel Moura, Sandra Braz, Rui Victorino

Centro Hospitalar Universitário Lisboa Norte, Lisbon, Portugal

Introduction

Bone metastases are a common manifestation of many types of solid cancers and bone involvement can also be extensive in patients with hematologic malignancies such as multiple myeloma and lymphoma. We herein present a patient with lumbar spine lytic lesions in whom the etiological investigation led to the diagnoses of hepatocellular carcinoma (HCC) and multiple myeloma (MM). Bone metastases occur in 2-25% of metastatic HCC and skeletal lytic lesions are present in approximately 60% of patients with MM at the time of diagnosis. Bone metastases are rarely described as first manifestation of HCC.

Case description

A 54-year-old black man with uneventful personal history presented with 6-weeks history of low back pain and fatigue. The pain was severe, not relieved by analgesics and exacerbated by movement. The patient performance status was good and on clinical examination he had right hypocondrium tenderness and back pain exacerbation with the flexion of left thigh. Blood tests showed hemoglobin 11.7 g/dL, elevated liver enzymes (AST 60 U/L, ALT 205 U/L, GGT 329 U/L, alkaline phosphatase 231 U/L), INR 1.34 and normal serum bilirubine, albumin, creatinine and calcium. Hepatitis B virus (HBV) serology was compatible with chronic infection and serum alpha-fetoprotein (943 ng/ml) was very elevated. Serum protein electrophoresis showed 2 bands in β and γ regions and serum immunofixation showed a biclonal component IgA lambda. Bone marrow aspirate smear showed an increase of plasma cells with 20% of total cellularity. Lumbar spine imaging studies revealed multiple lytic bone lesions on vertebral bodies from D6 to L2. On thoracic, abdominal and pelvic computed tomography (CT) scan the liver was slightly enlarged, with irregular edges and multiple confluent parenchymal nodules suggesting HCC. The diagnoses of HCC and MM were established and in order to discriminate the bone lesions aetiology, a lumbar spine CT-guided biopsy was done. Histopathology showed metastasis of HCC. The patient was started on sorafenib and is currently on follow-up.

Discussion

This case illustrates the challenge on aetiologic diagnosis of lytic bone lesions when two diseases with documented bone involvement are present. The coexistence of HCC and MM may reflect a common etiopathogenesis. HBV infection can result in chronic hepatitis, liver cirrhosis and HCC and was recently reported to be associated with increased risk of MM.

#2025 - Abstract

PREVALENCE OF ANEMIA IN TWO RANDOM DAYS OF A INTERNAL MEDICINE SERVICE

Domingos Sousa^{1,2}, Sérgio Antunes Silva¹, Ana Isabel Rodrigues¹, Rita Martins Fernandes¹, Catarina Jorge¹, Margarida Viana Coelho¹, Rui Osório¹, Elena Rios¹, Armindo Figueiredo¹

¹ Centro Hospitalar Universitário do Algarve, Faro, Portugal

² Faculdade de Ciências da Saúde - Universidade da Beira Interior, Covilhã, Portugal

Background

Anemia is a global public health problem. A recent study into the burden of anemia reported that in 2013 nearly 2 billion people or 27% of the world's population were affected, and while prevalence has decreased, the total number of people with anemia has increased over the past decade. Although anemia is more prevalent in developing countries it is also common in developed countries, particularly among hospitalized patients. With advances in medical technologies, diagnostics, therapies, and complex interventions, anemia is often a secondary consequence. Accordingly, hospital-acquired anemia (HAA) has been identified as a danger of modern medical care. The main causes of anemia are blood loss, decreased red blood cell (RBC) production, and hemolysis.

Our objective was to characterize the population of patients with anemia admitted to an Internal Medicine service of a central hospital on two random days in 2019 (6 of March and 3 April 2019).

Methods

Cross-sectional study based on consultation of the clinical files of patients admitted to the Internal Medicine Services of Faro's Hospital. Health Organization (WHO) criteria, hemoglobin values less than 12 g/dl in women and less than 13 g/dl in men, were used to define anemia. We excluded patients who had haemoglobin values behind 8.0 g/dl and received a blood transfusion during the last 2 weeks and patients on chemotherapy or radiotherapy.

Results

A total population of 280 patients with a mean age of 79.8 years was considered. The prevalence of anemia was of 41.2%. Less than 20% of the patients had been studied for the aetiology of the anemia with blood tests, upper digestive tract endoscopy or colonoscopy. Less than 10% of the patients with anemia was under iron therapy and/or folic acid and vitamin B12 during the 2 days of hospital stay included.

Conclusion

The prevalence of anaemia in hospitalized patients is high and strongly correlated with unfavourable outcomes: increase of length of stay, morbidity and mortality, whether it is present on admission or develops later during hospital stay.

Given the significant number of patients affected, there is a pressing need for greater knowledge of its mechanisms and causes. The reasons why a patient's Hb level may decrease during hospitalization can be very complex and multifactorial. Our observational study pointed the need of a thorough approach by the internist because anemia can be a challenging diagnosis and can be forgotten or despised if we do not consider a standardized definition.

#2026 - Case Report

AMYLOIDOSIS: A CHALLENGE OF INTERNAL MEDICINE

Francisca Saraiva Santos, Mário Parreira, Susana Marques, Ermelinda Pedroso

Centro Hospitalar de Setúbal, Setúbal, Portugal

Introduction

Amyloidosis is a heterogeneous disease caused by extracellular deposition of insoluble abnormal fibrillar protein aggregates in different tissues that alter their normal function. It can be acquired or hereditary, localized or systemic. Its classification depends upon the type of abnormal protein. The most common form of systemic disease is light chain (AL) amyloidosis, which results from the deposition of monoclonal immunoglobulin light chains. Amyloids can accumulate in liver, spleen, kidney, heart, nerves and blood vessels causing different clinical syndromes.

Case description

The authors present the case of a 57-year-old man with medical history of heart failure NYHA class III, hypertension, type 2 diabetes mellitus well controlled with oral antidiabetic therapy, obesity and obstructive sleep apnea-hypopnea syndrome, hospitalized as a result of community acquired pneumonia and acute kidney disease, with decompensated heart failure. Among other aspects, physical examination showed important macroglossia with slurring of voice, but no difficulty in eating, which would have been present for a year. Thus, after exclusion of angioedema, a biopsy of the tongue was performed and the anatomopathological analysis revealed, by the Congo red method and polarized light, the presence of amyloid substance. The patient was discharged for Internal Medicine outpatient clinic to continue the study of amyloidosis.

Discussion

Deposition of amyloid on the tongue is very rare and is almost always secondary to systemic amyloidosis, specifically with immunoglobulin light chain amyloidosis. Even so, until now, there is no monoclonal spike on serum protein electrophoresis and

urine analysis does not reveal the presence of proteins; there is no enlargement of the kidney or liver and, from the complementary study performed until now, a transthoracic echocardiogram showed concentric left ventricular hypertrophy with pericardial effusion, and an electromyographic evaluation was compatible with axonal sensory-motor polyneuropathy in the lower limbs, which doesn't seem to, but can also be related to diabetes. The patient is now awaiting cardiac magnetic resonance imaging to rule out or confirm the involvement of this organ.

#2027 - Medical Image

MULTIPLE HEPATIC METASTASES

Hugo Miguel Rodrigues Almeida¹, Beatriz Rodríguez², Sónia Canadas¹, Rita Fernandes¹, João Correia¹

¹ Hospital Sousa Martins, ULS Guarda, Guarda, Portugal

² Complejo Asistencial Universitario de Salamanca, Salamanca, Spain

Clinical summary

A 75-year-old woman, dependent on ADL with a history of psychiatric illness and hypertension, goes to emergency department for severe abdominal distension and lower limb edema. No other complaints. Physical exploration highlights extreme cachexia, pain and the presence of an abdominal mass in the right hypochondrium.

In the complementary diagnostic exams shows a cytocholestatic pattern without bilirubin elevation, elevation of inflammatory parameters and severe hyponatremia.

Chest X-ray showed bilateral pleural effusion and abdominal CT revealed hepatomegaly with multiple lesions of the hepatic parenchyma (larger dimension 8.5 cm) suggestive of metastases. Neoplastic lesion in the blind with peritoneal implants in the right iliac fossa (approx 2 cm).

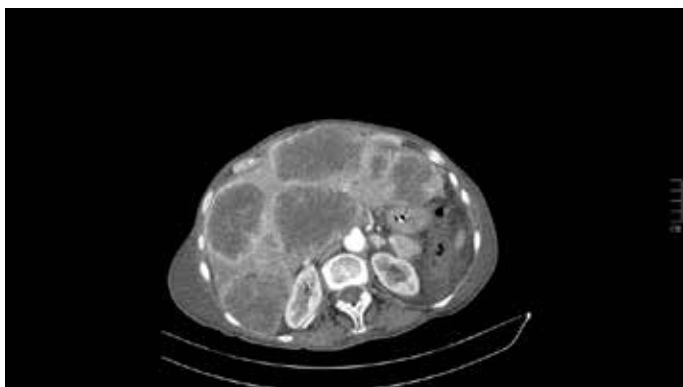


Figure #2027. Hepatic metastases.

#2028 - Case Report

IMMUNE THROMBOCYTOPENIC PURPURA – A CASE OF MULTIPLE RECURRENCE

Telmo Borges Coelho, Mariana Brandão, Maria Alves, Paula Ferreira, Manuela Sequeira, Vítor Paixão Dias

Centro Hospitalar Vila Nova de Gaia | Espinho, Vila Nova De Gaia, Portugal

Introduction

Immune thrombocytopenic purpura (ITP) is an acquired disorder caused by autoantibodies targeting platelet antigens. It is one of the most common causes of thrombocytopenia in otherwise healthy adults and is more prevalent in women. ITP is a diagnosis of exclusion, occurring in the absence of other hematological findings. Glucocorticoids (GC) and intravenous immune globulin (IVIG) are first-line therapies.

Case description

We report the case of a 49-year-old woman with ITP diagnosed at the age of 37. At the time of inaugural presentation, alternative causes of thrombocytopenia were excluded. Immunologic studies and serological tests were negative, and peripheral blood smear was unremarkable. Complete remission was achieved and platelet count (PLT) remained normal for several years. Since the diagnosis, 3 recurrence events (all with $PLT < 10.000/ul$) arose, being successfully treated with GC and IVIG. The patient then presented to our ER with recent-onset spontaneous ecchymoses, petechiae in the lower limbs and gingival hemorrhage. History was negative for trauma or medication use, but there was mention of previous H. pylori infection and an upper respiratory infection 2 weeks prior to admission. Remaining physical examination was normal. Laboratory tests showed isolated severe thrombocytopenia ($PLT < 10.000/ul$). The patient was admitted for recurrent ITP and started on Prednisolone (1 mg/kg/day) and IVIG (1g/kg), with subsequent PLT count recovery ($PLT: 66.000/ul$, 4 days later) and no further evidence of bleeding. Upon discharge, she maintained a Prednisolone scheme and was referred to the Hematology Department for reassessment.

Discussion

The described patient experienced multiple recurrent episodes of ITP in the twelve years that followed the initial diagnosis. The reported episode was preceded by a respiratory infection. Infections, particularly viral, have been suggested to trigger ITP. An association between H. pylori infection and ITP development was also reported.

In every relapse, the patient's platelet count was extremely low. Nonetheless, no major bleeding occurred, and remission was transiently accomplished with GC and IVIG. The current goal of ITP treatment is to prevent clinically important manifestations of thrombocytopenia, rather than obtaining normal platelet counts. However, in patients with recurrent severe thrombocytopenia, second-line therapies such as rituximab, thrombopoietin receptor agonist or splenectomy may be considered.

#2032 - Case Report

THROMBOTIC THROMBOCYTOPENIC PURPURA – A CASE STUDY HIGHLIGHTING CLINICAL SUSPICION AS A CORNERSTONE FOR DIAGNOSIS AND TREATMENT

Elsa Meireles, Mafalda Mourisco, Filipa Brochado, Luísa Pina Marques, Luís Teles, Ana Luísa Barbosa, Mariana Silva, Ana Lima, Joana Ferreira, Isabel Loureiro

Centro Hospitalar de Entre o Douro e Vouga, Santa Maria Da Feira, Portugal

Introduction

Thrombotic Thrombocytopenic Purpura (TTP) is a primary thrombotic microangiopathy defined by a severe congenital or immune-mediated deficiency in ADAMTS13. This rare condition has a high mortality rate if not treated promptly. Given that the results for ADAMTS13 activity are usually not readily available, its diagnosis and management rely on a strong clinical suspicion.

Case description

A 61-year-old female came to the Emergency Department reporting asthenia, emesis, periods of confusion and syncope, beginning 3 days before admission. Apart from a normocytic normochromic anemia known since the previous month, under oral iron therapy, she was otherwise healthy. The only significant findings on the physical exam were fever and a mild scleral icterus. The initial study revealed hemolytic anemia (with hyperbilirubinemia due to the indirect fraction, low haptoglobin and increased reticulocytes and lactate dehydrogenase), severe thrombocytopenia ($5000 \times 10^9/L$), and acute kidney failure. The peripheral blood smear documented schistocytes. There was no coagulation disorder (including fibrinogen), vitamin B12 deficiency or liver dysfunction. Blood cultures, direct Coombs test, viral and autoimmune serologies, work up for typical causes of anemia, immunoglobulin assay and immune tests (including anti-platelets autoantibodies) were all negative.

The clinical presentation (fever, acute renal failure, mild neurological disorder, severe thrombocytopenia and microangiopathic hemolytic anemia) and a high risk PLASMIC score (7 points) strongly suggested TTP. Treatment was initiated with methylprednisolone (1000 mg/day intravenously) and she was transferred to an ICU to perform plasmapheresis. She showed sustained clinical improvement, without further complications, and a steady platelet count rise, with $244000 \times 10^9/L$ platelets at discharge.

The results for ADAMTS13 activity came out later in the clinical course, showing severe deficiency (0%), formally confirming the diagnosis.

Discussion

TTP is a medical emergency whose treatment should not be delayed in the absence of ADAMTS13 activity measurements. In this case, clinical response and stabilization were achieved long before levels of ADAMTS13 activity were available, highlighting clinical suspicion as an anchor for successful management and patient survival.

#2037 - Case Report

HEPARIN INDUCED THROMBOCYTOPENIA - A CASE REPORT IN A ONCOLOGICAL PATIENT WITH VENOUS THROMBOEMBOLISM

Tatiana Gonçalves, Jorge Leitão, Arsénio Santos, Armando Carvalho

Internal Medicine Department A – Centro Hospitalar e Universitário de Coimbra, Coimbra, Portugal, Coimbra, Portugal

Introduction

Heparin-induced thrombocytopenia (HIT) is a serious complication and is associated with the formation of antiplatelet factor 4 antibodies (anti-PF4/heparin antibody). The HIT Type II is a rare and serious immune-mediated disease, causing thrombocytopenia 5 to 15 days after initiation of therapy. Paradoxically, there is a high risk of thromboembolic complications. The HIT Type II occurs in 1 to 6% of patients treated with non-fractionated heparin (UFH) and up to 0.9% of patients receiving low molecular weight heparin (LMWH).

Case description

We present a case of a patient of 66 years with a history of pancreatic cancer with liver metastasis. Admitted to the Internal Medicine Service for pulmonary thromboembolism very high risk (Pulmonary Embolism Severity Index V) and deep vein thrombosis of the left common femoral vein, treated with enoxaparin at therapeutic doses. During hospitalization, the patient had a progressive reduction in platelet counts and at the 11th day of hospitalization had a 91% reduction in relation to the initial platelet count. On suspicion of HIT, the anti-PF4/heparin antibody was required which was positive. Enoxaparin therapy was immediately discontinued and initiated the fondaparinux. Initially maintained low platelet values, with recovery to normal values at the end of the 20th day of hospitalization. Due to the high thrombotic risk and difficulty in performing fondaparinux in ambulatory, was started edoxaban without any intercurrentence to date.

Discussion

This case is about autoimmune thrombocytopenia in an oncological patient, with pulmonary thromboembolism and venous thrombosis of the left lower limb. The authors consider pertinent report this case because it is uncommon and the therapeutic decision are complex.

#2068 - Medical Image

LESER-TRELAT SIGN IN A SIGNET-RING CELL CARCINOMA

Catarina Teles Neto, Marta Valentim, Ana Gameiro, Luís Siopa Hospital Distrital de Santarém EPE, Santarém, Portugal

Clinical summary

80 year-old man presenting with weight loss, right hypochondrium pain and vomiting, with 1 year of symptoms evolution, was admitted.

Physical exam showed multiple hyperkeratotic lesions, distributing on trunk and dorsal region, a paraneoplastic sign knowing as Leser-Trelat sign (figure 1). Multiple nodular hepatic hypoechogenic formations were detected on the echography. Analytically: CEA 2627 ng/mL. CT body scan: lymphatic, pulmonary, suprarenal and hepatic metastasis, without evidence of the primary tumor. Upper endoscopy and colonoscopy were performed, without alterations. The Hepatic biopsy revealed: infiltration by well differentiated carcinoma, with mucus lakes and numerous signet-ring cells, whose immunohistochemical profile was compatible with origin in the gastrointestinal tract.

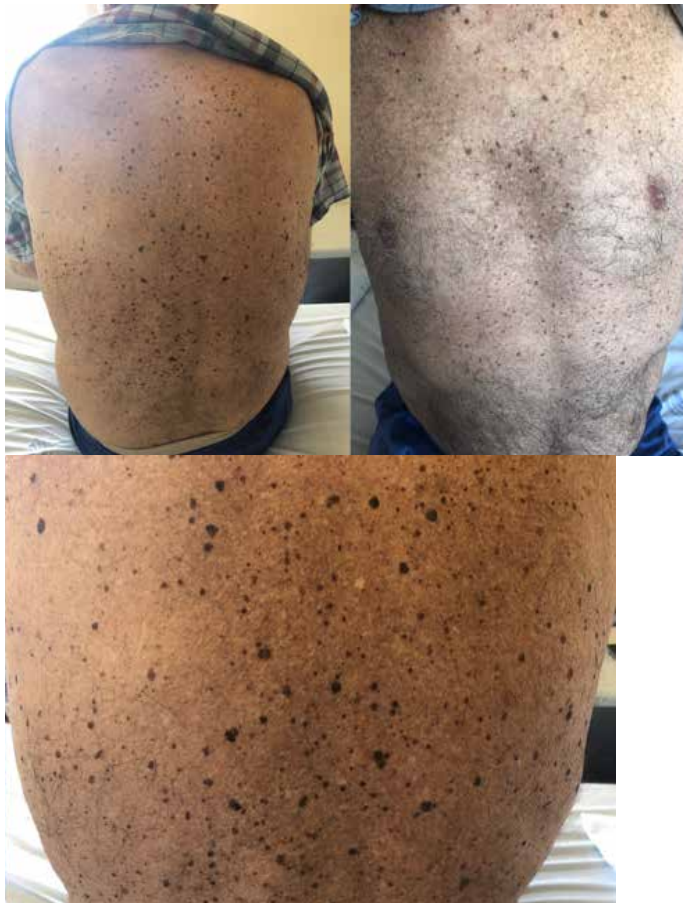

Figure #2068. Leser-Trelat Sign.

#2069 - Case Report

SYSTEMATICAL APPROACH TO CONSTITUTIONAL SYMPTOMS - A CASE REPORT

Alexandra Esteves, Ana Carvoeiro, José Costa Carvalho, Paula Felgueiras, Diana Guerra, Carmélia Rodrigues

Unidade Local de Saúde do Alto Minho, Viana Do Castelo, Portugal

Introduction

The classic triad of intermittent fever, nocturnal sweating and involuntary weight loss implies an aggressive diagnostic and systematic approach, as it can be found in hematologic malignancies, various inflammatory or rheumatologic conditions

or infections as tuberculosis, especially in progressive worsening presentations.

Case description

We present a 37-years-old man with complaints of recurrent fever (38°C), nocturnal sweating, anorexia and weight loss, later developing a painful discomfort of the right costal grid and hip which had begun insidiously some three months before. Thoracic computed tomography and magnetic resonance of the thorax revealed a lytic lesion in the middle part of the 8th right costal arch, several mediastinal adenopathies with reactive characteristics and an anterior mediastinal mass with 47 by 32 mm initially assumed as a non-atrophied thymus. About 3 months after the onset of complaints, the patient presented to the Emergency Department complaining of worsening symptoms. On physical examination he had mild pallor and an emaciated appearance. Additional study was unremarkable with a normal chest x-ray, complete blood count and smear and blood biochemistry showed only slightly elevated inflammatory parameters. The patient was discharged under a 7-day course of oral doxycycline. In follow-up he had complete resolution of fever and respiratory complaints. Blood and sputum cultures, interferon gamma release assay test, viral and bacterial serologies and extended immunological study came back negative. A surgical excisional biopsy of the anterior mediastinal lesion was performed, which finally confirmed the suspicion of lymphoproliferative disease. Histology was compatible with nodular sclerosing Hodgkin lymphoma. Patient started ABVD protocol, initially with refractory disease in the mediastinum after two cycles, later achieving complete remission after 6 cycles of the escalated BEACOPP protocol. Follow-up at 6 months showed complete remission.

Discussion

Hodgkin's lymphoma (LH) is a rare entity, accounting for only about 10% of lymphomas in developed countries. It mainly affects young adults or older patients in their sixth or seventh decade. Even in patients with advanced disease (stage III and IV) the response to treatment is favourable. As late complications of presentation are common several years after remission of the disease, long-term follow-up is crucial.

#2070 - Case Report

IMMUNOGLOBULIN LIGHT CHAIN AMYLOIDOSIS WITH CARDIAC INVOLVEMENT

Ramiro Lopes, Carlos Candeias, Teresa Salero, Rui Osório, Catarina Mendonça, António Moura

Internal Medicine - Centro Hospitalar Universitário do Algarve, Faro, Portugal

Introduction

Immunoglobulin light chain (AL) amyloidosis is the most common form of this disease with new 9 million cases diagnosed per year. Cardiac amyloidosis is a rare disease with poor prognosis and

a median survival of six months since the onset of heart failure symptoms. This can occur due to deposition of amyloid protein produced by monoclonal plasmatic cells, including multiple myeloma (MM) or Waldenström macroglobulinemia.

Case description

We report the case of a 54 year old men, with no known medical history. In the last four months, patient reported progressive exertional dyspnoea (New York Heart Association classification system of symptom severity (NYHA) IV), fatigue, orthopnoea and hands paraesthesia. Two months before the present episode had same symptoms and was admitted to the hospital. In the echocardiogram a concentric hypertrophy with a LVEF of 65% and restrictive diastolic dysfunction was found. Was treated with ivabradin, spironolactone, aspirin, furosemide and atorvastatin and was discharged. Was again admitted due to worsening of previous symptoms (NYHA III). Physical examination showed bibasilar crackles and hepatomegaly and no other significant findings. Laboratory findings showed anaemia, natriuretic peptide of 2530 pg/mL, Troponin I 1.159 ug/L, cholestasis, increased serum creatinin and urea with proteinuria of 2,045 g and a serum monoclonal component IgA/lambda. There were 28% of plasma cells in bone marrow (BM) aspirate.

The ECG had low voltage in the limb leads and cardiac magnetic resonance showed increased ventricular index mass (VIM) and global left ventricular late gadolinium enhancement.

Although the negative abdominal fat biopsy for amyloid protein, in the presence of IgA MM with kidney and liver dysfunction, the diagnosis of heart failure due to AL amyloidosis related cardiomyopathy (Mayo stage IIIb) was made.

Started treatment with cyclophosphamide, bortezomib and dexamethasone but due to repetitive syncopes with arrhythmia, underwent ICD placement.

After eight chemotherapy treatments, the patient had clinical improvement (NYHA I) with normalization of VIM, kappa light chains, cardiac biomarkers, liver enzymes and kidney function. BM transplantation was refused due to high mortality risk.

Discussion

The survival rate in AL amyloidosis depends on the gravity and extension of organ damage, and hematologic response to treatment. High level of suspicion and early diagnosis is the key for treatment success. The patient died 2 years after the diagnosis.

#2075 - Medical Image

MULTIPLE PULMONARY NODULES

Filipa Abelha Pereira, Daniela Barroso, Manuela Bertão

Centro Hospitalar Universitário do Porto - Hospital de Santo António, Porto, Portugal

Clinical summary

54-year-old man, ex-smoker, with increasing pain at the sacroiliac regions and lateral thoracic walls, anorexia, weight loss and

progressive asthenia. Without caught, bronchorrhea, dyspnea or pleuritic pain. Thoracic-abdominal-pelvic CT revealed a large lesion at the superior lobe of the right lung (7.3 cm) with center necrosis, multiple other lesions in both lungs, multiple adenopathy, metastatic lesions in the liver, right suprarenal gland, and a fracture at the third left rib. Anatomopathology revealed an invasive adenocarcinoma, of pulmonary origin. Positive KRAS mutation. A bone scintigraphy showed diffuse bone metastatic lesions.

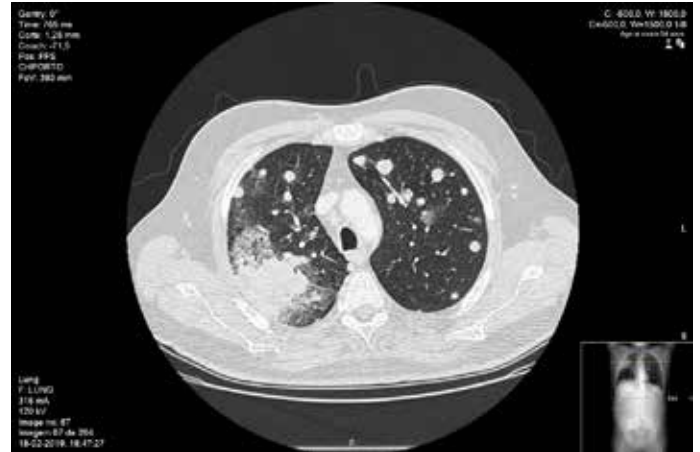


Figure #2075.

#2077 - Case Report

A RARE DISEASE, A COMMON PRESENTATION...

Leonor Coutinho Soares, Carolina Midões, Cleide Barrigoto, Umbelina Caixas, Helena Amorim

Medicina 1.4, Hospital de São José, CHULC, E.P.E, Lisbon, Portugal

Introduction

Lymphadenopathy represents a diagnostic challenge because of the multiplicity of potential etiologies. Infections, cancer, lymphoproliferative and auto-immune diseases must be considered.

Adult T cell lymphoma (ATL), is a peripheral T cell neoplasm associated with infection by the human T-lymphotropic virus, type I (HTLV-I), usually transmitted by bodily fluids, namely, through breastfeeding, unprotected sex and blood. ATL is an uncommon lymphoid neoplasm, and its incidence varies along with the HTLV-I infection prevalence.

Case description

40 years old Brazilian male, living in Portugal for 16 years, without any known disease or current medication. He had 2 tattoos and history of alcohol, tobacco and cocaine abuse.

Presented in the emergency room (ER) with anorexia, weight loss (16 kg), fever, night sweats and diffuse abdominal pain for 2 months. Lab tests and chest x-ray were normal. Abdominal-pelvic computed tomography (CT) showed celiac, mesenteric and peri-aortic enlarged lymph nodes suggesting lymphoproliferative

disease. Excisional biopsy of an inguinal node, showed an unspecific reactive process. He was then discharged to a hematology appointment but was again admitted to the internal medicine ward 3 weeks later for uncontrolled abdominal pain and to complete investigation. Initial blood tests showed mild leukocytosis and monocytosis, with elevated C-reactive protein; elevated liver enzymes and lactic dehydrogenase; HIV, HCV, HBV, EBV and CMV serologic tests were negative. Tuberculosis screening tests were also negative. Full body CT revealed a large abdominal and supraclavicular lymph-node conglomerate and stomach wall enlargement. Supraclavicular lymph node excisional biopsy suggesting ATL. Bone marrow aspiration and biopsy and upper gastrointestinal endoscopy with gastric biopsy was negative for tumor invasion. These findings, along with serologic antibodies to HTLV-I confirmed the diagnosis of a stage III ATL (Ann Harbour staging system).

The patient's abdominal pain was unremitting despite opioids improving only after steroid therapy. He was discharged after 13 days of hospitalization referred to hematology appointment for the initiation of chemotherapy.

Discussion

This case illustrates the approach to an adult with lymphadenopathy and how challenging it can be. It shows a rare type of lymphoma, specially in a non-endemic HTLV-1 area as Portugal. Globalization has been challenging for medicine in terms of differential diagnosis, making us think outside the box.

#2079 - Case Report

SICKLE CELL DISEASE AND TWIN PREGNANCY – IN REGARDS OF TWO CLINICAL CASES

Cátia Da Cruz Correia, Ana Cristiina Mestre, Ana Alves Oliveira
Hospital Distrital de Santarém EPE, Santarém, Portugal

Introduction

Sickle cell disease (SCD) is a common hereditary disease, presenting with anemia and intermittent severe pain. Pregnancy in these patients associates with high levels of maternal and fetal morbidity and mortality, an increased risk of thrombotic events and infections. Multiple gestations are also a well-known cause of high-risk pregnancy and the combination with SCD seems to give an even higher risk, but information available on this subject is sparse.

Case description

Case 1

A 29 years old black woman, with a history of SCD with elevated fetal hemoglobin, one prior full-term delivery and three miscarriages, was admitted during spontaneous twin pregnancy at 22 weeks with community acquired pneumonia and completed an intravenous antibiotic course. During a follow-up appointment thirteen days later, she complained of fatigue and mild chest

pain, without thorax imaging alterations and low molecular weight heparin (LMWH) was initiated with improvement of the symptoms. The remaining gestation was uncomplicated and ended at 37 weeks with a scheduled cesarean section (CS). Prophylactic LMWH was maintained for 6 weeks after the birth.

Case 2

A 22 years old black woman, with SCD diagnosed in early infancy, controlled until this current first twin pregnancy, having already had two pain crises, one leading to hospital admission 1 month before, medicated with folic acid and LMWH. At 33weeks she was admitted after presenting with persistent arthralgias, unspecific chest pain and hand palm itching. Given worsening anemia, increased total bilirubin, elevated hepatic markers and biliary acids, she received two blood units and initiated ursodeoxycholic- and acetylsalicylic acids. Five days later she developed a generalized seizure, stabilized with magnesium sulfate. Due to increasing liver markers and blood pressure, emergency CS was performed, with the birth of two healthy girls. There were no neurological deficits but cerebral imaging revealed an ischemic lesion, confirmed by electroencephalogram as being at the origin of the seizure. Levetiracetam, nifedipine and LMWH were introduced. At the follow up appointment 5 weeks later the patient had suspended all medication, but remained stable, with normal tensional values, no seizures, and was medicated with acetylsalicylic acid.

Discussion

These cases describe possible complications associated to pregnancies in SCD, showing the importance of the perinatal management measures that are indicated in SCD, but also the importance of patient compliance.

#2083 - Case Report

A TONSIL IN A MILLION!

Fani Ribeiro, Tiago Valente, Mariana Leal, Luísa Azevedo, Gorete Jesus

Centro Hospitalar do Baixo Vouga, Aveiro, Portugal

Introduction

Head and neck cancers can arise in oropharyngeal structures and include a variety of histopathologic tumors, mostly squamous cell carcinomas. Despite being rare, cancers of the tonsils are increasing in incidence, especially in developed countries. The main risk factors include tobacco use, alcohol consumption, human papillomavirus (HPV) infection and Epstein-Barr virus (EBV) infection.

Case description

A 44-year-old woman was referred to the Internal Medicine Outpatient Department after a 1 month growing lumps in the left side of the neck. Her primary care physician initially treated her with antibiotics without resolution. Her past medical history was irrelevant except for tobacco use. There was no history of odynophagia, change in voice, dental cavities, fever, night sweats

or weight loss. The remainder physical examination, including oral inspection and video laryngoscopy, was normal.

A computed tomography (CT) scan of the neck showed left suspicious submental and cervical lymph nodes. Thoracic and abdominal CT was normal. Laboratory exams including thyroid function, interferon-gamma release assay (IGRA) and serologies for EBV, cytomegalovirus, and toxoplasmosis were normal. A lymph node excisional biopsy revealed: lymph node metastasis of poorly to moderately differentiated squamous cell carcinoma. Upper gastrointestinal endoscopy was normal and cervical magnetic resonance showed: moderate hypertrophy of the palatine tonsils and hypertrophic lymphoid tissue of the base of the tongue. Positron Emission Tomography: high uptake in the left submental and cervical lymph nodes; moderate uptake in oropharynx lymphoid tissue. Blind biopsies of the oropharynx were then performed diagnosing a left tonsillar squamous cell carcinoma with HPV type 16 positivity. The patient started treatment and waits for follow-up.

Discussion

Despite many head and neck cancer patients initially present with a neck mass, the mucosally based primary site of origin may be difficult to identify as in the presented case. A high level of suspicion should be maintained, especially in risk groups such as smokers and alcohol consumers. Even in patients with these traditional risk factors, oropharyngeal squamous cell carcinomas, particularly those arising in the base of the tongue and in the tonsillar region may be associated with HPV.

#2086 - Case Report

NON-HODGKIN LYMPHOMA AND ANAL CANAL SQUAMOUS CELL CARCINOMA - A RARE COINCIDENCE

Ana Rita Gomes, Sofia Guerreiro Cruz, José Barata
Hospital Vila Franca de Xira, Vila Franca De Xira, Portugal

Introduction

Squamous cell carcinoma (SCC) is one of the most common anal canal malignancies, for which the treatment is well established and the prognosis is favorable. In regard to Non-Hodgkin Lymphoma (NHL), although the spleen is frequently involved in disseminated NHL, splenic presentation as the initial or only site of disease is uncommon. We report a case of SCC of anal canal and splenic marginal zone lymphoma (SMZL).

Case description

A 41-year-old female, presented with left hypochondrium pain and lumps in anal region. She has a past medical history of uterine cancer (hysterectomy at 26 years-old and anexectomy at 32 years-old). There was no history of smoking.

On evaluation, was identified hepatosplenomegaly and a polylobulated, ulcerated and friable lesion, located about 2-3 cm from the anal verge along anterior wall of perineum.

The patient was negative for HIV, Hepatitis B and C. Abdominal CT-scan revealed a 24cm large spleen and a 20cm large liver.

A laparoscopic splenectomy was performed, and the histopathological examination revealed small-sized mature B cells with round nuclei and basophilic cytoplasm- typical findings in SMZL. The biopsy of anal lesion and the histopathological examination revealed SCC and also an high grade anal intraepithelial neoplasia (AIN) lesion. The pelvic MRI scan revealed SCC stage T2N0M0.

The postoperative course was uneventful. The patient started radiotherapy and then chemotherapy. A recent abdominal CT-scanner revealed a 15mm nodule between the perineum wall and vagina, which is being followed.

Discussion

SMZL is an indolent NHL subtype that originates from B memory lymphocytes, present in the marginal zone of secondary lymphoid follicles. Splenectomy was the therapy of choice for decades, although there is a recent tendency to rituximab monotherapy. According to the European Society, after the diagnosis of symptomatic SMZL, splenectomy is made in cases refractory to rituximab, without lymphadenopathy, with splenomegaly and low surgical risk.

SCC is a dreadful condition. Radiotherapy can be considered for local control of the disease, but chemotherapy remains the best modality of treatment. The most important risk factor for SCC is behavior that predispose individuals to HPV infection. Other risk factors include a previous lower genital tract dysplasia or carcinoma, a history of smoking and HIV infection.

We present an unlikely association between two distinct entities, with a totally different approach, which is a rare and interesting coincidence.

#2093 - Case Report

ASSOCIATION OF TUBERCULOSIS AND ACUTE LEUKEMIA AS A CAUSE OF WASTING SYNDROME

Carlos Figueiredo, Bruno Mendes, Catarina Pires, Inês Gonçalves,
João Cardoso, António Guerreiro
Hospital Santa Marta - CHULC, Lisboa, Portugal

Introduction

Fever of unknown origin in a patient with wasting syndrome has a wide differential diagnosis.

Case description

A 60-years old black woman, from Cape Verde living in Portugal for the past 20 years, partially dependent in her daily activities, with a past history of stroke with gait disturbance, arterial hypertension and ethanolism, was admitted to an internal medicine ward due to functional deterioration. Subacute stroke was initially diagnosed with no evident according to the TOAST classification and motor rehabilitation was started. At

admission anaemia and neutropenia were also detected. During hospitalization progressive wasting and fever with no particular pattern was noted. Broad-spectrum antibiotic was started with little improvement, and persistent sterile blood cultures. Positive serologic results for Parvovirus, Chlamydia, Borrelia and Leishmania led to administration of directed antibiotic therapy, also unsuccessful. IGRA was also positive and HIV serology was negative. Computed tomography revealed enlarged paratracheal and iliac lymph nodes. After few weeks, peripheral blood smear showed 21% of myoblasts and myelogram was performed revealing 64% blasts with positive Sudan black B stain. Acute myelomonocytic leukemia was diagnosed but the patient had no clinical conditions to initiate chemotherapy. It was done lumbar puncture and flexible bronchofibroscope without alterations. Endobronchial ultrasound bronchoscopy was performed with puncture of mediastinal adenopathies showing no acid-alcohol resistant bacilli and negative NAAT. During hospitalization progressive physical decline was maintained with later death. Postmortem Mycobacterium tuberculosis was isolated in the samples retrieved from mediastinal lymph node biopsies.

Discussion

Fever of unknown origin with wasting syndrome is a diagnostic challenge. In this particular case positive serologic results were most likely cross reaction and delayed the definitive diagnosis, which was only completed post-mortem. Two concomitant diseases - acute leukemia and lymph node tuberculosis - were documented as the cause of the wasting syndrome and have real implication in therapeutic decision.

#2097 - Case Report

MARGINAL ZONE B-CELL LYMPHOMA ASSOCIATED WITH INTRACEREBRAL HEMORRHAGE: A CASE REPORT

Vasiliki Tsoutsouli, Lazaros Sideras, Georgios Charis Paskalis, Georgios Sidiropoulos, Dimos Foutsitsakis, Anna Xanthopoulou, Dimitrios Kazineris, Zacharo Sachla

Internal Medicine Clinic of G. Papanikolaou General Hospital, Thessaloniki, Greece

Introduction

Marginal zone B-cell lymphoma (MZBCL) is a rare disease which can be considerably difficult to recognize and diagnose when signs of systemic involvement are absent. We report a case of MZBCL complicated with intracranial hemorrhage.

Case description

A 50-year-old male patient with history of hypertension under therapy was admitted to the neurosurgery department, because of intracerebral hemorrhage. His blood pressure (BP) was elevated despite antihypertensive therapy. After Magnetic Resonance Imaging/Angiography (MRI/MRA) of the brain that showed no aneurysms, the neurosurgeons decided that the

cause was the unadjusted high BP. At first, the BP levels were promptly adjusted to normal levels with clonidine, amlodipine and irbersartan and then we searched for the cause of the hypertension. The laboratory investigation showed the presence of hyperalbuminemia, polyclonal hypergammaglobinemia 42,2g/dL (range 11-18,8), high levels of IgG immunoglobulin and high light chains in blood and urine. Abdominal and chest Computed Tomography scan revealed pathologically swollen lymph nodes around liver, stomach, mesenterium and nephric artery, in armpits, in the groin and in thorax mesangial. A left adrenal nodule of 1,6cm was also found, but the blood and urine tests for catecholamines, aldosterone, cortisol and renin were normal. There was strong suspicion of hematologic neoplastic disease. A bone marrow biopsy was performed. The patient had also a neck-lymph node biopsy. Both biopsies showed MZBCL. It is considered that the hyperviscosity of the disease with the combination of hypertension was the cause of intracerebral hemorrhage. The patient is under surveillance for MZBCL in a 3 year follow-up.

Discussion

Intracranial hemorrhage can be a rare complication of MZBCL. It is important to investigate the underlying cause of the hypertension at a patient without previous symptoms at a young age and not to characterize it as idiopathic.

#2099 - Medical Image

A STORY OF STOICISM AND THE DELAYED DIAGNOSIS AND TREATMENT OF STAGE IV LYMPHOMA

Joana M Esteves, Francisca M Pereira, Maria Teresa Boncoraglio, Miguel Costa, Marta Gomes, Carlos Oliveira
Hospital Santa Maria Maior, Barcelos, Portugal

Clinical summary

A 76-year-old man with a 2-year-old left painless axillary mass presented to the Emergency Department with complaints of new-onset swelling and painful ulceration (yellow arrow). He also showed cervical, submandibular, right-axillary (white arrows) and inguinal lymphadenopathies. CT scan confirmed a massive lymph node conglomerate arising from the left axilla and descending over the left hemithorax, a smaller right axillar conglomerate, a 6 cm splenic infiltrative mass, and a 6 cm perirenal mass. Upon biopsy of one cervical adenopathy and after exclusion of bone marrow involvement and subclinical infections, the diagnosis of stage IV, non-Hodgkin diffuse large B-cell vs. grade 3b follicular lymphoma vs. transformation/overlap of these two entities was made, and the patient started R-CHOP.

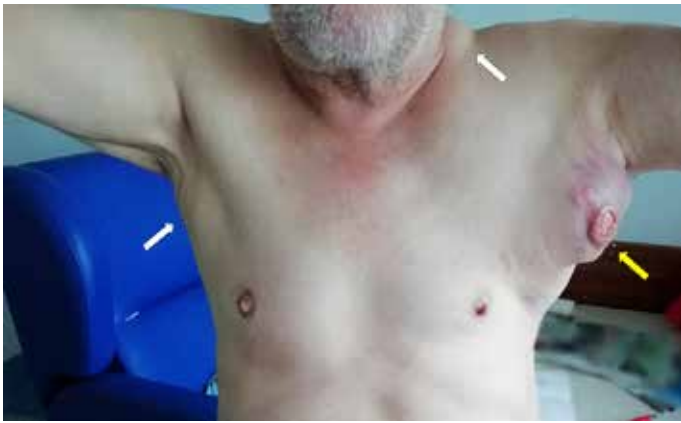

Figure #2099.

#2100 - Case Report

ONCOLOGIC EMERGENCY AS AN INITIAL PRESENTATION OF LYMPHOMA

David Paiva, Hélio Martins, Jorge Cotter

Hospital Senhora da Oliveira, Guimaraes, Portugal

Introduction

Oncologic emergency is an uncommon entity in the emergency department, but with a high mortality risk. The identification of this entity as well as the emerging approach of the diagnosis is very importante for a better approach to the patient.

Case description

A 54-year-old man, with dyslipidemia and smoking habits, was evaluated on the emergency department for complaints of asthenia, dyspnea and cervical pain with a week of evolution. Axillary and cervical adenopathies in study, with 4 months of evolution. At admission, patient with marked dyspnea and hypotension in dorsal decubitus, that relief in right lateral decubitus position. Analytically with leukocytosis without anemia or other analytical alterations of relief.

Head and neck computed tomography revealed bulging adenopathies dispersed throughout all cervical ganglion chains that exerted a compressive effect on the vascular structures, namely the internal jugular veins. Reduction of the caliber of the arterial column at the level of the oropharynx, more expressive near the free edge of the soft palate. An emergency tracheostomy was performed to protect the airway and a guided biopsy of the ganglionic chain was done. Histological result was compatible with a diffuse large B cell lymphoma and patient started chemotherapy treatment with R-CHOP scheme (cyclophosphamide, doxorubicin, vincristine, and prednisone plus rituximab), with a good response to therapy.

Discussion

Large B-cell non-Hodgkin's lymphoma may present as an acute manifestation, with rapid growth of adenopathies. Usually this lymphoma subtype presents a good response to therapy, although it depends on the stage that patient presents.

#2108 - Case Report

POST THROMBOTIC SYNDROME VS PARANEOPLASTIC SYNDROME AS INICIAL MANIFESTATION OF PANCREAS CANCER

Isabel Borges¹, Madalena Meneses¹, Luis Dias²

¹ Hopsital do Divino Espirito Santo, Ponta Delgada EPE, Ponta Delgada, Portugal

² Hospital do Divino Espirito Santo, Ponta Delgada EPE, Ponta Delgada, Portugal

Introduction

Post thrombotic syndrome (PTS) occurs in 20-50% of deep venous thrombosis (DVT) and is characterized by edema, skin redness, varicose veins, hyperpigmentation and, in severe cases, lipodermatosclerosis. Leg heaviness, pain, cramps, paresthesia and claudication, can also happen. The risk of DVT is high in patients with advanced-stage cancer (ASC), 20-25%.

Case description

We report a men, 56 year-old, with type 2 Diabetes mellitus and smoker (46pack-year), examined on the Eergency Department (ED), because of assimetric arthralgia and inflamatory signs of the knee, ankle and foot, with migratory pattern, that worsens at the end of the day. He also complaints of asthenia, anorexia, nausea and weight loss, about 20kg in 2 months. Because of assymetric lower limb (LL) edema, calf myalgia and claudication, he was evaluated by Vascular Surgery and Neurology specialities. On examination, he had no fever or signs of respiratory distress. LL showed ankle edema, redness of the right toes and medial face of both ankles, right gemelar pain without homans sign, and LL pulses wide and simetric. Blood tests (BT) revealed elevation of the inflamatory markers without an infectious focus (RCP 15.4 mg/dl), D-dimers 6000 ng/ml and NT-ProBNP 1560 pg/ml. On the thorax X-ray, there was a circumspect hipotransparency on the basis of the right hemitorax. On the LL X-ray, there wasn't relevant features. He was admitted in Internal Medicine ward for investigation. According to the clinical findings and risk factors, we admitted the possibility of paraneoplastic rheumathologic syndrome (PRS) or an unrecognised DVT. BT highlighted increased ferritin, sedimentation rate, neuron specific enolase, CA 15.3, CEA, CA 19.9, and eosinophilia; autoimune study was negative. He underwent a thorax-CT scan, that revealed pulmonar thromboembolism and LL ultrasonography showed DVT of the right ileo-femoro-popliteal vein and left femoro-popliteal vein. The abdominopelvic-CT scan revealed a pancreatic mass. Biopsy of the liver's nodules suggested a pancreatic adenocarcinoma (ACP). During his stay we verified pain control by the use of NSAIDs.

Discussion

Anatomically extensive and persistent leg symptoms one month after acute DVT are two of the major risk for PTS. In bilateral DVT, the risk of occult neoplasm exceeds 40%. PRS occurs in 10-15% of patients hospitalized with ASC and 50% will develop it in the course of the disease. Schmidt's triad is present in up to 10% of ACP.

#2114 - Case Report

FOLLICULAR LYMPHOMA WITH EXTRANODAL INVOLVEMENT: AN ATYPICAL CLINICAL PRESENTATION

Catarina Jorge¹, Tatjana Mihailovic¹, Sérgio Silva¹, David Dias², Domingos Sousa¹, Sara Duarte¹, Diana Reis¹, Armindo Figueiredo¹

¹ Algarve's University Hospital Centre - Faro Unit, Internal Medicine Department, Faro, Portugal

² Algarve's University Hospital Centre - Faro Unit, Oncology Department, Faro, Portugal

Introduction

Follicular lymphoma is the second most common type of non-Hodgkin lymphoma and usually has an indolent clinical presentation. The cervical, axillary, mediastinal and inguinal lymph nodal chains are commonly affected; extranodal involvement is less frequent.

Case description

A 70-year-old female who had been well until 2 months before presenting a pain in the left shoulder, without trauma, controlled with topical analgesics for 2 weeks. Because of persistence and increased pain intensity, the patient turned to the family doctor and she was medicated with non-steroidal anti-inflammatory drugs. However, due to persistence of uncontrolled pain, an imaging study with X-ray and CT scan of the left shoulder was requested, which revealed osteolytic lesion and subcapital humerus fracture with radiological characteristics showing aggressive lesion and rapid growth. The patient is hospitalized for investigation of the humeral osteolytic lesion with associated pathological fracture. Good general condition, without constitutional or B symptoms, or other focal symptomatology of organ or system. In the objective examination, small painless cervical adenopathies and one more left inguinal were identified; without other lymph nodal chains involved. Thoracic-abdomino-pelvic CT scan revealed retroperitoneal, mesenteric, iliac and left inguinal lymphadenopathies. Neck ultrasound showed submandibular adenopathies and infiltrative nodular lesions of the submandibular salivary gland. Biopsy of the humeral lesion and excisional biopsy of left inguinal adenopathy were performed. The histological study of the two biopsies revealed a follicular lymphoma grade 3A. Admitted Follicular Lymphoma, grade 3A and stage IV, with involvement of bone, salivary gland and cervical, retroperitoneal, iliac and inguinal lymph nodal chains. The patient was quickly referred to a Hemato-Oncology center and started chemotherapeutic treatment within 2 weeks with R-CHOP.

Discussion

Bone involvement as the initial extranodal presentation of follicular lymphoma is a rare condition, making the present case interesting and challenging in the diagnostic approach.

#2115 - Case Report

SÉZARY SYNDROME - A RARE FORM OF CHRONIC ERYTHEMA

Gonçalo Durão-Carvalho¹, Sofia Durão², Rafael Oliveira¹, Miguel Rito³, Joana Louro¹, Teresa Martinho¹, João F. Lacerda (2,4)

¹ Caldas da Rainha Hospital - West Hospital Centre, Caldas Da Rainha, Portugal

² Santa Maria Hospital - North Lisbon Hospital Centre, Lisbon, Portugal

³ Oncology Portuguese Institute of Lisbon Francisco Gentil, Lisbon, Portugal

⁴ Faculty of Medicine - University of Lisbon, Lisbon, Portugal

Introduction

The differential diagnosis of a chronic erythema encompasses benign and malignant causes, such as cutaneous T-cell lymphomas. Sézary syndrome (SS) is a rare leukemic variant of these disorders. We present an unusual patient with advanced stage SS, in whom the main focus were to preserve quality of life.

Case description

80-year-old man admitted to a medicine department due to a Pneumonia. Medical history of 1,5-year generalized intense pruriginous exfoliative erythema refractory to antihistamines and topical corticosteroids and history of congestive heart failure, dyslipidemia and hypertension.

On examination: extensive desquamative reddish lesions (involving the head, thorax, dorsus and legs); severe alopecia; bilateral ectropion; palmar and plantar hyperkeratosis with onychodystrophies. No adenopathies nor hepatosplenomegaly were palpable.

Laboratory findings showed: Hb 15.3 g/dL, leucocytes 47,520/ μ L; lymphocytes 38,970/ μ L; platelets 148,000/ μ L; VS 38; β 2-microglobulin 4.35; LDH 463 U/L; uric acid 7.7 mg/dL; HTLV I/II and HIV negative serology.

Immunophenotyping in peripheral blood revealed a T-lymphocyte population of 77.6% (30241/ μ L) with phenotype compatible with Sézary Syndrome: CD3+, CD4+, CD8-, CD5+, CD2+, CD7-. A CT scan showed axillary and inguinal bilateral lymph nodes >1,5 cm; cardiomegaly and left bronchiectasis.

A punch skin biopsy was made and histopathology showed intense lymphocytic infiltrate (small lymphocytes) without significant morphological atypia and with rare epidermotropism. On immunohistochemistry: CD3+; CD4+; PD1+; CD5+; CD7-; CD2-; (CD20-; CD10-; BCL6-).

Discussion

This case fulfills criteria for SS diagnosis- presence of erythroderma, lymphadenopathies, Sézary cells and an absolute Sézary cell count \geq 1000/ μ L-despite an atypical skin histology. It is considered a pT4 Nx M0 B2, which represents a Stage IV A1 or A2. A correct staging of SS would require surgical excision of a lymph node for histopathological analysis. Considering the patient's age, Eastern Cooperative Oncology Group 3, comorbidities and 5-year survival rate <20% (ISCL/EORT criteria), he was not considered

a candidate for intensive chemotherapy. Based on a palliative strategy, and considering the elevated tumor burden, the patient was treated with an oral regimen: low-dose chlorambucil (10 mg/m² D1-D7, 28 days cycle) and prednisone (in progressive reduction). 4 months after diagnosis, the patient has completed 2 cycles of chlorambucil, with significant improvement.

#2136 - Case Report

DIFFUSE LARGE B-CELL LYMPHOMA: CNS RELAPSE AFTER 15 YEARS OF FULL REMISSION

Miguel Romano, Francisco Teixeira Da Silva, Francisca Silva Cardoso, João Pedro Pais, Ana Sofia Matos, Marta Isabel Moreira, Manuel Ferreira, Diana Guerra, Carmélia Rodrigues
Unidade Local de Saúde do Alto Minho - Viana do Castelo, Viana Do Castelo, Portugal

Introduction

Diffuse large B-cell lymphoma (DLBCL) is the most common histologic subtype of non-Hodgkin lymphoma (NHL) accounting for about 30% cases. It is an aggressive and high-grade lymphoma that can arise in nodal or extranodal sites. Patients with DLBCL have a 5% risk of central nervous system (CNS) recurrence and prophylaxis should be given in specific situations significantly reducing the relapse rate.

Case description

A 78-year-old woman with history of ocular globe DLBCL treated with CHOP and local radiotherapy and in full remission since 2004 was admitted in the emergency department, with a two month history of lower back and rib cage pain and consequent functional loss. Pain intensity was 10/10, without radiation, aggravating or alleviating factors and refractory to previous prescribed medication. The patient denied fever but had sustained complains of anorexia, vomits without relation with food and polydipsia. On physical examination she presented afebrile with normal vital signs and generalized pain aggravated by palpation. Neurological examination was unremarkable. Initial serum tests noted severe hypercalcemia (21 mg/dL, albumin-corrected) with elevated LDH and diminished PTH. She received immediate IV hydration and bisphosphonates and was admitted to a level two care unit for surveillance and hypercalcemia control. A full body CT showed pathological fractures (T8-T9) and an intra-raquidian canal mass in the same region without ganglion involvement. An MRI of lumbar and dorsal spine was performed evidencing T7, T9, L2 and L4 pathological fractures and T7-T9 and L2-L4 intercanalicular masses with lumen reduction and medulla compression. The lumbar bone lesion was biopsied with findings compatible with DLBCL invasion probably indicating a CNS relapse from the lymphoma diagnosed in 2003. Unfortunately the patient didn't respond to treatment, dying 20 days after admission.

Discussion

CNS relapse is an extremely severe complication of DLBCL. At the time of the first diagnosis, the recommend treatment didn't include rituximab as first line chemotherapy. However whether the frequency of CNS relapses changed between the pre-rituximab and rituximab eras also remains controversial, but a high rate of relapse was reported in that period. Our case emphasizes the importance of a proper diagnosis and urgent treatment of hypercalcemia, highlighting the need to accurately identify at-risk patients for relapse, screen for CNS disease, and develop safe and effective treatment/prophylaxis strategies.

#2140 - Case Report

NIVOLUMAB-INDUCED HYPOPHYSITIS - SECONDARY ADRENAL INSUFFICIENCY IN A PATIENT WITH GASTRIC ADENOCARCINOMA

Federica Parlato, Tânia Matos, Manuel Silvério António, Margarida Andrade, Guilherme Sapinho, Ana Lúcia Costa, Sandra Braz, Rui Victorino, Luís Costa
Centro Hospitalar Universitário Lisboa Norte, Lisbon, Portugal

Introduction

Nivolumab is an anti-programmed death-1 (anti PD-1) specific monoclonal antibody and an immune checkpoint inhibitor (ICPI), first approved for metastatic melanoma treatment. More recently its use expanded to several other malignancies. ICPIs cause immune-related adverse events (irAEs), which can affect every organ. Endocrine effects are usually early toxicities and often irreversible, requiring permanent hormonal substitution. Secondary adrenal insufficiency (SAI) due to anti PD-1-associated hypophysitis is an exceedingly rare phenomenon, occurring in <1% of patients.

Case description

A 78-year-old woman with gastric adenocarcinoma stage IV presented with complaints of generalized muscular weakness, nausea, anorexia, apathy and hypersomnolence lasting more than 2 weeks. Gastric carcinoma was diagnosed about 1 year earlier and the patient underwent total gastrectomy. Intra-operatively hepatic metastases have been found and she initiated adjuvant capecitabine and oxaliplatin chemotherapy and nivolumab immunotherapy. The patient had received 14 nivolumab treatments and the complaints above mentioned began 4 days after the last administration. At hospital admission she looked prostrated and her blood pressure was 90/40 mmHg. Blood tests showed normal serum creatinine and kalemia, hyponatremia (125 mmol/L) and hypoglycemia (66 mg/dL). Further laboratory investigation revealed normal thyroid-stimulating hormone levels, slightly reduced free thyroxine, non-measurable adrenocorticotropic hormone, severely reduced serum cortisol levels, reduced follicle stimulating hormone levels, normal estradiol and non-measurable luteinizing hormone levels. Brain magnetic resonance excluded empty sella. SAI due to nivolumab induced-hypophysitis diagnosis was established and intravenous

hydrocortisone treatment was initiated with rapid recovery of blood pressure values and normalization of natremia. Two days after, the patient was discharged on oral hydrocortisone. She maintains regular oncology and endocrinology follow-up.

Discussion

Endocrine irAEs manifestations are often non specific contributing to missed diagnosis. Due to potential life threatening complications, including hemodynamic instability, it is crucial to be aware of immunotherapy adverse events. This case also demonstrates that hypophysitis may emerge as a late complication of nivolumab therapy. Nivolumab was administered for 11 months prior and had been well tolerated. Endocrine monitoring is needed at any point of treatment.

#2144 - Case Report

CAMERON EROSIONS: A RARE CAUSE OF ANEMIA DUE TO GASTROINTESTINAL BLEEDING

Renato Nogueira, Joana Cunha, Diana Fernandes, Eugénia Quelhas, Celeste Guedes, Augusto Duarte

Centro Hospitalar do Médio Ave EPE, Vila Nova De Famalicão, Portugal

Introduction

Sliding hiatal hernias occur when the gastroesophageal junction and some portion of the stomach are displaced above the diaphragm. Although a common endoscopic finding the cause is mostly unknown. Complications include mucosal prolapse, incarceration, volvulus, esophageal shortening and erosions on the mucosal folds. When these erosions are linear at the diaphragmatic impression, they are called Cameron erosions. Cameron erosions and gastric ulcers are the mild and severe forms of the same disease spectrum, respectively. The first are found on the lesser curve of the stomach at the level of the diaphragmatic hiatus. Their clinical significance is due to their ability to cause significant acute, chronic, or obscure gastrointestinal bleeding, often requiring blood transfusions.

Case description

A 51-year-old white female comes to the internal medicine clinic with a 3-year-old history of microcytic, hypochromic anaemia. Her past medical history was significant for hypertension and chronic obstructive lung disease. On presentation she had a haemoglobin of 5.7 g/dl, requiring 4 units of red blood cells, iron concentration was 18 ug/dl and ferritin level was 1.7 ug/L. The patient underwent esophagogastroduodenoscopy (EGD), which showed a chronic gastritis and distal hiatal hernia at the junction of the diaphragmatic junction, colonoscopy was normal, faecal occult blood test was positive. She was put on iron pump inhibitors and EV iron supplementation which initially raised her haemoglobin to 13.2 g/dl but a steady decrease down to 6.4 g/dl was verified in the follow-up. Further studies were negative, these included anti-gliadin, anti-endomysium and antireticulin antibodies and stool

parasitology. Cyanocobalamin, folic acid and thyroid hormone levels were normal. Abdominal CT scan was normal. pH-metry showed a pathological gastroesophageal reflux.

She later repeated the EGD, again, a hiatal hernia was identified, in the herniary sac several linear erosions/ulcers were detected - Cameron erosions.

She later underwent a Nissen fundoplication surgery which corrected the hernia.

At 6-month follow-up her hemoglobin was 13.9 g/dl and an iron concentration of 132 ug/dl without iron supplementation.

Discussion

This case emphasizes the need for a high index of suspicion for Cameron lesions as a causative agent of substantial blood loss in patients with hiatal hernias after other common causes of gastrointestinal bleeding have been ruled out.

#2147 - Case Report

UPPER RESPIRATORY SYMPTOMS AND CUTANEOUS LESIONS AS PRESENTATION OF PERIPHERAL T-CELL LYMPHOMA

Andreia Margarida Margarida De Matos, Iolanda Santos, Rebeca Calado, Maria Carolina Afonso, Emília Louro, Adélia Simão

Coimbra Hospital and University Center, Coimbra, Portugal

Introduction

Peripheral T-cell lymphoma (PTCL) is an uncommon and heterogeneous group of non-Hodgkin disease. Not otherwise specified type represents 25% of all PTCL, and occurs in adult European and American people with a median age of 60. Major involvement is nodal but extra-nodal involvement occurs in 25-40%: mostly bone marrow, liver, spleen, gastrointestinal system, and skin, with wide clinical presentation and prognosis. Mostly (70%) is diagnosed at advanced state, has high proliferative index and 6 months of average duration of survival.

Case description

67 year-old man with fever, non-productive cough, nocturnal sweating and weight loss (15%) in the past 4 weeks was admitted to the emergency department. He has small non-pruritic and painless cutaneous lesions (face, trunk and scalp) with progressive involvement and a painful oral ulcer. He had scalp and trunk nodular lesions indurated, necrotic and erythematous plaques, with associated submandibular swelling, multiple cervical adenopathies, and with liver and spleen enlargement. Blood tests disclosed pancytopenia and 1.8% of T-CD4/CD8 cells in bone marrow aspirate whose biopsy shows dysplastic cells. Thoracic and abdominal CT revealed pericardial effusion, lombo-aortic adenopathies, adrenal gland nodule, liver and spleen enlargement with multiple hepatic nodules. He performed a PET scan: extensive hypermetabolic visceral (ocular, perisinus, prostate, liver, spleen, adrenal), cutaneous, subcutaneous and medullar involvement. Skin, submandibular and palate biopsy confirmed diffuse dermis

and epidermis infiltration by T-cells (mostly CD4) consistent with non-specified type peripheral T-cell lymphoma with high proliferative index (Ki-67 90%). The patient ended up deceasing in few days after spontaneous tumor lysis syndrome.

Discussion

We report a men with PTCL, an uncommon and pathogenesis unknown disease that represents only 3.7% of all lymphomas and 10% of non-Hodgkin lymphomas. Although nodal involvement is frequent, skin involvement occurs and is considered as an independent prognosis factor. Skin and subcutaneous manifestations are described in 10-20% of largest series: mostly nodular or multifocal tumors (61%), but maculopapular eruptions, urticated, and like in our case, indurated plaques and ulcerated lesions have been rarely reported. Although rate of STLS is only 1.08% in hematological malignancy, we present an advanced stage lymphoma with high proliferative index with STLS.

#2165 - Case Report

RENAL LYMPHOMA: AN ATYPICAL PRESENTATION

Ilídio Brandão, Marta Filipa Lemos Mendes, Filipa Rodrigues, Isabel Apolinário
Hospital de Braga, Braga, Portugal

Introduction

Large B-Cell Lymphoma is a type of non-Hodgkin's lymphoma that occurs in up to 40% of the cases in the extra-medullary tissue.

Case description

Female, 54 years old. Institutionalized in a psychiatric hospital by oligophrenia. Medicated with carbamazepine 200 mg 3id, chlorpromazine 100 mg 3id, haloperidol 5 mg 3id. Brought to the Emergency Service by lumbar pain, dysuria, fever and chills with 2 days of evolution. On physical examination, hemodynamic stability, fever (39.4°C) and right kidney renal Murphy. Analytically, Hb 9.2 g/dL (microcytic/hypochromic), 4100 leukocytes, 215000 platelets and CRP 165 mg/L, LDH 353 U/L; urinalysis urine test with leukocyturia and erythrocytria. Thus, the diagnosis of Acute pyelonephritis was admitted. Patient took uroculture and initiated empirical antibiotic therapy with amoxicillin/clavulanic acid. Maintained clinical fever and low back pain so antibiotics were changed to ceftriaxone 2g IV/day at 72 hours. At that time, E. Coli had already been isolated in the uroculture, susceptible to the therapy instituted according to antibiogram. Patient didn't present clinical/analytical improvement, so performed CT scan that revealed: "Mass in the lower half of the right kidney with 5cm greater diameter, compatible with tumor lesion. Adenopathic mass adjacent to IVC with 9x6.5cm". She was admitted to internment for suspicion of metastatic renal/urothelial neoplasia. During the hospitalization, a cytological examination of the urine that was negative for urothelial carcinoma and biopsy of the lesion was carried out, whose histological examination

identified diffuse large B-cell lymphoma with activated B-cell phenotype. Completed staging with CT/PET that revealed adenopathic conglomerates below and supra-diaphragmatic, pulmonary nodular lesions and, eventually, splenic involvement with metabolically active lymphoproliferative disease. Thus, in the case of diffuse large B-cell lymphoma stage IV, it was decided to perform oral chemotherapy (Idarubicin) and Rituximab sc because it was a patient with oligofrenia who didn't accept intravenous therapy

Discussion

Primary renal lymphoma (PRL) is a rare entity and its existence is even questioned. Secondary involvement of the kidney is the most frequent. Discussion of PRL vs metastasis is discussed in this case. We emphasize the atypical presentation of this clinical case, along with the always necessary scrutiny of the differential diagnoses and particularities of the treatment in the concrete situation of the psychiatric patient

#2173 - Case Report

WHERE DOES IT COME FROM? - A CASE OF BONE METASTASIS OF UNKNOWN ORIGIN

Ines Gonçalves, Laura Costa, Filipa Pinho, Camila Oliveira, Francisco Gonçalves, Luisa Pinto, Antonio Silva
Hospital de Braga, Braga, Portugal

Introduction

Bone metastases are the most common bone malignancies, of which 80% are etiologically originated in prostate, breast and lung primates.

Case description

The authors report the case of a 67-year-old man with a personal history of dyslipidemia, smoking (30 pack-years) and ischemic heart disease.

He was admitted for right chest pain, with irradiation to the shoulder, with 8 months of evolution. The pain had worsened in the last month and associated he had a dry irritative cough and supraclavicular swelling. In the physical examination, swelling in the anterior aspect of the thorax, a supraclavicular and axillary adenomegaly was palpable. Analytically, without any changes of relief.

Thoracic computed tomography (CT) showed a massive neoformative mass centered on the middle and anterior arch of the right 2nd rib with massive adenopathic conglomerate in the right axillary and clavicular region. The imaging characteristics described suggested a primitive bone neoformation process. However, during hospitalization, the thoracic bone lesion was submitted to biopsy and its histology showed: an adenocarcinoma bone metastasis, with nonspecific immunohistochemical study.

In the investigation of the primary, he performed abdominopelvic CT and positron emission tomography, which, in addition to the previously described, revealed a 2 cm nodule of the left adrenal,

compatible with metastasis. Furthermore, he underwent high and low endoscopy that did not have alterations. Finally, he was submitted to bronchofibroscopy that was normal.

The primary tumor was not identified, however taking into account the metastatic pattern, in oncology group was decided to treat as occult lung neoplasm. So, the patient started radiotherapy and chemotherapy with palliative intent.

Discussion

In 30% of patients with bone metastases, it is not possible to identify the primary, even after multiple complementary diagnostic tests. However, its affiliation, through the metastatic pattern, immunohistochemistry, and molecular study, is important as it has implications for prognosis and treatment. Lung cancer is the leading cause of occult primary bone metastases and is associated with poor prognosis.

#2175 - Case Report

A FULMINANT CASE OF AL AMYLOIDOSIS

Teresa Furtado, Elsa Soares, Patrícia Valério, Catarina Abrantes, Sofia Coelho, Ana Farinha, Ana Natário
Centro Hospitalar de Setúbal, Setúbal, Portugal

Introduction

AL amyloidosis is a clonal plasma cell proliferative disorder in which fibrils of monoclonal light chains are deposited in any tissue or organ. It is an uncommon disorder and the exact incidence is unknown. The clinical presentation is dependent on the pattern and severity of organ involvement, although virtually all patients have a multisystem amyloid deposition, it is not uncommon to present with evidence of mainly one organ being affected. For diagnosis purpose the biopsy is required.

Case description

We present the case of a 75-year-old women, with a previously normal renal function admitted with complaints of oliguria, anorexia, loss of weight and edema. At hospital admission she presented with hypotension, generalized edema and bilateral periorbital purpura. The laboratory tests revealed acute kidney injury with high levels of serum creatinine and urea (13.1 mg/dL and 230 mg/dL), hematuria with a ratio of urinary total proteins:creatinine of 26. Renal ultrasound had no pathological features. The serum protein electrophoresis showed a monoclonal pattern in alpha 2 region and severe hypoalbuminemia of 0.7 g/dL and hypocomplementemia of C3. Levels of free light chains were measured with a ratio of 0,3, immunofixation revealed a monoclonal gammopathy of Lambda light chains. A bone marrow aspirate and biopsy confirmed the presence of monoclonal gammopathy. A renal biopsy was done showing deposition of Lambda free light chains at glomerular level with extensive tubular necrosis. During hospital stay there was no renal recovery and she started hemodialysis. On the 14th day of hospitalization she had a massive drop in hemoglobin level and a gastric endoscopy revealed

a diffuse hemorrhage in the antrum region, which reappeared after washing out, without an associated lesion probably related to deposition of amyloid which could not be treated endoscopically. After this acute episode the patient developed shock and had a fatal outcome.

Discussion

Amyloidosis AL clinical presentation is dependent on the pattern and severity of organs involved. The diagnosis is difficult and requires a high level of clinical suspicion. In this particular case, with severe multiorgan involvement (renal, cutaneous, autonomic and gastrointestinal) ended up with a fatal outcome. It is important to distinguish it from other forms of systemic amyloidosis, which present with different clinical course and therapeutic approaches. Unfortunately in our case it was to late and curative medical intervention was

#2177 - Case Report

UNBEARABLE PAIN: WHEN THE SOLUTION IS ON THORAX RADIOGRAPHY

Daniela Félix Brigas, Margarida Madeira, Francisca Santos, Gonçalo Mendes, Hugo Viegas, Alexandra Gaspar, Clara Rosa, Eugénio Dias, Susana Marques, Ermelinda Pedroso
Setúbal Hospital Center, EPE, Setúbal, Portugal

Introduction

Osteoarticular pain is often devalued by the attending doctor and the patient himself. Although, an intense shoulder pain without mechanical features, associated to functional disability, consumptive and neurological symptoms, in a patient with smoking habits, are red flags that should motivate a further etiological search.

Case description

We report a case about a 60-years-old construction worker with smoking habits, who was admitted with an intense long-term left shoulder pain, with significative worsening in last month, which caused inability for his work activity. On admission, he presented left miosis and ptosis, paresis and muscular atrophy of left arm and hypoesthesia of homolateral forearm and hand. The presence of collateral circulation on left hemithorax was noticed. Thorax radiography showed a left apex hypotransparency, which caused a contralateral deviation of the mediastinal structures, associated to a left diaphragmatic hemicupula elevation. Thoracic computerised tomography documented "hypocaptant proliferative lesion, with 95x69 mm, which enfolds vascular structures and deviates esophagus and trachea". During hospital stay, higher doses of opioid drugs were gradually required to pain control. Posteriorly, patient developed dysphagia and food impaction sensation, in extrinsic esophageal compression context.

After a bronchofibroscopy with inconclusive result, a transthoracic aspiration puncture was performed, in order to do a lesion biopsy.

Anatomopathological test described an undifferentiated carcinoma, whose immunological profile were consistent to a prostate, liver or kidney secondary lesion.

Imaging tests and bone scintigraphy didn't identify the primary tumor. After optimisation of symptomatic treatment, patient had discharge and, nowadays, etiological study is maintained in external consultation.

Discussion

This case illustrates the natural history of Pancoast Syndrome, characterized by typical presentation of intense shoulder pain, Horner Syndrome, homolateral limb paresis and phrenic nerve paresis. Although the hypothesis of apex tumor can be easily confirmed by a basic imaging test, the symptoms devaluation by the patient delayed the diagnosis.

#2189 - Case Report

CHRONIC MYELOPROLIFERATIVE NEOPLASMS: DIAGNOSTIC CHALLENGES

Mariana Cristina Quaresma, Nuno Pereira, Ridhi Ranchor, Carina Andrade, Fátima Farinha, João Araújo Correia
Centro Hospitalar do Porto, Porto, Portugal

Introduction

Chronic myeloproliferative neoplasms are a cause of chronic anemia and include a diverse spectrum of entities including polycythaemia vera, essential thrombocythemia, chronic myelogenous leukaemia, and primary myelofibrosis, among others. They should be considered in the differential diagnosis of autoimmune, neoplastic, granulomatous and infectious disease.

Case description

The authors present a case report of an 80-year-old female referenced to the outpatient clinic with diffuse osteoarticular and musculoskeletal complaints, asthenia, anorexia and unintentional weight loss of about 20% of total body weight for the past 9 months. Hepatosplenomegaly was detected with no other significant findings on physical examination. She also presented with anaemia of inflammatory states with frequent need of transfusion, despite oral iron supplementation. Sedimentation rate was 80mm with negative C-reactive protein. Blood smear had dacrocytes, some schistocytes, target-cells and 2% of blasts. Coagulation, kidney and hepatic function were normal. The immunologic study and serology for hepatotropic viruses were negative. There were no unequivocal complaints suggesting polymyalgia rheumatica or giant cell arthritis. The abdominopelvic CT showed homogenous hepatomegaly and homogeneous splenomegaly with suggestive features of portal hypertension. Echocardiography was normal without evidence of endocarditis. Solid tumors including gastrointestinal and breast, were excluded. The aspirate of the sternal medulla was dry which motivated a medullar biopsy of the sacroiliac crest. The anatomo-pathological and immunocytochemical examinations revealed an hypocellular

medulla with 10% hematopoietic cells, fibroblastic and vascular proliferation and fibrosis of the medullary reticulum. The blast count was 1%. JAK2 mutation screening was positive for the V617F mutation. After discussion with Haematology, the patient was started on the JAK1-2 inhibitor ruxotinib. Despite short-term follow-up the patient is clinically stable without worsening of the aforementioned symptoms and with a stable haemoglobin value without further transfusions. Other cytogenetic screenings for risk assessment and prognosis are in progress.

Discussion

Chronic myeloproliferative disorders frequently require an extensive workout and pose diagnostic challenges. They should always be considered in older adults presenting with chronic anaemia.

#2195 - Case Report

CASE REPORT: BLADDER SCHISTOSOMIASIS AS MGUS CONFOUNDER

Camila Carvalho De Oliveira, Inês Manuel Gonçalves, Filipa Santos Pinho, Laura Costa, Joana Fonte, Jorge Cabral Ribeiro, Herlander Marques, Francisco Nunes, Luísa Pinto, António Oliveira Silva
Hospital de Braga, Braga, Portugal

Introduction

Monoclonal gammopathy of undetermined significance (MGUS) is the most frequent entity in the spectrum of plasmocytic dyscrasias. It is characterized by the presence of a serum or urinary monoclonal immunoglobulin (Ig), also called M-protein, in the absence of evidence of multiple myeloma (MM), amyloidosis or other lymphoproliferative diseases. Of unknown cause, its incidence increases with age and it is more frequent in males and black race. A conservative attitude regarding the treatment can be considered, despite the risk of progression to lymphoproliferative disease or to MM (around 1%/year); so it is prudent to maintain regular surveillance. The predisposition to develop infections is also greater.

Case description

70-year-old female, black race, admitted for right lumbar pain, dysuria, polyachiuria and fever with two days of evolution, no other complaints. Chronic kidney disease (CKD) secondary to bladder schistosomiasis obstruction was noticed before, treated with praziquantel. In addition, had bilateral ureterohydronephrosis with need for JJ stent urinary drainage, and anemia under study in the Internal Medicine attendance. Of relevant on physical examination, had renal Murphy signal positive at right. Analytically, hemoglobin 7.7 g/dL and leukocytosis of $15.8 \times 10^9/L$, with normal leukocyte formula. Plasma Creatinine 5.3 mg/dL (for basal of 2 mg/dL) and C Reactive Protein of 165 mg/L. In the summary urinalysis had leukocyturia. Renal ultrasound revealed normal kidneys, with slight ectasias in the right kidney, with no evidence of excessive dilatation of excretory system. It was established the

diagnosis of acute pyelonephritis and CKD exacerbation in an infectious context, having started empirical antibiotic therapy. From the study performed, normochromic normocytic anemia was interpreted as being multifactorial; protein electrophoresis revealed monoclonal IgG/kappa peak, associated with serum IgG elevation and serum free light chain ratio. Presented increased light chains in the urine, but with a normal ratio.

Discussion

Since the patient presented concomitant CKD and anemia, the hypothesis of plasmocytic dyscrasia can not be excluded. The history of schistosomiasis, associated with the development of CKD due to obstructive causes and/or glomerular disease, worsens the interpretation of the existence of MGUS or MM. Therefore, surveillance must never be forgotten and the Internist plays a key role in interpretation and monitoring in a multidisciplinary way.

#2200 - Case Report

SILENT LUNG CANCER, HIGHLY INVASIVE AND WITH MULTIPLE METASTIZATION

Rafael Oliveira, Ana Canoso, Mauro Santos, Ana Filipa Rodrigues, Gonçalo Durão-Carvalho, Cristina Teotónio, Isabel Maldonado
Centro Hospitalar do Oeste - Unidade das Caldas da Rainha, Caldas da Rainha, Portugal

Introduction

Lung cancer has one of the highest mortality rates. Cases with this level of invasion usually present with symptoms. About 60% of new diagnosis present with acute cough (or changes in the characteristics of chronic cough), 6 to 31% with hemoptysis, 25 to 40% mention pain and 55-90% asthenia. In this particular case, there were no symptoms at presentation

Case description

A 70 year old woman patient, with a past history of anemia and dyslipidemia, was taken to the Emergency Department after being found fallen at home, disorientated, with an incoherent speech and with sphincter incontinence. Cranial CT scan identified hypodense cerebellum lesions, expansive and suggestive of metastization. These lesions were further characterized by Cranial MRI. A CT scan of the thorax, abdomen and pelvis showed an expansive lesion in the right pulmonary hilus, highly suggestive of a primitive lesion. Multiple lesions suggesting of bone and adrenal metastization were also identified. A Bronchofibroscopy was performed describing infiltration from the upper 1/3 of the trachea with extension to the carina, right and left bronchus. Histopathology of the sample was compatible with adenocarcinoma cells – imunohistochemical study (TTF-1) still in course.

Discussion

This case report allowed for a revision of the main characteristics of lung cancer but mostly enforced the notion that the spectrum of presentation may vary tremendously. Even in the case of an

exuberant local lesion, it may occur without any warning signs or symptoms of the affected system.

#2201 - Case Report

BRAIN METASTASES FROM A UPPER-TRACT UROTHELIAL CARCINOMA

Hugo Raúl Castro¹, Juan Francisco Barrios¹, Luis Benjamin Godínez¹, Carlos Raúl Aquino¹, Pablo Tigerino², Gabriel Antonio Ríos¹

¹ Instituto Guatemalteco de Seguridad Social, Guatemala, Guatemala

² Universidad de San Carlos de Guatemala, Guatemala, Guatemala

Introduction

Upper-tract urothelial carcinoma (UTUC) is considered a relatively uncommon disease, with limited information of clinical cases. UTUC includes any malignancies from the calyceal system to the distal ureter. This relatively uncommon disease appears in 5-10% of all renal tumors and 5-10% of all urothelial tumors, it's calculated an incidence of 1-2 cases per 100,000. UTUC appears more in men than in women with a ratio of 2:1. We present the case of a 59 years-old male with an upper-tract urothelial carcinoma (left renal pelvis) who received 4 cycles of chemotherapy with gemcitabine-cisplatin as neoadjuvant treatment one year prior. He came to the emergency with history of headache of 1 month.

Case description

Patient referees that approximately one year before he started with diffuse abdominal pain of gradual onset and moderate intensity, which radiated to the left renal fossa. The imaging studies show retroperitoneal adenopathies and a mass in the left renal pelvis. Biopsy reported a high-grade urothelial carcinoma with a ck7, ck20, GATA3 and p63 positive immunophenotype. For which he received chemotherapy with 4 cycles of neoadjuvant gemcitabine-cisplatin, and 6 months after, a surgical resection. Approximately 5 months later he started with persistent headache. He came to the emergency room one month later and a brain MRI was performed a cystic lesion with hyperintense halo in T2 in the temporo-occipital region that compresses and displaces the occipital horn of the right lateral ventricle was found. The patient was taken to surgical resection and the pathology report was compatible with a metastatic UTUC. CT scans of the thorax, abdomen and pelvis were without evidence of disease.

Discussion

The UTUC is an extremely rare cancer type. The case of the patient was notable for the infrequent presentation of cerebral metastasis without evidence of measurable disease in the pelvic cavity.

#2207 - Medical Image

A VIRTUAL AIRWAY

Diana Ferrão, Francisco Gonçalves, Joana Pimenta, Clara Machado-Silva, Pedro Ribeirinho-Soares, Fernando Nogueira, Catarina Pereira, José Marques, Jorge Almeida
Centro Hospitalar e Universitário de São João, Porto, Portugal

Clinical summary

We report a 52 year-old patient, smoker, with a cervical mass that has been growing for two months, with occasional dyspnea. At

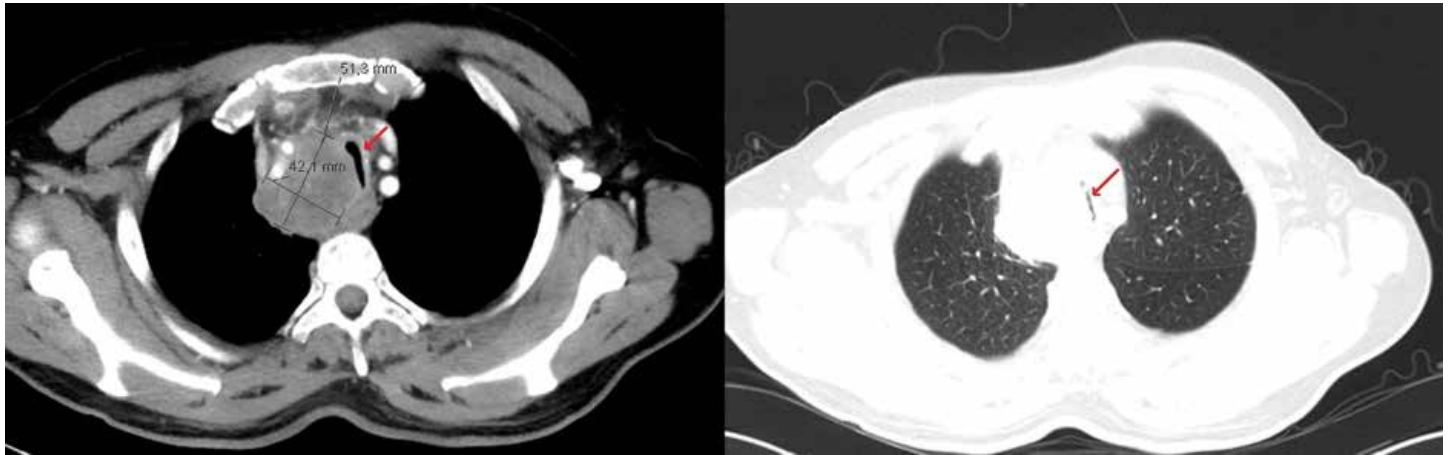


Figure #2207. Large mediastinal mass compressing the trachea.

#2211 - Medical Image

A DEEPER LOOK BEHIND THE CUTANEOUS NODULES

Danay Perez Mijenes
ULSM HOSPITAL PEDRO HISPANO, Matosinhos, Portugal

Clinical summary

Male, 72 years old, referred to External Consultation of Internal Medicine due to the appearance of cutaneous lesions, such as brownish macules, located in the frontal region, which progressed to painful, purple tense nodules with a hematic content, distributed to the remaining tegument, predominantly on the face, trunk and upper limbs. Associated asthenia and anorexia, loss of 5% of body weight in 3 months and pancytopenia, with evidence of immature neoplastic hematological cells in peripheral blood immunophenotyping. A skin biopsy was performed, with histology suggestive of dendritic plasmacytoid cells leukemia, with a staging study demonstrating spinal involvement, leukemic dissemination, ocular involvement and diffuse ganglion.

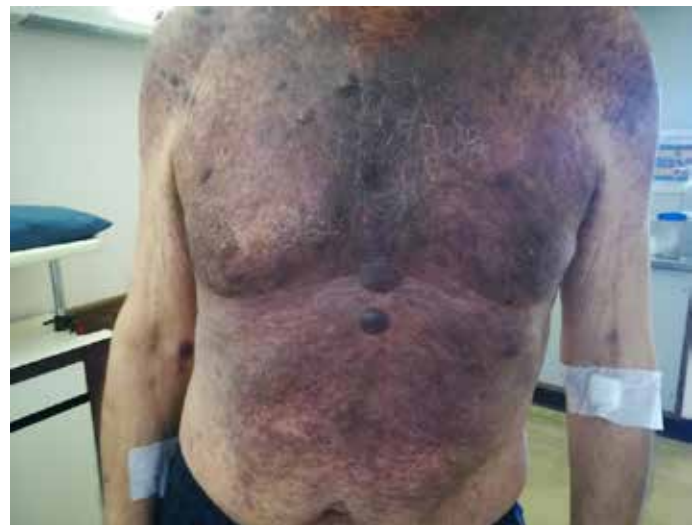

Figure #2211. Cutaneous manifestations of leukemia.

#2230 - Case Report

MANTLE CELL LYMPHOMA - ABOUT AN ADENOPATHIC CONGLOMERATE

Olinda Lima Miranda, Magda Costa, Filipe Gonçalves, Jorge Cotter
Hospital Senhora da Oliveira, Guimarães, Portugal

Introduction

Mantle cell lymphoma is a lymphoproliferative disease that results from undifferentiated pre-germ cells that are in the

primary follicles or in the mantle region of secondary follicles. It can manifest in 70% of cases in stage IV and in 40% of cases with symptoms B (fever, night sweats and weight loss) or with generalized lymphadenopathy or hepatosplenomegaly. One of the less common presentations is the extranodal involvement of the gastrointestinal tract as it happens in this case.

Case description

A 72-year-old female with a history of heart failure, dyslipidemia and hysterectomy due to fibromyoma it was admitted at the emergency department for asthenia and dyspnea with a month of evolution. Analytically with ferripriva anemia (hemoglobin of 4.5 g/dL), without leukogram and platelets changes. Upper endoscopy revealed vascular ectasia of the gastric antrum. In the abdominal tomography, there was "Mesenteric adenomegalias with a maximum short axis of 34 mm, with adenopathic conglomerate in the right flank region (...) slightly homogeneous splenomegaly, measuring the spleen 15.4 cm in bipolar diameter". Imaging control was requested three months later and showed "in the mesenteric fat, especially to the right of the midline, multiple adenomegalias are defined partially juxtaposed and of relatively homogeneous density, the larger ones reaching diameters between 3 and 3.5 cm in their short axis. They are accompanied by homogeneous splenomegaly (17.5 cm of greater axis). A biopsy of the conglomerate guided by tomography was performed. The histology revealed mantle cell lymphoma, with positivity for cyclin D1. It was oriented to hemato-oncology consultation.

Discussion

Mantle cell lymphoma is most often diagnosed late in the disease (Stage 4). In this case, the patient had no symptoms or palpable adenopathies. The adenopathic conglomerate was a finding that allowed to arrive at an unexpected diagnosis, in a patient without clinic or analytical alterations that suggested a lymphoproliferative process.

#2254 - Case Report

PULMONARY LESIONS IN ONCOLOGICAL PATIENTS, OLD AND NEW ENEMIES; NEW CHALLENGES FOR THE INTERNIST.

Cristina Rodríguez Fernández-Viagas, Susana Fabiola Pascual Pérez, Ángela Soler Gómez, Manolo Corrales Cuevas, Estefanía Martínez De Viegol Agrafojo, Ricardo De Los Rios De La Peña, Marina Martín Zamorano

Hospital Universitario Puerta del Mar, Cádiz, Spain

Introduction

Latest advances in Oncology field have led to new therapies that target the immune system, stimulating host antitumor response. This contrasts with cytostatic/cytotoxic treatments that cause defects in the immune system inducing neutropenia and contributing the appearance of opportunistic infections that are one of the major causes of morbidity and mortality in

cancer patients. We present two cases to help us reflect on the therapeutic and diagnosis approach of oncological patients today.

Case description

We present a first case of a 69-year-old smoker patient with a well-treated history of TB in the youth. He had been diagnosed with sigmoid metastatic adenocarcinoma who underwent surgery and is receiving chemotherapy. A follow-up CT scan showed a cavitary lesion in left upper lobe occupied by a nodular image compatible with aspergilloma. The patient was asymptomatic and no fevered. Galactomannan antigen in serum (negative) and precipitin (positive) were requested. Consecutive sputum samples did not show any acid fast bacilli, sputum cultures and blood cultures were negative. Galactomannan antigen in bronchial alveolar lavage was positive. Voriconazole treatment was started and chemotherapy was restarted after 2-weeks of triazole. Resolution of aspergilloma was observed in one-year follow-up CT scan. We present a second case of a 61-year-old smoker diagnosed with non-small cell lung carcinoma stage IV (EGFR, ALK and ROS-1 negatives with PDL1 positive) with hepatic and pulmonary progression after 4 chemotherapy sessions. It was decided to start atezolizumab. Two months later, in control CT scan, new cavitary nodules appeared. The patient was asymptomatic and microbiological tests were requested (negatives). In this case, it was decided to wait, maintain immunotherapy and repeat a new control to reevaluate with iRECIST criteria. New CT showed a decrease in the size and number of nodules presented previously. Definitive diagnosis was made: pseudoprogression during immune checkpoint inhibitor therapy

Discussion

Tumors respond differently to immunotherapy compared to systemic chemotherapy and molecularly targeted agents. Some patients experience a rare response called pseudoprogression. It is a radiological deterioration of previously known lesions or even appearance of edema and infiltration of activated T cells and other immune cells. Recognizing this phenomenon can help us in the diagnosis, avoiding the premature interruption of such treatments that can bring significant clinical benefit.

#2255 - Case Report

MALT LYMPHOMA PRESENTED AS A SOLITARY PULMONARY NODULE: A RARE CAUSE

Cristina Rodríguez Fernández-Viagas, Susana Fabiola Pascual Pérez, Manolo Corrales Cuevas, Ángela Soler Gómez, Ricardo De Los Rios De La Peña, Estefanía Martínez De Viegol Agrafojo, Daniel Gutiérrez Saborido

Hospital Universitario Puerta del Mar, Cádiz, Spain

Introduction

Primary pulmonary lymphomas are relatively rare, especially MALT (mucosa-associated lymphoid tissue) subtype which represents

3-4% of extranodal non-Hodgkin's lymphomas and 0.5-1% of malignant lung tumors. It presents a nonspecific symptomatology, so it is mandatory to correlate the imaging findings with clinic context and histological study, which is essential for an accurate diagnosis.

Case description

We present a 63-year-old patient with history of multiple cardiovascular risk factors (smoker from her 18s, hypertension, diabetes and dyslipidemia) and chronic kidney disease in hemodialysis treatment. During pre-transplant evaluation she was diagnosed with a solitary pulmonary nodule. PET-CT was performed, which showed a spiked pulmonary nodule of 0.9x1.15 cm in the left lower lobe with low uptake of the tracer (SUV max 3.95 g/ml), no lymphadenopathy, no locoregional signs of distant tumor dissemination was shown. Analysis revealed hemoglobin 10.8 g/dl, 5320 cel/mm³, 213,000 platelets; neither proteinogram nor β 2 microglobulin was requested. The patient denies constitutional syndrome or B symptoms, only refers grade 2 MRC scale baseline dyspnea. According to these findings, a complete resection of the pulmonary nodule was decided. The anatomopathological study helps us to establish a definitive diagnosis: pulmonary marginal zone lymphomas of MALT origin.

Discussion

Lymphoid tissue associated to the bronchial mucosa is the origin of pulmonary lymphoma MALT type. The median age at diagnosis is 50-60 years, with only few patients aged <30 years. Pulmonary lymphoma MALT type may be comorbid with autoimmune or infectious diseases, such as rheumatoid arthritis, Sjögren's disease, amyloid deposits, collagen vascular diseases, *Helicobacter pylori* infection and acquired immune deficiency syndrome. Clinical manifestations are usually non-specific, including cough, mild dyspnea, chest pain and occasionally hemoptysis, most of the patients are asymptomatic. Radiologically, they can occur under multiple forms, considering the possibility of pulmonary MALT lymphoma due to low attenuation lesions on CT. A high level of suspicion must be maintained in order to be able to make an appropriate diagnosis, being necessary a histological study to make the definitive diagnosis.



ORGANIZATION AND QUALITY OF HEALTH CARE

#32 - Abstract

ASSESSING MENTAL STATUS AND QUALITY OF LIFE IN EXTREMELY ELDERLY PEOPLE

Laisa Socorro Briongos Figueroa¹, Marta Cobos Siles¹, Miriam Gabella Martin¹, Jesica Abadia Otero¹, Beatriz Vargas Ruiz², Juan Carlos Martin Escudero¹

¹ Internal Medicine Service. Rio Hortega University Hospital, Valladolid, Spain

² Nursing Care Department. Rio Hortega University Hospital, Valladolid, Spain

Background

It's known that elderly people usually complain about quality of life despite having less chronic illnesses associated to aging. Our aim was to analyze interactions between multimorbidities, health related quality of life (HRQoL) and dependence level.

Methods

Cross-sectional study including Internal Medicine in-patients over 80 years-old without diabetes mellitus during 2018. Mental status was evaluated using Pfeiffer test (SPMQS), Basic Activities of Daily Living (BADLs) and Instrumental Activities of Daily Living (IADLs) were estimated using The Older Americans Resources and Services (OARS) questionnaire. Comorbidity was evaluated using Charlson index (CI) and HRQoL with EuroQoL (EQ5D3L). Data analyzed using SPSS v.15.0.

Results

We identified 305 patients, 59% women. Mean age was 88±5 and 38% were aged over 90. Estimated HRQoL was 0.43±0.33 on a scale between 0 and 1 for EQ5D3L-index-value and 55.7±19 for visual analogue scale.

Mean dependence level was 6.2±5 for BADLs and 9.2±5 for IADLs with a correlation of -0.9 (p<0.001) for BADLs/EQ5D3L and -0.907 (p<0.001) for IADLs/EQ5D3L. 31.6% of patients had severe cognitive impairment with a mean score of 5.4±3.6 in SPMQS, good correlated with EQ5D3L-index-value (-0.726; p<0.001). Corrected CI mean score was 6.2±1.7 correlated with EQ5D3L-index-value as -0.171 (p=0.003).

After adjusted analysis, EQ5D3L remained significantly associated to BADLs (β : -0.465 (-0.037 to -0.025), p<0.001) and IADLs (β : -0.537 (-0.043 a -0.031), p<0.001); R²=0.875, p<0.001

Conclusion

HRQOL in our non-diabetic population is affected by biopsychosocial sphere dimensions, specially functional dependence. Thus, a higher dependence in BADLs and IADLs correlates well with worse HRQoL

#77 - Abstract

PERCEPTION AND PRACTICE OF PLACEBO USE AMONG PHYSICIANS IN MANGALORE, INDIA

Ravinder Singh Aujla¹, Ritika Agarwal¹, Smriti Sinha²

¹ Kasturba Medical College, Mangalore, India

² Srinivas Institute of Medical Science and Research Centre, Mangalore, India

Background

This study focuses on the quantitative usage of placebos in clinical medicine, knowledge of placebos, the thoughts of the health care professional on the effectiveness of placebos and the ethical views of health care professionals on the topic of placebo use.

Methods

A time bound cross-sectional study was conducted among the physicians in five hospitals and various private clinics in Mangalore, India. The sample size was calculated to be 86. Written consent was taken and the study was carried out thereafter on the willing participant using a self-administered questionnaire.

Results

Seventy two percent of physicians were found to be utilizing placebo prescriptions. Vitamins were the most commonly prescribed placebos. Pure placebos were prescribed by 69.4%, impure placebos by 83.9% of physicians. Pure placebos were deemed acceptable by 70.9% of physicians if used for their psychological effect, but only 46.5% said the same for impure placebos. Placebos were most commonly prescribed to conform to the patients' requests for some sort of medicine. Though, 70.9% of physicians agreed that a pure placebo was acceptable if used for its psychological effect, while only 46.5% said the same for an impure placebo. 64.5% of placebos prescribers found that the placebo was sometimes effective while 17.7% believed that it was usually effective. Among our physicians, 54.8% and 62.8%

of placebo prescribers felt that many or some patients would be disappointed if they were to find out that they had been treated with pure or impure placebos respectively. This may be a reason as to why the non-prescribers do not prescribe placebos. Only, 20.9% and 17.4% of physicians agreed that placebos were a traditional component of medical practice, for pure and impure placebos respectively.

Conclusion

Physicians agreed that placebos were acceptable in some circumstances in clinical practice. They believe that pure placebos are more acceptable than impure placebos. Physicians think that the information and training about placebos during their medical studies was insufficient. Therefore, perhaps more time should be put into teaching about placebos during medical studies.

#153 - Abstract

THE PREVALENCE OF INAPPROPRIATE INTRAVENOUS PHOSPHATE REPLACEMENT IN TWO MEDICAL WARDS

Chaozer Er, Joelynn Qiao Bin Tay, Nicholas Wong Wai Cheong, Clarissa Hui Wen Aw

Woodlands Health Campus, Singapore, Singapore

Background

Mild to moderate hypophosphataemia (serum phosphate: 0.3-0.85 mmol/L) can usually be corrected with oral replacement. Intravenous phosphate replacement carries the risk of hypotension, hypocalcaemia and arrhythmia whereas oral replacement is generally well tolerated. We intended to study the prevalence of inappropriate intravenous phosphate replacement given to patients with mild to moderate hypophosphataemia in two of our medical wards (total 68 beds).

Methods

We prospectively collected the data of patients who were prescribed intravenous phosphate replacement in two of our medical wards from 14/02/19 to 13/03/19.

Results

In that one month, 37 patients were prescribed intravenous phosphate replacement. Out of the 37 patients, only one patient had a serum phosphate level of <0.3 mmol/L. The rest of the patients (n=35) were prescribed intravenous phosphate replacement when their serum phosphate level was >0.3 mmol/L. None of the patients were given intravenous replacement because of ileus, nil by mouth or malabsorption state.

Conclusion

Inappropriate intravenous phosphate replacement is common (97%) in two of our medical wards.

#309 - Abstract

COMPARATIVE COST-ANALYSIS ON THE INTERNALIZATION OF THE CPAP SERVICE IN SLEEP APNEA-HYPOPNEA SYNDROME (ECOCPAP STUDY)

Domingo García Jiménez¹, Juan Mora Delgado², Demetrio González Vergara³, Daniel Marín Dueñas²

¹ Pulmonary, General Hospital of Jerez de la Frontera, Jerez De La Frontera, Spain

² Internal Medicine, General Hospital of Jerez de la Frontera, Jerez De La Frontera, Spain

³ Pulmonary, High Resolution Hospital of Lebrija, Lebrija, Spain

Background

Since its inception, the provision of domiciliary respiratory therapies, including CPAP, is outsourced. The high prevalence of SAHS and the diagnosis of new cases, in a treatment that is prescribed indefinitely, has produced a notable increase in the number of prescribed CPAPs, a number that increases every year and which is a problem for the administration in charge to finance this therapy. In our knowledge there is no study that proposes an alternative financing system.

Methods

We have implemented a new organizational system where the hospital acquires the equipment by itself and performs the control, maintenance and monitoring of this therapy. The objective of this study was to compare the costs of the new system against the traditional, with an external supplier, three years after its implementation and assess the quality of the new services provided. A comparative analysis of costs of both forms of provision was made from the perspective of the health system, with a focus on daily microcosts per patient, considering direct health costs of the new organizational system and compared with the costs that patients would have generated by continuing with the external supplier company. A satisfaction survey was also carried out on the service provided and compared with that carried out on the supplier company in the immediately preceding time period.

Results

We acquired 21 CPAP devices that began to be delivered in October 2013. The study comprises an average of 1183.10 days per patient, 6 scheduled nursing check-ups have been made to each patient and 14 incidences or unscheduled consultations. The total cost of the new system was € 6,825.11 (cost per CPAP device/day of € 0.27) compared to € 22,781.18 (cost of CPAP device/day of € 0.91) that would have cost the traditional system. The new system has saved 70.04%.

In the satisfaction survey carried out, the new organizational system obtained better results than the external supplier company.

Conclusion

The internalization of the CPAP service supposes a significant saving of costs and an improvement in the perceived satisfaction

#334 - Abstract

QUICK DIAGNOSIS UNIT. A REALITY COST-EFFECTIVE EXPERIENCE OF 5 YEARS IN A HOSPITAL OF THIRD LEVEL IN SPAIN

Maria Cepeda, Pablo Velasco, Samuel Puente, Rodrigo Martinez
General Hospital Segovia, Segovia, Spain

Background

The development and implementation of the Quick Diagnosis Unit (QDUs) have demonstrated the effectiveness for the diagnosis of suspected serious diseases on an outpatient basis, avoiding unnecessary hospitalization what supposes benefits so much economics as of comfort for the patient. The objective of our study is to describe the function of the QDU in the first 5 years of operation in the General Hospital of Segovia (Spain).

Methods

A retrospective descriptive study of the patients attended in the QDU of the General Hospital of Segovia, third level with 350 beds to cover an approximate population of 160,000 population. In the period between May 2012 and April 2017.

Results

During these 5 years, 2081 patients were treated with an average age of 64.48 years, the average delay for the first visit is 1.42 calendar days.

The main reasons for referral are: anemia, syndrome constitutional and abdominal pain, with slight variations between them, followed by lymphadenopathy, jaundice and rectal bleeding.

The patients have referred from Primary Care 40.26%. (838 patients), emergency 42.96% (894 patients) and other specialists 16.77% (349 patients).

The overall average time to diagnosis is 11.22 days with a median of 9.47. It fits highlight oncological diagnoses that have accounted for 25% of diagnoses, with an average delay of 14.71 days (median 14 days), the most frequent being digestive neoplasms (colon, pancreas, stomach), followed by lung and hematology. The destiny of the patients once discharged has been: primary, internal medicine, surgery and oncology.

Conclusion

The effectiveness of the Unit is demonstrated with the high percentage of serious pathologies diagnosed with very tight time averages (oncological diagnosis in 2 weeks), in most cases even lower than in patients admitted with the same pathologies. All this due to the ease of carrying out the first visit, the collaboration protocol of the central services for the carrying out complementary tests, as well as with the rest of the specialties that give preference to patients derived from our Unit.

The QDU of the General Hospital of Segovia has demonstrated its efficacy and effective as an alternative to conventional hospitalization for the diagnosis of potentially serious diseases (more 25% oncological diagnoses).

#508 - Abstract

INNOVATION IN HEALTH CARE, CONTINUOUS WIRELESS MONITORING TO IMPROVE MANAGEMENT OF CRITICALLY ILL PATIENTS: LIMS STUDY PRELIMINARY RESULTS

Filomena Pietrantonio¹, Anna Rosa Bussi², Elena Alessi¹, Matteo Pascucci¹, Mario Ronchetti³, Roberto D'Amico⁴, Gualberto Gussoni⁵

¹ Internal Medicine Unit - Internal Medicine Department Ospedale dei Castelli - ASL Roma 6, Roma, Italy

² Internal Medicine Unit Ospedale di Manerbio, Brescia, Italy

³ Health Management Head Office ASL Roma 6, Roma, Italy

⁴ Department of Medical and Surgical Sciences, Mother and Child and Adult Health, Modena and Reggio Emilia University, Medical Statistics Chair, Italy, Reggio Emilia, Italy

⁵ Fadoi Foundation, Milano, Italy

Background

Wireless vital parameter continuous monitoring (WVPCM) is compared to regular nurse monitoring in order to provide data on the clinical and economic impact of critically ill patients (CIPs) in Internal Medicine Units (IMU). Study Design: Pilot prospective randomized controlled open-label multi-center study with WIN@ Hospital wearable wireless system creating alerts on portable devices (ipad). Experimental Arm: CIPs with MEWS (Modified Early Warning Score) ≥ 3 and/or NEWS (National Early Warning Score) ≥ 5 at admission underwent WVPCM over the first 72 h. Active Comparator: CIPs with MEWS ≥ 3 and/or NEWS ≥ 5 at admission undergoing regular nurse monitoring.

Methods

Primary outcomes: reduction of major complications (MC) from 15% to 5%. Secondary outcomes: one day reduction in length of stay (LOS); reduced nurse monitoring time; accurate patient stratification and definition of end stage disease. Statistical methods: according to the preliminary study (Manerbio, 2016), 27% of hospitalized patients, of which 15% have MC, are critical (MEWS ≥ 3), and require monitoring. Clinical significance is set at 5% relative reduction in MCs in the experimental arm. 148 patients shall be recruited per arm (total 296; calculated by setting the alpha error at 5%, beta error at 20%, 80% test power, 5% loss).

Results

Preliminary results: Enrolled 145 and evaluable 125 patients (51 M/74 F), mean age 80.5 years, Comorbidity: Cumulative Illness Rating Scale CIRS-CI: 4, CIRS SI: 1.8. About 38% scored a BRASS (Blaylock Risk Assessment Screening Score) ≥ 20 indicating need for discharge planning requiring step-down care. More than 50% of patients present IIA index > 3 indicating high dependency from nursing assistance. Nurses saved a minimum of 49.6 minutes to a maximum of 58.1 minutes on time spent monitoring each patient per day. A trend towards reduction of major complications in the experimental group appears to be seen (31% versus 45%).

Decrease in re-admissions (7% versus 11%) and mortality (7.3% versus 23.9%) has been observed. More than 30% of the patients meet the criteria defining end stage disease.

Conclusion

WVPCM, detecting early deterioration in CIPs, may facilitate timely response in at-risk patients, increasing safety and reducing costs.

#521 - Case Report

LEAN HEALTHCARE APPLIED TO HOSPITAL PROCESSES: A CASE STUDY ON AN INTENSIVE CARE UNITY – ICU

Luis De Almeida Valle¹, Ruben Huamanchumo Gutierrez²

¹ Unimed Costa do Sol Hospital, Macaé, Brazil

² Federal Fluminense University, Niterói, Brazil

Introduction

This work is part of an applied academic research developed to improve the quality of the services performed in a healthcare institution, by using LEAN and Process Management methodologies, to achieve a standardized protocol for the prevention of ventilator-associated pneumonia (VAP) at an adult hospital Intensive Care Unity (ICU).

Case description

Nationally and internationally recognized databases and an extensive bibliographic survey were used in this work. Among the documents researched and used, there are protocols from renowned Brazilian and International Institutions. The healthcare professionals treating the inpatients at the ICU were the research universe. A semi-structured questionnaire, a comparative benchmarking, three focus groups, and a process flowchart were also used. The following steps were performed: a) identification of existing standardized national and international protocols for the VAP prevention process; b) development and proposition of a protocol to standardize the VAP prevention process, aiming at reducing the process variability and VAP incidence at the ICU; c) the validation of the newly designed protocol at the ICU.

In order to dry and reduce the variability of the activities and processes their standardization was sought, a protocol was designed from the bibliographic survey and the field research, and the validation by the ICU professionals was achieved. It was found that, at the ICU: a) there were not any standardized VAP prevention protocols; b) there were actions identified as isolated personal routine for the VAP prevention; c) some professionals used an alternative protocol for the VAP prevention, the Ventilator Bundle.

Discussion

The nonexistence of a standardized protocol for the VAP prevention was identified by 69% of the respondents. The personal routines mentioned by the professionals, carried

out as if they were protocols, showed that the team sought to guarantee the quality in the care of the patients. Some of the medical professionals mentioned the Ventilator Bundle as the sector's protocol for the VAP prevention. This was subsequently characterized as not actually so. This LEAN work contributed for the standardization of prevention procedures, reduction of work process variability, and reduction of resource waste due to ineffective measures, improving the services provided.

#578 - Abstract

THE PREVALENCE OF INAPPROPRIATE INTRAVENOUS POTASSIUM REPLACEMENT IN TWO MEDICAL WARDS OF A PUBLIC HOSPITAL IN SINGAPORE

Joelynn Qiao Bin Tay, Chaozer Er, Nicholas Wong Wai Cheong, Clarissa Hui Wen Aw

Woodlands Health Campus, Singapore, Singapore

Background

Mild hypokalaemia (serum potassium 3-3.4 mol/L) can usually be corrected with oral replacement. Intravenous potassium replacement carries the risk of phlebitis and arrhythmia. We intended to study the prevalence of inappropriate intravenous potassium replacement in two of our medical wards.

Methods

We prospectively collected the data of patients who were prescribed intravenous potassium replacement in two of our medical wards from 14/2/19 to 13/3/19.

Results

In that one month, 19 patients were prescribed intravenous potassium replacement. Out of the 19 patients, 5 patients had a serum potassium level of >3mmol/L. None of these 5 patients were given intravenous potassium replacement because of nil by mouth, ileus or malabsorption state.

Conclusion

The prevalence of inappropriate intravenous potassium replacement in our medical wards was estimated to be 24%.

#580 - Abstract

APPROACH OF DIABETIC PATIENTS IN A HOSPITAL AT HOME UNIT - A NOVEL REALITY

Rita Nortadas, Vitoria Cunha, Pedro Azevedo, Conceição Escarigo, Sofia Salvo, Claudia Viegas, Elvis Guevara, Joao Correia, Francisca Delerue

Hospital Garcia de Orta, Almada, Portugal

Background

Hospital at home (HaH) is an alternative model of inpatient hospitalization. Our Unit was the first in Portugal and started

activity on November 2015. More than 1,000 patients were already treated. Most of them were admitted for respiratory and urinary tract infection (UTI's), heart failure (HF), chronic obstructive lung disease and complex ulcers of lower limbs, for intravenous therapy, oxygen therapy, ventilation and topic treatment.

We created a professional group of Therapy and Health Education, aim to work on literacy and knowledge of inpatients and caregivers on diabetes. One of our main concern was about diabetic non insulinic therapy during the stay at UHD, because the treatment of hyperglycemia in a convencional ward is almost exclusively with insulin in every international recommendations. There is no literature about the treatment of diabetes in HaH unit.

Methods

This was a retrospective study that included all diabetic patients admitted at our Unit during the last 3 years (N=439). We have collected the information from clinic electronic registers (SAMS (R), SCLIN (R) and ALERT (R)) and treated in a data base program (EXCELL (R)).

Results

We analysed 439 diabetic patients, that were admitted at our Unit during the last 3 years which represents 38% of total of patients; 56% were women and the average age was 67.9 years. The causes of patient's admissions were 31% congestive HF, 31% UTI's, 14% respiratory infections and 12% skin infections. About renal function, 63% had decreased renal function but only 19% had <30mL/min/1.73m² and 31% had class III or IV the NYHA heart failure. Every patients had guaranteed diet, and only 3% needed a fasting period for some hours. Tomography with contrast was done in 2%. Six percent of patients used corticosteroids.

Conclusion

Patients in a HaH unit are clinically more stable, have less comorbidities that contraindicate non insulin therapy, need a smaller number of diagnostic complementary exames, rarely need fasting period and only a few of them are treated with steroids. We can assume that non insulin therapy should be maintained in this patients, but an individual consideration for each case should be done attending at its particular features. More studies are need yet to get consistent information about diabetic patients ingressed at HaH unit.

#650 - Abstract

IMPLEMENTATION OF HOSPITAL AT HOME IN PORTUGAL- 3-YEARS EXPERIENCE IN OUR UNIT

Claudia Viegas, Rita Nortadas, Vitória Cunha, Pedro Azevedo, Pedro Beirão, Elvis Guevara, Conceição Escarigo, Sofia Salvo, Ana Gomes, João Correia, Francisca Delerue
Hospital Garcia de Orta, Almada, Portugal

Background

The increase of chronic diseases and elderly people is a great challenge to the healthcare system and innovative solutions implementation is required. The main objective is offer a better treatment in a sustainable model of care, a typical feature of home hospitalization units (HHU).

Methods

In order to implement a HHU, we carried out a analysis of scientific articles about home hospitalization. The team also visited University Hospital Infanta Leonor, in Madrid, as they had previous experience in this area. Our team comprises: MDs, RNs, administrative secretary, nutritionist, social worker, psychologist, pharmacists and health manager advisor.

Results

We have already 1199 patients admitted, with a average length of stay 9.18 days and satisfaction index more than 93%. Our 3-years experience with very positive results regarding costs and patient/caregivers satisfaction queries led to a National Strategy Implementation of the HHU in Portugal. On the 3rd of October 2018, 25 other hospitals signed a protocol to create HHU in 2019. Currently 11 units are already entry in operation.

Conclusion

The good results of our unit were recognized by government and the Portuguese Health System is now promoting this model across all the country in an uniform way.

#770 - Abstract

USE OF BLANKET ORDERS IN OUR SERVICE OF INTERNAL MEDICINE

Víctor Madrid Romero, Anunciación Gonzalez López, Nuria Rodrigo Castroviejo, Carlota Tuñón De Almeida, Sara Muñoz Alonso, Victoria Palomar Calvo, Juan José Torres Ramos, Luis Miguel Palomar Calvo
Hospital Virgen de la Concha, Zamora, Spain

Background

One of the biggest problems we face on the Internal Medicine Service is the proper use of medication once the patient is discharged from the hospital, due to the patient's lack of comprehension of our reports. And between the problems of medical conciliation, the use of generic orders, known as blanket orders, is one of the biggest failures we made as physicians. It has been demonstrated to be a difficulty for the patient to complete adequately his treatment, so we will try to expose the cause of this practice in our service.

Methods

We perform a descriptive observational study in which we collect the number of patients hospitalized and the use of blanket orders, and type, at discharge from hospital in our service of Internal

Medicine during December 2018, trying to relate them with different factors, as gender, age, reason for hospital admission, pluripathology, polymedication and number of specialists involved in the monitoring.

Results

We recollect information about 202 patients, 48.5% been male and 51.5% female. 80.2% of them has multiple pathologies and 81.2% use several medications. Of all of them, 49.5% present blanket orders at discharge (the more frequent are "keep treatment as usual" (37.5%) and "same treatment before admission" (5.4%)). At least 25.8% are monitored by 3 or more specialists, 28.7% for 1 and 24.3% for 2. Comparing different variables, we cannot obtain statistically significant values and elucidate which of the variable influences the use of blanket orders.

Conclusion

Due to the lack of statistical significance we cannot demonstrate why we use blanket orders, or why we use it more than usual, but we can say at least that almost half the patients in our service has them in their medical report at discharge, and this is a practice we must eliminate of our daily practice.

Common sense will tell us that maybe the presence of multiples pathologies or medications, the duration of hospital admission or the number of specialists involved in the treatment make more difficult for us to make a proper medical report, but is our duty as warrant of the health of our patients to make sure they understand the medication we prescribe and they take it properly. If not, all the previous work made in their behave is almost useless. In order to improve this situation in our service we will make further investigation trying to discover this unknown cause, but meanwhile we will fight to concinnated the phisicians in our service.

#782 - Abstract

MANAGEMENT OF CHRONIC COMPLEX PATIENTS – COORDINATION BETWEEN INTERNAL MEDICINE AND PRIMARY CARE

Tiago Fiúza, Adelaide Belo, Sofia Sobral, Cláudia Vicente, Josiana Duarte, Teresa Goes, Isabel Taveira, Rui Seixas, Teresa Bernardo, José Sousa E Costa

Unidade Local de Saúde do Litoral Alentejano, Santiago Do Cacém, Portugal

Background

In the last decades there has been an increase in life expectancy, and subsequently an increase in the prevalence of chronic diseases, associated with functional and cognitive impairment and social problems. Inevitably, this leads to higher rates of healthcare use and added costs.

Methods

Chronic patients with multimorbidity who were identified as high-

users of healthcare services were enrolled in the project with the aim of keeping them clinically stable while at home, avoiding the overuse of those services. To each patient was attributed a Case Manager (nurse), who is in charge of coordination between different levels of healthcare (General Practitioners, Emergency and Hospital care) and the patient or his primary caregiver. The medical team is composed by General Practitioners and Internal Medicine specialists and residents, aided by nurses and social service workers. These are in constant contact with the case managers to devise and adjust an Individual Care Plan, which is the basis of the project, in terms of optimal medical treatment, but also because it includes the patient's psychic and social needs.

Results

As of February 2019, 87 patients were enrolled in the project. However, only the patients who had a follow-up period of ≥ 6 months were included in this analysis. The gender distribution was fairly equal (33 women, 32 men). The median age was 78 years (minimum 53, maximum 88). The mean Charlson Index Score was 6.3 (10-year survival estimation $< 2\%$). The mean Gijon Social-Familial Evaluation Scale was 7. After a follow-up of ≥ 6 months, we saw a 61% reduction in the number of Emergency Room (ER) admissions, a 66% reduction in the Basic ER admission rate, a 55% reduction in Primary Care appointments and a 55% reduction in the hospitalization rate. Among the hospitalized patients, the mean length of stay was reduced from 10 to 7.2 days. There was a slight increase in hospital appointments, since all the patients are followed by an Internal Medicine specialist, apart from other needed specialty appointments. Subsequently, all the previous results translated to estimated savings of 189.912.41€.

Conclusion

The early detection of patients suffering from chronic diseases and their coordinated follow-up between different levels of healthcare, using case management and telemonitoring, is proven to have reduced costs and improved health indicators. The Internal Medicine specialty is fundamental in the holistic management of these patients.

#812 - Abstract

HOW KEEN ARE RESIDENTS ON CONDUCTING BEDSIDE ROUNDS?

François Bastardot^{1,2,3}, Vanessa Kraege¹, David Gachoud^{1,4}, Matteo Monti^{1,4}, Julien Castioni^{1,5}, Antoine Garnier^{1,6}

¹ Department of Medicine, Lausanne University Hospital (CHUV), Lausanne, Switzerland

² Division of General Internal Medicine and Primary Care, Brigham and Women's Hospital, Boston, United States

³ Harvard Medical School, Boston, United States

⁴ Medical Education Unit, School of Medicine, University of Lausanne, Lausanne, Switzerland

⁵ HR Department, Lausanne University Hospital (CHUV), Lausanne, Switzerland

⁶ Medical Directorate, Lausanne University Hospital (CHUV), Lausanne, Switzerland

Background

Medical rounds are the center of the Internist's day. Residents are free to organize this time, which is usually shared between the hallway and patients' rooms. Conducting rounds in patients' rooms increases the degree of patient satisfaction and decision sharing. What proportion of rounds is spent in patients' rooms? What are the associated resident characteristics?

Methods

Residents of the Department of Medicine, in the Lausanne University Hospital (Switzerland), were observed during a time-motion study between May and July 2018. Simultaneously, we collected their movements using over 383 RFID chips disposed throughout the wards. We considered the sum of activities tagged by observers as "rounds" between 9:30am and 12:30pm as "medical rounds".

Results

Thirty-two residents (56% women, 18/32) were followed for 53 day shifts. Their clinical experience was 40 ± 17 months. Round duration was 87 ± 32 minutes for an average of 8.8 ± 2.5 patients per Resident. Although round length increased with the number of patients (Spearman's rho 0.29, $p=0.03$), it decreased with clinical experience (-0.31 , $p=0.03$). The proportion of round time spent in patients' rooms was $52.6 \pm 20.9\%$. This percentage decreased with clinical experience (rho -0.29 , $p=0.03$), but was not associated with the number of patients ($p=0.36$), the resident's gender ($p=0.92$), nor the country of graduation ($p=0.76$). There was no correlation between bedside time and round duration after adjustment for number of patients and clinical experience ($p=0.91$).

Conclusion

Despite a department policy demanding that the entire rounds be conducted at the patients' bedside, residents spend only half of rounds in patients' rooms, with significant variation among them. Reluctance might be explained by confidentiality concerns, paternalistic attitudes towards patients, and thinking that bedside rounds are time-

consuming. According to our data, this latter common belief is wrong. This is a crucial argument to conduct full rounds at patients' bedside.

#814 - Abstract

HEALTH INFORMATICS IN THE HOSPITAL: HOW MUCH AND WHERE DO INTERNISTS USE THE COMPUTER?

François Bastardot^{1,2,3}, Vanessa Kraege¹, Julien Castioni^{1,4}, Pierre-François Regamey⁵, Gérard Waeber¹, Antoine Garnier^{1,6}

¹ Department of Medicine, Lausanne University Hospital (CHUV), Lausanne, Switzerland

² Division of General Internal Medicine and Primary Care, Brigham and Women's Hospital, Boston, United States

³ Harvard Medical School, Boston, United States

⁴ HR Department, Lausanne University Hospital (CHUV), Lausanne, Switzerland

⁵ IT Department, Lausanne University Hospital (CHUV), Lausanne, Switzerland

⁶ Medical Directorate, Lausanne University Hospital (CHUV), Lausanne, Switzerland

Background

Health informatics have changed the practice of medicine. The electronic health record is now Internists' primary tool for clinical documentation, prescription of drugs, laboratory tests and radiology exams, as well as reporting consultants' notices. After twenty years of evolution in a Swiss University Hospital, how much are health informatics used? Are physicians still bound to a desktop computer? How present is the computer in the doctor-patient interaction in the hospital?

Methods

Residents of the Department of Medicine, in the Lausanne University Hospital (Switzerland), were observed during a time-motion study between May and July 2018. We recorded activities and contexts (patient contact and computer use). Simultaneously, we collected residents' movements using 383 RFID chips distributed around the wards. Day shifts were 8:00 am to 6:24 pm. Observations without geolocation data (13%, 9/67) were dropped.

Results

Thirty-three residents (58% women, 19/33) were followed for 58 day shifts. Their postgraduate training was 3.2 ± 1.5 years. Daily computer use was 289 ± 73 min, with a range from 150 min to 485 min. Women tended to use the computer longer than men (302 ± 62 min vs 270 ± 83 min, $p=0.095$). Time with computer decreased significantly with postgraduate training (R^2 0.15, coefficient -1.69 , $p=0.003$), but did not increase significantly with the number of patients handled ($p=0.180$). Residents used a computer 57% of time (165/289 min) in the medical office, 14% (39/289 min) in the hallway, 7% (19/289 min) in patients' rooms, and 22% (66/289 min) in other areas. While in contact with inpatients, residents used the computer only 6% of time (5/92 min).

Conclusion

Even though computer use diminishes with postgraduate training, physicians spend significant time on the computer. They are no longer bound to the medical office, but still have not incorporated computer use to the patients' bedside.

Health informatics use still represents a marginal proportion of bedside time, which differs significantly from the ambulatory setting, where computer use complicates the doctor-patient relationship.

#828 - Abstract

EFFECTIVENESS OF AN ACUTE MEDICAL ADMISSION BUFFER UNIT ON IN-HOSPITAL PATIENT FLOW-LOGISTICS AND CLINICAL GOVERNANCE

Ciro Canetta¹, Silvia Accordino¹, Elisa La Boria¹, Michela Masotti¹, Pietro Formagnana¹, Stella Provini¹, Sonia Passera¹, Fabiola Sozzi²

¹ Ospedale Maggiore ASST Crema - UO Medicina Generale e di Accettazione Urgenza, Crema, Italy

² Ospedale Maggiore Policlinico IRCCS Milano - UO Cardiologia, Milano, Italy

Background

Increasing number of acute complex medical patients accessing to Emergency Department (ED) and needing different levels of care require hospitalization. This involves prolonged boarding in ED, hospital overcrowding, increase in hospital bed occupancy rate and outlying phenomenon. Consequences are longer length of stay (LoS) and escalating clinical risk. We analysed the effects on patient flow logistics and clinical governance of a high technology/time-limited medical buffer unit, interconnected with hospital's macro-organization as an interface between primary services (ED) and downstream medical specialty wards, in the first-level ED hospital of Crema (Italy). Medical Admission Unit (MAU) is a logistically and functionally distinct more intensive care section of the intermediate-care Internal Medicine ward (IMw), both configuring a single Internal Medicine Unit (IMU)

Methods

All consecutive patients admitted to MAU over one year period since its introduction (Dec 2017–Nov 2018) have been included. Data regarding inflow provenance (ED or other wards) and outflow status (discharge, transfer or death), destination wards, LoS, main diagnosis, high care setting and mortality have been analysed. Central data from hospital collection system (total number of ED admissions, total days of hospitalization and average duration, in-hospital mortality, total number of outliers' bed-days splitted into medical and surgical department) have been compared to those from the previous year.

Results

Out of the 1194 patients considered, 96.2% were from ED and 3.8% from other wards (due to clinical instability). 27.4% were

directly discharged (or died), the others were transferred to IMw or other medical specialty wards (47.6% and 25% respectively). Despite a 31.4% increase in IMU admissions from ED we observed: 1) a reduction in global IMU LoS (10.3 vs 11.2 days); 2) an outlier/overall bed-days reduction (7.9% vs 10.9%), particularly in surgical department (6.8% vs 12.2%); 3) an in-hospital mortality reduction, either considering IMU (7.4% vs 10%) or the whole medical department (4.6% vs 5.7%).

Conclusion

Reorganization of patient flow has shown an interdepartmental positive effect reducing outlying phenomenon. This effect, in addition to patient-centered/problem-oriented approach to complex patients' management in a more intensive care buffer unit, has shown an improvement in standards of care and clinical governance, decreasing overall LoS, clinical risk and in-hospital mortality.

#868 - Abstract

INTELLIGENT SYSTEMS FOR IMPROVING THE CORRESPONDENCE BETWEEN THE DIAGNOSIS MADE BY 118 OPERATIVE CENTER AND EMERGENCY DEPARTMENT

Clara Balsano, Enrico Pallotta, Daniela Buccella, Barbara Romano, Maria Pettinelli, Gino Bianchi, Mario Petrucci, Luigi Valenti, Nicolò Casano

School of Emergency and Urgency Medicine, Department of Clinical Medicine, Life, Health & Environmental Sciences-MESVA, University of L'Aquila, L'Aquila, Italy

Background

The Italian Ministry of Health published in 2015 a report, Computer System for Monitoring Health oversight (SIEMES) on 27 alert events reported by Italian hospitals and collected from 2005 to 2012. In keeping with, several studies in the literature indicate that the main risk during the calls made to the 118 Operative Center (OC) is wrong triage codes assigned to time dependent pathologies, such as cardiovascular and neurological (vascular based) attacks.

In these latter, the misinterpretation of the diagnosis by 118 OC has significant effects on the outcome of diseases: longer hospital stays, longer periods of rehabilitation, higher cost for the Health System.

We would like to improve, in myocardial infarction/heart attack and stroke, the existent gap in making a correct diagnosis by 118 O.C. to activate, as soon as possible, the appropriate triage code. Our study has been developed in Abruzzo Region (Italy).

Methods

We examined and compared, by Machine Learning and Deep Learning methods, the database of 118 O.C. and Emergency Department (E.D.), collected in 2017 and 2018 years. In particular, the retrospective analysis was done in patients who, between 2017 and 2018 years, made a call to 118 O.C.

Results

We evaluated the congruence between the diagnosis made at the first call to 118 O.C. and at E.D. We observed a mismatch correspondence, between the data collected by 118 O.C. and ED, regarding cardiovascular (24%) and neurovascular (30%) codified events.

Our analysis took advantage from the use of a language of information ontology. This allowed us to manage the data information overload, transforming data in OWL coding, in order to receive a faster feedback to our QUERY.

To improve the error rate of misdiagnosis we are developing and validating innovative technological supports (voice recognition software, app etc.).

The voice recognition software should help to collect patient information during the first call to 118 O.C. supporting operative personnel in sending by a smartphone or tablet App reliable and controlled data to physicians.

Conclusion

Intelligent Systems could help in improving the correspondence between the diagnosis made by 118 Operative Center and Emergency Department. The use of informatics tools which can speed up the communications of patient personal data by 118 O.C. to physician and allow more effective interventions.

Our work will create better conditions in emergency to improve the Health System financial burden, too.

#949 - Abstract

HYPERUSERS IN THE EMERGENCY DEPARTMENT IN DISTRICT HOSPITAL

Sónia Da Costa Fernandes, Vera Seara, Gonçalo Mesquita, Juliana Chen Xu, Joana Gonçalves, Teresa Pinto
CHPVVC, Vila Do Conde, Portugal

Background

Emergency Department (ED) in Portugal is daily confronted with the problem of overcrowding and excessive waiting times. As such, it is imperative to identify and characterize the pattern of the most frequent users, although there is still a great heterogeneity in its definition.

OBJECTIVES: To characterize users aged 18 or over, who most attended the ED of a District Hospital in the year 2018.

Methods

A retrospective descriptive study of hyperusers in the ED from a District Hospital in the period from January to December 2018. The authors defined hyperusers as those with a frequency equal to or greater than 10, and this was documented by consultation of the clinical computer process using SClinico program.

Results

50,375 admissions were made in the ED in the year 2018. 169

users made 10 or more of these admissions, corresponding to 2732 (5.4%) of the total ED admissions in the past year. The majority were women (63.3% - 107 patients), compared to 62 male users (36.7%). The mean age was 53.7 years (Standard Deviation (SD) 22.6 years), with a minimum of 18 years and a maximum of 101 years. 60 users (35.5%) had 65 years old or higher and 19 users (11.2%) were very elderly patients with 85 years old or higher. The mean number of admissions to the ED was 16 (SD 13.8). The higher user was admitted 138 times the ED, and she was a 42-year-old woman with Crohn's disease history, that was taking tuberculostats intravenously for disseminated tuberculosis. 68 (40.2%) of these users had some mental illness or additive behavioural pathology and 26 (15.4%) were pregnant women. 46.7% (N = 79) of the patients presented with cardiovascular disease, 8.9% (N = 15) had a known oncological disease. Of these 169 patients, 48 (28.4%) required at least 1 hospitalization at the Internal Medicine service of that Hospital, due to one of the admissions in the ED.

Conclusion

In this ED we conclude that a large part of the hyperusers had cardiovascular risk factors and a very significant percentage of this population had a history of mental illness. Almost 50% of patients was 65 years old or higher. We believe that better articulation and coordination of Secondary Care with Primary Care can provide a possible solution to this problem.

#958 - Abstract

HOSPITAL AT HOME - THE FIRST 1000 PATIENTS TREATED AT THE FIRST PORTUGUESE UNIT

Pedro Correia Azevedo, Rita Nortadas, Vitória Cunha, Conceição Escarigo, Pedro Beirão, Ana Gomes, Sofia Salvo, Elvis Guevara, João Correia, Francisca Delerue
Unidade de Hospitalização Domiciliária - Hospital Garcia de Orta, Almada, Portugal

Background

Home hospitalization is an alternative to the conventional acute hospitalization that arose in the 1940s in the United States. The adherence has grown to this safe, effective, and responsive approach to a large number of acute medical conditions avoiding the problems associated to conventional hospitalization.

Methods

In Portugal, Hospital Garcia de Orta first adapted this concept with the Unit for Home Hospitalization in 2015. The authors present the data from the first 1000 patients treated at the first portuguese hospital at home unit, which corresponds to 3 years of activity.

Results

1000 patients were hospitalized (from a universe of 1932

referrals), mean age 62 years. The mean length of stay was 8.6 days; it corresponded to 8512 days of hospitalization. Most patients came from the emergency department (66%). Pluripatology, polypharmacy and the increasing complexity of the admitted patients were highlighted. The most frequent diagnosis in medical patients was community-acquired pneumonia and in surgical patients was wound infection. Few intercurrents occurred during hospitalization; in 8.95% there was a return to the hospital. At discharge, the majority of patients were referred to the outpatient hospital. 30 days after discharge, clinical stability predominated. The cost per patient is 40% lower than conventional hospitalization.

Conclusion

This model of hospitalization has demonstrated the potential to include more and more patients and the experience of the first Portuguese unit is already contributing to the expansion to other hospitals in the country.

#998 - Abstract

ANTIBIOTIC CONSUMPTION IN AN INTERNAL MEDICINE WARD

Sofia Furtado, Marta Torre, António Figueiredo Trigo, Manuel Monteiro, Liliana Dias

Centro Hospitalar Universitário Lisboa Central, Lisboa, Portugal

Background

The increasing prevalence of antibiotic (ATB) resistance is a threat to public health. The systematic use of ATB leads to the emergence of multiresistant bacteria and potentially untreatable infections. In 2012, 45.3% of inpatients in Portugal received an antibiotic, compared to 35.8% in Europe. The purpose of this study is to describe the ATB consumption burden in an Internal Medicine (IM) ward to identify potential points of improvement.

Methods

Prospective observational study of ATB use in an IM ward of a central tertiary hospital in Lisbon. All patients consecutively admitted in 2 months (11-12/2018) were included.

Results

There were 205 admissions. Median age was 79 (67-85) years, 54% were women and Charlson Comorbidity Index was in average 5.6 ± 2.8 . Median length of stay was 10 (5-18) days. One-hundred and seventy-one (83%) patients were admitted from the emergency room. Thirty-five (17%) were in an intensive/intermediate care unit before or during hospitalization in the ward. In the previous 90 days, 67 were hospitalized, 55 had an ATB prescription and 24 were submitted to an invasive procedure. One-hundred and six (52%) patients were admitted with signs of a bacterial infection (61% respiratory, 30% urinary; 12% nosocomial) and had an ATB prescription (94% as empirical therapy). The majority (n=80) started ATB in the emergency room.

Cultures were previously done in 75 cases, which were positive in 37.

The most common initial ATB were: ceftriaxone (n=39), azithromycin (n=36), amoxicillin/clavulanate (n=30), piperacillin/tazobactam (n=19). Median duration of initial ATB was 5 days (2-7). The initial ATB was changed in 44/106 cases: escalation for clinical reasons (n=11), de-escalation according to sensibility test (ST) (n=4), adequacy to ST (n=4), adequacy to clinical context (n=4), stopped for no consistent signs of infection (n=12), change from IV to oral/IM (n=4), adverse effect (n=2), other (n=3).

Overall, in the study period, 128 (62%) patients received at least one ATB and ATB were used in average in 43% of inpatient days. There was a total of 255 ATB prescriptions, with a total of 131 infections.

Conclusion

ATB were frequently prescribed in an IM ward, where patients are often frail. There was a high rate of changes to the initial ATB prescription and a low de-escalation rate, despite of cultures being frequently done. ATB stewardship policies are needed to improve ATB use.

#999 - Abstract

IMPROVING EDUCATION TO INCREASE AWARENESS AND COMPLIANCE TO NATIONAL EARLY WARNING SCORE (NEWS) IN THE ACUTE MEDICAL WARD (AMW)

Rachel Wenrui Lim, Than Zaw Oo, Tharmmambal Balakrishnan, Hartini Bte Osman, Yucai Yee, Chee Woei Lee, Huiyan Lu, Daniel Seto Yuan Wah, Wan Tin Lim

Singapore General Hospital, Singapore, Singapore

Background

The National Early Warning Score (NEWS) has been validated and implemented in our Acute Medical Ward (AMW) in Singapore General Hospital. Compliance rate to the response plan however has been poor, with one important reason being the lack of awareness among the healthcare providers. The aim of our study was to improve the education of NEWS to the doctors.

Methods

There were two cycles of education periods, each with an end survey to assess the doctors' understanding and perception of NEWS. For the first cycle, educational powerpoint slides were created by a team of doctors and nurses of the Quality Improvement team which were used to conduct briefings to doctors and nurses during teaching sessions and also disseminated to all doctors via email. The contents were concise and comprised of common scenarios to illustrate expected response plans for each NEWS risk categories. In the second cycle, additional monthly teaching sessions were given to the teams of doctors working in the AMW. Questionnaires were conducted at the end of each cycle to assess their understanding and perception of NEWS.

Results

AMW House officers and Medical officers were surveyed. The response rate of the first survey (S1) was 29 out of 36 (80.56%) whilst the second survey (S2) was 15 out of 22 (68%). Attendance rate at the NEWS education briefings were similar at 79% and 87%, with 65% and 62% of doctors agreeing that the briefing was useful. The education slides sent via email were only reviewed by 28% of doctors in S1, with improvement to 40% during S2. More doctors also reported having looked at the NEWS score or colour zone for their patients during S2(67%) as compared to S1(48%). Both surveys were unifying in the statement that the most common reason for the poor compliance rate was that they were not informed by the nurses about the NEWS score. 76-88% doctors reported the NEWS colour zone was informed by the nurses in only less than 20% of phone calls.

Conclusion

The implementation of NEWS system in a tertiary hospital has many challenges. Although NEWS has been validated to improve the identification of deteriorating patients, it requires acceptance, compliance and adherence to the response plans in order to have improved patient outcomes. Education of staff remains important in the initial phase of implementation. The survey results provided valuable insights into areas where we need to improve, to reinforce the use of NEWS colour zone as common language among healthcare providers to create better awareness.

#1011 - Abstract

CHOOSING WISELY CAMPAIGN: TOP FIVE RECOMMENDATIONS BY THE TURKISH SOCIETY OF INTERNAL MEDICINE

Pinar Yildiz ¹, Mine Durusu Tanriover ², Serhat Unal ³

¹ Eskisehir Osmangazi University Faculty of Medicine, Department of Internal Medicine, Eskisehir, Turkey

² Hacettepe University Faculty of Medicine, Department of Internal Medicine, Ankara, Turkey

³ Hacettepe University Faculty of Medicine, Department of Clinical Microbiology and Infectious Diseases, Ankara, Turkey

Background

Today, it is important to make intelligent choices in every aspect of our lives. In health, the smart choice is high-quality care that provides the greatest benefit. In other words, making rational choices in health services makes it possible to increase health quality, reduce waste, and maintain patient safety. Using the slogan 'Less is More', Choosing Wisely Campaign emphasizes the use of smart choices in order to prevent excessive and unnecessary practices that threaten patient safety and lead to waste in health resources. We have been working with the European Federation of Internal Diseases (EFIM) for the Choosing Wisely campaign since January 2017 as the Turkish Society of Internal Medicine (TSIM). Here, we aim to present the methodology and the results of our Choosing Wisely top five list.

Methods

The top five list of the TSIM was formed through a two-step process. A panel was established by ten members of the board of academic internal medicine of the Society. They reviewed all of the lists of evidence-based recommendations and sorted out the recommendations that are most likely to be relevant in daily practice of internists in Turkey. Each member of the panel chose ten recommendations and finally thirteen recommendations were determined as they scored the most points. These recommendations were then voted by the internists and residents working in different hospitals in two meetings of TSIM where Choosing Wisely campaign was introduced.

Results

Forty-two residents and 28 internists who attended a conference on Choosing Wisely Campaign voted among the thirteen recommendations that were retrieved from the first step of the project. The five recommendations that got the highest score were as below:

1. Don't perform repetitive CBC and chemistry testing in the face of clinical and lab stability.
2. Don't use unnecessary invasive devices such as urinary catheters.
3. Don't perform routine general health checks for asymptomatic adults.
4. Don't perform unnecessary transfusions.
5. Don't prescribe drugs without a drug overview.

Conclusion

The Turkish Society of Medicine leads the first initiative of the Choosing Wisely Campaign in Turkey. Outlining the top five recommendations was the first step of the project. These recommendations pertained to common medical practices in both ambulatory and hospital care. We believe that this is both a social and a professional project that should be strengthened by involving different stakeholders for the implementation of these recommendations.

#1024 - Abstract

STUDY OF THE LABOR STRESS IN MEDICAL AND NURSES OF CRITICAL CARE AND DEPARTMENTS OF EMERGENCIES: PREVALENCE AND ASSOCIATED FACTORS

Pascual Valdez¹, Verónica Sánchez¹, Liliana Pierini¹, Cintia Simón¹, María Del Rosario Bruno¹, Jesica Rodriguez Pavón², Daniel Elisabe², Adriana Pose², Rosa Castagna², Marcos Zec Baskarad², Hugo Zelechower²

¹ Vélez Sarsfield Hospital, Government of the Autonomous City of Buenos Aires, Caba, Argentina

² Vélez Sarsfield Hospital, Government of the Autonomous City of Buenos Aires, Buenos Aires, Argentina

Background

Objectives: To determine factors predictors / associated to wear in the 3 dimensions of burnout syndrome: depersonalization (DP), professional performance (RP) and emotional fatigue (CE).

Methods

Prospective design, 98 doctors (M) and nurses (E) of Intensive Care and Emergency Department of Velez Sarsfield Hospital were studied

Results

DP: 9.77 ± 0.66 , RP: 34.54 ± 0.92 and CE: 27.77 ± 1.10 . Higher DP in males (10.47 vs. 9.20, $p < 0.0002$). Age, professional seniority and institutional seniority: 41.22, 14.31 and 10.66 years respectively, younger age is predictive of PD ($p: 0.03$) and lower professional age predictive of PD ($p: 0.03$) and CE ($p: 0.03$). RP nurses intensivists vs others: 29.14 ± 2.88 vs 38.08 ± 1.65 , $p: 0.02$. High wear showed 51.02% in DP, 37.75% in RP and 56.12% in CE; 24.48% have all three dimensions burned. 69.38% reported having ever made mistakes due to work conditions, pNS M vs E, the presence of errors was associated with DP ($p: 0.001$), CE ($p: 0.001$) and RP ($p: 0.01$). The health alterations that occurred after the start of work were presented with a mean of 4.80 ± 0.26 , CE and RP were predictors of the number of health problems ($p: 0.0000$ and 0.03 respectively).

Conclusion

They associate high DP: men, younger age, lower professional seniority, single people, presence of errors, lower job satisfaction. Associate low PR: intensive care nurse, singles, presence of errors, number of health problems. They associate high CE: lower professional seniority, presence of errors, less extra-labor satisfaction, lower job satisfaction, number of health problems.

#1026 - Abstract

EVALUATION OF THE CONTINUITY OF AMBULATORY TREATMENT IN ADDICTIONS

Pascual Valdez, Marina Riso, Silvia Cortese, Carlos Damin Juan A. Fernandez Hospital. Toxicology Division, Caba, Argentina

Background

Introduction: The lack of continuity in the treatment of patients suffering from addiction is one of the main difficulties faced by professionals working with this problem. The premature abandonment of the treatment correlates with a greater number of relapses and worse prognosis.

Objectives: To evaluate the continuity in the treatment of patients who consult for problematic substance and tobacco use in a toxicology office.

Methods

Retrospective, longitudinal, observational, analytical design. Clinical histories entered in the last year were reviewed. Consecutive sampling. Descriptive and inferential statistics.

Results

The continuity in patients with problematic substance use (cocaine, PACO, marijuana) (N=418) was 45% at the 1st month, from 22% at the 3rd month and from 10% to the 6th month; in the patients who consulted due to smoking (N=211), the continuity was lower, from 38% at 1 month and from 9% at 3 month ($p < 0.001$). Within the group of patients with substance use, those who exclusively consume alcohol (N=96) showed the greatest continuity, being at the 1st, 3rd and 6th month, 47%, 33% and 18% respectively ($p=0.012$)

Conclusion

In this study, the continuity of treatment in the ambulatory device at 3 and 6 months is lower than some found in the literature, but it reproduces the known lower continuity in cocaine or base paste users as opposed to other substances such as the alcohol.

#1030 - Abstract

MULTICENTER STUDY ABOUT ETHICAL CONFLICTS IN INTERNAL MEDICINE

Pascual Valdez¹, Mariana Peñalba¹, Javier Parodi¹, Emilce Carrizo¹, Nanci Camo¹, Eduardo Del Cerro¹, Mariano Isuz¹, Cristián Panigadi¹, José Daher¹, Pablo Centeno¹, Pablo Kuschner¹, Andrés Vilela¹, Lucia Valdez¹, Paula Vendramini¹, Benjamín Ruiz Valdepeñas¹, Antonio Blanco Portillo¹, Luis Alberto Cámara²

¹ Research Council of the Argentine Society of Medicine (SAM), Caba, Argentina

² Research Council of the Argentine Society of Medicine (SAM), Buenos Aires, Argentina

Background

Objectives: To know which are the main ethical conflicts (conflict of values) that internists face in daily practice.

Methods

Survey administered through coordinators in medical clinic services of public hospitals Argerich, Durand, Santojanni and Vélez Sarsfield (GCBA), Ramón Carrillo, Paroissien and Simplemente Evita (PBA), and Santa Isabel Sanatorium (CABA).

Results

There were 156 respondents (62.82% women). Age 36.10 ± 0.80 years. Years of professional practice 10.06 ± 0.79 years. 71.79% frequently encounter ethical conflicts that in 41.01% make it difficult for them to practice daily. 68.33% satisfactorily resolve ethical conflicts. Regarding the finding of ethical conflicts: women > men 75% vs 64% (P 0.005). In relation to difficulty in daily practice generated by the conflicts found: women > males 45% vs 35% (P 0.03), degree of difficulty: women > males 64% vs 58% (P 0.01). Satisfactory resolution of conflicts: men > women 69% vs 52% (P 0.02), staff > professionals in training 72% vs 46% (P 0.005), higher professional seniority in linear regression (P 0.0019). The most common way to resolve ethical conflicts is to consult colleagues 71% vs 29% the rest of the options (P <0.00001), pNS between men and women. The most frequent conflicts: CPR, limitation of efforts, palliative care and communication.

Conclusion

More than half find important conflicts in their practice. Satisfactory resolution of conflicts is greater in men than in women, in plant vs. residents and as professional seniority increases.

#1248 - Abstract

IMPACT OF AN ANTIBIOTIC STEWARDSHIP PROGRAM IN MANAGING COMMUNITY-ACQUIRED PNEUMONIA AMONG EMERGENCY DEPARTMENT

Gabriele Angelo Vassallo¹, Adwoa Agyei-Nkansah²

¹ Barone Lombardo Hospital, Canicatti, Italy

² Department of Internal Medicine, University of Ghana, Accra, Ghana

Background

Antibiotic stewardship refers to a set of coordinated strategies to improve the use of antimicrobial medications with the goal of optimizing patient clinical outcomes, reducing the emergence of resistance and decreasing unnecessary costs. The aim of this study is to evaluate the impact of an Antibiotic Stewardship Program in managing Community-Acquired Pneumonia among Emergency Department.

Methods

Medical records of patients with Community-Acquired Pneumonia admitted to Emergency Department of a Sicilian Hospital were retrospectively abstracted. Based on this data, local microbiological reports and international clinical guidelines, a local Antibiotic Stewardship Program for the management of pneumonia was drawn-up. Through a simulation model, the Antibiotic Stewardship Program was applied to collect data to predict its performance in the real world.

Results

The application of this Antibiotic Stewardship Program reduced rate of hospitalization (-40%), length of stay in Emergency

Department (from 8 to 1 day), prescription of corticosteroids (-10%) and antibiotics (-9.6%) in particularly carbapenems (-96%) and quinolone (-87,5%). Finally, the overall cost of antibiotic therapy significantly decreased (-89,7 %).

Conclusion

Based on these results, an Antibiotic Stewardship Program, if implemented in an Emergency Department, will improve hospital performance, reduce prescription of corticosteroids and antibiotics with consequent reduction of cost. Prospective and multicentric studies are needed to confirm these preliminary data.

#1252 - Abstract

MAJOR BLEEDING IN AN INTERNAL MEDICINE WARD – FROM INCIDENCE TO RISK FACTORS

Lénio P. Couto^{1,2}, Ana D. Mendes¹, Tiago Gonçalves¹, Marta C. Amaral¹, José Delgado Alves¹

¹ Serviço de Medicina IV, Hospital Professor Doutor Fernando Fonseca, Lisboa, Portugal

² Serviço de Medicina Interna, Hospital Santo Espírito Ilha Terceira, Angra do Heroísmo, Portugal

Background

Major bleeding is a frequent concern in medical practice. In Internal Medicine wards patients are older and frailer, with many comorbidities and acute illnesses, sometimes requiring invasive procedures which may increase the risk of bleeding. Although the incidence and risk factors for bleeding are broadly described in outpatients, little is known regarding hospitalized patients, namely in Internal Medicine wards.

Methods

An observational retrospective case-control study was conducted. We revised clinical files from all patients admitted in our ward between July 2017 and July 2018. Cases were defined by in-hospital major bleeding (bleeding of a critical organ, a hemoglobin level fall ≥ 2 g/dL, or the need for transfusional support). A control group was randomly created. Patients' demographics, diagnosis and therapeutics were registered and both groups were compared using Mann-Whitney and Chi-square tests.

Results

From a total of 1508 patients admitted in that period of time, 22 had major bleeding - incidence of 1.46%. Most occurred within the first two weeks of hospitalization (10.4 ± 8.4 days), 91% were managed conservatively and we found 3 deaths (13.7%) directly related to hemorrhage. Spontaneous bleeding (81.8%) occurred mostly from gastrointestinal tract (36.4%) and soft tissues (18.2%). Comparing to control-group, patients with major event were older (78.9 ± 10.5 years, $p=0.007$) and more frequently on anticoagulation (54.5%, $p=0.011$) or on antiplatelet therapy - simple (40.9%, $p=0.011$) or dual (9.1%, $p=0.031$). Also, there were

more patients with heart failure (59.1%, $p=0.031$), chronic kidney disease (45.2%, $p=0.008$), gastritis (22.7%, $p=0.013$) and liver failure (18.2%, $p=0.013$) in the bleeding group.

Conclusion

Major bleeding is rare in Internal Medicine wards. Nevertheless, it must be early identified and carefully managed. Heart failure, chronic kidney disease, gastritis, liver failure, anticoagulants and antiplatelet drugs might constitute risk factors for bleeding in inpatients. Stronger studies are needed to confirm these associations.

#1283 - Abstract

DOING THE BEST FOR PATIENT ATTENDED BY INTERNAL MEDICINE PHYSICIANS: NET PROMOTER SCORE RESULTS

Marta León Téllez, Jose María Sierra Manzano, Purificación Sánchez Oliva, Igor Andronic
Santa Barbara's hospital, Soria, Spain

Background

Knowing the opinion of patients about their care by the internal medicine physicians is something that every institution should know for current consequently and adopt the necessary measures for its improvement and reach the highest quality. To know and do now what they need next because the improvement of the quality of care goes hand in hand with the improvement of the patient's experience.

Methods

A tactile terminal "blackmirror" is implanted in the service with a self-designed questionnaire in the emergency department, one of the questions is "how can we improve" and answers are collected in the so-called "moment of truth" just the attention of the internist is evaluated almost at the moment what allows an instantaneous feedback. With the opinions and results (the answer range goes from 0-10), a training course for internal medicine personnel about kindness and treatment is designed and established to improve this most negative aspect.

After the course a period of four months is evaluated, with the same questionnaire of initial attention.

Results

More than five thousands opinions from April to December of 2018 (before the course) and almost two thousands from January to April of 2019 (after the course).

More than five thousands opinions from April to December of 2018 (before the course) and almost two thousands from January to April of 2019 (after the course).

Improvement of the NPS is evidenced from -15.4 in 2018 to -9.7 in 2019, also from the overall satisfaction of 5.6 to 5.7, and from the waiting time from 2.61 to 2.71, the fulfilled expectations go from 3.31 to 3.37, maintaining professionalism stable.

Kindness and treatment were evaluated as the second problem of medical care and after the course they moved to a third place

Conclusion

The patients must be listened to as soon as possible after their experience with the health care. The NPS through "blackmirrors" allows to detect problems, establish improvement actions and evaluate the results of its implementation. All of us. All of us, patients, internists, others health workers, we must take a leap in the quality of care with training.

#1373 - Abstract

IDENTIFYING RISK FACTORS FOR BLADDER CATHETERIZATION IN INTERNAL MEDICINE PATIENTS: CAN IT BE HELPFUL FOR CLINICAL PRACTICE?

Maria João Lobão^{1,2}, Paulo Sousa²

¹ Cascais Hospital, Cascais, Portugal

² NOVA National School of Public Health, Lisboa, Portugal

Background

Urinary tract infections are one of the most common nosocomial infections worldwide and the vast majority of it is indwelling catheter related. Bladder catheterization is a very frequent procedure. In many cases, catheters are placed inappropriately leading to prolonged and unnecessary use. We aimed to identify risk factors for bladder catheterization in patients admitted to internal medicine wards that could help clinical decision about catheter placement in addition to recommended indications.

Methods

We performed a historical cohort study that included a systematic random sample of 388 patients, representative of the 3492 admissions occurred in a Portuguese internal medicine ward (93-beds). Variables related to patient (age, sex, Charlson comorbidity index, place of residency, functional and nutritional status, sphincter incontinence), and to admission episode (admission local, principal diagnosis and length of stay) were analyzed. Binary Logistic Regression was used to identify risk factors for catheter use and to develop the predictive risk model.

Results

In this cohort, 96 patients (24.6%; 95 CI: 20%-29%) had an indwelling catheter during the episode. The final predicted model included three variables: Total dependence (OR: 24.47) and major dependence (OR: 11.43) (Barthel Scale), Charlson comorbidity index (OR: 1.19) and length of stay (OR 1.08). The model has a good quality of fit (Hosmer and Lemshow goodness of fit test: $p=0.887$; AUROC: 82.5%), a specificity of 92.5% and a sensibility of 34.4%.

Conclusion

The high percentage of patients submitted to bladder catheterization found in this study, suggests the possibility of inappropriate use in

some patients. This finding, that deserves further study, underscores the need of judicious clinical reasoning about indications and benefits of this procedure for each patient individually. The model can be used as a complement tool for clinical decision. Given their characteristics, it permits to identify patients at risk and establish a closer surveillance and individual decision strategy.

#1589 - Abstract

GEOGRAPHIC LOCALIZATION OF INTERNAL MEDICINE PATIENTS IN A SINGAPOREAN ACADEMIC MEDICAL CENTER

Mei Ling Kang, Wan Cheng Chow, Kok Yong Fong

Singapore General Hospital, Singapore, Singapore

Background

Department of Internal Medicine (DIM) is Singapore General Hospital's biggest clinical unit with daily census of 280-400 patients. Care before 2016 was team-based, with patients admitted to beds in medical wards spread over 14 locations. Outliers to surgical wards were common when Bed Occupancy Rate exceeded 90%. Seventeen medical teams routinely cared for >25 patients in multiple wards in our 1600-bedded hospital; spending 20% of morning rounds traveling. Nurses were ward-based and communication between teams was challenging. Staff satisfaction was low and large geographic spread required high level of physician staffing. Tackling low efficiency and quality, we initiated a project to localize 60% of DIM patients to 6 wards; and Geographic Teams (GT) to manage them.

Methods

With senior leadership support and partnering Bed Management Unit (BMU), we analyzed the reasons for current bed assignment; and identified archaic algorithms, new services and bed demands and antagonistic admission patterns. Over 2 years, we systematically addressed these issues; and others like ward renovations, infection control demands, staff reluctance for changes and information technology limitations; through a series of stakeholder engagements and feasibility studies.

Results

By April 2018, with 2 wards ring-fenced to admit only DIM patients; we met our target of localizing 60% of patients to 6 wards. 40% of patients were still dispersed but to fewer wards. Proximity allow each GT to manage 26-30 patients; and DIM was able to reduce 17 medical teams to 16. Staff interaction and satisfaction improved; and GT wards became high-functioning units where multi-disciplinary huddles; discharge initiatives and other projects occur. Resident training was enhanced with closer supervision by consultants in the wards; and GTs were tasked to remediate weaker learners. Average Length of Stay (ALOS) was higher in GTs: 6.1-8.4 days (vs 5.0-6.8 in other teams); and on-going efforts at tweaking roster and communicating with BMU were required to maintain geographic model of care.

Conclusion

Although Geographic models of care have been reported in literature to be associated with higher ALOS; with variable clinical benefits; and considerable work is required to make it work, we find geographic localization of patients facilitates teamwork, communication and efficiency; and is a necessity for a large department for clinical, academic and operational reasons.

#1691 - Abstract

PROLONGED LENGTH OF STAY AND NOSOCOMIAL INFECTION IN AN INTERNAL MEDICINE DEPARTMENT

David Lopes Sousa, Ana Sofia Teixeira, Carlos Athayde, Armando Carvalho

Centro Hospitalar e Universitário de Coimbra, Coimbra, Portugal

Background

Delay in continuing care placement and other social security responses may lead to prolonged length of stay of patients in acute care wards. We aim to characterize this population in our hospital setting and the incidence of nosocomial infection after clinical discharge.

Methods

Retrospective analysis of all patients discharged from an Internal Medicine department from January to December 2016. Patients were included if ICD-9 code V632 was present in the discharge summary. Furthermore, all inpatient episodes lasting more than 15 days were individually reviewed and included if the electronic medical record showed only "waiting for placement" or similar as an active problem for three or more consecutive days, during which the patient did not require exclusive in-hospital care. Total length of stay, time to clinical discharge, mortality and incidence of nosocomial infection after clinical discharge were documented.

Results

Of 2323 episodes, 43 met the inclusion criteria. The patients were 51,2% male, with a mean age of 81,63 ±8,6 years. Median length of stay was 43 days, with median time to clinical discharge of 21 days. Incidence of nosocomial infection after clinical discharge was 37,2%, of which 81,3% were caused by multi-drug resistant microorganisms. 25,6% of patients had 2 or more different nosocomial infections. A mortality rate of 7,0% was observed, in all cases related to nosocomial infection.

Conclusion

Patients waiting for placement in an acute care setting have a high incidence of nosocomial infection that can lead to death. Faster placement in continuing care facilities may help curb this problem.

#1751 - Abstract

SETTING UP A NURSE-LED OPTICAL COHERENCE TOMOGRAPHY (OCT) CLINIC: ROLE AND STRUCTURE OF THE CLINIC

Boo Hui Tan

NHS Lothian, Edinburgh, United Kingdom

Background

Modern healthcare provision faces new challenges with an ageing population and emergence of treatments for previously untreatable diseases which causes an increase in demand of workforce. In the 2018 census by The Royal College of Ophthalmologist, it shows that there is a severe shortage of consultants with 67% of hospital eye units using locum doctors to fill consultant posts. Nurse led optical coherence tomography (OCT) clinic is a service to follow up patients after the initial diagnosis and management by consultants. This service frees up consultant clinic slots so that their expertise and skills can be reallocated. This study will explore the role, structure of a nurse-led OCT clinic and to analyse the clinical characteristics of patients attending this clinic which could be useful for setting up a similar clinic.

Methods

A retrospective study was conducted by choosing 45 patients at random and their discharge letters were analysed for their demographics, diagnosis, follow up duration and if they were reviewed by a consultant at any point. The structure of the OCT clinic was also documented.

Results

Data from 45 patients showed that 62.2% of the patients who attend the clinic have a diagnosis of Age-related macular degeneration (AMD). 13.3% of the patients have diabetic macular oedema and 13.3% of them were diagnosed with vein occlusions. Diagnoses like scar, haemorrhage and swelling account for 11% of patients referred to this clinic.

40% of the patients will get a follow up appointment in between 8 to 12 weeks. 26.7% will require follow up of 6 weeks or earlier and 26.7% will be seen in between 6 to 8 weeks. Only 4.4% of patients do not need further follow up. 66.7% of patients has been reviewed by a consultant at one point.

Structure of the nurse led clinic was also illustrated.

Conclusion

Nurse led OCT clinic is a very valuable service to Ophthalmology departments and has a role in improving patient care and increasing resources. Majority of patients in this clinic pathway require further follow up as only 4.4% of patients are discharged from the service. Running a well-trained nurse led OCT clinic will free up time and resources from Ophthalmology consultants who will be able to see patients who require their expertise and skills. Data also showed that 66.2% of the patients who attended the clinic have the diagnosis of AMD. This clinic is valuable in managing

this group of patients as the demand for AMD clinics increase due to recent developments in AMD treatments.

#2074 - Abstract

ASSESSMENT OF HEALTHCARE QUALITY INDICATORS IN 65 PLURIPATHOLOGICAL PATIENTS ATTENDED IN AN INTERNAL MEDICINE DEPARTMENT OF A SPANISH HOSPITAL.

Alberto Benavente Fernández, Antonio José Martín Pérez, María Del Rocío Fernández Díaz, Ana Isabel Parejo Morón, Sergio Fernández Ontiveros, Pedro Manuel García Ceberino

Internal Medicine Department. San Cecilio University Hospital, Granada, Spain

Background

A basic strategy towards providing the best clinical practise, based on high quality and safety patient centered care, is to analyze the achievement of quality indicators, as it can lead to strength well doing practices and identify areas of improvement. We aim to analyze the achievement of quality indicators, determined by the Andalusian Healthcare system over pluripathological patients, in order to enforce strengths and improve weaknesses.

Methods We analyzed the quality indicators established by the Andalusian Healthcare Service regarding pluripathological patients, which are:

1. Over 80% of the patients must have identified the categories which determines the pluripathological condition, as well as the complex criteria.
2. Functional capacity assessment (determined by Barthel scale and speed walking test in Barthel >60, must be performed in at least over 80% of the patients and the fall risk must be determined in over 80% of all the patients).
3. Cognitive impairment assessment (determined by Pfeiffer test must be performed over 80% of the patients).
4. Prognostic assessment (determined by the PROFUND scale must be performed over 80% of the patients).
5. Pharmacologic assessment (determined by STOPP-START criteria must be performed over 70% of the patients).
6. Previous decision planning must be performed over 70% of the patients.
7. Non-urgent scheduled intakes should be over 20% of all the intakes.

Results

Over the 65 patients studied, 57% were ♂ and 43% ♀, with an age range from 54 to 94 years (mean 80.34 years). All patients are identified with pluripathological determining categories and complex criteria. Barthel scale has been performed in all patients, nonetheless speed walking test, when indicated, has not been established in any patient. Fall risk has been registered in 44.6% of the patients. All patients underwent cognitive impairment,

prognostic and pharmacologic assessment using Pfeiffer test, PROFUND scale and STOPP-START criteria respectively. Previous decision planning was 100% accomplished. Non-urgent scheduled intakes were 1%.

Conclusion

Overall, the achievement of quality indicators, determined by the Andalusian Healthcare system over pluripathological patients, is high.

Our strengths are in identifying pluripathological determining categories and complex criteria, cognitive impair, prognostic, pharmacologic and previous decision planning assessment.

Our weaknesses, with a wide margin for improvement, are speed walking test, fall risk and scheduling intakes.

#2192 - Abstract

URICATH STUDY: CHARACTERIZATION OF THE USE OF URINARY CATHETERS IN THE INTERNAL MEDICINE SERVICES OF A EUROPEAN COUNTRY

Paulo Almeida¹, Sofia Duque², Ana Araújo¹, Andreia Vilas-Boas³, António Novais⁴, Heidi Gruner⁵, João Gorjão Clara⁶

¹ Centro Hospitalar do Baixo Vouga, Aveiro, Portugal

² Centro Hospitalar Lisboa Ocidental, Lisboa, Portugal

³ Hospital da Luz, Vila Nova De Gaia, Portugal

⁴ Centro Hospitalar Tondela-Viseu, Viseu, Portugal

⁵ Centro Hospitalar Lisboa Central, Lisboa, Portugal

⁶ Hospital CUF Descobertas, Lisboa, Portugal

Background

Approximately 12-16% of inpatients have a urinary catheter (UC) during their hospitalization. The UC's use is a risk factor of urinary tract infection (UTI) and a restraint that might cause pressure ulcers, functional deterioration and increased risk of institutionalization. This study aims to analyze the prevalence, indications and complications of the use of UC in inpatients in Internal Medicine (IM) Services.

Methods

A multicenter, cross-sectional observational study called UriCath was conducted in IM Departments of a European country on 04/17/2019. Inclusion criteria were the presence of a UC on study's day and the hospitalization in IM acute care wards. Data collection was performed through consultation of the clinical process. Statistical analysis was performed on SPSS 24.0.

Results

Of 3135 inpatients in 39 hospitals, 678 patients were included (mean age 80.2±7.5; 50.4% female). The prevalence of UC's presence was 21.6%. 23.7% were institutionalized and 91.7% came from the emergency department. The average value of the Eastern Cooperative Oncology Group Scale of Performance Status was 2.4±1.0 and for Barthel Index was 46.0±37.8. The most frequent

co-morbidities were: hypertension (68.0%), diabetes mellitus, heart failure (41.0%) and dementia (36.0%). The average value of Charlson comorbidity Index was 8±0.3. 36.2% had genitourinary system diseases (16.4% had benign prostatic hyperplasia). 55.2% were taking diuretics and 38.1% hypnotic drugs. The main causes of admission were bacterial pneumonia (18.0%) and heart failure (11.9%). In 77,3% of the patients the day of the placement of the UC was known and they had the UC for 13.1±28.3 days. The main reasons for UC's use were: monitoring of urinary output (47.3%), urinary retention (23.2%) and sacral/perineal pressure ulcers (10.6%). The reason for UC's use was unknown in 14.6% and written in the clinical file in 33.5%. The presence of UC was not recorded in 24.0%. The removal of the UC was attempted only in 8.8% (in 80.0% it was necessary to put it). In 75.7% there was no known complications of UC's use. The most frequent complication were: UTI (18.0%) and haematuria (3.1%).

Conclusion

The prevalence of UC's use is higher than that described in the literature. Development of clinical guidelines for the restricted use of UC only in patients with clear and identified indications and for timely removal is essential to reduce morbimortality and health costs associated with inadequate UC use.

#2196 - Abstract

INTEGRATED MANAGEMENT PROGRAM OF COMPLEX CHRONIC CARE: ONE-YEAR OUTCOMES

Sérgio Brito¹, Nuno Ferreira¹, Ana Leitão¹, Teresa Carvalho¹, Carlos Russo², Carla Magueja², Anabela Costa³, Célia Lourenço³, Rafic Nordin², Luís Campos¹

¹ Internal Medicine Department - Hospital de São Francisco Xavier, Centro Hospitalar Lisboa Ocidental, Lisboa, Portugal

² ACES Lisboa Ocidental e Oeiras, Lisboa, Portugal

³ ARS Lisboa e Vale do Tejo, Lisboa, Portugal

Background

Population ageing is one of the most significant demographic and social trends of the 21st century. It means that more people are living with multiple chronic conditions that lead a progressive dependence physical but also social and financial. Integrate care models between hospital and primary healthcare are good solutions to contraposed the actually fragmented and episodic care offered to these multimorbid elderly patients.

AIM: To present an integrate care model between hospital and primary healthcare and the impact of interventions carried out in the first year of the Integrated Management Program of Complex Chronic Care(Pro-GIC).

Methods

Prospective observational study of Pro-GIC patients followed between 2017-2018. Both teams (hospital and primary care) work together (internists, general practitioners and nurses) to obtain an

individual care plan according to the clinical statement and the will of the patient/caregiver. The necessary interventions (clinical, social and others) were carried by each partner and the case manager (hospital nurse) is responsible for monitoring the process through close contact with the patient and teams. The results of interventions were analyzed (before and after Pro-GIC): number of visits to the Emergency Room (ER), number of hospitalizations and also the degree of patient's satisfaction.

Results

Eighty-one patients were followed during one year (53% female; 67% aged between 75-100 years) with mean 6 (± 2.2) chronic diseases and 7.6 (± 4.21) prescribed drugs per patient, respectively. Other conditions: 48% with moderate degree of dependence; 28% at risk of malnutrition and 68% at social risk. One year mortality rate was 7% and institutionalization rate 9%. In remaining 68 patients the outcomes obtained before and after Pro-GIC intervention were: decreased number of visit ER (5.3 vs 2.8 visit/patient) in 85% of patients and 41% of reduction in hospitalizations (0.7 vs 0.4 admission/patient). The overall patient's satisfaction was 100% (response rate 69%).

Conclusion

The Pro-GIC, an integrated care model between hospital and primary care contributed to manage simultaneously both acute and chronic health problems with an approach centered in the person (not in the disease) and deals with health problems in their physical, psychological, social, cultural and existential dimensions. With these results we intend to extend this program but it's necessary that governments understand the urgent need to finance and promote the integration of healthcare.

#2252 - Abstract

SURVIVAL OF A COHORT OF PATIENTS WITH HEART FAILURE ACCORDING TO THEIR VENTRICULAR FUNCTION

Jose Lopez Castro

Hospital, Monforte De Lemos, Spain

Background

The prognostic variability of the patients with HF in Function of the Fraction of Ventricular Ejection (LVEF) continues being object of study, existing controversy in the long-term prognosis.

Objective: to know the survival of a cohort of patients with HF stratified according to FE%.

Methods

Prospective observational study of a cohort of 665 patients hospitalized for HF between January 1, 2003 and December 31, 2006, who underwent a formal echocardiography and their FE% was calculated.

Results

Results: 50% of patients > 80 years died after three years of follow-up.

After three years, 25% of the cohort has died. In the sixth year of follow-up, mortality reaches 60% of the sample.

Conclusion

Conclusions: In our series, patients with systolic dysfunction had a higher long-term mortality rate (45%), although those with preserved EF% ($\geq 50\%$) had significant mortality in relation to their comorbidity.



PALLIATIVE CARE

#223 - Abstract

CANNABIS USE IN ONCOLOGY: A BRIEF REVIEW

José Sousa Vale

ARSLVT, Lisbon, Portugal

Background

Experience with the use of a certain drug, knowledge of its side effects, and its mode and dose of administration are usually key aspects in prescribing practice by doctors. Currently, with regard to cannabis and its use in clinical practice, one of the limiting factors may be medical knowledge.

Methods

Three electronic databases (PubMed, Cochrane, and Google Scholar) were searched from their inception to December 2018. The search strategy adopted the keywords “Cannabis” AND “Medical Marijuana” AND “Medical Cannabis”; “Cannabis” AND “Oncology”; “Cannabis” AND “Chemotherapy-induced Nausea and Vomiting”.

Results

The search hit 300 records. After applying the inclusion criteria 39 articles selected for the synthesis of this paper. This article seeks to dispel myths about medical cannabis and aims to explore the pharmacology, current indications for the use of cannabis in the oncology area, more specifically in the nausea and vomiting induced by chemotherapy and in appetite, and to review the theoretical aspects in the literature of its antineoplastic effect. Finally, it also addresses some practical and clinical aspects in its use.

Conclusion

The exact place of cannabis in medical practice is still much debated, but the body of evidence grows, and legislation is changing to reflect its increasing use. Public and medical opinion have also changed significantly in relation to its usefulness under various clinic conditions. Further trials are necessary to assess the safety and efficacy of medical cannabis. Policies should provide guidance regarding the application of current evidence on medical cannabis to clinical practice.

#249 - Abstract

GLYCEMIC CONTROL IN PATIENTS ADMITTED TO A PALLIATIVE CARE UNIT AND ASSOCIATED TREATMENT: A GLOBAL APPROACH

Juan Mora Delgado¹, Marina Báez Rivas², Ana Roldán Mena², María Luisa Calvo Castillo², Silvia Patricia Silva Romeiro², Víctor Rivas Jiménez³

¹ Internal Medicine, General Hospital of Jerez de la Frontera., Jerez De La Frontera, Spain

² Medical Oncology, General Hospital of Jerez de la Frontera, Jerez De La Frontera, Spain

³ Palliative Care Unit, General Hospital of Jerez de la Frontera, Jerez De La Frontera, Spain

Background

Controlling diabetes is a challenge, especially in palliative and at ‘end of life’ situations. In general, the main focus is safety, comfort and quality of life, rather than strict control of blood glucose. Health professionals sometimes find it hard to decide on a management plan and when to withdraw treatment in rapidly changing circumstances.

Methods

We present a retrospective descriptive study in which the digital clinical records of all patients admitted to the Palliative Care Unit from June 2018 to January 2019 are analyzed. All patients with type 2 diabetes were selected.

Results

Out of a total of 170 admissions, a total of 57 patients (29 men and 28 women) were recruited, of whom 3 were readmitted in the period analyzed, with an age mean of 76 years, its outcome being the exitus in 39 patients, 16 hospital discharges and 2 transfers. The location of the primary neoplasm was most frequently lung (10 patients), pancreas (10), colon (6) and liver (5).

16 of them had glycosylated hemoglobin in the last year (all requested by their primary care physician) with an average of 7.8%.

The majority of patients had a baseline bolus regimen and correction according to regimen (23), or correction only (19). 3 patients presented a basal bolus plus scheme. In 8 patients no pattern is reflected, only control of preprandial glycemias, and

in 4 it does not appear. The correction was made in 25 patients with rapid insulin and in 20 with regular insulin. In 12 it does not appear. In no case was it done with ultrafast insulin. The average of capillary glycemia before breakfast was 180 mg/dL, at lunch of 207 mg/dL, and at dinner of 224 mg/dL. 44 of the patients had corticosteroid regimen, 41 of them with dexamethasone, the most frequent dose being 4 mg per day (20 patients). When 'last days' situation reached, glycaemic controls were only maintained in 4 patients.

At home, 22 of the patients used basal glargine insulin, of which 10 had basal bolus therapy regimen, 5 with basal plus regimen, and 7 in association with oral antidiabetics. In total 38 patients used oral antidiabetic

Conclusion

The glycemia figures of this group of patients during admission are in an acceptable range, taking into account that it is intended to avoid glucose levels below 90 mg/dL as well as higher than 300 mg/dL, being in these extremes when symptoms related to hypo/hyperglycemia. The use of corticosteroids is high. It would be interesting to propose broader studies in this not much explored field in Palliative Care.

#406 - Abstract

IMPLEMENTING A DIGITAL SOLUTION TO IMPROVE TRANSITIONS BETWEEN HOSPITAL AND THE COMMUNITY IN END OF LIFE CARE: WHAT WE'VE TRIED AND WHAT WE'VE LEARNT

Mark Lander¹, Rosie Shadat¹, Theresa Mann², Josephine Arumugam¹, Joanne Bennetts², Kevin Tomkinson¹

¹ University College London Hospitals NHS Foundation Trust, London, United Kingdom

² Central and North West London NHS Foundation Trust, London, United Kingdom

Background

Electronic Palliative Care Coordination Systems (EPaCCS) record and share of people's key care details and preferences to allow delivery of the right care, in the right place, by the right person, at the right time. Within this London teaching hospital, 30-day readmissions in the last year of life are high and confidence collaborating with community services low. We are embedding the London-wide EPaCCS to facilitate collaboration with community providers.

Methods

A multiple-stepped approach was used:

- Working group formation.
- In-depth project development proposal.
- Hospital enrolment as EPaCCS user.
- Development of clinical user training guide, safety case report and benefits realisation log.

- Intensive staff education supported by advance care planning training.
- Information Technological (IT) support to develop hospital electronic record 'flag' highlighting existing EPaCCS records.

Results

Opportunities:

- Staff understand benefits of creating and using EPaCCS.
- Integrating EPaCCS with hospital records has potential to reduce readmissions at the end of life.

Challenges:

- Clear project ownership is needed to drive progression.
- Hospital administrative processes impede implementation.
- Staff turnover, clinical pressure and limited IT intra-operability compromises engagement with EPaCCS and quality of record keeping.

Conclusion

EPaCCS improve care in the last year of life. Key steps to embed these include:

- Cohesive interoperability and data sharing between hospital systems and EPaCCS.
- Clear flagging systems to alert the presence of records.
- Cultural shift, staff training and support to system-wide engagement with EPaCCS and prioritise high quality end of life care.

#445 - Abstract

ANTIPLATELET THERAPY AT THE END OF LIFE. DIFFERENCES IN THE MANAGEMENT BETWEEN FIRST AND THIRD LEVEL HOSPITAL. MULTICENTRIC STUDY

Lidia Gagliardi Alarcón¹, Victoria Garay Airaghi², Amaya Capón Sáez², María Herrera Abian¹

¹ Hospital Universitario Infanta Elena, Madrid, Spain

² Hospital Clínico San Carlos, Madrid, Spain

Background

Comparing the clinical characteristics of antiplatelet therapy in patients who die in the Acute Geriatric Unit Care (AGUC) and Palliative Care Unit (PCU) from two different hospitals. Describing the outpatient antiplatelet treatment and its management during the last admission in Emergency Department, 48 hours and 24 hours prior to the exitus letalis.

Methods

Descriptive, retrospective and multicenter study. We recruit patients who died intrahospitally (AGUC and PCU) from October 2018 to January 2019 in two hospitals (first-level (1LH) and third-level hospital (3LH)) from different health care areas of the Community of Madrid (Spain). Variables analyzed: history of cardiovascular pathology, cerebrovascular accident or peripheral vascular disease and ambulatory antiplatelet treatment,

antiplatelet prescription in the Emergency Department and End-of-life prescription (48-hours & 24-hours previous death). Statistical analysis: Chi square. Statistical package: IBM SPSS Statistics 23.

Results

222 patients were included (median age 83, SD 11; 57.2% women): 121 from 3LH and 101 from 1LH. History of cardiovascular disease: 24% at 3LH and 80.2% at 1LH ($p = 0.000$). Vasculopathy 29.8% at 3LH versus 15.8% at 1LH ($p = 0.015$). Cerebrovascular accident 9.9% at 3LH and 25.7% at 1LH ($p = 0.002$). Usual antiplatelet regimen: 23.1% at 3LH versus 29.7% at 1LH ($p = 0.268$). Acetylsalicylic acid 100mg was the most used antiplatelet drug in both samples (64.3% at 3LH and 86.7% at 1LH).

Emergency Department prescription: antiplatelet therapy was maintained in 53.57% of the cases at 3LH and in 50% at 1LH ($p = 0.594$).

48 and 24 hours-previous death prescription: at 1LH, antiplatelet active treatment 48h previous death was presented at 26.6% and 6.6% in 24hours previous death. At 3LH, 13.3% (48h) and 10.7% (24h) remained under antiplatelet therapy.

Conclusion

- First-level hospital patients have a greater component of cardiovascular disease, nevertheless, both samples have a similar percentage of outpatient antiplatelet therapy.
- In the last Emergency Department prescription, antiplatelet drugs are maintained in half of the sample in both hospitals.
- At the first-level hospital there is a higher tendency to maintain the antiplatelet therapy in the last 48 hours of life, although the percentage of patients with antiplatelet prescription at 24h prior to the exitus is most marked at the third-level hospital.

#448 - Abstract

ANTIBIOTICS AT THE END OF THE LIFE: LAST ANTIMICROBIAL PRESCRIPTION IN EMERGENCY DEPARTMENT AND MANAGEMENT IN TWO DIFFERENT HEALTH AREAS

Lidia Gagliardi Alarcón¹, Victoria Garay Airaghi², Amaya Capón Sáez², María Herrera Abian¹

¹ Hospital Universitario Infanta Elena, Madrid, Spain

² Hospital Clínico San Carlos, Madrid, Spain

Background

Contrasting the demographic and clinical characteristics of patients with intrahospital mortality in different levels of care in the Palliative Care Unit (PCU) and Acute Geriatrics Unit Care (AGUC) in a multicenter approach. Studying the differences in antibiotic prescriptions from the last Emergency Department Episode and admission.

Methods

Descriptive, retrospective and multicenter study of patients who died from October 2018 to January 2019 in two hospitals (first and third level: 1LH and 3LH, respectively) of different health areas of the Community of Madrid (Spain). Variables analyzed: demographic (age, gender, social status, previous hospital contact, etc.), comorbidity (Considering "high comorbidity" a Charlson Index > 5), functional status (Barthel Index < 60: poor functionality) and antibiotic therapy prescription in the Emergency Department (pharmacological class, in monotherapy or in combination). Statistical analysis: Chi square; Statistical package: IBM SPSS Statistics 23.

Results

222 patients were included: 121 from third-level hospital (3LH) and 101 first-level (1LH). Mean age: 83 years old (SD 12), in both samples. Gender: 59.5% women at 3LH and 54.5% at 1LH ($p=0.449$). Patients with high comorbidity: 8.3% at 3LH and 18.8% at 1LH ($p=0.020$). Patients with functional dependence: 52.7% at 3LH, 78.2% at 1LH ($p=0.000$). Institutionalization: 13.3% at 3LH; 50.6% at 1LH ($p=0.000$). Hospitalization in the previous 6 months: 49.6% at 3LH; 66.3% at 1LH ($p=0.012$). Antibiotics were prescribed in their last emergency episode in 61.2% of 3LH patients and in 73.3% of 1LH ones ($p=0.057$). The groups of antibiotics prescribed most frequently at 3LH were: β -lactam with beta-lactamase inhibitor (33.5%), third-generation cephalosporins (28.6%) and carbapenems (23.2%). In the case of 1LH management were: beta-lactam with beta-lactamase inhibitor (39.4%), carbapenems (27.2%) and third-generation cephalosporins (19%). Antibiotics were used in combination in 18.9% of the cases of 3LH versus 29.7% of 1LH ($p=0.125$).

Conclusion

- More than two thirds of patients who died hospitalized received antibiotic therapy during the Emergency Department admission, especially at the first-level hospital.
- The antibiotic group most frequently prescribed in our study was a beta-lactam with an inhibitor of beta-lactamases.
- Carbapenems are widely used in both centers, being more often prescribed at the first-level hospital, which has greater institutionalization and comorbidity in their patients

#450 - Abstract

ANTIBIOTHERAPY AT THE END OF LIFE: IS THE DEPRESCRIPTION DEFINING THE LIMITATION OF THE THERAPEUTIC EFFORT? MULTICENTRIC STUDY

Lidia Gagliardi Alarcón¹, Amaya Capón Sáez², Victoria Garay Airaghi², María Herrera Abian¹

¹ Hospital Universitario Infanta Elena, Madrid, Spain

² Hospital Clínico San Carlos, Madrid, Spain

Background

Distinguishing the timing and evolution of the antibiotic regimen during the last admission of patients who died hospitalized in two

different centers in two different departments: the Palliative Care Unit and Acute Geriatrics Unit Care.

Methods

Descriptive, retrospective and multicenter study. From October 2018 to January 2019. Two hospitals of the Community of Madrid (Spain): a third-level hospital (3LH) and a first-level hospital (1LH). Variables analyzed: antibiotic therapy received in the Emergency Department (ED), at 48 and 24 hours prior to death; use of antibiotics together or not with continuous deep sedation. Statistical analysis: Chi square; Statistical package: IBM SPSS Statistics 23.

Results

222 patients: 121 (3LH) and 101(1LH). Mean age 83(SD 12), in both samples. Gender: 59.5% women (3LH) and 54.5% (1LH) ($p=0.449$). Presence of antibiotic therapy in the ED: 61.2% at 3LH vs.73.3% at 1LH ($p=0.057$). In combination with terminal sedation intravenous perfusion 0% 3LH vs.2.7% 1LH. Antibiotics most used in ED: At 3LH, ceftriaxone (24.5%), amoxicillin and clavulanic acid (20.3%) and meropenem (15%). At 1LH: amoxicillin and clavulanic acid (33.8%), levofloxacin (17.7%) and ertapenem (16.3%).

Use of antibiotic therapy in the last 48 hours of life: 35.2% 3LH vs 55.4% 1LH ($p=0.006$). In combination with terminal sedation perfusion: 2.7% 3LH vs.28.3% 1LH ($p=0.002$). Antibiotic regimen most used: At 3LH, piperacillin and tazobactam(21.6%), meropenem (18.9%) and tigecycline (18.9%). At 1LH, amoxicillin and clavulanic acid (24%), levofloxacin (24%) and ceftriaxone (15.6%). Use of antibiotic therapy in combination: 40.5% in 3LH vs. 26.1% in 1LH ($p=0.162$).

Use of antibiotic therapy 24 hours before death: 22.4% 3LH vs.40% 1LH ($p=0.006$). In combination with terminal sedation perfusion: 3.8% at 3LH vs.44.7% at 1LH ($p=0.000$). Antibioterapy most used in the end of life at 3LH: meropenem (23%), levofloxacin (22.9%) and amoxicillin and clavulanic acid (15.4%); at 1LH, amoxicillin and clavulanic acid (26.2%), ceftriaxone(18.4%) and piperacillin and tazobactam (15.8%).

Conclusion

At the first-level hospital, antibiotic therapy tends to be maintained in the last 24 and 48 hours before the exitus letalis more frequently, even with the terminal sedation perfusion. Tertiary hospital has a remarkable tendency to withdraw antibiotics in a terminal situation, although they have broader spectrum. Beta-lactams with beta-lactamase inhibitors are the most widely used antibiotics throughout the last admission in both centers.

#679 - Abstract

DEATH DOULAS MEDIA SCOPING: MEDIA REVIEW

Ana Pedroso¹, Deborah Rawlings², Jennifer Tieman²

¹ Internal Medicine Department, Hospital São Francisco Xavier (CHLO), Lisboa, Portugal

² Palliative & Supportive Services, College of Nursing and Health Sciences, Flinders University, Adelaide, Australia

Background

If health care systems are not meeting the needs of their population, people will find others to provide care, advocate, and fill in the gaps in care. The term, “doula” is a Greek word meaning a woman caregiver. Better known in their work in birthing, death doulas are a newly emerging phenomenon with little formal literature investigating this role.

This study looked at media reports on death doula to explore their role, care practices and characteristics as well as the meaning of their appearance for end-of-life care systems.

Methods

We engaged a media company at the end of 2017 to provide a report of media items retrieved by searching for “death doula” or “death midwives”. The search was conducted within their database of print, TV & radio summaries and online news archive. The initial search identified 127 articles with 93 items being included following removal of repeated and non-related articles.

Results

The media items included news reports, interviews, videos and reports of doula training. The following roles were described:

- providing psychological support, information and resources,
- being present around the time of death,
- understanding and the person’s needs and desires,
- connecting people,
- giving meaning to the end of life,
- supporting and empowering dying people and their families, and
- helping families to cope with grief.

The media reports also suggest that the role has arisen in response to a need for empowerment during the dying process, giving alternatives to the modern clinical approach and shifting the emphasis towards awareness and choice.

Conclusion

This new role seems to reflect a desire for different approaches and ways of caring at the end-of-life. Such new roles remind us as health professionals that our practice needs to reflect the patients’ needs and desires. Can the appearance of this new role in end-of-life care help health systems learn what dying peoples and their families want?

#741 - Abstract

COMPLEXITY, NOT MULTIMORBIDITY, IS KEY IN ALLOCATING CARE TO A SPECIALIZED RESPONSE TEAMRui Carneiro^{1,2}, Catarina Simões^{1,3}, António Carneiro⁴¹ Equipa Acompanhamento, Suporte e Palição, Hospital da Luz - Arrábida, Vila Nova De Gaia, Portugal² Departamento de Medicina, UCI e Urgência, Hospital da Luz - Arrábida, Vila Nova de Gaia, Portugal³ Escola Superior de Saúde de Santa Maria, Oporto, Portugal⁴ Departamento de Medicina, UCI e Urgência, Hospital da Luz - Arrábida, Vila Nova De Gaia, Portugal**Background**

Complexity is the by-product of a pluripathological situation with the psycho-social vulnerability and health resource utilization pattern. Multimorbidity means the presence of two or more diseases. These terms are often (and wrongly) used interchangeably.

We seek to evaluate the presence of multimorbidity and the presence of high complex palliative care needs in Internal Medicine Department (IMD, ward and ICU).

Methods

Analytical cross sectional study conducted in the IMD of a private Portuguese hospital. Sample: 400 patients; average age 76 (35-101). A data collection tool was used: Charlson Comorbidity Index (CCI) and Diagnostic Instrument of Complexity in Palliative Care (IDC-Pal).

Results

Almost half the patients admitted had CCI above 4 (meaning high comorbidity and a 21% 10-year chance of survival) and nearly 40% had complex/high complex palliative care needs, according to IDC-Pal. The numbers were seen both in the ICU as in the ward. 20% of patients with low CCI were, in fact, complex/highly complex, whereas three quarters of people with high CCI were non-complex situations.

Conclusion

When selecting patients to specialized intervention, multimorbidity should not be a sole trigger. Multimorbidity and complexity are two distinct clinical entities.

#744 - Abstract

GOOD RESOURCE ALLOCATION AS AN INDICATOR OF SUCCESSFUL PALLIATIVE CARE TEAM INTEGRATION IN A INTERNAL MEDICINE DEPARTMENTRui Pimenta Carneiro^{1,2}, Catarina Simões^{1,3}, António Carneiro⁴¹ Equipa de Acompanhamento, Suporte e Palição, Hospital da Luz - Arrábida, Vila Nova De Gaia, Portugal² Departamento de Medicina, UCI e Urgência, Hospital da Luz - Arrábida, Vila Nova de Gaia, Portugal³ Escola Superior de Saúde de Santa Maria, Oporto, Portugal⁴ Departamento de Medicina, UCI e Urgência, Hospital da Luz - Arrábida, Vila Nova De Gaia, Portugal**Background**

Our 100-bed hospital has a Palliative Care Team (PCT) embedded in the Internal Medicine Department (IMD – covering emergency, ICU and ward). An IMD doctor with PC competence works alongside with a specialized nurse, with the support from a psychologist and nutrition professional, seeing primarily patients from the IMD but also consults other specialities and have an outpatient clinic.

We seek to calculate the penetration rate of PCT among complex and/ or poor prognosis patients admitted to IMD.

Methods

Analytical cross sectional study conducted in the IMD of a private Portuguese hospital. Sample: 400 patients; average age 76 (35-101). A data collection tool was used: Goldstandards Framework (GSF), Prognostic Indicator Guidance (2nd edition) and Diagnostic Instrument of Complexity in Palliative Care (IDC-Pal).

Results

About 15% of all IMD patients were comanaged with PCT. Nearly one third of limited prognosis patients and two thirds of complex/highly complex patients were followed by the PCT. All patients receiving input from the PCT were in end-of-life scenario and almost 90% had complex/ high complex palliative needs.

Conclusion

The penetration rate of the PCT was 71% for complex or high complex patients. Amongst the end of life patients, the PCT penetration rate was of 35%. These numbers are higher than those seen in literature, demonstration the good level of integration of a PCT in the IMD.

#758 - Abstract

PSYCHOLOGICAL AND SOCIAL NEEDS OF PATIENTS ADMITTED TO A PALLIATIVE CARE UNIT

Resfa García Font, Joaquina Rodríguez Sanchez, Ascensión González García, Tomás Camacho Pizarro, Miguel Ángel Sánchez Marmolejo, Ramírez Ortiz Esther
Hospital Vázquez Díaz, Huelva, Spain

Background

The situation of extreme vulnerability, as well as the lack of autonomy of palliative patients oncology and the high consumption of health and social resources are the reason for this study. Comprehensive psychological and social support for bereaved family members also is expected.

Methods

Describe the number of patients and characteristics of the social intervention performed in oncological patients hospitalized in the Internal Medicine Service (Palliative Care Unit) in 2018. Retrospective descriptive study of the clinical histories of the patients who entered our Palliative Care Unit from January 1, 2018 to December 31, 2018

Results

The total number of patients admitted in this period was 389, 62.5% were men.

Place of origin: 169 patients from hospitalization facilities acute hospital (most frequent Oncology or Internal Medicine), from home 113 patients (6.2%), 88 patients from Emergency (21.4%) and from Outpatient 24 patients (6.2%).

The most frequent tumors were: lung neoplasia (22.3%); Colorectal neoplasia 19.3%; breast neoplasia 6.5%; pancreas neoplasm; 4.4%. liver neoplasia and bile way 3.3%; prostate neoplasia 3.3% and kidney 3.1%.

92% of the patients received some type of assistance from the social worker. Incapacity pensions were processed (10%). The most used resources were residential centers (40%) and Cáritas reception centers (25%). The highest percentage of social intervention was carried out in persons belonging to ethnic minority communities and the elderly. 25 families were assisted in the duel. Four patients were transferred to their country of origin (Morocco, Senegal, Tunisia and Romania).

Conclusion

It is crucial the detection and the multidisciplinary approach in the psychosocial field of oncological patients admitted to a palliative care unit, since it is a situation of extreme personal and social vulnerability.

Future research should focus on determining the adequacy of provision of palliative care for minority ethnic communities, older people living in nursing and residential homes

#979 - Case Report

INTEGRATED APPROACH IN PALLIATIVE CARE - A CLINICAL CASE

Mariana Conde, Joana Rua, André Maia, Catarina Parra, Anabela Morais

Centro Hospitalar de Trás-os-Montes e Alto Douro, Vila Real, Portugal

Introduction

The World Health organization defines palliative care as “an approach that improves the quality of life of patients and their families facing the problem associated with life-threatening illness.” In clinical practice, the need for a perspective including a holistic and integrated view of the patient, his family and his disease has become a clear necessity. Only a multidisciplinary team can guarantee the best possible care.

Case description

A 37-year-old female, math teacher, lived in a rural area with her husband and children. No relevant past medical history.

In March 2017 she was diagnosed with cerebral glioblastoma. She underwent two craniotomies and initiated the STUPP protocol until September that year, when expansion of the lesion and left hemiparesis were identified. The patient was then admitted for a third intervention, with poor evolution (development of fatigue and hydrocephalus), prompting transfer to a Palliative Care unit.

On admission, she presented with dysphagia, oral candidiasis, arthralgia, severe headache, depressive humor, left hemiparesis, periods of agitation alternated with stupor and persistent infection of the surgical wound.

From the beginning the priority was to define an intervention plan for the patient and her family, through clarification of goals and of the clinical situation, management of expectations and hopes and presenting the best treatment options available.

The team began a systematic intervention of all symptoms and clinical problems the patient presented with. Programmed psychosocial accompaniment to the patient, family and caregivers was an important part of the plan. Social and spiritual intervention were also guaranteed. In all these levels, emotional support, empathic communication and active listening were a priority.

Approximately 1 month after admission there was an extraordinary improvement, with partial recovery of left hemiparesis and complete resolution of the infection. The patient was cognitively well and motivated. On re-evaluation by Oncology she was able to resume chemotherapy with palliative intent.

After 13 months of follow-up in ambulatory she maintains partial functionality, controlled symptoms and remains at home, with her family.

Discussion

This case demonstrates the importance of intervention by palliative care, with an integrated multidisciplinary approach, in this example with a significant recovery of performance status and allowing patient maintenance under ambulatory palliative therapy.

#1023 - Case Report

SEVERE FATIGUE, JAUNDICE AND EXTENSIVE MALIGNANT LIVER INFILTRATION - MEETING THE CHALLENGES OF THERAPY RELATED TOXICITIES AT THE END OF LIFEFilipa Tavares^{1,2}¹ Unidade de Medicina Paliativa, Centro Hospitalar Universitário Lisboa Norte, EPE, Lisboa, Portugal² Núcleo de Cuidados Paliativos, Centro de Bioética - Faculdade de Medicina de Lisboa, Lisboa, Portugal**Introduction**

Malignant infiltration is a recognised cause of acute liver failure. The differential includes a range of conditions, that must be evaluated to enable specific therapy, when available, to be instituted.

Case description*Case 1*

A 70-year-old man with a BCLC stage C hepatocellular carcinoma was referred to Palliative Care (PC). Concerns about end of life aroused after subacute functional decline (to 3-4 on ECOG PS scale), severe fatigue, right upper quadrant abdominal pain, jaundice, ascites, and a continuous rise in liver chemistries after 2 cycles of nivolumab. Grade 1 encephalopathy has found. Bisoprolol replaced a recent amiodarone prescription (new onset atrial fibrillation). He died 3 days after. Blood tests were positive for cytomegalovirus (CMV) IgM antibody.

Case 2

A 54-year-old woman, with hypertension, type 2 diabetes mellitus, and a recently diagnosed advanced mixed hepatocellular cholangiocarcinoma with total bilirubin levels persistently over 28mg/dl was referred to PC. Parenteral hydration and insulin corrected high glucose and ketonemia levels and improved fatigue and anorexia. On a second opinion basis sorafenib 200mg bid was started. By day 7 she was admitted acutely delirious, lethargic, and minimally responsive. Her transaminases rose (2x ALT and 5x AST). A notable ST elevation in the inferior and lateral leads and high sensitive-troponin t of 1292ng/l deserved a conservative approach. She died 72 hours later.

Discussion

Immune-related hepatitis and CMV infection/reactivation (lately detected in case 1) are well known serious side effects of anti-PD-1 drugs (as nivolumab), commonly presented with nonspecific symptoms such as fatigue.

In case 2, sorafenib (a tyrosine kinase inhibitor) may have contributed, in a poorly controlled diabetic, to the occurrence of myocardial infarction (MI). Early cardiotoxicity, symptoms of ischemia, overt infarction and increasing mortality after MI have been associated with this class of cancer therapeutics.

Although palliative care is a crucial part of managing distress symptoms, close collaboration between specialists is needed to make sure that the correct underlying pathophysiology of a falling malignant liver is addressed.

#1102 - Abstract

THE OPIOID USE IN INTERNAL MEDICINE - SEVEN YEARS LATER

Helena Manso¹, Diogo Drumond Borges¹, Rita Vieira Alves¹, Marília Fernandes¹, André Teixeira¹, Inês Rego Figueiredo¹, Ana Llado¹, Filipa Lourenço¹, Ana Paula Costa², Catarina Santos², Heidi Gruner¹, António Panarra¹

¹ Serviço Medicina 7.2 - Centro Hospitalar Universitário Lisboa Central, Lisbon, Portugal² Serviços Farmacêuticos - Centro Hospitalar Universitário Lisboa Central, Lisbon, Portugal**Background**

The use of opioid analogues (OA) in Internal Medicine has been increased in the last years mostly in the context of palliative care. However, few studies have addressed its use in hospitalized patients in internal medicine wards. The objective was to compare the use of OA in two different years (2011 vs. 2018).

Methods

We conducted a retrospective study of all the electronic clinical records of patients using OA (namely morphine, buprenorphine or fentanyl) in an Internal Medicine Unit of a tertiary hospital in 2011 and 2018 (January 1st to December 31st). Patients were compared regarding demographics, cause for hospital admission, OA prescribed, comorbidities, length of stay and inpatient mortality rates.

Results

OA were used by 133 out of 1536 patients (8.7%) in 2011, compared to 128 out of 1338 patients (9.6%) in 2018, with a mean age of 78.8 vs. 76.9 years respectively. Male patients were 62.4% (N=83) vs. 54.7% (N=70). Concerning comorbidities: 33.8% (N=45) vs. 34.4% (N=34) patients had a Neoplastic Disease. The average length of stay was 12.5 vs. 22.4 days, and inpatient-mortality rate of 57.4% vs. 55.5%. The use of oral OA increased from 2011 to 2018 (morphine - 12 vs. 35 patients respectively), and are now preferred to transdermal systems (buprenorphine - 13 vs. 12 patients, fentanyl - 11 vs. 18 patients).

Conclusion

There was no major difference regarding the number of OA users, age, inpatient mortality rates or comorbidities, within 7 years. Nevertheless, patients stayed longer at the hospital and there is a notable increase in the use of morphine. This illustrates the growing importance of symptomatic comfort measures in which OA may be cost-effective in patients carefully selected and monitored.

#1103 - Abstract

CHRONIC OPIOID USE (OR ABUSE?) IN HOSPITALIZED PATIENTS

Helena Manso¹, Diogo Drumond Borges¹, Rita Vieira Alves¹, Marília Fernandes¹, André Teixeira¹, Inês Rego Figueiredo¹, Ana Paula Costa², Catarina Santos², Heidi Gruner¹, António Panarra¹

¹ Serviço Medicina ² - Centro Hospitalar Universitário Lisboa Central, Lisbon, Portugal

² Serviços Farmacêuticos - Centro Hospitalar Universitário Lisboa Central, Lisbon, Portugal

Background

The widespread use of opioid analogues (OA) for acute or chronic pain management has contributed in part to the “opioid epidemic” in some countries. However, OA can safely be prescribed and contribute to overall improvement in quality of life. The objective of this study was to compare chronic and “naive” OA users admitted to an internal medicine ward in Portugal.

Methods

Inclusion of all patients admitted to an internal medicine department of a tertiary hospital in Portugal during 2018 (January 1st to December 31st) with OA use (morphine, buprenorphine or fentanyl) according to the electronic clinical records. Patients were divided in two groups - namely “chronic” users taking OA prior to admission, or “naive” users” if OA was started during hospitalization - and were compared concerning demographics, length of stay, in-hospital and 90-days mortality, and OA prescribed and dosage.

Results

Out of 1338 patients, only 18 (1.3%) were chronic OA users, while 110 patients (8.2%) were OA “naive”. Chronic users were slightly younger (72.1 vs 77.7 years), female (55.6% vs 43.6%) and most of them had a neoplastic disease (61.1% vs 30%), but there was no significant difference in terms of length of stay in hospital (22.8 vs 22.2 days). In-hospital mortality was significantly smaller in chronic users (22.2% vs 60.9%), but this difference diminishes at 90-days (50.0% vs 72.7%). Nevertheless, length of stay and in-hospital mortality of OA users largely exceeds the mean rate of the internal medicine department, which were 10.8 days and 9.6% respectively for this period. Concerning the OA prescribed, the preferred for “naive” users was morphine (83.6% vs 33.3%), or morphine plus a transdermal system namely buprenorphine or fentanyl (9.1% vs. 16.7%), with each of these transdermal systems being used in less than 5%. On the contrary, 27.8% of chronic users used buprenorphine and 22.2% used fentanyl.

Conclusion

Our study suggests that opioids are prescribed frequently for the first time in internal medicine wards, either due to a cancer or a non-cancer-related diagnosis (usually heart failure and acute or chronic pulmonary disease, and some due to osteomuscular pain) but mostly associated with a terminal disease. Furthermore,

the use of OA is associated with increased length of stay and in-hospital mortality and at 90 days, independently of whether the patient is a chronic or a “naive” user.

#1270 - Abstract

VALIDATION OF PALLIATIVE PROGNOSTIC INDEX (PPI) IN A SINGAPORE HOSPICE SETTING

Kayleigh Huimin Ho¹, Daniel Song Chiek Quah²

¹ Singapore General Hospital, Singapore, Singapore

² Singhealth, Singapore, Singapore

Background

The accurate ascertainment of a patient’s prognosis after the diagnosis of an irreversible progressive illness allows for informed decision making, meaningful communication, closure and legacy work which has been shown to help with families’ and caregivers’ ability to cope with bereavement. One of the tools that have been developed to improve prediction of survival in palliative care patients is the palliative prognostic index developed by Morita et al in 1999 which was found to be useful in estimating survivals of <3 weeks and >6 weeks.

Access to palliative care services in Singapore is largely prognostication based. This study aims to validate the PPI model in a Singapore hospice setting for predicting 3 and 6 weeks survival by evaluating if the PPI cut off of 6 and 4 respectively can be used to prognosticate patients. Secondary objectives were to evaluate the association between PPI and survival and to assess agreement between doctor’s clinical prediction and patient’s actual survival duration

Methods

A retrospective case notes review of all patients referred to a 37 bedded inpatient hospice in Singapore between 1 June 2015 and 31 December 2016. Patients were referred to the hospice based on a prediction of survival of < 3 months. Patients with incomplete PPI and death data were excluded. All patient demographic information and components of the PPI were collected. Death data were collected either from the electronic records of Assisi inpatient Hospice. All study procedures and materials were approved by Singhealth Centralized IRB.

Results

PPI>6 showed significantly shorter survival than those ≤6 (Median survival 9 vs 32 days, P<0.001). Sensitivity and specificity of 3 weeks survival was predicted to be 78.5% and 69.9% respectively, with PPV 63.4%.

PPI>4 has significantly shorter survival than those PPI≤4 (Median survival 11 vs 46 days, P<0.001). Sensitivity and specificity of 6 week survival was 82.9% and 80.7% respectively, PPV 79.6%.

When patients were stratified into 3 groups based on PPI on admission <2, 2-4, >4. There was a significant difference between the survival in these three group (P<0.001). The median survival

was 83 days for patient in Group A, 40 days for patients in Group B and 11 days for patients in Group C.

Conclusion

Our study validates the PPI in the inpatient hospice setting in Singapore and may be able to help identify patients with poor prognosis that can be referred to community hospice services to allow optimal use of healthcare resources.

#1598 - Case Report

INTESTINAL PERFORATION - A CONSERVATIVE TREATMENT CASE IN PALLIATIVE CARE

Inês Egídio Sousa, Marta Ilharco, Susana Escária, Ana Campos, Bianca Vaz, Maria Hatton, Inês Romero, Rita Abril, Isabel Galriça Neto

Hospital da Luz, Lisboa, Portugal

Introduction

Small bowel obstruction with perforation is an uncommon complication in neoplastic disease, with high morbidity and mortality, being surgery the mainstay of treatment. A case is reported in which conservative approach was chosen in a palliative context, with resolution of the condition.

Case description

72-year-old male with stage IV prostate adenocarcinoma (bone, peritoneal and ganglion metastasis with right ureter invasion and large abdominal vessels involvement), under radioisotopes treatment. Admitted to A&E with fever, vomiting, constipation, abdominal pain and left sciatica. On physical examination the patient had abdominal tenderness and distention. Bloods on admission showed acute kidney injury and raised inflammation markers (c-reactive protein (CRP) 26 mg/dL), abdominal CT revealed ascites and densification of mesenteric fat. The patient was hospitalized with the diagnosis of intestinal subocclusion. Over the first days there was clinical deterioration with increased CRP (44 g/dl) and a CT showing severe gastric and small bowel distension and pneumoperitoneum, indicating small intestine perforation. A nasogastric (NG) tube was inserted and empirical antibiotic therapy with piperacillin-tazobactam initiated. The patient was transferred to the Palliative Care Unit and started on systemic corticosteroid therapy and haloperidol. After 3 days there was clinical improvement, with decreased gastric drainage and intestinal transit re-established. NG tube was taken out and diet was progressively reinstated. A repeat CT after 1 week, showed resolution of both the distention and pneumoperitoneum. Due to sciatic pain a CT spine was obtained revealing an adenopathic conglomerate invading the L2 and L3, an L2 pathological fracture and a voluminous secondary pelvic lesion in contact with the left sciatic nerve. Pain control was achieved with morphine and gabapentin. Following 5 weeks of hospitalization the patient was tolerating soft diet, opening bowels regularly, well controlled pain,

renal function and CRP were back to normal. He was discharged home on dexamethasone.

Discussion

The reserved prognosis of the advanced oncologic disease determined the decision for nonoperative management focusing on patient's comfort, allowing global symptomatic improvement as well as resolution of the condition. In advanced disease with reserved prognosis, surgical intervention may present increased risks and deterioration of the quality of life. Hence, non-conservative measures should always be considered.

#1934 - Abstract

END OF LIFE DECISION MAKING ON MEDICAL WARDS - WHAT ARE THE KEY AREAS FOR IMPROVEMENT?

Jonathan Brown¹, Michael Mercer²

¹ Manchester University NHS Foundation Trust, Manchester, United Kingdom

² Torbay and South Devon NHS Foundation Trust, Torquay, United Kingdom

Background

Approximately 58% of people die in hospital. The proportion of patients who survive cardiorespiratory arrest is low. Cardiopulmonary resuscitation (CPR) carries a significant risk of traumatic injury followed by a prolonged period in intensive care. As such, acute medical doctors are regularly involved in end of life decision making with patients and families. This study aimed to assess the completion and subsequent documentation on end of life forms, thus identifying key areas for improvement.

Methods

This was a single centre, retrospective snapshot study on end of life forms of patients admitted over one month to three medical wards in a teaching hospital. Primary endpoints included analysis of documentation on end of life forms. A standard of 100% correct completion was deemed attainable. Secondary endpoints included number of patients admitted with an existing end of life care plan in place, and the number of new end of life plans communicated to the General Practitioner (GP) on the patient's discharge.

Results

58 patients were identified within the study period. Of the 16 primary end points assessed, the areas meeting standards (100% completion) included clear documentation of resuscitation status, date of completion, doctors name, job title and signature and previous end of life forms rescinded. Areas not meeting standards (<100% documented) included full patient identification on form, mental capacity assessment, discussions with patient/family/representative, time, doctor registration number, clear treatment escalation decisions, rationale for decision making. The secondary endpoints identified 31% of patients were admitted with existing end

of life forms, and 16% of patients aged 70+ were discharged with an end of life form, of which 42% were communicated to the GP.

Conclusion

The core information required from an end of life form is the accurate advanced documentation of a patient's decision regarding CPR. This study shows that in 100% of cases where an end of life form was completed, the decision regarding CPR was clearly documented.

The main area for improvement highlighted was the lack of documentation of patient's mental capacity and subsequent discussions with next of kin. Furthermore, there was a distinct lack of communication of end of life plans with patient's GPs. These findings are unlikely to be specific to our hospital. We recommended redesigned end of life forms, to simplify mental capacity assessment and promote clearer documentation of discussions.

#2103 - Abstract

PALLIATIVE CARE - WHAT DO PEOPLE KNOW?

Filipa Botelho De Viveiros Cardoso, Rita Valente, Estefânia Turpin, Miriam Araújo, Teresa Souto Moura

Centro Hospitalar Universitário Lisboa Central, Lisboa, Portugal

Background

Palliative Care is an approach intended to improve the quality of life not only of the patient facing a life-threatening illness, but also his/hers family. It spares no one and tries to relieve any suffering by early diagnosis and assessing problems related with the illness. From our perspective, this still is a taboo subject, thus we intended to ascertain what people know about this specialty by creating a questionnaire based on the directives written on portuguese 'Diário da República'.

Methods

An anonymous inquiry based on national norms, was given to all people we found at the hospital during 1 month, independently of their age and literacy. Plus, an online version was created in order to reach people from outside our hospital. Data was analysed via Excel.

Results

904 questionnaires: 400 were health care professionals (HCP) while 504 were not (NHCP).

Characterization of the population:

- HCP(28%male; 65.7%aged between 18-39): 189medical doctors (32.8%male), 28surgeons (64.2%male), 71nurses (12.7%male), 112other type of professionals such as physiotherapists, etc (20.5%male).
- NHCP (39% male;44.6%between 40-59 years): 41.1%had a bachelor degree,8.5% did'nt know which patients should be referred to palliative care.

Characterization of the answers:

Those who previously contacted directly or indirectly with people on palliative care:66.5% HCP vs 49.2%NHCP.

Who might be referred to palliative care? Oncologic and non-oncologic patients with diseases in advanced and progressive stage (59% HCP; 48.1% NHCP).

The age of the person to be indicated does not matter (82.5% HCP; 74.4%NHCP).

Palliative care should encompass patients and their family (83.3% HCP; 75.2% NHCP).

Either public, social or private institutes might be involved in Palliative Care (93% HCP; 78.1% NHCP).

49.5% of HCP and 41.8% of NHCP think that there isn't a specific specialty.

Conclusion

In 'Diário da República' it is said that Palliative Care should be given to oncologic and non-oncologic patients with diseases in advanced and progressive stage. However, in our point of view, people with all types of life-threatening diseases should be referred to palliative care as soon as possible, independently of the stage of progression. Moreover, we didn't expect that there would be such a small difference in opinion between HCP and NHCP of who should be addressed to Palliative Medicine. Despite bias (small population), one might say that there is still work to be done concerning medical education, not only to HCP but also to the general population.



PERIOPERATIVE MEDICINE

#204 - Abstract

THE EVALUATION OF EFFECTIVENESS OF ACTIVE THERAPEUTIC SUPERVISION PROGRAM IN PATIENTS, WHO UNDERWENT EXTENSIVE SURGERY

Elizaveta Trofimova, Daria Kotova, Victoria Shemenkova, Sergei Kotov

1st Pirogov City Clinical Hospital, Moscow, Russia

Background

Aim of the study is to evaluate the reduction on the frequency of nonsurgical complications in patients, who underwent high surgical risk procedures.

Methods

During the period from 2011 till 2018 year in the University Clinic of urology 1st Pirogov Clinical Hospital 111 patients underwent surgery. Two groups of patients were compared: retrospective and the follow-up (prospective). The retrospective group consisted of 65 patients, who underwent surgery, and were not included in the active therapeutic supervision program. In the follow-up group 46 patients were included, who underwent surgery during the period 2016–2018 and who received active therapeutic supervision. During realization of the program cardiological risks were evaluated, the medicamental therapy was improved. Postoperative monitoring in the intensive care unit as well as in the urological department was established. The two groups were comparable by sex (21.5%/19.5% women and 78.5%/80.5% men), age (65.2 (55.1–75.3) and 66.2 (57.8–74.6) $p=0.56$), BMI (27.5 (22.3–32.7) and 26.7 (21.6–31.8) $p=0.48$), Lee-index (0.9 and 0.9, $p=0.61$), co-morbidity. POSSUM index was 30.7 (24.1–37.3) and 34 (29.9–38.1) $p=0.008$ respectively. In the retrospective group 53 cystectomies (81%) and 12 nephrectomies followed by thrombextraction (19%) were performed. In the follow-up group 35 cystectomies (76%) and 11(24%) nephrectomies followed by thrombextraction (19%) were performed. The mortality and postoperative nonsurgical complications during the first 30 days after the surgery were evaluated, as well as the length of hospital and ICU stay.

Results

The number of hospital deaths was 10 in the retrospective and 1 in the prospective group (Fisher-Index=0.024). There were 40 cases

of nonsurgical complications in the retrospective group and 13 cases in the prospective (Fisher-Index=0.0009). The length of the hospital stay was lower in the follow-up group (21 days (17–27) and 11 days (8–16) $p<0.0001$) as well as the length of ICU stay (5 days (3–7) and 2 days (2–3) $p<0.0001$). During the research the difference between the intraoperative blood loss was noted: 400ml in the retrospective (200–700ml) and 175ml in the follow-up group (100–300ml) $p=0.0002$, that can be explained by the more careful preoperative preparation and by improving the medicamental therapy.

Conclusion

The active therapeutic supervision program led to the mortality reduction as well as to the decrease of nonsurgical complications and length of the hospital stay in patients, who underwent extensive surgery.

#1314 - Abstract

CO-MANAGEMENT IN ORTHOPEDIC DIVISION – A BEFORE-AFTER STUDY

Pauline Darbellay Farhoumand, Hermès Miozzari, Christophe Fehlmann

University hospitals of Geneva, Geneva, Switzerland

Background

Co-management is the shared responsibility, authority and accountability for the care of hospitalized patients between a specialist (usually in a surgical specialty) and a hospitalist. High quality data about the impact of co-management on mortality, post-surgical complications, length of stay and costs are missing and results are conflicting. We assessed the impact of implementation of a co-management team by conducting a before-after study in an orthopedic division of Geneva University Hospitals.

Methods

We assessed the impact of co-management by comparing patients admitted the year before and after the implementation of one internal medicine (IM) resident for 5 units of the division of general orthopedics. This resident co-managed, with residents of orthopedics, about 100 patients. We excluded patients over 75 years old with a bone fracture, already co-managed by a geriatrician. The IM resident was charged with systematic daily charts rounds

with nurses, weekly bedside rounds with orthopedics' resident, drugs prescriptions, general orientation advice, and follow-up of any medical condition. She was not responsible of admission and discharge notes, postoperative anticoagulation management and discharge planning. Outcomes measured were length of stay, ICU transfers, number and nature of secondary medical diagnosis coded and nurses' satisfaction.

Results

During the year before and after the implementation, 8252 (4212 before, 4046 after) patients were concerned by the co-management. They were more men (52.4%) and were 53.5+/-20.3 years old. The length of stay was not different between the two periods (6.4 days versus 6.5 days, $p=0.685$) none were the number of ICU transfers (1.9% before and after). However, the number of secondary medical diagnosis coded for the billing was higher for the period with the IM resident (3.4% versus 2.9%, $p<0.001$). Finally, the nurses' satisfaction was excellent: 95% would like the project continuation and 82.5% think that the care of patients in emergency situations was improved.

Conclusion

The implementation of a co-management team in orthopedics division was associated with a better detection of secondary medical problems and a high level of nurses' satisfaction. We observed no reduction of length of stay and no impact on ICU transfers. Length of stay and the number of ICU transfers observed in our study are much lower than measured in previous positive studies assessing the impact of co-management in surgical divisions.



PREVENTIVE MEDICINE

#37 - Abstract

ACUTE MYOCARDIAL INFARCTION AND ITS ASSOCIATION WITH HYPOVITAMINOSIS D - AN EPIDEMIOLOGICAL STUDY FROM TERTIARY CARE CENTER IN EASTERN INDIA

Shambaditya Das, Abhirup Banerjee, Brikodar Patary, Mrinal Acharya, Ananta Dutta, Niladri Sarkar

Institute of Post Graduate Medical Education & Research, Kolkata, India

Background

Vitamin D deficiency is emerging as a new risk factor for various cardiovascular diseases (CVDs), especially atherosclerotic vascular diseases. The possible mechanism could be upregulation of rennin-angiotensin axis, loss of beneficial action against modulation and inflammatory process in vascular smooth muscle cell and endothelial cells and increased of other metabolic disorder.

Methods

It is a single centre case-control study involving consecutive 54 patients, above the age of 18 years, ambulatory prior to presentation, with AMI (evidenced by persisting chest pain, ST-T changes in ECG consistent with STEMI and NSTEMI, TropT positive) taken as CASES and age-sex matched 54 CONTROLS were taken without any history or current chest pain or AMI. Blood samples were drawn on presentation for 25(OH) Vitamin D levels.

Results

Out of the 54 cases, 30 (55.6%) had deficiency, 18 (33.3%) had insufficient and 6 (11.1%) had sufficient 25(OH) Vitamin D levels. While in 54 subjects of control group, adequate, insufficient and deficient levels of Vitamin D were found in 40 (74.1%), 10 (18.5%) and 4 (7.4%) respectively. Regression was used for the associated modifiable risk factors in both groups. It was also found that propensity of triple vessel disease were more in cases with deficiency of 25(OH) Vitamin D.

Conclusion

Hypo-vitaminosis D was present in statistically significant number of patient of AMI compared to normal population. There is increased prevalence of more severe disease with hypovitaminosis D in AMI patients. It can be concluded that hypo-vitaminosis D in AMI could be either be an epiphenomenon or increases the risk of ACS.

#52 - Abstract

RELEVANCE OF PSA SCREENING IN GERIATRIC INDIVIDUALS – A CROSS SECTIONAL ANALYSIS FROM A TERTIARY CARE REFERRAL TEACHING HOSPITAL IN INDIA

Rahul Unnikrishnan¹, Sunil Senan², Priya Vijayakumar², George Paul²

¹ Rashid Hospital, Dubai, United Arab Emirates

² Amrita Hospital, Kochi, India

Background

PSA screening is a routine clinical practice in the geriatric clinical practice – often intended to pick up early cases of prostate cancer. Multiple studies done across the world have demonstrated population specific normative values of PSA with varying thresholds for prostate cancer. Universal application of the normative values results in false positive screening results thus leading to unnecessary apprehension and invasive follow up for the same – often unnecessary.

Methods

Restrospective, cross sectional study done at Kochi, India where PSA of patients between January 2012 and June 2013 were studied (n=1038).

Results

- 105 patients were found to have an elevated PSA, of which 24 underwent biopsy after serial estimations as per protocol. Only 7 were proven to be malignant.
- Mean PSA values were found to be 1.55, 1.4 and 1.20 in the 60-69 years, 70-79 years and 80+ categories respectively.

Conclusion

- Age specific ranges of PSA is essential in interpreting PSA of elderly and our study showed values that are similar to the expected.
- The study also demonstrates that roughly 10% of the elderly population in all age subsets has PSA values over the normal.
- Only 7 malignancies were picked up by the routine use of PSA testing in the study population of 1038. i.e. 6.7 per 1000. This brings us to the question of cost effectiveness and utility of routine PSA screening, particularly when it places roughly 10% at risk for biopsy.

4. Malignancies were detected in patients with falling PSA values and also who had unsuspecting findings on PR, hence questioning its relevance

#166 - Abstract

EXPERIENCE IN THE APPLICATION OF VOLUMETRIC SPHYGMOMETER FOR SCREENING ASSESSMENT OF VASCULAR WALL STIFFNESS IN PERSONS OF WORKING AGE

Marina Milyutina^{1,2}, Ekaterina Makarova^{1,2}, Yulia Ivanova¹, Monika Shonia^{1,2}, Natalia Lyubavina², Stanislav Martynov²

¹ NNIIGP, Nizhny Novgorod, Russia

² FSBEI HE PRMU MOH Russia, Nizhny Novgorod, Russia

Background

Volumetric sphygmometry is a perspective method to identify patients with high cardiovascular risk. The aim of the work was to assess the index of the vascular wall according to volumetric sphygmography in people of working age.

Methods

The study included 189 men (average age 39+9,45 years) working at the metallurgical plant, who had passed through medical examination. The level of total cholesterol (CCS), C-reactive protein (CRP), lipid spectrum, status and smoking experience were determined. Assessment of arterial stiffness was organised with the help of volumetric sphygmography on the device VaSera VS-1500N (FukudaDenshi, Japan). The cardiovascular index (CAVI) and the calculated age of the arteries were also estimated.

Results

The average value of the CAVI index, reflecting the stiffness of the vascular wall, was in normal values' borders, amounting to 6,9+1,05. In 37.5% CAVI exceeded the norm for this age group (with a maximum increase to 10.9). Analysis of the lipid spectrum showed that 69 (36.5%) subjects had an increase in the level of low density lipoproteins (LDL). 36 of them (52.1%) had an increase in LDL combined with a high level of CCS, and 47.8% had an isolated increase in LDL, with a normal level of CCS. Correlation analysis revealed a significant positive connection between the CAVI index and total cholesterol ($r=0.33$, $p=0.003$), as well as LDL levels ($r=0.33$, $p=0.0037$). 15,9% of workers had heightened CAVI in normal lipid metabolism. More than a third of the surveyed (35.4%) was smokers, the connection between CAVI and smoking experience was found out ($r=0.28$, $p=0.017$). The CAVI value correlated with the CRP level ($r=0.33$, $p=0.004$) and with the natriuretic peptide ($r=0.25$, $p=0.03$). 27 patients (14.3 %) had the calculated biological age of the arteries, which exceeded the chronological (calendar) age by 4 years or more. Moreover, it can be estimated as an indicator of the development of the syndrome of early vascular aging.

Conclusion

More than a third of people of working age (37.5%) have indicators of vascular wall stiffness that exceed the norm, correlating with lipid metabolism disorders. Method of the volumetric sphygmometry allows you to identify early signs of vascular wall damage, vascular syndrome of early aging.

#178 - Abstract

AMBULATORY BLOOD PRESSURE MONITORING AS A TOOL FOR QUALITY ASSESSMENT OF HYPERTENSION MANAGEMENT

Luis Ramos Santos¹, Catarina Nóbrega¹, Margarida Temtem², Mariana Gomes¹, Diogo Raposo André¹, Maria Da Luz Brazão¹

¹ Internal Medicine Department, Hospital Central do Funchal, Funchal, Portugal

² Cardiology Department, Hospital Central do Funchal, Funchal, Portugal

Background

Hypertension is a worldwide public health problem with significant morbidity and mortality. Its diagnosis and adequate control allow for improved survival and quality of life. Ambulatory blood pressure monitoring (ABPM) is increasingly used as a diagnostic test, with traditional recommendations such as suspected white-coat hypertension or masked hypertension. Recommendations on its role as a tool for assessing adequacy of blood pressure-lowering drugs are scarcer. Our purpose is to present data that highlight the need to used ABPM more frequently to assess drug therapy results and avoid treatment inertia that may affect individual prognosis.

Methods

Retrospective descriptive analysis of ABPM tests performed in and Internal Medicine department from October 2017 to October 2018. Oscillometric method was used with a standard protocol of 30 minute-interval day measurements and 60 minute-interval night measurements. European Society of Cardiology and European Society of Hypertension cut-off levels for defining hypertension with ABPM were used. All patients filled informed consent forms.

Results

125 tests were performed in the study period. 56,8% were females, mean age of 55.2 years (± 14.4). 71% of the tests were ordered for BP control assessment in previously medicated patients. 99 patients were previously diagnosed with hypertension. 98% were already medicated. Of these 69% had uncontrolled hypertension (either combined systolic and diastolic or each in isolation). 41 patients (42,3%) were treated with at least 3 drugs (with 1 being a diuretic), and of these, 28 (68,3%) were still hypertensive, which means they should be evaluated for resistant hypertension. 41,6% were dippers, 38,4% non dippers, 13,6% reverse dippers e 6,4% extreme dippers.

Conclusion

ABPM is a valuable tool for identifying medicated hypertensive patients with uncontrolled BP. In this series, almost 70% of medicated hypertensive patients were not on target. Its use as a follow-up test is essential for hypertension management and extends far beyond its classic diagnostic indications. Increased availability of this test would likely lead to significant improvement in BP control and inherent reduction of morbidity and mortality due to hypertension.

#221 - Abstract

SPECTRUM OF DISEASES AND MULTI-MORBIDITY IN INTERNAL MEDICINE CLINICS

Sara Sajid, Iqra Amin, Minaz Mawani, Noreen Nasir, Sadia Masood, Aysha Almas

Aga Khan University, Karachi, Pakistan

Background

Internists are often the first contact for a patient; therefore they are challenged with a wide variety of co-morbid conditions and diagnoses. Pakistan is the sixth most populated country in the world and is expected to exceed 300 million by 2050. According to the 2014 WHO Non-Communicable Diseases (NCDs) Country Profile, about 50% of all deaths are attributed to NCDs. About 80 million of its individuals (approximately 50% of the population) suffer from one or more chronic conditions. It is therefore essential to estimate the current status of burden of disease in order to identify and control the contributing risk factors and treat them efficiently.

Methods

A cross-sectional study was conducted of patients presenting to the Internal Medicine clinics at Aga Khan University hospital over the period of one year in 2017.

All patients aged more than 16 years, presenting to the clinics were included. A performa was developed after consultation with the five internists; pilot tested and then was used for data collection. The number of patients recorded for this study was 2110. Chronic medical condition was defined as a disease lasting three months or longer.

Multi-morbidity was defined as greater than two co-morbid conditions at the time of the clinic visit.

Results

Around 19,259 out-patients were seen by various physicians, out of which 1847 (9.6%) records were included for this study. Mean (SD) age of the participants was 49.2 (17.2%) years, with 538 (29.1%) patients being above 60 years.

Our sample had 727 (39.4%) men and 1120 (60.6%) women. Hypertension was the most common chronic condition (35.1%) and depression was the most common new diagnosis (39.2%). The top three existing co-morbid conditions included hypertension (35.1%), diabetes (28.3%) and depression (8.3%). The three most

common new diagnoses included depression (2.1%), hypertension (2.1%) and vitamin D deficiency (2.1%). From the total number of patients included, 416 (22.5%) had one existing co-morbid condition. Multi-morbidity was present in 921 (50%) patients. 158 (8.6%) patients had more than four existing chronic conditions.

Conclusion

Internal Medicine clinics see a wide spectrum of diseases, among which hypertension, diabetes and depression are the three most frequent presentations. Almost 50% of patients suffer from multi-morbidity, which is challenging to treat in a busy Internal Medicine clinic.

#247 - Case Report

OVERLOOKED CLINICAL PRESENTATION OF IRON DEFICIENCY; RESTLESS LEG SYNDROME

Serhat Sayin

Aksaray Training and Research Hospital, Aksaray, Turkey

Introduction

Restless leg syndrome (RLS) is a neurological sensory-motor disorder characterized by sensation of movement in the legs and disturbing sensations. The first modern definition of HBS in 1945, the Swedish neurologist Karl Ekbom was also the first to define the relationship between iron level and disease. Although the pathophysiology of the disease is not fully clear, it is thought that the local reduction of dopamine in the central nervous system, which causes hyperadrenergic state, has an important role. Abnormal iron metabolism, dopaminergic dysfunction and a number of abnormalities in the central opiate system cause disease. Low levels of iron or dysfunction the dopaminergic system and low levels of iron are an important important factor in the etiology of RLS.

Case description

A 34-year-old male patient was admitted to our center with complaints of stress, restlessness and discomfort in the legs, especially in the rest and at night. The patient had a history of complete blood donation 8 times in the last two years and his complaints had begun after his last blood donation. Physical examination normal. Renal, thyroid tests and electrolyte levels were normal. On the hemogram, Hb was in the normal range but MCV: 76 fl (79-94) was detected. Iron: 40 µg/dl (30-190), iron binding capacity: 336 ng/ml (110-370), ferritin: 8 ng/ml (30-400) revealed. It was thought that the symptoms of iron deficiency could be related to HBS. The diagnosis was evaluated by the International RLS Working Group Diagnosis Criteria. Secondary RLS was accepted because the disease was caused by iron deficiency. Oral iron sulphate treatment was started and two weeks later the complaints were decreased.

Discussion

In case of iron deficiency accompanied by anemia and anemia related fatigue, fatigue, impaired concentration, and pallor, this

decrease is usually not overlooked and treated. However, in cases where anemia is not accompanied, iron parameters are generally undesirable and many symptoms due to iron deficiency cannot be attributed to any cause. RLS secondary to iron abortion is one of the most tragic examples of this condition, which seriously affects the quality of life of patients, and patients who are not diagnosed correctly are prescribed antidepressants and sometimes antipsychotics unnecessarily. RLS is a neurological sensory-motor disorder that should not be missed in clinical evaluation. In patients with RLS, iron parameters should be evaluated with or without anemia.

#1021 - Abstract

SPORTS AND HEALTH PRACTICE. A RESEARCH PERFORMED IN YOUNG PEOPLE WITH HIGHER EDUCATION

Pascual Ruben Valdez^{1,2}, Franco Stampalia¹, Leonardo Valente Magallanes¹, Hernán Pérez¹, Federico Carmona¹, Andrea Díaz¹

¹ Buenos Aires University (UBA). Argentina, Buenos Aires, Argentina

² Sociedad Argentina de Medicina, Buenos Aires, Argentina

Background and Objectives

To quantify people who do physical activity (PA), identify professional behaviors before the request of PA, establish differences in habits and risk factors between people with and without PA.

Methods

Prospective, observational, transversal, analytical design. They include people from CABA, with tertiary or university studies completed or underway.

Results

Results: 67% currently practice PA. It is done 3 times a week for 75 minutes. 59% consider that the time dedicated is adequate. In 21% it was indicated by a professional. 54-71% of the professionals take basic behaviors in the consultation by PA. 33-66% request complementary methods. 28% are referred to cardiology. Less than 20% measure tolerance to exercise in the office. In 10% of those who do not have PA, it was contraindicated. Adequate food behaviors range from 44% to 91%. The prevalence of overweight was 28.57% and the mean BMI was 22.85 ± 2.55 , without differences with and without PA. 62% have a family history of vascular risk factors, without differences with and without PA. Smoking 16%, without differences with and without PA. The 6-30% oppose objections to PA in some pathological situation.

Conclusion

Two thirds perform PA, 3 times a week for 75 minutes. Before the request for PA, professional behaviors are incomplete in the interview and physical examination, and there is an excess of requests for complementary methods and cardiological consultations

#1028 - Abstract

ASPECTS OF SEXUALITY AND SEXUAL TRANSMISSION INFECTIONS IN ADOLESCENTS

Pascual Valdez¹, Paula Vendramini¹, Natalia Vendramini¹, Lucia Valdez D'Stéfano¹, Andrea Diaz¹, Julio Wacker¹, Dario Leff²

¹ Buenos Aires' University (UBA). Argentina., Caba, Argentina

² Buenos Aires' University (UBA). Argentina., Buenos Aires, Argentina

Background and Objectives

Identify knowledge and risk behaviors among adolescents about sexually transmitted infections (STI).

Methods

Methods: Prospective, observational, transversal and analytical study. Survey of adolescents between 16 and 26 years old through social networks

Results

741 respondents. Women 78.13%. Age 21.37 ± 0.10 years. Self-reported average status: 80.43%. 73.41% with university studies in progress or completed. The ITS questions were answered with an error range of 2.51% to 19.83%. The condom is cited as preventive of STI by 70.98%. 5.26% do not know about anal sex as a source of STIs. 16.46% presented an STI, the most frequent being HPV with 53.91% (p value X2: 0.009). 43.72% have been tested HIV. The beginning of sexual relations (SR) occurs on average at 16.65 ± 0.07 years, with 6.20% still not having started them (women 5.87% vs men 7.40%, p value X2: 0.02). The total number of sexual contacts is 8.80 ± 0.45 . The weekly frequency of SR is 2.24 ± 0.07 . The 37.69% responded that they always take care of themselves and 31.36% said they used condoms throughout the SR. No condom is used in 43.16%, 14.67% and 93.66% of anal, vaginal and oral relations respectively. He received sex education in the school 63.02%.

Conclusion

Conclusions: The risk behaviors reported do not correlate with the general answers about self-care in sexual health. Sex education in secondary education is far from appropriate.

#1037 - Abstract

TOLERANCE BREAKDOWN AND T CELL DYSREGULATION IN NON-SILICOTIC SILICA EXPOSED WORKERS

Benoît Brilland^{1,2,3}, Céline Beauvillain^{3,4}, Géry Mazurkiewicz⁵, Pierre Rucay⁶, Julie Tabiasco³, Emeline Vinatier⁴, Jérémie Riou⁷, Pascale Jeannin^{3,4}, Gilles Renier⁴, Jean-François Subra^{1,2,3}, Jean-François Augusto^{1,2,3}

¹ Service de Néphrologie-Dialyse-Transplantation, CHU d'Angers, Angers, France

² LUNAM Université, Angers, France

³ CRCINA, INSERM, Université de Nantes, Université d'Angers, Angers, France

⁴ Laboratoire d'Immunologie, CHU d'Angers, Angers, France

⁵ Service Santé au Travail Côte de Lumière, Les Sables D'Olonnes, France

⁶ Service de médecine du travail, CHU d'Angers, Angers, France

⁷ MINT, UNIV Angers, INSERM 1066, CNRS 6021, Université Bretagne Loire, IBS- CHU, Angers, France

Background

Chronic silica exposure can lead to silicosis associated or not with autoimmune diseases (rheumatoid arthritis, ANCA associated vasculitis or systemic sclerosis). The pathophysiology of silica-induced autoimmune diseases is not well determined. We conducted a prospective clinical study to analyze the impact of silica exposure on auto-antibodies secretion, regulatory T-cell, T-cell phenotype and activation status in non-silicotic subjects.

Methods

In companies known for moderate to high silica exposition, thirty to sixty-year-old subjects exposed to silica were included. Purified leukocytes were analyzed by flow cytometry. Serum was screened for antinuclear antibody (ANA) (Hep2 cell indirect immunofluorescence) and Anti-neutrophil cytoplasmic antibody (ANCA) (ethanol-fixed neutrophils indirect immunofluorescence).

Results

Among the 55 subjects exposed to silica included, ten were exposed less than 5 years, 18 were exposed 5 to 10 years and 27 were exposed more than ten years. Forty-two healthy subject were included as control.

We show a significant increase in the expression of the HLA-DR activation marker on T cells (CD3+, CD4+ or CD8+) in subjects exposed to silica compared to unexposed subjects; the increase was greater with longer exposure time and a significant decrease in the frequency of regulatory T cells (CD4+CD25+CD127-FoxP3+). Exposed subjects had an increase in autoantibody positivity compared to the control group. Among the subjects exposed more than 10 years old, 44% presented ANAs, 22% ANCA versus 5% and 2.5% respectively in the control group.

Conclusion

We show that silica exposure is associated with a tolerance breakdown: this condition is associated with a decrease of

regulatory T cells and an increase in T cell activation status. These results show alterations in the T lymphocyte compartment associated with an abnormal humoral signature in subjects exposed to silica.

#1114 - Abstract

CALCITONIN PLACE IN SCREENING, MONITORING AND PROGNOSIS OF MEDULLARY THYROID CANCER

Karima Sifi¹, Sabah Hanachi², Khalida Boudaoud³, Salima Zekri², Nassim Nouri¹, Karima Benmebarek⁴, Noredine Abadi¹

¹ Laboratory of Biology and Molecular Genetics Faculty of Medicine University Salah Boubnider of Constantine 3, Constantine, Algeria

² Laboratory of biochemistry Constantine University Hospital Center, Constantine, Algeria

³ Laboratory of Biology and Molecular Genetics Faculty of Medicine University of Constantine, Constantine, Algeria

⁴ Department of Constantine University Hospital Center, Constantine, Algeria

Background

Serum calcitonin (CT) is a sensitive and specific marker of medullary thyroid cancer (MTC).

It's a diagnostic marker for prognosis and monitoring.

The use of specific adult norms by sex allows a better interpretation of moderate CT elevations. Stimulation tests provide little additional information and tend to be abandoned.

The aims of this study were to assay CT in patients with probable MTC and to estimate the interest of its dosage for the screening, the diagnosis, prognosis and the follow up of the MTC (index cases and their relatives).

Methods

Our study included 40 patients referred by endocrinology department, divided into 27 MTC index cases and 13 first degree relatives. CT was assayed by chemiluminescence immunometry, measuring range of 2-2000 pg/ml, lower basal threshold to 10 pg/ml.

Results

Preoperatively, the CT assay was performed in 12% of patients only with rates ranging from 10 to 150 pg/ml in 4% of cases and over 1000 pg/ml in 8% of cases.

Postoperatively, 68% of index cases had elevated calcitonin and 32% of MTC patients have normalized their CT rates. The MTC screening in relatives of index cases who presented a mutation in the RET proto-oncogene showed that 66.7% of relatives showed high CT rates ranging from 11-766 pg/ml before surgery and 50% saw a persistence of their high CT after surgery.

Conclusion

Calcitonin is a very sensitive biochemical marker. The absence of its preoperative dosing leads to late MTC diagnosis and the initial surgery is often incomplete.

#1149 - Abstract

SMOKING PREVALENCE AMONG INPATIENTS AT HOSPITAL DE CLÍNICAS, “DR MANUEL QUINTELA”, AN URUGUAYAN TEACHING HOSPITAL

Mauricio Luis Minacapilli Manetti, Virginia Nuñez, Antonella Pippo, Carolina Parodi, Mary Barros, Selva Romero, Laura Llambi
Hospital de Clínicas, Montevideo, Uruguay

Background

According to the World Health Organization, smoking is the leading cause of morbidity and preventable death worldwide. Nowadays, in Uruguay, smoking prevalence is 21,6%. Tobacco attributable cost burden up to the 15% of the GDP according to the World Bank. In Uruguay, the annual cost is probably over 2.5% of GDP. A 2013 study from Uruguay, found a smoking prevalence of 27.3% among in-patients, with longer hospital stay compared to the hospital mean stay. No data about smoking prevalence in in-patients is available in our Hospital, nor its impact in duration of hospital stay and its costs. Our objective was to assess the smoking prevalence and its characteristics in inpatients at internal medicine wards

Methods

We conducted an observational, analytic, single cross-sectional study, with the administration of a survey and data from the hospital's medical records software. We included patients who were older than 18 years of age and provided their informed consent form, from two internal medicine wards

Results

We included 100 patients, 38% were smokers, 27% were former smokers and 35% had no history of tobacco use. There was a greater prevalence of smoking among men, with a 50% of prevalence, against 28.03% in women. The mean age was 48.65 years old among smokers, 63.11 in former smokers, and 58.68 in the no smokers group. 44.73% of smokers were maintaining abstinence, meanwhile 21% of smokers didn't pretend to quit. In the group of non smokers, 28.57% recognised exposure to second hand smoke at home. Hospitalisation mean duration in the smokers group was of 31.07 days in the last year, vs 20.11 days in the non smokers group ($p=0.1337$). Regarding the use of other drugs, 15.78% of smokers and 2.85% of no smokers had alcohol intake daily. Marijuana consumption was up to 15.78% and cocaine 21.05%, but only 1 patient used marijuana and cocaine in the no smokers group. Up to 14% of the patients died during the hospitalization, 14.28% were no smokers, 28.57% were former smokers and 57.14% were smokers ($p=0.0569$). The mean of age in this group was 49.37 years old among the smokers, 70.75 in ex-smokers, and 76 years old in no smokers

Conclusion

A high prevalence of tobacco use was detected among in-patients, with longer hospital stay, and greater mortality at younger

age. Longer hospital stays pose greater health costs and worst outcomes related to hospitalization. Most of these patients were highly motivated to cessation and could be benefited from multidisciplinary approach to achieve cessation.



RARE DISEASES

#104 - Case Report

WILSON'S DISEASE: A DIAGNOSTIC AND THERAPEUTIC CHALLENGE

Miguel Trindade, Ricardo Oliveira, João Serôdio, Ricardo Marques, Ana Bastos Furtado, José Delgado Alves
Hospital Professor Fernando Fonseca, Lisboa, Portugal

Introduction

Wilson's disease is a rare autosomal recessive disease. A defect on the copper carrier protein ATP7B prevents copper excretion. The prognosis of Wilson's disease is favorable if the diagnosis is made early.

Case description

A 24-year-old woman was admitted with palpebral and lower limb edema and choloria. The workout revealed hyperbilirubinemia (2.7 mg/dL), hypoalbuminemia (2.1 g/dL) and severe coagulopathy (prothrombin time 39.2 seconds). The abdominal CT showed homogeneous hepatomegaly with umbilical vein permeabilization. The ceruloplasmin was low (4 mg/dL) and she was started on a copper chelating agent (trientine). The subsequent investigation also revealed low total serum copper, increased free serum copper and markedly augmented urinary copper excretion (3840 mcg/24h). There were no Kaiser-Fleischer rings. The liver biopsy showed acute hepatocellular injury with confluent necrosis and without evidence of copper pigment deposition. A brain MRI also showed bilateral high T2 signal in the red nucleus and substantia nigra. The molecular study reported pathogenic mutations in the ATP7B gene in compound heterozygosity. The Leipzig score was 7 and Wilson's disease diagnostic was made. At eleven months of follow-up, she maintains chelating therapy and is asymptomatic with normal liver function.

Discussion

This is a rare Wilson's disease report. The treatment was started early, and liver function was restored. The absence of neuropsychiatric manifestations and an inconclusive liver biopsy presented a diagnostic challenge that was only surpassed by the genetic test. To our knowledge, this is the first report of the combination of two mutational variants: c.3402del and c.3061-12T>A.

#115 - Case Report

A RARE REASON OF PROTEINURIA: IMERSLUND-GRASBECK SYNDROME

Sibel Yucel Kocak, Ceren Gumusel, Ozlem Kaptanogullari Harmankaya, Murvet Yilmaz, Suheyila Apaydin
Bakirkoy Dr. Sadi Konuk Training and Research Hospital, Istanbul, Turkey

Introduction

Imerslund Grasbeck syndrome(IGS) is a rare disease caused by vitamin B12 malabsorption. In terminal ileum, there is a dysfunction or absence of intrinsic factor (IF)-B12 receptor. As a result of mutation in Cubam receptors, the absorption of vitamin B12 is impaired. In this case, IGS patient with proteinuria was presented because of its rarity and long follow-up period(26 years).

Case description

A 26-year-old female patient admitted to nephrology clinic with proteinuria. When he was 2 years old, examined for anemia (hb 3.6 g/dL) and thrombocytopenia(38,000/mm³) due to fatigue and weakness. He was diagnosed with IGS due to megaloblastic anemia with vitamin B12 deficiency and had rapid recovery after parenteral vitamin B12 treatment. Two of her brothers died when they were 2,5 and 3 years old. All system examinations were normal. In laboratory; leukocyte 7460/mm³, erythrocyte 3,590,000/mm³, hb 11.4 g/dL, MCV 97.5 fl, RDW 15.7%, PLT 324,000/mm³, vitamin B12 101 pg/mL, folic acid 4.51 ng/mL and other values were normal. 708 mg/day proteinuria was detected in 24 hours urinalysis. Protein/creatinine ratio was 818.58 mg/g, albumin/creatinine ratio was found 442.34 mg/g in spot urine. In the peripheral blood smear, large hypersegmented nucleus neutrophils, anisocytosis and poikilocytosis were detected. Abdominal ultrasonography was normal. Parenteral vitamin B12 intramuscular was started.

Discussion

IGS is a malabsorption syndrome with good prognosis with vitamin B12 deficiency and proteinuria, but it can be fatal if it is not treated parenterally. In our case, two brothers died when they were babies. It should be kept in mind that IGS may be due to vitamin B12 deficiency in patients presenting with proteinuria. IGS is diagnosed with macrocytic anemia, low vitamin B12 levels and proteinuria. Although it is a rare disease, it should be considered

in patients with proteinuria. Kidney biopsy is not recommended, it should not be treated with angiotensin converting enzyme inhibitors or angiotensin receptor antagonists. A limited number of cases were observed for 50 years and no progressive kidney disease developed. This case is presented because it is a rare cause of proteinuria and has a good renal prognosis for 26 years. Genetic studies will allow us to avoid more aggressive techniques such as renal biopsy in patients with proteinuria and also offers the opportunity to examine family members.

#137 - Case Report

A RARE CASE OF MEDULLA OBLONGATA ABSCESS

Amit Verma

Eastbourne District General Hospital, Eastbourne, United Kingdom

Introduction

Abscess of the brain stem is rare and fatal. Even rarer is pyogenic abscess of Medulla Oblongata.

We report a case of Medulla abscess which presented as mixed upper and lower motor neuron signs a week after tooth extraction. The association of tooth abscess to Medulla exists but only few cases have been reported so far.

The clinical symptoms, examination findings, radiological appearance and treatment of the case are discussed.

Case description

This 68 years old gentleman had a 7 day history of weakness in left leg and left arm, numbness of left leg and slurring of speech. Cough with phlegm was present for 2 days. He had tooth extraction secondary to abscess 7 days prior to admission.

On physical examination he was drowsy but easily arousable and oriented. CNS examination revealed reduced power in left hip and shoulder joint, absent knee and ankle reflex both sides and bilateral extensor planters. Horizontal nystagmus to the left was present. Gag reflex was absent and speech was slurred. Chest examination revealed coarse crepitations in left lung base.

His basic lab investigations was normal (white cells 9.3, CRP 1). Lung imaging showed aspiration pneumonia on left side. CT head then MRI revealed abscess in Medulla Oblongata.

The next day he was intubated (worsening pneumonia) and abscess was drained neurosurgically. The sample was positive for streptococcus intermedius. He was given 3 month course of ceftriaxone. His neurology improved progressively post drainage and was discharged following rehabilitation and physiotherapy.

Discussion

There are very few reports of abscess in Medulla Oblongata. Only handful of them ended in good outcome.

The presenting symptoms of medullary abscess are variable as they depend on which nuclei and tracts are affected. Fever and inflammatory markers are unreliable signs. MRI brain is usually diagnostic and investigation of choice in such cases. The growth of

streptococcus intermedius in sample points to the source as tooth abscess, which is known but not reported so far.

In our patient, brisk diagnosis and rapid neurosurgical intervention led to favourable outcome in what has been largely a fatal disease. Subsequent imaging confirmed adequacy of drainage and medical treatment.

Historically the abscess in Medulla Oblongata has been most often fatal. Adequate suspicion, prompt diagnosis with MRI and quick surgical drainage together with medical management can result in excellent outcomes and prevent fatality associated with it.

#203 - Case Report

INTESTINAL ANGIOEDEMA INDUCED BY ANGIOTENSIN-CONVERTING ENZYME INHIBITORS: RARE FORM OF ABDOMINAL PAIN PRESENTATION

Ema Neto, Maria Ana Canelas, Márcio Mesquita, Tiago Costa, Beatriz Samões, Paula Ferreira

Centro Hospitalar Vila Nova de Gaia/Espinho, Vila Nova De Gaia, Portugal

Introduction

Intestinal angioedema caused by angiotensin-converting enzyme inhibitors (ACEI) is rare, with only about 20 cases reported in the medical literature until 2010. Patients with this condition typically present with common symptoms such as diffuse abdominal pain, cramping, nausea, and emesis, most common attributed to more frequent medical conditions. Awareness of this entity is essential to diagnose and correctly treat it.

Case description

43-year-old female, treated with perindopril 4mg/daily for hypertension, with no allergies, is brought to emergency room (ER) department with severe and diffuse abdominal pain, in the left quadrants since the day before. On physical exam presented diffuse abdominal pain, and blood work revealed Leukocytosis of 19.000/uL and C reactive protein of 3.38 mg/dL. Abdominal computerized tomography revealed marked parietal jejunum thickening in the left iliac flank with vascular engorgement and moderate ascites, suggesting angioedema. After a twelve hours surveillance period, the patient was discharged from the ER, with indication to suspend perindopril and start amlodipine (5 mg daily), bilastine (10 mg daily for 10days) and a short prednisolone cycle (20 mg twice/day for 5 days) and was referred to immunoallergology consultation to further investigation. Evaluation one month after revealed a full regression of the symptoms after the perindopril discontinuation, and no more evidence of intestinal angioedema in control abdominal echography. Protein electrophoresis, ANA and complement assays, sedimentation rate and inhaled prick tests were all negative.

Discussion

The use of ACE inhibitors in the general population is widespread, and awareness of potential intestinal angioedema is important

and is often overlooked at initial presentation. An accurate diagnosis and proper discontinuation of the precipitant agent helps the patient recover quickly avoiding unnecessary tests and invasive procedures.

#210 - Case Report

FROM JOINT PAIN TO TETRAPARESIS: DIAGNOSING HEMOPHAGOCYTIC LYMPHOHISTIOCYTOSIS (HLH)

Florina Gabriela Udrea, Gabriela Voicu, Mihai Bojinca
Dr I Cantacuzino Clinical Hospital, Bucharest, Romania

Introduction

Hemophagocytic lymphohistiocytosis (HLH) is a rare and potentially fatal hyper-inflammatory condition. It is a genetic condition due to mutations in genes involved in the cytolytic secretory pathway (perforin and granzymes) responsible for apoptosis in target cells. Primary HLH can occur at any age, from in utero until as late as 70 years old. The entire spectrum of clinical manifestations needs to be considered in making the diagnosis.

Case description

We present the case of a 50 years old female patient who arrived in emergency room with fever, changes in mental status, tetraparesis and hypotension. She had a long disease history that began eight years ago when she received different hypothetical diagnoses of urticaria vasculitis, Schnitzler syndrome, lymphoma, sarcoidosis, Langerhans cells histiocytosis, autoinflammatory syndrome. During the last years all immune connective tissue disorders have been excluded. Immunohistochemical analysis of a mediastinal node revealed CD68+ in many histiocytes and immunophenotyping flow cytometry put into evidence a very low level of NK cells. At the moment of admission lab tests showed: leucopenia, thrombocytopenia, hyponatremia, hypoproteinemia, high level of aminotransferases, CK, hypertriglyceridemia, hypofibrinogenemia, very high level of ferritinemia, with normal values for acute phase reactants. Electromyography confirmed a myopathic pattern, myositis immunoblot was negative and muscle biopsy revealed the absence of inflammatory infiltrate except for many CD68+ macrophages. We thought about a macrophage activation syndrome with hemophagocytosis associated with a myositis. However, NK cells were very low, soluble CD25 level was very high and hemophagocytosis was present in the bone marrow as well. We established the diagnosis of HLH according to diagnostic guidelines for HLH-2004. Firstly, she received corticosteroid therapy in high doses, however, without response. Then we switched to dexamethasone and cyclosporine A. After 8 weeks her mobility recovered, lab tests improved, the level of NK cells increased 10 times and soluble CD25 level decreased by 50% from admission.

Discussion

HLH is a potentially fatal condition easily missed in adults. There is a great need for awareness of this condition, which requires early

diagnosis, effective therapy and strong connections between physicians involved in management of the case.

#218 - Abstract

IGG4-RELATED DISEASE AND HYPEREOSINOPHILIC SYNDROME: OVERLAPPING PHENOTYPES?

Aurore Moussiegt¹, Romain Muller², Mikaël Ebbo², Jean Emmanuel Kahn³, Nicolas Schleinitz², Matthieu Groh¹

¹ Department of Internal Medicine, National Referral Center for Hypereosinophilic Syndromes, Hôpital Foch, Suresnes, France

² Department of Internal Medicine, Hôpital de La Timone, Marseille, France

³ Department of Internal Medicine, Hôpital Ambroise Paré, Boulogne Billancourt, France

Background

IgG4-related disease (IgG4-RD) is associated with peripheral eosinophilia in 10-30% of cases, possibly the consequence of a Th2-driven immune response. A preliminary study suggested that disease features of IgG4-RD and lymphocyte variant-hypereosinophilic syndrome (HES) could overlap. Yet, no reference to IgG4-RD was made in the latest classification criteria for eosinophilic disorders and related syndromes established by the International Cooperative Working Group on Eosinophil Disorders (ICOG-Eo).

Methods

We investigated both the French multicentric research group for IgG4-RD and the National Referral Center for Hypereosinophilic Syndromes (CEREO) databases. Patients fulfilling (i) Comprehensive Diagnostic Criteria (CDC) for IgG4-RD (and/or organ-specific diagnostic criteria for IgG4-RD); and presenting with (ii) eosinophilia $\geq 1\text{G/L}$ were included. Data regarding baseline clinical and paraclinical findings as well as treatment responses were retrieved using a standardized form.

Results

Thirty-two patients (27 male; median age at diagnosis: 55 (26-79) years) were included. The main related IgG4-related involvements included lymph nodes (n=21), salivary glands (n=15), pancreas (n=13). Twenty-nine (91%) patients had high IgG4 levels (median 7,4 g/L) and all but one (97%) had polyclonal hypergammaglobulinemia (reaching 110g/L in a patient). The median AEC (range) peak was 2 (1-18) G/L and the main eosinophil-related organ damage included lungs (n=10), skin (n=7), ENT (n=7), heart (n=5), gastro-intestinal tract (n=4) and peripheral arterial vasculopathy (n=4). Eighteen (56%) patients had high IgE levels, while vitamin B12 and tryptase were elevated in a single patient (3%). Twenty-seven (84%) patients fulfilled classification criteria for HES (idiopathic (n=25) and lymphocytic (n=2)).

Oral corticosteroids were effective against both eosinophil and IgG4-related organ damage in all cases, yet further-line treatments

were required for 22 (69%) patients. Mepolizumab was effective against eosinophil-related organ damage in both treated patients but failed to cure IgG4-RD. Rituximab led to a drastic decrease of serum IgG levels, was effective against IgG4-related features in all 9 treated patients, and further enabled complete or partial hematological responses in all patients but one.

Conclusion

IgG4-RD should be considered as a possible diagnosis in presenting with unexplained eosinophilia or eosinophil-related organ damage, especially in the setting of polyclonal hypergammaglobulinemia.

#244 - Case Report

KIKUCHI FUJIMOTO DISEASE – A SERIES OF CASES OF A RARE ENTITY

Diogo Raposo André, Jéssica Chaves, Filipa Vicente, Mónica Caldeira, Fernando Jacinto, António José Chaves, Maria Luz Brazão

Hospital Central do Funchal, Funchal, Portugal

Introduction

Kikuchi-Fujimoto disease (KFD) is a rare benign necrotizing lymphadenitis of unknown aetiology with good prognosis. Characterized by cervical lymphadenopathy, nocturnal diaphoresis and fever. KFD can be confused with tuberculosis, systemic lupus erythematosus (SLE) and lymphoma, misleading physicians to start chemotherapy.

Case description

Case 1

A 72-year-old female with hematuria, dysuria, and pollakiuria was admitted with pyelonephritis. Thoracic and abdominal CT scan revealed accidentally thoracic and abdominal adenopathies. Laparoscopic excision of hepatic ganglia was performed, which revealed non-necrotizing granulomatous lymphadenitis.

Case 2

A 19-year-old male with odynophagia, fever, skin rash, asthenia, anorexia, and weight loss. Hepatomegaly, right cervical adenomegaly, and neurological aggravation were noted. Due to the high suspicion of Lymphoma, the patient started chemotherapy. The excisional biopsy of cervical adenomegaly then confirmed necrotizing lymphadenitis.

Case 3

Female of 58-years-old complained of myalgias, asthenia, weight loss, nocturnal diaphoresis, dyspnea, and non-productive cough for the last 2 months. Unilateral pleural effusion and bilateral axillary nodes were initially depicted. As it was compatible with Lymphoma it was started chemotherapy. The axillary nodes biopsy later confirmed follicular hyperplasia.

Case 4

A 58-year-old male attended the Urgency Service for painful adenomegaly in the right inguinal region with 3 cm in diameter

associated with fever. The thoracic-abdominopelvic CT scan showed adenomegaly altered uptake of contrast next to external femoral vessels on the right. Analytically, it showed a positive serology for AchBs, AchBc, IgG CMV and IgM CMV. Remaining complementary diagnostic exams without alterations. The excisional biopsy later confirmed necrotizing lymphadenitis.

Case 5

A 31-year-old female with KFD, histologically confirmed 3 years ago, developed scaly erythematous cutaneous lesions on the face and scalp. The cutaneous biopsy was representative of discoid Lupus erythematosus.

Discussion

KFD, although rare, may mimic infectious, autoimmune and neoplastic diseases. KFD, especially in the adult population, poses a risk of subsequently developing autoimmune disorders.

#279 - Case Report

A RARE CASE OF LAUGIER-HUNZIKER SYNDROME

Mariana Gomes¹, Mónica Caldeira², Pedro Vale Fernandes³

¹ Internal Medicine Department, Hospital Central do Funchal, Funchal, Portugal

² Hematology-Oncology Department, Hospital Central do Funchal, Funchal, Portugal

³ Dermatology Department, Hospital Central do Funchal, Funchal, Portugal

Introduction

Laugier-Hunziker Syndrome (LHS) is a rare benign condition characterized by acquired, benign hyperpigmented macules of the lips and buccal mucosa frequently associated with longitudinal melanonychia. No underlying systemic abnormalities are associated with LHS and no malignant predisposition exists. The etiology of melanosis in LHS is unknown and no treatment is required, except for esthetic and/or psychological reasons.

Case description

A 69-year old woman non-smoker with a medical history of hypertension, anemia and biliary lithiasis presented with chief complaint of pigmented lesions on the tongue, lips and fingernails. It was present since many years, with no change in colour or size. She was asymptomatic and there was no drug or exposure history to explain the findings. Clinical examination revealed a diffuse brownish pigmentation on the dorsal tongue and lips. Nails of both hands showed longitudinal melanonychia. After evaluation, a biopsy of the tongue and nails was performed and sent for histopathological examination. Our patient had clinical and histopathologic findings compatible with LHS.

Discussion

Oral pigmentation is quite common and has numerous etiologies, ranging from exogenous (eg. smoking and drugs) to physiological

(eg. racial pigmentation) to neoplastic (eg. melanoma). It may also be present in other conditions such as hyperthyroidism, Addison's disease and Peutz–Jeghers syndrome. Most of these conditions were ruled out in our patient on the basis of history, clinical and laboratory findings for the associated features.

Evaluation of a patient presented with pigmented lesions should include a full medical and dental history, extraoral and intraoral examinations and in even some cases biopsy and laboratory investigations are required. A differential diagnosis is important to exclude other mucocutaneous pigmentary disorders that do require medical management and biopsy is advised to rule out malignancy.

#490 - Case Report

COMPLETE PRIMARY HYPERTROPHIC OSTEOARTHROPATHY: ABOUT A FAMILY

Fatma Ben Fredj, Maïssa Thabet, Imen Ben Hassine, Jihed Anoun, Anis Mzabi, Monia Karmani, Amel Rezgüi, Chadia Laouani Kechrid
 Université de Sousse, Faculté de Médecine de Sousse, Hôpital Sahloul,
 Service de Médecine Interne, Unité de Recherche de Gériatrie et
 Gérontologie Clinique, Sousse, Tunisia

Introduction

Pachydermoperiostosis (PDP) or primary hypertrophic osteoarthropathy (OAH) is a rare hereditary disorder. It is a radioclinical entity affecting bones and skin. The differential diagnosis may sometimes arise with acromegaly or secondary OAH but also with chronic inflammatory rheumatism due to joint manifestations. We report the case of a family with PDP in its complete form.

Case description

We report the case of a 25-year-old man suffering from polyarthralgia with palmoplantar hypertrophy.

His history began in 2015 with the progressive installation of more pronounced diffuse polyarthralgia in large joints (knees, ankles, elbows) with diffuse bone pain and.

The patient described hypersudation, seborrhea and increased thickening of the forehead folds and palmoplantar hypertrophy during last 3 years.

Skin examination noted oily skin, pachydermia of the extremities with a pleated thickening of the forehead, without ptosis. Palmoplantar hypertrophy and digital hippocratism were evident with sullen fingers and toes. The patient shod 44 versus 41 three years ago.

Standard radiographs showed periosteal thickening of long bones, metacarpals, metatarsals and phalanges.

There was neither a biological inflammatory syndrome nor disturbance of the phosphocalcic balance. Hormonal doses of T4, TSH, GH, IGF1 were normal, as well as liver and renal checks.

The cerebral scan showed no abnormalities including the absence of pituitary adenoma. There were no abnormalities in the esogastric fibroscopia and cardiac ultrasound

The diagnosis of PDP was retained and the patient was put on colchicine.

We noted consanguinity of the parents and the physical examination of the other members of the family found the same manifestations in the father and the brother with variable intensity. Noting that the father described appearing the same symptomatology at the age of 22 years and he was on non-steroidal anti-inflammatory drugs and analgesics for more than 7 years for chronic diffuse polyarthralgia. The father had a "cutis verticis gyrata" and a pachydermia more marked.

Discussion

PDP is a benign genetic affection that primarily affects the skin and bones. Its pathophysiological mechanism remains unclear. Radiology has an essential place in the positive diagnosis. But this rare entity poses diagnostic problems with secondary OAH and chronic inflammatory rheumatism.

#504 - Case Report

DEALING WITH UNCERTAINTY IN INTERNAL MEDICINE: LEARNING FROM A CASE OF MENINGITIS RETENTION SYNDROME POSSIBLY CAUSED BY SARCOID MENINGITIS.

Naohiko Kunimoto¹, Toshiaki Wakai², Shadia Santos Constantine¹, Myeongchul Son¹, Masaji Saijo¹, Megumi Imamura¹, Urara Nakagawa¹

¹ Sapporo tokushukai hospital, Sapporo, Japan

² University of Michigan Medical School, Ann Arbor, United States

Introduction

Meningitis retention syndrome (MRS) has been reported as a rare complication of meningitis. This diagnosis is made based on symptoms and positive lumbar puncture but it still carries a high level of uncertainty. Even though uncertainty and unpredictability are common parts of internist practices, we receive little training on how to incorporate it in the medical decision making process. We learned about this through a case with two rare clinical entities: meningitis retention syndrome and sarcoid meningitis.

Case description

52-year-old woman with history of sarcoidosis developed low back pain (LBP) and urinary retention 11-days prior to admission. She visited multiple clinics with no success in identifying the cause of her symptoms. Fever developed 6-days prior to the admission, which brought her to Urology-specialized hospital. She was diagnosed as acute pyelonephritis but no clinical improvement was noted regardless of antibiotics followed by transferring to our institution. The fever resolved on the 3rd day of hospitalization, however, the urinary retention and LBP continued. Head CT/MRI and lumbar MRI were failed to reveal etiology except for chest CT showing enlarged mediastinal lymph nodes. On the 6th day, she complained of mild neck pain. We performed lumbar puncture, whose result was consistent with aseptic meningitis. The urinary retention was likely secondary to aseptic meningitis, a syndrome known as MRS.

Discussion

Signs of meningitis were not obvious in the initial presentation. Lumbar puncture results were consistent with aseptic meningitis. This is when we made the diagnosis of MRS. MRS is rare complication of meningitis.

Neurologic complications occur in 5 to 10 percent of patients with sarcoidosis, and sarcoid meningitis is also rare. There is no test for the diagnosis of sarcoid meningitis other than clinical suspicion. In this patient, we suspected sarcoid meningitis based on the clinical presentation including history of sarcoidosis, the CT finding and presence of aseptic meningitis.

No case of sarcoidosis associated with MRS has been reported. Epidemiologically, it is likely that this MRS might have been caused by viruses, however, in the setting of patients with history of sarcoidosis, MRS may be caused by sarcoid meningitis.

Even though both of them are rare, they can coincide, and MRS complicated by sarcoid meningitis may need to be considered in differential diagnoses in patients with back pain, fever, urinary retention with history of sarcoidosis.

#557 - Case Report

PLYLEPHLEBITIS, A RARE PATHOLOGY

María Inês Marques, Sara Ramalho, Rita Nortadas, Ana Oliveira Gomes, Leticia Santos, Bianca Vaz, Rita Passos Coelho, Elvis Arias Guevara

Hospital Garcia de Orta, Almada, Portugal

Introduction

Pylephlebitis is uncommon thrombophlebitis of the portal vein or any of its branches that is caused by abdominal infection, usually pancreatitis and diverticulitis. Being a rare pathology and with no pathognomonic signs, it is easy to miss unless there is a high index of suspicion and early treatment is crucial for a good prognosis.

Case description

We describe the case of a 69 years-old male, with previous history of hypertension, type 2 diabetes mellitus, dyslipidemia, smoking habits, non-anticoagulated atrial fibrillation and hemorrhoids. He was admitted to the emergency department with a 2 weeks history of fever, jaundice, anorexia and 5 Kg weight loss. He also mentioned rectal bleeding which he thought was related to his known hemorrhoids. Laboratory studies revealed an elevation of the inflammatory markers, conjugated hyperbilirubinemia and elevated lactic dehydrogenase. Abdominal ultrasound revealed homogeneous hepatomegaly and a small amount of perihepatic fluid, without biliary lithiasis or biliary ductal ectasia. Computed tomography of the abdomen showed an almost completely thrombosed inferior mesenteric vein, extra-hepatic portal vein and complete thrombosis of the superior mesenteric vein; it also showed colic diverticulosis with colic wall thickening. Serologies for hepatotropic viruses (HAV, HBV, HCV, CMV e EBV) were negative, as was the thrombophilia and autoimmunity studies. Blood cultures collected at admission isolated *Escherichia coli*. We admitted

diverticulitis complicated by pylephlebitis. He initiated a course of ceftriaxone and metronidazole, which was altered afterward according to antimicrobial susceptibility testing and initiated anticoagulation with enoxaparin, followed by favorable evolution.

Discussion

Pylephlebitis is a rare entity that might complicate common diseases like diverticulitis. Contrast imaging exams are very important to establish the diagnosis. Treatment consists of wide spectrum antibiotics and anticoagulants. Without early treatment can rapidly culminate in mesenteric/ splanchnic ischemia and death.

#558 - Abstract

SCURVY, A FORGOTTEN DISEASE?

María Folgueras, Lucía Meijide, Carmen Yllera, Silvia Suárez, Lucía Suárez, Jessica Paola Rugeles, Luis Caminal, Carlota Argüello
Hospital Universitario Central de Asturias (HUCA), Oviedo, Spain

Background

The scurvy is considered a forgotten disease in developed countries. However, cases are diagnosed specially in population at risk.

We conducted this study to describe the features of patients with vitamin C deficiency trying to define the main risk factors to develop this pathology, evaluate the possibilities for an early diagnosis.

Methods

Protocolized collection of demographic, clinical and laboratory data of patients with confirmed deficiency of vitamin C since June 2014 to December 2017 from the Internal Medicine Department at HUCA. A descriptive study was performed.

Results

6 patients with mean age of 64.5 years (23;86). 4 were partially or totally dependent for activities of daily living (ADL). 4 followed a diet without fruits or vegetables. 1 had dementia, 1 was alcoholic and 1 suffered from dysphagia. 3 had mental disorders including eating disorders.

5 related asthenia or weakness and 3 were depressed. Everyone had arthromyalgias, all of them had ecchymosis, and four presented petechiae. 3 had gingivitis and 2 had lost teeth. Two had perifollicular hemorrhages. 1 patient had "corkscrew" hair. 1 presented spontaneous hemarthrosis and 1 had a bone fracture. Vitamin C levels were lower than 0.2 mg/dl in 5 patients. Everyone had anemia and other deficits such as hypoalbuminemia, vitamin B12 and vitamin D.

All patients were treated with vitamin C, improving clinical manifestations in few weeks.

Conclusion

The main source of vitamin C are fruits and vegetables, therefore the deficiency occurs in people at risk such as our patients who

were partially dependent for ADL and had different mental disorders which implies poor diets.

Clinical manifestations appear with vitamin C levels lower than 0.2 mg/dl. Apart from asthenia and weakness, main symptoms are due to the deficient formation of connective tissue, such as cutaneous hemorrhages, bleeding gingivitis as well as other hemorrhages. Most of our patients presented asthenia and weakness and all of them had arthralgias. Everyone had ecchymosis/petechiae and half had gingivitis. The presence of anemia is explained by participation of vitamin C in the conversion of folic acid as well as into iron absorption.

At last, it's important to think about this diagnosis in patients with purpuric lesions or arthralgias and risk factors such as alcoholism, dependency or mental disorders. Also, it should be considered to check vitamin C levels in patients with other nutritional deficiencies levels since they usually coexist.

#573 - Case Report

DEEP VEIN THROMBOSIS (DVT) AND ACUTE PULMONARY EMBOLISM (APE) BECAUSE OF RETROPERITONEAL HEMATOMA IN A WOMAN WITH EHLERS-DANLOS SYNDROME (EDS)

Catarina Vilaça Pereira, Andreia Dias, Ana Vaz, Fernando Nogueira, José Cunha Marques, Diana Ferrão, Pedro Ribeirinho Soares, José Pestana Ferreira, Jorge Almeida
Centro Hospitalar São João, Porto, Portugal

Introduction

Ehlers-Danlos Syndrome (EDS) is a rare genetic connective tissue disease characterized by hyperflexibility, joint hypermobility and tissue fragility.

Case description

We present the case of a woman with a history of SED type VI, glaucoma with severe hypovision, moderate tricuspid insufficiency, allergic asthma and rhinitis, right brachial plexus lesion and repetitive neurocardiogenic syncope. The diagnosis of type VI SED was confirmed by a genetic test that revealed homozygosity for a presumptively pathogenic mutation of the PLOD1 gene, according to the Villefranche classification. The patient has blood relatives and sister with the same syndrome who died at age 38 due to abdominal aortic aneurysm rupture. Clinically and in the context of EDS it presents cutaneous hyperdistensibility and joint hypermobility. At the age of 38, he went to the Emergency Department (ED) of a hospital for sudden onset dyspnea, abdominal pain in the left iliac fossa, and painful complaints in the lower limb, with no one accompanying symptom, complaints with less than one week of evolution. She had abdominal CT angiography that showing signs of APE at the level of segmental branches bilaterally, left iliofemoral thrombosis and retroperitoneal hematoma. She underwent a transthoracic echocardiogram with only slight dilatation of the

right cavities. Analytically, there was a fall in hemoglobin (Hgb 8.6 g/dL), elevation of inflammatory parameters (leukocytosis 17,160, C-reactive protein 131.3 mg/L), elevation of D-dimers, without respiratory failure. Starts hypocoagulation with unfractionated heparin. She was admitted to an intermediate care unit for 6 days and transferred to the Internal Medicine Service. She performed CT scans and abdominopelvic magnetic resonance imaging to better characterize the peri-DVT hematoma, which revealed "dimensional reduction of the blood collection and stability of iliofemoral thrombosis.

Discussion

Thus, thrombosis was interpreted as a consequence of compression caused by retroperitoneal hematoma, which, in turn, by distant embolization culminated in APE. Thus, the present case intends to evidence the implication of EDS in increasing vascular fragility and increased propensity for the appearance of spontaneous hematomas, with potentially serious consequences and multiplicity of diagnoses in the same patient.

#584 - Case Report

FATAL ACCIDENTAL COLCHICINE OVERDOSE

Rafaela Braga Mamfrim¹, Natalia Monte Faissol¹, Ricardo Eiras¹, Victor Hugo Silveira¹, Amanda Saavedra², Renata Fachada², Adriana Osório De Castro², Luiza Coutinho Flores Da Cunha²

¹ Hospital Casa de Portugal, Rio De Janeiro, Brazil

² Hospital Municipal Miguel Couto, Rio De Janeiro, Brazil

Introduction

Colchicine is a drug mainly used for the treatment and prevention of gouty arthritis and it is a safe drug when used according to established therapeutic guidelines. However, there are a few cases of patients that self medicate and therefore could have a fatal accidental overdose. The clinical features associated with it and the options of treatment are discussed below.

Case description

A 81 year old male with history significant of gout presented with nausea, vomiting, abdominal pain and diarrhea after ingesting 36x0,5 mg Colchicine tablets over the previous 12 hours in an attempt to alleviate the pain of acute gout.

He was admitted into the Intensive Care Unit (ICU) for observation. At that time, he was alert and orientated, hypotensive with no other vital signs alterations. International normalized ratio (INR) was 4, but other than that laboratory results were unremarkable. Gastrointestinal decontamination with activated charcoal or gastric lavage was not considered due to the time of ingestion. Therefore, it was recommended to proceed with fluid resuscitation, management of the pain and observation.

After 72 hours, he developed respiratory insufficiency, mixed respiratory and metabolic acidosis and needed to be intubated. Chest radiography showed bilateral patchy shadowing throughout both lung fields and PaO₂/FiO₂ was 135, confirming acute

respiratory distress syndrome (ARDS). Besides, patient presented with fever and leukocytosis, being started on intravenous antibiotics.

His clinical condition worsened over time: he presented with hypotension and atrial fibrillation, requiring vasopressors and cardioversion. He was anuric requiring dialyses and still dyscrasic. However, despite aggressive supportive treatment, he continued to deteriorate and death occurred 10 days after admission on ICU.

Discussion

Colchicine impairs neutrophil chemotaxis and degranulation; therefore, decreases the response of granulocytes and other inflammatory cells and consequently, decreases pain.

Colchicine overdose is a severe condition with a high mortality rate secondary to rapidly progressive multi-organ failure and sepsis. The ingested dose and arrival time to hospital play a critical role in the treatment and mortality due to the rapid absorption from gastrointestinal tract after ingestion.

Patients taking colchicine should be advised about early symptoms of intoxication and the severity of colchicine overdose in order to prevent the fatal outcome.

#590 - Case Report

SPONTANEOUS DISSECTION OF THE CELIAC TRUNK - CASE REPORT

Hilda Freitas¹, Natalia Oliveira¹, Antonio Cabral¹, Paulo Ferreira², Vanessa Machado², Cristina Ramalho²

¹ TrofaSaude Hospital Braga Sul, Braga, Portugal

² TrofaSaude Hospital Braga Centro, Braga, Portugal

Introduction

Spontaneous dissection of the celiac trunk is a very rare clinical entity, which can occur in adults (more men than women), aged 50-60 years or older. In general, the clinical picture is manifested by sudden Abdominal Pain in the epigastrium region, and an epigastric murmur is often heard. There may be weight loss without obvious explanation.

Case description

The authors describe a clinical case of 61 years old man, autonomous, with a medical history of diabetes, hypertension, sinusitis and smoking. 2 days before went to our Emergency Department he began generalized malaise and abdominal pain, followed by vomiting. He went to other Hospital where he performed exams, remained under surveillance and then had discharge. He maintained abdominal pain and so came to our hospital. Laboratory studies: platelets 27000, prolongation of APTT and TP. Abdominopelvic CT scan: "The celiac trunk with a slight increase in its dimensions, as well as the hepatic and splenic artery are visualized. The spleen shows a hypodense area compatible with an infarct. The hypothesis of arteritis is to be considered". He was hospitalized. Performed additional tests: brain and pulmonary computer tomography angiography,

Echocardiogram: without important changes. Infectious and autoimmune study negative. He started after blood samples and exams performed prednisolone. After the study made the hypothesis of arteritis seemed unlikely: MRI-angiography suggested as the most probable diagnosis: Dissection of the celiac trunk. He presented progressive improvement of platelets. He fulfilled 3 days of prednisolone. Indication for hypocoagulation, he started enoxaparin, later changed to warfarin. He has been accompanied in consultation of Internal Medicine, and is currently asymptomatic.

Discussion

Conditions that have been identified as causing arterial dissection include arterial hypertension, atherosclerosis, trauma, iatrogeny, pregnancy, syphilis, polyarteritis nodosa, fibromuscular dysplasia, cystic degeneration of the media and other congenital disorders of vessel walls. Other precipitating events can include mechanical stretching and microtraumas caused by effort or by rapid increases in intra-abdominal pressure. However, in the majority of cases of isolated spontaneous dissection of the celiac trunk the cause remains unknown. It should be included as a differential diagnosis hypothesis when patients present with acute epigastric abdominal pains.

#603 - Case Report

WHEN FEVER IS BACK

Monica Nechita Ferreira¹, Isabelle Vandernoot²

¹ CHU Brugmann; Internal Medicine Department, Bruxelles, Belgium

² CHU Erasme, Genetic Department, Bruxelles, Belgium

Introduction

Autoinflammatory diseases (AID) are characterized by a recurrent inflammation due to abnormality of innate immunity. The spectrum of AID is wide, a large number of genes being detected recently.

Case description

The authors present the clinical case of a woman of Moroccan origin, 35 y old, observed in consultation for recurrent fever.

Antecedents: unconfirmed suspicion of lupus at age 14; several episodes of lymphadenopathy from the age of 15 with a cervical biopsy that showed necrotic lymphadenitis interpreted as Kikuchi disease. Since many years, several hospitalizations per year for high fever, cervical adenopathies, abdominal pain, arthralgias and rash with a huge inflammatory syndrome. Infectious, neoplastic and autoimmune status was always negative as well as genetic test for Mediterranean Family Fever (2009).

In the anamnesis the patient explains that she had since the birth recurrent temperatures up to 39-39.5°C, persistent 4-7 days, every one or two month. The fever attacks are accompanied by abdominal and joints pain and lymphadenopathy palpated mainly in the neck. Family history non contributory.

Laboratory testing demonstrated: Inflammatory syndrome, polyclonal hypergammaglobulinemia of inflammatory origin,

hyper Ig A and Ig D; negative ANA and ANCA, no active urinary sediment, no amyloidosis. Normal ocular and neurological exams. Abdominal scan showed multiple para-aortic lymphadenopathy associated with moderate hepatosplenomegaly - stable image in the last years. PET Scanner with diffuse and thymic-reactive osteomedullary hypermetabolism.

Further genetic analysis revealed two Mevalonate kinase (MVK) mutations: c.794T> G mutation (P. Leu265Arg) and c.1129G> A mutation (p.Val377Ile), confirming MVK deficiency/ Hyperimmunoglobulin D syndrome ((MKD/HIDS). Start recently treatment with Canakinumab (anti IL1).

Discussion

The authors emphasize the necessity for a good anamnesis with elements such as age of onset, recurrency, duration of the crisis, clinical signs, family tree, all elements which suggest an AID and guide the request for genetic tests.

MKD/HIDS is a very rare AID (less than 200 cases described worldwide), with an autosomal recessive inheritance.

The responsible gene is the one that encodes the MVK. The mechanisms of inflammation in MKD/HIDS involve IL1 pathway and presently proposed treatments are based on inhibition of this pathway. The authors discuss the pathogenesis, diagnostic criteria and treatments of AID.

#633 - Abstract

UNDESIRABLE SURGERY IN PATIENTS WITH FAMILIAL MEDITERRANEAN FEVER (FMF). DATA FROM APULIA, ITALY AND A STRONG APPEAL FOR INTERNISTS

Leonilde Bonfrate¹, Giuseppe Scaccianoce², Anna Belfiore¹, Paolo Buonamico¹, Francesco Minerva¹, Vincenzo Ostilio Palmieri¹, Stefania Pugliese¹, Piero Portincasa¹

¹ Clinica Medica "A. Murri", Department of Biomedical Sciences and Human Oncology, University of Bari "Aldo Moro" Medical School, Bari, Italy

² Division of Gastrointestinal Endoscopy, "Umberto I" Hospital, Altamura, Italy

Background

FMF is a hereditary autosomal recessive autoinflammatory disorder caused by MEFV gene Chr 16p13.3 encoding the protein pyrin (marennostin), 781 amino acids and expressed predominantly in the cytoplasm in cells of myeloid lineage. We reported a novel cluster of Italian FMF patients (Bonfrate L. et al., Eur J Clin Invest 2017; 47: 622-9.), several with a prior surgical history.

Methods

49 FMF subjects (M:F=26:23, age 38 yrs ±2SE) originating from the Murgian area were observed for up to 8 years.

Results

Age at disease onset was 22.1 yrs±1.2SE (diagnostic delay

15.5 yrs±1.9 yrs); 82% of patients suffered from abdominal pain, and serum amyloid A was increased in 20% of patients. A prior abdominal surgery was recorded in 17/49 (35%) patients: appendectomy (65%), laparotomy (24%) and cholecystectomy (13%), without symptom improvement. The surgical group was older (43.3 yrs±4.4 yrs vs. 28.6±4.6 yrs, P=0.03), had greater International Severity Scoring System (ISSF) (3.5±0.4 vs. 2.5±0.2, P=0.02), and longer diagnostic delay (24.4±5.2 vs. 12.2 ±1.7 yrs, P<0.01) than the surgery-free group. The variant c.2080A>G (M694V, exon 10) was present in heterozygosity in 37% of surgical group (vs. 0% among the surgery-free group). In over 98% of patients, inflammation markers, duration and intensity of febrile painful attacks, quality of life and ISSF score improved dramatically following colchicine treatment (1mg/day, Acarperia Farmaceutici Srl, Italia). One FMF female avoided the emergency abdominal surgery, when surgeons were properly instructed.

Conclusion

Apulia and Basilicata regions express clusters of FMF patients. Poor awareness of FMF exposes the patients to the risk of undesirable surgery, post-surgical morbidity and complications. Educational programs are reducing the surgical burden of FMF.

#637 - Medical Image

PERIORBITARY MASS IN A 22 YEARS OLD MALE

Ricardo Taborda, Nuno Vieira E Brito, Paula Alcântara
Hospital de Santa Maria CHLN, Lisboa, Portugal

Clinical summary

A 22 years old male healthy male underwent bone body scan due to exercise related pubalgia which showed a captating lesion in the orbit. He had a familiar history of neoplasia with cancer in mother and grandmother before 50. There were no alterations in laboratory findings or in the physical exam as well as no symptoms. A CT scan and a MRI showed an inflated lesion of the right zygoma whose density was that of Fibrous displasia a rare genetic benign condition of the bone where osteofibrous tissue replaces normal bone marrow and whose diagnosis is normally and occasional find and whose prognosis is good.

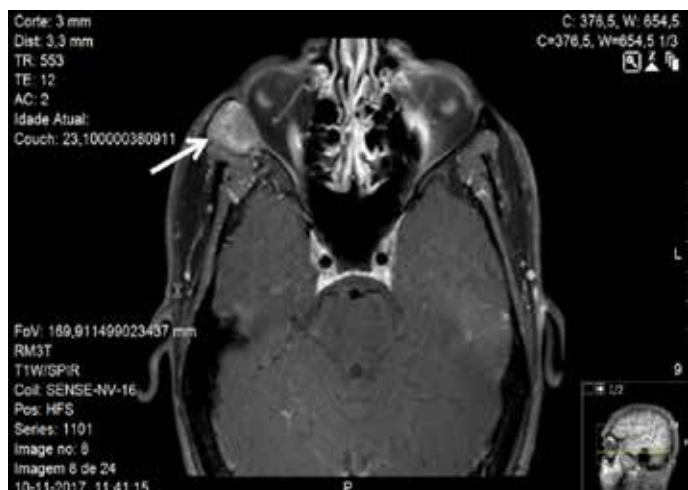

Figure #637.

#646 - Medical Image

SUPERIOR MESENTERIC ARTERY (SMA) SYNDROME OR WILKIE SYNDROME

Magdalena Martín Pérez, Isabel Ríos Holgado, Rocío Rojas Lorence

Hospital Punta de Europa, Algeciras, Cádiz, Spain

Clinical summary

A 43-year-old patient with abdominal pain, vomiting and weight loss lasting several weeks. Physical examination revealed cachexia, distention and increased abdominal sounds. The CT scan showed great gastric distension as well as obstruction of the third part of the duodenum by acute compression by the superior mesenteric artery (SMA) and the aorta, with an aortomesenteric angle of <20 degrees compatible with SMA Syndrome. It's a rare pathology whose incidence is not well known, ranging from 0'013 to 1% according to studies; Patients with an acute condition usually respond to conservative treatment (decompression, correction of hydroelectrolyte alterations, nutritional support); however, those with chronic symptoms usually require surgery, being the duodenojejunostomy the procedure of choice.

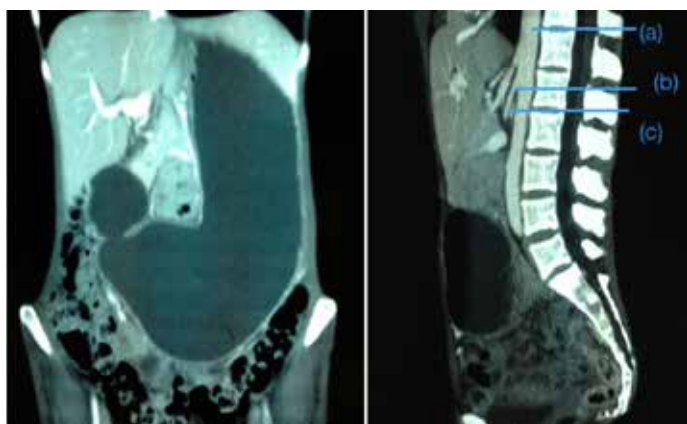


Figure #646. SMA syndrome. Left panel: frontal view. Right panel: a) Aorta, b) aortomesenteric angle, c) SMA.

#685 - Case Report

A CASE OF REFRACTORY ANEMIA AND EPISTAXIS: THE OSLER-WEBER-RENDU DISEASE

Joana Rua, Guilherme Assis, Daniela Viana, Rute Aleixo, Cristiana Pinto, António Trigo Faria, Paula Vaz Marques
CHTMAD, Vila Real, Portugal

Introduction

The Osler-Weber-Rendu Disease, also known as hereditary hemorrhagic telangiectasia, is a rare fibrovascular dysplasia, with dominant autosomal inheritance. The main manifestations are recurrent epistaxis and telangiectasia on the face, hands and oral cavity, associated or not to arteriovenous malformations in several organs. Those and a positive familiar history are the diagnostic criteria, requiring 3 out of 4 for a definitive diagnosis. It has a big spectrum of complications that can affect the hematologic, neurologic, pulmonary, dermatologic and/or gastrointestinal systems, so these patients can be misdiagnosed for a long-time. Treatment is mainly supportive and preventive.

Case description

The authors describe a case of a 76 years-old man with an history of hepatic cirrhosis, refractory anemia and recurrent epistaxis, needing several blood transfusions over the past few years, who came to the emergency room with complaints of non-productive cough and fever, associated with two syncope episodes in the last two weeks. Familiar background included a daughter with Osler-Weber-Rendu Disease. Physical examination showed telangiectasia on the face and buccal mucosa, hypotension, wheezing on the pulmonary auscultation and hypoxemia. The chest x-ray was normal and blood tests revealed severe anemia, altered liver function and elevated inflammatory parameters. He was admitted with the diagnosis of an upper respiratory infection and to investigate the anemia and epistaxis's etiology. The investigation revealed a severe iron deficiency anemia and angiodysplasia of the fundus and body on the upper digestive endoscopy. The brain and pulmonary-CT and the abdominal-MRI showed no arteriovenous malformations. The patient completed the antibiotic course, started intravenous iron and was discharged after an asymptomatic period with a stable hemoglobin value and no signs of bleeding.

Discussion

Although it is a rare disease, it should be a part of the differential diagnosis of refractory anemia and epistaxis, especially if there is a positive family history, even if other causes of bleeding are present. Diagnosis is important to exclude major manifestations, like arteriovenous malformations which can result in life-threatening clinical situations. Early supportive treatment gives more life-quality to these patients and can avoid the referred complications.

#696 - Case Report

ACUTE DISSEMINATED ENCEPHALOMYELITIS (ADEM) RELATED TO CMV INFECTION IN A PRIMARY CARE HOSPITAL

Rafael Carlos Da Silva¹, Carolina Kamer¹, Lais Ferreira Farias¹, Josie Budag Matsuda¹, Daniel Ribas Dos Santos²

¹ Centro Universitário para o Desenvolvimento do Alto Vale do Itajaí, Rio Do Sul, Brazil

² Unidade de Terapia Intensiva - Hospital Bom Jesus, Ituporanga, Brazil

Introduction

Acute disseminated encephalomyelitis (ADEM) is an inflammatory demyelinating disease of the central nervous system (ADEM). It is characterized by monophasic clinical course. ADEM related to CMV is a rare condition with only few cases reported. We describe a case of severe ADEM following CMV infections in a young patient with favorable outcome following standard treatment.

Case description

A young female 17 years old presented to us with history of dull low back pain in the course of 1 week followed for fatigue and rapidly progressive tetraparesis followed by coma. There was no history of fever. Assisted ventilatory support and intensive care admission was demanded. There was no prior medical condition, neither recent vaccination history. Physic examination demonstrated a comatose young female, with vital signs within normal limits. The pupils were myotic and reactive to the light, Babinski sign was present bilaterally and pyramidal liberation was noticed in inferior extremities. Nuchal rigidity present. CT - head and CSF analysis were performed and broad-spectrum antibiotics plus acyclovir were empirically started. Serology were negative for human immunodeficiency virus, viral hepatitis and rubella. However, IgG for CMV demonstrated high titles with IgM reagent as well. CSF was colorless with 426 white cells/ μ L, 65% lymphocytes, 62 mg/dL CSF protein, 95 mg/dL glucose and 16 mg/dl lactate. CSF PCR for herpes virus negative. CT scan has shown diffuse hypodensities areas symmetrically distributed in both hemispheres, brainstem and cerebellar peduncles. As she was at a primary care hospital, MRI was not available. ADEM was considered and pulse methylprednisolone (15 mg/kg/day) for 5 days was initiated. In the 3rd of treatment the patient presented signs of neurologic improvement with recovery of consciousness. The patient was discharged with no motor deficits.

Discussion

ADEM usually follows either a vaccination within the preceding four weeks, or an infection which may be a childhood exanthema. It is important to distinguish ADEM from acute infectious encephalitis. Considering that most common cause of viral encephalomyelitis is due to herpes virus and PCR was negative we excluded this diagnostic. Furthermore, CMV infection in immunocompetent adults are most part of the times subclinical or either self-limited. However, despite of rarity, CMV can be associated with ADEM. Early diagnosis is important as therapeutic response may depend on timing. The outcome is frequently favorable.

#710 - Abstract

GLUCOSE HOMEOSTASIS AND INSULIN RESISTANCE IN ACUTE INTERMITTENT PORPHYRIA

Isabel Solares¹, Laura Izquierdo-Sanchez², Montserrat Morales¹, Francisco Javier Castelbon¹, Daniel Jerico², Karol Marcela Cordoba², Pedro Berraondo², Rafael Enriquez De Salamanca¹, Antonio Fontanellas²

¹ Hospital 12 de Octubre, Madrid, Spain

² CIMA Universidad de Navarra, Pamplona, Spain

Background

Glucose homeostasis is poorly understood in hepatic porphyrias. Early studies reported an association between insulin resistance (IR) and acute intermittent porphyria (AIP). Since carbohydrate loading has a repressing effect on the enzyme δ -aminolevulinatase synthase 1 (ALAS1) induction, the existence of IR could affect the protective effect of glucose during the acute attack of porphyria. Our aim is to evaluate IR in patients with AIP. Given that hepatic PBGD deficiency was associated with a delayed glucose tolerance test (GTT) in AIP mice, we performed a transcriptional analysis of genes involved in the regulation of hepatic heme biosynthesis in response to glucose and insulin during an acute attack in AIP mice.

Methods

We included AIP patients followed in the Hospital 12 de Octubre from August/2018 to March/2019. AIP diagnosis was based on biochemical criteria and Porphyrinogen Deaminase (PBGD) gene sequencing. Patients were classified as asymptomatic carriers (AC), prolonged remission (PR), or recent attack (RA) if last crisis developed in a period greater or less than 3 years, respectively. IR was estimated by homeostasis model assessment (HOMA) and compared to age-matched healthy controls (HC). IR was considered if HOMA>3.4. In AIP mice, transcriptional analysis of ALAS1, PGC-1a and pAkt was performed during fasting, and in response to glucose and insulin (commercial or a new conjugated insulin).

Results

In the clinical setting, we included 22 AIP patients: 4 AC, 13 PR and 5 RA. Five of them showed IR; 3 were PR and 2 AC. No subject in the HC group (N=20) had IR. Significant differences were found between AIP patients and HC (p=0.04). Glucose loading in AIP mice induced a decrease in PGC1 expression but gene transcription of ALAS1 remained unchanged. Co-administration of glucose and commercial insulin facilitated a more rapid normalization of hepatic ALAS1 expression. However, commercial insulin generated hypoglycemia, resulting in glucagon liberation and ALAS1 up-regulation. Conjugated insulin facilitated hepatic glucose uptake and faster normalization of hepatic ALAS1 expression by activating pAkt and reducing the transcription levels of PGC-1. ALAS1 repression induced by conjugated insulin was evidenced by significant reduction in the urinary excretion of neurotoxic heme precursors.

Conclusion

AIP patients showed a significant higher rate of IR compared to HC. In AIP mice, administration of conjugated-insulin can increase efficacy of glucose loading and protect from acute attack

#914 - Case Report

TAFRO SYNDROME IN OTHER THAN IDIOPATHIC MULTICENTRIC CASTLEMAN'S DISEASE: IS IT POSSIBLE?

Maria Cynthia Fuentes-Lacouture¹, Carmen Cecilia Gomez¹, Iván Noreña¹, Martha Romero², Julián Alberto Naranjo-Millán²

¹ Fundación Cardioinfantil, Bogotá D.c, Colombia

² Fundación Santa Fe de Bogotá, Bogotá D.c, Colombia

Introduction

TAFRO syndrome has been almost exclusively associated to idiopathic multicentric Castleman's disease (MCD). However, some cases have been also described about its possible association with other entities. We present the case of a young male with HIV diagnosis and HHV-8 positive MCD who met criteria for the diagnosis of TAFRO syndrome.

Case description

A 28-year-old male patient with a recent diagnosis of HIV was admitted to the hospital because of a 1-month history of asthenia and adynamia. Initial workup showed anemia and thrombocytopenia. HIV viral load was 1.127.195 copies/ml, and CD4 count by flow cytometry was 144 cells/mm³. Physical examination revealed fever, lymphadenopathy and hepatosplenomegaly. Additional tests for *Histoplasma sp*, *Cryptococcus sp*, Hepatitis B and C, Epstein Barr Virus and Cytomegalovirus were all negative. Cervical lymph node biopsy was performed and a final diagnosis of Human Herpes Virus – 8 (HHV-8) MCD was made. Treatment with rituximab 375 mg/m² was started. The patient persisted with nocturnal diaphoresis, asthenia, adynamia, anasarca and fever with a temperature of 39.3°C. Additional workup showed hemoglobin at 6.15 gr/dL, 38,500/mm³ platelets, erythrocyte sedimentation rate 45, albumin 2 gr/dL and hepatosplenomegaly demonstrated by CT. Despite HHV-8 positivity, TAFRO syndrome was suspected. Treatment with rituximab was continued, but with poor response and progressive deterioration, the patient died 4 months after diagnosis.

Discussion

MCD is a lymphoproliferative etiologically classified as HHV-8 positive or idiopathic, according to its co-infection with this virus. Over time, some patients with idiopathic variant presented with an aggressive spectrum of the disease, with the presence of cytopenia, anasarca, fever, bone marrow fibrosis and organomegaly, naming it as TAFRO syndrome according to its manifestations. Characteristically, patients positive for HHV-8 and Epstein Barr virus are excluded from this syndrome. However, several cases have been reported in the medical

literature interrogating the possible co-existence of TAFRO syndrome in other neoplastic or autoimmune entities, sharing the pathophysiology characterized by the presence of higher levels of IL-6, VEGF, and NK lymphocytes. Finally, we believe in the coexistence of TAFRO syndrome in all MCD patients, regardless of HHV-8 state. We present the case of a patient with HIV and MCD, who met all diagnostic criteria for TAFRO syndrome, despite being HHV-8 positive.

#931 - Abstract

THROMBOTIC MICROANGIOPATHIES IN A TERTIARY CARE HOSPITAL

Inês Albuquerque¹, Ana Monteiro¹, Iolanda Vieira², Inês Nogueira Costa¹, Jorge Almeida¹

¹ Centro Hospitalar de São João, Porto, Portugal

² Instituto Português de Oncologia do Porto, Porto, Portugal

Background

The differential diagnosis of thrombotic microangiopathies (TMA) is vast and clinical challenge. Thrombotic thrombocytopenic purpura (TTP) is of special concern, given the dismal prognosis if therapy with plasma exchange (PEX) is not started promptly. We report a series of cases of TMA

Methods

We reviewed patients admitted to the hospital for microangiopathic anemia from January 2013 to December 2017. Twenty six patients were identified. Eight patients were excluded because of the absence of thrombocytopenia; a positive direct coombs test; or previous diagnosis of prosthetic cardiac valve dysfunction and hypersplenism. The remaining eighteen cases were analyzed.

Results

Among the eighteen TMA cases, seven were female (38,9%) and the mean age was 55.6 (min 21 – max 81) years.

Eight patients were diagnosed with TTP; two patients had microangiopathy due to prosthetic cardiac valve dysfunction; two TMA were paraneoplastic; two patients had TMA due to malignant hypertension; one patient had hemolytic uremic syndrome; one patient had disseminated intravascular coagulation; one patient had vasculitis; and one patient's TMA was provoked by tacrolimus-associated toxicity.

TTP patients had a mean age of 49.3 years. None presented with the classic pentad: five patients had neurologic manifestations, three (35.7%) had mild renal impairment, two patients had gastrointestinal symptoms; none had fever. Mean hemoglobin was 7.3 g/dL and mean platelet count was 24x10⁹/L. In three patients, ADAMTS13 activity was not measured; the other five patients had non-measurable ADAMTS13 activity and in three of those an inhibitor was identified. Only one patient (12.5%) died. The remaining seven initiated PEX and corticoid therapy promptly; four patients needed rituximab for resistance to PEX or recurrence of TTP.

The ten patients with alternative diagnosis had a mean age of 60.7 years; mean hemoglobin was 8.0 g/dL and mean platelet count $101 \times 10^9/L$; six (60%) had renal dysfunction; and four patients (40%) died. In three of these patients, PEX was initiated.

Conclusion

Clinical distinction between causes of TMA is seemingly impossible. There are also no rapid tests that can confirm or deny TTP and help the decision making process of starting or withdrawing PEX. This case series however, is in line with two features that have already been described in the literature: TTP patients more commonly present without kidney impairment and have lower platelet counts.

#934 - Case Report

ACUTE BUDD CHIARI SYNDROME IN WOMEN WHO HAS JUST GIVEN BIRTH WITH ESSENTIAL THROMBOCYTHEMIA

Rafaela Mamfrim, Amanda Saavedra, Rafael Neder, Thaisy Secco, Luiza Flores, Bianca Feldman, Thales Rizzi, Victor Bemfica
Hospital Municipal Miguel Couto, Rio De Janeiro, Brazil

Introduction

Budd-Chiari Syndrome (BCS) is defined as hepatic venous outflow tract obstruction. It is associated with an underlying cause in over 80% of the cases and frequently, more than one thrombotic risk factor is present 50% may be due to an underlying chronic myeloproliferative disorder and 20% occur in women who have been on oral contraceptives, are pregnant or have just given birth.

Case description

A 32 year old woman with history of 1 previous spontaneous abortion was admitted at the hospital due to abdominal pain, ascites, jaundice and lower edema status post a surgically drained lower abdominal wall hematoma, developed 24 days after a caesarian section.

An abdominal doppler ultrasound demonstrated a severe hepatosplenomegaly and inferior vena cava thrombosis, compatible with BCS. Upper gastrointestinal endoscopy showed esophageal varices with no signs of bleeding.

At that time, patient was discharged home with warfarin. Although systemic anticoagulation was prescribed, patient developed venous thromboembolism. She was readmitted for supportive treatment and subcutaneous anticoagulation. After clinical stabilization, the patient was discharged home again with warfarin.

One month later, she presented with variceal hemorrhage. Warfarin was suspended and she was submitted to variceal band ligation. After 10 days without anticoagulation, the patient's general condition declined. She developed acute kidney failure requiring hemodialysis, her ascites worsened and abdominal doppler ultrasound showed extension of thrombosis.

Patient maintained splenomegaly and a high count of platelets suggesting a myeloproliferative disorder. Bone marrow biopsy

was performed and showed a high count of megakaryocytes. Besides, JAK2 mutation was positive, confirming essential thrombocythemia (ET).

Despite treatment, patient developed chronic liver disease with signs of portal hypertension and needed hemodialysis. Patient is still hospitalized and receiving supportive treatment.

Discussion

BCS is associated with hypercoagulopathic disorders just as pregnancy and myeloproliferative syndromes as essential thrombocythemia (ET), which is extremely rare with a high morbimortality.

ET has thromboembolic and hemorrhagic complications due to elevated platelet count and a JAK2 mutation is present in almost 50% of patients.

The potential gravity of the syndrome shows the importance of early diagnosis to define the therapeutic approach and optimize the outcome.

#942 - Medical Image

THE STRANGE CONTENTS OF AN ABDOMINAL HERNIA

Rita Varudo, Rosa Alves, Tiago Judas
Garcia de Orta Hospital, Almada, Portugal

Clinical summary

We present a case of a 60-year-old woman with multiple medical comorbidities including grade III obesity, underwent cholecystectomy by Kocher's laparotomy with development of incisional hernia. The patient was admitted to the emergency department with dyspnoea, easy fatigue and fever. The initial clinical examination revealed a very painful abdomen to the palpation, with incisional hernia in the right lateral wall without signs of peritoneal irritation. A computed tomography scan performed showed a large hernia with a 15 cm diameter neck, consisting of small intestine loops, colon, hepatic and pancreatic segments, right kidney, peritoneal and retroperitoneal fat. She was hospitalized due to urosepsis and started antibiotic therapy with clinical and analytical improvement.

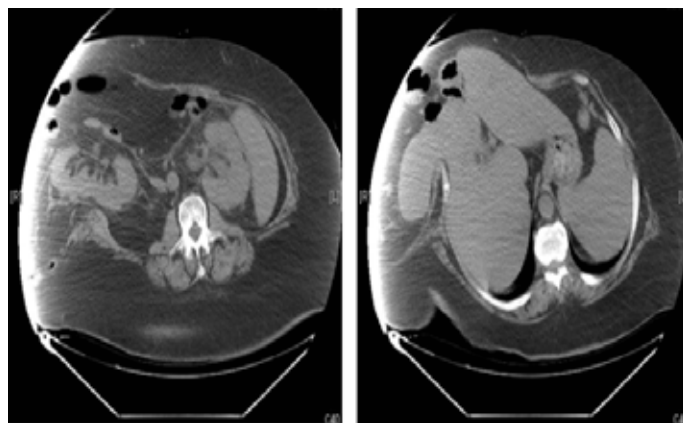


Figure #942. Incisional hernia.

#945 - Case Report

EARLY ONSET, BUT LATE DIAGNOSIS OF A RARE DISEASE

Pamela Farah, Pascale Daniel, Aline Tohme
Saint Joseph University, Beirut, Lebanon

Introduction

Gaucher disease (GD), the most common sphingolipidosis, remains rare. We present the case of a patient diagnosed of Gaucher disease at the age of 56 years old.

Case description

The patient was born in 1962 from consanguineous parents, non Jewish. She presented to the emergency department in August 2018, for extreme pain on her right hip. Her medical record consisted of splenectomy at 9 years old secondary to splenomegaly without further investigation, recurrent infections in the upper respiratory system, recurrent tonsillitis, anemia attributed to gynecological loss, spinal compression fracture at L2 treated with percutaneous cementoplasty in 2014. Her sister was diagnosed with Gaucher disease at the age of ten years old, and she died from the disease's complications at the age of 45.

Upon admission, the blood test exams showed the following: Hb 11.5 g/dL, MCV 95 fl, white blood cells 8200/mm³, platelets 261000/mm³, ferritin 2654 ng/mL, normal liver function tests, and normal creatinine clearance. MRI of the right hip was suggestive of osteonecrosis of the right femoral head, and a very important edema of the adjacent soft parts, interesting the muscles ilio-psoas, glutes, adductors and external obturators on the right side. The patient was suspected to have Gaucher disease. In order to confirm the diagnosis, the dosage of the lysosomal enzymes from dried blood, and the molecular genetic testing were performed. The first exam showed that the activity of beta-glucosidase was below its reference range (24.06 pmol/spot*20h), with an elevated concentration of glucosylsphingosine, and the latter exam showed a homozygous mutation of p.V414G which is similar to the known missense mutation p.V414. The patient was operated in January 2019 with total right hip replacement and was treated, since November 2018, with intra-venous Imiglucerase (60 UI per kilogram) each 2 weeks. Moreover, she presented a new compression fracture on D12, confirmed with lumbar MRI, on March 2019.

Discussion

It is important to include Gaucher disease in the diagnostic decision tree in cases of splenomegaly in order to avoid potentially harmful splenectomy. Almost all GD patients develop skeletal complications. Pathological damage such as osteonecrosis, bone infarcts and fracture, once it has occurred, is irreversible. Thereby, total hip replacement in patients with Gaucher's disease with symptomatic osteonecrosis of the femoral head is advised despite the low risk of early failure due to aseptic loosening.

#957 - Case Report

BARDET-BIEDL SYNDROME, A LATE DIAGNOSIS

Marta Matos Pereira¹, Joana Serôdio¹, Manuel Barbosa¹, Elsa Araújo¹, Miguel Morgado², Selmira Faraldo¹

¹ Serviço de Medicina 2, Hospital Conde de Bertiandos, ULSAM, EPE, Ponte De Lima, Portugal

² Departamento de Medicina Crítica, ULSAM, EPE, Viana Do Castelo, Portugal

Introduction

Bardet-Biedl Syndrome is a rare autosomal recessive genetic disease with multisystemic involvement characterized by retinal dystrophy, obesity, cognitive impairment, kidney disease, polydactyly and hypogonadism. Timely diagnosis made upon clinical characteristics usually present at late childhood it's of major importance because of its impact on management and prognosis.

Case description

A 58 year-old woman was sent to Internal Medicine office visit after being diagnosed with Chronic Kidney Disease following an episode of acute cholangitis. She had previous history of hypertension, cognitive impairment and bilateral blindness since childhood.

On physical exam, she had bilateral blindness, polydactyly (12 hand-fingers), retrognathism and central obesity (BMI of 35.38kg/m²). Blood tests showed impaired renal function (urea 67mg/dL, creatinine 1.64 mg/dL, with estimated glomerular filtration rate of 34.1 mL/min/1.73m²) with stage G3b CKD and hypercholesterolemia (total cholesterol 211mg/dL, LDL-cholesterol 147mg/dL), with normal glycemic profile, hepatic function and urine analysis. Kidney ultrasound revealed renal asymmetry and mild bilateral ectasia, confirmed on CT-scan. She also performed renogram scan, ruling out renal obstruction. EKG and echocardiogram showed no abnormalities.

Based on referred clinical findings and despite its late presentation on late adulthood, the hypothesis of Bardet-Biedl syndrome was assumed and the patient started anti-hypertensive and lipid-lowering therapy. She was referred to outpatient appointments with both Nephrology and Ophthalmology for follow-up.

Discussion

Regardless of its rarity, Bardet-Biedl syndrome can be detected only by clinical features which usually evolve during childhood but are fully present in early adulthood. Early recognition, usually on pediatric ages, and diagnosis reduces morbidity and helps preventing complications in these patients.

In this case, despite patient's older age, polydactyly and CKD in association with past history of obesity, hypertension, blindness and cognitive impairment led to diagnosis, with clinical improvement after optimized therapy.

#964 - Medical Image

PENILE NECROSIS IN A DIABETIC

Grace Staring¹, Isabel Borges², Rita Mendes³, Mafalda Carvalheiro⁴, Paulo Leal Filipe³

¹ Centro Hospitalar do Oeste - Unidade de Torres Vedras, Torres Vedras, Portugal

² Hospital do Divino Espírito Santo de Ponta Delgada, Ponta Delgada, São Miguel - Açores, Portugal

³ Centro Hospitalar Lisboa Norte - Hospital Santa Maria, Lisboa, Portugal

⁴ USF Ericeira, Ericeira, Portugal

Clinical summary

The clinical images belong to a 74-year-old diabetic patient without good blood sugar control who suffered from various diabetic complications. Hemodialysis was carried out for 2 years for end stage renal failure (ESRF). Due to lower extremity ulcerations and severe neuropathy, he had been submitted to bilateral under-the-knee amputation 2 months prior to his admittance in the emergency room (ER). He complained of a painless, darkened penile glans with 1 month evolution. Blood tests indicated normal calcium levels and borderline high inflammatory markers. Biopsies revealed dry penile necrosis. Male genitalia necrosis is rare but associated with high morbidity and mortality. This case is presented because it is a striking example of the end organ effects of diabetes and associated vascular disease.

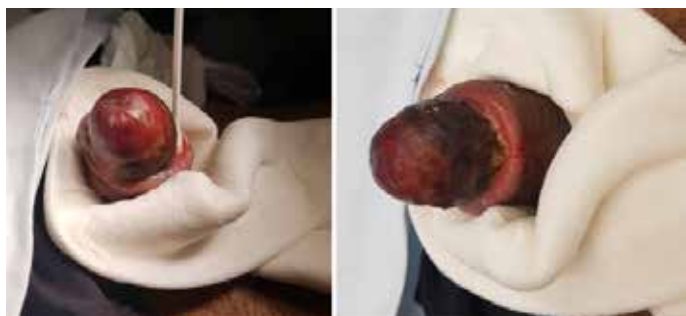

Figure #964. Penile necrosis.

#1000 - Case Report

ACQUIRED FAMILIAL AMYLOID POLYNEUROPATHY: A UNIQUE CAUSE OF IATROGENIC

Marli Cruz¹, Paula Marques Ferreira², Judit Gandara³, Vítor Lopes³, Jorge Daniel³, Helena Pesseguero³, Sofia Ferreira³

¹ Hospital da Luz Arrábida, Vila Nova De Gaia, Portugal

² Centro Hospitalar de Vila Nova de Gaia, Vila Nova De Gaia, Portugal

³ Centro Hospitalar do Porto, Porto, Portugal

Introduction

Acquired familial amyloid polyneuropathy (FAP) occurs in patients who underwent a sequential liver transplantation (SLT), in which the liver from a FAP patient is removed and transplanted into another recipient. Liver retransplantation appears like a possible treatment to minimize the progression of symptoms.

Case description

We report 2 cases of acquired FAP after SLT, their evolution and treatment.

A 59-year-old male, who underwent SLT in 2003 for HCV cirrhosis, refers, in 2011, paresthesia in the feet, which progressively worsened over the following two years, up the knees with tactile and vibratory hypoesthesia up to that level, autonomic dysfunction (urinary urgency) but without motor deficits. Neurophysiological study showed small fibers neuropathy of the lower limbs and an abnormal heart rate response to deep breathing (HRDB) suggesting a parasympathetic cardiovagal dysfunction. Salivary gland biopsy revealed amyloid substance (transthyretin - TTR) deposits - grade 3. In 2013, he was submitted to liver retransplantation. After that, he experienced improvement of the sensory neuropathy and stability in the autonomic impairment but he developed motor neuropathy (reduced feet flexion and dorsiflexion - grade 3/5).

The second case reports a 65-year-old male who underwent SLT for HBV cirrhosis, in 2002. About 7 years after transplantation, he developed distal paresthesia (feet) - with progression up to hypoesthesia - autonomic dysfunction (gastroparesis and constipation), without motor deficits. The neurophysiological study revealed small fiber neuropathy at the level of the left foot. Salivary gland biopsy showed amyloid (TTR) deposits - grade 2. After the liver retransplantation in 2010, we observed an improvement of the sensory neuropathy and stability of dysautonomia.

Discussion

The period until the onset of symptoms in acquired FAP is relatively short - in the 2 cases described less than a decade - but with similar symptoms when compared to those with the hereditary pattern of the disease. Liver retransplantation appears as a treatment option. In order to optimize the approach of patients with acquired FAP, it would be important to understand their natural history better, so as to enable the ideal selection and timing for retransplantation.

#1078 - Case Report

CHOREA AND HEMIPARESIS ASSOCIATED WITH HYPERGLYCAEMIA

Ana Sofia Costa Matos, João Pedro Pais, Miguel Romano, Francisca Cardoso, Marta Andrade, Ana Nascimento

Unidade Local de Saúde do Alto Minho, Viana Do Castelo, Portugal

Introduction

Diabetes mellitus, especially when not controlled, can lead to several neurological complications being involuntary movements and focal neurological signs the rarest presentations.

Case description

We present a case of a 90-year-old female with a history of diabetes mellitus referred to the emergency department for polydipsia, dysuria and decreased strength of the upper limbs with a weeklong. Physical examination highlighted prostration

and dehydration with dry mouth and sunken eyes. Analytical study presented changes compatible with an urinary infection (active urinary sediment, leucocytosis and elevation of C-reactive protein), as well as hyperglycaemic hyperosmolar state (glycaemia 697 mg/dl, calculated osmolality 308 mmol/L, pH 7.43, HCO 3-25, absence of ketonuria), and acute kidney injury (Cr 2.2 mg/dl). On the second day of hospitalization, the patient presented tonic-clonic movements of the left limbs and right hemiparesis. The left-sided movements were interpreted as a seizure, however without response to antiepileptic drugs, and it was not possible to identify a recent ischemic lesion on computed tomography or brain magnetic resonance imaging that supported an acute cerebral accident. A more detailed evaluation of the patient allowed characterization of the movements of the upper limbs as chorea movements. The referred brain imaging exams showed bilateral hyperdensity of the caudate nucleus and putamen, supporting the hypothesis of chorea secondary to hyperglycaemic hyperosmolar state. During inward stay, along with better glycaemic control, the chorea movements resolved and a significant improvement of right hemiparesis was observed, corroborating the hypothesis that these neurological alterations were secondary to metabolic decompensation.

Discussion

Movement disorders related with hyperglycaemia may present in the form of chorea or ballismus. Nonketotic hyperglycaemic chorea is a rare clinical syndrome with predominance in the female sex and average age of 71 years. Typically observed in patients with a blood glucose value of 400-1000 mg/dl and regression of involuntary movements is common after regulation of hyperglycaemia. While cranial CT imaging can be normal, hyperdense lesions in the basal ganglion region is typically observed in some patients. On cranial MR, hyperintense lesions are observed in the putamen and caudate nucleus especially in the T1 sequence. Despite the focal nature, these manifestations often reverse completely after correction of the metabolic disorder

#1088 - Case Report

SITUS VISCERUS INVERSUS: A VARIANT OF NORM OR PATHOLOGY?

Natalya Volkova, Ilya Davidenko, Alexey Harlamov, Anastasia Shevchenko, Anastasia Chernova
Rostov State Medical University, Rostov-On-Don, Russia

Introduction

Situs viscerus inversus - mirror-image reversal of organs, resulting from abnormal embryogenesis. Situs inversus is present in 0.01% of the population. Normal embryogenesis involves rotation of thoracic and abdominal organs to the right side, but rotation to the left side occurs in case of situs viscerus inversus. Situs inversus can be classified as incomplete, when only thoracic or only abdominal organs are transposed (heart, blood vessels, lungs etc). The prognosis for this type of anomaly is unfavorable: only

5-13% of people with this anomaly live more than 5 years. When all organs are transposed it is situs viscerus inversus totalis, that is not associated with the pathology of the organs and the prognosis for patients is favorable.

Case description

A 59 years old woman, reported to therapeutic department with decompensated type 2 diabetes mellitus. At the age of 7 years old, in connection with complaints of discomfort and pain in the heart region, the patient was recommended to undergo an ECG, during which dextrocardia was suspected and confirmed. Despite of this anomaly and potential of mirror-image reversal of other organs, no other organs were examined for inversion at that time. Subsequently, woman visited doctors for various reasons, including pregnancy, but anamnesis of the detected dextrocardia did not affect the examination plan, as well as the process of the patient's diseases. At the age of 35, there were difficulties during fibrogastroduodenoscopy procedure due to the patient's right-sided disposition of the stomach. Later, at the age of 42, the patient was diagnosed with type 2 diabetes mellitus, which until now has a typical course, compensation is achieved on the diet therapy and drugs. Since 45 years old woman has having essential hypertension under the treatment of antihypertensive drugs. There was also no difficulty in performing panhysterectomy for uteri fibroids. Thus, the patient found out situs viscerus inversus totalis, it has not influence on the course of her diseases and the prognosis of life.

Discussion

Firstly, it's necessary to conduct further examinations to determine the location of other organs and clarify the type of inversion if the patient has an abnormally located organ. And, secondly, it is necessary to keep in mind some features of various manipulations and surgical interventions related to the topography of the organs in patients with organ inversion.

#1167 - Case Report

AN UNKNOWN CAUSE OF ASCITES

Teresa Salero, Rui Osório, Ramiro Sá Lopes, Sérgio Menezes Pina, Catarina Mendonça, António Veiga Moura
Centro Hospitalar Universitário do Algarve - Faro, Faro, Portugal

Introduction

Retroperitoneal fibrosis is a rare condition in which fibrous tissue replaces retroperitoneal fat. It is usually secondary to a chronic inflammatory process of the retroperitoneum and may evolve to urethral compression.

Case description

A 69-year-old female, with Parkinson's Disease, heart failure and hypothyroidism, medicated with carbidopa/levodopa, dihydroergocriptine, rasagiline, levotiroxine, clonazepam, enalapril, spironolactone and furosemide.

Admitted at an Internal Medicine ward for complementary study of asthenia, 15% weight loss, abdominal perimeter enlargement and lower limb oedema, over the past 6 weeks. Sustained apyrexia and without other relevant complaints.

Blood work revealed normocytic normochromic anaemia, acute renal lesion and hypothyroidism, without inflammatory levels elevation. Tumour markers with 10fold elevation of CA 125 and negativity for blood and urine cultures, tuberculin skin test, IgG4 and other serology tests as well as autoimmunity.

Abdominal ultrasound showed bilateral pleural effusion (mainly at left), large non pure ascites and marked bilateral hydronephrosis, unable to exclude an obstructive cause. These aspects were confirmed by a computed tomography (CT) of neck, chest, abdomen and pelvis with contrast, which also referred to an apparent thickened and hyperintense pelvic wall.

Pelvic magnetic resonance for further study excluded suspected malignant lesions at the ovaries and also described a thickened area at pre-sacral fat, about 1.5cm wide and hypointensity at T1 and T2, suggesting fibrosis.

Enrolled a diagnostic and therapeutic paracentesis, revealing a proteinic material in cytology exam, with moderate quantity of mature mesothelial cells.

Gynaecologic exam excluded significant changes. Upper digestive endoscopy revealed chronic gastritis and positivity for *Helicobacter pylori*.

Finally, performed a diagnostic laparoscopy where hepatic tissue showed slight chronic inflammatory infiltrate at portal spaces, without periportal necrosis; fibrosis and unspecific inflammatory infiltrate at abdominal wall biopsies and without malignancy process.

Hence, assumed a retroperitoneal fibrosis, probably iatrogenic to the ergotamine derivate. After di-hydroergotamine withdrawal, patient presented a fibrosis reduction (confirmed by control CT scan) and normalized renal function.

Discussion

This case report entails an alert for the complex diagnosis of this condition, which lack of treatment may lead to terminal kidney disease.

#1189 - Case Report

DON'T BE COCCI : AN AILING HEART AS A SEQUELAE TO AN UNHEALTHY LIVER.

Rahul Shashikant Pansare, Hiba Khan, Maria Sturla

St. Mary Mercy Hospital, Livonia, United States

Introduction

Streptococcus infantarius subsp. *infantarius* (*S.infantarius*), formerly *streptococcus bovis* biotype II.1, has been recovered from traditionally fermented dairy and plant products. We report a case where we stumbled upon *S.infantarius* bacteremia and native aortic valve endocarditis.

Case description

A 66-year-old Caucasian gentleman present to the ED due to acute lower back pain. He had never seen a doctor in 10 years. Past medical history was significant for morbid obesity (445 lbs). Physical examination was negative for back tenderness. Vital signs were positive for hypoxia on room air. Labs were significant for AST 45, ALT 25, total bilirubin 2.2. CT spine showed lumbar spondylosis. CT chest angiography ruled out PE but showed liver cirrhosis which was confirmed by liver ultrasound which further showed changes suggestive of non-alcoholic fatty liver disease. BNP was normal. Echo showed EF of 63% and severe pulmonary artery hypertension (PAH). Patient later developed multiple febrile episodes of upto 103.4 F which necessitated blood cultures and antibiotics. CT abdomen ruled out occult abscess but showed portal vein hypertension. Blood cultures grew *S.infantarius*. Colonoscopy to rule out malignancy and MRI spine to rule out osteomyelitis could not be performed due to ongoing back pain and weight constraints. TEE revealed a 1.17cm aortic valve vegetation. Cardiology recommended conservative management. Patient was discharged with a 4 week antibiotic course after which his back pain resolved.

Discussion

S. infantarius is a Group D. Streptococci (GDS) and is a rare cause of native valve endocarditis in the USA. Liver cirrhosis has been associated with *S.infantarius* bacteremia possibly due to compromised reticuloendothelial system or portosystemic shunting of bacteria due to portal hypertension thus bypassing the liver. This mandates workup with TEE to rule out endocarditis and colonoscopy to rule out colon cancer. It is important to recognize that GDS is not a homogenous group of bacteria and demonstrate variable pathogenicity. *S.infantarius*, in fact, appears to be associated with biliary tract infection and non-bowel digestive cancers reported via sparse case series. Of note, in a report of 30 cases of GDS endocarditis, all 23% who had imaging evidence of spine involvement had presented with signs and symptoms of discitis which could not be ruled out in our patient.

#1193 - Medical Image

LAMOTRIGINE-INDUCED STEVENS-JOHNSON SYNDROME

María Gloria Rojano Rivero, María Elena Mansilla Rodríguez, Marta Sáenz De Tejada López, Elena Sánchez Ruiz Granados, Jose Manuel Arrabal Díaz

Hospital Infanta Elena, Huelva, Spain

Clinical summary

A 44 year-old-woman treated for years with alprazolam, mirtazapine, lamotrigine and lorazepam for an anxiety-depressive disorder, was hospitalized for developing ulcerative painful skin lesions, affecting oral and genital mucosa, and non-painful erythematous lesions in trunk, palms, soles and extremities, more extensive in photoexposed areas, with no fever or pruritus.

Complete blood tests and an abdominal ultrasound were run, with any relevant findings.

Due to the symptoms and the tests results, it was firmly suspected to be a drug-induced Stevens-Johnson syndrome, more probably caused by lamotrigine. The medication was stopped and it was added corticosteroids along with other maintenance measures, with a practically total clinical remission in 2 weeks.

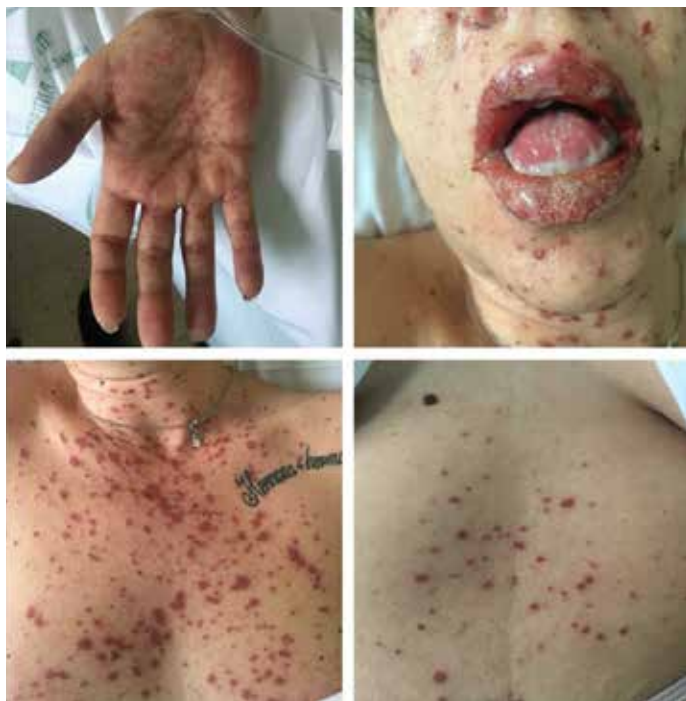

Figure #1193.

#1210 - Case Report

RECOGNIZING THE CLINICAL SPECTRUM OF REYNOLDS SYNDROME

Monica Nechita Ferreira ¹, Elena Creanga ², Luc Lasser ³, Francis Corazza ⁴, Jean Luc Vachier ⁵

¹ CHU Brugmann, Internal Medicine Department, Bruxelles, Belgium

² CHU Brugmann, Gastroenterology Department, Bruxelles, Belgium

³ CHU Brugmann, Gastroenterology Department, Bruxelles, Belgium

⁴ CHU Brugmann, Immunology Department, Bruxelles, Belgium

⁵ CHU Erasme, Cardiovascular Department, Bruxelles, Belgium

Introduction

Reynolds syndrome RS is a rare disease characterized by the co-occurrence of primary biliary cholangitis-PBC and limited cutaneousystemicsclerosis-LCSS. It is classified as an autoimmune disorder since there are specific autoantibodies associated with both facets of the disease-antimitochondrial antibodies-AMA (anti M2) for PBC and anticentromere antibodies-ACA for LCSS. The signs and symptoms of RS include those of both PBC- fatigue, pruritus, hepatomegaly and LCSS-calcinosis, digital ulcers, Raynaud's phenomenon, esophageal dysfunction, sclerodactyly, facial telangiectasia- CREST syndrome, often in association with pulmonary arterial hypertension PAH.

Case description

We present two cases of RS with different clinical manifestations and evolution.

Case 1

65-year-old female with progressive dysphagia, odynophagia and related severe malnutrition. She was found positive for ANA-1/2560 with ACA and AMA positive. Subsequent imaging showed megaesophagus with severe esophagitis, complete absence of esophageal contractions, absence of hypertonia of the lower esophageal sphincter and food impaction. Additional imaging showed Child C cirrhosis stage with hepatocarcinoma nodule, vascular invasion and left branch portal vein thrombosis. She did not have PAH. Her hospitalization was complicated by several infectious, worsening hepatic and cardiac failure, and, per family request, she was placed on palliative care.

Case 2

74-year-old woman, with progressive dyspnea and pruritus, Raynaud phenomena, telangiectasia, sclerodactyly, no fingers ulcerations.

Initial investigation found: hepatic cytolysis and cholestasis, negative viral serologies, ANA 1/1280, ACA and AMA positive.

Subsequent tests (echocardiogram, right cardiac catheterization, oesophagogastrosopy, esophageal manometry, chest CT, abdominal ultrasound and fibroscan) have shown: precapillary pulmonary arterial hypertension in a context of LCSS and PBC with F2 hepatic fibrosis.

This patient was treated with endothelin-receptor antagonists (Ambrisentan) and phosphodiesterase inhibitors (Tadalafil) with considerable improvement of his dyspnea. Ursodesoxycholic acid was also successfully administered for pruritus, with normalisation of hepatic test.

Discussion

Reynolds syndrome is a rare condition characterized by the association of two autoimmune diseases with a spectrum of clinical presentation. Early clinical recognition of this entity is critical to confirm the diagnosis, implement specific therapy and prevent associated organ failure.

#1218 - Case Report

LYSINURIC PROTEIN INTOLERANCE PRESENTING AS BEHAVIORAL CHANGES IN ADULTHOOD

Nihan Senturk Oztas, Cigdem Cetin

Istanbul University Istanbul Medical Faculty, Istanbul, Turkey

Introduction

Lysinuric Protein Intolerance(LPI) is a rare, metabolic disease resulting from resesive-inherited mutations in SLC7A7 gene. There is defect of cationic aminoacid (lysine, arginine and ornithine) transport at the basolateral membrane of intestinal and renal tubuler cells resulting diaminoaciduria, notably lysinuria and subnormal blood levels of arginine, ornithine and lysine.

As a consequence urea cycle becomes defective and marked hyperammonaemia occurs after protein digestion.

Initial presentation in adulthood is not common. We described 31 years old man presenting with acute behavioral changes diagnosed as LPI confirmed by aminoacid analyses.

Case description

A 31 year old man was transferred to the emergency department because of behavioural changes. According to information received from his family, he had similar episode 9 years ago and had been treated as case of viral encephalitis. His brother also had hysterics and he was died by suicide.

On admission to hospital he was afebrile and there was no meningism and any other abnormal neurological sign. Initial cranial screening and CSF analysis were normal. There was mild hepatosplenomegaly but no other abnormalities on general examination.

There was a microcytic hypochromic anemia with a hemoglobin of 10.4 g/dl, mild leukopenia (wbc: 2600/mm³), thrombocytopenia (plt: 90.000/mm³). Laboratory findings showed elevated transaminases (AST:72 IU/L, ALT:43IU/L), lactate dehydrogenase (3112 IU/L), ferritin (1923 ng/ml) level and hyperammonemia (550 mmol/l). Plasma levels of some aminoacids were low; lysine 97 mmol/L (120-250), ornithine 20 mmol/L (27-120) and arginin 13 mmol/L (45-150). Estimation of 24 hour urinary aminoacids showed an increased excretion of lysine of 869 mmol/L (0-250). LPI was confirmed by aminoacid analyses.

With the implementation of sodium benzoat, citrulline suplementation clinical findings and laboratory results were improved.

Discussion

Reports of LPI initial presentation in adult life are rare. Although our case had problems in childhood which are not significant for diagnosis, he had reached thirty years in good health probably by avoiding dietary protein unconsciously.

Although it is a very rare condition, mental changes concomitant with hyperamonia should be considered the diagnosis of LPI and detailed family and dietary history should be obtained in all patients.

#1302 - Case Report

SPLEEN INFARCT: AN UNCOMMON ETHIOLOGY

Neera Toledo Samaniego, Alejandra García García, María Toledano Macías, Cristina Ausín García, Blanca Pinilla Llorente
General University Hospital Gregorio Marañón, Madrid, Spain

Introduction

Segmental arterial mediolysis is a rare entity which is defined as a nonatherosclerotic and noninflammatory disruption of the arterial media layer with intramural dissection and/or thrombosis/rupture of dissecting aneurysm.

Case description

A 62-year-old man without any previous disease was admitted in urgency because of severe pain in epigastric and left upper quadrant that appeared few hours before admission. Laboratory tests showed hemoglobin 16.2 g/dL with a normal mean corpuscular volume, 10.900 leukocytes/mcL, 227.000 platelets/mcL, international normalized ratio (INR) of 0.95, fibrinogen 495 mg/dL, alanine aminotransferase 29 IU/L, gamma-glutamyl transferase 112 IU/L, alkaline phosphatase 61 IU/L, total bilirubin 0.6 mg/dL and creatinine 0.65 mg/dL. An aorta computed tomography (CT) scan done to rule out aorta dissection, revealed a spleen infarct and disruption of media layer arterial with 50-70% stenosis of celiac artery with dissection of splenic and common hepatic arteries. In internal medicine ward were rule out other causes for this such vasculitis. Anticoagulation with low molecular weight heparin was begun during the first three weeks and after antiagregant therapy with clopidogrel. The patient was observed during seven days. A new control CT was made one week and four weeks later. There were not progression of the dissection and the real light in hepatic artery was much bigger with revascularization. None endovascular procedure was done because of the risk of making more damage to a sick artery. After 3 months of follow up, the patient did not present any new event

Discussion

Segmental arterial mediolysis (SAM) is a very rare disease and there is an important lack of knowledge in this disease. It usually occurs in the fifth decade of life and it is manifested as abdominal pain because of visceral infarction or hemorrhages. It can be fatal because of the degeneration of the arterial wall leading to dissections or aneurysm formations, with a high risk of bleeding. Normally SAM involves mesenteric arteries, but it can also occur in cerebral vascular arteries. The risk of this entity after acute episode is rupture of aneurysms and bleeding, so endovascular or surgery treatment of aneurysm can be an option. Because long-term prognosis is unclear there are no standard therapeutic strategies. There is not standard treatment of this patients; it have been described the use of antiagregant therapy and anticoagulation, with low evidence.

#1383 - Abstract

FABRY DISEASE, UN UNDERDIAGNOSED DISORDER

Pilar Salvá D'Agosto, Adrián Ferre Beltran, Francesc Alberti Vich, Jose Luis Garcia Villa, Catalina Maria Nadal Marti, Maria Teresa Bosch Rovira

Hospital Universitari de Son Espases, Palma De Mallorca, Spain

Background

Fabry disease is an X-linked lysosomal storage disorder caused by mutations in GLA gene leading to deficient alfa-galactosidase A activity and glycosphingolipid accumulation. There is a classic presentation with pediatric onset and multi-organic

involvement, and a non-classic presentation with later onset and predominantly cardiac phenotype. Manifestations in female are variable due to residual enzyme activity and X chromosome inactivation patterns. Early initiation of enzyme replacement therapy provides significant clinical benefits. Certain mutations are susceptible of chaperone treatment.

Methods

A retrospective descriptive study that includes patients 18 years or older diagnosed with Fabry's disease at the University Hospital of Son Espases.

Results

7 patients were included, 3 men and 4 women. The median age of symptoms onset was 48.1 years (SD 12.7) and were diagnosed at 53.8 years (SD 14.2). They all had ventricular hypertrophy and 85.7% heart failure. 71.4% had arrhythmias but only 28.6% had an implantable cardioverter defibrillator. 42.9% also had renal failure. 42.9% of the patients were on enzymatic replacement treatment, 28.6% on chaperone therapy and only one patient had no treatment due to advanced age. 2 patients had c.658C>T (R220X) mutation, 3 c.902G>A (R301Q) mutation, 1 c.713G>A (S238N) mutation and 1 c.427G>A (A143P) mutation.

Conclusion

Fabry disease in our hospital has a predominantly non-classic presentation with cardiac phenotype, where men and women are equally affected. Probably there are more undiagnosed cases but the variability of symptoms and the lack of consciousness of this disorder within different clinical specialties makes it difficult to identify.

#1447 - Case Report

LATE-ONSET HEREDITARY VARIANT TRANSTHYRETIN AMYLOIDOSIS: A CASE REPORT

Diogo Abreu, Joana Antunes, Ana Filipa Batista, Sara Faria, Luísa Loureiro, Amélia Pereira

Hospital Distrital da Figueira da Foz, Figueira Da Foz, Portugal

Introduction

Hereditary variant transthyretin (ATTRv) amyloidosis, formerly known as familial amyloidotic polyneuropathy, is a rare autosomal dominant disease that typically presents with a symmetric lower-extremity sensorimotor neuropathy, autonomic neuropathy, cardiac conduction defects and vitreous opacities. In patients with ATTR Val30Met, the most common mutation, the usual age of disease onset is in the third to fourth decades of life, although there are less frequent cases of late-onset disease.

Case description

We report the case of a 53-year-old Portuguese woman, former seamstress, observed in our consultation with generalized

polyarthralgias, more intense in the ankles, associated with burning paresthesias. She also referred wrist and interphalangeal arthralgias and low back pain. She denied morning stiffness, improvement with rest and intermittent claudication. There was little relief with analgesic and anti-inflammatory drugs.

The patient had a pacemaker placed recently due to a Mobitz II atrioventricular block and was diagnosed with a bilateral carpal tunnel syndrome and a peptic ulcer. She was medicated with methylprednisolone, naproxen and sucralfate. There was no family history of ATTRv amyloidosis.

The physical examination was normal. A lumbosacral CT scan from the previous year revealed no root compressions. The doppler ultrasonography of the lower extremity arteries showed discrete signs of bilateral aortoiliac and femoropopliteal atheromatosis. An electromyography of the inferior limbs did not confirm a polyneuropathy, though evidencing changes suggesting compression at least of S1 root.

One year later she was discharged after being referenced to the pain management and psychiatry consultations. The patient was readmitted four years later, this time with decreased sensitivity of the inferior limbs and polyneuropathy, confirmed by electromyography. The genetic testing detected the Val30Met mutation of the transthyretin gene, confirming the diagnosis of ATTRv amyloidosis. The patient was referenced to a specialized medical center.

Discussion

This case report describes an atypical late-onset ATTRv amyloidosis without family history. It is important to be aware of divergent clinical courses and that it can occur as de novo mutations, since an earlier diagnosis can have a huge impact in patients' survival and quality of life.

#1453 - Case Report

SEVERE OPHTHALMOLOGICAL INVOLVEMENT IN EOSINOPHILIC GRANULOMATOSIS WITH POLYANGIITIS: A CASE REPORT.

Helena Rodrigues, Cátia Araújo, Rogério Ferreira, Lélita Santos, Armando De Carvalho

Centro Hospitalar e Universitário de Coimbra, Coimbra, Portugal

Introduction

Eosinophilic granulomatosis with polyangiitis (EGPA; formerly known as Churg-Strauss syndrome) is a rare multisystem disease characterized by a necrotizing granulomatous vasculitis of small- and medium-sized-vessels with eosinophilia. Usually, it involves the lungs and skin, but can also affect other organs. Ocular involvement is a rare but established complication that can lead to visual loss if not treated promptly.

Case description

We report the case of a 60-year-old man admitted to the

emergency department due to a sudden loss of bilateral vision. He had a history of persistent cough and wheezing for three months, general fatigue, myalgias and masticatory claudication for one month. A few days earlier, he developed low fever and nonpruritic cutaneous lesions. He was observed in the Ophthalmology department and diagnosed with central retinal arterial occlusion. Blood tests revealed an elevated eosinophilic count and eosinophilia was confirmed by blood smear. EGPA was diagnosed based upon the respiratory symptoms, eosinophilia, positive myeloperoxidase - anti neutrophil cytoplasmic antibody (MPO-ANCA) and positive results on skin and lung biopsy. During hospital admission, the patient developed a rapid and progressive deterioration of renal function that was completely reversed with corticosteroid pulse along with plasmapheresis and cyclophosphamide. Visual acuity wasn't, however, fully recovered.

Discussion

This was a case of an atypical presentation of EGPA with a rapid progression of symptoms and system involvement. Diagnosis of this disease had to be made promptly to guide proper therapy and prevent further loss of renal function and permanent visual impairment.

#1462 - Abstract

MUCOCUTANEOUS FEATURES OF SYSTEMIC SCLEROSIS: ABOUT 62 CASES

Imen Ben Hassine¹, Wafa Baya², Amina Aounallah¹, Syrine Daadaa², Anis Mzabi³, Fatma Ben Fredj⁴, Lobna Bousofara¹, Rima Gammoudi², Sana Mokni¹, Wafa Saidi², Najet Ghariani¹, Colandine Belajouza², Neirouz Ghannouchi³, Mohamed Denguezli⁴, Chedia Laouani Kechrid³, Rafia Nouira⁴

¹ Internal Medicine Department, Sousse, Tunisia

² Sahloul University Hospital, Sousse, Tunisia

³ Dermatology Department, Sousse, Tunisia

⁴ Farhat Hached University Hospital, Sousse, Tunisia

Background

Cutaneous features of systemic sclerosis (SS) are of major interest for the diagnosis. The aim of this work is to describe the skin involvement profile of 62 patients with SS.

Methods

A descriptive cross-sectional study including 62 patients in the Internal Medicine departments of Sahloul and Farhat Hached University Hospitals and in the Dermatology Department of Farhat Hached University Hospital, from January 1990 until December 2015.

Results

There were 56 women and 6 men with a mean age of 43.16 years. The average time to diagnosis of SS was 25.7 months. Tightness of skin was observed in 61 patients. It was diffuse in 29%. Three phases were observed: the oedematous phase in

19.4%, the indurated phase in 71.7% and the atrophic phase in 8.3%. Sclerodactyly was noted in 87%. Pigmentation disorders were observed in 30.6% of patients. Hyperpigmentation was present in 7 cases and hypochromia in 12 cases. Telangiectasia was observed in 16 patients. Subcutaneous calcifications were observed in two cases. Nail changes was observed in 6 patients. Trophic complications were noted in 25.8% of cases with digital ulcerations complicated by pulpal necrosis in 13 cases and digital amputations in 5 cases. Raynaud's phenomenon was observed in 83.9%. It was the inaugural symptom in 60% of cases. Symmetrical and bilateral acrocyanosis of the fingers was noted in 4.8% of the cases. Anti-Scl70 antibody was positive in cases of diffuse cutaneous involvement, trophic complications and Raynaud's phenomenon respectively in 21.4%, 60.7% and 89.3%. However, no correlation was found between the positivity of these antibodies and cutaneous features.

Conclusion

SS is a disabling autoimmune disease. It engages functional prognosis through cutaneous involvement, hence the need for early diagnosis and management.

#1470 - Case Report

CASTLEMAN'S DISEASE AND RHEUMATOID PURPURA: ABOUT A CASE

Wafa Baya, Jihed Anoun, Imen Ben Hassine, Fatma Ben Fredj Ismail, Monia Karmani, Amel Rezgui, Chedia Laouani Kechrid
Internal Medicine Department, Sahloul University Hospital, Sousse, Tunisia

Introduction

Castleman's disease is a rare entity characterized by uni-tumoral or multi-centric non-tumor lympho-proliferation. We report a second case of his association with a rheumatoid purpura.

Case description

This is a 61-year-old patient with no history of smoking at 40 AP who had a profound deterioration of general condition in three months with secondary installation of necrotic vascular purpura. The examination found in addition to multiple peripheral, firm, mobile and painless lymphadenopathies, as well as anasarca. Biologically, liver function, renal function and urinary sediment were normal. There was a mild inflammatory biological syndrome, hypoalbuminemia and hypoproteinemia. A thoraco-abdominal CT scan revealed upper and lower diaphragmatic adenopathies. Ganglion puncture and initial bronchial biopsies were non-contributory.

The ascites puncture had brought back a cloudy, exudative liquid with predominantly lymphocytic pleocytosis. Culture and cytology were negative.

Hepatitis B and C viruses and HIV serologies were negative. HHV8 serology in ascites fluid is ongoing. Rheumatoid factor and anti-CCP antibody were positive.

A cutaneous biopsy revealed leukocytoclastic vasculitis with granular IgA and C3 deposition in IFD allowing to retain the diagnosis of rheumatoid purpura. The biopsy of a jugulo-carotid adenopathy showed the appearance of a Castleman's disease in its plasmocytic form.

The patient was placed on high dose corticosteroid therapy and was assigned to hematologists for additional management.

Discussion

Castleman's disease is a lymphoid proliferation characterized by a polymorphic clinical picture that is frequently associated with autoimmune diseases. The installation of a vascular purpura should evoke an IgA vasculitis.

#1494 - Case Report

ONCOGENIC OSTEOMALACIA: A CASE REPORT

Rim Dhahri¹, Leila Metoui¹, Marwa Slouma¹, Sameh Sayhi², Imene Gharsallah¹, Bassem Louzir¹

¹ Internal Medicine Department of Military Hospital of Tunis, Tunis, Tunisia

² Internal Medicine department of Military Hospital of Tunis, Tunis, Tunisia

Introduction

Oncogenic osteomalacia also known as tumor-induced osteomalacia is a rare paraneoplastic disease linked to the presence of mesenchymal tumors especially phosphaturic mesenchymal tumor mixed connective tissue variant. Clinical presentation is typically identical to osteomalacia secondary to vitamin D deficiency; however the presence of hypophosphatemia and hyperphosphaturia with an elevated level of Fibroblast Growth Factor 23 allows reconsidering the diagnosis.

Case description

We report the case of a 60-year-old woman presenting a two-year history of walking difficulties with initial diagnosis of osteoid osteoma of the left femur. Given the recurrence of clinical symptoms after excision surgery, a second radiological and biological assessment showed hypophosphatemia, hyperphosphaturia, radiological signs of osteomalacia and elevated Fibroblast Growth Factor 23 concluding to oncogenic osteomalacia. Computed tomography and scintigraphy were not able to locate the tumor. Positron emission tomography revealed hypercaptation on the terminal ileum. Diagnosis of osteomalacia secondary to mesenchymal tumor located on the terminal ileum was retained. Patient was put on calcium and phosphate supplementation with a good course.

Discussion

Oncogenic osteomalacia is a rare paraneoplastic disorder essentially linked to the presence of mesenchymal tumor. In this report, we described a patient presenting antalgic gait with muscular weakness. Radiological assessment revealed diffuse bone demineralization and multiple pathological fractures. Laboratory tests showed hypophosphatemia with hyperphosphaturia and

normal calcium, parathyroid hormone and 25-hydroxyvitamin D3 serum levels. These findings associated with elevated FGF23 allowed the diagnosis of oncogenic osteomalacia.

#1585 - Case Report

MEDIUM-AGE MAN WITH A SCURVY DIAGNOSIS: A FORGOTTEN DISEASE

Carlos Báguena Pérez-Crespo, Francisco Javier Hernández Felices, Gabriel Puche Palao, Elena Del Carmen Martínez Cánovas, María Del Carmen Hernández Murciano, Ignacio Iniesta-Pino Alcázar, Lia Ferraro, Vicente David De La Rosa Valero, Ana Martín Cascón, Mónica Martínez Martínez

Hospital General Universitario Reina Sofía, Murcia, Spain

Introduction

The diagnosis of scurvy is a rare condition today, but it is important to include it in the differential diagnosis of haemorrhagic lesions accompanied by other affectations, especially in the group of patients with some of the most important risk factors, such as alcoholism, psychiatric conditions or social isolation.

Case description

A 54-year-old man consulted for hemorrhagic lesions since two weeks associated with an unquantified weight loss and asthenia. His unique disease known was schizophrenia, diagnosed in the adolescence. No adverse reaction to any drug known and he asserted that he has not suffered trauma or any other cause that justifies the lesions, but admitted that he has had episodes of red lesions in lower limbs for years, although he never presented bruises or bleeding.

On physical examination: careless appearance with evident lack of hygiene in his mouth and slight skin pallor. Furthermore two types of skin lesions were presented: in one hand bruises on the right foot and knee, in the other hand papular and erythematous perifollicular lesions in both lower limbs.

In the analysis only highlight a microcytic anemia (Hb 7,1) with all the rest of the test normal (including coagulation, autoimmunity and imaging studies).

During admission, dermatology service was consulted and suspect of scurvy lesions. With a more deep evaluation of the patient we noticed that because of his psychiatric conditions he followed a diet based on bread and sardines.

The C Vitamin level were below the average, and starting with the vitamin treatment in a few weeks all the lesions disappeared and the C Vitamin levels normalized.

Discussion

The variety of clinical manifestations presented by scurvy make us have to take it into account in a large number of differential diagnostics, which is why it is very important to interrogate about nutritional habits during the anamnesis of all patients. The treatment of this condition is simple, consisting of a varied diet and vitamin C supplementation.

#1665 - Case Report

A CASE REPORT OF AN AUTOIMMUNE POLYGLANDULAR SYNDROME

Beatriz Chambino, Lénia Rodrigues, Luis Maia Morais, Manuel Araújo, Ana Leitão, Luis Campos

Medicina Interna, UF3 - Hospital São Francisco Xavier, Lisboa, Portugal

Introduction

Autoimmune polyglandular syndromes (APS) are characterized by the association of 2 or more autoimmune (AI) diseases. In particular, APS type 3b is typically associated with AI thyroiditis and gastrointestinal-associated disease, namely pernicious anemia, celiac disease, inflammatory bowel disease (IBD). Here we describe a patient with APS type 3b presenting with AI thyroiditis, pernicious anemia and IBD.

Case description

A melanodermic male, of 31 year old, presented to our emergency ward with a history of progressive fatigue, auto-limited episodes of diarrhea, mouth ulcers, and a weight-loss of 30 kg (30% of body weight), since the 6 months before. He was born in Cape Verde, living in Portugal for the last 12 years, had not been traveling for foreign countries, denied toxic consumptions, or known allergies. His personal and familiar medical histories were irrelevant.

At examination, the patient presented emaciated, with pale skin and mucosa, a smooth tongue, without hepatosplenomegaly and enlarged lymph nodes or any other major alterations.

Laboratory evaluation revealed a macrocytic anemia (hemoglobin 3.2g/dL, hematocrit 9.2%, MCV 112fL; reticulocyte index 0.07), undetectable levels of folate and B12 vitamin, hemolysis markers with negative Coombs tests (bilirubin 1.6mg/dL; LDH 2475U/L; haptoglobin <10mg/dL) and a subclinical hypothyroidism (TSH 13uU/mL; T4L 12.8pmol/L).

Autoantibodies anti-thyroid peroxidase confirmed an AI thyroiditis.

A megaloblastic anemia with peripheral blood smear showing macrocytic erythrocytes and hypersegmented neutrophils, and anti-intrinsic and anti-gastric parietal cell autoantibodies positive and gastric atrophy on endoscopic visualization was compatible with a pernicious anemia.

The presence ASCA autoantibodies, fecal calprotectin of 680ug/g and ulcers and granulomas in distal ileal mucosa, was consistent with Crohn's disease.

The patient started intramuscular cyanocobalamin and oral folate, with good clinical evolution and medullar response, and was discharged 8 days after (hemoglobin 10g/dL; hematocrit 31.8%; MCV 87fL; RDW 19.4%; reticulocyte 4.7%; reticulocyte index 2.35).

Discussion

The concomitant presence of AI thyroiditis with pernicious anemia and IBD supports the diagnosis of AI Polyglandular Syndromes type 3b.

APS require a close follow-up between different medical

specialties because of the overlapping pathologies. This case is important to raise awareness of the diversification of AI diseases and their emergence.

#1693 - Case Report

WALDENSTRÖM MACROGLOBULINEMIA AND CARDIAC AMYLOIDOSIS: A RARE COMBINATION

Alexandre N. Fernandes, Maria Inês Vicente^{1,2}, Carolina Sequeira¹, Marta Custódio¹, Tânia Strecht¹, Ana Paula Antunes¹, Ana Gorgulho¹, Jana Zelinová¹

¹ Hospital de Cascais, Cascais, Portugal

² IPO Lisboa, Lisboa, Portugal

Introduction

Waldenström Macroglobulinemia (WM) is a rare low-grade B-cell lymphoma that accounts for 1–2% of non-Hodgkin lymphomas. It is characterized by bone marrow infiltration by lymphoplasmacytic cells associated with an IgM monoclonal gammopathy in the blood. Amyloidosis is a rare systemic disorder that results from tissue deposition of amyloid protein, which is defined by its resistance to proteolysis and its three-dimensional configuration as a beta pleated sheet. There are several subtypes of amyloidosis including primary amyloidosis, also known as light chain amyloidosis, secondary and familial amyloidosis. WM-associated amyloidosis is rare (3%) and generally of the systemic AL type. It is characterized by multiorgan involvement and high IgM levels.

Case description

A 57-year-old male was admitted in our hospital for evaluation of hepatosplenomegaly, fatigue and weight loss of 4kg within 6 months. He also referred epistaxis and spontaneous gum bleeding for the past 2 months. He had no relevant medical history but was a former smoker of 30 pack-year. Physical examination showed palpable hepatosplenomegaly. Laboratory findings showed discrete anaemia, normal white blood cell and platelet count, cholestasis pattern with elevated serum total bilirubin, alkaline phosphatase and γ -glutamyl transpeptidase. Imaging studies showed cardiomegaly and marked hepatosplenomegaly, with no sign of focal lesions. Serum protein electrophoresis revealed monoclonal gammopathy with quantitative IgM of 2492 mg/dL. Immunofixation showed IgM κ bands. Bone marrow biopsy showed lymphoplasmacytic cells involving 38% of total cells. Echocardiogram was suggestive of an infiltrative process. Cardiac MRI revealed abnormal patterns of late gadolinium enhancement in both global transmural and subendocardial distribution (favoring infiltrative disease). Biopsy of subcutaneous fatty tissue was positive for AL amyloidosis. The diagnosis of WM with IgM-related amyloidosis was therefore established.

Discussion

The authors highlight that cardiac amyloidosis is unusual both as a presenting and coexisting entity in WM. The latter is a rare

disease with a heterogeneous clinical presentation which makes it challenging to make an accurate diagnosis. Cardiac amyloidosis is an underdiagnosed condition but a leading cause of morbidity and mortality in these patients, which halts early detection before irreversible changes occur.

#1694 - Abstract

BEVACIZUMAB IN HEREDITARY HEMORRHAGIC TELANGIECTASIA: ONE CENTRE EXPERIENCE

Alexandra Vieira Aires Santos, Anabela Aires, Margarida Antunes, M. João Diniz

Hospital São José, Centro Hospitalar Universitário Lisboa Central, Lisboa, Portugal

Background

Hereditary hemorrhagic telangiectasia (HHT) is a rare autosomal dominant disorder of the fibrovascular tissue. Lesions are characteristically telangiectasias and arterio-venous malformations (AVM) that bleed spontaneously. When in the nasal cavity and GI tract they present a higher risk of bleeding, resulting in epistaxis and chronic digestive hemorrhage, the main symptoms of HHT that often progress to severe events, causing iron deficiency anemia and transfusion dependence. The severity and frequency of these episodes have a significant impact on the QoL. Our aim is to evaluate the use of intravenous bevacizumab (IVB) in HHT.

Methods

A retrospective review of HHT cases treated with IVB in a central hospital.

Results

Two patients with HHT and severe anemia, refractory to conventional treatments, are being treated with IVB at low doses. 65 year-old female patient with HHT diagnosed at 52. She presented with severe refractory gastrointestinal bleeding. The last transfusion occurred 15 days before starting IVB. After 30 months of follow-up the patient maintains complete clinical remission, without bleeding or anemia.

68 year-old female patient with HHT diagnosed at 38. She presented with epistaxis, initially controlled with local measures. The recurrent severe epistaxis intensified in the last 12 years. After 24 months of IVB, the patient remained with significant bleeding and high flow epistaxis.

Conclusion

The pathogenic mechanism of HHT is unclear but presumed to be related to aberrant signaling of TGF- β 1 which induces increased expression of VEGF. The off-label use of low dose IVB, a monoclonal antibody that targets VEGF, has shown promising results in patients with HHT and hemorrhage refractory to conventional treatments, allowing reduction of epistaxis, GI

bleeding and anemia. Both cases presented are clinically severe, with similar transfusion dependence. The response to IVB was completely different. There were no severe events.

As a severe rare disease, often life-threatening, there are few prospective studies or treatment guidelines. The use of IVB in HHT increases the possibilities of treatment of severe cases refractory to conventional treatments. However, more studies are necessary to establish doses and clinical, genetic, molecular or biochemical predictors of response to IVB. The multidisciplinary approach is essential in this disease that is progressive, in which several medical specialties treat the patient almost simultaneously.

#1699 - Abstract

ACQUIRED HEMOPHILIA: CASE SERIES OF A SINGLE CENTER

Anabela Maria Paulo Aires, Alexandra Santos, Margarida Antunes, M. João Diniz

Hospital São José, Centro Hospitalar Universitário Lisboa Central, Lisboa, Portugal

Background

Acquired hemophilia A (AHA) is a potentially life-threatening rare bleeding disorder caused by autoantibodies against circulating Factor VIII. Overall, AHA has an estimated prevalence of 1-1,5 cases/million/year. Although more frequent in the elderly and associated with malignancies, autoimmune disorders, drug exposures or in the post-partum period, 50% of cases are apparently idiopathic. The diagnosis should be suspected when isolated prolonged aPPT is observed with spontaneous hemorrhage and no previous family or personal bleeding history. Low FVIII activity and the presence of inhibitory antibodies confirm the diagnosis. Along with the diagnosis and treatment of the underlying disorder, control of acute bleeding is a priority together with eradication of antibody production through immunosuppressive therapy. The aim of this review is to describe our experience in managing AHA.

Methods

A retrospective review of AHA cases diagnosed between 2002 and 2018 in a central hospital.

Results

During this period, 9 patients were referred to our Centre, 7 men and 2 women, with a median age of 77 years old [60; 89]. All presented bleeding symptoms (muscle hematoma, hematuria and gastrointestinal bleeding) associated with anemia [Hb 5,7;10,7g/dL]. Results showed prolonged aPPT [48,6;>320sec], reduced FVIII:C plasma levels [<0,50;30,70%] and incomplete aPTT correction on the mixing study. Inhibitor titer varied between 0,8 and 137,65 BU. 2 patients died after diagnosis and before treatment. The others received bypassing agents [rFIIa (2) and aPCC (6)] and immunosuppressive therapy with prednisone (6) or prednisone+ cyclophosphamide (1). 3 cases had a known

underlying disorder. Bleeding control occurred in all treated patients and inhibitor eradication was achieved in 5 of them. There was no correlation between inhibitor titer and bleeding severity. There were no adverse events related with treatment.

Conclusion

AHA is a rare autoimmune bleeding disorder characterized by a heterogeneous bleeding phenotype, often underdiagnosed or misdiagnosed. The diagnosis requires a high degree of suspicion and it is a clinical challenge. Most patients are first evaluated in the emergency room and there is a lack of awareness of this medical condition, causing delay in the diagnosis and inadequate treatment. As a rare disease, there are few guidelines or recommendations. Sharing experiences and continuous medical education, in a multidisciplinary setting, are essential to prompt diagnosis and treatment of AHA.

#1712 - Medical Image

PYODERMA GANGRENOSUM

Ana Vera Cruz, Maria Margarida Pereira, Marta Cerol, José Ramalho, Gonçalo Ferrão, Juliana Mortágua, José Pedro Andrade
Hospital de Santarém, Santarém, Portugal

Clinical summary

The abdominal wall of a 50-year-old man with history of ulcerative colitis, obesity and type 2 diabetes submitted to Nissen fundoplication plus laparoscopic abdominal wall hernia repair. 10 days after presents at the emergency department with fever, seropurulent exudate from the wound and purulent discharge of all stitches. Completed 3 courses of antibiotherapy with progressive worsening. Dermatology consultation was requested and the diagnosis of Pyoderma Gangrenosum was established. High dose corticosteroid treatment was initiated - pulse therapy with methylprednisolone followed by 1mg/kg/day with slow but progressive cicatrization of the skin lesions.

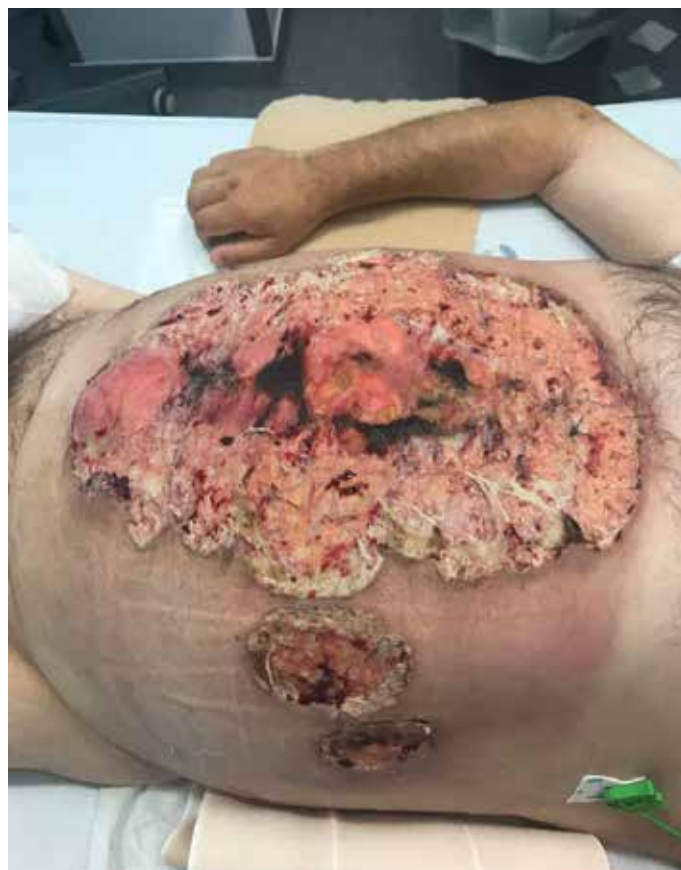

Figure #1712. Pyoderma gangrenosum.

#1741 - Abstract

EOSINOPHILIA FOLLOW-UP DURING BULLOUS PEMPHIGOID

Imen Ben Hassine¹, Wafa Baya², Amina Aounallah¹, Lobna Bousofara¹, Fatma Ben Fredj Ismail², Sana Mokni¹, Rima Gammoudi¹, Najet Ghariani¹, Wafa Saidi¹, Colandine Belajouza¹, Mohamed Denguezli¹, Rafia Nouira¹

¹ Dermatology Department, Farhat Hached University Hospital, Sousse, Tunisia

² Internal Medicine Department, Sahloul University Hospital, Sousse, Tunisia

Background

Bullous pemphigoid (BP) is the most common autoimmune bullous skin disease. Eosinophilia has been frequently reported in patients with BP. The aim of this study is to determine correlations between eosinophilia and disease activity.

Methods

This is a descriptive retrospective cross-sectional study including patients followed for BP over a period of 20 years from January 1995 to December 2015.

Results

114 patients were included, 57 men and 57 women, with a mean age of 69.9 years [3 months - 98 years]. Eosinophilia was

observed in 75 patients (67.5%) at the time of diagnosis, with a median of 900 elements/mm³ and an extreme of 12852 elements / mm³. Investigations were made to eliminate hypereosinophilic syndrome in 2 patients who had serum eosinophils > 2000/mm³. In the second month, the rate of eosinophils started to decrease with a median of 400 elements/mm³ and extremes ranged from 100 to 4600 elements/mm³. In the fifth month, a normalization of eosinophils rates occurred with an average of 300 elements/mm³. No correlation was found between the generalized or localized nature of skin lesions and the rate of eosinophils ($p= 0.75$). In addition, a positive correlation was found between the evolution of BP and eosinophils rates ($p= 0.022$). These rates decreased significantly between the first day and the second month for those who did not relapse and between the second month and the fifth month in the group of patients who relapsed.

Conclusion

Our results confirm the existence of a link between the rate of eosinophilia and the evolution of BP, regardless of the severity of the disease.

#1743 - Case Report

HEMOPHAGOCYTIC SYNDROME: A DIFFICULT DIAGNOSIS

Tiago Rabadão, Leonor Naia, Mariana Teixeira, Filipa Ferreira, Margarida Eulálio, Fernando Silva, Rosa Jorge
Hospital Infante D. Pedro, Aveiro, Portugal

Introduction

Hemophagocytic syndrome (HPS) is a life-threatening disease, especially if diagnosed late. Previously established diagnostic criteria (HLH-2004) are controversial and do not reflect, especially in adults, all described clinical manifestations.

Case description

49 year old woman presented with one week history of anorexia, asthenia, pruritus, abdominal pain, nausea and liquid stools. The patient had poor living conditions and suffered from mild cognitive impairment and blindness since childhood. On admission, she presented with fever (38.2°C), pain on right superior abdominal quadrant and scratchy skin lesions. She had microcytic anemia (Hb: 7.4 g/dL), leukocytosis and thrombocytosis; ferritin was 18953 ng/mL, sedimentation velocity 130 mm/h, AST-210 U/L, ALT-71 U/L, g-GT-111 U/L, ALP-183 U/L, lactate dehydrogenase 750 U/L, C-protein reactive of 28.51 mg/dL, β_2 microglobulin of 8210 ng/mL and IL-6 of 97.2 ng/L. Levels of CD25 and fibrinogen were elevated; NK cell activity was normal and triglycerides levels were low. CT-scan revealed axillar, cervical, mediastinic and mesenteric adenopathies; splenomegaly and also pericardic, peritoneal and bilateral pleural effusion; PET-scan showed increased cervical adenopathies uptake. Axillar adenopathy, bone and skin biopsies were performed, showing reactive changes. Study was negative for liver and heart disease, hemathologic and

solid tumor, autoimmune disease, infection and genetic defects. The patient had a long hospital stay and recurrent deterioration episodes with different manifestations including hypotension, high fever and other organic dysfunctions. She was admitted after in the intensive care unit. Although fulfilling only 4 criteria for diagnosis of HPS, treatment with dexamethasone and cyclosporine was started due to high clinical suspicion. Clinical stability was achieved, with gradual improvement the initial symptoms, anemia and hyperferritinemia. After discharge, there was no adherence to therapeutic prescription with clinical relapse resulting in hospital readmission. The patient remained under Hematology follow-up, after developing cushingoid appearance with new onset hypertension. The patient was not eligible for bone marrow transplantation due to low family support.

Discussion

This atypical case shows that clinical judgment should be encouraged instead of relying just on strict adherence to pre-established diagnostic criteria, especially in adults.

#1750 - Case Report

PULMONARY ARTERIOVENOUS MALFORMATION IN RENDU-OSLER-WEBER SYNDROME

Guillermo Soria Fernández-Llamazares, María Mercedes Ferreiro-Mazón Jenaro, Eduardo Luis Peñaloza Martínez, Cristina Llamazares Mendo, Marta Bacete Cebrián, Luis Teigell García, Antonio Muiño Míguez, María Gómez Antúnez
Hospital General Universitario Gregorio Marañón, Madrid, Spain

Introduction

Hereditary haemorrhagic telangiectasia (HHT) or Rendu-Osler-Weber (ROW) syndrome is an autosomal dominant rare vascular disorder. It can involve multiple systems and it is characterized by the presence of angiodysplastic lesions which cause communication between arteries and veins. Most common clinical manifestations include epistaxis, mucocutaneous telangiectasias and gastrointestinal or intracranial bleeding.

Case description

A 24-year-old male came to Emergency Department with a two-week history of cough and weakness without other symptoms. A chest x-ray revealed a well-defined pulmonary parenchymal lesion of approximately 4 centimeters of diameter. A total-body computed tomography (CT) was performed, showing a solitary round mass with good contrast enhancement, well demarcated, suggesting arteriovenous malformation perfused by a single artery and drained by a single vein. It showed an intracavitary thrombus into the sac. He had also hepatosplenomegaly with tortuous hepatic veins without cirrhosis signs. Blood test showed normal complete blood count with normal coagulation parameters and elevation of aminotransferases, bilirubin, alkaline phosphatase and gamma-glutamyl transpeptidase. Serological test for HIV,

HCV, HBV were negative. The physical examination showed reddish lesions in lips and tongue. Subsequent anamnesis revealed history of recurrent epistaxis and familiar history (mother and grandmother) of haemorrhagic telangiectasia. According to the Curaçao criteria he was diagnosed with Rendu-Osler-Weber (ROW) syndrome.

Discussion

Pulmonary arteriovenous malformations (PAVMs) are uncommon in the general population. Reports suggest than most common cause is HHT. However, PAVMs can occur in other conditions, the most common of which is hepatic cirrhosis. Only 5 - 15% of patients with Rendu-Osler-Weber (ROW) syndrome have pulmonary arteriovenous malformations. No evidence in the literature was found about anticoagulation in patients with intra-malformation thrombus, but it is known these patients have a higher risk of systemic embolisms, so we started anticoagulation with enoxaparin in order to prevent them. Anticoagulation in patients with ROW syndrome is not related with a higher risk of bleeding.

#1757 - Case Report

ALL THAT GLITTERS IS NOT GOLD : A RARE CASE OF LIPOID PNEUMONIA

Nikhil Victor Dsouza

Kasturba Medical College, Mangalore, Manipal Academy Of Higher Education, Manipal, Mangalore, India

Introduction

Lipoid pneumonia is an overlooked diagnosis when evaluating for symptoms like chronic cough, breathlessness, hemoptysis due to its non specific presentation and an inadequate history. Exogenous lipoid pneumonia results from inhaling or aspirating fatty materials (oily nose drops, mineral oil). Endogenous lipoid pneumonia (often called "cholesterol pneumonia") consists of chronic inflammatory foci containing cholesterol and its esters, derived from destroyed alveolar walls located either behind a bronchial obstruction or in lung parenchyma at a site of chronic suppuration. It can mimic other diseases because of its nonspecific clinical presentation and radiographic signs

Case description

72 year old gentleman presented with productive cough with expectoration associated with breathlessness on exertion since 15 days, fever since 15 days (evening rise of temperature) and loss of appetite from 15 days. He has no prior co-morbid conditions except history of smoking. On examination patient was conscious, oriented. Clubbing and right cervical lymphadenopathy was present and Jugular Venous Pulsation not elevated. Respiratory system examination revealed trachea to be central, bilateral chest movements equal, decreased intensity of breath sounds in right mammary, infraaxillary, inter scapular and infra scapular areas. Crepitations was present in the above mentioned areas. A provisional diagnosis of right lower lobe pneumonia with

differential of pulmonary tuberculosis (TB) was made. Blood investigations were within normal limits except ESR was 79 and sputum was negative for acid fast bacilli. Chest Xray revealed mild right sided pleural effusion. CECT chest was done which showed consolidatory changes in the right lower lobe, loculated right pleural effusion. Based on the pleural fluid analysis-lymphocytes 44%, ESR 79 and CECT finding patient was started on anti Tubercular therapy (ATT) and bronchoscopy was planned. Bronchoscopy was done and bronchoalveolar lavage reported to have many macrophages with intracellular lipid accumulation, diagnosis of Lipoid pneumonia was made, ATT was stopped and specific treatment was provided and subsequently the patient improved.

Discussion

In India with TB being prevalent, diagnosis of such conditions may be overlooked and many may be treated as TB and end up as non resolving pneumonia. Hence this case establishes the need for physicians to be aware and do a thorough work up beyond tuberculosis to avoid missing such rare entities.

#1779 - Medical Image

WHEN THE HELIOTROPE RASH ISN'T SO PURPLISH-VIOLET

Isabel Cruz Carvalho, Ana De Carmo Campos, Sara Sarmiento, Miguel Ardérius, Teresa Fonseca

Centro Hospitalar de Lisboa Norte - Hospital Pulido Valente, Lisboa, Portugal

Clinical summary

A 43-year-old melanodermic man presented with edema and facial flushing, more evident in the frontal, malar, periorbital and upper lip. Also had small cutaneous ulcers in the bony eminences of the metacarpophalangeal joints and digital extremities, after minor trauma. There was a progressive worsening of the condition over 7 months, with normal skin biopsies. After muscular and systemic involvement dermatomyositis was diagnosed.

The diagnosis was delayed due to the racial characteristics of the patient, limiting the recognition of facial flushing and the identification of the hand ulcers as Gottron's papules. It is a rare condition and we thought it would be interesting to share the dermatomyositis dermatologic clues in melanodermic patients.

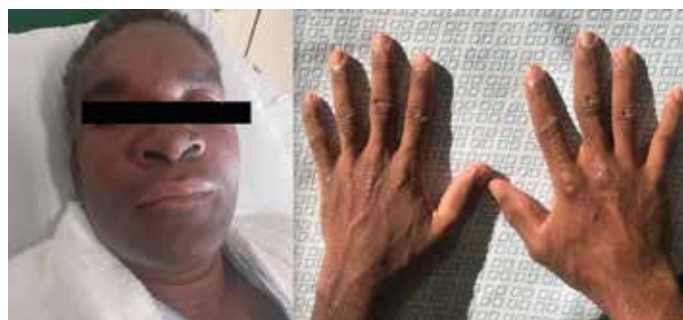

Figure #1779. Edema and facial flushing + Gottron's papule.

#1800 - Medical Image

LOBAR CONSOLIDATION IS NOT ALWAYS SYNONYMOUS OF PNEUMONIA: A STRANGE CASE OF PULMONARY HEPATISATION IN A YOUNG HEALTHY WOMAN

Serena Melandri

Department of Internal Medicine and Prevention of Atherosclerosis
Sapienza University, Rome, Italy

Clinical summary

A 46 y old woman comes to our attention because of dyspnoea on mild exerts since 4 months, increasing and crippling; no risk factor (smoking, obesity) or diseases in history, but work exposure to pollution (airport). She performed 2 chest CT-scan with contrast medium and a broncho-alveolar lavage (BAL). The first showed two parenchymal consolidation in the right superior and inferior lobes and bilateral ground-glass opacity. The BAL was positive for *Stenotrophomonas M.* and *P. Aeruginosa*, negative for alcohol-acid resistant bacteria, fungi, neoplastic cell. She was treated with Bactrim and levofloxacin without any change in clinical and radiological signs. Lab tests are normal, except for lymphopenia, anti SSA-RO and electrophoretic $\beta 2$ peak. Biopsy diagnoses a bronchial-associated lymphoma.

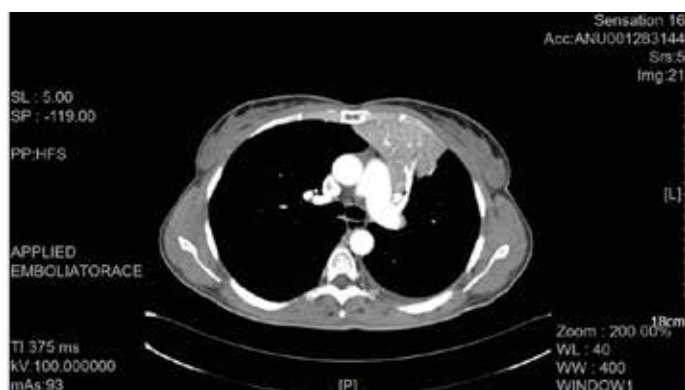
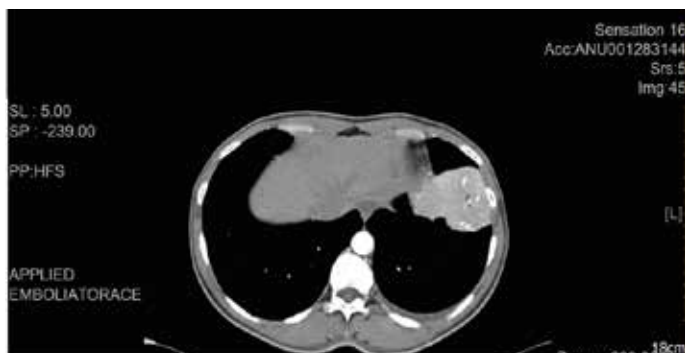
Figure #1800. Pulmonary consolidation in right superior and inferior lobe simulates pneumonia. lung biopsy diagnosis a bronchial associated lymphoid tissue lymphoma.

#1843 - Case Report

MULTIPLE MYELOMA AND AL AMYLOIDOSIS – A RARE CASE OF NEPHROTIC SYNDROME

Cátia Carvalho, Daniana Condado, Maria Helena Pacheco, Lurdes Venâncio

Centro Hospitalar Universitário de Lisboa Central - Hospital Santo António dos Capuchos, Lisboa, Portugal

Introduction

The nephrotic syndrome is a highly prevalent disease with an incidence of 3 new cases per 100.000 each year. It can be a primary kidney disease or secondary to drugs, infections or systemic diseases, such as amyloid disease or multiple myeloma – both malignant clonal plasma cell proliferative disorders. Multiple myeloma accounts for 1% of all cancers and almost 10% of all hematologic malignancies, with an incidence in Europe of 4.5-6 per 100.000 each year. AL amyloidosis is the most common type of systemic amyloidosis in developed countries with an incidence of 9 per million each year and the progression to myeloma is very unusual. Meanwhile, myeloma patients are in risk to develop amyloidosis at a low rate of 1% per year, 30% have subclinical amyloid deposits and 15% will develop overt clinical amyloidosis through the course of disease, which influences the treatment and prognosis of the disease.

Case description

We report a 70-year-old portuguese female with general edema and hypertension for the last 3 months. Laboratory investigation showed a hemoglobin 13.3 g/dL, erythrocyte sedimentation rate 78 mm/h, serum albumin 21.4 g/L, calcium 8 mg/dL, urine microscopic examination with +++ proteinuria, urine 24h protein >12.332mg with mycroalbuminuria 7884.6mg, serum eletrophoresis showed an alfa2 peak and seric immunofixation showed the presence of a biclonal IgG and IgA and lambda light free chains. Serum IgG was 2.27g/L, IgA 0.65g/L, serum lambda free light chain was 1590mg/L and serum free light chain ratio (kappa/lambda) was 0,01. Skeletal survey showed no lytic lesion. Renal biopsy revealed lambda light chain deposition and positive birefringence of Congo red-stained. Bone marrow biopsy revealed 17% dysmorphic plasmocitic neoplasm, including some nucleated forms, Beta-2-microglobulin 2.5mg/L. So the diagnosis was nephrotic syndrome due to lambda light chain multiple myeloma (stage II) and lambda light chain AL amyloidosis. She initiated CyBORD treatment with anti-hypertensive therapeutic, waiting for an autologus transplant, with a huge clinical benefit and a massive reduction on the lambda free chains.

Discussion

This case report shows how important is a quick multidisciplinary approach, since nowadays, with the development of a more accurate diagnosis, the treatment can be more specific and with better results.

#1864 - Abstract

CLINICAL MANIFESTATIONS DURING BULLOUS PEMPHIGOID

Imen Ben Hassine¹, Wafa Baya², Amina Aounallah¹, Fatma Ben Fredj Ismail², Sana Mokni¹, Rima Gammoudi¹, Lobna Bousofara¹, Wafa Saidi¹, Najet Ghariani¹, Colandine Belajouza¹, Mohamed Denguezli¹, Rafia Nouira¹

¹ Dermatology Department, Farhat Hached University Hospital, Sousse, Tunisia

² Internal Medicine Department, Sahloul University Hospital, Sousse, Tunisia

Background

Bullous pemphigoid (BP) is the most common auto-immune epidermal bullous dermatosis. The aim of our work was to specify the clinical characteristics of this pathology in tunisian patients.

Methods

This is a descriptive retrospective cross-sectional study including BP patients over a period of 20 years [January 1995 - December 2015].

Results

114 patients were included, 57 men and 57 women, with a mean age of 69.9 [3 months - 98 years]. Three patients were under 8 years old. Pruritus preceded bullous lesions in 103 patients with an average of 2 months. The most common lesion was large, serous-containing, tight-bodied lesions resting on healthy or erythematous skin. It was found in 89 patients. Pseudo-urticarial lesions were noted in 36 patients and eczematiform plaques in 6 patients. Bubbles broke and left erosions surmounted by crusts and hypochromic scars in 97%. BP localized form was found in 54 patients (47.3%) and the generalized form in 60 patients (52.6%). Upper limbs were affected in 94.7%, anterior thighs in 93.9%, the anterior trunk in 78.1% and the abdomen in 66.7%. Cephalic extremities were affected in 46.5% of cases. Mucosal involvement was found in 38 patients (33.3%) (oral in 27.2%, genital in 36.8%, nasal in 10.52%). Thirty-nine patients had scalp erosions. Nail dystrophy was found in 13 of them.

Conclusion

BP, in Tunisia, is unique in the extent of skin lesions as well as the frequency of cephalic, mucous and unguinal forms.

#1957 - Abstract

BULLOUS PEMPHIGOID: TREATMENT AND EVOLUTION

Imen Ben Hassine¹, Wafa Baya², Amina Aounallah¹, Sana Mokni¹, Fatma Ben Fredj Ismail², Rima Gammoudi¹, Lobna Bousofara¹, Wafa Saidi¹, Najet Ghariani¹, Colandine Belajouza¹, Mohamed Denguezli¹, Rafia Nouira¹

¹ Dermatology Department, Farhat Hached University Hospital, Sousse, Tunisia

² Internal Medicine Department, Sahloul University Hospital, Sousse, Tunisia

Background

Treatment of bullous pemphigoid (BP) is mainly based on local or general corticosteroid therapy. Long-term relapses are rare but pose therapeutic problems because of the large cumulative doses in these elderly people. The aim of this study was to specify therapeutic and evolutionary peculiarities of this pathology in tunisian patients.

Methods

This is a descriptive retrospective cross-sectional study including BP patients over a period of 20 years from January 1995 to December 2015.

Results

57 men and 57 women were included with a mean age of 69.9 years. BP localized form was found in 54 patients (47.3%) and the generalized form in 60 patients (52.6%). Mucosal involvement was found in 38 patients (33.3%) (oral in 27.2% of cases, genital in 36.84% of cases, nasal in 10.52% of cases). All patients received local treatment and antibiotic therapy was used in 81 patients. Oral corticosteroids were immediately prescribed for 106 patients (93%) at doses ranging from 0.5 mg/kg/day to 1.5 mg/kg/day. The mean duration of the attack treatment was 25.6 days with a progressive decrease until a maintenance dose of 15 to 30 mg/day after 5 to 6 months. Immunosuppressive therapy was used in 3 cases justified by extensive lesions and corticosteroid resistance (cyclophosphamide in one case and azathioprine in two cases). Significant improvement was observed in 81 patients after 6 months of treatment. A relapse was observed in 31 (27.2%) patients during the first year of follow-up. The relapses were due in 90% of the cases to an untimely stop of the treatment by the patients. In 10% of cases, relapses were observed during the depression of corticosteroid therapy or steroid resistance.

Conclusion

The relapse rate is very significant during the first year of follow-up, which requires a rigorous analysis to detect the factors.

#2010 - Case Report

SAPHO SYNDROME: A RARE CONDITION DIAGNOSED IN A AFRICAN 19-YEAR OLD WOMEN

Vanessa Machado¹, Paulo Ferreira¹, Cristina Ramalho¹, Hilda Freitas², Antonio Cabral², Natalia Oliveira²

¹ Trofa Saúde Hospital em Braga Centro, Braga, Portugal

² Trofa Saúde Hospital em Braga Sul, Braga, Portugal

Introduction

SAPHO syndrome (synovitis, acne, pustulosis, hyperostosis and osteitis) is an inflammatory disease of skin, bone and joints. Data estimate 1 in 10.000 in Caucasian populations, although reports suggest a global distribution, ages between 30 and 50 years old. Infectious (ex.: Cutibacterium acnes), genetic and immune

dysregulation factors have been associated to pathogenesis. Osteoarticular manifestations are the hallmark and cutaneous manifestations are associated in more than 60% of the cases.

Case description

A 19-year old African woman student in Portugal, previously healthy, was admitted three times in the emergency department due to facial pustular lesions, dyspnea, precordial and back pain. Medicated with several antibiotics, non-steroidal anti-inflammatory and antihistaminic drugs and corticosteroids, was always discharged.

At admission in our hospital (3 months after the first symptoms), the patient presented with multiple non pruriginous facial skin lesions (not fully healed) and some acne-like minor pustules, chronic bi-parietal headaches, thoracic pain, polyarthralgia and asthenia. Painful complaints at palpation of the shoulders, whole column and sacroiliac joints were also present.

Hospitalization was performed. Initial analyses revealed anaemia, thrombocytosis and alkaline phosphatase elevation. Dermatology collaboration appointed to the hypothesis of acne fulminans and less likely SAPHO syndrome and suggested doxycyclin therapy that was initiated.

The clinical presentation evolved with febrile syndrome, sustained polyarticular pain and bilateral sternoclavicular joint swelling and local tenderness. Autoimmune, bacteriological, rheumatologic, thyroid analyze was ruled out. Sedimentation rate elevation (VS > 100 mm), inflammatory parameters elevation and positive lupus anticoagulant were identified. The bone scintigraphy revealed inflammatory changes in particular the bull's head signal. Anti-inflammatory and corticosteroid therapy were introduced. Dorsal and lumbar spine MRI was also performed revealing inflammatory/degenerative spine (L4-S1) disease. A favorable clinical course with febrile resolution and evident improvement of polyarthralgia permitted discharge two weeks later.

Discussion

We alert Physicians to consider this diagnosis in the presence of upper anterior chest wall pain, osteoarticular symptoms with inflammatory arthritis/osteitis and acneiform skin eruption. With a combined therapy, symptoms can be controlled.

#2018 - Case Report

CHURG-STRAUSS SYNDROME (CSS) – A CASE REPORT

Fabio Caleça Emidio, Roberto Calças Marques, Frederico Rajão Martins, Ana Ribeiro

Centro Hospitalar Universitário do Algarve, Faro, Portugal

Introduction

Churg-Strauss syndrome (CSS) is a rare systemic necrotizing vasculitis of the small and medium vessels of unknown etiology, affecting all age groups and both genders. It is associated with extravascular eosinophilic granulomas, peripheral eosinophilia

and asthma, and patients usually respond well to steroid treatment, despite relapses being frequent. Timely diagnosis and treatment usually lead to a good prognosis with a one-year 90% survival rate. The diagnostic criteria defined by the American College of Rheumatology (ACR) are currently the most accepted. These include asthma, peripheral eosinophilia greater than 10%, mono or polyneuropathy, migratory pulmonary infiltrates, paranasal sinus pathology and extravascular eosinophils on biopsy.

Case description

A 83-year-old patient, with chronic kidney disease of undetermined etiology under hemodialysis, presented with progressive dyspnea and productive cough with three days, without fever. He had medical history of undefined obstructive pulmonary disease, pansinusitis, severe and recurrent nasosinus polyposis.

Initially hospitalized with the diagnosis of community-acquired pneumonia, subsequently developed a pleural effusion in the lower third of the left lung. Two evacuative and diagnostic thoracentesis were performed, revealing an exudate with 30% eosinophils and ANCA-MPO titre > 300 UA/mL, which raised suspicion of CSS. Pleural biopsy showed fibrosis and moderate inflammatory lymphocytic infiltrate with presence of eosinophils. Analytically with leukocytosis and peripheral eosinophilia (14%), rheumatoid factor < 8.9; IgE 684; ANA's negative, which also supported the diagnosis. Corticosteroid therapy was started with prednisolone 1mg/kg/day (50mg) with immediate and favorable response.

Discussion

In this particular case the suspicion for the diagnosis of CSS had been raised by the development of pleural effusion, present in only a third of the patients. However, this patient also had a history of pansinusitis and recurrent nasal polyposis as well as respiratory pathology whose differential diagnosis between asthma and chronic obstructive pulmonary disease was not definitely established. In this case, 4 of the 6 criteria defined by ACR for the diagnosis of CSS, as previously described, were fulfilled. The favorable response to corticosteroids and the presence of MPO-ANCA also support this diagnosis. Neurological involvement, systemic symptomatology and cutaneous vasculitic lesions were not found, and pulmonary symptoms prevailed.

#2057 - Case Report

AN UNEXPECTED CONNECTION

Joana Dias Alfaiate, Alexandra Dias, Mário Gola, Fátima Pimenta
Centro Hospitalar Médio Tejo, Albergaria Dos Doze, Portugal

Introduction

Chronic cough is a generic symptom with a wide spectrum of etiologies and hard to achieve diagnosis. This case shows unusual case of chronic cough.

Case description

Male patient, 42 years old, professional electrician, is admitted

in the emergency department for fever, incapacity to take deep breaths and mild abdominal pain in the right hypochondrium. Associated, the patient describes, chronic cough and yellow and bitter expectoration, both with 1 month of evolution. In the clinical history there was a recent accidental electrocution that resulted in pulmonary and hepatic contusions and disruption of the biliary tract.

The laboratory tests registered an elevation of the inflammatory markers and hypoxia. A condensation localized in the right pulmonary base was revealed by a thoracic x-ray.

The patient was admitted in the infirmary with the diagnosis of Pneumonia and started empiric antibiotic. Despite the medication there was no clinical recovery and the reevaluation by thoracic x-ray shown a cavitation in the prior affected area. A broncofibroscopia with LBA was made, with a yellow and translucent liquid was collected for laboratory examination. A thoracic and abdominal computer tomography was also required, and it confirmed the pulmonary cavitation and shown the presence of a communication between the biliary tract and the pulmonary bronchi.

The diagnosis of a fistula between the biliary tract and the bronchi was made, and the patient was sent for a cardiothoracic department, where the fistula was closed.

Discussion

This case shows the importance of being alert, because even the most “by the book” pneumonia can be something else. Discrepancies in evolution should always be treated with care and correctly investigated.

It also brings to the light a rare complication of pulmonary and hepatic contusion.

#2078 - Case Report

AN UNSUSPECTED CONGENITAL HEART DEFECT IN PATIENT WITH DYSPNEA

Antonella La Marca¹, Antonino Davide Romano¹, Ripalta Amato¹, Vincenzo Manuppelli², Gianluigi Vendemiale¹

¹ Internal Medicine, Foggia, Italy

² Cardiology, Foggia, Italy

Introduction

An atrial septal defect is a birth defect of the heart in which there is a discontinuation of the interatrial septum. It is possible that such condition might not be diagnosed until adulthood. We report a case of undiagnosed atrial septal defect in a patient who referred to our unit due to an acute respiratory failure with an history of pulmonary thromboembolism currently treated with DOAC.

Case description

In the February 2019, a 35 years-old man with an acute respiratory failure was admitted to our Internal Medicine Unit. He reported fever with nocturnal dyspnea and thoracic pain.

Regarding his medical history, patient is a smoker and a welder with professional exposure to fine powders. He is on chronic oxygen

therapy since 2017 due to a diagnosis of Chronic Obstructive Pulmonary Disease. In November 2013, aging 29 years-old, he presented some similar clinical symptoms thus he underwent a pulmonary-perfusion scintigraphy with evidence of a small vessels perfusion defects like a pulmonary thromboembolism. Since such episode to date, he is on anticoagulant therapy with DOAC. Laboratory investigations demonstrated only a little inflammatory state with an increased level of C-reactive protein (90 mg/L; range 0–5 mg/L). Microbiological tests were positive for both H1N1 influenza virus and Haemophilus. Chest X-ray shows a COPD-like pattern with increased bronchovascular markings. A thoracic CT scan was performed with evidence of both bilateral ground glass opacifications and an important dilation of the pulmonary trunk and the right and left branches of pulmonary artery. Such findings were more deeply analyzed performing both transthoracic and a transesophageal echocardiography that finally demonstrated an atrial septal defect like “ostium secundum” with echo drop out.

Discussion

This case report highlights the importance of clinical reasoning in Internal Medicine. We firstly hypothesized an acute respiratory failure due to a COPD exacerbation. In consideration of both his young age and professional exposure to small powders, we performed a chest CT scan that revealed a very strange pattern, partially inconsistent with his pulmonary embolism history. The echocardiography finally challenged the diagnosis. Thus, the finding of a hole in the atrial septum with a cardiac shunt $sx > dx$, completely explaining the increased pressure in the vascular pulmonary system and the CT scan pattern. Finally, patient stopped his long-time antithrombotic therapy and referred to a heart surgeon consultation.

#2081 - Abstract

CARDIAC INVOLVEMENT IN PATIENTS WITH SYSTEMIC AMYLOIDOSIS

Elena Vladimirovna Reznik, Luan Nguyen, Elena Alexandrovna Stepanova, Igor Gennadievich Nikitin

Russian National Research Medical University, Moscow, Russia

Background

Amyloidosis can manifest as lesions of various organs, including the heart. Our aim was to analyze the cardiac involvement in patients with systemic amyloidosis (SA).

Methods

We retrospectively studied 38 patients with SA (63.2% females), confirmed by a morphological examination, including Congo red stain and polarized light. The median (interquartile range) of age was 72.5 (65.5–80.5) years.

Results

Left ventricular (LV) hypertrophy was in 94.1% of patients, 64.7% had interventricular septum and /or posterior LV wall thickness

of 15 mm or more. The LV ejection fraction (EF, Simpson) was 55 (48-56.1%). Reduced LV EF (<40%) was detected in 17.6%, mid-range (40%-49%) - in 11.8%, preserved (\geq 50%) - in 70.6% of patients. Mild or moderate mitral regurgitation had 82.4%, aortic regurgitation - 41.2%, tricuspid regurgitation - 76.5%, pulmonary regurgitation - 12.5% of patients. 23.5% of patients showed signs of granular sparkling myocardium appearance, 17.6% - regional LV wall motion abnormalities, 70.6% - pulmonary hypertension, 29.4% - LV diastolic dysfunction (17.4% - abnormal relaxation, 6% - pseudonormalization, 6% - restriction pattern), 17.6% - normal diastolic function (DF); 52.9% LV DF was not assessed. Symptoms and signs of chronic heart failure (CHF) were in 73.7% of patients: III NYHA class - in 67.9%, IV class - in 14.2%. 55.3% of patients had diagnosis of coronary artery disease, 81.6% - arterial hypertension, 31.6% - myocardial infarction in anamnesis. 50% of patients had low ECG voltage. Atrial fibrillation (AF) was detected in 39.5% of patients: in 15.8% - permanent, in 2.6% - persistent, in 21.1% - paroxysmal form. Conduction disorders were present in 26.3% of patients: atrioventricular (AV) block - in 10.5%, right bundle branch block (BBB) - in 18.4%, left BBB - in 18.4%. A pacemaker was implanted in 15.8%: due to a complete AV block in 8.3%, bradysystolic AF - in 5.6%, sick sinus syndrome - in 2.6% of patients. Cardiac autopsy was performed in 50% of patients. Amyloid deposition was found in 100%, heart weight was 457.5 (383-620) g. Coronary lesions were found in 63.2%: mild degree in 25% of them, moderate - in 33.3%, severe - in 41.7%.

Conclusion

Patients with the heart damage of unclear etiology, especially with severe LV hypertrophy, low ECG voltage, CHF with preserved LV EF, valvular regurgitation, idiopathic atrial fibrillation, conduction disturbance, should be screened for amyloidosis. Clinical alertness and lifetime diagnosis of amyloidosis is necessary.

#2141 - Medical Image

FIBRODYSPLASIA PROGRESSIVE OSSIFICANS - A BONE ARREST

Cleopatra Goric, Filipa Leitão, Joana Carvalho, Maria Eugenia Andre

Hospital Amato Lusitano, Castelo Branco, Portugal

Clinical summary

Female 51 years old, institutionalized, dependent on daily life activities with progressive ossificatory fibromyalgia, respiratory insufficiency under domiciliary oxygen supply, with history of several hospitalizations due to pneumonia. She was admitted to emergency room complaining of dyspnea, she presented cyanosis of the lips, marked muscular rigidity with predominance of the upper limbs.

Analytically, there was elevation of inflammatory parameters, type I respiratory failure in arterial blood gases and chest radiography suggestive of pneumonia. Patient was hospitalized for pneumonia, initiated intravenous antibiotic therapy. On the 2nd

day of hospitalization, there was worsening of the clinical state with hemodynamic instability. She died on the 3rd day after admission.

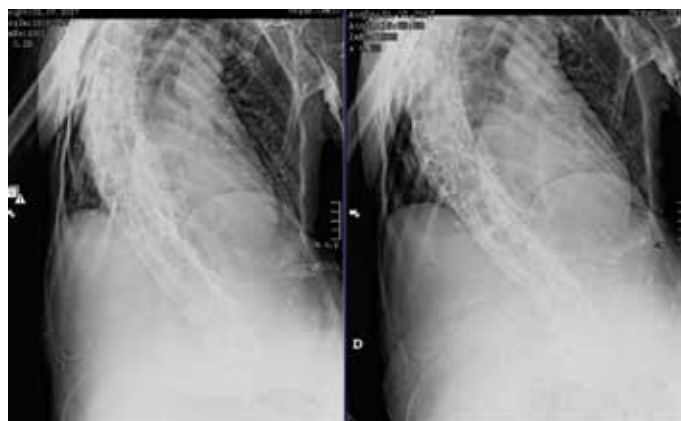


Figure #2141.

#2150 - Case Report

OSSEOUS TUBERCULOSIS IN PATIENT WITH LANGERHAN'S CELL HISTIOCYTOSIS

Meriem Kermiche, Yacine Kitouni, Daoud Roula

University Hospital Center, Constantine, Algeria

Introduction

Langerhan's cell histiocytosis (LCH) is a rare disease of unknown origin. The disorder ranges in clinical severity from a solitary lesion of bone to a generalized disease with multiple organ involvement. Rarely, LCH has been reported to be associated with some disorders such as pulmonary tuberculosis.

Case description

A 25-year-old female patient with type 1 diabetes mellitus was hospitalized due to complaints of chest pain and the shoulder, physical examination of respiratory system and other systems were normal, Chest computed tomography revealed an osteolytic lesion of the sternum with a mediastinal tissue mass, the biological assessment showed an accelerated sedimentation rate with a positive, tuberculin skin test was negative, the histologic examination of a surgical microbiopsy of the sternal mass demonstrate a large infiltration of lymphocytes and langerhans cells with rares eosinophiles. Immunohistological study showed CD 1a protein positives. the diagnosis of langerhans cell histioytosis was retained, positron emission tomography revealed other bone lesions (left acetabulum, right scapula and dorsal vertebra). The patient was put on corticosteroid: prednisone 1 mg / kg / day for one month and then progressive degeneration with a clear regression of the mass in six months, five months later the patient presented a paraparesis due to osteolytic lesions of thoracic vertebrae, the histological study of the biopsy confirmed the diagnosis of tuberculosis.

Discussion

Langerhans' cell histiocytosis is a rare disease, it can occur at any age but is more frequent in children, its clinical presentation is

variable and ranges from isolated skin or bone disease to a life-threatening multisystem condition. Skeletal involvement is the most commonly involved organ, but in rare cases, it has been reported in the sternum. LCH has been associated with certain other diseases but it has been rarely reported to be associated with chronic infectious disease like tuberculosis, it should be considered as the main differential diagnoses for multifocal lytic bony lesions. Although these two diseases have a relatively similar radiological pattern of bone involvement, a histological confirmation is essential for the definite diagnosis of histiocytosis or tuberculosis.

#2219 - Case Report

SPECTRUM OF PSEUDOHYPOPARATHYROIDISM ASSOCIATED DISEASES - A CASE REPORT

Inês Cunha, Joana Andrade, Vera Romão

Centro Hospitalar Tondela Viseu, Viseu, Portugal

Introduction

Pseudohypoparathyroidism (PHP) and associated diseases are extremely rare (with estimates of 0.34-1.10 cases of PHP per 100.000). They are characterized by endocrine, bone and neurocognitive abnormalities.

Case description

We report a case of a 48-year-old woman with a history of arthralgias affecting shoulders, metacarpophalangeal joints, interphalangeal distal and proximal joints and lumbosacral spine. Physical examination revealed multiple metacarpophalangeal and interphalangeal joint deformities with brachydactyly and nasal hypoplasia. Those changes were congenital and her brother shared similar deformities.

She had a slightly increased rheumatoid factor (21.9 IU/ml), negative anti-cyclic citrullinated peptide antibody, C-reactive protein, sedimentation rate, antinuclear antibodies and HLA-B27 and normal ionized and urinary calcium, phosphorus, vitamin D level, parathyroid hormone (PTH) and thyroid function.

Hand radiographs revealed osteopenia, arthroses, erosions and brachydactyly. Radiologists concluded that the radiographs were suggestive of the following diagnostic hypotheses: pseudohypoparathyroidism (PHP), pseudopseudohypoparathyroidism (PPHP) or acrodysostosis, entities of the same spectrum that share several characteristics, making it difficult to distinguish between them.

Discussion

PHP is characterized by PTH and thyroid stimulating hormone (TSH) resistance, with hypothyroidism manifestations, brachydactyly, ectopic ossification, cerebral calcifications, childhood obesity and, in some cases, short stature and cognitive deficit.

PPHP is a similar entity, but it is distinguished by the absence of

resistance to PTH and TSH, more frequently ectopic ossification and it is not associated with obesity.

Acrodysostosis is characterized by variable resistance to PTH and TSH, skeletal dysplasia, brachydactyly, facial dysostosis, nasal hypoplasia, short stature, obesity and, in some cases, developmental delays and cognitive deficit. Unlike the others, it is not associated with ectopic ossification.

The case described was a diagnostic challenge due to the rarity of these entities and the overlap of characteristics between them. It is also an example of how important anamnesis is, including family history and the physical examination of the patient's physiognomy, and the conjugation with imaging exams and a multidisciplinary approach.



RESPIRATORY DISEASES

#119 - Case Report

RESPIRATORY INFECTION WITHOUT MICROORGANISM: NON-INFECTIOUS PNEUMONIA

Victoria Palomar, Sara Muñoz, Víctor Madrid, Carlota Tuñón, Cristina Martín, Luis Miguel Palomar
Complejo Asistencial de Zamora, Zamora, Spain

Introduction

A 38-year-old man who is smoker, mechanic, has a cat, no contact with birds comes to the emergency with cough and low expectoration, intermittent fever and dyspnea of two months of evolution.

Case description

In physical exploration we found low-grade, oxygen saturation = 90 % and pulmonary auscultation with rhonchi in left hemithorax.

- Income analysis: Eosinophilia 23.5%. Altered coagulation. PCR 82.6, VSG 52. GAB: global respiratory failure. IgE 1963. Eosinophils were elevated from 2.2 to 4.5 x10³ / m.
- Chest x-ray: Increase in density compatible with left hemithorax infiltrate.

The patient enters Pneumology receiving treatment with levofloxacin and ceftriaxone.

- Serology: HIV and Legionella negative s . *M. Pneumoniae* and *C. Pneumoniae* IgG positive
- Autoimmunity: negative.
- Smears: Mature eosinophils.
- Legionella and pneumococcus antigen: negative.

The patient remains stable but without radiological improvement and fever of 39 °C, so it is decided to perform bronchoscopy: scarce mucus in bronchial trees. Bronchoaspirate: No BAAR. Negative aerobic culture. Cytology: Negative for malignant cells, nonspecific.

We change piperacillin tazobactam which maintains low-grade.

High resolution computed tomography: multiple patched areas of condensation, air bronchogram, peripheral predominance and areas in ground glass in left hemithorax and LS. Mediastinal lymph nodes.

Discussion

Pulmonary eosinophilia=pulmonary infiltrates + blood/pulmonary

eosinophilia. Abnormal eosinophilia >350 eos/μl in peripheral blood 5% in bronchoalveolar lavage (BAL). BAL is most useful test without the need for histological confirmation in the majority.

Clinical-radiological picture, eosinophilia in BAL and/or blood, early response to corticoids and exclusion of other causes of eosinophilia usually are enough for diagnosis. Doubtful cases: pulmonar or transbronchial biopsy .

Must exclude eosinophilia secondary to drugs, parasites or systemic diseases such as vasculitis, collagenosis or malignant disease, fungal infections. Obstructive or restrictive ventilatory alteration in respiratory function tests. In chest X-ray and tomography: peripheral pulmonary infiltrates in upper 2/3 of lung fields, bilateral and ground glass pattern. Treatment = corticoids in the majority.

After persisting important peripheral eosinophilia, corticosteroids are added to the suspicion of chronic eosinophilic pneumonia, presenting a significant improvement and decrease in infiltrates and disappearance of eosinophils.

#125 - Medical Image

A RARE COMPLICATION OF A FOOTBALL MATCH

Carolina Vasconcelos Barros, Carolina Morna, Mariana Gomes, Teresa Faria, Luz Brazão
Hospital Central do Funchal, Funchal, Portugal

Clinical summary

A 25-year-old young male presented to the emergency department with a persistent retrosternal chest pain and neck swelling. The pain had begun 9 hours earlier, after a scream celebrating a goal at a football match, radiating continuously to the neck and being exacerbated by deep inspiration. On clinical examination, he had normal breath sound on pulmonary auscultation, but the presence of a crunching sound synchronous with heart beat was noted on the cardiac auscultation and the presence of crepitus on the palpation of the supraclavicular fossa bilateral. Investigations revealed a chest radiograph with the presence of bubbles of gas extend into the neck and the absence of a pneumothorax. A thoracic CT confirmed the diagnosis of spontaneous pneumomediastinum.

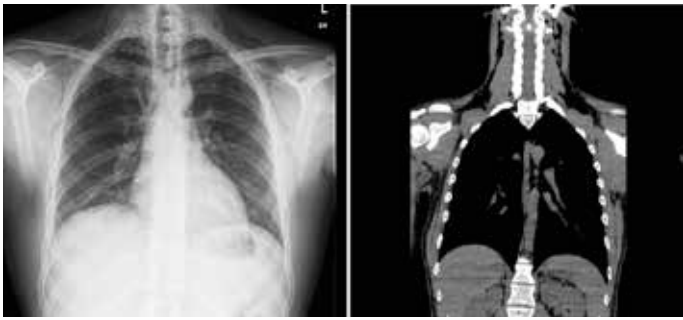

Figure #125.

#130 - Abstract

ADHESION MOLECULES AS BIOMARKERS IN EXACERBATION OF UNCONTROLLED NON-ALLERGIC ASTHMA IN ADULTS

Natalia Lyubavina, Ekaterina Makarova, Galina Varvarina, Lyubov Tyurikova, Nikolay Menkov
FSBEI HE PRMU MOH Russia, Nizhny Novgorod, Russia

Background

Asthma is a disease, characterized by chronic airway inflammation. Adhesion molecules CD50 and CD54 of immune cells provide contact of immune cells during of the immune response. The significance of their soluble forms (sCD50 and sCD54) in the pathogenesis of non-allergic asthma is currently actively studied.

Methods

We have examined 50 patients with exacerbation of uncontrolled non-allergic asthma. The moderate asthma was diagnosed in 25 patients, the severe asthma – in 25 patients (by GINA 2018). Serum levels of sCD50, sCD54 molecules were determined by EIA, the results are presented in U/ml. Serum samples of patients were compared with serum samples of 30 healthy donors. All patients received ICS/LABA, nebulised budesonide 1000 - 1500 mcg and systemic GCS. Patients with severe asthma received prednisolone more than 30 mg/day more than 7 days, patients with moderate asthma received less than these indicators. Patients with purulent sputum had a course of antibiotics.

Results

70% of patients with exacerbation of non-allergic asthma had cough with sputum. The sputum was purulent in severe asthma and the level of neutrophils in sputum was 49[12;80] versus 22 [4;30] with moderate asthma ($p=0.049$). Patients with moderate asthma had the level of ESR 13 [3;16] versus 18 [8;28] mm/h with severe asthma ($p=0.02$). There was an increase serum levels of sCD50 (416[326;562], $p=0.01$) and sCD54 (73[62;209], $p=0.03$) in patients with severe asthma. We found the correlation between FEV1 and levels of sCD50 and sCD54 ($r_1=-0.44$ $p_1=0.02$; $r_2=-0.4$ $p=0.02$). After treatment production of sputum decreased and was detected only in 30% of patients; and the number of sputum neutrophils decreased to 20 [10;40] ($p=0.0001$). The level of ERS became normal in patients with severe asthma. On

the background of longer treatment severe asthma with systemic GCS and antibiotics was observed normalization of the level sCD54 (299[30;364], $p=0.03$) and sCD50 (61[48;125], $p=0.01$).

Conclusion

An increase of serum levels of soluble adhesion molecules (sCD50, sCD54) and the correlation between levels sCD50, sCD54 and FEV1 were found in severe uncontrolled non-allergic asthma. High serum levels of sCD50, sCD54 can be considered as markers of severe uncontrolled non-allergic asthma in adults. Antibiotics, IGCS and systemic GCS lead to the normalization of increased serum levels of sCD54, sCD50 in patients with exacerbation of severe uncontrolled non-allergic asthma.

#149 - Abstract

PULMONARY EMBOLISM: A SILENT DISEASE

César Ricardo Coimbra De Matos¹, Rui Marques², Inês Frois Cunha², Margarida Neto³, Ana Maria Pinto⁴, António Assunção⁵

¹ UCSP Azeitão, Setúbal, Portugal

² Centro Hospitalar Tondela-Viseu, Viseu, Portugal

³ Centro Hospitalar de Setúbal, Setúbal, Portugal

⁴ USF Lusitana, Viseu, Portugal

⁵ USF Viriato, Viseu, Portugal

Background

In spite of the increase of knowledge and therapeutic options for control of risk factors, pulmonary embolism remains a frequent cause of admissions at hospitals and high mortality and morbidity of patients.

Methods

The purpose of this study is to characterize patients with pulmonary embolism admitted at the Coronary Intensive Care Unit of a Central Hospital based on demographic data, clinic situation, risk factors and intervention. This study also intend to compare admission rates between patients with anticoagulants, anti platelet agents and without none of these drugs. Pulmonary hypertension analysis was made based on risk factors and previous therapy.

This is a quantitative, descriptive, cross-sectional and retrospective study on patients with pulmonary embolism. The data was collected during 2017 at the referred care unit. The comparative analysis is based on descriptive and inferential statistics.

Results

A total of 23 patients was diagnosed with pulmonary embolism, the majority caucasian female patients (60,9%) with an average age of 72,3±13,7 years. Among risk factors, the presence of previous diagnosis of arterial hypertension in 47,8%, diabetes in 13%, dyslipidemia in 60%, venous insufficiency in 40%, smoking habits in 26%; only one patient has made full genetic workup of predisposing factors identifying Factor V Leiden's mutation. At

admission, 11,1% of patients present an ejection fraction below 40% and none of them had previous history of acute myocardium infarct, cardiac insufficiency or previous pulmonar embolism. About 34,7% of patients were under antiplatelet therapy and 8,7% under new oral anticoagulants (NOACS). D-dymers were quantified at admission with an average of 2808 ug/L. Intra hospital mortality rate was 13%. The lenght of stay at hospital was 2 days in patients under NOACS, 3,6 days in patients under anti platelets and 4,1 days in patients without any therapy. Pulmonary artery systolic pressure was greater than 25 mmHg at rest in 86,7% of patients presenting the following risk factors: previous diagnosis of arterial hypertension in 40 %, diabetes in 40 %, dyslipidemia in 21,6%, venous insufficiency in 21,4%, smoking habits in 13,3%.

Conclusion

The knowledge of local data of pulmonar embolism and the importance of each risk factors allows to adopt better strategies that can improve treatment and prevention of these events. An improvement in anticoagulation options has showed a decrease in relapses and mortality.

#170 - Medical Image

MEDIASTINAL LARGE B-CELL LYMPHOMA PRESENTED BY AIRWAY OBSTRUCTION

Adriana Bandeira, Joana Gonçalves, Luis Pereira
Centro Hospitalar de Leiria, Leiria, Portugal

Clinical summary

78 years old male patient presenting in the ER with a progressive history of breathlessness and cough, was admitted for further studying.

CT scan showed a large medial-posterior mediastinal mass surrounding the carina and main bronchial structures conditioning airway compression. Biopsies were conducted via rigid bronchoscopy, dilation was performed and distal segments were seen permeable motivating an unsuccessful attempt to place a Y prosthesis, causing respiratory distress and requiring invasive mechanical ventilation. Biopsy of the mass was compatible with diffuse large B-cell lymphoma and a 3-days cycle of cyclophosphamide and steroids resulted in significant endoscopic improvement with ventilatory weaning and extubation occurring without interurrences.

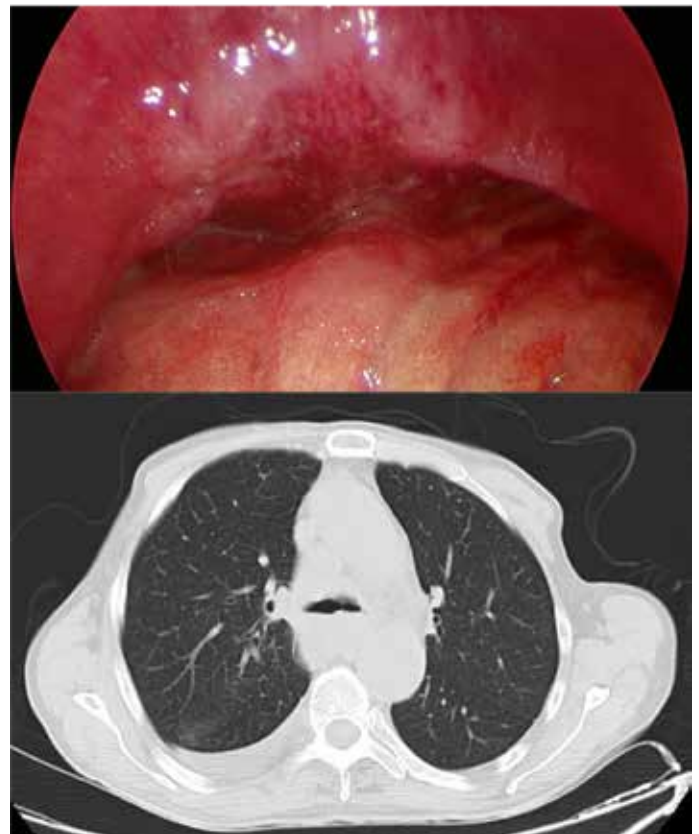


Figure #170. Bronchoscopy and CT scan of the carina.

#179 - Case Report

NOT EVERYTHING THAT COUGHS IS FIBROSIS!

Juliana Sofia De Jesus Barata, Roberto Silva, Mafalda Baptista, Sara Martins, Ana Craveiro, Eunice Magalhães
Centro Hospitalar Universitário da Cova da Beira, Covilhã, Portugal

Introduction

Pulmonary fibrosis is a progressive and chronic irreversible pathology whose main clinical manifestations are dry cough and exertional dyspnea.

Case description

The authors present a patient, male, 76 years old, former worker in a polishing and wood varnishing plant, sulfate, diabetic, former smoker followed in pneumology consultation since 2012 for chronic phase hypersensitivity pneumonitis with diffuse pulmonary fibrosis and partial respiratory failure without stable OLD criteria.

In 2014, due to symptomatic aggravation and functional ventilatory, he started systemic corticosteroid therapy with good response and without intercurrent aggravations. In June 2017, there was a new symptomatic aggravation, with MRC3 effort dyspnea and productive cough of abundant mucus sputum, as well as imaging, with increased areas of honeycomb at the level of high-resolution computed tomography of the chest.

Although increased corticosteroid dose and combination

of azathioprine and pregabalin maintained aggravated symptomatology. The patient eventually accepted to perform videobronchofibroscopy, whose microbiological study of bronchoalveolar lavage revealed the presence of *Candida albicans*, CMV and *Pneumocystis jirovecii*. The patient was treated with cotrimoxazole, fluconazole, ganciclovir with progressive improvement.

Discussion

In the case presented, although the clinical-functional and imaging aggravation was compatible with the progression / exacerbation of known pulmonary fibrosis, the aggravation was due to infection by opportunistic agents, with a significant improvement after adequate therapy.

We present the case in order to alert clinicians to the need that often arises in extending the etiological study to what appears to be the natural evolution of a pathology (in this case pulmonary fibrosis

#183 - Case Report

PNEUMONIA BY PNEUMOCYSTIS JIROVECII IN IMMUNOCOMPETENT PATIENT

Juliana Sofia De Jesus Barata, Roberto Silva, Mafalda Baptista, Sara Martins, Ana Craveiro, Eunice Magalhães
Centro Hospitalar Universitário da Cova da Beira, Covilhã, Portugal

Introduction

Pneumonia by *Pneumocystis jirovecii* is a potentially fatal infection that occurs in immunocompromised patients such as patients with human immunodeficiency virus (HIV), neoplasms, corticosteroids and immunosuppressive drugs. However in immunocompetent patients this entity is rare.

Case description

The authors present the case of a patient, male gender, 63 years old, former farmer, diabetic, passive smoker for 35 years with clinical condition with 2 years of evolution characterized by hyperthermia (maximum 38°C) of morning and evening predominance that gave paracetamol and sporadic dry cough unrelated to the circadian cycle. At the beginning of the symptomatology (in January 2015), the patient was admitted to the infectious department where he underwent antibiotic therapy with doxycycline and later with levofloxacin, and a complementary computerized chest tomography (CT-Thorax) revealed a diffuse increase of the density of the lung parenchyma with pattern in geographic chart and diffuse poorly defined reticular pattern. The patient was submitted to videobronchofibroscopy and the microbiological and anatomopathological study of the bronchial aspirate and the broncho-alveolar lavage were negative. He maintained symptomatology and follow-up in consultation, with apparent resolution of the condition during the year 2016. However, in January 2017 recurrence of the symptomatology and the CT-Thorax presented ill-defined nodular appearance with ground glass opacifications and the patient was again submitted to videobronchofibroscopy whose study of *Pneumocystis jirovecii*

was positive. The patient started treatment with cotrimoxazole at full resolution.

Discussion

We present the case of *Pneumocystis jirovecii* infection in an immunocompetent patient, because it is a rare cause of undetermined febrile syndrome, little described in the literature.

#185 - Medical Image

DIFFUSE ALVEOLAR HEMORRHAGE AND WARFARIN THERAPY

María Elena Mansilla Rodríguez, Ana Fulgencio Delgado, Sindy Berenice Cedeño De Jesús, Blanca Hidalgo Armayones
Hospital Infanta Elena, Huelva, Spain

Clinical summary

We present the clinical case of a 73-year-old patient with a DDDR pacemaker and chronic atrial fibrillation anticoagulated with Warfarin who comes to the Emergency department for hemoptysis and tachypnea of 24 hours of evolution. The Blood tests show anemia, INR 3,4 and hypoxaemic respiratory insufficiency. The chest X-ray showed areas of consolidations with air bronchogram and ground-glass pattern, in both lung fields with greater extension in the anterior segment of LSD and LID in relation to occupation of the distal airway compatible with the suspected hemorrhage alveolar, which was confirmed with the chest TC. Diffuse alveolar hemorrhage is a rare and serious complication of warfarin. Strict control of the INR is required to avoid bleeding and complications arising from its overdose.

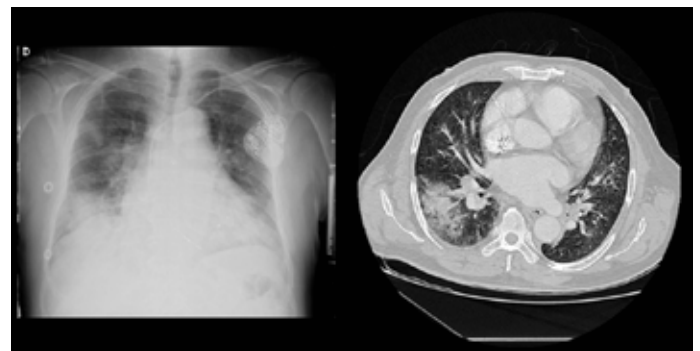


Figure #185. Left: Chest X ray. Right: TC Chest.

#192 - Medical Image

A CASE OF A PRIMARY SPONTANEOUS PNEUMOTHORAX

Daniela Casanova, Ana Luisa Campos, David Paiva, Ana Teresa Gonçalves, Isabel Trindade, Jorge Cotter
Hospital Senhora da Oliveira, Guimarães, Portugal

Clinical summary

A 24-year-old man, football player and smoker of 2 pack-year. Admitted on the emergency department with pleuritic thoracic

pain, with onset after extreme exercise. Without dyspnea or trauma associated. Radiolucent image on left hemithorax without lung markings was documented in chest radiography. In the computed tomography at admission it was described a massive left pneumothorax with atelectasic lung associated. Thoracic drain was placed and oxigenotherapy was started. With positive clinical and radiographic evolution. The patient became asymptomatic and with hemodynamic stability, and had clinical discharge with reevaluation scheduled in one month.

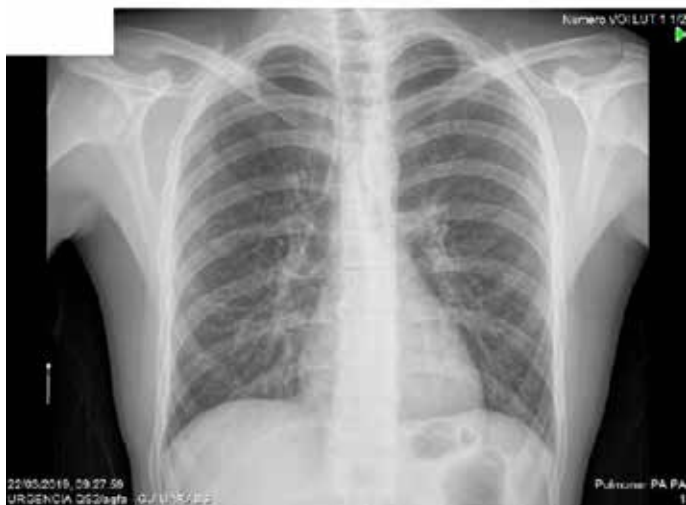
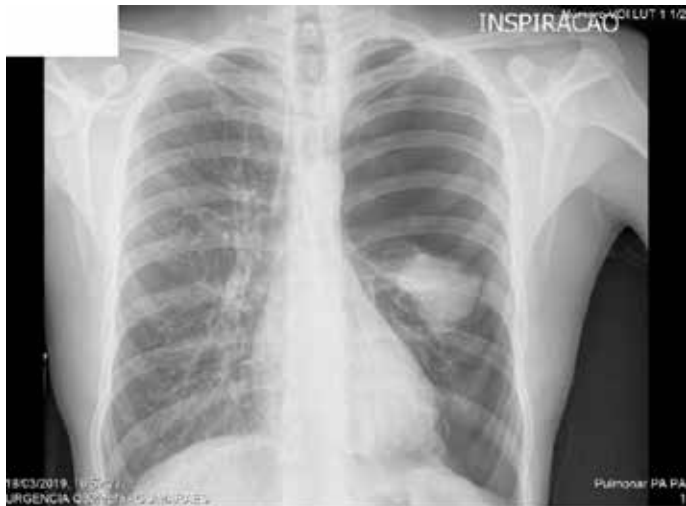
Figure #192. Chest radiography performed at admission (above) and at discharge (below).

#201 - Abstract

THE INFLUENCED FACTORS AND PROGNOSIS OF CANDIDA COLONIZATION IN THE RESPIRATORY TRACT IN PATIENTS WITH HOSPITAL-ACQUIRED PNEUMONIA

Ding-Yun Feng, Yu-Qi Zhou, Tian-Tuo Zhang

Third Affiliated Hospital of Sun Yat-sen University, Guangzhou, China

Background

Candida is one of the most common pathogens in nosocomial

infection. Hospital-acquired pneumonia (HAP) as the leading nosocomial infection often has candida colonization in the respiratory tract. And the influenced factors and need for intervention of candida colonization is controversial in HAP. The objective of this study was to describe the epidemiology of candida colonization, find the influenced factors and prognosis of candida colonization in the respiratory tract in patients with HAP.

Methods

HAP patients with sputum culture-positive were identified from the patients hospitalized during the period from 1 January 2014 to 31 December 2017 in university affiliated hospital. The relevant data were reviewed and analyzed retrospectively.

Results

There were 362 cases was bacterial or fungi culture-positive, and 121 cases (33.4%) were Candida. All cases were divided into subgroups: candida colonization group and no candida colonization group. Multivariate analysis indicated that several factors including stomach tube intubation, low blood urea nitrogen/ blood albumin levels, infection with pseudomonas aeruginosa or acinetobacter baumannii, and surgery were independently associated with candida colonization in the respiratory tract in patients with HAP. The candida colonization group received antifungal therapy significantly, but the length of stay and 30-day mortality of both groups had no statistical differences.

Conclusion

Candida colonization in the respiratory tract is common, particularly in patients with some influenced factors. The benefit of antifungal therapy for candida colonization in HAP is negative.

#213 - Abstract

DIAGNOSTIC APPROACHES TO TUBERCULOUS LYMPHADENITIS - A RETROSPECTIVE STUDY

Cristina Braço Forte, Ana Alfaiate, Susana Carreira, Susana Sousa, Vitor Santos, Paula Duarte

Pneumology Department, Hospital de São Bernardo, Centro Hospitalar de Setúbal, E.P.E., Setúbal, Portugal

Background

Tuberculous lymphadenitis is the most common form of extrapulmonary *Mycobacterium tuberculosis* infection. Nevertheless, diagnosis may not be easy, given the lack of specific presentation, the need for tissue sampling, non-specific pathological findings and the relatively low microbiological yield.

Methods

Retrospective assessment of the diagnostic approaches to tuberculosis (TB) lymphadenitis at an Urban Chest Disease Center (UCDC), in Portugal, over a period of 9 years.

Results

From 2009 to 2017 all the patients were referred to UCDC after diagnosis, either to start or continue treatment. The study included 32 patients with TB lymphadenitis, 21 females (65.6%), with a mean age of 50.2 years.

There were 14 (43.8%) cases of cervical, 13 (40.6%) of axillary, 4 (12.5%) of supraclavicular, and one case of submandibular lymphadenopathy. All patients were tested for human immunodeficiency virus (HIV) and 8 (25%) tested positive.

Collection of lymph node tissue was performed through fine-needle-aspiration cytology (FNAC) in 27 (84.4%) and through excision in 5 (15.6%).

The cyto/histological analysis was suggestive of tuberculous lymphadenitis in 32 patients. A microbiological analysis was performed on 22 cases, with a positive smear in 5/22 patients (22.7%), a positive culture in 19/22 (86.4%) and a positive nucleic acid amplification test (NAAT) in 11/13 (84.6%). They all had a positive response to anti-bacillary treatment.

Conclusion

We found a predominance of women with cervical and axillary tuberculous lymphadenitis, as described in the literature. In this study, it becomes clear that in the approach to lymphadenitis it is still not routine to send lymph node samples for both cyto/histological and microbiological analyses.

These results strengthen the need for increased suspicion of TB lymphadenitis and for utilization of a combination of cytology/histology and microbiology in diagnostic approaches to lymphadenitis.

#219 - Abstract

ACUTE PULMONARY THROMBOEMBOLISM – THE REALITY OF A PORTUGUESE HOSPITAL

Carina Rôlo Silvestre, Daniel Duarte, Ricardo Cordeiro, Teresa Vilaça, Ivone Barracha, Rosa Amorim
Centro Hospitalar do Oeste, Torres Vedras, Portugal

Background

Pulmonary embolism (PE) presents with a wide clinical spectrum, from asymptomatic to potentially lethal condition. Early diagnosis and the correct therapeutic approach are crucial to a successful outcome.

Methods

Retrospective study of all patients presenting with acute PE from January 2016 to December 2018.

Results

134 patients were included, 61.3% were women, with a median age of 77 years old, 36.6% of whom had more than 80. The most frequent risk factors were chronic cardiac failure (28.4%), active cancer (25.4%), smoking habits (21%) and COPD (18.7%). At presentation the majority had more than one symptom, the most

commons being dyspnea (59%), excessive tiredness (19.4%) and chest pain (18.7%). On admission, 22.4% of the patients were hypotensive, these patients had greater D-dimer values ($p=0.023$). Chest radiograph was abnormal in 55.2%, the most common findings were infiltrates in 63.5% and pleural effusion in 20.3%. The most common electrocardiographic findings were sinus tachycardia (28.7%) and atrial fibrillation (17.9%). Arterial blood gas showed hypoxemia in 32% and hypoxemia and hypocapnia with normal pH in 26%. Echocardiogram showed acute findings in 54% of the cases. CT pulmonary angiography showed central PE in 46.8% of the cases and peripheral in 53.2%. Among patients submitted to venous doppler of the lower limbs (60.4%), 24.6% had evidence of deep vein thrombosis (DVT). Women were 8.4 times likely to have DVT than men. Evaluating the pre-test probability of PE with the revised Geneva score showed 12.7% with high probability and 69.4% with intermediate. The PE Severity Index (PESI) stratified 45.5% of the patients in very high and 23.9% in high risk of PE. Of note, 5% of patients initiated anticoagulation with unfractionated heparin and 95% with enoxaparin, 1.5% had thrombolytic treatment. About 3.7% were transferred to intensive care unit. The mortality was 8.2%. Patients with provoked PE had 3.8 more times likely to die than the patients with no provoked PE ($p=0.037$). Mortality was higher in older patients ($p=0.05$) and high risk in PESI score ($p=0.05$), but only 11% of high risk group died.

Conclusion

This study confirms the high prevalence of the diagnosis of PE. Contrary to the expected, the main associated co-morbidity, considering the high age of the patients, was not the physical dependence nor the fact that they are bedridden, but chronic disease with modifiable factors. There was also a low mortality rate when compared to the risk and mortality scores applied.

#294 - Case Report

ACUTE EOSINOPHILIC PNEUMONIA - NOT ALL LUNG INFILTRATES ARE INFECTIONS!

Flávio Pereira¹, Joel Pinto¹, Daniela Meireles¹, Ana Rafaela Araújo¹, Susana Cavadas¹, Carla Nogueira²

¹ Centro Hospitalar do Baixo Vouga, Aveiro, Portugal

² Centro Hospitalar Vila Nova de Gaia/Espinho, Vila Nova De Gaia, Portugal

Introduction

Acute Eosinophilic Pneumonia (AEP) is a rare disease, that affects more frequently men between 20 and 40 years of age, without history of asthma. Patients present with an acute febrile illness characterized by dyspnea, nonproductive cough with severe hypoxaemia, diffuse pulmonary infiltrates and an increase in bronchoalveolar lavage (BAL) eosinophils. Most patients with AEP improve rapidly with glucocorticoid therapy.

Case description

A 35 year-old-man presented at Pneumology appointment with a

3-week history of productive cough, fever, dyspnea (mMRC grade 1), night sweats, asthenia, anorexia and weight loss (approximately 6%). His past medical history was not relevant, with no previous atopic illness. He was initially treated for community acquired pneumonia with amoxicillin/clavulanate (7 days) and clarithromycin (3 days). General physical examination revealed rhonchi on upper third of left hemithorax. Blood investigations revealed leucocytosis ($11.15 \times 10^3/\mu\text{L}$) with eosinophilia ($5.15 \times 10^3/\mu\text{L}$), very high erythrocyte sedimentation rate (113 mm/hr), elevated C-Reactive protein (15.49 mg/dL) and IgE (369 IKU/mL). The chest radiograph showed opacities in both upper lobes. High resolution computed tomography scan was characterized by reticular opacities in both upper lobes, predominantly in left side. Auto-immune study was negative. Sputum cultures were negative. In 3 weeks follow-up appointment patient's chest radiograph revealed only upper left lobe opacity. Patient did a transbronchial lung biopsy which revealed alveolar septum thickening and lymphocytic and eosinophilic inflammatory infiltration, without any other changes. AEP was suspected, and patient started prednisolone (40 mg/day for 15 days, then reduced to 30 mg). After 5 weeks of glucocorticoid therapy the patient experienced complete resolution of symptoms and abnormalities on the chest radiograph.

Discussion

Some investigators have suggested that AEP is an acute hypersensitivity reaction to an unidentified inhaled antigen. It is very important to exclude alternative causes of pulmonary eosinophilia. Systemic glucocorticoid therapy represents the mainstays of treatment. After the initiation of treatment, the clinical and radiologic response is often rapid. Long term prognosis is excellent, and recurrence rarely occurs after completion of therapy.

#299 - Case Report

EXTRAPULMONARY TUBERCULOSIS AND LYMPHOMA

Culacsiz Simona¹, Ioan Anton Arghir¹, Cristina Cioti¹, Andreea Georgiana Stoica¹, Mihaela Maria Ghinea¹, Zizi Niculescu¹, Elena Dantes², Oana Cristina Arghir²

¹ Faculty of Medicine, Constanta, Romania

² Constanta Pneumophthysiology Hospital, Constanta, Romania

Introduction

TB and malignant non Hodgkin's lymphoma are important leading causes of death worldwide. Both Burkitt lymphoma and EPTB are related with impaired immunity, being more frequent among HIV infected people.

Case description

Two cases of bilateral pleural effusions and ascitis are reported in 2 nonHIV infected females. A 26 year-old apparent healthy female, without previous Epstein-Barr infection, was diagnosed

with Burkitt lymphoma and another one, 27 year-old, with vitiligo, identified with left subapical shadows and left pleural effusion, 5 month ago, investigated for abdominal pain and polycystic ovary syndrome, was lately diagnosed with both pulmonary and extrapulmonary (EP) tuberculosis (TB), having a very good evolution under antiTB therapy.

Discussion

EPTB with both pleural and peritoneal involvement is rare among nonHIV infected individuals and vitiligo can be considered an immunosuppressive condition. Five month delayed diagnosis of pulmonary and extrapulmonary TB in a 28 year-old female is attributed to chronic abdominal pain and polycystic ovary syndrome.

#332 - Case Report

THE LUNG LOST TO TUBERCULOSIS

Catarina Cascais Costa¹, Lília Andrade¹, Andreina Vasconcelos¹, Joana Costa², Alcina Saraiva¹

¹ Centro Hospitalar Baixo Vouga, Aveiro, Portugal

² Centro Hospitalar Universitário de Coimbra, Coimbra, Portugal

Introduction

Tuberculosis, a contagious disease caused by Mycobacterium tuberculosis, with a 2% declining incidence per year, according to WHO, remains the leading cause of infectious deaths, in the world. The present clinical case aims to highlight some diagnostic difficulties and the impact of its sequels.

Case description

The authors present the case of a 21 years old female, with autism, oligofrenia and psychomotor agitation. She had an history of bronchial asthma and recurrent respiratory infections since childhood. In this context, a thoracic CT was performed in 2007, which showed "... right pulmonary apical fibrosis..." suggestive of a previous infection sequelae. She received treatment for respiratory infections in 2010, twice with amoxicillin-clavulanic acid and once with clarithromycin and levofloxacin. She had a fifth hospital entry in 2010 with fever, productive cough, wheezing, dyspnea, signs of respiratory distress and decreased vesicular murmur in the lower two thirds of the right hemithorax. Thoracic radiography revealed an unilateral heterogeneous air space opacification, with air bronchogram throughout the right pulmonary hemithorax, with homolateral deviation of mediastinal structures. Peripheral blood samples showed leukocytosis, elevated sedimentation rate and C-reactive protein. Pulmonary CT scan showed "reduction of the volume of the right lung field, with large areas of atelectasis...". It was impossible to obtain patient cooperation to collect sputum, so with her mother's agreement, a gastric juice specimen was collected to look for acid-fast bacteria. The direct examination was negative but BK-PCR culture was positive. The patient completed six months of antibacillary therapy. Between 2011 and 2013 she had three episodes of respiratory infection per year, the frequency of which decreased after initiation of prophylactic

therapy with azithromycin in 2013. Thoracic radiography changed over time and in 2014 there was a total opacity of the right lung field with mild air bronchogram and homolateral retraction of the mediastinum compatible with a “destroyed lung”.

Discussion

The previously taken antibiotic therapy may have delayed pulmonary tuberculosis diagnosis and allowed disease evolution, since all given antibiotics are partially effective against *Mycobacterium tuberculosis*.

This clinical case illustrates a “destroyed lung” the most severe form of pulmonary tuberculosis involvement, which in itself can lead to repeated infections debilitating general patient’s health.

#333 - Case Report

COMMUNICATION ERROR

Catarina Cascais Costa¹, Gilberto Teixeira¹, Lília Andrade¹, Andreína Vasconcelos¹, Joana Costa², Alcina Saraiva¹

¹ Centro Hospitalar Baixo Vouga, Aveiro, Portugal

² Centro Hospitalar Universitário de Coimbra, Coimbra, Portugal

Introduction

Intra-thoracic gastro-intestinal fistula is a communication between esophagus and pleural space or bronchi, being esophageal-pulmonary fistulae the most frequent ones. They are rare conditions that may be associated with neoplasms, infectious conditions as in tuberculosis or esophageal herniation caused by the chemical damage of acidic and digestive enzymes. Inconstant and non-specific symptoms make diagnosis difficult.

Case description

The authors describe of a 77-year-old female patient case that went to the hospital with complaints of productive cough and dyspnea with an evolution of 4 days. She had a several years evolution history of dysphagia and microcytic hypochromic anemia. An upper digestive endoscopy showed non-neoplastic esophageal ulceration associated with massive hiatus hernia.

She had elevated respiratory rate (16 cycles per minute) and desaturation (SpO₂ 84%) despite oxygen therapy with 1.5l/min. Thoracic radiography showed an hydropneumotorax in the right pulmonary hemithorax. A thoracentesis was performed and a thoracic drainage placed with large yellowish thick fluid drainage, compatible with empyema. Fluid biochemistry had exudate characteristics, confirmed by Light’s criteria, with pH 7.22 and increased amylases (5423 IU / L). She was hospitalized under wide-spectrum antibiotic therapy without clinical improvement. The presence of food residues in the drainage tube led to perform a thoracic computed tomography (CT) scan which presented a fistulous path between esophagus and pleural space.

Discussion

Communication between esophagus and pleural space can be frequently seen in CT.

In this clinical case, the most probable etiology to this continuity solution between the digestive and respiratory structures is the esophageal mucosa ulceration and fragility associated to the hiatal hernia.

#363 - Case Report

AN UNUSUAL CAUSE OF CHRONIC COUGH

Dimitrios Tsilingiris, Christos Siafarikas, Vasileios Andrianesis, Matthew Katsaras, Konstantinos Reppas, Maria Mylona
1st Department of Propaedeutic & Internal Medicine, Laiko General Hospital, Athens University Medical School, Athens, Greece

Introduction

Pericardial cysts (PC) are rare congenital abnormalities with a reported incidence rate of 1/100.000. They are thought to result from failure of fusion of one of the mesenchymal lacunae that form the pericardial sac. The most common locations of these cysts are middle mediastinum and right cardiophrenic angle. Pericardial cysts are usually asymptomatic unless a complication or rapid growth occurs. Herein we present an interesting case of PC in a patient with chronic cough.

Case description

A 70-year old Caucasian woman, with a history of diabetes mellitus and hypertension under treatment, visited our outpatient clinic due to worsening of non-productive cough for the last two months with no clinical response to previously prescribed antihistamines, PPIs and inhaled corticosteroids. The cough was associated with a tickling feeling in the throat and had no association with meals, season, time of day or body posture. The patient did not also experience any upper airway viral infection in the past 2 months. She was afebrile and physical examination and blood chemistry were unremarkable. Chest X-ray revealed a homogenous density mass in the left cardiophrenic angle, while on her chest CT scan a sharply-marginated cystic mass of 10×20 mm was seen. With probable diagnosis of pericardial or thymus cyst, she was initially closely monitored for a year, when she underwent chest MR Imaging, which revealed that the mass was enlarged (40×55mm) and its density altered. The patient was then prepared for surgical resection of the cyst via median sternotomy. She had a complicated recovery with post-pericardiotomy syndrome, paroxysmal atrial fibrillation and acute pulmonary edema and was discharged 20 days later, clinically improved with no cough since then. Pathology revealed a single layer of mesothelial cells and fluid-filled cyst compatible with pericardial cyst.

Discussion

Pericardial cysts are usually asymptomatic. However, resection is indicated when they are enlarged or accompanied by complications and symptoms such as infection, tamponade, hemorrhage and persistent cough or dyspnea.

#376 - Abstract

PNEUMONIA: A RETROSPECTIVE STUDY IN CENTRO HOSPITAL UNIVERSITÁRIO COVA DA BEIRA

Clara Jorge ¹, Pedro Carlos ¹, Sónia Gomes ¹, Catarina Dionísio ², Marlene Louro ³, Leopoldina Vicente ³

¹ Centro Hospitalar Universitário Cova da Beira, Covilhã, Portugal

² Centro Hospitalar Universitário Cova da Beira, Guarda, Portugal

³ Centro Hospitalar Universitário Cova da Beira, Covilhã, Portugal

Background

Pneumonia (PN) it's defined as an infection of the lung parenchyma. Community-acquired pneumonia (CAP) represents 10% of low respiratory infections, with a mortality rate of 13.6% in hospital setting. Nosocomial pneumonia (NP) its the most common infection acquired in the hospital.

Methods

A retrospective data analysis has been done, describing the patients admitted with pneumonia to the department of Internal Medicine between January 2017 and December 2017.

Results

A total of 167 patients were assessed, among which 76% had CAP, 16.8% NP and 7.2% aspiration pneumonia (AP). The mean age was 82.9 years and the ratio female to male was 2.

Microbiological agents were identified in 34.6% of the patients admitted with CAP: *S.p* (22%), multi-resistant staphylococcus aureus (MRSA) (2.4%), *Pseudomonas aeruginosa* (3.1%) and methicillin-sensitive *Staphylococcus aureus* (MSSA) (2.4%). In 14.3% of NP, 3.6% were MRSA, 7.1% MSSA and 3.6% *Pseudomonas aeruginosa*. The identification was made using the antigen urine test in 16.4% of the cases, 8.4% by sputum and/or blood culture, and 0.6% by bronchial alveolar fluid. Invasive pneumococcal disease was diagnosed in 8 patients. In total, no microbiological agents were identified in 70.7% of the cases.

Patients with PN by *S.p* presented several risk factors: heart failure (32.6%), dementia (23%), cerebrovascular disease (15.5%), structural lung disease (16%), smoking (6%) and alcoholism (3.7%). Beta-lactam antibiotics associated with macrolides were used in 52.7% of patients, extended-spectrum β -lactam antibiotics were prescribed in 15% and fluoroquinolones in 11.4%. Therapy escalation occurred in 6% of cases and de-escalation through antibiotic sensitivity test was done in 9% of the patients. The mortality rate (MR) was 16.2%. The majority of the patients (95.8%) had a CURB-65 score superior to 2. It was also observed that 59.9% of the patients used proton pump inhibitor (PPI) in the outpatient care.

Conclusion

As reported in the literature, *S.p* remains the most identified microbiological agent in PACs with low microbiological identification rate.

Appropriate empiric ATB was established in 94.6%. Conforming

to literature, the patients present an MR between 9.2% -22% at 30 days of hospitalization. It should be noted that almost 60% of the patients consumed PPI, considered as risk factor for PN development.

#378 - Case Report

SYNDROME OF INAPPROPRIATE SECRETION OF ANTIDIURETIC HORMONE AS AN INITIAL PRESENTING SIGN OF LUNG CANCER

Lília Castelo Branco, Ana Margarida Coelho, Andreia Diegues, Cátia Marisa Loureiro Pereira, Elisabete Pinelo, Eugénia Madureira

Internal Medicine Department, Unidade Hospitalar de Bragança, Unidade Local de Saúde do Nordeste, Bragança, Portugal

Introduction

The syndrome of inappropriate anti-diuretic hormone secretion (SIADH) is caused by retention of free water secondary to dysregulated release of anti-diuretic hormone (ADH). It is suggested by hyponatremia, low serum and high urine osmolality and continued excretion of urine sodium in the absence of other causes of hyponatremia.

Case description

An 81-year-old male presented to emergency department with progressive dyspnea, productive cough and pleuritic pain with for the past 2 weeks. He had an 80 pack-year smoking history (he stopped smoking 20 years ago), a non-stratified pulmonary disease, negative family history for cancer and a possible occupational exposure to asbestos and other carcinogenic chemicals as a constructor over 20 years. His usual medications included omeprazole 20 mg; enalapril + lercanidipine 10+10 mg; montelukast 10 mg, atorvastatin 40 mg and two inhaled bronchodilators. On physical examination, patient was in no acute distress, appeared clinically euvolemic but dehydrated and with decreased breath sound over the right middle lung at auscultation. Laboratory workup revealed hemoglobin of 13,8g/dL; sodium of 117 mEq/L; potassium of 4,6 mEq/L; chlorine of 88 mEq/L, serum lactate of 1,5 mmol/L, normal renal function, serum osmolality of 252 mOsm/kg, urine osmolality of 362 mOsm/Kg and urine sodium of 126 mmol/L. Chest radiograph on admission showed right hilar mass with pleural effusion which suggested the hypothesis of lung cancer. Chest computerized tomography (CT) scan revealed right hilar lung mass, mediastinal adenopathy highly suspicious for malignancy. Since clinical suspicion was high for lung cancer, a bronchoscopic biopsy was performed with non-conclusive results. Head, abdominal and pelvic CT were performed to exclude other cancers. Over the course of hospitalization, although the sodium level was stabilized with treatment, the patient developed gradually increased dyspnea and uncontrolled pain, with the need of palliative care support. The patient progressively deteriorated his clinical status and died 21 days after admission.

Discussion

Paraneoplastic syndromes occur in 10% of lung cases, SIADH occurs in 7-6% of lung cases and is linked to a worse outcome. Hyponatremia has been identified as a negative prognostic factor in several malignancies but is uncommon to be the first presentation of advanced disease. With this case, we pretend to illustrate the high level of suspicion needed to early diagnosis and treatment.

#382 - Medical Image

"CRAZY-PAVING" LUNG PATTERN: BEYOND THE TYPICAL

Mariana Brandão, Telmo Borges Coelho, Eduarda M. Tinoco, Paula Ferreira, Manuela Sequeira, Vítor Paixão Dias

Centro Hospitalar Vila Nova de Gaia/Espinho, Vila Nova De Gaia, Portugal

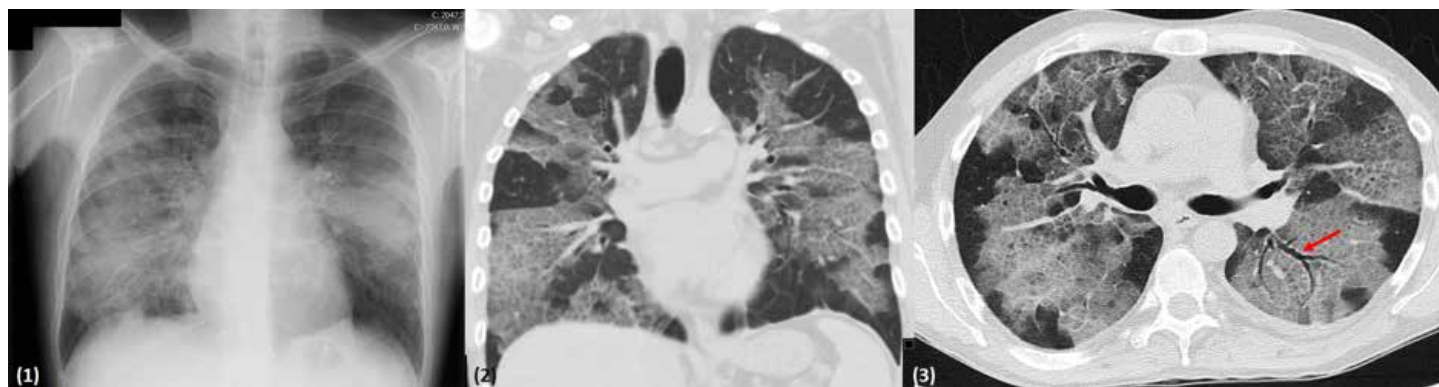


Figure #382.

#391 - Case Report

PULMONARY CONSOLIDATIONS, MORE THAN A PNEUMONIA

Diana Alexandra Pimenta, Rui Rolo, João Cunha

Hospital Braga, Braga, Portugal

Introduction

Cryptogenic Organizational Pneumonia is a rare entity. The diagnosis is made by the presence of clinic, suggestive radiological pattern and histological demonstration, in the absence of a known etiology. The recommended treatment is corticosteroid therapy. The prognosis is favorable, but relapse or progression to pulmonary fibrosis may occur.

Case description

Male patient, 56-years-old. He was recruited to the Emergency Department (ED) by a clinical clinic, with about 4 weeks of evolution, initially with dry cough, odynophagia, rhinorrhea, otalgia, myalgias and holocranial headaches.

He reported worsening of the symptoms about 2 weeks, with progressive worsening dyspnea, associated with worsening of cough with moderate to severe greening of the cough, fever, nocturnal hypersomnolence and asthenia. Given the tragic symptomatology, he appealed to the health services 4 times consecutively and was

Clinical summary

51-year-old male, with a history of smoking and occupational exposure to silica dust, presented to the ER with dyspnea, productive cough and fever of insidious onset. Laboratory tests showed leukocytosis, elevated C reactive and positive IgM antibody to Chlamydia pneumoniae. Chest radiograph revealed bilateral opacities with "bat wing" distribution. Thoracic CT scan showed a bilateral parenchymal pattern with areas of ground-glass densification and thickened interlobular septa, exhibiting "crazy-paving" pattern. Areas of air bronchogram were also visible. Although "crazy-paving" was once considered pathognomonic of alveolar proteinosis (PAP), it is not specific of PAP, and can be observed in adults with high level silica dust exposure or pulmonary infections, all to consider in this case.

medicated with 3 cycles of antibiotic therapy. Due to the persistence of complaints and the notion of aggravation of dyspnea, he resorted to ED again. The objective examination showed a global decrease in the vesicular murmur and presence of crepitations in the lung bases bilaterally. Analytically with leukocytosis, neutrophilia and increased C-reactive protein. Gasimetry with hypoxemia, chest X-ray with scattered bilateral infiltrates. He was hospitalized for continuity of care. Initiated therapy with ceftriaxone+clarithromycin. Due to the lack of response to the antibiotic, therapy was escalated to piperacillin/tazobactam and chest CT was performed: presence of airborne bronchogram consolidations dispersed by the pulmonary parenchyma bilaterally. Due to the absence of clinical response, he underwent bronchofibroscopy with bronchoalveolar lavage which revealed lymphocytic alveolitis with increased CD4/CD8 ratio and eosinophilia. Due to the persistence of hypoxemia and bilateral consolidations in the pulmonary parenchyma, the hypothesis of cryptogenic organizational pneumonia (COP) was raised and corticosteroid 1 mg/kg was initiated. The patient presented symptom improvement after one week of treatment. Pulmonary consolidation was confirmed one month after starting therapy. Maintained steroids during weaning for 6 months.

Discussion

The diagnosis of COP is a challenge, since the differential diagnosis

includes a broad spectrum of diseases with similar clinical and imaging characteristics. This clinical case aims to highlight the importance of clinical suspicion for the diagnosis of this entity.

#404 - Case Report

PLEURAL FIBRINOLYSIS, A CASE OF THERAPEUTIC SUCCESS

Diana Alexandra Pimenta, Catarina Lacerda, Rui Rolo, João Cunha
Hospital de Braga, Braga, Portugal

Introduction

Parapneumonic effusions and empiemas are pleural effusions that form in the pleural space adjacent to bacterial pneumonia. Fibrinolytics can be used early in the case of localization in the pleural cavity and empyema, facilitating the drainage of dense fluids and avoid the formation of septa in the pleural cavity.

Case description

A 44-year-old patient, a former smoker, with no relevant personal history, appealed to the emergency department for complaints of right pleuritic pain, asthenia, myalgia, nocturnal hypersomnia, progressive worsening dyspnea and fever with 1 day of evolution. On objective examination he had fever, polypnea, decreased vesicular murmur on the right, and abolished his lower half. From the study: leukocytosis, C-reactive protein elevation and large volume pleural effusion in the right hemithorax. Chest CT: presence of pleural effusion, and "rounded formation with 38x32mm, in the posterior segment of the LSD, (...) very probable neoplastic process". Toracentesis - cloudy liquid, with foul smell, pH: 6.6. Admitted diagnosis of empyema. Placed thoracic drainage. Interned the sick. Therapy was instituted with clindamycin + ceftriaxone unresponsive, and therapy was escalated to piperacillin/tazobactam and clindamycin after improvement. Given the suspicion of pulmonary neoplasia, bronchofibroscopy was performed - without alterations. Without microbial isolation. Negative cytological study. Subjected to pleural fibrinolysis with Alteplase 10 mg at the 9th day of hospitalization, for maintaining loculated pleural effusion. He presented resolution of the effusion afterwards, maintaining passive drainage of the pleural effusion until the 11th day of hospitalization. Given the initial suspicion of possible lung neoplasm, the patient underwent reassessment chest CT scan: "(...) nodular formation, with a transverse diameter of about 20 mm, with a net content and with a slight peripheral contrast uptake compatible with an intraparenchymal abscess (...)"

Discussion

Empyema is an important cause of morbidity and mortality. It is often necessary to resort to surgery for resolution of intrapleural loci. The association of fibrinolytics appears as an alternative to surgical intervention, however the evidence in the adult is still limited. The presented case demonstrated a high efficacy, without complications, with consequent reduction of the morbidity and the time of internment.

#554 - Case Report

DIFFERENTIAL DIAGNOSIS BETWEEN PULMONARY ARTERY SARCOMA AND PULMONARY EMBOLISM

Eva Cervilla Muñoz¹, Francisco Galeano Valle¹, Jorge Del Toro Cervera², Pablo Demelo Rodriguez

¹ Hospital General Universitario Gregorio Marañón, Madrid, Spain

² Hospital General Universitario Gregorio Marañón, Madrid, Spain

Introduction

Pulmonary artery sarcoma (PAS) is rare tumor with poor prognosis which originates from the intimal layer of the pulmonary trunk and pulmonary arteries. PAS diagnosis is challenging, since it can be difficult to distinguish from a pulmonary embolism

Case description

A 70-year-old woman with a previous history of breast cancer in complete remission and previous episodes of superficial vein thrombosis, presented with a history of 8-months evolution constitutional syndrome, associating exertion dyspnea and left hemitorax pleuritic pain. She did not recall hemoptysis, cough, fever or peripheral edema.

A thoracic computer tomography showed an increased diameter of pulmonary arteries with thrombosis affecting the main trunk with extension to lobar, segmental and subsegmental arteries. D-Dimer value was 188 ng/ml. The rest of laboratory parameters were also within normal ranges. A doppler ultrasound of lower extremities ruled out a deep vein thrombosis. A transthoracic echocardiogram revealed a dilated right ventricle with preserved systolic ejection function, severe pulmonary hypertension (systolic pressure of the pulmonary artery of 69 mmHg) and obstructive gradient in the trunk of the pulmonary artery secondary to an obstructive lesion. A magnetic angio-resonance demonstrated a heterogeneous mediastinal mass centered at the bifurcation level of the pulmonary arteries, with extension to both main pulmonary arteries, extravascular extension and ganglionic, pleural, vertebral and thoracic metastatic dissemination. The diagnosis of pulmonary artery sarcoma was established and chemotherapy treatment initiated.

Discussion

PAS usually presents with symptoms such as dyspnea, cough, chest pain or syncope, which may resemble a pulmonary embolism and lead to a delay in the diagnosis. Insidious onset of symptoms, constitutional syndrome and persistent symptoms despite anticoagulation should raise the suspicion and further studies should be performed.

#559 - Case Report

MEDIASTINAL LYMPHADENOPATHY: A CASE REPORT

Miguel Reis Costa, Pedro Pinto, Rosana Maia, Duarte Silva, Irene Miranda, Diana Guerra

ULSAM - Hospital de Viana do Castelo, Viana Do Castelo, Portugal

Introduction

The list of differential diagnosis for lymphadenopathy (LAD) is vast and it is important to take into account the patient's medical history and review of systems. Mediastinal LAD is frequently asymptomatic until compression of a mediastinal structure occurs.

Case description

We report the case of a 61-year-old woman with a history of controlled hypertension and multinodular goiter (in the meantime submitted to thyroidectomy). She was also diagnosed with sigmoid colon adenocarcinoma stage T2N1M0 in 2012, thus submitted to sigmoidectomy and adjuvant chemotherapy. In a follow-up care after surgery, in 2014, a chest and abdominal CT Scan were performed, revealing mediastinal LADs (the biggest ganglion measuring 20x13 mm in the paraortic space), with no signs of neoplasia, metastasis in bowel loops/ mesentery, hepatosplenomegaly or abdominal lymphadenopathies. No chest CT was performed before surgery for comparison. The patient was subsequently referenced to the internal medicine department where she referred no history of dyspnea, cough, anorexia, asthenia, night sweats, weight loss, rash or fever. No significant alteration in physical examination was objected. Analytically a slight leucopenia, with a normal blood smear, an increased sedimentation rate (40mm/h), and normal serum immunoglobulins and light chains. Normal levels of CEA, SACE and serum calcium. Viral serologies and tuberculin skin test were negatives. She repeated chest CT that identified 4 micronodules in the inferior lobe of the right lung, an additional unspecific nodule in the medium lobe and a bilateral peribronchovascular ground glass pattern, saving the subpleural areas; the mediastinal LADs were stable in size and morphology. An endobronchial ultrasound-transbronchial needle aspiration of the mediastinal nodules was performed and revealed a non-necrotizing granulomatous lymphadenopathy with no signs of malignancy, which led to a final diagnosis of sarcoidosis, stage II, in an asymptomatic patient.

Discussion

Considering the patient's age and medical history, there was a strong suspicion of malignancies including lymphoma and metastatic carcinoma or tuberculosis. Even though always considered a differential diagnosis, sarcoidosis was at first considered unlikely, only being able to be confirmed with biopsy. This shows how cautious a physician must be when presented with a case in which the possibilities diagnosis are so vast.

#567 - Case Report

IS IT AN HEMOTHORAX OR AN HEMORRHAGIC PLEURAL EFFUSION?

Filipa Sofia Silva, Ana Rita Piteira, Patrícia Domingues, Joana Ferreira, Diana Pedreira, Pedro Carreira, Paula Lopes, Manuela Fera

Setúbal Hospital Center, Setúbal, Portugal

Introduction

A pleural effusion is a collection of fluid abnormally present in the pleural space. It is the most common manifestation of pleural disease, and its etiologies include cardiopulmonary disorders, systemic inflammatory conditions and malignancy. The fluid can be a transudate or an exudate (common causes are parapneumonic effusion and malignancy - usually lung or breast cancer, lymphoma, and leucemia).

Case description

A 79-year-old woman, without known pathologies, went to the Emergency Department. She complained with retrosternal pain and dyspnea, with a week of evolution. She fell in her house, for about three months ago, but apparently, no traumatic injury resulted from it. She denied anorexia or weight loss. At objective examination patient had an excellent performing status, there wasn't vesicular murmur in the lower 2/3 of the right hemithorax. Gasometrically coexisted hypoxemia and hypocapnia. Analytically there was an increased in inflammatory parameters. At chest X-ray there was an hypotransparency suggestive of massive right pleural effusion. It was performed a thoracentesis, the fluid was totally hematic, and the cytochemical was compatible with an exudate, with 1350 leukocytes / μL with 70% of polymorphonuclear cells and hypoglycaemia. The anatomopathological took several weeks until the result was known. Initially this case was interpreted as an empyema in the context of a posttraumatic retained hemothorax. Patient fulfilled empiric antibiotic therapy in the beginning with piperacillin tazobactam and after with meropenem because of the lack of therapeutic response. During hospitalization, there was a persistent increase in inflammatory parameters. The third computed tomography of the chest revealed a solid nodular formation with 29 mm in the right lower lobe. The worse became a reality, was it an hemothorax or a malignant hemorrhagic pleural effusion? Patient was forwarded to the Thoracic Surgery of the Reference Hospital Center. Meanwhile, the immunocytochemical result confirmed the diagnosis, it was a malignant hemorrhagic pleural effusion in the context of a pulmonary adenocarcinoma. Actually patient is waiting her first Oncology Pneumology appointment.

Discussion

In a patient with an excellent performance status sometimes it is not easy to distinguish between a benign or malignant etiology. The suspicion is often the key to diagnosis.

#585 - Abstract

EVALUATION OF NEUTROPHILE / LIMFOCITE RATIO IN BRONHO-PULMONARY TUMORS

Daniela Belu, Anca Belu, Traian Tache, Zizi Niculescu

Constanta County Emergency Hospital, Ovidius University Constanta, Constanta, Romania

Background

Currently, evaluation of the neutrophil-lymphocyte ratio proves to be useful in the study of renal and testicular cancers, there are also studies on its follow-up in the progression of bladder and ovarian tumors.

Immune response and implicitly neoplastic progression associated with elevated neutrophil count may be a marker for both neoplastic and inflammatory conditions.

Tumor cells secrete the granulocyte colony stimulating factor, with neutrophil growth and favoring angiogenesis in tumor tissue.

Methods

We propose to evaluate the neutrophil-lymphocyte ratio in patients admitted to the Medical Clinic II of the Constanta County Clinical Hospital with newly diagnosed bronchopulmonary cancer to have a view of the possibility of considering it as a prognostic factor in respiratory neoplasia.

Methods

We are considering a group of 128 patients aged between 45 and 77 years without significant associated pathologies, hospitalized between 01.01.2016-01.01.2019.

We are searching for the determination of the neutrophil / lymphocyte ratio in both patients without and with secondary metastatic determinations.

Results

The neutrophil/lymphocyte ratio is over 2,7 in patients with no metastatic bronchopulmonar tumors and over 3 in patients with respiratory neoplasia and secondary determinations. It is proven that neutrophils stimulate local angiogenesis and thus tumor progression and metastasis. Lymphopenia is responsible for low immune response, favoring aggressiveness and tumor progression.

Conclusion

This ratio is a marker that deserves more attention.

No exact threshold has been identified for prognostic or diagnostic value, but values above 2.7 should be considered a real alarm signal.

We are convinced that this result could help diagnose and could be useful especially in case of a clinical suspicion, imagistically confirmed or not.

#717 - Case Report

PARANEOPLASTIC ACRAL ERYTHEMA IN A PANCOAST'S TUMOUR

Diogo Canhoto, Lília Maia Santos, Ana Franco, António Jorge Ferreira

Pulmonology Department, Coimbra Hospital and University Centre, Coimbra, Portugal

Introduction

Palmar erythema is a frequent manifestation of systemic disease. Recent studies have suggested an association with underlying malignancy, particularly that prone to haematogenic dissemination. It has been postulated that the angiogenic factors that produce the erythema may act as facilitators of bloodborne metastasis.

Case description

A 52-year-old female patient undergoing chemotherapy with cisplatin and pemetrexed for a lung adenocarcinoma of the right superior sulcus (T3N2M0) was admitted to urgent care for holocranial cephalgia. Performance status was 0. Inquiry revealed a subacute onset for vertigo, ataxia, and bilious vomiting, as well as right neuropathic omalgia and ipsilateral upper extremity dysesthesia. On examination, static right jugular venous distention, bilateral digital clubbing, and atrophy of the interosseous muscles of the right hand. No features of Horner's syndrome were present. Lastly, symmetrical painless palmar erythema was present from the time of diagnosis, having partially remitted with chemotherapy and recrudesced 2 weeks prior to presentation of neurologic symptoms. Blood work-up was inconspicuous.

Contrasted cranial CT performed on the suspicion of intracranial hypertension revealed numerous supra- and infratentorial space-occupying lesions compatible with metastases. Compression of the IV ventricle by a bulbopontine lesion produced mild hydrocephalus.

Thoracic high-resolution CT showed an 11 cm right upper lobe mass invading the brachial plexus and impinging on the superior vena cava, producing focal stenosis.

Urgent holocranial radiotherapy provided near-immediate improvement of cranial hypertension signs and neurologic deficits, with the exception of tractus segmentalis symptoms of the upper limb.

Despite the grim prognosis, the patient is alive 3 months after presentation, and is expected to resume chemotherapy in ambulatory.

Discussion

The complexity of the neurological findings at presentation was the result of multiple cranial space-occupying lesions compounding a neurogenic thoracic outlet syndrome. Impending superior vena cava syndrome was apparent from adynamic right jugular venous turgescence.

Fluctuations of palmar erythema paralleled changes in tumour burden and signalled the presence of cerebral metastatisation prior to the appearance of symptomatic neurological deficits.

Acral erythema remains an underdiagnosed cutaneous marker of malignancy, for which its unexplained presence or flaring should prompt further study.

#724 - Case Report

PLEURAL-PANCREATIC FISTULA: A RARE CAUSE OF PLEURAL EFFUSION

Duarte André Ferreira, Teresa Vieira Gouveia, Tatiana Henriques, Maria Luz Brazão
Hospital Central do Funchal, Funchal, Portugal

Introduction

Pleural effusions result from excessive accumulation of fluid in the pleural space and may be a consequence of numerous pathologies. Pancreatic pleuropulmonary fistula is an uncommon etiology that should be considered when there is a history of pancreatitis or pancreatic trauma.

Case description

A 58-year-old man, with history of carcinoma of the right retromar trigone, former smoker, alcoholic, started dyspnea for minor exertion, nonproductive cough and pleurisy pain on the right shoulder blade. He reported weight loss of 4 kg in 4 months. After 2 weeks, he underwent a thoracic computed tomography (CT) on a clinic, revealing a massive right pleural effusion that filled the entire right lung cavity. He was referred to the Emergency Department. On examination he was: afebrile, tachycardic. Laboratory evaluation revealed leukocytosis, neutrophilia and C reactive protein of 24 mg/dL. Thoracic radiography showed homogeneous hypotransparency occupying the entire right lung field. Diagnostic and therapeutic thoracentesis was performed, with drainage of 2000 ml of serohematic fluid, which revealed an exudate with predominance of polymorphonuclear (PMN) and amylase of 2723 U/l. Negative bacteriological and mycobacteriological studies. Pathologic anatomy of pleural fluid was negative for neoplastic cells and biopsy of pleural thickening revealed pleural fragments with chronic inflammatory process. He performed a thoraco-abdomino-pelvic CT of which the pancreas tail heterogeneity was highlighted, associated with a 35mm collection. After this, a Magnetic Resonance Cholangiopancreatography was performed, which revealed a pseudocyst from the tail of the pancreas to the left subdiaphragmatic region, passing through the aorta and ending in the right subpleural region.

Discussion

Pleural effusions can be the consequence of numerous pathologies. In this patient, one of the most probable causes would be neoplastic; other causes would be a parapneumonic process/empyema or pulmonary embolism. Exudates are usually caused by infections, tumors, inflammation, involvement of lymphatic drainage or drugs. The predominance of PMN may suggest parapneumonic effusion, pulmonary embolism or abdominal etiology, whereas the presence of increased amylase suggests tumor, esophageal rupture, pancreatic disease or tuberculosis. The imaging studies confirmed

the pancreatic etiology, in this case a pseudocyst on the tail of the pancreas with a pleuro-pancreatic fistulous path.

#731 - Medical Image

BRONCHIAL CARCINOID TUMOR PRESENTING AS A PNEUMOMEDIASTINUM

Joana Carreiro¹, Bernardo Ferreira², Maria Guadalupe Benites¹, Almerindo Rego¹

¹ Terceira Island Santo Espírito Hospital, Angra Do Heroísmo, Portugal

² St. António dos Capuchos Hospital, CHULC, Lisbon, Portugal

Clinical summary

22-year-old, male, smoker, presenting with dry cough for 2 months, evolving to violent coughing fits with hemoptysis and retrosternal discomfort, without hypoxemia. The X ray didn't show any abnormalities.

The CT scan revealed pneumomediastinum and a densification of ill defined limits on the lingula. The bronchofibroscopy showed an occlusion of the left superior brachium/lingula by an endobronchial mass. Histology confirmed an carcinoid tumor.

Pneumomediastinum has an incidence of 1/25,000 in ages between 5-34 years. The diagnosis can be confirmed via chest X-ray or CT scanning of the thorax. The main symptom is usually severe central chest pain. The tissues in the mediastinum slowly resorb the air in the cavity so most cases of pneumomediastinum are treated conservatively.

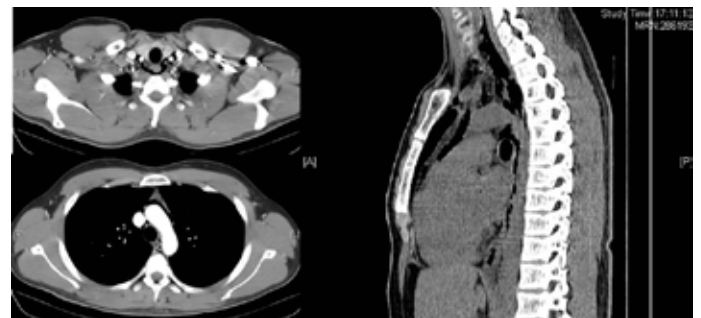


Figure #731. Pneumomediastinum.

#732 - Case Report

PNEUMOLOGY AND INTERNAL MEDICINE SIDE BY SIDE IN THE DIAGNOSIS OF A SYSTEMIC PATHOLOGY: A CLINICAL CASE OF HYPEREOSINOPHILIC SYNDROME

Adelaide Pereira Alves, Inês Pereira Sucena, Eloisa Silva, Carla Ribeiro, Teresa Shiang, Manuela Vanzeller

Centro Hospitalar de Vila Nova de Gaia/Espinho, Vila Nova De Gaia, Portugal

Introduction

Hypereosinophilic syndrome (HES) is rare. It may occur in the context of recognized causes of hypereosinophilia (such as parasitic infections), but in about 75% of cases it is not possible

to identify the underlying etiology. Pulmonary involvement is common and may be the initial manifestation.

Case description

Man, 37 years old. History of asthma and chronic rhinosinusitis with an increase in the frequency of upper airway infections and documented peripheral blood hypereosinophilia in the last three years. He went to the Emergency Department for a two-week course of fever, dyspnea and mildly hemoptoic cough. He presented leukocytosis with exuberant eosinophilia (7850/ μ L) and CRP 10.38 mg/dL. The chest CT showed bilateral opacities with ground-glass opacification. A diagnosis of pneumonia was assumed and the patient was hospitalized for treatment and continuation of the study of hypereosinophilia. He fulfilled seven days of levofloxacin 750 mg once a day with clinical and radiological improvement. The patient maintained marked peripheral hypereosinophilia (maximum 19.480/ μ L). From the complementary study, negative autoimmunity, negative stool parasitology, normal tryptase serum level and normal karyotype. Bronchoalveolar lavage with eosinophilia > 35% was observed. Pulmonary biopsy was compatible with interstitial pneumonia with a significant number of eosinophils. Transthoracic echocardiography documented a granular-like myocardium. Bone marrow biopsy showed hyperplasia of the myeloid line at the expense of only the eosinophilic series, without phenotypic anomalies, without fibrosis and without evidence of neoplasia. Immunophenotyping of the bone marrow showed no evidence of lymphoproliferative disease. The search for genetic mutations (FIP1L1-PDGFRA, JAK2, BCR-ABL, FDGFR1 and C-KIT) was negative. A diagnosis of idiopathic hypereosinophilic syndrome with pulmonary, cardiac and haematological involvement was established and the patient was treated with systemic corticosteroid therapy, with clinical and analytical improvement.

Discussion

The diagnosis of HES can be challenging. After exclusion of secondary causes requiring targeted treatment, diagnostic investigation should be continued regardless of the presence or absence of symptoms. With the present clinical case, we intend to demonstrate the importance of a multidisciplinary approach, namely a closed articulation with Internal Medicine, since virtually any organ can be affected.

#734 - Case Report

CPAP USE FOR TREATMENT OF POST-TRACHEOSTOMY TRACHEAL STENOSIS

Rui M. Domingues¹, Ana Luísa Azevedo¹, Edgar Amorim², Ana Luísa Vieira³, Olinda Caetano¹, André Santa Cruz^{1,4}

¹ Internal Medicine Department, Braga Hospital, Braga, Portugal

² Physical Medicine and Rehabilitation Department, Braga Hospital, Braga, Portugal

³ Pulmonology Department, Braga Hospital, Braga, Portugal

⁴ Life and Health Sciences Research Institute (ICVS), School of Medicine, University of Minho, Braga, Portugal, Braga, Portugal

Introduction

Tracheal stenosis is a potential late complication of tracheostomy, which occurs in approximately 1% of patients. Virtually, all patients post-tracheostomy have some degree of stenosis, but only 3% to 12% require intervention.

Case description

We report the case of a 53 years old woman with previous history of hypertensive end-stage renal disease needing haemodialysis and hemorrhagic stroke in 2015. The stroke involved basal ganglia, required surgical intervention and a long period of recovery with the need of a tracheostomy. The stroke led to chronic left spastic hemiparesis, central facial paralysis, permanent right hemiballismus and severe cognitive impairment. She was admitted to the Hospital due to community-acquired pneumonia, and started treatment with ceftriaxone and clarithromycin. During her stay, she had several episodes of sudden difficulty in breathing, with stridor and low-peripheral oxygen saturation. Medical treatment was ineffective, as she always needed to start mechanical non-invasive ventilation, with immediate improvement. Episodes continued even after pneumonia treatment and her husband confirmed that she had had those episodes occasionally before the admission. Thoracic CT showed a slightly narrowed trachea and bronchofibroscopy showed a mild complex tracheal stenosis with expiratory collapse. Management was first discussed with Otorhinolaryngology, but stenosis level was too low to be managed by that specialty. Pulmonology colleagues were consulted, but did not recommend the use of any tracheal device due to the low probability of success and high risk of complications. Thoracic Surgery was regarded as inadequate, considering patient overall status. Therefore, non-invasive ventilation was started on a regular basis: continuous CPAP with nasal mask during the night, and on-demand CPAP during the day, whenever the patient presented stridor. After this point, episodes became rare, with consequent improvement in patient's comfort.

Discussion

This case shows a novel and well-succeeded approach to the management of patients with collapsing tracheal stenosis and multiple comorbidities who are not candidates to more complex procedures.

#735 - Medical Image

GIANT BULLOUS EMPHYSEMA: VANISHING LUNG SYNDROME

Joana Carreiro¹, Bernardo Ferreira², Maria Guadalupe Benites¹, Almerindo Rego¹

¹ Terceira Island Santo Espírito Hospital, Angra Do Heroísmo, Portugal

² St. António dos Capuchos Hospital, Lisbon, Portugal

Clinical summary

56 years old male, with a history of smoking and COPD GOLD C, referred to the hospital with dyspnea to moderate effort and

wheezing. Pulmonary auscultation revealed diminished breathing sounds on the right lung.

The Chest X-ray showed a large bulla occupying the right hemithorax, mimicking a pneumothorax.

The CT scan revealed bilateral bullous emphysema, more evident on the right lung, where a giant bulla $\frac{2}{3}$ of the hemithorax was observed, with collapse of the middle and inferior lobes.

Giant bullae often mimic pneumothorax on radiographic appearance and can be misdiagnosed, but the management of the two conditions is vastly different. Distinguishing between the two may require CT scan.

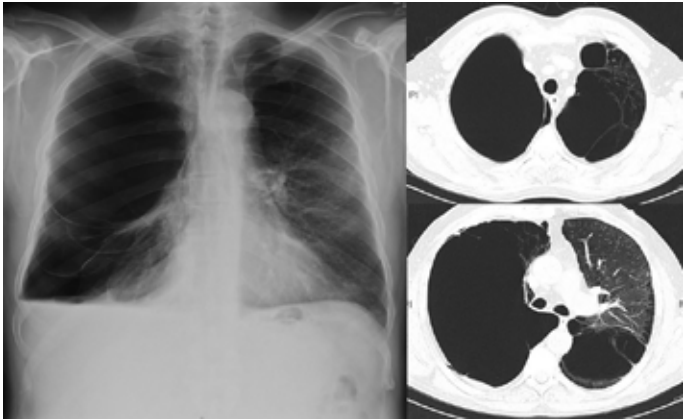


Figure #735. Bullous emphysema.

#736 - Case Report

OCCUPATIONAL EXPOSURE TO CHLORINE DIOXIDE: TWO CASE REPORTS

Ana Alfaiate¹, Cristina Braço Forte¹, Marisa Rosário², Ana Cysneiros¹, Susana Sousa¹, Ivone Fernandes¹, Paula Duarte¹

¹ Respiratory Medicine Department, Hospital de São Bernardo, Centro Hospitalar de Setúbal, E.P.E., Setúbal, Portugal

² Otolaryngology Department, Hospital de São José, Centro Hospitalar Universitário de Lisboa Central, Lisboa, Portugal

Introduction

Chlorine dioxide is a widely used chemical with known respiratory toxicity. The authors bring two case reports of accidental exposure resulting in different degrees of respiratory toxicity.

Case description

Case 1

A 29 years old male, with no relevant past medical history and a never smoker who worked as an infrastructure maintenance technician was seen at the Emergency Department following accidental exposure to chlorine dioxide at his workplace. He reported correct use of protective gear together with a face mask. The accident occurred after a gas leakage that resulted to a 15 minutes exposure. He presented six hours following the accident with dry cough and dyspnea. Arterial blood gases at room air were: pH 7.45, PaO₂ 48mmHg, PaCO₂ 40mmHg, HCO₃ 28.5mmol/L, Sat. 89%, lactates 1.2 mmol/L. Chest radiography

was normal. The patient was admitted with a clinical diagnosis of chemical pneumonitis. Treatment was supportive and the patient improved rapidly.

Case 2

A 21 year old male, with no relevant past medical history and a never smoker who worked as an infrastructure maintenance technician presented to the Emergency Department following accidental intoxication to chlorine dioxide. Despite the reported use of protective gear, the patient experienced intense inhalation and skin contact for ten minutes. He immediately felt shortness of breath, chest pain and hoarseness. On admission he was tachycardic, polypneic, with bilateral crepitations on chest auscultation and with second degree chest and lower limbs chemical burns. Arterial blood gases with 40% FiO₂ were: pH 7.41, PaO₂ 51 mmHg, PaCO₂ 41 mmHg, HCO₃ 26.4 mmol/L, Sat. 87%, lactates 1.3mmol/L. Full blood count showed leukocytosis and neutrophilia. His chest radiography showed extensive bilateral ill defined opacities. There was clinical worsening and the patient was admitted to Intensive Care. He presented severe type 1 respiratory failure, upper airway edema and bilateral vocal cord paralysis and was intubated and mechanically ventilated at 72 following admission. He was established to have acute ARDS and was accepted for ECMO. Later, there was progressive clinical improvement with possibility of extubation at the 26th day of hospitalization.

Discussion

There is a wide spectrum of lung injury following inhalation of chlorine dioxide. Longer or higher exposure can lead to development of acute lung edema or, infrequently, ARDS. The clinical outcome in these two cases was different, probably owing to different degrees of exposure.

#743 - Case Report

TUBERCULOSIS AND SARCOIDOSIS: THE IMPORTANCE OF THE DIFFERENTIAL DIAGNOSIS

Sofia Garcês Soares, Teresa Martins Mendes, Marina Mendes, Marta Dalila Martins, Dalila Parente, Catarina Couto, Inês Ferreira, Ana João Sá, Mari Mesquita

Centro Hospitalar Tâmega e Sousa, Penafiel, Portugal

Introduction

Tuberculosis and sarcoidosis are both granulomatous diseases that have some similarities and can affect multiple organs making its differential diagnosis difficult. Sarcoidosis etiology is not well established. It is thought that it can be caused by an immunological response to environmental factors or to an infection where mycobacteria are included.

Case description

A 38-year-old man, with no relevant personal background but with a family history of pulmonary tuberculosis 6 years before

(screening was negative), referred to the emergency department due to non-productive cough with 3 months of evolution without other symptoms and chest x-ray showing an heterogeneous infiltrate of the right lung field and bilateral hilar reinforcement. There were no major changes at physical examination. The initial workup revealed mild lymphopenia and heterogeneous bronchial parenchyma condensation areas in both upper lobes, dispersed extensive micronodular parenchymal infiltrate with areas with miliary pattern and multiple adenopathies on chest CT. He was admitted to the medical ward for probable disseminated tuberculosis. However, complementary study showed negative AFB on 3 sputum samples; negative AFB and negative BK DNA on bronchoalveolar lavage and its bacterial culture had polymicrobial flora. HIV, HBV and HCV were negative and there weren't any neoplastic cells on bronchoalveolar lavage either. A transthoracic needle biopsy showed epithelioid granulomas with negative BAAR and negative mycobacterial culture. Serum ACE level was high. Prednisolone was started given the high suspicion of sarcoidosis. After about a month, Mycobacterium Tuberculosis was isolated in a sputum sample and on bronchoalveolar lavage. Tuberculosis treatment was initiated. After 4 months of therapy, he kept complaints of dry cough and the previous radiological findings. A new bronchoalveolar lavage showed lymphocytosis (46.6%; CD4/CD8 ratio 4.37). Sarcoidosis diagnosis was made and corticotherapy was reinitiated.

Discussion

This clinical case is an example of the difficulty of the differential diagnosis of these two pathological entities. Its definitive diagnosis may last for months and its concomitant occurrence is rare. In addition, it pictures the challenge of managing infectious diseases and chronic inflammatory diseases at the same time.

#786 - Case Report

NON-INFECTIOUS PNEUMONIA

Cristina Llamazares Mendo, Guillermo Soria Fernández-Llamazares, María Mercedes Ferreiro-Mazón Jenaro, Marta Bacete Cebrián, Eduardo Luis Peñaloza Martínez, Alejandro David Bendala Estrada, Antonio Muiño Míguez, María Gómez Antúnez, Isabel Pérez Tamayo

Gregorio Marañón General University Hospital, Madrid, Spain

Introduction

Cryptogenic organizing pneumonia (COP) is an infrequent inflammatory lung disease with distinctive clinical, radiological and pathological features, whose etiology must be idiopathic. Recurrence and chronic forms with distal airway fibrosis are common. A surgical lung biopsy is the gold standard for diagnosis and corticosteroids are the most appropriate treatment.

Case description

A 74-year-old male with a history of type 2 diabetes and psoriasis treated with ustekinumab, came to the Emergency Department

with a 10-day left pleuritic chest pain without fever or other respiratory symptoms. He also reports dizziness, constitutional syndrome and low dysphagia. The physical examination was anodyne, except for gait instability with positive Romberg sign. The blood test showed 13.200 leukocytes/ μ L, CRP 12 mg/dL, ESR 68 mm/h and the chest X-ray displayed multiple bilateral pulmonary opacities. He was admitted to hospital with suspected bilateral bronchopneumonia and empirical treatment with ceftriaxone was initiated. Microbiological cultures were negative. After one week of antibiotic therapy, the chest X-ray had not improved. The body CT presented bilateral consolidating foci in pulmonary parenchyma and nonspecific bilateral paratracheal adenopathies, which were compatible with an inflammatory or neoplastic pathology. The cranial CT was normal and the gastroscopy showed chronic gastritis. A fibrobronchoscopy was performed: transbronchial biopsy was normal and AARB and LBA cultures were negative, ruling out tuberculosis and neoplastic etiology. Two weeks later, we saw a decrease in consolidative foci on the chest X-ray and two months later, the bilateral opacities were smaller size and density in the chest CT, suggesting an organized pneumonia in resolution. Throughout the study, the patient remained afebrile and clinically stable with progressive improvement of lung opacities.

Discussion

The patient presented a COP. Although a confirmatory diagnostic test could not be obtained, it was an exclusion diagnosis. Usually, the decision to start corticosteroids or immunosuppressive drugs depends on the severity of the symptoms, the progression and the radiographic extension. Our patient had a favorable evolution without specific treatment and he is currently undergoing clinical and radiological follow-up to detect possible recurrences. However, it is unknown if ustekinumab had any role in clinical improvement (like other published cases treated with biological drugs) or even in the onset.

#789 - Case Report

A RARE CANCER WITH A FREQUENT PARANEOPLASTIC SYNDROME

Paulo Almeida, Flávio Pereira, Tiago Valente, Joel Pinto, Eliana Araújo, Beatriz Pinheiro, Ana Araújo

Centro Hospitalar do Baixo Vouga, Aveiro, Portugal

Introduction

In about 8% of patients, cancer cause symptoms not attributable to direct compression or invasion of the tumor, called paraneoplastic syndromes. The syndrome of inappropriate antidiuretic hormone secretion (SIADH) is characterized by hyposmotic euvolemic hyponatremia and affects 1-2% of all patients with cancer.

Case description

A 53-year-old woman with antiphospholipid syndrome and history of smoking was admitted in the emergency department complaining of fatigue, anorexia, weight loss (not quantified), with nausea

and vomiting over the last 4 days. General physical examination was irrelevant. Blood investigations showed hyponatremia (128 mEq/L), elevated liver enzymes (AST 175 U/L, ALT 160 U/L, FA 500 U/L, GGT 655 U/L) and high lactate dehydrogenase (404 U/L). The chest radiograph revealed a left inferior pulmonary opacity. Abdominal ultrasonography was suggestive of diffuse hepatic metastization. A thoracoabdominopelvic computerized tomography (CT) was performed, which confirmed multiple mediastinal adenopathies, obliteration of the left lobar bronchus with associated collapse and massive hepatic metastasis. Hyponatremia aggravated (lower value of 114 mEq/L), despite the absence of vomiting or use of diuretics. Low serum osmolality and uric acid levels and a high urine sodium with elevated urine osmolality, confirmed SIADH. Bronchofibroscopy was performed, with histological examination of lung biopsies compatible with small-cell lung neuroendocrine carcinoma (SLCL), with intense and diffuse labeling for thyroid-1 transcription factor. Brain CT was performed, which showed a single lesion on the pituitary stalk suggesting metastatic lesion, confirmed by magnetic resonance. Hormonal study was normal. Bone scintigraphy was compatible with bone metastasis (body of the 11th dorsal vertebra).

Discussion

Lung neuroendocrine tumors (NETs) account for approximately 1-2% of all lung malignancies in adults. SLCL usually has an aggressive behavior, with rapid tumor growth and early and distant dissemination. SIADH is associated with SLCL in 70% of cases, clinically manifesting in about 7-16%. Although our patient presented with multiple metastasis, the stage of SLCL does not correlate with the incidence of SIADH. The patient was guided to multidisciplinary consultation in order to decide on therapeutic orientation.

#800 - Case Report

HAMMAN'S SYNDROME

Alejandra García García, Alejandro Parra Virto, Francisco Galeano Valle, Pablo Demelo Rodríguez

Hospital General Universitario Gregorio Marañón, Madrid, Spain

Introduction

Hamman's syndrome is a rare entity with only 200 cases reported in the literature until 1994. We present the case of a 29-year-old woman who presents pneumomediastinum and subcutaneous emphysema after vaginal delivery.

Case description

A 29-year-old primigravida woman of 40 + 3 weeks, with no medical history, went to the emergency room due to irregular uterine dynamics every 15 minutes of twelve hours of evolution. There was no vaginal bleeding or rupture of the amniotic sac. The patient had performed proper monitoring of pregnancy, without incident.

At the onset of labor dynamics, an abdominal ultrasound and a fetal cardiotocographic record showed no alterations. The patient

had a spontaneous eutocic delivery with cephalic presentation, the newborn being a 3.2 kg male with Apgar of 10 in the first minute. Labor lasted 18 hours and no complications were recorded.

At 8 hours after the birth, the patient presented with odynophagia and a sensation of crepitus in the cervical region, without dyspnea. Blood pressure was 126/73 mmHg, heart rate 80 bpm and oxygen saturation 98% breathing room air. Pulmonary auscultation was normal. A chest X-ray showed subcutaneous emphysema in both clavicular and bilateral cervical regions, with no evidence of pneumothorax. A blood test showed hemoglobin 11.8 g/dL, 113,000 platelets/mm³, 12,700 cells/mm³ (82.3% neutrophils). Kidney function, ions and liver function were normal. A chest computed tomography (CT) scan showed extensive subcutaneous emphysema and deep cervical and extensive pneumomediastinum. The presence of mediastinitis, free fluid or esophageal rupture was ruled out.

The diagnosis of spontaneous pneumomediastinum secondary to labor was made and a conservative management was decided. The subsequent evolution was favorable, being asymptomatic and with complete resolution of the lesions at 2 weeks of follow-up.

Discussion

In conclusion, spontaneous pneumomediastinum (Hamman's syndrome), despite being a rare disease, should be considered in the differential diagnosis of chest pain in the immediate postpartum. The pathophysiology of Hamman's syndrome is based on the rupture of the marginal alveoli secondary to an increase in intra-alveolar pressure with sustained Valsalva maneuvers (forced expiration against a closed glottis) associated with coughing, vomiting, screaming and birthing. The most common clinical presentation of Hamman's syndrome is retrosternal chest pain, shortness of breath, facial or neck pain, sore throat and dysphagia.

#836 - Abstract

USEFULNESS OF SPUTUM SAMPLES COLLECTION IN SUBJECTS WITH SUSPECTED ACUTE RESPIRATORY INFECTIONS

Marta Lobo Antuña, Adrian Arapiles Muñoz, Jorge Polo Sabau, Ignacio Mahillo Fernández, Ricardo Fernández Roblas

Fundación Jiménez Díaz, Madrid, Spain

Background

Acute respiratory tract infections are common and an etiologic diagnosis can be made by culture of respiratory tract secretions. The objectives of our study are to describe the diagnostic yield of sputum culture in hospitalized patients with suspected respiratory tract infections, to analyze the clinical and epidemiological features associated with a higher probability of a positive result and to determine the proportion of patients in whom a positive culture lead to a change in antimicrobial therapy.

Methods

We retrospectively reviewed 279 consecutive sputum samples received at the Microbiology Department of our institution, only

including in a database all samples from hospitalized patients with clinical features suggestive of respiratory infection. We registered clinical and epidemiological variables as well as radiological findings and early mortality rates, comparing the patients in whom sputum culture grew one or more specific microorganism with the remaining.

Results

A total of 162 patients were included for analysis. Mean age was 72±15 years (range 21-96). Ninety-four patients (58 %) were males, 3 (1.9 %) were HIV-infected, 18 (11.1 %) were diabetic, 7 (4.3 %) had regular alcohol consumption, 26 (16.0 %) received immunosuppressive drugs, and 64 (39.5 %) had chronic obstructive pulmonary disease (COPD). Antibiotics were administered prior to sample collection in 115 cases (71.0 %). Lung infiltrates were detected on x-ray film in 72 cases (44.4 %), with cavitation observed in 5 (6.9 %). Positive cultures were found in 24 cases (14.8 %). Among patients with positive culture, this result led to a change in antimicrobial therapy in 12 cases (50 %). Patients with a history of COPD had positive cultures more often than the remaining (23.4 % vs 9.2 %, $p=0.023$) but only in 21% ($n=11$) of the group these results led to a change in the antimicrobial therapy. There were no statistically significant differences regarding other epidemiological, clinical or radiological variables.

Conclusion

Overall, diagnostic yield of sputum culture in hospitalized patients with suspected respiratory tract infections was low and did not entail a change in antimicrobial regimen in half of the cases with a positive result. Possible explanations were found but extensive further studies will be needed in order to confirm these results and determine the benefits of sputum culture in other specific group of subjects.

#845 - Abstract

AN RDW-BASED SCORE PREDICTS LONG-TERM MORTALITY IN PATIENTS HOSPITALIZED WITH COMMUNITY ACQUIRED PNEUMONIA (CAP): A DERIVATION AND VALIDATION STUDY

Remo Melchio, [Jacopo Davide Giamello](#), Elisa Testa, Stefano Leccardi, Cristina Serraino, Christian Bracco, Andrea Paolo Falchetta, Elena Migliore, Chiara Brignone, Salvatore D'Agnano, Luigi Maria Fenoglio

Division of Internal Medicine, A.O. S. Croce e Carle, Cuneo, Italy

Background

red-blood-cell distribution width (RDW) has been associated with mortality in several clinical conditions, including CAP. Aim: derivation and validation of an RDW-based score to predict long-term (>3 months) mortality in patients admitted for CAP in a general ward.

Methods

This retrospective multicentric observational study consisted of a derivation and a validation cohort of patients admitted for CAP in Internal Medicine wards in 2016 and 2017. 87 clinical and laboratory candidate variables were collected. Main outcome was all cause of death, median follow up was 18 months; survival was estimated with the Kaplan–Meier method. Cox multivariate analysis was used to develop the score. In the validation cohort the predictive performance of the score was assessed by discrimination and calibration analysis.

Results

In derivation cohort ($N=405$, median age: 80 years, 56% males, median CURB65=2), 18-months mortality was 44% whereas in the validation one ($N=217$, median age 79 years, 54% males, median CURB65=2), was 34%.

Cox multivariate analysis identified as independent predictors for death: RDW (HR 1.18; 95%CI 1.10-1.25, $p<0.001$), systolic BP < 90 mmHg (HR 3.38; 1.76-6.48, $P<0.001$), BUN > 21 mg/dl (HR 1.58; 1.13-2.20, $p<0.005$), temperature (HR 0.84; 0.73-0.97, $p=0.02$), confusion (HR 2.84; 2.09-3.86, $p<0.001$). The predictive accuracy of the score showed good discrimination (c index 0.75 (95% CI 0.70-0.78) and 0.81 (0.77-0.84) in the derivation and validation cohort respectively) and calibration.

Conclusion

we derived and validated a simple clinical score including RDW to predict long-term mortality after admission for CAP in a general ward.

#860 - Medical Image

UNEXPECTED RADIOGRAPHIC FINDINGS

[María Elena Mansilla Rodríguez](#), Gloria María Rojano Rivero, Marta Sáenz De Tejada López, Blanca Hidalgo Armayones, Maryam Sidahi Serrano, Manuel Jesús Romero Jiménez
Hospital Infanta Elena, Huelva, Spain

Clinical summary

A 45-year-old man with a history of hypertension and an active smoker who was admitted due to global respiratory failure, respiratory syncytial virus respiratory infection, exacerbation of chronic bronchitis and heart failure. At admission, dilated cardiomyopathy with severely depressed left ventricular ejection fraction of ischemic origin was detected, requiring revascularization with drug-eluting stents. This chest x-ray shows global cardiomegaly, bilateral alveolar-interstitial infiltrate predominantly in bases with more consolidating areas and a lighter in the left pocket of the pajamas. The patient denied tobacco use during admission. With this case we want to highlight how difficult daily clinical practice can be when patients do not want to follow our clinical recommendations.

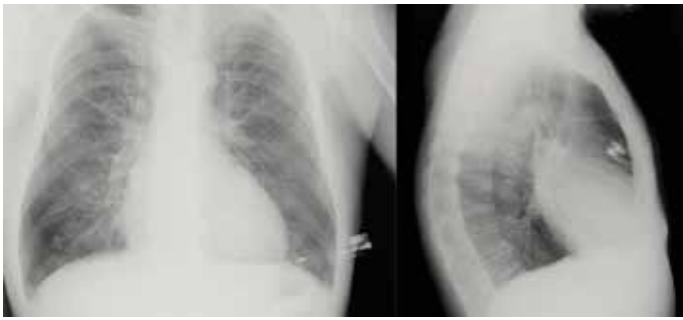


Figure #860. Chest X-ray.

#907 - Case Report

CAPILLARY LEAK SYNDROME AS A POSSIBLE COMPLICATION OF LOW-DENSITY LIPOPROTEIN APHERESIS: A CASE REPORT

Lucía Ordieres-Ortega, Luis Sánchez Cámara, María Luisa Rodríguez Ferrero, Pablo Demelo Rodríguez, Inés Ruiz Barranco, Daniel Barraca, Diego Barbieri Merlo, Ana María García-Prieto, Alexis Jaspe-Codecido, Fernando Anaya

Hospital General Universitario Gregorio Marañón, Madrid, Spain

Introduction

Capillary leak syndrome (CLS) is a rare and potentially lethal disease, characterized by hyperproteinaemia with sudden hypovolemia and oedema of the limbs. Its pathogenesis is still unclear. Around 500 cases have been reported worldwide. The average onset is around 47 years old and it is more frequent in women.

Most patients develop nausea, abdominal pain, polydipsia, dizziness, hypotension, oedema and kidney failure. Possible complications are compartmental syndrome, pulmonary oedema and shock. Diagnosis is mainly of exclusion, discarding other possible alternatives such as nephrotic syndrome, sepsis or transfusion-related acute lung injury (TRALI).

Case description

A 47-year-old female with a history of familiar hypercholesterolemia with LPL deficiency and five secondary episodes of acute pancreatitis, underwent a third low-density lipoproteins (LDL)-apheresis session without any disturbances. Six hours later, she arrived to the Emergency Department with dyspnoea and dizziness. Her blood pressure was 80/40 mmHg and her oxygen saturation 84%, with pulmonary hypoventilation. Two litres of saline solution were provided, along with supplementary oxygen on a Venturi mask at 31%.

The blood test, electrocardiogram and thoracic echocardiogram were normal.

A chest X-ray revealed severe pulmonary injury with bilateral pleural effusion and pulmonary overload with Kerley's A and B lines. She required intubation.

A computerized tomography described a marked bilateral pleural effusion with interstitial and alveolar oedema, without pulmonary embolism. Bilateral pleural drainage catheters were

placed, releasing 1500 cc each of trasudate. The patient's renal function worsened, requiring extra-renal depuration (ERD). She progressively recovered urine flow rates, and ERD was interrupted. Her respiratory function also improved, and she was extubated.

Microbiological cultures were negative.

Discussion

Our patient's clinical case presented a diagnostic challenge. A TRALI was considered, since the entire process began within the first 6 hours after the apheresis. However, the reposition was performed with albumin. The final diagnosis was that of CLS.

To date, no cases linking hypertriglyceridemia to CLS have been previously reported. Neither is there any case that establishes the plasmapheresis itself as a trigger of CLS.

CLS is a rare disease that can be fatal. It is important to include it in the

differential diagnosis and be aware of its possible complications, requiring an aggressive treatment.

#915 - Medical Image

TRACHEOBRONCHOPATHIA OSTEOCHONDROPLASTICA

Cátia Castanheira Figueiredo, Catarina Almeida, Nídia Oliveira, Joana Lemos, Alexandra Vaz, António Correia
Centro Hospitalar Tondela-Viseu, Viseu, Portugal

Clinical summary

Tracheobronchopathia osteochondroplastica is a rare disorder characterized by ossified lesions and cartilaginous nodules. Affects the lower two-thirds of trachea and proximal bronchi and the membranous part of the trachea is spared. It is more frequent in males, usually older than fifty years old. Its prevalence ranges from 0.2% to 0.7% and is often asymptomatic, but can manifest with chronic cough, hemoptysis or recurrent pneumonia. The etiology is not clarified. The authors describe the case of a 91 years old man that recurred to the ER with airway obstruction with food. The X-ray showed irregularity in tracheal surface. A bronchoscopy was performed and showed nodular calcificated lesions in the cartilaginous part of the trachea compatible with tracheobronchopathia osteochondroplastica.

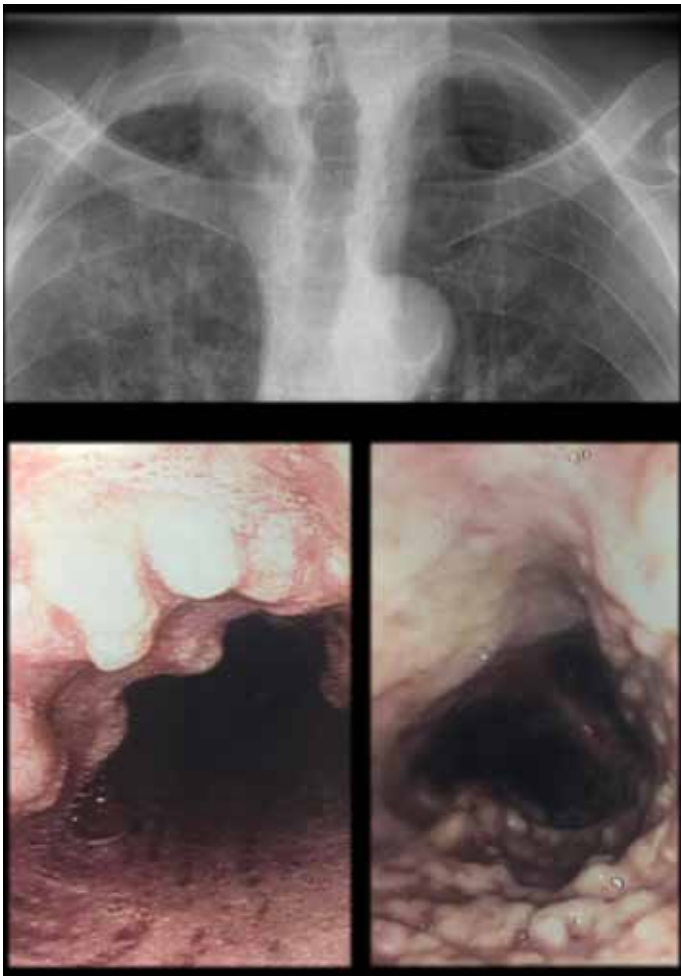

Figure #915.

#923 - Abstract

COMMUNITY ACQUIRED PNEUMONIA: A RETROSPECTIVE STUDY WITH CURB-65 SCORING ON ADMITTED PATIENTS

Pedro Carlos¹, Catarina Chaves², Clara Jorge¹, Ana Dionísio¹, Sónia Coelho¹, Artur Gama¹, Leopoldina Vicente¹

¹ Centro Hospitalar Universitário Cova da Beira, Covilhã, Portugal

² Centro Hospitalar Tâmega e Sousa, Penafiel, Portugal

Background

Pneumonia is a leading cause of morbidity and mortality worldwide, affecting up to 4,000,000 individuals annually on the UE. Mortality rates vary widely, with an estimated 13.6% on hospitalized patients.

Methods

Retrospective statistical data analysis included a total of 130 patients admitted to Internal Medicine ward with a diagnosis of community acquired pneumonia (CAP), between January 2017 and December 2018.

Results

From the total sample, 30% were male and 70% female. Age

varied between 33 and 101 years old (mean of 82,73 years). Hospitalization duration ranged from 1 day to a maximum of 44 days (mean of 10,67 days).

Microbiological pathogen identification was achieved in 33,08% of the cases: *Streptococcus pneumoniae* (62,7%), including 5 cases of invasive pneumococcal disease, *Pseudomonas aeruginosa* (13,9%), *Staphylococcus aureus* (methicillin-resistant 6,97% and methicillin-sensitive 4,65%), *Escherichia coli* (7%), *Proteus mirabilis* (2,35%) and *Citrobacter freundii* (2,35%).

Inpatient mortality rate was 13%, gradually increasing to 14.62% on 30-day and 21.53% after 6 months. Calculating the CURB-65 score on admission, only 3,08% had a score lower than 2, a low risk group that could be treated as outpatients, with mean hospitalization of 6.25 days and 0% mortality rate up to 6 month follow up. Patients with a score of 2 (35.4%), presented inpatient, 30-day and 6-month mortality rate of 4.35%, 6.52% and 13.4% respectively, with a mean hospitalization of 11.76 days.

An admittance CURB-65 score of 3 points was observed in half of patients (52.3%), with a mean hospitalization of 10.06 days. Mortality rate observed: inpatient and 30-day 16.2% and 6-month of 2.06%.

Finally, 9,23% of patients scored 4 on the CURB-65 scale, presenting the highest mean age (88,58 years) of all subgroups. Mortality rate: inpatient 33.3%, 30-day 41.67% and 6-month of 58.3%.

Conclusion

Application of CURB-65 on this sample presented similar findings to those reported previously (30-day mortality of 0.6%, 3%, 6.1%, 14.3% and 40% with scores of 0, 1, 2, 3 and 4 respectively). There was also a gradual increase of global mortality rate even until 6-months after a pneumonia episode and low rates microbiological pathogen isolation on CAP, with prevalence of *S. pneumoniae*, as reported on current literature. Clear limitations were the small sample dimension and failure to include outpatient care. Although its simplicity, the predictive prognostic value of this score can assist clinical decision making when necessary.

#925 - Abstract

IS IT REALLY COPD? CLINICAL MISCLASSIFICATION OF COPD IN AN INTERNAL MEDICINE WARD

Bruno Mendes^{1,2}, Carlos Figueiredo^{1,2}, Mariana Cabral^{1,2}, José Sousa^{3,2}, Sara Amaral^{4,2}, Sara Pinheiro⁵, Catarina Pires^{3,2}, Teresa Garci^{3,2}, Alexandra Mineiro^{1,2}, António Guerreiro^{3,2}, João Cardoso^{1,2}

¹ Pulmonology Department - Hospital Santa Marta, CHLC, Lisboa, Portugal

² Faculdade de Ciências Médicas - Universidade NOVA, Lisboa, Portugal

³ Internal Medicine Department - Hospital Santa Marta, CHLC, Lisboa, Portugal

⁴ Endocrinology Department - Hospital Santa Marta, CHLC, Lisboa, Portugal

⁵ Endocrinology Department - Hospital IPO, Lisboa, Portugal

Background

The objective of this study was to determine the real frequency of chronic obstructive pulmonary disease (COPD), according to the Global Initiative for Chronic Obstructive Lung Disease (GOLD), in patients who were admitted to the internal medicine ward of our hospital classified as having COPD due to history of exposure to risk factors or symptoms suggestive of the disease.

Methods

We conducted a retrospective study with evaluation of all patients admitted to internal medicine ward between January and December 2018. All patients with a former diagnosis of COPD in their electronic record (given by either a general practice physician or by former admissions to hospital) were included. In these selected patients we reviewed the spirometry prior to admission. We used forced expiratory volume in 1 second / forced vital capacity ratio (FEV1/FVC) < 0.70 post-bronchodilator as spirometry criteria for COPD diagnosis according to GOLD. Tobacco smoking and exposure to other noxious gases was assessed. Finally, we searched for symptoms of dyspnoea, chronic cough or sputum production at admission.

Results

COPD previous diagnosis was found in 58 (11.8%) of 488 patients admitted to the internal medicine ward. Among the COPD patients 38 (65.5%) had clinical records of performed spirometry, 25 (43.1%) of them with spirometrically confirmed COPD diagnosis, 5 (8.6%) with no spirometry criteria and in 8 (13.8%) the results were not available. 20 (34.5%) of the patients didn't perform any spirometry exam. Among the patients accessed 54 (93.1%) had history of exposure to risk factors, 21 (36.2%) emphysema and 28 (48.2%) symptoms suggestive of COPD during admission

Conclusion

In the reported study less than half of patients (43.1%) had a true diagnosis of COPD according to GOLD criteria. We emphasize that history, symptoms or radiology findings are not enough for a confirmed diagnosis of the disease as all patients had risk factors exposure, computed tomography scan changes or symptoms

suggestive of COPD but 8.6% showed no obstructive lung disease in spirometry. According to GOLD only spirometry can confirm COPD in a patient with a clinical context.

COPD is the third leading cause of death worldwide, killing more than three million people every year. The diagnosis of this disease is many times undervalued in clinical practice and spirometry not performed. We pretend to emphasize the importance of a correct diagnosis and management of COPD.

#940 - Case Report

EXTENSIVE THORACIC LYMPHADENOPATHY IN A YOUNG PATIENT: A DIAGNOSTIC CHALLENGE

Carlos Couto, Paula Pedro, Vicencia Ribeiro, José Duarte

Hospital Garcia de Orta, Almada, Portugal

Introduction

Mediastinal lymphadenopathies can be an incidental finding on an asymptomatic patient and they always imply a differential diagnosis between lymphoproliferative disease, tuberculosis or other infectious disease and sarcoidosis.

Case description

We present the case of a non-smoker caucasian 44-year-old male with no relevant personal medical history and naïve from medication, who worked as a locksmith. His father had deceased with a non-specified pulmonary cancer and the remaining familial medical past was irrelevant.

He was referred to our Pulmonology Clinic due to mediastinal lymphadenopathies, incidentally found on a surveillance chest x-ray and confirmed by thoracic CT.

He had been complaining of dry cough lasting for a year, nocturnal sweating, asthenia and weight loss of 10% of his body weight during the previous 6 months. The patient also mentioned xerophthalmia and large joint arthralgias (knees and elbows).

Several complementary exams were ordered in the pursuit of the diagnosis. From those exams, some results stood out. Blood tests revealed normal leucocyte count and CRP values, discretely elevated creatinine of 1.3 mg/dL (normal range: 0.6 to 1.1 mg/dL) and serum ECA of 60 UI/L (normal range: 30-50 UI/L). Tuberculin skin test showed cutaneous anergy. Sputum and bronchial secretion direct and cultural mycobacteriological examination were negative. 24 hours urine calcium revealed hipercalciuria with 427 mg calcium excreted in 24 hours (normal range: 100 to 320 mg/24 hours). Thoraco-abdomino-pelvic CT scan revealed plenty of mediastinal adenomegalies with 2.8 cm diameter maximum and also discrete retro-peritoneal lymph node involvement in the major abdominal and pelvic lymphatic chains. Endobronchial echoendoscopy was performed with lymph node puncture at the 11L, 7 and 11R stations, which was negative for neoplastic cells, alcohol resistant acid bacilli, and granulomatous lymphadenitis. Videobronchoscopy was ordered and bronchoalveolar lavage revealed lymphocytic alveolitis with elevated CD4 + / CD8 + ratio of 6.7.

After examining the clinical findings and the results from the complementary exams, the diagnosis of sarcoidosis was made. A therapeutic approach with prednisolone was started.

Discussion

This case illustrates a typical presentation of sarcoidosis with exuberant reumatological and constitutional symptoms and the radiological evidence of impressive conglomerate of large lymphadenopathies. Being an exclusion diagnosis, the case highlighting the need for a cautious workup.

#948 - Case Report

THE DIFFERENT FACES OF ASPERGILLUS

Juliana Sofia Jesus Barata, Roberto Silva, Mafalda Baptista, Sara Martins, Ana Craveiro, Eunice Magalhães
Centro Hospitalar Universitário da Cova da Beira, Covilhã, Portugal

Introduction

Aspergillus spp is a fungus that exists in the environment and is commonly isolated both from the outer and inner environment, including hospitals.

It may be manifested by a variety of infectious and allergic diseases depending on the host's immune status and structural lung changes. The most frequently identified agent is *Aspergillus fumigatus*.

Case description

The authors present 4 clinical cases evidencing the different pathological forms by *Aspergillus*.

Initially we present the most common form. 66-year-old male, with sequelae of pulmonary tuberculosis and bronchiectasis, complaining of sporadic haemoptysias by aspergilloma in the right upper lobe.

Secondly, we report a case of a 62-year-old male, non-smoker, obese, followed in consultation for severe allergic bronchial asthma of difficult control in treatment with omalizumab with high total IgE E, specific IgE for *Aspergillus fumigatus* positive and radioallergosorbent test (RAST) for fungi and yeast positive, thus treating a case of allergic bronchopulmonary aspergillosis without central bronchiectasis.

Third, 70-year-old female, asymptomatic, followed in consultation of pulmonology since 2002 by bilateral millimetric excavated nodules. The etiological investigation revealed specific IgG for *aspergillus fumigatus* and excluding all other causes of cavitary disease we assumed the diagnosis of chronic cavitary aspergillosis. Finally, a case of invasive pulmonary aspergillosis in a 46-year-old patient with a history of systemic lupus erythematosus with renal, cutaneous and joint involvement under systemic corticosteroid therapy.

Discussion

We have shown the different forms of presentation of *Aspergillus* in patients with distinct and specific clinical features, often being a diagnostic and therapeutic challenge.

#961 - Case Report

IT'S NOT ALWAYS PULMONARY TUBERCULOSIS: A SUSPECTED CASE OF PULMONARY ALVEOLAR MICROLITHIASIS

Natacha Silveira¹, Orlando Cardoso², Maria José Manata², Fernando Maltez²

¹ Department of Medicine, Portimão Unit - Algarve Hospital University Center, Portimão, Portugal

² Department of Infectious Diseases, Curry Cabral Hospital - CHLC, Lisboa, Portugal

Introduction

Pulmonary alveolar microlithiasis is a rare autosomal recessive disorder characterized by deposition of calcium phosphate microliths in the lungs. Despite the dramatic imaging findings, the patients are often asymptomatic and the diagnosis is incidental.

Case description

We present a 30 year-old female, Nepalese but residing in Portugal for three years, admitted by dyspnea and productive cough with two months of evolution, associated with hemoptoic sputum in the previous days. She was previously treated for pulmonary tuberculosis in Nepal six years ago, with no medical records of specified regimen, but having completed six months of therapy. Analytical studies demonstrated leukocytosis (12290/uL) without neutrophilia, C-reactive protein 4.4 mg/L. Arterial blood gas was normal.

Chest radiography showed an interstitial pattern, with multiple bilateral lung nodules, most of them in the lung basis. Computed tomography scan detected several micronodules with hyperdensity dispersed throughout the lungs, with predilection for the basis.

A bronchofibroscope was made and all the microbiologic products were negative for tuberculosis. Pulmonary function tests showed moderate restrictive pattern.

The patient was discharged and referred to pneumology in outpatient care, while waiting genetic testing for SLC34A2.

Discussion

Although the symptoms and chest radiography were suggestive of miliary tuberculosis, such diagnosis was not confirmed throughout the investigation. This case highlights the importance of the differential diagnosis and to think in other hypothesis less frequent, such as this entity. Sarcoidosis was also excluded. The mismatch of clinic (the patient had no hypoxemia) and radiologic results were suggestive of pulmonary alveolar microlithiasis.

Long-term prognosis is poor, with slow progression to respiratory failure. There is no effective therapeutic option for this disease, with lung transplant being the only successful modality and with a low rate of recurrence.

#969 - Case Report

INVASIVE ASPERGILLOSIS IN IMMUNOCOMPETENT HOST: A CASE REPORT

Bárbara Soeiro, Rosário Monteiro, Diana Amorim, Cristina Rodrigues, Sílvia Correia

ULSM - Hospital Pedro Hispano, Matosinhos, Portugal

Introduction

Four main syndromes caused by *Aspergillus* species in human are identified: allergic bronchopulmonary aspergillosis, chronic necrotizing pneumonia, aspergilloma and invasive pulmonary aspergillosis (IPA). The latter is the most aggressive form, evolving frequently with lung necrosis and usually occurs in patients with immunodeficiency.

Case description

We describe the case of a 62-year-old man with a history of gastric carcinoma considered cured, lung adenocarcinoma (pT2aNORO) submitted to left superior lobectomy and adjuvant chemotherapy with a 3.5 years follow-up without relapse. He was an active smoker (180 pack-year), with lung emphysema and also an alcoholic chronic liver disease.

He presented with 2 months of weight loss, anorexia and fatigue. In the 2-weeks preceding our observation, he started progressive dyspnea, cough with purulent sputum and left pleuritic pain. On admission, he showed tachypnea, diffuse crackling on lung auscultation, type 1 respiratory failure and a fever of 39.5°C. Blood tests revealed a PCR of 246 mg/L and leukocytosis of 17120/uL with neutrophilia. Rapid antigen testing for Influenza A was positive. Chest CT-scan showed multiple bilateral consolidation areas, a cavity lesion in the left medial lobe and a diffuse micronodular infiltrate.

A diagnosis of flu with secondary bacterial infection was initially made and he completed oseltamivir plus amoxicilina/clavulanate treatment. He improved clinically but maintained marked fatigue. No bacteria grew on sputum cultures, and direct Ziehl-Neelsen coloring was negative. Control CT-scan was performed and showed progression of micronodular infiltrate, same dimension cavity and only partial resolution of consolidation. A bronchofibroscopy was performed and bronchoalveolar lavage showed growth of *Aspergillus fumigatus* on all samples. An endobronchial lesion was biopsied and showed hyphal invasion of the bronchi, confirming a diagnosis of invasive pulmonary aspergillosis.

The patient was started on intravenous voriconazol for 7 days and continued on oral formulation with good tolerance. He maintains clinical improvement after 3-weeks of treatment. Total time of therapy will be decided upon clinical and imagological evolution.

Discussion

Aspergillus invasive infection is increasing in critical ill patients, but was classically described in severe immunosuppression (HIV, chemotherapy or transplanted). There are some reports on immunocompetent host. Some reports suggest the potentiation with Influenza co-infection.

#974 - Medical Image

A CASE OF CANNONBALL METASTASIS

Duarte André Ferreira, Mauro Fernandes, Margarida Temtem, Tatiana Henriques, Maria Luz Brazão

Hospital Central do Funchal, Funchal, Portugal

Clinical summary

A 64 year old man, smoker, former alcoholic, with history of bladder urothelial neoplasia, with transurethral resection a year ago, presented to the emergency department with weight loss in the last 4 months; dyspnea, productive cough and muco-purulent expectoration with about 3 weeks of evolution. In the last days, he also referred thoracic pleuritic pain. On examination he was afebrile, emaciated. On auscultation he presented snorings on both lung fields. The thoracic radiography and computer tomography (CT) showed multiple rounded hypodensities scattered bilaterally, "balloon release". The abdominal and pelvic CT also showed other possible metastasis on the liver and left adrenal gland. The primary neoplasia was probably on the left pelvis or right pelvic ureter.

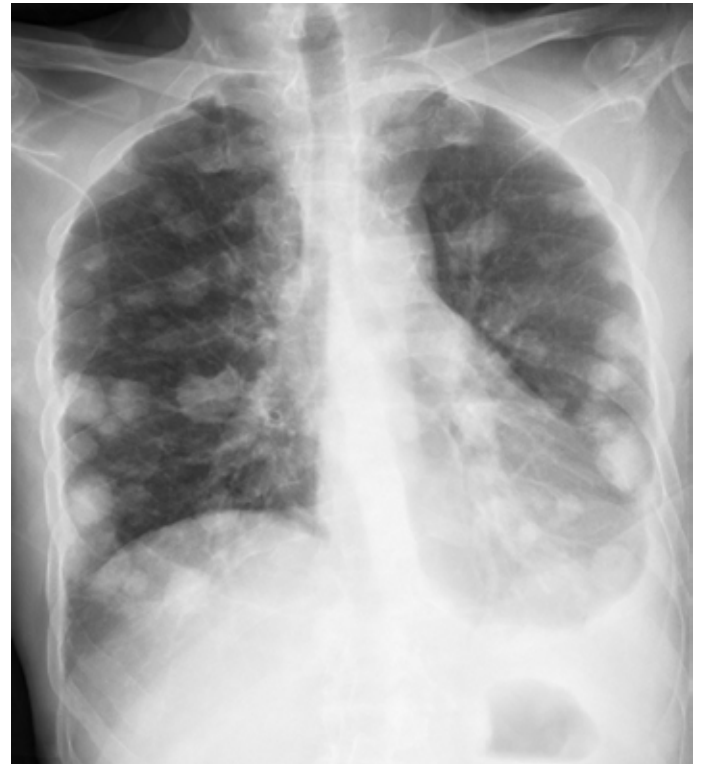

Figure #974. Cannonball metastasis.

#1008 - Case Report

SARCOIDOSIS - THE CHALLENGE OF A DIAGNOSIS

Margarida Temtem, João Aragão Vital, Rafael Nascimento, Maria João Ribeiro, João Miguel Freitas, Rubina Miranda, Maria Da Luz Brazão

Central Hospital of Funchal, Funchal, Portugal

Introduction

Sarcoidosis is a non-infectious, multisystemic granulomatous disease of unknown etiology. Typically affects young adults and it presents one or more of these characteristics: bilateral hilar adenopathies, reticular pulmonary opacities or cutaneous, articular or ocular injuries.

Case description

Man, 55 years, black ethnicity, was admitted to Emergency Department (ED) with productive cough with green expectoration started 1 month before, worse myalgias, anorexia and fever sensation with night sweats. Involuntary weight loss of 16 kilograms in one month. On admission presented polypnea at rest, 90% of peripheric oxygen saturation and pulmonary auscultation with crackles on bases. Arterial gasimetry: respiratory alcalemia and hypoxemia. Blood tests: lymphopenia. Chest radiography: bilateral diffuse pulmonary opacities. He was hospitalized with the diagnosis of community-acquired pneumonia and started empirical antibiotic therapy - amoxicillin+clavulanic acid+clarithromycin. On the 4th day, he presented clinical worsening with dry cough, thoracalgia and hypoxemia. Chest computed tomography (C-CT): "interstitial lung disease with non-typical morphological pattern: usual or non-specific interstitial pneumonitis". He started oseltamivir. Serologies for influenza A and B, IgM antibodies for atypical respiratory agents, rapid HIV test, blood and urine cultures, Kock bacillus and bacteriological examination of sputum with search of alcohol-acid resistant bacillus - all negative. Autoimmunity study - negative. He repeated C-CT after his infectious condition: "emphasis of bilateral reticulo-interstitial accentuation, symmetrical and distal predominance, associated with densification in depolyzed glass more evident in the lower lobes."

Angiotensin-converting enzyme was ordered (360.5 U/L) and bronchofibroscopy was scheduled+bronchoalveolar lavage collection. The patient refused to do these exams. It was assumed the probable diagnosis of sarcoidosis and started a therapeutic trial with prednisolone 40mg/day. He had a great response to therapy.

3 months later C-CT: "diffuse bilateral subpleural interstitial fibrosis+pulmonary parenchymal nodularities and depolyzed glass opacities; these aspects were less expressive than the previous exam, particularly with resolution of depolished glass opacities."

Discussion

The diagnosis of sarcoidosis is by exclusion of others probable diagnosis, is rare and may mimic other systemic diseases, such as vasculitis or tumors. Thus, it becomes challenging the diagnosis.

#1036 - Medical Image

EMPYEMA – THE IMAGING CHALLENGE

Ana Paula Antunes, Tânia Strecht, Madalena Sousa Silva, Carolina Sequeira, Ana Gorgulho, Inês Vicente, Alexandre Nascimento Fernandes, Catarina Vizinho Oliveira
Hospital de Cascais, Lisboa, Portugal

Clinical summary

Empyema is characterized by a bacterial infection on the pleural space that evolves into a purulent collection. Respiratory failure and, in some cases, sepsis can lead to death. Rapid intervention is therefore crucial; however the imaging evaluation is sometimes a challenge. We present a case of an 84-year-old man who turns to the Emergency Department for dyspnea, fever and cough. On observation: subfebrile, with abolished vesicular murmur in the right base with crackles. Chest CT scan revealed a collection with about 9.2 cm of axial axis with a locus of gas, thickened wall, adjacent to the pleura. Initially treated as a pulmonary abscess, it evolved with the need for CT-guided drainage; latest imaging control after antibiotic cycle of 8 week showed a liquid blade 9 mm thick.

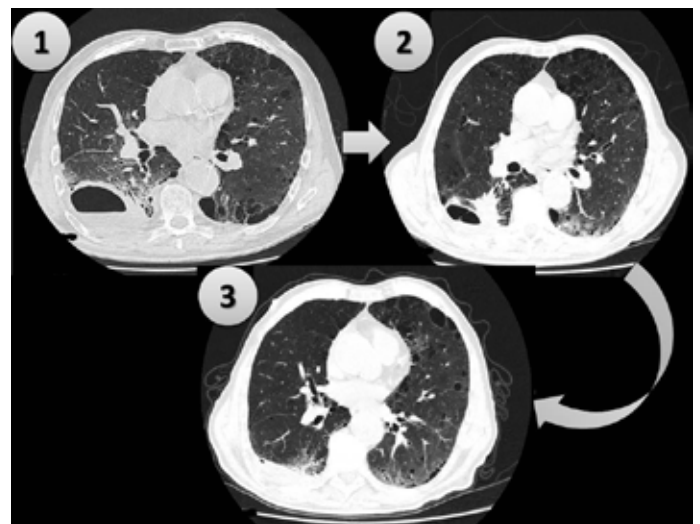


Figure #1036. The evolution of empyema on CT scan.

#1065 - Medical Image

LEFT PULMONARY HERNIA AS A COMPLICATION OF RESPIRATORY EXACERBATION

Lucía Meijide Rodríguez, María Folgueras Gómez, Elisa Esther Rodríguez Ávila, Andrea Carro González, Claudia Morán Castaño, Sara Rodríguez Suárez, Carmen Yllera Gutiérrez, Jessica Rugeles Niño, Silvia Suárez Díaz, Lucía Suárez Pérez
Central University Hospital of Asturias, Oviedo, Spain

Clinical summary

A 72-year-old woman, who has asthma with several exacerbations in the last year, is admitted to the hospital for dyspnoea, accompanied by cough since one week ago. She was treated with

Moxifloxacin and Salbutamol, but dyspnoea persists. Likewise, she recounts a left costal pain with pleuritic characteristics since four days ago. Physical examination shows a small hematoma in the left costal side.

Due to the presence of a persistent chest pain, a chest CT is performed, which shows a pulmonary parenchyma herniation through the eighth left intercostal space, which could justify patient's pain.

The patient is evaluated by the Thoracic Surgery Service, which recommends treatment of acute respiratory symptoms and subsequently assess the surgical attitude of the pulmonary hernia.

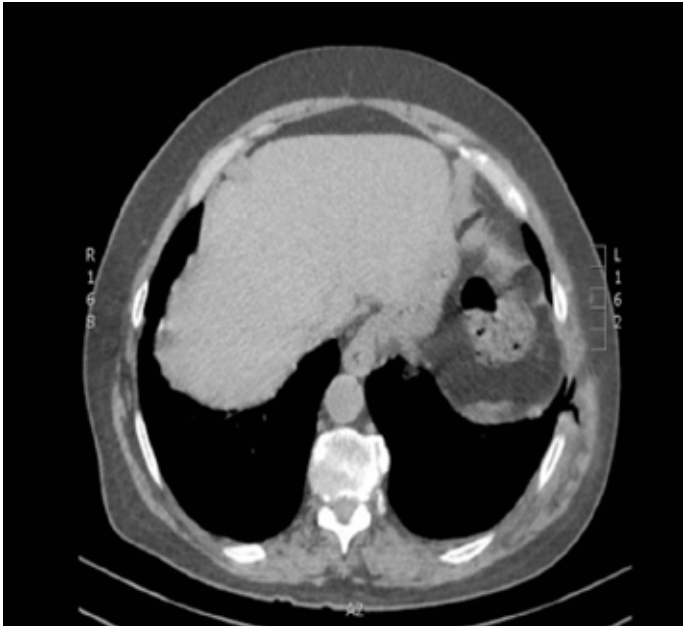


Figure #1065.

#1083 - Case Report

IDIOPATHIC PLEUROPULMONARY FIBROELASTOSIS - A RARE ENTITY

Rosana Maia, Marta Moreira, Pedro Pinto, Miguel Costa, Duarte Silva, Edgar Torre, Vitor Pereira, Carmélia Rodrigues, Diana Guerra

ULS Alto Minho - Hospital de Santa Luzia - Viana do Castelo, Viana do Castelo, Portugal

Introduction

Idiopathic pleuropulmonary fibroelastosis (IPPF) is a rare pulmonary interstitial disease, characterized by fibrosis of the visceral pleura and pulmonary parenchyma, with no identified etiologic factor.

Case description

Female, 79-year-old, with chronic respiratory disease, hypertensive, non-smoker, partially dependent, referred to the Emergency Department (ED) for fever, dyspnoea, productive cough and abdominal pain. Respiratory frequency 43 cpm, blood pressure 89/57 mmHg, cardiac frequency 88 bpm, oxygen

saturation (OS) 98% (FiO₂ 24%). Pulmonary Auscultation: scattered crepitations. Arterial gasometer: pH 7.40, pCO₂ 48 mmHg, pO₂ 73 mmHg, HCO₃ 29.7 mmol/L, Lactides 0.5 mmol/L, OS 94%. Analytically, PCR 25.82 mg/dL and BNP 1676.5 pg/mL. Chest x-ray: diffuse interstitial infiltrate, more pronounced to the left. Admitted for decompensated heart failure, pneumonia with multiresistance risk factors and global respiratory failure (RF). She completed 7 days of antibiotic therapy with ceftriaxone and azithromycin. Due to persistence of increased inflammatory parameters, chest and abdominal pain, abdominal ultrasound and thoraco-abdominopelvic CT were performed: pulmonary fibrosis, biliary consolidation foci and pleural effusion (PE). Thoracentesis: complicated parapneumonic PE. Clindamycin was initiated and thoracic drainage was placed (removed at the 33rd hospitalization day). Due to the absence of clinical improvement, after performing bronchofibroscopy and CT guided lung biopsy, corticosteroid therapy was initiated. Improvement of dyspnoea and RF. Histology: IPPFE.

Discussion

The prognosis of IPPFE is highly variable and unpredictable. Clinical suspicion and appropriate diagnostic guidance is important. No therapy has been shown to alter its natural history, however, lung transplantation may be considered in more advanced stages.

#1117 - Medical Image

THE SECRET WITHIN PLEURAL EFFUSION

Inês S F Da Silva, Inês B. Mesquita, Cláudia Sofia Santos, Salvato Feijó, Alcina Mota Ponte

Centro Hospitalar de Leiria, Leiria, Portugal

Clinical summary

A caucasian 47-year-old male, presented with pleuritic chest pain. He also reported 2 weeks of fever, night sweats, asthenia, nonproductive cough and dyspnea on physical exertion. He had positive familial history of tuberculosis. On examination, the temperature was 38°C, oxygen saturation 96% (FiO₂ 21%). Absent vesicular breath sounds and vocal fremitus at the right lung base on lungs' examination. Chest X-ray showed right pleural effusion. Thoracentesis and bronchofibroscopy were performed. Pleural fluid had 668/mm³ total nucleated cells, 87% mononucleated cells. Chest CT scan was also performed and showed cavitation of the right upper lobe. *M. tuberculosis* was detected using molecular biology. Antituberculous therapy was administered.

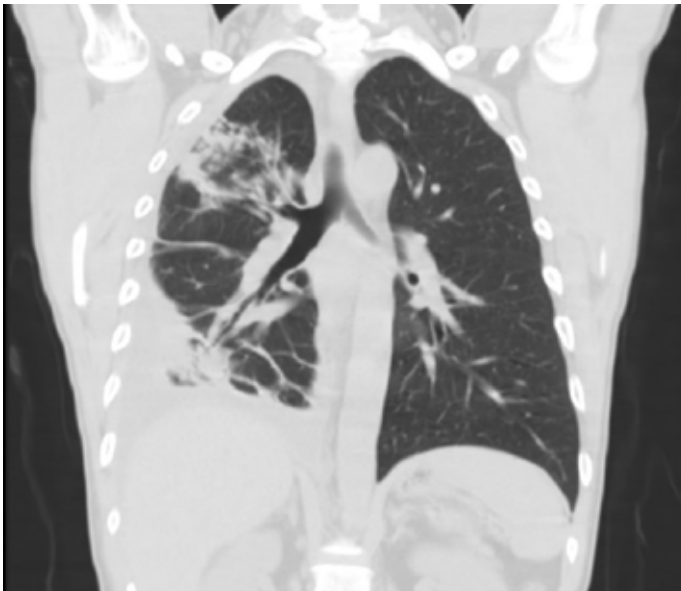


Figure #1117. Chest CT scan shows cavitation of the right upper lobe.

#1128 - Abstract

ASSESSMENT OF THE USE OF BETA-BLOCKERS IN PATIENTS WITH CHRONIC OBSTRUCTIVE PULMONARY DISEASE (COPD)

Sonia Peña Balbuena, Alexander Bezerin, Carlos Santos Martín, Jose Ignacio Madruga

Hospital Clínico Universitario de Salamanca, Salamanca, Spain

Background

The most common comorbidities in COPD are cardiovascular. The benefits of beta-blockers (BB) in COPD have been clearly established because they reduce the risk of death and exacerbations. The main goal of this study is to analyze the use of BB in COPD patients. We will also discuss in-hospital mortality and the existence of a previous history of exacerbation with the use of BB on admission.

Methods

An observational study was carried out with patients with a previous diagnosis of COPD admitted in Internal Medicine, for a period of 6 months. We registered epidemiological, clinical and evolutionary data. The data are presented as frequency (percentage) and mean value (standard deviation). An analysis of the subgroups compared the use or lack of use of BB in patients with cardiovascular comorbidities in which the use of BB has been proven to reduce the risk of mortality: heart failure (HF) and ischemic heart disease (IHD). The chi-squared test was used and statistical significance was established for values of $p < 0.05$.

Results

In total 65 patients were included in the study, 53 (81.5%) men. The mean age was 77 years (9.9). According to the GesEPOC guidelines, their phenotypes were non-exacerbator 26 (40%), exacerbator-emphysema 18 (27.7%), mixed COPD-asthma 12

(18.5%), exacerbator-chronic bronchitis 7 (10.8%) and undefined 2 (3.1%). With regard to the severity: 11 patients (16.9%) presented low risk and 54 (83.1%) high risk. The average BODEx index was 2.9 (1.8), with 30 mild cases (46.2%), 18 moderate (27.7%), 14 severe (21.5%) and 3 very severe (4.6%). Some type of cardiovascular comorbidity was presented in 76.9% of the patients: 64.6% arterial hypertension, 40% heart failure (HF), 16.9% ischemic heart disease and 20% atrial fibrillation. The average number of exacerbations prior to admission was 0.6 (0.9). In-hospital mortality for all causes was 8 patients (12.3%).

We observed that only 10 (34.5%) of patients with HF or IHD received BB. Within this group, none of the patients who died had received BB (5 patients, 100%; $p=0.04$). No statistically significant differences were observed between the patients who received BB or those who did not receive it on admission regarding their previous status as exacerbators or non-exacerbators.

Conclusion

Beta blockers are clearly underused in patients with COPD and cardiovascular comorbidity, especially relevant among those patients with HF or IHD, because its use reduces the risk of mortality and exacerbations.

#1140 - Medical Image

WHEN A PNEUMONIA COMPLICATES - ABOUT A CASE OF HYDROPNEUMOTHORAX IN A YOUNG MAN

Margarida Brito Monteiro, Mariana Beja, António Madeira Gerardo, Marta Jonet

Hospital Prof. Doutor Fernando Fonseca, E.P.E., Amadora, Portugal

Clinical summary

A 30-year-old man with schizophrenia was hospitalized due to decompensation of his underlying disease. During the hospitalization, he developed a fever and a productive cough. He had increased inflammatory parameters and a well defined hypotransparency in the base of the left lung in the chest radiography. He was diagnosed with nosocomial pneumonia and started empirical antibiotic therapy. On the 4th day, due to deterioration, a chest CT was ordered. Extensive densification at the base of the left inferior lobe with central cavitation and multiloculated pleural effusion was found. To exclude tuberculosis he underwent a bronchofibroscopy. Despite that, patient continued to aggravate. A new CT showed a hydropneumothorax, with loculated areas and atelectasis of almost the entire left lung.

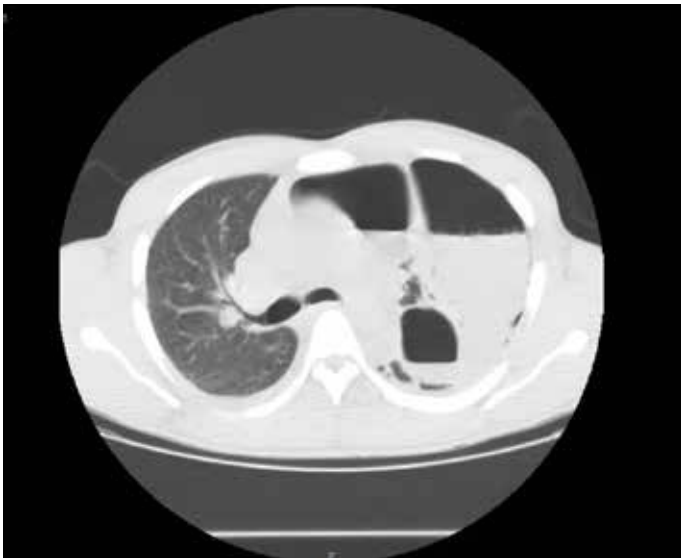

Figure #1140. On the right side of the image, there is atelectasis of the left lung, with a necrotic areas and with septum hydro-aerial levels. On the right we see a healthy lung.

#1164 - Medical Image PNEUMATOCELE

Sara Braga, Joana Ribeiro

Hospital Sousa Martins, Guarda, Portugal

Clinical summary

A pneumatocele is a cavity in the lung parenchyma filled with air that may result from pulmonary trauma or most often as a sequel to acute pneumonia, commonly caused by *Staphylococcus aureus*. The first line of therapy is the treatment of the underlying pneumonia with antibiotics. There is usually a slow resolution with no squeals.

These images belong to a 45-year-old man, who has a severe glioblastoma.

When CT was performed in the patient due to the possibility of a pulmonar embolism, which was confirmed, a pneumatocele was also discovered.

The first image is at admission and the second is after treatment with Vancomycin and Clindamycin. Due to the advanced condition in which the patient is, we could not exclude an aspiration pneumonia.

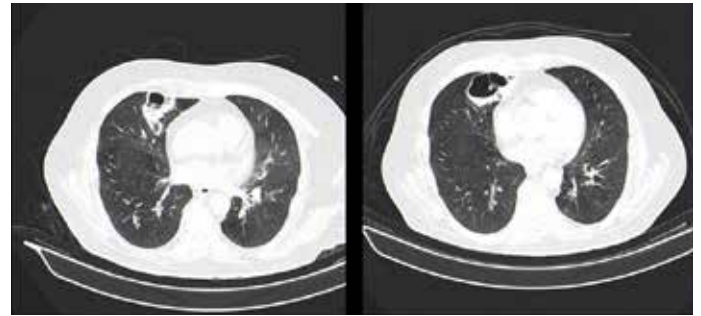


Figure #1164. Left: at admission. Right: after treatment.

#1165 - Medical Image

PLEURAL PLAQUES: MARKERS OF ASBESTOS EXPOSURE

Paulo Almeida, Tiago Valente, Viktor Malyarchuk, Beatriz Pinheiro, Ana Araújo

Centro Hospitalar do Baixo Vouga, Aveiro, Portugal

Clinical summary

An 80-year-old man who worked as a construction worker was admitted in the Medicine ward due to decompensated heart failure. The chest radiograph (CRX) showed well delimited focal areas suggestive of pleural calcifications (Panel 1). A high resolution computed tomography (HRCT) of the chest revealed multiple gross calcifications, some of them associated with pleural thickening areas suggestive of pleural plaques (PP), without pulmonary parenchyma changes (Panel 2 and 3). The pulmonary function tests, bronchofibroscopy and pleural biopsies had no alterations. PP are a marker and the commonest manifestation of asbestos exposure. A CRX is used as the standard method, but HRCT is more sensitive and specific. Due to the high risk of lung cancer, our patient kept follow-up.

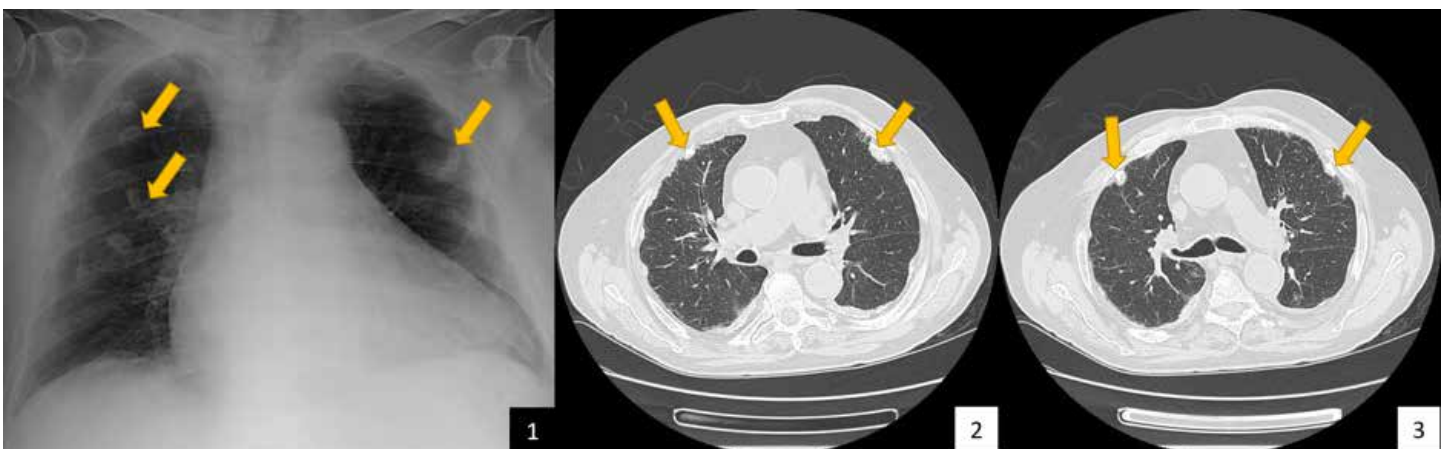


Figure #1165.

#1190 - Medical Image

REEXPANSION PULMONARY EDEMA AFTER PLEURAL DRAINAGE

Sónia Isabel Silva Guerra, Mariana Conceição, Ângela Cunha, Joana Correia, Jorge Vale

Centro Hospitalar Tondela-Viseu, Viseu, Portugal

Clinical summary

A 65-year-old male with gastric adenocarcinoma under palliative chemotherapy presented with a six-week history of progressive dyspnea. Chest radiography (CR) showed a large left pleural

effusion with contralateral mediastinal shift (Panel 1). A thoracic drain was placed, and 4700 mL of serous hematic fluid were evacuated in the first 24 hours. Despite relieving dyspnea, the CR showed left diffuse alveolar infiltrates, suggestive of reexpansion pulmonary edema (RPE) and subcutaneous emphysema (Panel 2). After diuretic and oxygen treatment, reduction of alveolar opacities was observed (Panel 3). RPE is a rare complication of pleural drainage. Prolonged lung collapse and rapid reexpansion during drainage are risks factors. Asymptomatic cases require careful observation. Treatment is supportive.

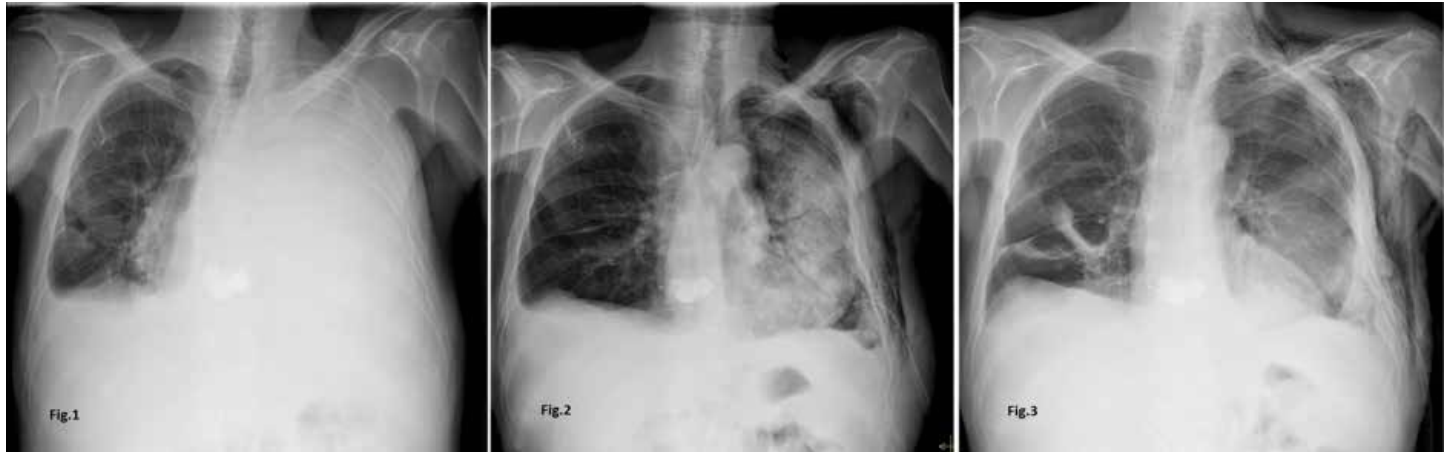

Figure #1190. Panel 1: Left pleural effusion. Panel 2: Reexpansion pulmonary edema. Panel 3: Resolution of reexpansion pulmonary edema after treatment.

#1194 - Case Report

SEPTIC PULMONARY EMBOLISM – A CASE REPORT

Sónia Isabel Silva Guerra, Mariana Conceição, Ângela Cunha, Joana Correia, Jorge Vale

Centro Hospitalar Tondela-Viseu, Viseu, Portugal

Introduction

Septic pulmonary embolism (SPE) is a rare and serious disease. The emboli containing pathogens, commonly *Staphylococcus aureus*, embolize through pulmonary artery causing focal lung abscesses. Infective endocarditis of the tricuspid valve is one of the most common origin. The treatment consists in broad spectrum antibiotics and surgical treatment if no focus reduction.

Case description

A 40-year old male with history of hepatitis C and drug addiction, presented at Urgency Department with symptoms of persistent fever (maximum 39°C) and 1 month evolution of dyspnea, cough with purulent sputum, intermittent hemoptysis, pleuritic pain, weigh loss and anorexia. Chest X-ray showed heterogeneous hypotransparency at right lower lobe. The inflammatory parameters were increased. The patient had already been treated with levofloxacin, but with no significant improvement. A computerized tomography chest scan was done and showed

multiple images of pulmonary consolidation, much of them with cavitation and surrounded by ground-glass areas in lower lobes. He was hospital admitted and treated with broad spectrum antibiotics. Given the history of intravenous drug abuse, a thoracic echocardiogram was performed and showed a 11 mm vegetation in tricuspid valve, therefore assumed SPE from infective endocarditis. Blood cultures were positive for *Staphylococcus aureus* methicillin-sensitive. He completed 4 weeks of flucloxacillin with progressive recovering and reduction of tricuspid vegetation.

Discussion

The characteristics of SPE at presentation are nonspecific and usually go unrecognized by clinicians. SPE should be suspected in high risk patients, principally with injectable drugs use and symptoms of fever, dyspnea and thoracic pain. Images of multiple pulmonary nodules with or without cavitation are very suggestive. Mortality is high, thus an infectious focus should be promptly investigated to improve prognosis.

#1197 - Case Report

GOOD'S SYNDROME

Lucía Ordieres-Ortega, Guillermo Soria Fernández-Llamazares, Eva Cervilla Muñoz, María Toledano Macías, Nuria Gabarro López
Hospital General Universitario Gregorio Marañón, Madrid, Spain

Introduction

Good's syndrome (GS) is defined by the presence of hypogammaglobulinemia and thymoma, and causes a T-cell dysfunction. Patients develop opportunistic infections, especially due to encapsulated pathogens.

Also, more than half of the patients with thymoma present autoimmune manifestations, including pure red cell aplasia, systemic lupus erythematosus or myasthenia gravis.

Treatment includes thymectomy and corticosteroid treatment. However, GS may still progress after treatment, leading to persistent infections, which will define the patient's prognosis. Intravenous immunoglobulin can be effective as a prophylaxis if the patient presents persistent hypogammaglobulinemia.

Case description

A 68-year old woman was admitted to the hospital for a 3-days history of fever, cough and dyspnoea. She also referred important weakness, weight-loss and joint pain during the previous month. A chest computed tomography revealed a 5x3.2 cm paracardiac mass in contact with right atrium, and multiple supraclavicular and paratracheal adenopathies. At day 6 the patient developed acute respiratory insufficiency, requiring orotracheal intubation with ventilatory support. The bronchial aspirate (BAS) culture was positive for *Mycobacterium tuberculosis*, *Aspergillus fumigatus* and *Aspergillus terreus*. A polymerase chain reaction (PCR) of the BAS was performed, being positive for *Pneumocystis jirovecii* and *Mycobacterium tuberculosis*.

A biopsy of a supraclavicular adenopathy confirmed also ganglionic tuberculosis (TB). PCR for CMV in a blood sample was positive with titles of 431 copies/mL. The patient started treatment with ganciclovir, sulfamethoxazole-trimethoprim, prednisone, voriconazole and first line anti-TB agents. The immunological assessment showed total lymphopenia with low CD4, CD8 T-cells and B-cells, hypogammaglobulinemia with IgG4 deficiency and severe hypocomplementemia. Intravenous immunoglobulin treatment was initiated. Thymectomy was performed with a pathologic diagnosis of B2 thymoma.

Discussion

To the best of our knowledge, there are less than five reported cases of GS with *Mycobacterium* in the literature, which makes our case distinctive and helps broaden the scarce intelligence on the topic.

Early recognition and treatment of GS are important to prevent complications and avoid recurrent infections, especially considering that its prognosis is generally not good.

GS should always be suspected in patients with thymoma and recurrent infections.

#1200 - Case Report

LUNG ABSCESS PRESENTED AS CHEST WALL TUMEFACTION

Sónia Isabel Silva Guerra, Mariana Conceição, Ângela Cunha, Joana Correia, Jorge Vale

Centro Hospitalar Tondela-Viseu, Viseu, Portugal

Introduction

Lung abscess is defined as necrosis of lung parenchyma in a confined area caused by microbial infection (usually anaerobes), mainly in a patient prone to aspiration of oropharyngeal content and/ or with associated periodontal disease. Rarely, it can be complicated by extension of infection, invading other structures such as ribs, mediastinum and soft tissue of the chest wall. The causative pathogens include *Mycobacterium tuberculosis* and *Actinomyces spp.*, and *Staphylococcus aureus* has rarely been reported.

Case description

A 42-year-old male, non-smoker, no history of drugs or alcohol addiction, presented at Urgency Department with 3 weeks history of painful and increasing tumefaction on the right anterior chest wall, dry cough, anorexia and weight loss of 4 kg. On physical examination, he had no signs of respiratory distress, oxygen saturation 99% on ambient air, low-grade fever and unremarkable haemodynamic parameters. Poor dentition was observed. On the upper right anterior chest wall, a 9 cm mass with inflammatory signs was palpable. No abnormalities at auscultation. The inflammatory parameters were increased. Chest radiograph showed right superior diffuse opacity and chest ultrasonography confirmed a tumefaction liquid content. Contrast-enhanced computerized tomography (CT) chest scan showed multiloculated, heterogeneous, 9x2 cm collection on thoracic wall posteriorly to pectoralis major muscle, enhancing walls and small bullae, which contacts another intrathoracic collection in right superior lobe, also heterogeneous with 4.6x3.9 cm with liquid and gaseous content; no pleural effusion. The patient was hospitalized with diagnosis of lung abscess with extension to chest wall, under broad spectrum antibiotherapy. The bronchoscopy showed mucosal edema and purulent secretions, without endobronchial lesions. Methicillin-sensitive *Staphylococcus aureus* (MSSA) was isolated in bronchoalveolar lavage. CT-guided aspiration yielded purulent material and MSSA was also isolated. He completed 6 weeks of antibiotherapy with recovery and progressive decrease of the abscess cavity size.

Discussion

In this case, a lung abscess had a rare manifestation extending into the chest wall, which can difficult the diagnosis. It can be misdiagnosed as malignancy, leading to a delay in treatment and unnecessary diagnostic procedures. Imaging studies and sampling by aspiration or biopsy are decisive. Appropriate antimicrobial therapy and prompt drainage are the mainstays for a successful outcome.

#1239 - Medical Image

A GIANT BUBBLE IN COPD PATIENT

César Vieira, Rita Lencastre Monteiro, Rodrigo Leão, Rita Bizarro, Cátia Carvalho, Joana Diogo, Angela Ghiletchi, Carolina Coelho, Sebastián Parente, Cristina Lima, Conceição Loureiro
Hospital Santo António dos Capuchos - CHULC, Lisboa, Portugal

Clinical summary

59-year-old black male, carpenter, smoker, without regular medical follow-up. Was admitted at emergency department with fever (38°C), purulent cough and dyspnea. At observation, pulmonary murmur was globally diminished specially at the right hemithorax. The arterial blood gas (FiO₂ 21%) showed a global respiratory failure. Analytically we found increased inflammatory parameters and viral, bacteriological and IGRA tests were all negative. The thoracic computerized tomography showed a severe pulmonary emphysema with a giant air blisters (blebs). We admitted community respiratory infection and was treated with antibiotics with fast recovery and discharge to pneumology and cardiothoracic surgery that planned a blebectomy.

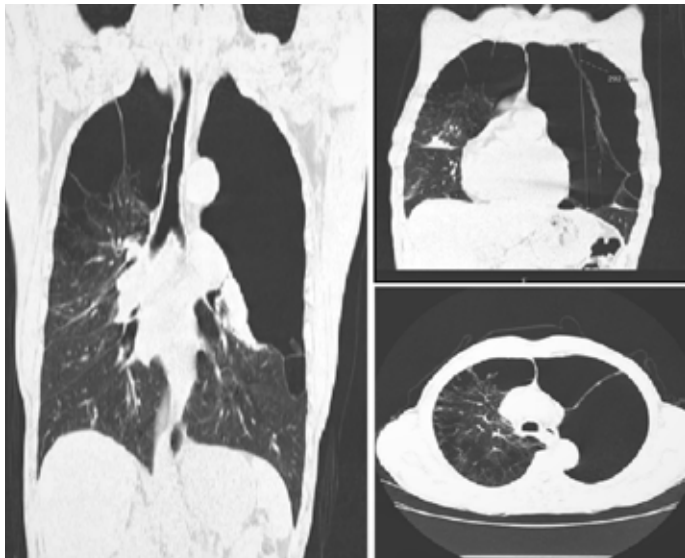


Figure #1239.

#1261 - Case Report

PULMONARY AMYLOIDOSIS - THE GREAT IMITATOR

Rita Ferro, João Olivério Ribeiro, Eurico Oliveira
Centro Hospitalar Tondela-Viseu, Viseu, Portugal

Introduction

Amyloidosis refers to the extracellular deposition of amyloid, a fibrillar, proteinaceous and insoluble material. Depending on the site of amyloid accumulation, it is classified in localised or systemic disease. The primary form of amyloidosis occurs in patients with no evidence of preceding or coexisting disease, while the secondary form is associated with other pathologies and usually occurs with systemic involvement.

Case description

A 65-year-old man with previous history of hypertension and cigarette smoking, presented to the emergency room with weight loss, dysphonia and hemoptysis with 2 months of evolution. During the physical examination, the patient was conscious and oriented, hydrated, eupneic, emaciated, normotensive and afebrile. Without alterations in the cardiac or pulmonary auscultation. Without peripheral edema or palpable adenopathies. Several complementary diagnostic exams were performed. The chest radiography showed several hypotransparent lesions in both lungs and the thoracic computed tomography scan disclosed bilateral lung nodules compatible with metastasis and a mass in the left upper lobe adhering to the hilum and parietal pleura. Blood chemistry, complete blood count, coagulation and haematocrit were normal. The patient was also submitted to a bronchofibroscopy, which did not show relevant alterations and the bronchial aspirate was amicrobial. The computed tomography guided transthoracic lung biopsy revealed necrotic tissue, which was non conclusive for diagnosis. The patient was admitted to thoracic surgery for resection of the left upper lobe nodule and the pathology showed pulmonary amyloidosis. The hypothesis of a possible systemic amyloidosis was further investigated with additional studies, but in the end the diagnosis was not sustained.

Discussion

Pulmonary manifestations of amyloidosis include tracheobronchial infiltrates, persistent pleural effusions and parenchymal nodules called amyloidomas. Pulmonary hypertension is a rare complication. Depending on localization of amyloid deposits, clinical presentation is variable and involves hoarseness, stridor, dysphagia and even airway obstruction.

#1286 - Case Report

SOMETHING MORE THAN PNEUMONIA

Daniela Da Costa Cardoso, Helena Temido, Lèlita Santos, Armando Carvalho

Centro Hospitalar e Universitário de Coimbra, Coimbra, Portugal

Introduction

Bronchiectasis that results from foreign body aspiration generally occurs in the right lung and in the lower lobes or the posterior segments of the upper lobes.

In adults, aspiration is often associated with altered state of consciousness, degenerative or psychiatric diseases. A post-obstructive pneumonia may follow the aspiration, often resulting in incomplete resolution. Delayed or ineffective therapy contribute to the development of bronchiectasis. Curative therapy is generally surgical excision of the affected lobe.

Case description

A 50-year-old man, with a past history of schizophrenia and chronic alcoholism, presented to the emergency department with complaints of dyspnea, productive cough with purulent sputum,

anorexia and asthenia lasting for a week. The complementary study revealed raised inflammatory parameters, severe respiratory insufficiency and a right superior lobar opacity in the chest radiography, compatible with community-acquired pneumonia. Because of an acute clinical worsening with respiratory failure invasive mechanical ventilation was initiated. The inspection of the airways in the bronchoscopy was normal. The culture of the bronchoalveolar lavage isolated *Morganella Morganii* and the bronchial biopsies were normal. After extubation and clinical stabilization, he was transferred to the Internal Medicine ward. Despite a good initial clinical response to antibiotics, the patient's clinical condition was complicated by nosocomial pneumonia by an unidentified germ. The control radiography revealed pneumothorax. Because of persistent air leakage he underwent a thoracic CT scan that confirmed a massive right pneumothorax with partial ipsilateral pulmonary collapse associated with a cavitated consolidation in the right upper lobe. He was submitted to right superior bisegmentectomy, with clinical improvement. The anatomopathological study unveiled obstructive bronchiectasis secondary to a vegetable aspiration.

Discussion

Severe pneumonia with incomplete therapeutic resolution, poor clinical or relapsing evolution along with complications such as an abscess should increase suspicion of a more severe aetiology such as carcinoma or foreign body obstruction.

#1311 - Case Report

HYPERSENSITIVITY PNEUMONITIS – A CASE OF LONG EXPOSURE AND LATE SYMPTOMS AND SIGNS DEVELOPMENT.

Juliana Chen Xu, Dolores Vazquez, Marta Rafael Marques, Susana Marques De Sousa, Angela Coelho, Silvina Miguel, Teresa Pinto CHPVVC, Póvoa De Varzim, Portugal

Introduction

Hypersensitivity pneumonitis (HP) occurs after continuous inhalation of certain antigens. Besides proven exposure to hazardous agent, there might be radiographic changes, although, often it may be normal, therefore, high resolution CT scan is preferred due to its sensitivity in distinguishing fibrotic changes, like ground-glass opacification, centrilobular nodules, septal thickening, traction bronchiectasis, honeycombing and air trapping areas.

There are certain serologic assays for specific IgG antibodies against agents that cause HP. However, these have variable specificity and sensitivity with high false positive and negative rates. Still, positive precipitins with symptomatology, exposure and positive image, indicates the diagnosis.

Case description

61-year-old woman with medical history of hypertension, dyslipidemia, hypertensive cardiomyopathy and hysterectomy.

She works for a cleaning company dealing with chemicals and owns 2 birds of the Psittaciformes order for 10 years.

The patient resorted to the emergency department (ED) due to clinic of 2-months-old cough with dyspnea, little sputum, myalgias and headaches, without fever. She had 2 previous episodes at the ED for the same reason, being discharged with antibiotics without improvement. On examination she was hemodynamically stable, afebrile and with grave crepitations at the base of both lungs on auscultation.

Laboratory analysis showed hypoxemic respiratory failure and on chest x-ray a right para-cardiac hypotransparency. Upon suspicion of chronic pulmonary embolism (D-dimers 1290 ng/dL), CT angiography was performed, showing ground-glass densification in both lungs, with apex-basal gradient and bilateral hilar adenopathies.

Further study showed precipitins anti-pigeon/parakeet/parrot IgG antibodies positive (98.7/167.0/328.0 mg/L, respectively) and bronchoalveolar lavage with intense lymphocytosis (80.4%), 0.2% eosinophils and high CD4/CD8 ratio: 3.73.

With the probable diagnosis of HP, she started deflazacort 45mg and eviction of bird exposure. In the reevaluation, 2 weeks later, she had no need for oxygen (97% saturation on room air) and chest x-ray had significant reduction of parenchymal opacities.

Discussion

Long term exposure to certain antigens, may not exclude HP, and it is seldom underdiagnosed often masqueraded as a recurrent pneumonia. Also, a detailed anamnesis with the documentation of usual environment and specific exposures are necessary for choosing the right tools for our etiological investigation.

#1335 - Medical Image

PNEUMOCOCCAL PNEUMONIA: AN IMAGE IS WORTH A THOUSAND WORDS

Margarida Paixão Ferreira, Joana Lima, Vera Cesário, José Vaz ULSBA - Hospital José Joaquim Fernandes, Beja, Portugal

Clinical summary

A 60-year-old male, with history of smoking habits, refers progressively worsening dyspnea and productive cough with green sputum in the previous 3 days, denying other symptoms. Physical examination revealed fever (T 38°C) and diminished breath sounds in the lower right hemithorax. Laboratory studies showed C reactive protein of 18.2 mg/dL, low platelet count (79,000/uL) and creatinine 3.15 mg/dL. The chest radiograph showed infiltrates in the inferior 2/3 of right hemithorax. Thoracic CT showed consolidation with air bronchogram. Blood cultures and urine antigen were positive to *Streptococcus pneumoniae*, which documents invasive pneumococcal disease. After 7 days of antibiotic therapy, the patient was afebrile and asymptomatic, with normalization of laboratory studies and imagiologic resolution.

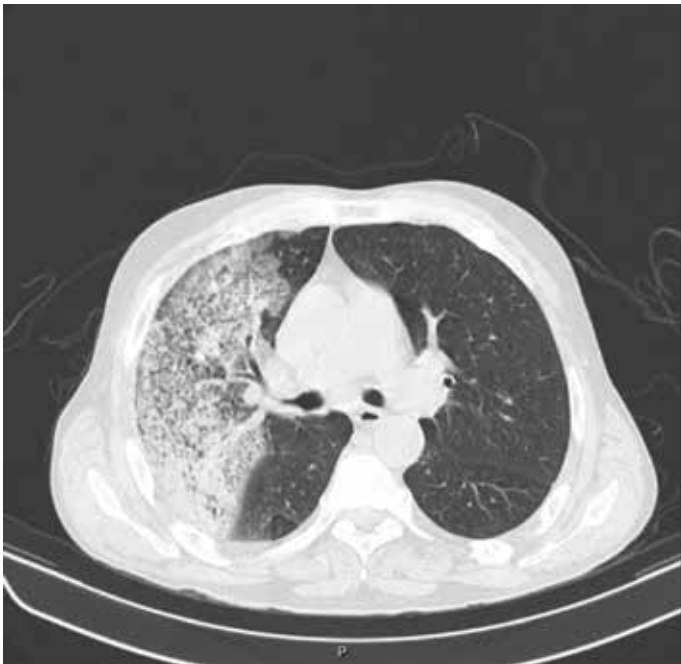

Figure 1335. Thoracic CT with consolidation and air bronchogram.

#1338 - Medical Image

SECONDARY SPONTANEOUS PNEUMOTHORAX - AN UNEXPECTED DIAGNOSIS

Diana Adrião, Ana Rita Barbosa, Marta Barbedo, Vítor Paixão Dias
Centro Hospitalar Vila Nova de Gaia/Espinho, Vila Nova De Gaia, Portugal

Clinical summary

An 86-year-old male patient, former smoker with a history of pulmonary embolism presented to the emergency department with dyspnea. He denied fever, productive cough or chest pain and was not under anticoagulants.

On examination, he was tachypnoeic, SpO₂ 88% on room air, with symmetric chest expansion, normal resonance on chest percussion and bilaterally decreased breath sounds. An arterial blood gas showed hypoxaemia and hypocapnia and D-dimer was elevated.

A CT pulmonary angiogram revealed:

- A filling defect in the bilateral pulmonary arteries, with extension to the superior lobar arteries and segmental branches;
- A large right-sided pneumothorax due to extensive centrilobular emphysema and numerous subpleural bullae.
- A tube thoracostomy was performed with re-expansion of the lung.

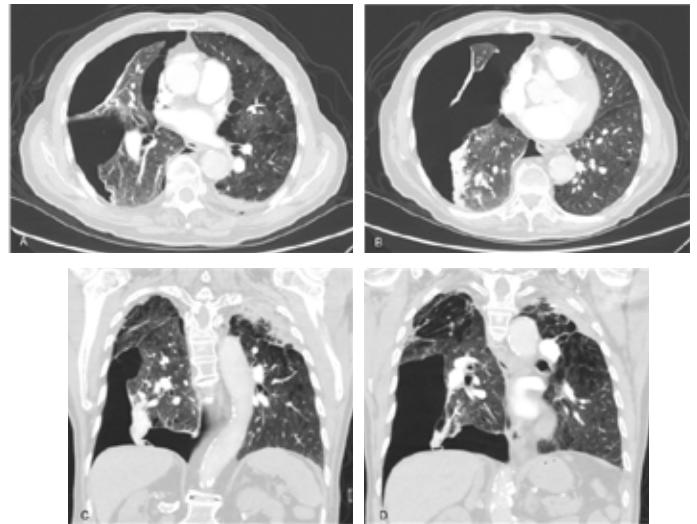


Figure #1338. Large right-sided pneumothorax and numerous subpleural bullae (axial (A, B) and coronal (C, D) CT scan, lung window).

#1345 - Abstract

LOWER RESPIRATORY TRACT INFECTIONS TREATED BY A HOME HOSPITALIZATION AND ECONOMIC ANALYSIS COMPARED TO HOSPITAL ADMISSION

Enrique Mira Bleda, Ana Fernández-Rufete Cerezo, Antonio Mateo López, Alicia Laso Ortiz, Encarnación Moral Escudero, José Ruipérez Ruiz

Virgen de la Arrixaca University Hospital, Murcia, Spain

Background

Carry out a descriptive analysis of admitted patients to the Home Hospitalization (HH) with the diagnosis of lower respiratory tract infections, describe the prevalence of multiresistant bacteria and estimate the economic savings of home treatment compared to hospital admission.

Methods

Retrospective and descriptive research of 43 patients with the diagnosis of lower respiratory tract infections, from september 2018 to april 2019, admitted and treated by the HH of a tertiary hospital in Murcia. To get data we reviewed the clinical histories. Extended spectrum beta-lactamases producers (ESBL) were considered multiresistant bacteria. The average price of one day of hospital admission is €600. The daily cost of HH is approximately 60%, about €360. The SPSS program was used for the statistic analysis.

Results

43 patients were included with the diagnosis of lower respiratory tract infections, 16 women (37.2%) and 27 men (62.8%) with an average age of 63. In terms of prevalence of the main comorbidities, 9.3% of patients suffered dementia, 14% vascular encephalopathy, 60.5% arterial hypertension, 37.2% mellitus diabetes, 32.6% dyslipidemia, 20.9% heart failure, 11.6% renal

insufficiency, 2.3 % cystic fibrosis and 46.5% chronic obstructive pulmonary disease, asthma or both of them. The incidence of ESBL producers multiresistant bacteria was 2.3%. The average length of stay was 8 days. If we consider that the daily cost of HH is €360, the total cost for all patients was €123840. At the hospital admission, the price would have been €206400, because the average price of one day is €600.

Conclusion

HH is a excellent option for treat clinically stable patients with the diagnosis of lower respiratory tract infections at home, to avoid or shorten hospital admission. It's better for patients, because they feel more comfortable at home, and it supposes lower healthcare burden at hospital and an important sanitary saving. In our research, we checked that if we treat patients at home, instead of at hospital, we save €82560, almost half the money.

#1421 - Abstract

ALPHA-1-ANTITRYPSIN DEFICIENCY: GENOTYPES' DIFFERENCES

Margarida Costa E Silva, Inês Ladeira, Teresa Shiang, Raquel Marçoa, Regina Monteiro, Miguel Guimarães, Ricardo Lima
Centro Hospitalar Vila Nova de Gaia/Espinho, Vila Nova De Gaia, Portugal

Background

Alpha-1-antitrypsin deficiency (α 1AT) is the most common hereditary disorder in adults and is often under-diagnosed. Pulmonary, hepatic or cutaneous disorders are the most frequent presentations, namely emphysema.

Methods

Observational retrospective study of patients with alpha-1-antitrypsin deficiency, observed at a Pulmonology clinic of a tertiary hospital, in a time period of 3 years. Demographic, clinical and laboratory data were collected.

Results

The study included 80 patients with an average age of 58 ± 13 years-old and 51,3% of patients were male.

The most frequent genotype was PI*SZ (n=32; 40%), followed by PI*ZZ (n=19; 24,0%) and PI*MZ (n=6; 7,5%). We also identified the following genotypes: PI*M1Z (n=5; 6,3%), PI*M1S (n=3; 3,8%), PI*M2Z (n=3; 3,8%), PI*IS (n=2; 2,5%), PI*SMpa (n=2; 2,5%), and with the same frequency, n=1 (1,3%), the genotypes PI*SS, PI*ZQO, PI*M2Mm, PI*M1Mpa, PI*M1M2, PI*M1Mp, PI*SP and PI*ZMm. PI*ZZ genotype mean age was 54 ± 7 years old while PI*SZ was 62 ± 14 and PI*MZ was 64 ± 8 ; $p=0,042$.

Alpha-1-antitrypsin serum levels were $24,6 \pm 12,2$; $58,1 \pm 11,4$; $69,7 \pm 7,4$; respectively for the genotypes PI*ZZ, PI*SZ and PI*MZ; $p < 0,05$.

COPD was present in 16 patients with PI*ZZ genotype and 13 patients with PI*SZ genotype ($p=0,006$), whilst emphysema was found in 14 and 10 patients respectively ($p=0,011$).

Regarding emphysema characteristics, panlobular emphysema was found in 10 patients with PI*ZZ genotype and in 6 patients with PI*SZ genotype; centrilobular emphysema presented in 3 patients with PI*ZZ genotype and 4 patients with PI*SZ genotype; $p=0,014$.

CO diffusion was $56,0 \pm 26,0$; $77,7 \pm 26,6$; $85,9 \pm 22,9$; respectively for the genotypes PI*ZZ, PI*SZ and PI*MZ; $p=0,029$.

Seven patients (8,8%) were under augmentation therapy with prolactin, all of them with PI*ZZ genotype.

Fifty-six patients were heterozygous (70%).

Only one patient was submitted to lung transplantation (1,3%).

Conclusion

PI*ZZ patients are younger, have lower serum levels of alpha-1-antitrypsin, worst lung function (FEV1 e CO diffusion), higher prevalence of COPD and emphysema (namely panlobular), which proffs its higher severity.

#1425 - Case Report

PLEURAL EFFUSION - THE VARIETY OF POSSIBLE ETIOLOGIES

Ana Rita Gigante, Eduarda Milheiro Tinoco, Filipa De Castro Lima, Teresa Shiang, Carla Nogueira, Eloisa Silva, Carla Ribeiro, Manuela Vanzeller

Centro Hospitalar Vila Nova de Gaia/ Espinho, Vila Nova De Gaia, Portugal

Introduction

In the presence of a pleural effusion and considering the wide range of differential diagnosis, a systemic approach it is essential, including anamnesis, physical examination, complementary exams and the results of pleural fluid.

Case description

A 54-year-old male smoker, former IV drug user on methadone with pleural tuberculosis on the right, diagnosed four months earlier on maintenance treatment (isoniazid/rifabutin). He presented to the emergency department complaining of progressive dyspnea, anorexia and fatigue in the last two months and orthopnea and lower limb edema for two weeks. At admission, he had type I respiratory failure, hypotension, decreased breath sounds in the lower half of both haemithorax, ascites and bilateral pretibial oedema. Laboratory findings included elevated C-reactive protein, lactate dehydrogenase, NT-proBNP and hypoalbuminemia. The chest X-ray showed a moderate effusion on left side as well as the previously diagnosed right pleural effusion. The patient was admitted. Echocardiography findings included severe hypertrophy of the left ventricle, with a discretely mottled texture, suggesting infiltrative heart disease; low-grade proteinuria and urinary immunofixation with lambda light chain monoclonal gammopathy, suspected of amyloidosis AL. After treatment optimization clinical and analytical improvement were achieved, albeit maintaining bilateral effusion. He was discharged awaiting further exams (cardiac MRI, bone marrow and abdominal fat biopsy).

Discussion

We present a patient's case with a right tuberculous pleural effusion, with evidence of good treatment outcome who later developed a new contralateral effusion, the cause of which was shown to be different. Therefore, in the case of a new effusion, it is important to reconsider a differential diagnosis and re-investigate, given the variety of possible etiologies and the possibility effusions have more than one underlying cause.

#1431 - Case Report

NIVOLUMAB INDUCED TOXICITY PRESENTING AS PNEUMONITIS- A CASE REPORT

Couto Couto, Gabriela Santos, Miguel Lopes, José Duarte
Hospital Garcia de Orta, Almada, Portugal

Introduction

Every year new drugs are available for the treatment of lung cancer, with promising results. However all types of medication can have side effects and lung toxicity is no exception.

Case description

We present the case of a 71-year-old male, caucasian, who worked as a construction painter. He had past medical history of a pulmonary nodule admitted as primary lung cancer and treated with stereotaxic radiotherapy in 2016, COPD (GOLD 3C), severe sleep apnea, pulmonary tuberculosis when he was 16-years-old, pulmonary embolism in 2014, ischemic cardiomyopathy, heart failure, arterial hypertension, diabetes mellitus type II, dyslipidemia and benign prostatic hyperplasia. He was an ex-smoker (smoking load - 50 pack years) and was medicated with rivaroxaban, amlodipine, gliclazide, atorvastatin, carvedilol, furosemide, metformin, pantoprazol and ramipril.

In July 2017 he was diagnosed with lung adenocarcinoma stage IIIB by his Pulmonologist (PDL1 e EGFR, BRAF and ROS1 negative). Clinically he presented with cough, mucus expectoration and asthenia. At auscultation diminished vesicular breath sounds were noted.

He was started on 1st line chemotherapy with cisplatin and pemetrexed on november 2017 and completed the 4 cycles of that regimen in January 2018. One year after, on January 2019, progression of disease was noted based on surveillance imagiologic exams and he was started on nivolumab.

After the institution of nivolumab there was a clinical deterioration with new onset of gradually progressive dyspnea and more frequent and dry cough. A thoracic CT was performed that showed many disperse ground glass opacities that were not present in previous exams. Empirical antibiotherapy was prescribed with no improvement, and inflammatory markers were negative. After excluding decompensated heart failure, the diagnosis of lung toxicity by nivolumab was made. This drug was stopped and systemic corticotherapy was initiated with improvement of the symptoms and some regression of the pulmonary ground glass opacities.

Discussion

Immune-mediated pneumonitis is a rare but potentially life-threatening toxicity of nivolumab. In most cases as in the case of our patient pneumonitis is recognised in the first weeks of treatment being dry cough and dyspnea the most common signs of this adverse event. Diagnostic algorithms recommend radiological investigation with a chest computed tomography scan. Management should be conducted according to the clinical symptoms. Corticosteroids are the drugs of choice.

#1487 - Abstract

COMMUNITY-ACQUIRED PNEUMONIA AND THE RESPONSE TO EMPIRIC ANTIBIOTIC THERAPY: THE CASE OF A PORTUGUESE INTERNAL MEDICINE WARD IN 2018

Inês Farinha¹, Alexandra Tenda Cunha¹, Ricardo Ambrósio Rodrigues², André Pinto Saraiva³, Ana Guiomar⁴, Rita Reigota², Diana Gonçalves², João Rocha Gonçalves², João Rua², Bráulio Gomes², João Daniel Melo²

¹ Department of Pulmonology, Coimbra Hospital and University Centre, Coimbra, Portugal

² Department of Internal Medicine, Coimbra Hospital and University Centre, Coimbra, Portugal

³ Department of Rheumatology, Coimbra Hospital and University Centre, Coimbra, Portugal

⁴ Department of Infectious Diseases, Coimbra Hospital and University Centre, Coimbra, Portugal

Background

Community-acquired pneumonia (CAP) is a major cause of hospitalization, morbidity and mortality. Identifying an aetiological agent is a slow process and none is detected in most cases. Empirical antibiotic combination therapy (β -lactam and macrolide) or monotherapy (respiratory fluoroquinolone) is recommended by international guidelines in CAP hospitalized patients admitted to a non-intensive care unit. The goal of this study is to assess the response of CAP hospitalized patients to empiric antibiotic therapy in a Portuguese Internal Medicine ward in 2018.

Methods

Data on demographic information, comorbidities, clinical presentation, microbiologic tests, antibiotics and clinical outcomes were collected. Patients with aspiration, nosocomial, healthcare- or ventilator-associated pneumonia were excluded. Empiric antibiotic treatment was defined as the first regimen administered. Outcomes were analysed at the individual level using SPSS. For descriptive statistics, median, mean and standard deviation (SD) were used. Chi-square test was used to compare patients treated with combination therapy (β -lactam and macrolide) or monotherapy (respiratory fluoroquinolone) and to compare the response to treatment between patients with or without comorbidities. Fisher's exact test was used to assess

the response to antibiotic therapy between patients above or below 65 years old. A value of $P < 0.05$ was considered statistically significant.

Results

A total of 270 patients were included, 54.4% were females. The most common comorbidities were arterial hypertension (76.3%), chronic heart failure (40.4%) and type 2 diabetes (25.9%). The median age was 84 years. Two thirds of patients presented with acute hypoxaemic respiratory failure. The mean CURB-65 score was 2.44 (SD 1.12). Fifty-six percent of patients had no microbiological tests performed. Among 105 patients who performed blood cultures, only 9.5% were positive. Empiric antibiotic combination therapy (β -lactam and macrolide) was used in 74.8% of cases and monotherapy (respiratory fluoroquinolone) in 12.5%. The mean duration of therapy was 7.34 days (SD 2.13) and a favourable response was found in 81.1% of cases. No statistically significant differences were found between the antibiotic regimens ($P=0.320$), in the response to therapy regarding the existence of comorbidities ($P=0.369$) or between the age groups ($P=0.480$).

Conclusion

Empirical antibiotic therapy recommended in international guidelines is effective in most patients hospitalized due to CAP.

#1490 - Case Report

A CURIOUS CASE OF COUGH

Mariana Conceição, Sónia Guerra, Ângela Dias Cunha, Joana Correia, Tito Abrantes, António Reis, António Simões Torres
Centro Hospitalar Tondela-Viseu, Viseu, Portugal

Introduction

Cough is a natural defense mechanism that allows the clearance of bronchial tree secretions and elimination of inhaled foreign particles. When cough is persistent and violent, this could have a significant impact for patients and be quite challenging for physicians.

Case description

An 84-year-old male, former smoker (25 pack-years) with a past medical history of atrial fibrillation under oral anticoagulation therapy with rivaroxaban, presented to the emergency department with an extensive abdominal haematoma and persistent dry cough.

Four weeks before presentation, he suddenly developed a violent cough that was constant throughout the days and progressively worsened. He denied trauma but reported a choking episode with a slice of orange. He also described prodromal symptoms of malaise, nasal congestion and runny nose, which lead to diagnosis of viral upper respiratory tract infection but the symptoms had not relieved with supportive treatment. Three days prior presentation, he developed an extensive abdominal

bruising. Physical examination revealed normal breath sounds and a large ecchymosis across abdominal anterior wall and flanks. Laboratory data revealing a normal blood count and biochemistry. Chest and abdominal CT showed a haematoma in the anterior rectus abdominis muscle with 10x4,5cm, without any other alteration. Bronchofibroscopy without endobronchial changes or microbiological isolates in bronchial aspirate. After further questioning, patient reported that his ten years-old grandson had similar coughing paroxysms and posttussive emesis in the previous month. Serology showed high titer of IgG antibodies against Pertussis Toxin (> 700 UI/mL) as IgA antibodies (152 UI/mL), suggesting a recent contact with *Bordetella pertussis*. He was treated with azithromycin for a five days course in addition to cough suppressants, with a dramatic improvement of symptoms. Abdominal wall haematoma was managed conservatively.

Discussion

Acute respiratory infection caused by *Bordetella pertussis* is traditionally considered a childhood disease, despite recent evidence suggests an incidence increase among adults and old-aged patients. Therefore, diagnosing pertussis require a high level of suspicion. The complications of pertussis can be infectious or mechanical. The authors report an unusual case of abdominal haematoma as a mechanical complication related to the classical whooping cough which is the hallmark of pertussis infection.

#1499 - Medical Image

STAGE II SARCOIDOSIS - A X-RAY IMPOSSIBLE TO FORGET

Gonçalo Durão-Carvalho, Joana Carneiro, Joana Louro
Caldas da Rainha Hospital - West Hospital Centre, Caldas Da Rainha, Portugal

Clinical summary

49-year-old Caucasian woman admitted at emergency room (ER) with 9-days of fever. Past medical history: 6-months bilateral ankle and knees arthralgia treated with prednisolone, stopped 2 weeks before. Physical examination: erythematous papule on the right forearm. Thorax X-ray showed nodule-like opacities on both pulmonary hili. Thorax CT revealed multiple adenopathies within the mediastinum and the hili and many irregular opacities on both pulmonary inferior lobes. Increased C-reactive protein (CRP), erythrocyte sedimentation rate (ESR) and angiotensin converting enzyme (ACE). Negative Mantoux and IGRA. Skin biopsy: multiple epithelioid granulomas, without necrosis, with multinucleated giant cells. No histological signs of lymphoproliferative disorder were found.

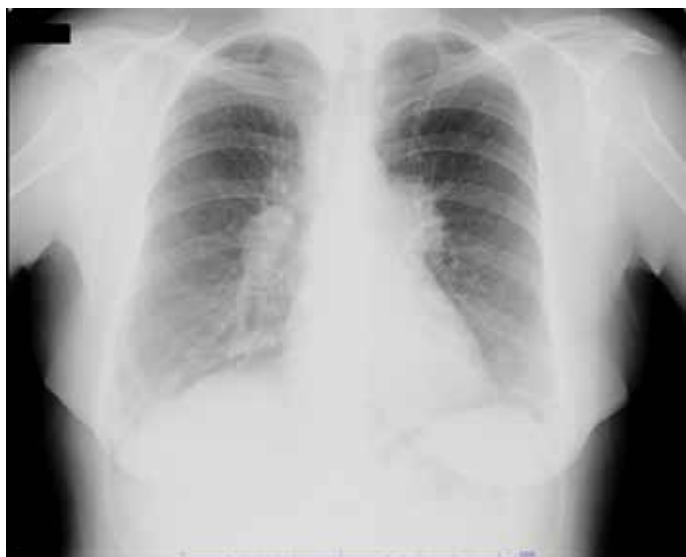

Figure #1499. Thorax X-ray: postero-anterior.

#1508 - Abstract

SARCOIDOSIS... NEVER FORGET IT!

Gonçalo Durão-Carvalho, Joana Carneiro, Joana Louro

Caldas da Rainha Hospital - West Hospital Centre, Caldas Da Rainha, Portugal

Background

Sarcoidosis is a systemic granulomatous disease where > 90% of patients have thoracic involvement with lymph node enlargement or parenchymal lung disease.

Methods

Two cases of patients followed at an Internal Medicine Department

Results

Case 1

49-year-old Caucasian woman admitted at emergency room (ER) with 9-days of fever. Past medical history: 6-months bilateral ankle and knees arthralgia treated with prednisolone, stopped 2 weeks before. Physical examination (PE): erythematous papule on the right forearm. Thorax X-ray showed nodule-like opacities on both pulmonary hili. Thorax CT revealed multiple adenopathies within the mediastinum and the hili and many irregular opacities on both pulmonary inferior lobes. Increased C-reactive protein (CRP), erythrocyte sedimentation rate (ESR) and angiotensin converting enzyme (ACE). Negative Mantoux. Skin biopsy: multiple sarcoid-like granulomas.

Case 2

55-year-old Caucasian woman admitted at ER with 7 days of fever and odynophagia. Self-medicated with paracetamol, ibuprofen and 3 days of amoxicillin/clavulanate without clinical improvement. PE: fever of 38.8°C. Laboratory with neutrophilia and increased CRP. No alterations on thorax X-ray. Assuming a flu-like syndrome, the patient was sent home with antipyretics. She returned 3 days later: fever maintenance (10 days), accompanied

by headache and nausea. Laboratory with more elevated acute inflammatory parameters. Considering a febrile syndrome with unknown etiology, in-patient management was offered with the following additional studies: increased ESR (120 mm) and normal ACE. Body-CT showed increased cervical, axillary, mesenteric and inguinal bilateral adenopathies; mediastinal ganglia and hili lymphatic nodules <1cm; no alterations on lung parenchyma. Biopsy of a cervical adenopathy: presence of epithelioid noncaseating granulomas, with multinucleated giant cells; negative Ziehl-Neelsen stain for *M. tuberculosis*. Negative Mantoux.

Conclusion

Whereas C1 represents a classic presentation of sarcoidosis (developed before 50 years old, with thoracic involvement and increased ACE), that does not happen in C2 (patient over 50-years-old, with no enlarged lymph nodes in the mediastinum or hili nor parenchymal lung disease; normal ACE). Concerning Chest Radiographic Staging, C1 belongs to Stage 2, while C2 to Stage 0. Its relevant to notice that in cases of extrathoracic involvement, radiographic staging does not correlate with the cronologic progression nor with the severity of the disease.

#1538 - Medical Image

MILIARY PATTERN: TB OR NOT TB?

Ângela Dias Cunha, Sónica Guerra, Mariana Conceição, Joana Correia, Ana Campos, António Reis, António Simões Torres
Centro Hospitalar Tondela-Viseu, E.P.E., Viseu, Portugal

Clinical summary

A 70-year-old man, smoker, with chronic kidney disease secondary to diabetes mellitus, arterial hypertension and ischemic cardiomyopathy, presented with a 4-month history of shortness of breath, dry cough and weight loss. Physical examination with normal breath sounds. Chest radiography revealed bilateral and diffuse small lung nodules. Laboratory data with normocytic anaemia, elevation of inflammatory markers and negative serologies (HIV, HBV and HCV). Chest CT showed innumerable nodules throughout the lungs, pleural surfaces and along bronchovascular structures and multiple mediastinal and abdominal adenopathies. Smear microscopy and *Mycobacterium tuberculosis* PCR assay of bronchial lavage were positive. Anti-tuberculosis drugs were started with clinical improvement.

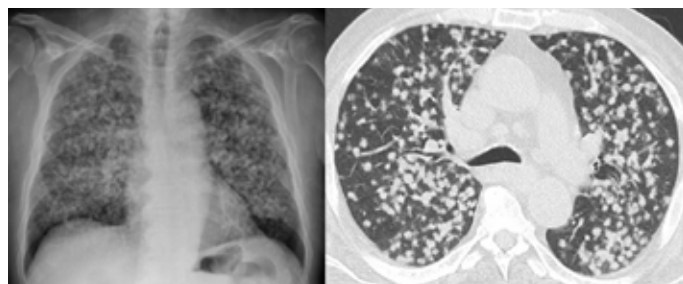


Figure #1538.

#1568 - Case Report

NON CYSTIC FIBROSIS BRONCHIECTASIS AND NON INVASIVE VENTILATION: A CASE REPORT

Sérgio Pina, Teresa Salero, Pedro Cavaleiro, Cristina Granja
Hospital de Faro, Centro Hospitalar Universitário do Algarve, Faro,
Portugal

Introduction

Bronchiectasis unrelated to cystic fibrosis (BUCF) has gained prominence in the past decade due to being more frequent than previously thought, specially in developing countries. It's a disorder characterized pathologically by permanent bronchial dilation and severe bronchial inflammation, clinically by chronic productive cough and recurrent infectious exacerbations and radiologically by abnormal and permanent dilatation of the bronchi. The aetiology is unknown in up to 50% of cases and post-infective in up to 42%. The use of non-invasive ventilation (NIV) during exacerbations is very controversial.

Case description

We present a case of a 44-year-old woman born in Cape Verde with non cystic fibrosis bronchiectasis due to recurrent lung infections during childhood. She was colonized with *Pseudomonas aeruginosa*. She had 5 hospital admissions the year before due to frequent exacerbations. She was well until 2 weeks prior to admission, when she developed malaise, tiredness, shortness of breath, exertional dyspnoea and chest pain. Over the next few days, her symptoms worsened, and her coughing fits increased in severity and became more productive. The morning of admission the dyspnoea acutely worsened and she was brought to the emergency department. On arrival she was conscious, oriented, but unable to complete sentences. Clinical examination revealed a blood pressure of 92/62 mmHg, heart rate of 122 bpm, temperature 38°C, respiratory rate 40 bpm, and oxygen saturation of 70% on her usual 3,5 L/min of oxygen delivered by simple nasal cannula. On auscultation, wheezing and crackles were heard on the lung fields. Blood gases were pH 7,30, pO₂ 60 mmHg and pCO₂ 66 mmHg. She had digital clubbing. She was immediately medicated with levofloxacin and inhaled colistine and started high flow oxygen cannula. She was transferred to the Intensive Care Unit and started NIV through face mask. This treatment led to a dramatic improvement in the patient's clinical condition. Five days after admission she was back to her prior health condition.

Discussion

The management of BUCF during exacerbations is still problematic. There aren't enough studies to help understanding how and when to implement NIV in these patients, however it seems to be beneficial with clinical and functional improvement and preventing the need of more invasive ventilation alternatives.

#1586 - Medical Image

NECROTIZING PNEUMONIA AS A RARE COMPLICATION OF BACTERIAL COMMUNITY ACQUIRED PNEUMONIA

Beatriz Brazão Câmara, Margarida Cabral, Flávia Santos
Hospital de Santo André, Leiria, Portugal

Clinical summary

The authors report the case of a 74-year-old female with no relevant personal history, that presented in the Emergency Department with a one-month history of shortness of breath, productive cough, anorexia and weight loss. Chest X-Ray revealed right lung consolidation with positive *S. pneumoniae* urinary antigen and she was started empirically on ceftriaxone and clarithromycin. During hospital admission she had increased dyspnea and became progressively more hypotensive and hypoxemic. High-resolution CT scan of the thorax was performed, which revealed right pulmonary consolidation associated with loculated effusion and extensive bilateral multiple cavities. She received continued medical management, with escalation of antibiotics for cavitating pneumonia, with gradual clinical improvement.

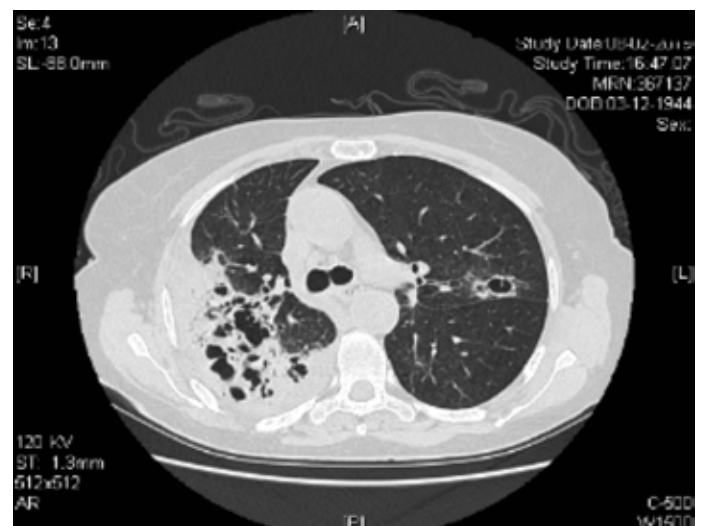


Figure #1586. High-resolution CT scan of the lungs – right pulmonary consolidation associated with ipsilateral pulmonary atelectasis and loculated pleural effusion and bilateral traction bronchiectasis with multiple cavities.

#1611 - Case Report

ADENOCARCINOMA OF THE LUNG MIMICKING PNEUMONIA

Ana Maria Gonçalves, Carlos Ramalheira, Sara Irina Almeida, Rita Dutschmann, João Machado
Hospital Professor Doutor Fernando Fonseca, Lisbon, Portugal

Introduction

Nonresolving pneumonia, includes cases of presumed pneumonia that resolve slowly, or fail to achieve complete resolution despite appropriate therapy. Almost 20% of the presumed

non resolving pneumonias are due to non-infectious causes. Neoplasms may be associated with nonresolving pneumonia by mimicking an infiltrative process. Bronchioloalveolar carcinoma (adenocarcinoma in situ) and lymphoma are the most common causes.

Case description

A 60-year-old man with a previous medical history of aortic stenosis, diabetes, and cigarette smoking (135 pack-year) presented in the emergency room with dyspnea and fatigue for two weeks. On physical examination, he had a reduced vesicular murmur in the right lobe, with inspiratory crackles. Blood tests showed $11,400 \times 10^9/L$ leucocytes and C-reactive protein: 5.21mg/dL. Arterial blood gas revealed pO₂: 69mmHg breathing room air. Chest radiography showed infiltrates in the right lobe with air bronchogram. A presumptive diagnosis of pneumonia was made, and he started an antibiotic course. Cultures were negative. During the next 10 days of antibiotic, there was no clinic improvement. CT scan of the chest showed infiltrates in the upper, middle and lower right lobes, with ground-glass opacities and multiple mediastinal adenopathies. Bronchoscopy was normal. Transbronchial biopsies of lung parenchyma, identified few isolated cells compatible with adenocarcinoma. PET-CT showed extend neoplastic infiltration of the right lung and left axillar adenopathy. On the following days, the patient presented a marked decline in clinical status and died.

Discussion

Our patient transbronchial biopsy revealed few adenocarcinoma cells and for this reason, it was impossible to determine a histological subtype of adenocarcinoma. However, considering the patient clinical and radiological presentation, we can presume that it could correspond to a bronchioloalveolar carcinoma. Frequently patients with bronchioloalveolar carcinoma have a discrepancy between the size of the infiltrate on the chest radiography and the pauci symptoms. The chest radiography often shows an irregular infiltrate, with air bronchogram, indistinguishable from pneumonia. Our patient presented only with dyspnea and fatigue, opposing with an exuberant infiltrate in the right lower lobe with air bronchogram. Blood and sputum cultures were negative, and the initial antibiotic course failed. Bronchoscopy was normal, since the architecture of the lung is not altered, so biopsy should always be considered.

#1622 - Abstract

HIGH-FLOW NASAL CANNULA OXYGEN THERAPY - PUTTING THE ROX INDEX TO TEST

Manuel Martins Barbosa¹, Tiago Mendes¹, Gabriel Atanásio², Janine Azevedo Resende², João Valente²

¹ Unidade Local de Saúde do Alto Minho, Viana Do Castelo - Ponte De Lima, Portugal

² Centro Hospitalar Vila Nova de Gaia, Vila Nova De Gaia, Portugal

Background

Therapy with high-flow nasal cannula (HFNC) oxygen is now being widely used in situations of hypoxic respiratory failure as an alternative to both non-invasive ventilation and intubation. One of the main disadvantages is that it increases the risk of misidentifying critically ill patients and delaying the decision of intubating. The ROX index calculation uses peripheral O₂ saturation, fiO₂ and respiratory rate and is a proposed tool to overcome this limitation.

Methods

We performed a single center, retrospective, observational analysis of all patients that underwent HFNC oxygen therapy, in an intermediate care ward, for respiratory failure and calculated their ROX index at 2h and 12h. Our objective was to see if we could replicate the results from previous studies that showed that obtaining ROX values equal or higher than 4,88 are precise enough to predict the success of HFNC oxygen therapy.

Results

A total of 31 patients submitted to HFNC were studied, 14 female and 17 male. The median age is 70.5 years. Out of the 31 patients evaluated, when HFNC was suspended 16 were better, 3 were submitted to non-invasive ventilation (NIV), 5 to orotracheal intubation (OTI) and 7 died. At day 30 of follow up, 16 were discharged, 1 was in medicine ward, 1 was in the Intensive Care Unit (ICU) and 6 more died.

Rox index after 2 hours of therapy was <4.88 in 6 patients. At 12h, 3 of those had ≥ 4.88 . The other 23 patients had a Rox score ≥ 4.88 since 2h, 22 of them maintaining the score at 12h. There is statistically significant difference between Rox at 2h and at 12h ($p=0.046$). Although they are different there is at least some degree of correlation between them (Spearman's correlation coefficient of 0.59).

The 4.88 cut-off value for the Rox index at 12h has statistical significant correlation with the outcome immediately after high flow therapy ($p=0.001$) and after 30 days ($p=0.014$), while at 2h only has a statistical significant correlation with the outcome immediately after therapy ($p=0.002$) but not at 30 days (0.09).

Conclusion

We can conclude that there is significant correlation on obtaining a ROX index score $\geq 4,88$ and the success of HFNC oxygen-therapy. We also conclude that this index is more reliable at 12h hours of therapy, comparing to 2 hours after therapy, especially when evaluating outcome at day 30.

As this results are consistent with larger studies, they provide clinical confidence in using the ROX index to predict HFNC therapy likelihood of success (accessed by avoiding NIV or OTI).

#1635 - Abstract

APPROACHES TO CHRONIC OBSTRUCTIVE PULMONARY DISEASE (COPD) IN A REGIONAL HOSPITAL

Monika Dvorakova, Leonor Gama, Tiago Fiúza, Teresa Bernardo, Lucas Ruiz, José António Santana Sousa Costa
ULSLA, Santiago Do Cacém, Portugal

Background

COPD belongs to one of the most common and serious chronic respiratory diseases that may seriously affect the quality of a patient's life. It is the fourth leading cause of death worldwide. Even though COPD is mainly a chronic disease, a substantial number of patients suffer from acute exacerbations, which are related to a significantly worse survival outcome. This study aimed to investigate the inpatients with exacerbation of COPD. The data analysed came from a regional hospital which provides service for around 100.000 locals.

Methods

Retrospective study of a population admitted for exacerbation of COPD in the Department of Internal Medicine from 1/1/2018-31/12/2018.

Results

The total amount of patients in the study was 49. Out of the tested group, the majority were men (39) and 10 were women. The average age of the male patients was 78 years, whereas the average age of the females was 74 years. 82% of the men and 30% of the women were smokers. Only 28.57% of all the patients were non-smokers. 36.76% were long-term users of oxygen therapy. The average length of hospitalization was slightly less than 2 weeks (13.8 days). The highest incidence of exacerbations was recorded in the winter (48.68%), followed by the summer season (25.44%), spring (23.73%) and the lowest occurrence was in autumn (10.17%). The main detected factor provoking the exacerbation was a respiratory infection (96.61%), in most of the cases tracheobronchitis and pneumonia. The hospital mortality rate was 3.39%. 10 patients had to be re-admitted within the same year. From all the 59 hospitalizations, 39% had already been followed by a pneumologist. After discharge, the majority of the cases were followed-up with a Pneumology consultation (44%). 22% with a consultation at a General Practitioner and 20.34% with an Internal Medicine consultation. 5% of the cases were redirected to the convalescent unit, only 1.7% were accompanied by palliative care specialists and 3.39% of the cases were not followed-up. The mortality rate after discharge until the end of 2018 was 24.5%.

Conclusion

This study confirmed what has been researched in studies worldwide. A much higher incidence of exacerbations of COPD may be observed in men of an advanced age who are smokers. This research highlighted a higher risk of exacerbations with a need for hospitalization in winter due to the then frequent respiratory infections.

#1682 - Case Report

IDIOPATHIC ACUTE EOSINOPHILIC PNEUMONIA: A CASE REPORT

Maria Silva, Christine Costa, Salvato Feijó
Centro Hospitalar de Leiria, Leiria, Portugal

Introduction

Idiopathic acute eosinophilic pneumonia (PEAI) represents a rare eosinophilic pulmonary disorder of unknown etiology. The diagnosis requires a high degree of suspicion and is based on a compatible clinical-radiological pattern associated with the demonstration of alveolar and / or blood eosinophilia.

Case description

We report a case of a 27 year old man, non smoker, who worked in a knives factory. Had no prior pathological history or chronic medication.

Applied to the Emergency Room for cough, fever and night sweats. Was already medicated with amoxicillin and ciprofloxacin without clinical improvement.

Additional study only showed hypereosinophilia 4700 μ l and hypoxemia. Chest radiography presented hypopermeability and heterogeneity of the left field, peri-hilar retraction and Chest Computed Tomography showed "changes in the pulmonary interstitium, peripherally, at vertices and mid-stages of left lung (...) interlobar thickening and bronchogram (...) areas of "crazy paving".

Fiberoptic bronchoscopy was performed and Bronchoalveolar lavage fluid and Bronchial Biopsy revealed a large number of eosinophils. Other causes of hypereosinophilia was excluded such as infectious diseases, neoplasms, clonal eosinophilia, allergic disorders, or vasculitides and the diagnosis of PEA was made. The patient started iv methylprednisolone at high doses and a clinical, analytical and radiological improvement was seen after 24 hours. The patient was seen in consultation after one and 4 months, he denied any symptomatology and analytical study and chest radiography were normal.

Discussion

The diagnosis of eosinophilic lung diseases relies mainly on clinical-imaging pattern and a prompt response to corticosteroids helps to confirm the diagnosis. Must be considered once all the other causes of eosinophilia are excluded.

#1725 - Abstract

CLINICAL IMPACT OF 19 BP DEL DHFR POLYMORPHISM IN BRONCHIAL ASTHMA

Margarida Cortez E Castro^{1,2}, Joana Ferreira^{3,4}, David Sarmento^{3,4}, Carla Carvalho^{3,4}, Andreia Matos^{3,4}, Manuel Bicho^{3,4}

¹ CHLN_HSM, ImmunoAllergy, Lisbon, Portugal, Lisbon, Portugal

² Genetics Laboratory, ISAMB, Lisbon Medical School, Portugal, Lisbon, Portugal

³ Genetics Laboratory, ISAMB, Lisbon Medical School, Portugal,; Lisbon, Portugal

⁴ Institute of Scientific Research Bento Rocha Cabral, Lisbon, Portugal, Lisbon, Portugal

Background

The bioavailability of NO and endothelial homeostasis depends on the cofactor BH4(tetrahydrobiopterin) that plays a key role in NO synthesis by endothelial nitric oxide synthase (eNOS). The functional polymorphism of 19-bp deletion within intron-1 of DHFR (rs70991108) could interfere in the regeneration of BH4 from BH2 (7,8-dihydrobiopterin) and contributes to endothelial dysfunction in asthma

Methods

Asthmatics (n=123) compared with control group (n=50).The polymorphism was analyzed by PCR. Control of asthma assessed by (ACQ7 and PAQLQ). Statistical analysis with SPSS23.0 establishing a significance level of $p < 0.05$.

Results

80 women and 43 males in the asthmatics and 39 women and 11 males in the controls ($p=0.137$). In asthmatics age: (mean \pm SD: 38.26 ± 19.24); in the control group age: (mean \pm SD: 51.50 ± 13.34). The genotype frequencies in asthmatics are: DD (6.5%); ID (66.7%); II (26.8%); in control group: DD (12.0%); ID (64.0%); II(24.0%); ($p=0.478$). The allelic frequencies in asthmatics are: allele D (39.8%); allele I (60.2%); in control group: allele D (44%); allele I (56%); ($p=0.476$). The genotype frequencies in uncontrolled asthmatics : DD (0.0%); ID (61.1%); II (38.9%); and in the controlled asthmatics are: DD (9.4%); ID (68.2%); II (22.4 %); ($p=0.047$). Genotypes ID and II are more frequent in the uncontrolled asthmatics. There is a trend to have differences in allelic frequencies in the uncontrolled asthmatics ($p=0.059$) being the Allele I more frequent among uncontrolled asthmatics. The uncontrolled asthmatics are older than the controlled asthmatics ($p < 0.001$). The genotype II confers a risk of being uncontrolled asthmatic of 2.950 times when compared with controlled asthmatics and adjusted for age: ORb: 2.950 [1.117-7.789]; $p=0.029$.

Conclusion

Uncontrolled asthmatic patients are more frequent among those that express allele I. Homozygous II confers a risk of 3 times of being uncontrolled asthmatic when adjusted for age.

#1727 - Case Report

WHEN PNEUMONIA DOES NOT IMPROVE

Mário Pinto, João Rodrigues, Carlos Figueiredo, Mariana Cabral, Inês Moreira, Rita Gerardo, João Cardoso
Hospital of Santa Marta, Lisbon, Portugal

Introduction

Pneumonia is characterized by inflammation of the alveoli, usually caused by infection with bacteria or viruses. Globally, it causes four million deaths per year. Lung cancer is the most common cause of cancer-related death in men, and the second most common in women. The association between these two conditions is well established: lung tumors increase risk of pneumonia, which often masks the underlying malignancy causing misdiagnosis, and the incidence of pulmonary carcinoma is higher among patients hospitalized for pneumonia.

Case description

The authors present the case of a 73-year-old male smoker of 60 pack-years, with previous known history of chronic obstructive pulmonary disease, who presented to the Emergency Department (ED) with productive cough, mucous sputum, and dyspnea. Chest radiograph showed an opacity in the right lower lung field. Diagnosis of community-acquired pneumonia was assumed, and he was treated with ceftriaxone and azithromycin. Two weeks after discharge, he returned to the ED with recurrent complaints and persistent anomalies in the chest radiograph, with a heterogeneous micronodular pattern in the right lower lung field and right hilar opacity. Assuming recurrent pneumonia, he was started on levofloxacin, without significant clinical improvement. A chest CT scan was then performed, and findings suggested a tumor of the right hilum, 45 mm in diameter, with invasion of the right pulmonary artery, and lymphangitis carcinomatosa of the right lower lobe. It also showed lymph node involvement in the mediastinum. Bronchofibroscopy with bronchial biopsy was performed, and pathology was compatible with pulmonary adenocarcinoma. For further staging, he underwent a full-body CT scan, with no evidence of distant metastasis.

For definitive staging with PET-CT, as well as mutation study and remaining therapy, the patient was referred to Pulmonary Oncology clinic.

Discussion

Lymphangitis carcinomatosa, or inflammation of the lymphatic vessels caused by malignancy, is generally due to invasion by tumor cells. However, it can also be secondary to obstruction of lymph drainage by a mass, such as a tumor of the pulmonary hilum. In the chest radiograph, it can mimic an infiltrate of infectious origin. In a patient with pneumonia who doesn't improve or shows persistent roentgenographic findings after appropriate antibiotic therapy, the diagnosis of lung cancer must be considered, especially if risk factors such as a smoking history are present.

#1768 - Abstract

SARCOIDOSIS: CHALLENGES FOR THE INTERNIST

Veronica Torres, Erick Cardozo, Pilar Portas, Mariela Casal
University of Uruguay, Montevideo, Uruguay

Background

Sarcoidosis is a systemic granulomatous disease with great diversity in its clinical presentation. It mainly affects lung and hylomediastinal adenopathies but can compromise any organ. Despite the development of new diagnostic methods, extrathoracic commitment represent a diagnostic and therapeutic challenge for the internist. It is recommended to rule out Variable Common Immunodeficiency (CVID) in patients with a diagnosis of sarcoidosis since there is a form of granulomatous interstitial pulmonary involvement (GILD) similar to sarcoidosis associated with IDCV. Objective: describe clinical presentation, diagnostic method, treatment and evolution of a series of cases of sarcoidosis and evaluate the possibility of common variable immunodeficiency in patients diagnosed with sarcoidosis.

Methods

Descriptive, retrospective, case series report. Adults with sarcoidosis attended 2012-2018 period. Variables: age, sex, pulmonary, extrapulmonary involvement, radiological stage, thorax CT, diagnostic method, pulmonary function, treatment, evolution, electrophoretic proteinogram.

Results

20 patients studied, 63% female, 48 average age, 4 years follow-up average. Clinic: Pulmonary 20% Extrapulmonary: hylomediastinal adenopathies 55%, extrathoracic adenopathies 35%, fever 4, erythemanodosum 4, skin 2, cardiac 2, renal 2, uveitis 1, arthritis 1, bone marrow 1 Radiological classification at diagnosis: stage I in 4 patients, III in 4, IV none, stage II the most frequent 55%. CT: 75% nodules, hylomediastinal adenopathies 50%, consolidations and subpleural nodules 30%, interstitial involvement 25%, peribronchovascular thickening 15%. Diagnostic method: transbronchial biopsy 2, lung biopsy 1, mediastinoscopy and lymph node biopsy 6, extrathoracic lymph node biopsy 4, skin biopsy 3, myocardial biopsy 1, bone marrow biopsy 1. Spirometry 84% normal, DLCO 79% normal and diminished 15%. Treatment with corticosteroids 85% and 2 cardiosarcoidosis also methotrexate 1, azathioprine 1. Radiology two years after debut: stage 0 7/14 (50%). Clinical and respiratory function stable. Complications cardiosarcoidosis 2, medullar 1. Normal PEF 12/13 and hypergammaglobulinemia 1/13.

Conclusion

The majority of cases presented extrapulmonary manifestations, pulmonary and mediastinal chest involvement, little ventilatory-respiratory repercussion, corticoid treatment and favorable respiratory evolution. They emphasize the cardiac commitment that in general is rare and the medullary that is exceptional. No IDCV was found.

#1802 - Case Report

COULD PLEURAL EFFUSION BE A DIAGNOSTIC CHALLENGE?

Agata Knurowska, Oliwia Kozak, Joanna Pienkowska, Zaneta Smolenska, Michal Studniarek
Medical University of Gdansk, Gdansk, Poland

Introduction

Pleural effusion and thickening of the pleura can cause a diagnostic dilemma because of its possible various etiogenesis. Malignant effusion related to mesothelioma is a major concern, although other rare conditions should be taken into consideration.

Case description

69 year old male, presented with dyspnea and cachexia. 7 years earlier he was diagnosed with pleural effusion and lung fibrosis. The patient was referred to computed tomography with suspicion of mesothelioma. The study showed bilateral pleural effusion and pleural thickening. The incidental finding was bilateral perirenal fat stranding. The retroperitoneal fibrosis process was suggested. A video-assisted thoracoscopic lung biopsy was performed. The histopathological examination did not reveal the presence of neoplastic cells, thus the chronic inflammation with foamy macrophages and minor calcifications were detected. Serum level of IgG4 was elevated to 583 mg/dl. Treatment with methylprednisolone was provided with excellent clinical improvement.

Discussion

Pleural effusion can be caused by a variety of conditions, benign and malignant. The radiological assessment of pleural effusion should be complex, the diagnostic process requires careful interpretation of obtained images and patient's clinical appearance. In presented case, the coexisting perirenal fat stranding was crucial for radiological diagnosis. Retroperitoneal fibrosis, including Erdheim Chester disease and IgG4-related diseases, show a wide range of symptoms involving multiple organs. Very often they can mimic malignant process.

#1813 - Medical Image

A MOON IN THE CHEST

Rebeca Martins Natal, Gonçalo Samouco, Hugo Almeida, Joana Ribeiro, Sara Braga, José Manuel Silva
Local Health Unit of Guarda, Guarda, Portugal

Clinical summary

A 22-years-old female, natural from São Tomé island, with previous medical history of an umbilical hernia, surgically corrected a few years ago, was admitted in the emergency room with dispnea, described as "sensation of incomplete expiration". Physical examination was innocent besides pulmonary auscultation with decreased murmur in the left base with no abnormal breath sounds. Complementary exams revealed no relevant findings in laboratory

results, EKG was normal, but postero-anterior chest x-ray revealed a rounded image well delimited with homogeneous hypotransparency in the left base, and left lateral chest x-ray the same rounded image but with the hypotransparency resembling last quarter moon. Computed tomography clarifies that was a diaphragmatic hernia with the spleen in the thorax.

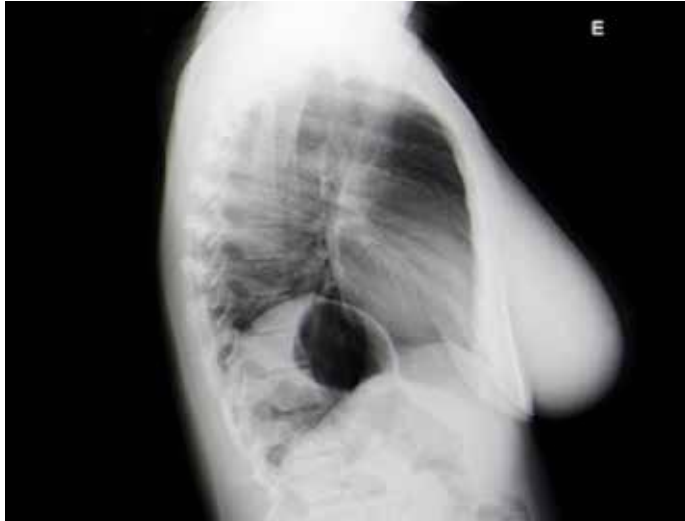

Figure #1813.

#1822 - Abstract

OBSTRUCTIVE SLEEP APNEA SYNDROME AND OXIDATIVE STRESS BEFORE AND AFTER TREATMENT WITH CPAP THERAPY: A ROLE IN CARDIOVASCULAR PREVENTION?

Serena Melandri

I Clinica Medica, Department of Internal Medicine and Prevention of Atherosclerosis, Policlinico Umberto I, Sapienza University, Rome, Italy

Background

Obstructive sleep apnea (OSA), a highly prevalent sleep disorder characterized by repeated disruptions of breathing during sleep, arouses a great interest today due to its systemic burden and to the growing evidence of a link between Intermittent Hypoxia (IH), sleep fragmentation and increased insulin-resistance, sympathetic outflow and hyperlipidemia. OSA induces inflammation and oxidative stress (OS): this could explain the higher risk of hypertension, CAD, stroke, arrhythmias and LV dysfunction and the increased overall and cardiovascular mortality in OSA patients. It still remains unknown whether CPAP can modify this inflammatory state. Our aim was to verify if constant therapy with CPAP (at least 240 min/night) might improve OS and IH.

Methods

We enrolled 13 patients (9 M, 4 F; mean age 58) affected by simple obesity (mean BMI: 35.3) and severe OSAS, diagnosed through polysomnography.

(Apnea/Hypopnea Index >30 steps/hour with or without Epworth scale > 14). Arterial blood gas analysis and spirometry were

analyzed too, to exclude any primitive or secondary lung disease. We therefore measured, at baseline and after 90 days of ventilator therapy: 8-iso-PGF₂ alpha, 8-isoprostane, which is a reliable marker of lipid peroxidation, Interleukin-6 and NOX2-derived peptide (sNOX2-dp), an index of NADPH oxidase activation. NOX2 is an isoform of Gp91 phox, the catalytic subunit of NADPH ox, a free-radical productive enzyme. Flow-mediated brachial artery dilatation (FMD) was also measured to assess endothelial function and reactivity to NO.

All patients were assessed monthly for treatment adherence and side effects.

Results

The mean AHI and Oxygen Desaturation Index prior to CPAP were respectively 43.3±11.9/h and 35.8±22.3/h, which decreased to 7±5/h and 2.8±1.6/h (p<0.001). The mean BMI was 35,3±5,5 kg/m² and it didn't change during therapy. Gp91phox decreased from 38.2±7.4 to 23.6±5.1 (p<0.001). FMD was not statistically significant. At the same time, all markers such as urinary 8-isoprostanes and NOX2-derived peptide levels in serum were decreased significantly after 3 months of CPAP treatment (p < 0.01 and p<0.005 respectively).

Conclusion

CPAP has a relevant impact on levels of sNOX2-dp, which correlates with severity of OSA, ROS production and endothelial dysfunction. Results suggest that CPAP decreases both inflammation and OS. These findings may be relevant for a better understanding of the pathogenesis of CV disease in OSA and for validation of CPAP as a fundamental part of the therapy

#1882 - Medical Image

AN (ALMOST) INNOCENT CHEST X-RAY

André Santos Pinto, Manuel Serrano Martins, Grace Staring, Wildemar Costa, Ivone Barracha, Rosa Amorim

Centro Hospitalar do Oeste - Hospital de Torres Vedras, Torres Vedras, Portugal

Clinical summary

These images are from a case of a 32-year-old male, admitted in the ER complaining of fever and lower back pain. Had already done two cycles of antibiotic therapy without no resolution. Irrelevant personal history, no smoking habits and an innocent physical examination. A postero-anterior chest X-ray was performed, that seemed innocent, but lateral incidence proved that there was a large retro-cardiac mass. The chest CT scan confirmed the presence of a heterogeneous mass in the left inferior lobe and the bronchofibroscopy identified a protrusion of the posterior internal wall in the left bronchial branch. Histological biopsies revealed the presence of an adenocarcinoma. Thus, the diagnosis of lung adenocarcinoma was confirmed in a patient who initially had an (almost) innocent X-ray.

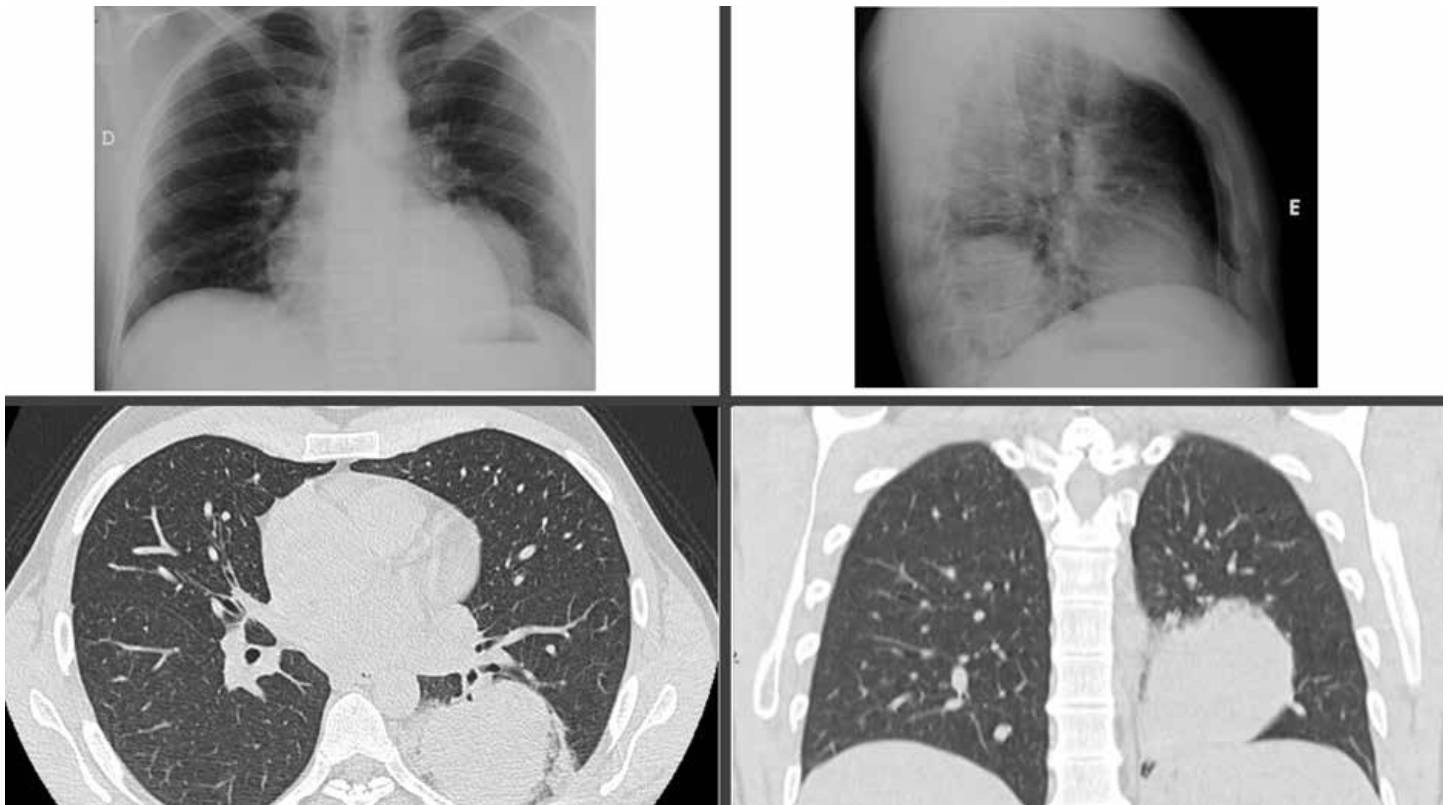


Figure #1882. An (almost) innocent chest X-ray.

#1892 - Case Report

HYDROPNEUMOTHORAX DUE TO PNEUMONIA

Sérgio Antunes Da Silva, Catarina Jorge, Margarida Viana, Domingos Sousa, Elena Rios, Ana Isabel Rodrigues, Diana Reis, Sara Aleixo, Rita Fernandes, Mário Lázaro

CHUA - Hospital de Faro, Faro, Portugal

Introduction

Pneumonia is one of the most common infectious diseases and an important cause of mortality and morbidity. Despite the advances made in the diagnosis and early treatment, complications may occur and must be treated accordingly

Case description

Male, 73 years old with past medical history of asthma, emphysema and deep vein thrombosis (DVT), went to the Emergency Ward (EW) with aggravation of breathlessness and productive cough. On admission was hypertensive with orthopnea and type 1 respiratory failure. On patient's auscultation there were no breath sounds on the right lung and oedema of the right leg (present for the past 4 weeks). The blood tests showed elevation of the inflammatory parameters (leukocytosis 35500 mm^3 and C reactive protein 316 mg/L). The chest x-ray showed right middle lobe consolidation suggestive of lobar pneumonia because of these findings the patient started empiric antimicrobial therapy. On the electrocardiogram was detected a new episode of atrial fibrillation so the patient initiated anticoagulation.

On day 5 of antibiotics the patient showed little improvement and was still dependent on oxygen supplementation. After a review of previous admissions to EW it was found that 3 weeks before the patient had a blood test with d-dimers $>25000 \text{ } \mu\text{g/L}$ but a lower limb eco-Doppler not suggestive of acute DVT. Due to the evolution during hospital stay a pulmonary CT angiogram was performed and showed bilateral pulmonary embolism with also a right-side hydropneumothorax (effusion of 60 mm thickness anterior-posterior) with septations of the pleural cavity accompanied by a small shift of the mediastinum to the left.

A chest tube was inserted with immediate drainage of 600mL of serofibrinous fluid (1200 mL/24h), its analysis results are of an exudate - leukocytes 33295 cel/mm^3 , pH 7,1, lactate dehydrogenase >1995 - and negative microbial culture.

The hydropneumothorax was assumed to be a complication of a necrotizing pneumonia and antibiotic switch was done.

Discussion

This case report reflects the importance of a systematic review of past EW visits and the day-to-day assessment of the patient's evolution during his stay in the hospital, since complications can be a part of the process of pathological states

#1906 - Case Report

DIFFERENTIAL DIAGNOSIS OF MALIGNANT PLEURAL EFFUSION

André Faria Esteves, Alexandra Briosas, Francisco D'Orey, Francisca Delerue, Ana Luisa Broa
Hospital Garcia de Orta, Lisboa, Portugal

Introduction

The most common primary tumors causing malignant pleural effusions (MPE) are lung and breast cancer. Other types of tumors can also present with MPE but they are usually associated with advanced metastatic disease.

Case description

A 60-year-old male, with a past medical history of smoking (approximately 60 pack/year) and hypertension, attended the Emergency Department due to a 5-month history of worsening dyspnea and tiredness and weight loss. Physical examination revealed hypertension, fever, dyspnea, bilateral absent breath sounds on the lower 2/3 and abdominal nodularity on the upper quadrants, with no signs of ascites or enlarged lymph nodes. The blood tests revealed raised alkaline phosphatase and C reactive protein, leukocytosis, normal red blood count and normal NTpro-BNP levels. Chest X-ray showed a left sided pleural effusion (PE). This finding led to a full-body CT scan, which showed a bilateral PE with adjacent pulmonary atelectasis, ascites, nodular lesions suggestive of peritoneal carcinomatosis and probable secondary osteolytic lesions, with pathologic rib fractures. The patient underwent thoracentesis (exudate, sterile, normal ADA) with pleural biopsy (histologic examination inconclusive) and immunophenotypic examination of the pleural fluid, which was highly suggestive of a metastatic carcinoma. Based on the past medical history and clinical presentation, the first hypothesis was lung cancer therefore he had a repeat chest CT which showed, besides the previously mentioned findings, diffuse gastric thickening. An upper endoscopy was then performed, revealing a 40 mm gastric ulcer histologically characterized as an adenocarcinoma (ADC), with intestinal-type component and signet ring cells (HER2 negative). For staging, the thoracentesis was repeated (now with positive cytology for gastric ADC) and a bone scintigraphy, head CT and PET scan were performed. Hereby, the patient was diagnosed with stage IV gastric ADC with peritoneal carcinomatosis and diffuse bone, pleural and lung metastases. He was started on palliative chemotherapy but died after the first cycle.

Discussion

This clinical case depicts an unexpected diagnosis of gastric cancer that came to light during the etiologic investigation of an MPE, alerting us for the need of a thorough and organized diagnostic approach. Moreover, this clinical case stands out for the uncommon presentation of an advanced metastized gastric tumor with a respiratory symptom (dyspnea), due to a PE.

#1909 - Case Report

A RARE AND NONINFECTIOUS PNEUMONIA IN YOUNG ADULTS

Rita Bizarro, Carolina Coelho, Angela Ghilechi, Rita Lencastre Monteiro, Joana Diogo, César Vieira, Cátia Carvalho, Ana Gonçalves, Conceição Loureiro

Centro Hospitalar e Universitário de Lisboa Central, Hospital de Santo António dos Capuchos, Lisboa, Portugal

Introduction

Eosinophilic pneumonia is characterized by alveolar and interstitial eosinophilic infiltration. The etiology is unknown. This condition is more frequent in young adults, with no previous record of respiratory diseases. There is a 2:1 ratio predomination of female. Recent studies have indicated, as predisposing factors, early-onset of smoking and dust exposure. This condition is characterized by cough, dyspnea and pleuritic chest pain, symptoms often confused with an acute respiratory insufficiency by another cause.

Case description

Male, 31 years old, unemployed, worked as interior house constructor. There was no relevant medical history except for smoking (10 pack-year). The habit was stopped 6 months before the symptoms.

The patient was admitted with dry cough, sudden onset of dyspnea and sternal chest pain, which was constant and with partial relief at rest. This pain was triggered after outdoor exercise under low temperatures. The physical exam showed hypoxemia (90%) and, at lung auscultation, the murmur was globally diminished with generalized bronchospasm. The arterial blood gas revealed PaO₂ 60.9 mmHg and, at the blood test, a leukocytosis (14830 cells, 17% eosinophilic predominance). The chest X-ray showed nodular para-cardiac images and the CT-scan showed areas with ground-glass opacification compatible with acute eosinophilic pneumonia. Due to the exuberance of dyspnea, and after excluded infectious causes, we prescribed prednisolone (1mg / kg / day), bronchodilator and oxygen therapy as well. There was a good medical evolution and the prednisolone was reduced after 5 days. By this time, the patient was asymptomatic.

Discussion

Although pulmonary biopsy leads to a definitive diagnosis, in this case, the eosinophilic pneumonia was established based on the compatible clinical history, the presence of peripheral eosinophilia, pulmonary infiltrate in both imaging tests, no sign of infection and sustained response to corticosteroids. In despite of the a good prognosis, most patients need to maintain a low corticosteroid dose to avoid recurrences.

The main interest of this case is that common respiratory symptoms are the initial manifestation of this rare pathology. A CT-scan is a fast and easily accessible method that could revealed the diagnosis. The authors pretend to review the differential diagnosis, the therapeutic options to be instituted and the follow-up strategy.

#1913 - Case Report

A MISLEADING NODULAR FORM OF SILICOSIS

Maria Silva, Cláudia Moreira, Christine Costa, Sónia Silva, Salvato Feijó

Centro Hospitalar de Leiria, Leiria, Portugal

Introduction

Silicosis is maybe the oldest Pneumoconiosis. It's a fibronodular interstitial lung disease caused by inhalation of crystalline silica. Histologically the most characteristic findings are the silicotic nodules and radiologically the centrilobular and subpleural micronodules smaller than 0.5 cm in the upper pulmonary field.

In chronic silicosis, conglomerate nodules of progressive massive fibrosis mimics neoplastic lesions, making the diagnosis more difficult.

Case description

We report a case of a 49 year old woman, non smoker, who worked in a ceramic factory for 18 years. The patient had no respiratory symptoms.

Chest Computed Tomography presented cicatricial changes in the upper lobes and a nodular lesion in the right upper lobe, 3,2 x 2,4 cm diameter.

Pulmonary functional testing was normal and fiberoptic bronchoscopy showed no alteration. Transthoracic lung biopsy was performed but the result was not conclusive. Therefore, the patient was proposed for surgical biopsy. The diagnosis of silicosis was established.

Discussion

With this case the authors aim to emphasize the importance of occupational history and to demonstrate how challenging the diagnostic of silicosis can be when the radiologic features are unusual.

#1920 - Case Report

A CASE OF ATYPICAL PROGRESSION OF INTERSTITIAL LUNG DISEASE

Marta Cerol, Natália Teixeira, Ana Vera Cruz, Margarida Pereira, Rita Paulos

Hospital Distrital de Santarém, Santarém, Portugal

Introduction

Sjogren syndrome is a chronic, systemic autoimmune disorder, which is characterized by lymphocytic infiltration of exocrine glands but can also affect extraglandular organs, including the lung. Interstitial lung disease is the most common pulmonary finding in Sjogren syndrome, and usually presents with mild symptoms of dyspnoea and cough and has an indolent progression.

Case description

We describe the case of a female patient, 72-year-old, with

a history of primary Sjogren syndrome, type two diabetes mellitus, non-compacted myocardiopathy and latent syphilis, polymedicated but with irregular adherence, admitted to the emergency department with dyspnoea and retrosternal pain. A diagnosis of bilateral pulmonary thromboembolism with low to intermediate risk was made and the patient was admitted to the medical department. The condition of the patient worsened with sudden onset of dyspnoea and bronchospasm. She developed low oxygen periphery saturation with progression to respiratory insufficiency and refractory bronchospasm with the necessity of intubation and mechanical ventilation. The patient was admitted to the intensive care unit, and after three days of mechanical ventilation was extubated. She continued presenting recurrent episodes of bronchospasm and despite optimization of bronchodilator therapy, showed only moderate improvement. A thoracic tomography showed diffuse bilateral dispersed thin-walled cyst with areas of ground glass attenuation and thickening of interalveolar septa and the bronchoalveolar lavage showed a lymphocyte count of 35%. After the exclusion of other causes, the presumptive diagnosis of lymphoid interstitial pneumonia was made and therapy with methylprednisolone was initiated, with a weak response. The respiratory insufficiency progressed and the patient died after thirty days as an inpatient.

Discussion

Lymphoid interstitial pneumonia is an uncommon form of interstitial lung disease, associated with a number of conditions, including Sjogren syndrome. The management should focus not only on corticoid therapy but also in controlling the underlying disease process. Despite usually having an insidious onset, even without treatment, on this patient the condition developed and progressed rapidly despite the therapeutic measures instituted, which lead to the death of the patient.

#1924 - Case Report

PNEUMONIA OR PNEUMONITIS? DIAGNOSTIC CHALLENGES

Bárbara Fontes Oliveira, Juliana Sá, Sara Costa, Guilherme Gomes, Marina Alves

Hospital de Braga, Guimarães, Portugal

Introduction

Community-Acquired Pneumonia (CAP) is a common diagnosis in emergency departments (ED) of Portuguese hospitals. Despite having a higher incidence in the geriatric age, it affects people in all the age groups, being an important cause of morbimortality and health care-associated costs. In fact, CAP associated hospitalizations have increased in recent years, not only because of the increment in average life expectancy, but also because of the increased number of multi-resistant microorganism. On the other hand, Hypersensitivity Pneumonitis (PH) is a much less frequent pathology and whose diagnosis is dependent on a high level of suspicion. In fact, many of its signs and symptoms overlap

with those of a typical CAP. The collection of a detailed medical history and a thorough physical examination are essential for the differential diagnosis.

Case description

A 54-year-old female was admitted to the ED due to dyspnea, irritating cough, fever, general malaise and myalgias. Physical examination showed tachypnea and bilateral crepitations on pulmonary auscultation. A chest X-ray showed bilateral alveolar infiltrate, and the patient had hypoxemic respiratory insufficiency. The patient was diagnosed with CAP and antibiotherapy was initiated empirically and was admitted to the Internal Medicine ward. The clinical history was investigated further, and revealed a clinical picture of dyspnea, wheezing, retrosternal tightening, sweating, asthenia, anorexia and weight loss that had been developing for the last 2 months. Furthermore, the patient had contact with several pets, namely birds, dogs and cats and worked as a cleaning lady. Based on this new information, new tests were requested. Computed Tomography of the thorax revealed a pattern of intense ground-glass opacities, air-trapping phenomena and centrilobular nodules, all of which suggest a HP, in the subacute phase. This diagnosis was confirmed by the results of bronchoscopy and analysis of bronchoalveolar lavage, and the patient started corticotherapy, with significant clinical improvement. The integration of the clinic with the imaging and laboratory results allowed us to establish the diagnosis: Hypersensitivity Pneumonitis, probably due to exposure to birds.

Discussion

With the presentation of this clinical case, it is intended to raise awareness of the presence of some disease stigmas, so as to make a timely and safe diagnosis and thus avoid the progression of the disease to a chronic form with irreversible fibrosis.

#1949 - Medical Image

FIBROTHORAX SECONDARY TO TUBERCULOSIS

Joana Batista Correia, Sónia Guerra, Rita Ferro, Mariana Conceição, Angela Cunha, Sandra Figueiredo, Carla António, António Simões Torres

Centro Hospitalar Tondela-Viseu, EPE., Viseu, Portugal

Clinical summary

75-year-old female patient, with clinical history of high blood pressure and pulmonary tuberculosis at the age 17. The patient presented with sudden cardiac arrest at her house, so the emergency rescue team successfully performed resuscitation. The patient's family reported symptom of flu for the past days. She was admitted to the hospital, showing respiratory acidosis on gasometric evaluation. Chest radiograph showed calcified pleural thickening of the left lung, causing marked volume loss of the affected hemithorax with sparing of the mediastinal pleura, consistent with fibrothorax secondary to tuberculosis.

Non-invasive ventilation was started and the patient showed progressive clinical and gasometric improvement. She got discharged at day 15 and remains clinical and functionally stable.

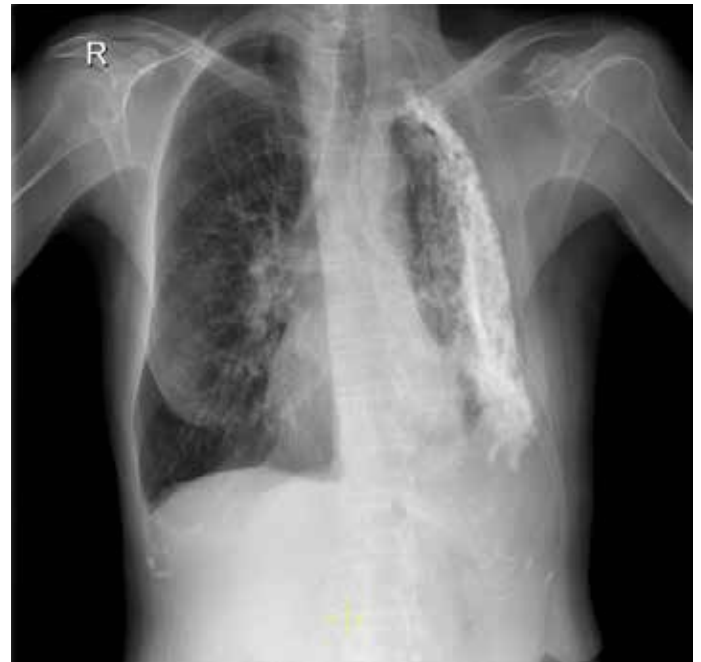

Figure #1949. Fibrothorax secondary to tuberculosis.

#1973 - Medical Image

COMPLICATED SILICOSIS

Joana Batista Correia, Sónia Guerra, Rita Ferro, Mariana Conceição, Angela Cunha, Isabel Gil Pereira, Carla António, António Simões Torres

Centro Hospitalar Tondela-Viseu, EPE., Viseu, Portugal

Clinical summary

41-year-old male patient, with no relevant clinical history, worker in the quarry industry with exposure to fine particles of silica for the past 20 years. The patient presented to the emergency service with worsening progressive dyspnea and dry cough. Chest radiograph shows large symmetric bilateral apical opacities, gradually migrating toward the hilum and lower lung areas, causing traction of the mediastinum, diaphragm and trachea (which shows a curved deviation) and leaving emphysematous lung tissue. The patient ceased the exposure to silica, but the symptoms and lung function progressed. As such, he was listed for lung transplantation but eventually died at the age of 47.

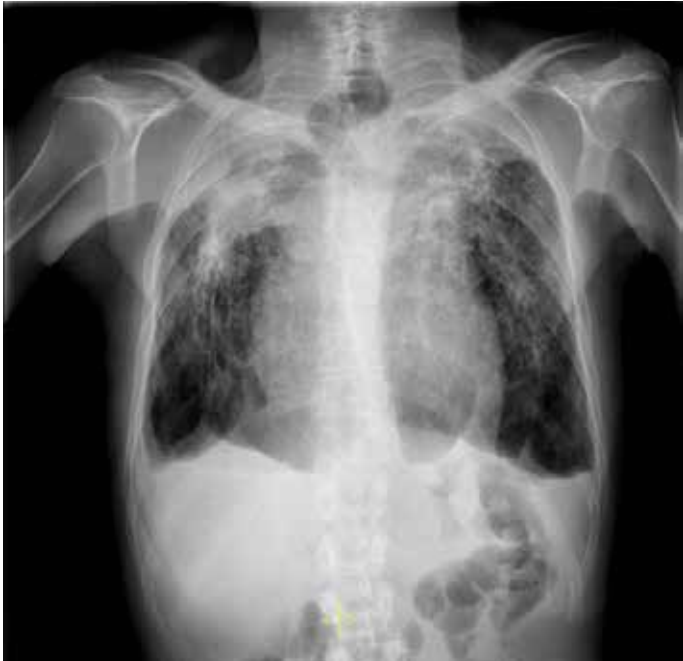

Figure. #1973. Chest radiograph - Complicated silicosis (large symmetric bilateral apical opacities, causing traction of the mediastinum, diaphragm and trachea and leaving emphysematous lung tissue).

#1990 - Medical Image

SOMETHING ELSE BEHIND PNEUMONIA

Ana Martins Neves, Sócrates Naranjo, Ana Bela Mateus

Hospital Dr. José Maria Grande, Portalegre, Portugal

Clinical summary

An 80-year-old, male, patient with multiple diseases: COPD disease; arterial hypertension; dementia; anemia, and several previous hospitalization episodes, due to community acquired pneumonia, associated to food content aspiration phenomena. Two months ago, he presented fever, general malaise, confusion; cough with expectoration, chest pain and mild dysphagia. Diagnosed, once again, with pneumonia, associated with aspiration of food content. During the hospitalization, several complementary diagnostic tests were performed, namely a chest CT-scan, which aimed to: marked dilation of the entire thoracic esophagus (etiology: megaesophagus or achalasia) associated with esophageal hiatus hernia; presence of a tracheoesophageal fistula (TEF) at the sternal manubrium. He awaits a endobronchial stent.

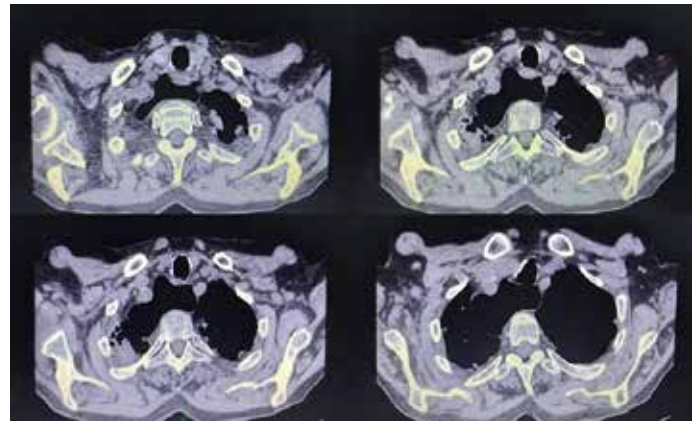


Figure #1990. CT-Scan - marked dilation of the entire thoracic esophagus (megaesophagus or achalasia) and a tracheoesophageal fistula.

#1993 - Medical Image

AN EXUBERANT IMAGEOLOGY OF A LONG HISTORY OF POWDER EXPOSURE

Rita Cebolais¹, Carolina Coelho¹, Angela Ghiletschi¹, Diogo Antão², Rita Lencastre Monteiro¹, Joana Diogo¹, César Vieira¹, Cátia Carvalho¹, Ana Gonçalves¹, Conceição Loureiro¹

¹ Centro Hospitalar e Universitário de Lisboa Central, Hospital de Santo António dos Capuchos, Lisboa, Portugal

² Centro Hospitalar e Universitário de Lisboa Central, Hospital de Santa Marta, Lisboa, Portugal

Clinical summary

Asbestosis is a pneumoconiosis caused by inhalation of asbestos fibers characterized by a diffuse pulmonary fibrosis. In this case, an 82-year-old woman presents with dyspnea, a weight loss of 5kg and a right posterior thoracic pain. She was a factory worker. At the physical exam, the pulmonary murmur was absent in the right hemithorax. ACT-Scan showed a massive right pulmonary effusion and multiple diffuse pulmonary plaques at the right mediastinal and diaphragmatic pleura. An atelectasis of the right lung was described with a mediastinal shift to the left side. The findings were compatible with asbestosis. A thoracentesis was performed. With this case, the authors want to emphasize the importance of the differential diagnosis of common respiratory diseases and to review this condition.

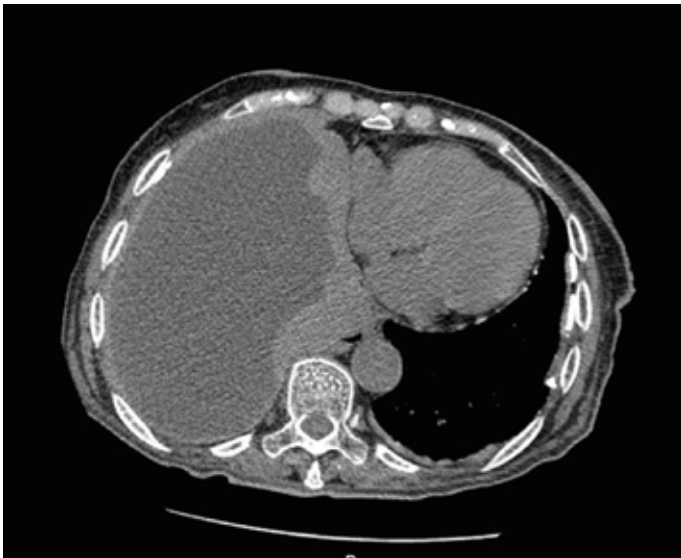


Figure #1993. CT-Scan image: massive right pulmonary effusion and multiple diffuse pulmonary plaques at the right mediastinal and diaphragmatic pleura.

#2000 - Medical Image

SEVERE CONGENITAL KYPHOSCOLIOSIS

Joana Batista Correia, Rita Ferro, Sónia Guerra, Mariana Conceição, Angela Dias Cunha, Ana Campos, Carla António, António Simões Torres

Centro Hospitalar Tondela-Viseu, EPE., Viseu, Portugal

Clinical summary

39-year-old female patient, with reported history of congenital kyphoscoliosis. The patient presented to the emergency service with acute progressive worsening dyspnea, showing respiratory acidosis on gasometric evaluation. Chest radiograph showed an abnormal curvature of the dorsal spine to the left and thoracic CT scan confirmed a severe kyphoscoliosis. Causes for acute respiratory dysfunction were excluded and chronic respiratory dysfunction due to kyphoscoliosis was considered the most probable diagnosis. She was admitted and started on non-invasive ventilation (BiPAP mode) with progressive clinical and gasometric improvement. As such, she got discharged at day 7, keeping follow-up appointments. The patient remains clinically stable, as well as in what concerns to lung function.

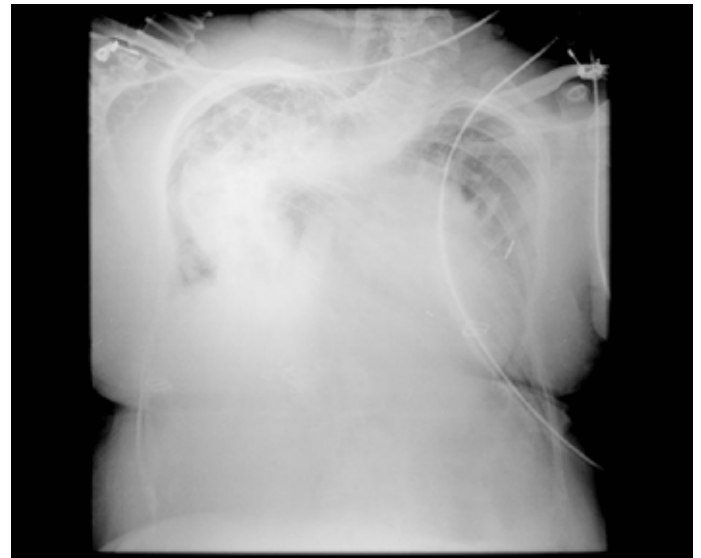


Figure #2000. Severe kyphoscoliosis (chest radiograph).

#2003 - Abstract

RESPIRATORY DISEASES AWARENESS – AN OPPORTUNISTIC SCREENING

Sara Raquel Pereira Martins¹, Catarina Castelo Branco¹, Ana Maria Oliveira¹, Tânia Araújo Ferreira¹, Marli Ferreira¹, Catarina Costa¹, Marli Cruz², Denise Magalhães³, João Neves¹, Pedro Leuschner¹, Alfredo Martins²

¹ Centro Hospitalar do Porto, Porto, Portugal

² Hospital da Luz Arrábida, Porto, Portugal

³ Hospital Pedro Hispano, Porto, Portugal

Background

Respiratory diseases are prevalent worldwide. In 2018, Portuguese Society of Internal Medicine undertook a 2-day event focused on preventive healthcare named Festa da Saúde. Respiratory disease interventions were based on patient education and opportunistic screening of Chronic obstructive pulmonary disease (COPD), Obstructive Sleep Apnea (OSA) and presence of respiratory symptoms in volunteers self-identified as no respiratory condition. This work aims to understand the impact of opportunistic screening at 9 months.

Methods

Opportunistic screening of COPD was conducted by spirometry. A FEV1/FVC <0.70 was considered positive. STOP-BANG \geq 5 or Epworth \geq 10 points were considered positive screenings for OSA. A standardized questionnaire was used to screen for respiratory symptoms. Clinical information was provided to the volunteer by letter to be delivered by him/herself to the general practitioner (GP). Volunteers consented to provide their contact for later assessment of the screening impact. GPs were previously informed about the program.

Results

89 volunteers aged 22-91 years underwent screening, 42% males.

None of the participants met spirometry criteria for COPD. 20 volunteers had positive OSA screening, 10 accepted referral to GP. 3 volunteers were lost during follow-up. Of the remaining 7 patients, 4 delivered the clinical information to their GP and only 1 did sleep study evaluation. Further 10 volunteers were referred to their GP for worrisome symptoms, smoking cessation or spirometry abnormalities other than FEV1/FVC < 0.70. We were not able to contact 3 of those volunteers. Of those 7 whose follow-up was possible, 6 consulted the GP, 1 being diagnosed with asthma, 1 with mild COPD and 1 with chronic cough due to gastroesophageal reflux.

Conclusion

Opportunistic screening may identify non-diagnosed patients and modify their management in a timely manner. Providing the volunteer with a clinical information letter was more effective in non-OSA patients. Other strategies must be considered to assure that positive screened volunteers are provided with adequate health care.

#2049 - Case Report

CRYPTOGENIC ORGANIZING PNEUMONIA: CLINICAL CASE

Rui Soares Correia, Ana Catarina Carvalho, Marlene Delgado, Carla António, António Correia
Centro Hospitalar de Tondela-Viseu, Viseu, Portugal

Introduction

Cryptogenic organizing pneumonia (COP) is a rare entity characterized by the organized inflammatory involvement of alveoli and bronchioles. The clinical presentation often mimics flu-like symptoms associated with chest imaging studies showing ground glass opacities and bronchial wall thickening with dilation. Diagnosis requires the presence of characteristic histopathologic features and the exclusion of other possible causes. Oral glucocorticoids are the established therapy.

Case description

A 59 year old male, with an history of Pulmonary Tuberculosis, peripheral vascular disease and an active smoker was admitted to the hospital presenting with a history of fever, weakness and muscle pain associated with anorexia and weight loss in the prior month. Prior to admission he was working in a farm, having been in contact with goats infected with paratuberculosis. Blood workup revealed thrombocytopenia and positive CRP and the chest radiograph showed bilateral opacities. Blood and urine cultures, urine *Legionella* and pneumococcus antigen search, ADA and Quantiferon TB were all negative. Cultures of gastric juice for mycobacteria, various serologies and autoimmunity were all negative as well. CT scan showed bilateral patchy infiltrates and bronchial wall thickening, predominantly in the right lung. It also revealed emphysema, and a saccular aneurysm of the abdominal aorta. Angio-CT scan confirmed the presence of a fusiform

aneurysm of the descending aorta with the presence of mural thrombus. Echocardiographic evaluation excluded endocarditis. Bronchofibroscope did not show endoluminal or epithelial lesions. Bronchial wash cytology showed no neoplastic cells and cultures of bronchial wash for mycobacteria and serology of Herpes simplex, EBV, CMV and *Mycobacterium tuberculosis* and *Pneumocystis jirovecii* DNA assays were all negative. Percutaneous biopsy was performed, and the histopathological analysis showed lymphoplasmacytic inflammation with lots of plasmocytes embedded in a connective matrix thus concluding the diagnosis of COP. The patient started glucocorticoid therapy, which induced a rapid clinical and imagiological improvement.

Discussion

In conclusion, we present a case of COP, a rare and challenging diagnosis. A thorough examination was required by integrating the essential knowledge, experiences, and clinical reasoning that supports professional practice in order to exclude other possible pathologies.

#2076 - Abstract

ADMISSIONS IN AN INTERNAL MEDICINE WARD: AN OPPORTUNITY TO ASSESS COPD INHALED THERAPY

Carlos Figueiredo, Bruno Mendes, José Sousa, Catarina Pires, Afonso Rodrigues, Inês Gonçalves, João Cardoso, António Guerreiro
Hospital Santa Marta - CHULC, Lisboa, Portugal

Background

Chronic obstructive pulmonary disease (COPD) is a common and treatable disease. COPD patients will be frequently admitted to internal medicine wards. We aimed to evaluate the adequacy of inhaled therapy among patients with COPD admitted to an internal medicine ward.

Methods

We performed a retrospective descriptive observational analysis of 25 patients with spirometry confirmed COPD in an internal medicine ward, between January and December of 2018. The patients were classified into groups according to Global Initiative for Chronic Obstructive Lung Disease (GOLD). Ten (40%) of patients were admitted for a COPD exacerbation. The degree of dyspnoea was evaluated by the modified Medical Research Council (mMRC) scale.

Results

Fourteen patients (56%) were female with a mean age of 72 years (SD 13); twenty four (96%) were smokers or former smokers, with a mean of 70 pack-years (SD 40). The mean FEV1 was 59% (SD 21%), most patients had mild or no history of exacerbations (21 patients, 84%) and a median mMRC dyspnoea of 3 (1-3). According to GOLD, five patients (20%) were classified to group A, six (24%)

to group B, one (4%) to group C and thirteen (52%) to group D. Regarding inhaled therapy, four (16%) patients had no previous inhaled therapy; three (12%) were medicated with a short-acting inhaler or long-acting beta-agonist (LABA); four (16%) with a long-acting muscarinic antagonist (LAMA); five with LABA and LAMA; 1 with a LABA and an inhaled corticosteroid (ICS); and 8 with triple therapy. Five patients (20%) had non-adherence to proposal therapy. Before the discharge four (16%) patients needed to start therapy and 14 (56%) needed to adjust their medication (according to escalation and de-escalation strategies of GOLD). At discharge three patients (12%) were prescribed with a short-acting inhalers or LABA; 1 (4%) with a LABA/ICS; three (12%) with a LAMA; six (24%) with a LABA/LAMA; and 12 (48%) with triple therapy. Seven patients (28%) had been referred to a respiratory rehabilitation program and two (in 10 smokers) had been referred to a smoking cessation appointment.

Conclusion

The small number of patients with spirometry confirmed COPD in this ward in a period of one year represents an underdiagnosed and potentially an undertreated condition. These COPD patients hospitalization presents an opportunity to assess the adequacy of inhaled therapy, smoking cessation, rehabilitation and to make pharmacologic adjustments.

#2129 - Medical Image

THE AZYGOS LOBE: AN UNUSUAL ANATOMICAL VARIATION

Tiago Valente, Fani Ribeiro, Gorete Jesus

Baixo Vouga Hospitalar Center, Aveiro, Portugal

Clinical summary

A 47-year-old male was admitted at the emergency department with a 1-week history of breathlessness, cough, pleuritic chest pain and fever with no analytical nor radiological abnormalities, suggesting a viral upper respiratory infection. His chest radiograph showed an azygous lobe with a thin fissure separating it from the rest of the right upper lobe and a tear-shaped shadow due to the azygos vein. The azygos lobe is a rare but normal anatomic variant of right upper lung seen radiologically in only 0.4% of population. It may be confused with a cavitation, an abscess or a lung mass if consolidated. Some pulmonary disorders such as infections, tumors or pneumothorax may develop within this lobe and the recognition of this anomaly is therefore important.

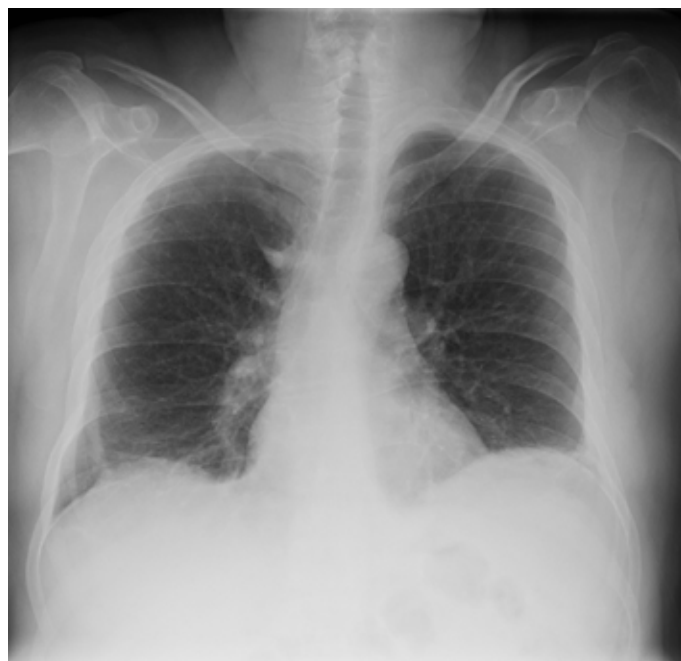

Figure #2129. Azygos lobe and vein.

#2146 - Medical Image

FULMINANT FLU

Rita Amorim Costa¹, Raul Neto¹, Isabel Taveira², Pedro Salvador¹

¹ Centro Hospitalar de Vila Nova de Gaia Espinho, Vila Nova De Gaia, Portugal

² Hospital Litoral Alentejano, Santiago Do Cacém, Portugal

Clinical summary

40-year-old male, former smoker, presented at the ER with fever, cough and hemoptysis within the last 4 days; he had respiratory failure type 1, elevated inflammatory parameters and tested positive for Influenza A. Chest radiography revealed bilateral interstitial hypotransparencies (Panel 1). He started oseltamivir and antibiotic. Despite optimized medical therapy, 8h after admission, invasive mechanical ventilation was needed (Panel 2). He evolved with multiorgan dysfunction and $\text{paO}_2/\text{FiO}_2$ ratio below 100. Thoracic CT was performed 2h after intubation, with evident aggravation (Panel 3). Due to acute respiratory distress syndrome he was submitted to extracorporeal membrane oxygenation. Despite all measures, he died at day 9. These images are intended to show the potential fulminating progression of influenza.

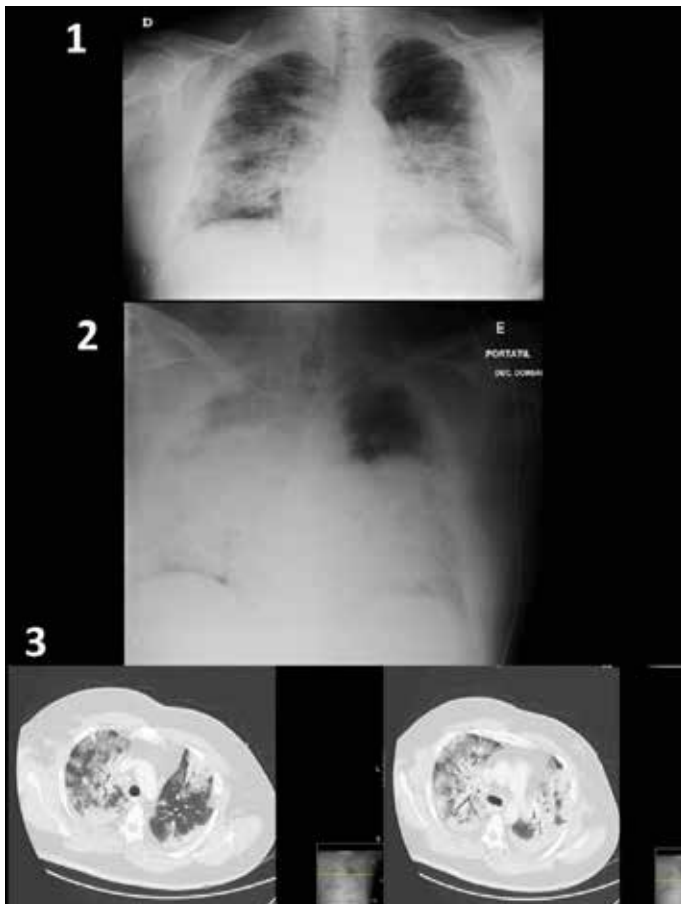


Figure #2146. Panel 1: X-ray at admission; Panel 2: X-ray 8 hours after admission; Panel 3: Thoracic CT 10h after admission.

#2153 - Medical Image

AN ABNORMAL THORACIC MASS

Leonor Boavida, Célia Henriques, Susana Oliveira

Professor Doutor Fernando Fonseca Hospital, Lisbon, Portugal

Clinical summary

A 92-year-old male was admitted with transient ischemic stroke. After recuperation he was asymptomatic. However, chest examination revealed decreased breath sounds in the right inframammary and infra-axillary areas. Chest X-ray showed a homogenous opacity with soft tissue density in the right lower pulmonary zone. For etiological clarification, a chest computerized tomography scan was performed revealing a right hemidiaphragm elevation with contralateral mediastinal shift. A diagnosis of diaphragmatic eventration was made. In adult patients it is often asymptomatic, and diagnosis is usually accidental. This case of a right side diaphragmatic eventration highlights a rare and benign entity that should be included in the differential diagnosis of intrathoracic masses.

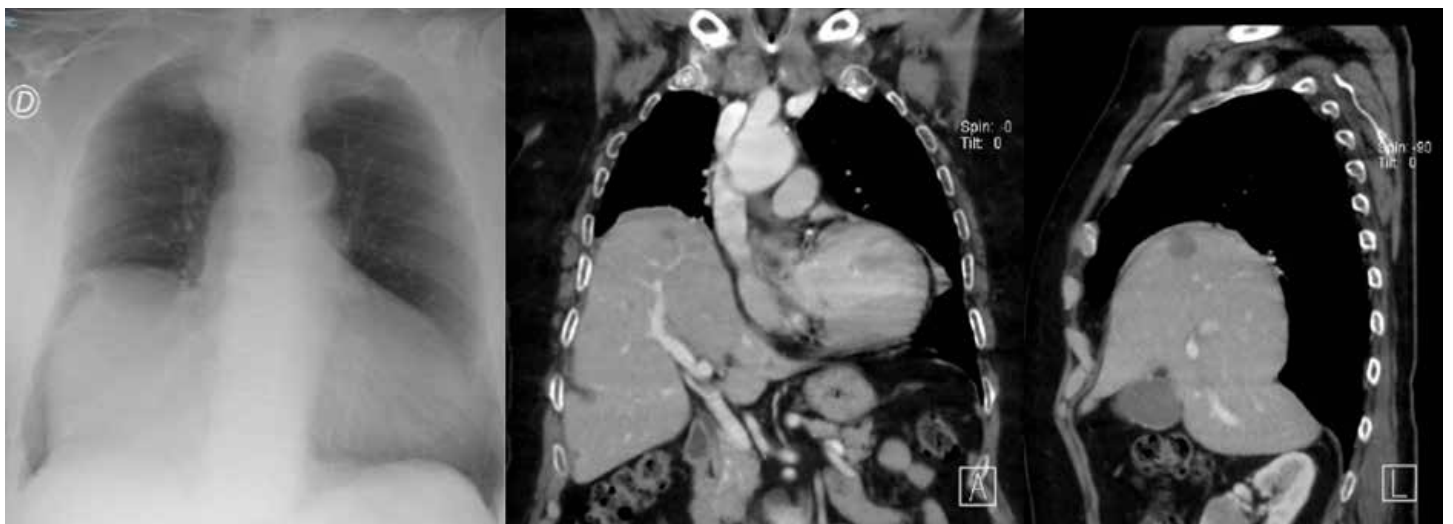


Figure #2153. Chest X-ray and CT scan (coronal and sagittal planes).

#2232 - Case Report

LUNG ADENOCARCINOMA WITH ENTERIC DIFFERENTIATION: A CASE REPORT OF A RARE TUMOUR

Maria Helena Lourenço, Graça Lérias, Isabel Madruga
Centro Hospitalar Lisboa Ocidental, Lisboa, Portugal

Introduction

Lung cancer is one of the most frequent and malignant neoplasms. There are numerous histological types and the course of the disease will depend upon its classification and treatment.

Case description

A 65-year-old man, smoker, with no other relevant medical history, is referred by his physician to the Emergency Service after having undergone a lumbar computed tomography (CT) scan due to lower back pain evolving for several weeks. The CT showed lytic lesions all over the lumbar spine. After a thorough clinical history, an unintentional weight loss was determined (11kg in 4 months) and at physical exam the patient complained of pain during abdomen palpation of the upper right area. Blood analysis showed an elevated lactate dehydrogenase (366 U/L) and a C-reactive protein of 4 mg/dL. Thoracic and abdominal CT revealed a peribronchial right mass, thrombosis of the right internal jugular and right subclavian veins, diffuse lymphadenopathy in the cervical and thoracic regions and nodules on the liver and suprarenal glands. During colonoscopy, three polyps were removed and histologically analysed, one of them with high degree dysplasia. A bronchofibroscopy with lung biopsy was done, showing normal lung tissue. A rib biopsy was then carried out where one of the masses was easily accessible. The anatomopathological exam revealed a metastasis of an enteric adenocarcinoma, with a positive CDX2 and a both negative Napsin-A and TTF1. The patient was diagnosed with lung adenocarcinoma with enteric differentiation at stage IV and was referred to the consultation to define treatment. Biomarkers testing was performed resulting in a both negative PD-L1 and EGFR. Before the consultation, the patient was admitted to the hospital again due to a pneumonia and a peripheral pulmonary embolism, eventually passing away after a few days.

Discussion

A lung adenocarcinoma with enteric differentiation is a very rare type of lung cancer. It was first described in 1991 and included in the World Health Organization classification in 2011. This type of cancer is diagnosed upon finding more than 50% of enteric pattern and at least one marker of enteric differentiation must be present during immunohistochemical study (CK20, CDX2 or MUC2). One of the first steps is to differentiate this type of tumour from a metastasis of colorectal adenocarcinoma. As it was observed with this case, this cancer may take a rapid and aggressive course. It is essential to ensure a fast diagnosis in order to give the patient the best care.



RHEUMATOLOGIC AND IMMUNE-MEDIATED DISEASES

#58 - Case Report

MYSTERIOUS MYOPERICARDITIS

Baiju Faizal Puthenkote

Lifecare hospital, Abudhabi, United Arab Emirates

Introduction

Adult onset Stills Disease (AOSD) is a very uncommon inflammatory disorder of unknown etiology. Cardiac involvement is reported in one-third reported cases in the form of pericarditis but myocardial involvement has been rarely reported.

Case description

35 year old Srilankan gentleman developed high grade fever with sore throat of 4 days duration, associated with chest pain and palpitation of 2 days duration. At presentation, he had neutrophilic leukocytosis with high CRP (400). Troponins were high and ECHO was suggestive of myopericarditis. On the 8th day, he developed swelling and pain over multiple large joints. Synovial aspirate suggestive of inflammatory arthritis. Pleural fluid analysis was exudative and culture negative. On the 14th day, he developed breathlessness and desaturation. Repeat chest imaging revealed bilateral pleural effusion with basal atelectasis and pneumonitis and he continued to worsen clinically. WBC Count and CRP remained elevated. blood culture negative. ANA Profile, anti dsdna, RF negative. ANCA negative. Coxsackie, Brucella serology negative. Ferritin 47,450. ECHO revealed significant pericardial effusion with RV diastolic collapse. In view of high ferritin and other supporting features, diagnosis of severe form of AOSD satisfying Yamaguchi criteria was made and he was given IV methyl prednisolone for 3 days and then 1 mg/kg prednisolone. He improved dramatically.

Discussion

AOSD, a diagnosis of exclusion, It is associated with markedly elevated serum ferritin values above 3000. Clinical diagnosis is based on Yamaguchi criteria and cardiopulmonary involvement in the form of pleurisy, pericarditis or effusion is not uncommon. High level of suspicion is life saving, initial presentation can mimic sepsis.

#84 - Case Report

SYSTEMIC LUPUS ERYTHEMATOSUS AND AMYOPATHIC DERMATOMYOSITIS OVERLAP SYNDROME

Rita Queirós, Andreia Costa, Nuno Silva, Fernando Salvador, Joana Vaz Cunha, Elisa Serradeiro

Unidade de Doenças Autoimunes, Serviço de Medicina Interna, Centro Hospitalar de Trás-os-Montes e Alto Douro, Vila Real, Portugal

Introduction

The concept of overlap syndrome includes a wide group of conditions characterized by the coexistence of immunological manifestations and results that meet classification criteria of two or more connective tissue diseases that occur simultaneously in the same patient.

Case description

Woman aged 72 years started non-pruritic maculopapular erythema in the face and neck region associated with photosensitivity that slightly improved with corticoid. Two years later the skin lesions got worse and polyarthralgias appeared in small and large joints of the upper limbs with an inflammatory and migratory pattern. There was also a history of alopecia since she was 30.

She went to the Emergency Department due to asthenia and deterioration of the general state with a month of evolution. Her blood test showed hemolytic anemia, lymphopenia, thrombocytopenia, active urinary sediment and non-nephrotic proteinuria, complement consumption, ANA's and anti-dsDNA antibodies were positive. The diagnosis of Systemic Lupus Erythematosus (SLE) was assumed and she was started on hydroxychloroquine and prednisolone. There was a noticeable improvement of arthralgias and a slight decrease of the cutaneous rash.

Three weeks later, she developed skin lesions with exuberant erythema throughout the face and neck region. Cutaneous biopsy revealed discrete interface dermatitis lesions compatible with dermatomyositis, despite the absence of proximal muscle weakness or elevated muscle enzymes. Electromyography demonstrated low amplitude motor and potential motor drive responses, that weren't relevant. SLE - Amyopathic Dermatomyositis Overlap Syndrome was assumed and topical tacrolimus was started with significant cutaneous improvement. Subsequently, renal biopsy

revealed class IV OMS lupus nephritis and cyclophosphamide was started according to the EUROLUPUS protocol.

Discussion

This case illustrates a rare association that alerts to how hard it is to diagnose when the spectrum of manifestations is similar and clinical differentiation becomes difficult. In this case, not everything that appeared to be SLE was just SLE.

#94 - Case Report

A CASE OF PARANEOPLASIC ANCA VASCULITIS

Nuno Vieira E Brito, Ricardo Taborda, Tiago Quaresma, Pawel Sierzputowski, Paula Alcantara

Centro Hospitalar de Lisboa Norte, Lisboa, Portugal

Introduction

Vasculitis as a paraneoplastic syndrome is a rare condition and one whose pathophysiology is yet unclear. The association between ANCA vasculitis and solid tumor is an even rarer condition with very few reported cases.

Case description

A 73 year old woman is admitted at the emergency department for sudden vision loss with 24 hours of migraine headache, weight loss of 7 kg over one year, asthenia and episodes of low fever with spontaneous remission. She had type 2 diabetes, arterial hypertension, prothrombin gene mutation and had been submitted to aortic and mitral valve replacement with a biological prosthesis. The ophthalmology observation suggested ischemic optic neuropathy and as such was referred to internal Medicine for evaluation. At admission the patient was anaemic with normocytic normochromic anaemia with haemoglobin of 10.4 g/dL, a erythrocyte sedimentation rate of 103 mm and a positive rheumatoid factor of 17.8 UI/ml, complement levels were normal and HIV and hepatitis tests negative. Doppler scan of the temporal, facial and occipital arteries showed a slight thickness but no image of halo and a Eco guided biopsy was absent for giant cells. Autoimmune serologies were positive for C-ANCA antibodies with a anti-PR3 of 361. Pulses of methylprednisolone were performed with a partial recuperation of sight. During investigation biopsy of the nose turbinate as well as CT scan of cranial sinus and thorax were absent for granuloma. During follow up there was never any renal involvement and the patient responded well lowering the erythrocyte sedimentation rate and continued improvement of sight but without lowering of C-ANCA title, 621 at a second evaluation. One month after discharge the patient was readmitted for myocardial infarction and underwent a coronarography that revealed severe atherosclerotic disease in the anterior descending artery. This admission was complicated with endocarditis to streptococcus oralis and episodes of hematochezia. A colonoscopy revealed adenocarcinoma with 30 mm. The patient underwent hemicolectomy with adenectomy

staging the disease at G3pTaaL1V1pN1b. After undergoing 2 cycles of chemotherapy and suspending all steroids there was evidence of vasculitis with a lowering of the antibody title to 300.

Discussion

The authors present a case of a tumor induced vasculitis whose diagnosis precedes that of the tumor and whose symptoms and antibody titer improve only with tumor control and treatment.

#97 - Case Report

A REVOLUTIONARY WORKUP: FROM ANTIPHOSPHOLIPID SYNDROME TO ERDHEIM-CHESTER DISEASE

Tamer Hasan Ghanayim

Lady Davis Carmel Medical Center, Haifa, Israel

Introduction

Erdheim-Chester Disease (ECD) is a rare histiocytic disease, with less than 500 cases reported in literature. It is characterized by multifocal osteosclerotic lesions of long bones, bilateral and symmetric in nature. Etiology is unknown, but a genetic basis exists, and a few mutations have been pinpointed, most prominently the BRAF V600E mutation. The clinical spectrum of ECD is wide, ranging from asymptomatic bone lesions to multisystem life-threatening variants. Once diagnosed properly, ECD can be treated effectively.

Case description

A 40-year-old, otherwise healthy male, with a family history of recurrent cerebrovascular attacks, has been undergoing an extensive medical evaluation for more than 10 years due to recurrent complaints of backache, lower extremities bone pain, dizziness, facial numbness, diplopia and unintentional weight loss. For more than a decade, he was presumed to suffer from APS, based on a constellation of findings, including a suspicion of bone infarcts based on several CT scans of the lower limbs, a rich family history of thrombosis and a single slightly positive lupus anticoagulant test. Has been treated with a vitamin K Antagonist. Due to progressive deterioration in his condition, especially aggravating skeletal symptoms leading to marked physical limitation, he sought medical attention and was eventually admitted to our ward for further investigation. Initially, he underwent a bone technetium-99m scintigraphy, revealing symmetric pathologic demarcation in the distal long bones and at the level of the nasal triangular region. The findings were suggestive of ECD. Further evaluation included a CT-guided biopsy of a sclerotic bone lesion in the distal tibia, showing groups of foamy macrophages (CD68+) associated with slight lymphocytic infiltrate, consistent with ECD. In order to confirm the diagnosis of ECD, genetic testing was performed, revealing a positive BRAF V600E mutation. Anticoagulation therapy was stopped and the diagnosis of APS was refuted after serial serologic tests of anticardiolipin, beta2-glycoprotein and lupus anticoagulant came negative. Treatment with vemurafenib

(a BRAF inhibitor) was initiated, leading to a satisfactory clinical response.

Discussion

ECD is an extremely rare, and usually overlooked disease. Establishing a diagnosis is crucial, as the disease could be potentially fatal without treatment, and is challenging mainly due to an abundance of non-specific findings. Treatment could be course-corrective and preventing further redundant investigations and futile therapy.

#105 - Case Report

HIP PAIN REVEALING SYSTEMIC SCLEROSIS IN A YOUNG WOMAN

Abire Allaoui, Khadija Echchilali, Mina Moudatir, Fatima Zahra Alaoui, Hassan Elkabli

Internal Medicine Department, Ibn Rochd University Hospital, Casablanca, Morocco

Introduction

Systemic sclerosis (SSc) is an orphan autoimmune disease with a complex physiopathology, characterized by a widespread microvasculopathy and a progressive fibrosis of the skin. SSc-related vasculopathy can explain common clinical features like Raynaud phenomenon but also some rare or less recognized features like osteonecrosis. This bone affection is underestimated in SSc in comparison with other autoimmune diseases such as systemic lupus erythematosus or antiphospholipid syndrome.

Case description

We report on a case of bilateral hip osteonecrosis that revealed SSc in a female patient of 38 years old. The patient presented with an unexplainable bilateral coxalgia that had started 2 years ago, firstly mistaken for arthritis and treated with anti-inflammatory drugs with no improvement. No history of smoking, alcohol use nor metabolic diseases were recorded, and no corticosteroids exposure was noted. Physical examination noticed Raynaud phenomenon, telangiectasis, discreet sclerodactyly, and painful mobilization of both hips associated to lameness. Nontraumatic osteonecrosis of the femoral head was identified by X-ray and magnetic resonance imaging as the underlying cause of the hip pain. Antinuclear antibody and Scl70 were positive (1:160/80). C3 and C4 were normal, and rheumatoid factor and Anti-citrullinated protein antibodies were negative. Sedimentation rate was 4 mm/h and c reactive protein test was normal. Tests to assess coagulopathy showed negative antibodies to β 2 glycoprotein, to cardiolipin and to lupus anticoagulant. Tests were also negative for antithrombin III, protein S, and protein C. A nailfold videocapillaroscopy showed loss of capillaries and neovascularization. Pulmonary function tests and chest CT-scan were also normal. No sign of arterial pulmonary hypertension was found during the workup. The patient fulfilled the 2013 ACR/EULAR criteria for classification of systemic sclerosis. In addition to a specific treatment for SSc,

a surgical consult was obtained, where a surgical hip replacement was decided.

Discussion

This observation is particular, because the osteonecrosis that was mistaken during 2 years for an arthritis and wrongly treated for it, has revealed SSc. Thus, rheumatologists and internists should be aware of potential bone involvement in SSc patients especially osteonecrosis, as a differential for arthritis, and to adapt the treatment. They should also keep a place for SSc in the list of osteonecrosis autoimmune causes, even it is a rare feature.

#116 - Abstract

SEX DIFFERENCE IN INFECTIVE ENDOCARDITIS

Boris Shvarts, Iftach Sagy, Vered Stavi, Jenan Awesat, Leonid Barski

Soroka University Medical Center, Beer Sheva, Israel

Background

The impact of sex on the presentation, etiology, pathogenesis and outcomes of IE has not been adequately studied. The aim of the present research was to study the impact of sex on the presentation, etiology, pathogenesis and outcomes of IE.

Methods

We performed retrospective study of 214 adult patients (131 male and 83 female) with Infected Endocarditis (IE). All cases of IE were reviewed by two investigators- senior physicians in internal medicine. Two groups of patients were compared: patients with IE females and males. In-hospital mortality was a primary outcome.

Results

In our study we obtained significant differences in etiologic factors of IE in male and female patients. Most etiological differences between male and female groups of patients were in coagulase negative staphylococcus (15.0 percent in male vs 3.8 percent in female groups), culture negative endocarditis (8.7 percent in male vs 23.8 percent in female groups). We did not find difference in the primary outcome between the two groups. However, one year mortality was significantly higher in the female group as compared to the male group (26 [31.3] vs 22 [16.8], $p=0.018$).

Conclusion

There exist significant differences in etiology of IE in male and female groups of patients. These differences are due to the relatively high percentage of male patients with IE due to coagulase-negative staphylococcus compared to women patients and particularly high percent of culture-negative endocarditis in female compared to male groups. Female sex is independent risk factor of increased one year mortality in patients with IE.

#144 - Case Report

IGA VASCULITIS WITH SEVERE INTESTINAL AND RENAL INVOLVEMENT REQUIRING CYCLOPHOSPHAMIDE IN A PATIENT TREATED WITH ANTI-TNFA FOR RHEUMATOID ARTHRITIS

Alessia Ferrarini, Diletta Olivari, Alessia Angeletti, Giulia Rossetti, Giovanni Pomponio, Armando Gabrielli

Clinica Medica- Ospedali Riuniti, Ancona, Italy

Introduction

IgA vasculitis (Henoch-Schönlein Purpura) is an immune complex vasculitis affecting small vessels with dominant IgA deposits. Although it generally follows upper respiratory tract infection, association with a number of inflammatory disease like Rheumatoid Arthritis (RA) is also described. Cutaneous purpura, arthralgia, acute enteritis and glomerulonephritis are among typical clinical manifestations. Renal involvement represents the main cause of morbidity and mortality in adults.

Case description

We report the case of a 67-year-old woman with a 3-year history of seropositive (RF+, ACPA+) rheumatoid arthritis, undergoing etanercept therapy, who developed a purpuric rash without symptoms of preceding infection. Clinical picture complicated with sudden onset of abdominal pain, gastrointestinal bleeding, macroscopic hematuria and severe proteinuria (6g/24h). Blood count, chemistry, C3 and C4 levels were normal. ANA, anti-DNAs, anti-ENA, ANCA, cryoglobulinaemia were negative. Increase of serum IgA (430mg/dl) was found. Skin biopsy revealed inflammation and focal fibrinoid necrosis of vascular wall (small and medium size vessels) with leukocytoclasia and C3 deposition. Esophagogastroduodenoscopy showed multiple superficial ulcers and mucosal inflammation with ischemic necrosis at biopsy. Intravenous methylprednisolone was started (1 mg/kg). After 1 month, due to persistence of hematuria and proteinuria (6.25 g/24h) and serum creatinine raising, kidney biopsy was performed, showing mesangial glomerulonephritis with C3 and IgA deposits. Cyclophosphamide was initiated (6g in 6 months), and resolution of clinical signs, proteinuria and hematuria was observed.

Discussion

Current literature reports few analogous cases of systemic IgA vasculitis following anti-TNF treatments in various chronic inflammatory condition. Our patient is peculiar for several reasons: 1. Unusual histological pattern resembling a necrotizing vasculitis; 2. Severity of intestinal and renal involvement; 3. Absence of evident infectious trigger.

#161 - Case Report

PERSISTENT REMISSION AT 2-YEARS FOLLOW-UP AFTER SINGLE COURSE OF RITUXIMAB IN AAPOX SYNDROME ASSOCIATED WITH IGG4-RELATED DISEASE: A CASE REPORT

Diletta Olivari¹, Giovanni Pomponio², Alessia Angeletti¹, Giulia Rossetti¹, Gaia Goteri³, Armando Gabrielli¹

¹ Clinica Medica, Università Politecnica delle Marche, Ospedali Riuniti, Ancona, Italy

² Clinica Medica, Ospedali Riuniti, Ancona, Italy

³ Section of Pathological Anatomy, Università Politecnica delle Marche, Ospedali Riuniti, Ancona, Italy

Introduction

IgG4-related disease (IgG4-RD) is a rising autoimmune disease characterized by multi-organ involvement and heterogeneous clinical behaviour.

Case description

We describe the case of a 50-year-old woman affected by a rare form of IgG4-RD, AAPOX (adult-onset asthma and periocular xanthogranulomas) syndrome, characterized by adult-onset asthma, eyelid xanthelasma and lacrimal and salivary glands enlargement. A pulmonary mass and multiple lymphadenopathies were detected at initial assessment. A single course of rituximab (1000 mg given 2 weeks apart, 2 total doses) as first-line monotherapy enabled to achieve a complete clinical remission, persistent at 2-years follow-up, without chronic steroid administration.

Magnetic resonance imaging (MRI), high-resolution computed tomography (HRCT) of the thorax, and positron emission tomography (18FDG-PET-CT) confirmed response to treatment. Circulating plasmablasts dropped to undetectable values and remained stable for one year. At 2-years follow-up, plasmablasts raised again, although clinical, laboratory and radiological remission persisted. A total body positron emission tomography confirmed absence of metabolically active lesions. Xanthelasma only remained unchanged.

Discussion

Actually, steroid therapy is the standard first-line treatment in IgG4-RD, but high doses are typically required and relapses are frequent in the tapering phase. Rituximab is a widely used steroid-sparing strategy, but reserved for refractory patients. In our case, rituximab has been administered as first-line monotherapy, revealing great and prolonged efficacy and tolerability. The rare variant of IgG4-RD affecting our patient with small baseline plasmablasts proportion, and the early administration of rituximab could have promoted the optimal response, persistent at 2-years follow-up. The raise of circulating plasmablasts two years after rituximab, even in absence of clinical and radiological signs of disease activity, could be worthy of concern for future relapse.

#174 - Abstract

EFFICACY OF INFLIXIMAB IN PATIENTS WITH RHEUMATOID ARTHRITIS (RA) DEPENDING ON A QUANTITY OF INFUSIONSEugenia Aronova¹, Galina Lukina²¹ V. A. Nasonova Research Institute of Rheumatology, Moscow, Russia² Moscow Clinical Scientific Center named after Loginov A. S., Moscow, Russia**Background**

To estimate efficacy of infliximab in patients with RA depending on a total dose of this biologic.

Methods

The cohort of 135 patients with active RA despite methotrexate therapy (114 women, mean age 48 years, mean disease duration 4 years, RF-positive 75,6%) treated with infliximab according to the standard scheme have been divided into three groups: patients who received less than 4 infusions (N=63); patients who received 5-7 infusions (N=31); patients who received more than 7 infusions (N=41). DAS28 >5,1 in the 1-st group was registered in 69% of patients, in the 2-nd group in 86,6%, in the 3-rd group in 62,1%.

Results

By the 54-th week significant decrease of RA activity was achieved in all groups but DAS28 in 1-st group was significantly higher than in other groups (4,4 vs 3,2 in the others; $p < 0,05$). The remission rate by this time point was 28,6% in the 2-nd group, 23,1% in 3-rd group and 18,2% in the 1-st group ($p < 0,05$). In all groups radiological progression was noted by the 54-th week but among patients who received not more than 4 infusions this progression was significantly more pronounced than in other groups.

Conclusion

The therapeutic effect of infliximab was more pronounced in patients who received "middle" doses of infliximab and the full annual course of infliximab as compared with patients having received low total dose. It refers both to the higher remission rate and to the slowing of radiological progression.

#175 - Abstract

DRUG SURVIVAL ON BIOLOGIC DISEASE-MODIFYING ANTI-RHEUMATIC DRUGS IN PATIENTS WITH RHEUMATIC DISEASES

Eugenia Aronova

V. A. Nasonova Research Institute of Rheumatology, Moscow, Russian Federation, Moscow, Russia

Background

Objectives: to estimate drug survival in patients using tumor necrosis factor inhibitors or other biologics (rituximab, abatacept, tocilizumab) and to reveal predictors of the discontinuation of therapy within the first year of therapy.

Methods

We retrospectively studied 53 patients with rheumatic diseases during the period from 2010 to 2018 to whom bDMARDs were initiated for the first time. Diagnosis were rheumatoid arthritis (88.7%), ankylosing spondylitis (9.4%) and psoriatic spondyloarthritis (1.9%). There were 10 males and 43 females (M:F ratio was 1:4,3), the median age (25%-75%) was 38 years (29.5%-56%) from 18 till 71 year. 34 patients were treated with TNF- α inhibitors and to 19 patients - non-TNF biologics. Discontinuation rates were estimated using cumulative incidence adjusted for risk ratio. Cox models were used to examine potential predictors of discontinuation.

Results

Cumulative incidence for time to discontinuation at 1 year was 70,6% for first TNF biologic and 57.9% for non-TNF (risk ratio 1.22 [95% CI 0.79-1.89]). The longest period of observation was 7 years - one case in group of TNF. The most common reasons for discontinuation of any first biologic were: primary and secondary inefficiency (68%), adverse events (20.8%) and the administrative reasons (11.2%). The frequencies of each reason were similar between TNF and non-TNF treated patients. Potential predictive factors for discontinuation within first year, including age, sex, and nosological diagnosis did not reach statistical significance in both groups.

Conclusion

Most often drug withdrawal occurs within the first year of therapy that causes need of medical observation during this period. Their insufficient effectiveness is the main reason for discontinuation of biologics. Discontinuation rates were similar between TNF and non-TNF biologics. We did not identify any significant predictors of drug discontinuation.

#176 - Abstract

PREDICTORS OF THE GOOD RESPONSE TO INFLIXIMAB THERAPY AT PATIENTS WITH A RHEUMATOID ARTHRITIS (RA)Eugenia Aronova¹, Galina Lukina²¹ V. A. Nasonova Research Institute of Rheumatology, Moscow, Russian Federation, Moscow, Russia² Moscow Clinical Scientific Center named after Loginov A. S., Moscow, Russia**Background**

Objective: To identify reliable predictors of infliximab effectiveness in the observational setting of RA patients.

Methods

135 RA pts treated with INF (3 mg/kg intravenously at baseline, week 2, week 6 and subsequently every 8 weeks) in one center were enrolled in the study. All pts were on stable DMARDs, mainly methotrexate, treatment. Clinical response to infliximab was

determined at week 54, using EULAR criteria. Potential baseline predictors of response (demographic, disease-specific, and patient-specific factors) were compared between pts who did or did not achieve a major response and identified using multivariate binary logistic regression models.

Results

Seventy-four pts completed the study; 75.9% of them achieved a major response (good: 24.1%; moderate: 51.8%). Short disease duration, low HAQ, RF-negativity, low C-reactive protein and ESR, morning stiffness of short duration at baseline and male gender predicted good clinical outcome. DAS28 score at baseline was inversely associated with good response. Age and pain score did not influence treatment response.

Conclusion

In this observational study of patients with established RA age and pain score did not predict response to INF therapy, whereas male sex, RF-negativity, signs of the lesser disease activity and low disability at baseline were associated with good response.

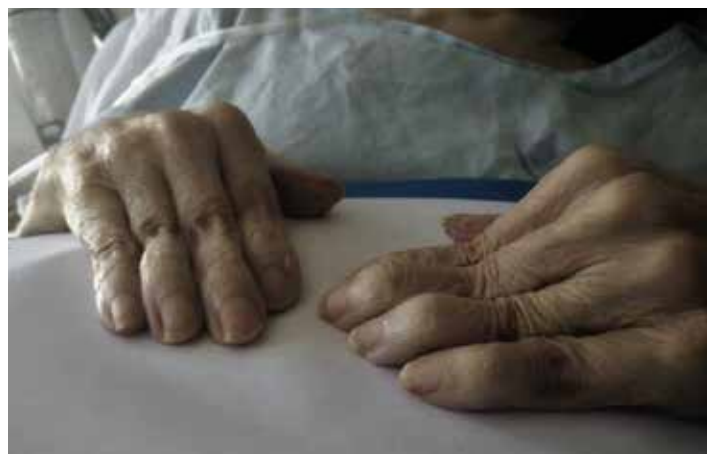

Figure #187. Swan neck fingers.

#189 - Case Report

A CASE OF TYPE 3 AUTOIMMUNE POLYGLANDULAR SYNDROME

Cristiana Fernandes, João Abreu, Carolina Veiga, Carina Silva, Sofia Barroso, Carlos Oliveira

Hospital Santa Maria Maior - Barcelos, Barcelos, Portugal

Introduction

Autoimmune polyglandular syndromes (APSs) are characterized by the association of two or more autoimmune endocrine diseases. Depending on the authors, they can be divided into three or four types. Type 3 APS is characterized by the presence of autoimmune thyroid disorders (AITD) associated with other autoimmune diseases (AIDs), without involvement of the adrenal gland. AITD is the most prevalent autoimmune disease and, as such, type 3 SPA is the most frequent type. APSs are more prevalent in middle aged women. The authors present a case of type 3 APS that associates vitiligo, alopecia,

#187 - Medical Image

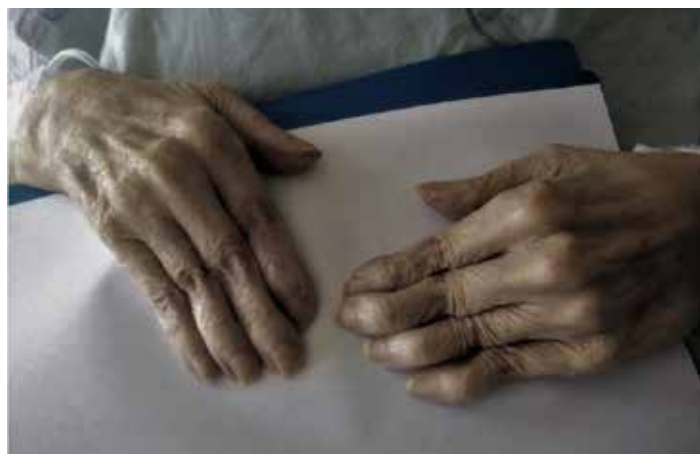SWAN NECK FINGERS

Diogo Santos, Graça Lérias, Isabel Madruga

Hospital de Egas Moniz - Centro Hospitalar Lisboa Ocidental, Lisbon, Portugal

Clinical summary

A 74 year old bedridden woman with prior history of degenerative osteoarthropathy with multiple osteoporotic vertebral fractures, was admitted for left lower lobe pneumonia; she presented with extensive bilateral finger deformities in a swan neck shape while still maintaining full usage of fine finger movements, including frequent usage of her mobile phone equipped with an analog keyboard with small input buttons.



Hashimoto's thyroiditis, pernicious anemia and autoimmune hemolytic anemia. Diagnoses were made sequentially over several years. Vitiligo and alopecia were the first diagnoses to be established.

Case description

An 80-year-old woman, with a history of arterial hypertension, hypothyroidism, heart failure, vitiligo and alopecia, was referred to the emergency room by her family doctor for easy fatigue and anorexia, associated with severe anemia (hemoglobin 5 g/dL). She was admitted for further study of the anemia, which led to the diagnosis of autoimmune hemolytic anemia and pernicious anemia (severe vitamin B12 deficiency, with positive antibodies to the gastric parietal cell and intrinsic anti-factor). After the initiation of corticotherapy and presented major improvement. Considering the history of hypothyroidism, the autoimmune thyroiditis study was carried out, which allowed the diagnosis of Hashimoto's thyroiditis. The patient didn't show signs of further autoimmune diseases.

Discussion

Individuals with an AID are at greater risk than the general population from developing other AIDs. By the time of the diagnosis of the first AID, usually there aren't any other autoimmune diseases, it may take several years between different diagnoses. As such, after the diagnosis of an APS, the sequential development of other AIDs is expected. The morbimortality of type 3 APS is determined by the individual components of the syndrome. APSs have a broad spectrum of presentation and may be clinically asymptomatic. The classification of APS is dynamic and may change over time, according to the appearance of new endocrine dysfunctions or other non-endocrine AIDs. However, the need for screening with serial assays of antibodies remains controversial.

#215 - Abstract

EMERGING PD-1 AND PD-1L INHIBITORS-ASSOCIATED MYOPATHY WITH CHARACTERISTIC HISTOPATHOLOGICAL PATTERN

Ana Matas¹, Albert Selva O'Callaghan², Joan Padrosa¹, Sergio Prieto¹, Josep Maria Grau¹, Jose César Milisenda¹

¹ Hospital Clínic de Barcelona, Barcelona, Spain

² Hospital Universitario Vall d'Hebron, Barcelona, Spain

Background

Drug-induced myopathy is among the most common causes of muscle disease. Recently, an association between programmed death-1 (PD-1) inhibitors, increasingly used as a cancer immunotherapy, and immune-related adverse events affecting the muscle has been described. Here, we describe the clinical and pathological findings of six unrelated patients with PD-1 and PD-1L inhibitors-associated myopathy.

Methods

We did a retrospective study, analyzing our database from January 2017 to July 2018, where 317 muscle biopsies for diagnostic purposes were performed.

Two myology experts oversaw care of patients and performed and analyzed muscle biopsies. Muscle biopsies were frozen in cooled isopentane, cryostat sectioned and stained and reacted routinely.

Results

We identified 6 patients receiving anti-PD-1 or PD-1L inhibitors consulting for muscle weakness, asthenia, myasthenic syndrome-like or other muscle related-symptoms with biopsy-proven inflammatory myopathies and one of them had myocarditis associated.

Muscle biopsy showed in most of the cases a marked phenomenon of necrosis, macrophagy and muscle regeneration with perivascular inflammatory infiltrates with a large component of macrophagic cells. Also, a tendency to perifascicular atrophy was noticed. The expression of MHC class I antigens predominated

in the perifascicular zones. We observed raised muscle enzymes only in 3 patients.

Conclusion

Although further information is required to understand the wide spectrum of immune-related adverse events involving the muscle during or after treatment with anti-PD-1 inhibitors, our studies have shown the importance of performing a muscle biopsy in those patients presenting clinical features of muscle involvement. In addition, the pathological picture seems to be quite different from other inflammatory myopathies, with a prominent aggregate of histocytes. Furthermore, a similar histological pattern could be observed in the myocardic biopsy of one patient.

#240 - Abstract

PLATELET COUNT, HEMOGLOBIN AND ALBUMIN LEVEL :DO THEY REFLECT THE INFLAMMATION DEGREE ?

Maissa Abbes, Maroua Slouma, Rim Dhahri, Leila Metoui, Imen Gharsallah, Bassem Louzir

Military hospital of tunis, Tunis, Tunisia

Background

C-reactive protein (CRP) and erythrocyte sedimentation rate (ESR) are the main inflammatory biomarkers used in assessment of the disease activity in different inflammatory diseases such as rheumatoid arthritis(RA). It has been shown recently that other serum biomarkers such as platelet count (PC), hemoglobin (Hb) and albumin level may reflect the inflammatory status. The aim of this study was to demonstrate the correlation between PC, Hb, albumin and clinical activity disease.

Methods

We conducted a cross sectional study including 92 patients with RA according to ACR EULAR 2010 criteria. We excluded patients having infection at the time of the study.

For each patient we measured the following biological markers: Hb (g/dL), PC (10/mL), ESR (mm/H1), CRP (mg/L) and albumin (g/L). Disease activity was assessed by the disease activity score (DAS VS).

Results

The mean age was 54±13 years. There were 72 females and 20 males (sex ratio : 3.6). The average age of the onset of the disease was 44±13 years. The mean disease duration was 101 months [1-444]. The mean disease activity score (DAS28) was 5.03 ranging from 1.95 to 8. Eighty percent of our patients (n=74) had active RA.

The mean ESR rate, CRP level, PC, Hb and albumin were respectively: 42.2mm/h1, 26.6mg/L, 296 (10/mL), 12.1g/dL and 33.6g/L.

The mean neutrophil lymphocyte ratio (NLR) and platelet lymphocyte ratio (PLR) were respectively: 3.1±2.1 and 174.5±89.8.

There was a positive correlation between PC and CRP ($r=0.31$, $p=0.003$). However, a negative correlation has been noted between Hb and ESR ($r=-0.31$, $p=0.004$).

A negative correlation was found between albumin and the main inflammation biomarkers ESR and CRP respectively: ($r=-0.27$, $p=0.019$) and ($r=-0.37$, $p=0.001$). Furthermore, we found a negative correlation between DAS28 and following biomarkers: Hb ($r=-0.28$, $p=0.016$) and albumin ($r=-0.37$, $p=0.004$). Additionally, the mean NLR and PLR were significantly higher in patients with active disease (1.5 versus 3.2, $p=0.000$) and (114 versus 182, $p=0.000$).

Conclusion

Among the different serum biomarkers, Hb and albumin concentration seems to be well correlated with the DAS28 in RA. However, platelet count increases with inflammation without a significant correlation with the activity score. In addition, a high NLR and PLR is associated with an active disease as it was showed in a recent study¹.

New prospective studies including larger study groups are required to verify the findings of the present study.

Reference:

1. Tekeoğlu İ, Gürol G, Harman H, Karakeçe E, Çiftçi İH. Overlooked hemato

#241 - Abstract

THE DIAGNOSIS DELAY IN RHEUMATOID ARTHRITIS PATIENTS.

Maïssa Abbes, Maroua Slouma, Rim Dhahri, Leila Metoui, Imen Gharsallah, Bassem Louzir

Military Hospital of Tunisi, Tunisi, Tunisia

Background

Many progress have been achieved in rheumatoid arthritis (RA) treatment and prognosis. However, many of RA patients still undergo delays in diagnosis and therefore the treatment initiation. The aim of this study was to estimate the diagnosis delay time in RA patients and identify the main factors associated with it.

Methods

We conducted a cross sectional study including 92 patients with RA according to ACR EULAR 2010 criteria. The diagnosis delay was defined by the time between symptoms onset and the diagnosis. The main factors of delay which were analyzed were: diagnosis age, gender, body mass index (BMI), the onset form, the disease activity score (DASVs) and the inflammatory biomarkers: C-reactive protein (CRP) and erythrocyte sedimentation rate (ESR). Statistical Package for Social Sciences (SPSS) was used for analysis.

Results

The mean age was 54 ± 13 years. There were 72 females and 20 males (sex ratio : 3.6). Seventy seven of our patients had

polyarticular onset, 21% presented with oligoarthritis and only 1% showed a monoarthritis. The mean disease duration was 101 months [1-444]. The mean disease activity score (DAS28) was 5.03 ranging from 1.95 to 8. Eighty percent of our patients ($n=74$) had active RA.

The weighted average of median lag time from the onset of symptoms to diagnosis was 48 ± 60.3 months with a range of 1- 240 months. There were no significant correlation between diagnosis delay and gender ($p=0.33$), age at onset ($p=0.19$), BMI ($p=0.73$), the onset form ($p=0.7$), DAS28 ($p=0.56$), CRP ($p=0.24$) and ESR ($p=0.32$).

The mean time to diagnosis was more delayed in patients with positive anti citrullinated protein (52 vs 45 months; $p=0.7$) and in those with positive rheumatoid factor (53.5 vs 46 months, $p=0.6$). Moreover, the diagnosis delay was longer in patients with radiographic hand joint erosions (51.6 vs 30 months, $p=0.11$).

Conclusion

The diagnosis of RA after the onset of symptoms is delayed, and therefore, the objective of starting treatment early is not achieved in most of the cases. Our study showed that positive rheumatoid factor and anti-citrullinated protein as well as radiographic hand joint erosions may be associated with a delay in the diagnosis of RA. Similar results have been found in a recent study¹.

New prospective studies including larger study groups are required to report the main factors associated with the delay.

Reference:

1. Barnabe C, Xiong J, Pope JE, Boire G, Hitchon C and al. Factors associated with time to diagnosis in early rheumatoid arthritis. *Rheumatol Int.* 2014 Jan; **34**(1):85-92.

#253 - Case Report

GIANT CELL ARTERITIS - A CASE REPORT

Maria João Marelo Tavares, Filipa Gonçalves, Jorge Cotter

Hospital Senhora da Oliveira - Guimarães, Guimarães, Portugal

Introduction

Giant cell arteritis is a segmental vasculitis characterized by a histopathological pattern typical of medium-caliber artery infiltration. More common in women than men. The diagnosis should be early in order for a treatment to be instituted as early as possible

Case description

A 60-year-old woman applied to the Emergency Department (ED) for incapacitating headache (8/10 pain scale) with about 1 month of evolution. Denied vision changes, photophobia, tinnitus, nausea or vomiting. No changes in muscle strength. No knowledge of fever. As a personal history we highlight hypothyroidism under levothyroxine; 1 miscarriage in the second trimester during the first pregnancy.

At the examination on the ED she was a body temperature of 38.1°C . She was conscious, oriented and cooperative, with

no neurological alterations. She presented scoring pain to palpation of the temporal arteries bilaterally. Cardiopulmonary auscultation did not present alterations. The patient did not tolerate orthostatism because of the aggravation of headache. She performed cerebral angioTAC that revealed no alterations. From the complementary study performed to highlight: PCR 65.5mg/L; VS 81mm; ANA, ANCA, Anti DNAs negative, without complement consumption; Anti-cardiolipins, anti-B2 glycoprotein and lupus negative anticoagulant. Protein C, S, antithrombin III and factor V Leiden negative. On suspicion of giant cell arteritis he underwent biopsy of the temporal artery and started treatment with prednisolone 1mg/kg/day with resolution of headache. It was excluded the involvement of great vessels due to vasculitis. It was excluded ocular involvement. Histological findings of the temporal artery biopsy fragment confirmed the initial suspicion: "The wall presents transmural involvement by a chronic lymphohistiocytic inflammatory process, consisting of small lymphocytes and cells of the histiocytic-macrophagic line with lesion and focal destruction of the internal elastic lamina... compatible with the clinical diagnosis of temporal giant cell arteritis..." At the moment she is in follow-up. She presents good clinical evolution with maintenance of corticoterapia. Introduction of biological in the short term is considered.

Discussion

Pathology with broad sintomatology (fever, headache, vision changes) and whose diagnosis may be difficult. The earlier suspicion the attempt terapautic institution in order to avoid complications such as blindness

#266 - Case Report

NEVER LOSE THE TRACE

Cristina Ausín, Victoria Sampedro, María Toledano, Eduardo Fernández, Blanca Pinilla, Maria Victoria Villalba
Hospital General Universitario Gregorio Marañón, Madrid, Spain

Introduction

Kikuchi-Fujimoto disease (KFD) was originally described in young women and is a rare, benign condition of unknown cause characterized by cervical lymphadenopathy and fever.

Histopathology of the involved lymph nodes differentiates KFD from several more serious conditions. No effective treatment has been established for it, nevertheless the signs and symptoms usually resolve in a few months.

Although not very frequently, there have been cases associated to Systemic Lupus Erythematosus (SLE), a fact that changes the prognosis and treatment notably.

Case description

We present the case of a 29-year-old woman who was initially admitted to the hospital because of an adenopathic conglomerate associated to fever, and after ruling out other causes she was finally diagnosed with an adenopathic biopsy of KFD. She also

presented mild leukopenia, and positive antinuclear antibodies (ANA). Since she didn't present any symptoms suggestive of SLE, no specific treatment was initiated. She appeared at the emergency room (ER) a year later after a miscarriage, referring Raynaud phenomenon, oral ulcers, arthralgia and dry mouth. She was then derived to our autoimmune disease consultation, where all the analysis were repeated, with positive results for ANA, anti Ro, anti RNP and anti Sm autoantibodies. Despite of not meeting all the classificatory criteria for SLE, due to the high suspicion, treatment with hydroxychloroquine was initiated. A month later, the patient went to the ER because of chest pain, with diagnosis of acute pericarditis, making necessary to start treatment with pulses of methylprednisolone followed by oral prednisone and azathioprine. Moreover, a gammagraphy of the salivary glands was performed with pathologic result, leading to a probably diagnosis of secondary Sjögren syndrome.

Discussion

KFD is a benign disorder that mainly affects young women, characterized by cervical lymphadenopathy associated with fever. The diagnosis is made by lymph node biopsy, and it is self-limited in the majority of patients, although recurrences have been reported, as well as SLE associations.

We present the case of a young woman with an initial diagnosis of KFD who loses follow-up and appears a year later with new symptoms that raise the suspicion of an underlying autoimmune disease. The specific autoantibodies she turns positive are specially important due to their association with several organ damage, as she develops later an acute pericarditis with the eventual need for immunosuppressive therapy.

#271 - Case Report

WHEN SIMPLE TURNS INTO A ZEBRA

Rita Sousa Gameiro, Rodolfo Gomes, Bárbara Picado, Fernando Martos Gonçalves
Hospital Beatriz Ângelo, Lisboa, Portugal

Introduction

Systemic lupus erythematosus (SLE) is a heterogeneous autoimmune disease with a wide range of clinical and serological manifestations that can affect any organ. Establishing the diagnosis can be a challenge, altering treatment and prognosis.

Case description

The authors present the case of a 40-year-old-woman with personal history of hypothyroidism and infertility and familiar history of male and female infertility, hemorrhagic stroke and intestinal cancer at young age. The patient presented to the emergency with a month history of rhinorrhea, productive cough, aggravated fatigability, palpitations, anorexia and weight loss. She also referred fever and myalgia in the last 2 weeks. At physical exam, she was pale, tachycardic and had crepitant rales on lower half of hemithorax bilaterally. Blood work showed elevated

inflammatory markers, normocytic normochromic anemia, elevated LDH and thrombocytosis. Chest radiograph identified an interstitial infiltrate on left lower third hemithorax and right lung base. Influenza A and B antigens were negative. We admitted pneumonia and discharged the patient on antibiotics. A week later, she was reevaluated, claiming progressive worsening of symptoms with functional incapacity. Her blood work showed aggravated anemia, high reticulocytosis, elevated LDH, hyperbilirubinemia, lowhaptoglobin and Coombs test positive for IgG, IgM, C3d and PAI. We then admitted the diagnosis of warm autoimmune hemolytic anemia and the patient was hospitalized. She followed a five-day course of methylprednisolone 1 g, then altered to prednisolone 1 mg/kg/day with clinical and analytical improvement. Regarding investigation, we identified positive ANA with a homogeneous pattern and high titer, positive antidsDNA antibody, positive anticardiolipin IgG and IgM antibodies and positive anti-TPO. Thoracic CT had extensive parenchyma alterations, including ground glass opacification, aspects of pulmonary fibrosis, septal thickening and bronchiectasis. Our patient fulfilled criteria for SLE, probable secondary antiphospholipid syndrome and autoimmune thyroiditis. She was also started on hydroxychloroquine and discharged on day 7. One month later, she maintained clinical and analytical improvement. Thiopurine methyltransferase mutation was negative, therefore azathioprine was started.

Discussion

SLE is an uncommon diagnosis, reinforcing the need for high clinical suspicion, as shown in the clinical case presented.

#273 - Case Report

ANCA-ASSOCIATED VASCULITIS WITH ENDOCARDIAL, MUCOCUTANEOUS AND CENTRAL NERVOUS SYSTEM INVOLVEMENT: CASE REPORT

Daniela Saavedra Becerril, Enrique José Antonio Robiou Vivero, Dora Luisa Covarrubias Flores, Victor Hugo Rosales Salyano, María Virgilia Soto Abraham, Anabel Ávila Lara
Hospital General de México, Mexico City, Mexico

Introduction

Valvular involvement in ANCA-associated vasculitis is rare. We report the case of a 44 year old man with acute systemic vasculitis of this type, following acute kidney injury and resulting in aortic valve replacement due to endocardial involvement.

Case description

A 44 year old man, smoker, with a history of type-2 diabetes mellitus and acute kidney injury one month prior hospitalization. Earlier symptoms included weakness and maculopapular rash in limbs.

The man was admitted to the hospital after three days of severe upper abdominal pain accompanied by diarrhea, oliguria, fever, minimal effort dyspnea and peripheral edema. At this point,

emergency hemodialysis was necessary. Renal ultrasound showed normal kidney size with nonspecific chronic nephropathy. Tests revealed proteinuria 1710 mg daily, positive antineutrophil cytoplasmic antibodies (c-ANCA) 97.96, antinuclear antibodies (ANA) cytoplasmic pattern 1:40, low complement C3 and PCR 92.6.

Later on, the man presented dyspnea and diaphoresis together with oppressive chest pain. ECG suggested acute coronary syndrome and anti-ischemic therapy started. The patient received high dose bolus methylprednisolone and prednisone (1 mg/kg/day) following deterioration of the renal function. Tenckhoff catheter and peritoneal dialysis were required.

Double aortic lesion with predominance of regurgitation and aortic valve vegetation was confirmed by echocardiography. The valve was replaced and histopathology showed dystrophic valve calcification, blood culture were negative.

An urinary tract infection prevented treatment with immunosuppressants. The infection was treated with carbapenem antibiotics. Kidney biopsy revealed diffuse crescentic ANCA-associated glomerulonephritis which was initially treated by plasmapheresis. Vertigo and left pyramidal syndrome suggested a cardioembolic stroke around the middle brain artery which was confirmed by tomography. Statins, plaquet antiaggregation and anticoagulation drugs were administered before the patient was discharged voluntarily.

Discussion

Valvular involvement in ANCA-associated vasculitis is rare, accounting for ca. 6%. When accompanied by endocardial compromise, clinical manifestations often overlap with those of subacute bacterial endocarditis, for instance, vegetations and increased ANCA levels. A complete clinical approach with evaluation and follow-up of cardiovascular function is always recommended, providing early and adequate treatment and to preserve myocardial function.

#291 - Case Report

ERYTHEMA NODOSUM: AN ENTITY NOT TO FORGET

Mariana Gomes, Carolina Barros, Helena Freitas Luís, Bela Machado, Mariana Bilreiro, Maria Da Luz Brazão
Internal Medicine Department, Hospital Central do Funchal, Funchal, Portugal

Introduction

Erythema nodosum (EN) is the most frequent panniculitis, characterized by red and purplish subcutaneous nodules, usually limited to the extensor surface of the lower legs, with occasional spread to thighs or arms. EN does not ulcerate and usually resolves without atrophy or scarring. It presumed to be a late hypersensitivity reaction associated with drugs (including oral contraceptives and some antibiotics), infections, several systemic diseases like sarcoidosis and inflammatory bowel disease or

it may be idiopathic in a large of cases. EN is more common in young women and the diagnosis is clinical with biopsy reserved for atypical cases. Most cases of erythema nodosum are self-limited and require no treatment. Bed rest and leg elevation are generally recommended to reduce the discomfort. Nonsteroidal anti-inflammatory drugs are the first-line treatment for pain management.

Case description

A 43-year-old woman was admitted in the emergency department with a 1-week history of fever, sore throat, myalgia, arthralgia and multiple painful skin nodules. There was no gastrointestinal complaints such as diarrhea and abdominal pain. She was taking antibiotic without improvement. Physical examination revealed multiple erythematous, tender, papulo-nodular skin lesions over both legs and in the left arm compatible with erythema nodosum. Chest radiography showed no hilar mass and/or mediastinal enlargement. Laboratory tests revealed increased inflammatory parameters. The patient was discharged with symptomatic treatment with non-steroidal anti-inflammatory drugs and a etiological study was requested. She was advised to return in one week for re-evaluation.

Upon her return, there was new painful skin lesions and a second line treatment with oral corticoid and colchicine was chosen, with progressive improvement. After evaluation, highlight the increased titre of antistreptolysin O.

Discussion

Streptococcal pharyngitis is the most frequent etiology of EN all over the world. Development of EN 1 to 4 weeks after pharyngitis is a well-known phenomenon. However it is important to find out other underlying conditions which treatment is individualized. Therefore, when a patient with erythema nodosum is seen in primary care it is important for the diagnostic evaluation to consider a broad differential diagnosis to other panniculitides. For this reason, cutaneous and subcutaneous biopsy is recommended to confirm the diagnosis. In this case, the etiology was evident and the biopsy was not performed.

#297 - Case Report

FACIAL OEDEMA AND AN ORAL MUCOSA LESION: A RARE PRESENTATION OF SARCOIDOSIS

Filipe J. Machado, Ana Raquel Freitas

Centro Hospitalar Entre Douro e Vouga, Porto, Portugal

Introduction

Sarcoidosis is a multisystemic disease of unknown etiology characterized by the accumulation of T lymphocytes, mononuclear phagocytes and noncaseating granulomas in the affected tissues. The most frequent organ involved is the lung (90 percent of cases) and, in the head-and-neck region, salivary glands and cervical lymph nodes constitutes the most frequent locations. Oral

mucosa involvement as disease's first clinical manifestation is very uncommon with only few cases reported among the literature.

Case description

A 73-year-old male presented with history of a 7-month right hemifacial oedema with ulterior regression and reappearance on the left hemiface. He denied unintentional weight loss, anorexia, fever or night sweats. He also denied red or dry eyes, photosensitivity, genital or oral ulcers or arthralgias. Physical examination was remarkable for bilateral oral (jugal) mucosa tumefaction and for bilateral cervical adenopathy. Laboratory testing revealed an elevated erythrocyte sedimentation rate and a discrete hypercalcemia. Angiotensin converting enzyme was normal and urinary calcium also within normal range. The oral mucosa was biopsied and revealed epithelioid non caseous granulomas with occasional Giant Langhans cells. Also, a thoraco-abdominopelvic computerized tomography evidenced three mediastinal adenomegalies. Upper gastrointestinal endoscopy and colonoscopy were negative for signs of inflammatory bowel diseases.

Discussion

Systemic sarcoidosis is characterized by the formation of non-caseating granulomas in the affected tissues. Our case report presents a rare oral mucosa involvement as first presentation of this pathology. It purposes to raise the awareness about the importance of the diagnosis and its complex workup taht include the mandatory exclusion of possible alternative diagnoses.

#298 - Abstract

INCREASE OF LIVER ENZYMES A CAUSE OF METHOTREXATE (MT) WITHDRAWAL IN PATIENTS WITH EARLY RHEUMATOID ARTHRITIS (RA)

Galina Gridneva

V.A. Nasonova Research Institute, Moscow, Russia

Background

The increase of liver enzymes (LE) - Alanine transaminase (ALT) and Aspartate transaminase (AST) is the most frequent objective (measured) adverse drug reaction (ADR) in MT therapy.

Methods

To estimate the frequency of LE elevation in the therapy with MT were included 106 pts with RA (≤ 3 years), according to ACR/EULAR 2010 (DAS28 $> 3,2$), naïve to MT. 68% had body mass index (BMI) > 25 kg/m², 31% had obesity, 8% were smokers, 25% took glucocorticoids per os (maximum 8 mg of methylprednisolone). All pts were administered subcutaneous MT (SCMT) 10-15 mg/week as monotherapy, with 5 mg up-titration each 1-2 weeks (to max 30 mg/week) up to achieving the target (remission or minimum disease activity) or up to emergence of adverse reaction (AR). The follow-up period was 12 months. For AR prophylaxis folic acid

(min 5 mg/week) was administered at any day(s) except for the day of SCMT injection. Liver enzymes levels were monitored monthly. To establish the connection between liver enzymes elevation and SCMT, the Naranjo scale has been used.

Results

The cases of increase in LE (n=12) amounted to 25% of all registered ADRs. Most of all LE elevation cases (10 of 12) occurred during the first 3 months of treatment. Mean BMI was 27± kg/m², 3 (25%) were smokers, 5 (41%) were taking oral glucocorticoids. There was no correlation with MT dose.

ALT increase 1,2–1,5 times from the upper limit of the norm (ULN) in 4(8% of the total); ALT increase 1,6–3,0 ULN in 4(8% of the total); ALT increase 3,1–8,0 ULN in 6(13% of the total); ALT increase > 8,0 ULN in 1(2%). AST increase 1,2–1,5 ULN in 2(4% of the total); AST increase 1,6–3,0 ULN in 8(17% of the total); AST increase 3,1–8,0 ULN in 1(2% of the total); AST increase > 8,0 ULN in 0. When the increase in LE was due to the use of SCMT (points 5-9 on the Naranjo scale), the therapy was interrupted for 1-2 weeks before normalization of the LE level. Then the treatment was successfully continued in a smaller dose of SCMT. When the increase in LE was not due to the acceptance of SCMT (points 0-4 on the Naranjo scale), in 4 cases the LEs returned to normal within a week without any treatment or SCMT abolition.

Conclusion

With a single increase in liver enzymes, it may be sufficient to make a short-term break in the treatment. The question of the administration of anti-cytotoxic drugs, such as ursodeoxycholic acid should be addressed individually. The necessity for a short-term withdrawal of MT did not affect its therapeutic effect in the future.

#312 - Case Report

MYOPERICARDITIS AS MANIFESTATION OF ADULT STILL DISEASE.

Vicente David De La Rosa Valero, María Del Carmen Hernández Murciano, Elena Del Carmen Martínez Cánovas, Ignacio Iniesta-Pino Alcázar, Gabriel Puche Palao, Carlos Báguena Pérez-Crespo, Ana Martín Cascón, Mónica Martínez Martínez, Francisco Javier Hernández Felices, Lia Ferraro
Hospital General Universitario Reina Sofía De Murcia, Murcia, Spain

Introduction

Cardiac involvement isn't uncommon in systemic inflammatory diseases. When such diseases present with a cardiac manifestation, it's generally in the form of pericarditis, which is usually acute and recurrent.

We report a case of adult Still's disease (ASD) presenting clinically as acute myopericarditis.

Case description

A 25-years-old man without history of interest who was admitted for a 4-weeks fever, arthralgias on the elbows and wrists, left chest

pain with pleuritic features and dyspnea. The examination revealed cutaneous-mucosal pallor, tachypnea, latero-cervical adenopathies, systolic murmur, pericardial rub, hepatosplenomegaly, and bimaleolar edema. In laboratory tests, hemoglobin 8.3, leukocytes 30,000 (neutrophils 92%), platelets 465,000, prothrombin activity 55.9%, GOT 200, GPT 120, GGT 270, LDH 1.100 and troponin I 4. C reactive protein 250, ESR 97 and ferritin 33,000. Rheumatoid factor, ANA, extractable nuclear antigen, anti-nDNA, ANCA and antiphospholipids were negative. Serology, blood cultures, urocultures and Mantoux were negative. Blood smear without findings. Thyroid hormones, immunoglobulins and complement were normal. Arterial blood gas with partial respiratory failure. Electrocardiogram showed sinus tachycardia with negative T in V 3-6. In chest radiography, we could see global cardiomegaly and bilateral pleural effusion. Pleural fluid: exudate type, with bacilloscopy, cultures and cytology negatives. In thoracoabdominal CT, minimal pleuropericardial effusion, cardiomegaly and hepatomegaly. On echocardiogram, moderate pericardial effusion, left ventricular ejection fraction of the 50%, moderate mitral regurgitation. The presence of chest pain of pleuropericardial characteristics, physical examination and elevation of cardiac enzymes were compatible with myopericarditis. Treatment was started with NSAIDs and broad-spectrum antibiotics to cover infectious etiology. Given the joint presentation with fever, arthritis, liver dysfunction, leukocytosis, pleural effusion and visceromegaly, ASD was diagnosed according to the Yamaguchi criteria and intravenous corticosteroid boluses were started, followed by oral prednisone in a descending pattern. Progressive clinical, analytical, radiological (normal) and echocardiographic improvement (slight pericardial effusion, mild mitral regurgitation) were evidenced.

Discussion

ASD is a multisystem inflammatory disease of unknown etiology. The initial presentation form with pleuromyopericardial manifestations is infrequent.

#316 - Case Report

EOSINOPHILIC FASCIITIS: A MISDIAGNOSED CASE OF A RARE ENTITY

Vasileios Andrianesis, Anastasios Karamanakis, Matthew Katsaras, Maria Mylona

1st Department of Propaedeutic & Internal Medicine, Laiko General Hospital, Athens University Medical School, Athens, Greece

Introduction

Eosinophilic fasciitis (EF), also known as Shulman syndrome, is characterized by inflammation of the tough band of fibrous tissue beneath the skin (fascia). Inflammation is caused by the abnormal accumulation of certain white blood cells including eosinophils in the fascia, arms and leg, which are most often affected. EF leads to skin swelling and eventually skin induration. Most commonly middle-aged adults are affected. Herein we present an interesting case of a patient with a delayed diagnosis of EF.

Case description

A 59-year old Caucasian man, with an unremarkable medical history, was admitted to our clinic due to progressive worsening of painful bilateral arms and forearms swelling and skin thickening for the last three months, fatigue, weight loss and low grade fever. He was previously diagnosed with allergy and has been prescribed levocetirizine dihydrochloride without any clinical response. He was afebrile and physical examination was unremarkable apart from painful erythematous and thickened woody skin of his arms and forearms and positive Groove sign. He had no sclerodactily or Raynaud's phenomenon. Blood chemistry revealed eosinophilia (1500 eosinophils/uL), mildly elevated inflammation markers and polyclonal hypergammaglobulinemia. Upper arm magnetic resonance imaging revealed fascial thickening. The patient's full body CT scan and heart echo revealed no underlying malignancy or infiltration respectively. No pathogen was isolated from his blood and urine cultures, TSH, HIV, HBV, HCV, procalcitonin, ANA, C3, C4, anti Scl 70, anti Jo-1 were also negative. Vitamin D levels, CPK and LDH were normal. The patient underwent skin, muscle and fascia biopsy, which revealed EF and was treated with methylprednisolone 1g/day for three consecutive days showing rapid clinical response. He was discharged with methylprednisolone 24mg x1 per os and methotrexate 12.5 mg weekly.

Discussion

EF is a rare clinical entity and can be a true diagnostic challenge to a physician with low clinical suspicion of the disorder. It is believed to be a variant of systemic sclerosis. The specific symptoms and severity of the disorder can vary from one individual to another, while the exact cause of it is unknown. Delayed diagnosis can lead to significant disability.

#324 - Case Report

FUNGAL ENDOCARDITIS IN A PATIENT TREATED WITH INFlixIMAB – A CASE OF INVASIVE ASPERGILLOSIS

Joana Azevedo Carvalho, Raquel Maia, Marisa Neves, Bruno Grima, José Delgado Alves

Prof. Dr. Fernando Fonseca Hospital, Amadora, Portugal

Introduction

Opportunistic infections have been reported in patients treated with anti-TNF α . Invasive aspergillosis is a rare fungal infection that is commonly associated with risk factors such as neutropenia or drugs and conditions that lead to chronically impaired cellular immune responses.

Case description

We report a case of a 47-year-old female patient with seronegative spondyloarthropathy treated with Infliximab and low-dose corticosteroids. The patient presented fever, dyspnoea and purulent cough. X-ray revealed a perihilar nodular hypotransparency in the left lung. The diagnosis of pneumoniae was done and she was

treated with a β -lactam antibiotic. The infliximab administration was deferred until nine days after clinical recovery. Fourteen days after drug administration, she was admitted with a frontal headache, dysarthria and cognitive slowing for 24 hours. CT-scan showed a subcortical hematoma in the left parietal region. There was a rapid neurological recovery and there were not identified any risk factors to haemorrhagic stroke. The patient X-ray maintained the same structural alteration of lung parenchyma and the CT-scan revealed a cavitary pulmonary nodule which was suggestive of aspergilloma. Bronchoalveolar lavage cytology showed *Aspergillus* spp. Voriconazole was started and, after 1 month of treatment, the patient was readmitted with left facial palsy associated with hemiparesis and dysarthria. On examination an abnormal systolic heart murmur, Janeway lesions and Osler's nodes were found. Laboratory evaluation revealed leucocytosis and elevated C-reactive protein. A severe right middle cerebral artery stroke was revealed on the CT-scan. Transoesophageal echocardiogram showed a large mitral valve vegetation. The diagnosis of fungal endocarditis with cerebral embolization was made.

Discussion

Fungal infections are challenging due to an indolent natural history and diagnosis infrequency. Despite of being crucial in the treatment of autoimmune diseases, immunosuppressive drugs increase the risk of fungal infections. It is extremely important to consider this type of infection in immunosuppressed patients.

#336 - Abstract

THE ROLE OF PET/CT IN THE MANAGEMENT OF GIANT CELL ARTERITIS

Alessandro Croce, Ramona Bonometti, Daniele Soddu, Mattia Bellan, Erinda Puta, Pierpaolo Sainaghi, Mario Pirisi

Ospedale Maggiore della Carità, Novara, Italy

Background

Giant cell arteritis (GCA) is a large vessel vasculitis that affects the aorta and/or its major branches including the superficial temporal artery. Together to cranial symptoms such as headache and visual disturbance extra cranial manifestations have been widely reported, sometimes as unique clinical presentation. Several imaging modalities are available to evaluate aortic involvement including fluorodeoxyglucose (FDG) positron emission tomography (PET), however there are few reports that analyzed the impact of the findings of this advanced imaging in predicting outcomes of the disease.

Methods

We retrospectively reviewed all the clinical records of patients receiving a diagnosis of large vessel vasculitis from 1st January 2010 to 1st January 2016 at a tertiary immunorheumatology clinic of a university Hospital, who underwent a PET. Clinical, laboratory, and imaging data were collected. Non-parametric analysis was performed.

Results

We recruited 19 patients (10 females, 52.6%). The median age was 74.0 [65.5-76.0]; at the diagnosis, the median erythrocyte sedimentation rate (ESR) was 65.5 [49.0-86.0], while C-reactive protein (CRP) was 8.5 [5.5-14.0]. 12 patients showed a typical cranial GCA (63.2%), while 7 (36.8%) were diagnosed with extracranial GCA. The two groups were comparable at diagnosis for age, gender, median ESR and CRP. Interestingly, the PET was significant for aortitis not only in the 7 patients with extracranial involvement, but also in 7/12 patients with cranial GCA (58.3%). Along a median follow-up of 15 months [4.5-26.5], 4 relapses were reported. Notably, all the relapsers were males and showed both aortic and cranial involvement. In a multivariate model, male gender was the only predictor of relapse ($p=0.02$), while age at onset, clinical subset (cranial vs. extracranial) and steroid dose did not fit the model.

Conclusion

The use of PET in GCA is relevant in the assessment of extension of disease since a significant number of patients without cranial symptoms in the end resulted to have large vessel involvement. In addition, PET is useful in identifying patients with cranial involvement that have also aortic inflammation since they seem to have worse prognosis.

#371 - Medical Image

IMAGES AND DIAGNOSIS OF IDIOPATHIC THROMBOCYTOPENIC PURPURA (ITP) AT THE EMERGENCY DEPARTMENT

Ana Oliveira Monteiro, Inês Branco Ferreira, Filipe Pinheiro, Delfim Duarte, Jorge Almeida
Centro Hospitalar de São João, Porto, Portugal

Clinical summary

ITP is an autoimmune disorder mediated by antiplatelet autoantibodies that cause platelet destruction and thrombocytopenia. A previously healthy 72-year-old woman was admitted at the emergency department reporting a sudden onset of metrorrhagia and purpuric injuries and hemorrhagic blisters of the oral cavity, ecchymosis on the face, on the left costal grid, and inner thigh. She was hemodynamically stable. She denied trauma or the use of any drug or substance. Laboratory tests revealed severe thrombocytopenia (platelets $<10,000/\mu\text{L}$) without anemia or coagulation changes. HIV and HCV tests were normal. The peripheral blood smear revealed the presence of rare normal morphological platelets. Abdominal ultrasound excluded hepatomegaly or splenomegaly. Systemic corticotherapy was initiated.

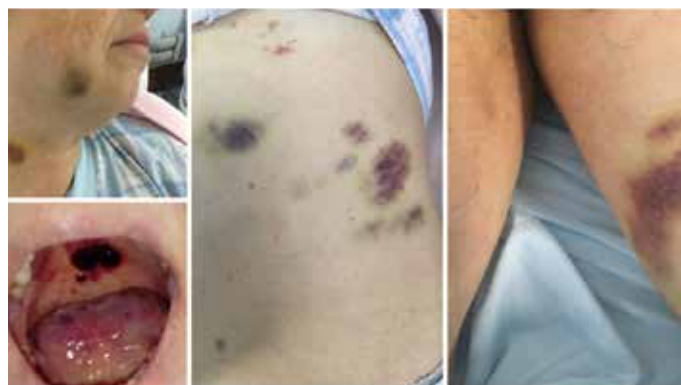

Figure #371.

#373 - Abstract

ANTI-RO/SSA POSITIVITY, ANTI-AQUAPORIN4 ANTIBODIES AND CENTRAL NERVOUS SYSTEM INVOLVEMENT: A RETROSPECTIVE STUDY ON A CONTROVERSIAL CORRELATION

Erika Zecca¹, Bellan Mattia^{2,1}, Daniele Soddu¹, Domizia Vecchio², Alessandro Croce³, Roberta Pedrazzoli¹, Cristoforo Comi², Mario Pirisi^{2,3}, Pier Paolo Sainaghi^{2,3}

¹ Internal Medicine Division, Immunorheumatology Unit, A.O.U. Maggiore della carità, Novara, Novara, Italy

² Department of Translational Medicine, Università del Piemonte Orientale - UPO, Novara, Italy

³ Internal Medicine Division, Immunorheumatology Unit, A.O.U. Maggiore della carità, Novara, Novara, Italy

Background

Different neurological manifestations have been observed in 20-25% of patients affected by Sjögren's syndrome. Among them, CNS demyelinating diseases, Neuromyelitis optica (NMO) and NMO spectrum disorders (NMOSD) with anti-aquaporin4 antibodies (anti-AQP4) positivity have been described.

The aim of the present study was to assess the clinical characteristics and seroimmunological correlations in patients with Ro-SSA antibodies and Central and peripheral nervous system (CNS and PNS) involvement.

Methods

We retrospectively reviewed clinical records, laboratory and Magnetic Resonance Imaging (MRI) reports of patients followed-up at a tertiary level immunorheumatology and neuroimmunology clinic.

We included patients showing an anti-SSA antibodies positivity and concomitant neurological symptoms at diagnosis.

We excluded patients fulfilling SLICC criteria for SLE. We recorded clinical and laboratory and MRI data for all patients.

Results

Out of 9598 clinical records reviewed, we identified 511 patients with anti Ro/SSA positivity. 11 patients had prevalent neurological

manifestations. 8 (72.7%) patients were women. The median age was 56 [IQR 31] years. CNS involvement was the main clinical feature in 7 patients (63.6%); 3 of them (27.3%) also had PNS manifestations. 4 patients showed exclusively PNS involvement. 3 subjects fulfilled criteria for SS while 8 patients were classified as undifferentiated connective tissue disease. 7 patients underwent spinal tap which reported inflammatory alterations (high levels of CSF proteins in 2 subjects and oligoclonal bands in 4 patients). Median Erythrocyte sedimentation rate (ESR) was 12 mm/h [IQR 18] while median C- Reactive protein was 0.34 mg/dL [IQR 0.32]. There was not complement deficiency in any patient. With regard to the tested autoantibodies, 2 subjects showed anti-La positivity. Out of the 4 patients tested for anti-AQP4 none was positive, even if 2 patients had NMOSD.

Conclusion

Anti-SSA positive may show a wide spectrum of neurological manifestations; CNS involvement was not associated to anti-AQP4 positivity in our cohort, even in patients with NMO/NMOSD. Further investigations are required to better disclose this association and to search for novel autoantibodies.

#374 - Case Report

ANCA MPO VASCULITIS WITH ENDOCARDIAL INVOLVEMENT OR INFECTIVE ENDOCARDITIS WITH IMMUNOLOGICAL PHENOMENA? – A CASE REPORT.

Andreia Filipa Tavares, Alexandra Castro
CHEDV, Santa Maria Da Feira, Portugal

Introduction

In infective endocarditis (IE), immunological phenomena can occur and trigger vasculitis of small vessels, similar to what happens in idiopathic ANCA vasculitis. Similarly, the latter can reach any organ in the human body, and the endocardium may also be affected. Thus, both the definitive diagnosis and the treatment to be implemented can become a real challenge.

Case description

An autonomous, 78-year-old woman, with a history of ischemic stroke on May 2018. Admitted on July 2018 by constitutional syndrome (asthenia, anorexia and weight loss), with progressive dependence on activities of daily living (ADL) and uncontrollable vomiting. Initial objective examination included: grade II/VI aortic systolic murmur and necrosis of the distal third of the left toe. He was afebrile and hemodynamically stable.

The analytical study showed: hemoglobin 9.8 g/dl, creatinine 1.8mg/dl, sedimentation rate > 120 mm/h, C-reactive protein 180 mg/dl, urinary sediment with leukoerythrocyturia and proteinuria (quantified 800 mg/24h). Computerized axial tomography showed discrete bilateral pulmonary infiltrates. Upper gastrointestinal endoscopy and arterial and venous lower limb ultrasound were

normal. 3 blood cultures (BC) and urine culture were negative. The complementary study showed: ANCA MPO positive, with remaining autoimmunity and virus negative. The transesophageal echocardiogram showed: echogenic, mobile structure at the aortic cusp, with moderate aortic insufficiency. She started prednisolone at a dose of 60mg/day and antibiotic therapy with ceftriaxone and gentamicin. Excluded distant embolization and other rare infectious causes of endocarditis. There was a rapid improvement, with progressive gain in autonomy in ADL and normalization of inflammatory markers and renal function in about 3 days. She repeated echocardiogram without evidence of vegetation. Given the response to the treatment, the ANCA MPO vasculitis with endocardial involvement was assumed to be the most likely diagnosis. Therefore, in the outpatient clinic, it started cyclophosphamide and weaned from corticoid, presenting a good clinical evolution.

Discussion

This case tries to demonstrate the difficulty in establishing a definitive diagnosis between two distinct, unusual nosologic entities, which present a similar clinical spectrum and multiorgan damage.

#380 - Case Report

A 58-YEAR-OLD WOMAN WITH RAPIDLY PROGRESSIVE DYSPNEA AND SKIN LESIONS.

María Del Carmen Hernandez Murciano, Elena Del Carmen Martínez Cánovas, Ignacio Iniesta-Pino Alcazar, Vicente David De La Rosa Valero, Gabriel Puche Palao, Carlos Baguena Perez-Crespo, Ana Martin Cascon, Monica Martinez Martinez, Francisco Javier Hernandez Felices, Rocio Gonzalez Molina
Reina Sofia General Hospital, Murcia, Spain

Introduction

Dermatomyositis is an idiopathic inflammatory myopathy with a variable clinical spectrum. In a low percentage of patients, which has been described between 2 and 18%, the cutaneous manifestations can develop with absence or minimal expression of muscular disease, this group is called dermatomyositis sine myositis or amyopathic dermatomyositis. In recent years, a variety of myositis-specific antibodies have been identified, including anti-MDA5.

Case description

A 58-year-old woman, without known medical history, was admitted to the service of infectious diseases due to rapidly progressive dyspnea with desaturation with exertion, dry cough and low-grade fever for one week. On examination, stable vital signs, 91% oxygen saturation and erythematous lesions on the back and palms of the hands that she had related to work efforts. Chest X-ray and thoracic CT showed pulmonary infiltrates in bases with air bronchogram. Respiratory symptoms, skin lesions and radiological findings led us to a dermatomyositis. However,

broad-spectrum antibiotics and corticosteroids were started until confirmation. Negative microbiological tests. ANA 1/80, anti-DNA -, anti-Ro +, anti-MDA5 +, rest of negative autoimmunity. Negative muscle enzymes. Electromyography without myopathy data, respiratory tests with severe mixed pattern. No occult neoplasia was found. She was diagnosed of amyopathic anti-MDA5 dermatomyositis with associated interstitial lung disease. Treatment was started with pulses of corticosteroids (1g daily), tacrolimus and cyclophosphamide with improvement of the clinic. Months later, she returned to the intensive care unit due to acute respiratory failure, as complications presented sepsis of probable respiratory origin and pneumomediastinum. Finally, she died four months after the diagnosis was done.

Discussion

Anti-MDA5 antibodies are associated with a amyopathic dermatomyositis, rapidly progressive interstitial lung disease, early mortality and poor prognosis.

#387 - Case Report

POLYGLANDULAR SYNDROME - A FAMILY HERITAGE

Joel Pinto, Paulo Almeida, Flávio Godinho, Daniela Meireles, Fani Ribeiro, Ana Araújo

Centro Hospitalar do Baixo Vouga, Aveiro, Portugal

Introduction

Polyglandular syndromes (PGS) are an association of at least two autoimmune pathologies, one of which is endocrine. They are rare and may be divided into 3 groups, of which type 3 is distinguished by the absence of adrenal involvement.

Case description

The authors present the case of a 39-year-old female, with no pathological history, who gets to the emergency department after detection of severe anemia in routine blood tests. She was complaining of asthenia and anorexia since the past 2 months, with no weight or blood loss. Her hemoglobin was normal 8 months before.

At physical examination she presented skin pallor, no adenopathy or organomegalies and normal rectal examination. Blood tests revealed macrocytic anemia with 5.4 g/dL of hemoglobin, mean corpuscular volume of 134fL, lactate dehydrogenase of 7278 U/L, vitamin B12 deficiency (91 pg/mL), normal ferritin and folic acid and negative viral serologies. Peripheral blood smear showed anisopoikilocytosis, macrocytosis, rare tear red blood cells and hypersegmentated neutrophils. Abdominal ultrasound and chest X-ray were normal. She received a transfusion of 2 units of red blood cells and supplementation with parenteral cyanocobalamin, being discharged for internal medicine consultation.

In the presence of megaloblastic anemia, the study was complemented with anti-intrinsic factor and anti-parietal gastric cell antibodies, the latter being positive. The thyroid function was

normal but anti-thyroglobulin and anti-peroxidase antibodies were positive. The association of pernicious anemia with autoimmune thyroiditis defined the diagnosis of type 3b PGS. The patient maintained monthly intramuscular vitamin B12 treatment, presenting progressive normalization of hemoglobin. A review of the family history allowed the identification of pernicious anemia diagnosis in patient's mother, which was later found to also be included in a type 3b PGS.

Discussion

Type 3 PGS is often observed in people of the same family and is associated with HLA class II genes mutations. It has an autosomal dominant inheritance pattern, with incomplete penetrance. The authors point out the importance of screening other autoimmune pathologies when the diagnosis of pernicious anemia is done. In this case, a detailed clinical history also allowed the identification of a second case of this syndrome in the same family.

#393 - Abstract

THE DIVERSE FACE OF FAMILIAL MEDITERRANEAN FEVER (FMF) IN GREECE: THE IMPORTANCE OF R202Q MUTATION OF MEDITERRANEAN FEVER (MEFV) GENE.

Dimitrios Sagris¹, Nikolaos K. Gatselis^{1,2}, Panagiotis Skendros³, Aggelos Stefanos¹, Asterios Saitis¹, Eirini I. Rigopoulou^{1,2}, Konstantinos P. Makaritsis¹, Kalliopi Zachou^{1,2}, Konstantinos Ritis³, George N. Dalekos^{1,2}

¹ Department of Medicine and Research Laboratory, University Hospital of Larissa, Larissa, Greece

² Institute of Internal Medicine and Hepatology, Larissa, Greece

³ First Department of Internal Medicine and Laboratory of Molecular Haematology, Democritus University of Thrace, Alexandroupolis, Greece

Background

Several groups have linked R202Q alteration of MEFV gene with FMF phenotype, particularly in Greek patients. Our aim was to address the diverse characteristics of FMF patients diagnosed in our center between 2000-2018 and evaluate the importance of R202Q mutation in the clinical presentation of the disease.

Methods

We retrospectively reviewed, prospectively collected data of 51 FMF patients (32 native Greeks, 10 Greeks originated from Minor Asia, 3 Cypriots, 2 Jewish, 1 Arab, 1 Albanian, 1 Armenian and 1 of unknown ancestry), tested for MEFV alterations in exon-2 and exon-10 by non-isotopic RNase-cleavage assay (NIRCA) and subsequent sequence analysis.

Results

51 patients (26 females) diagnosed with a median (interquartile range) age of 33 (32) years. Among all patients, 42 (82.4%) presented with recurrent fever, 34 (66.7%) abdominal pain,

16 (31.4%) joint involvement, 10 (19.6%) pleuritis, 9 (17.6%) peritonitis, 5 (9.8%) pericarditis and 4 (7.8%) rash. Atypical clinical manifestations were present in 8 (15.7%) patients. Actually 2 suffered mainly by infertility, 2 had severe liver involvement, 2 periaortitis/retroperitoneal fibrosis, 1 meningitis and 1 recurrent episodes of myocarditis. Mutations/polymorphisms detected in 43/51 (84.3%) patients [homozygotes 12/43, compound heterozygotes 8/43, heterozygotes 19/43, polymorphisms 4/43]. The most prevalent mutations were R202Q (44.2%), M694V (25.6%), E148Q (11.6%), V726A (9.3%) and M694I (7%). R202Q homozygosity was more common in patients with atypical presentation (4/8, 50%) compared to those with typical characteristics of FMF (5/43, 11.6%, $P < 0.03$) and was exclusively present in native Greek patients. Apart from one patient who died at the time of diagnosis due to severe amyloidosis, all patients treated initially with colchicine, with either complete or partial response in 47/50 (94%), irrespective of the presence of R202Q mutation. Three patients needed immunomodulatory agents (corticosteroids, methotrexate, canakinumab, anakinra) to achieve remission.

Conclusion

R202Q was the most prevalent mutation in native Greek FMF patients and its homozygosity significantly correlated with atypical clinical manifestations, including severe liver involvement, periaortitis, retroperitoneal fibrosis, myocarditis, meningitis and infertility. Genetic analysis of R202Q mutation is essential to confirm the diagnosis, particularly in native Greek patients and those with atypical presentation of the disease.

#431 - Case Report

SPONTANEOUS INTERNAL JUGULAR VEIN THROMBOSIS: A RARE MANIFESTATION OF A THROMBOPHILIC DISORDER

Catarina Parente, António Cardoso, Fátima Campante
Centro Hospitalar Barreiro Montijo, Barreiro, Portugal

Introduction

Thrombophilic disorders are diseases characterized by a state of hypercoagulability resulting in an increased risk of thrombotic events that can be classified as acquired or hereditary conditions.

Case description

A 19-year-old female patient, with a known history of anxiety syndrome and two childhood hospitalizations for acute pyelonephritis, was observed in the Emergency Department for a pleuritic pain with 2 days of evolution, denying fever or other respiratory symptoms. Laboratory studies upon admission demonstrated elevated inflammatory parameters and the chest x-ray revealed a consolidation of the left lower lobe and therefore she was admitted with the diagnosis of community acquired pneumonia. While hospitalized, it was difficult to obtain peripheral venous access, and because of a poor response to oral antibiotic therapy,

central venous catheterization was attempted with ultrasound-guided technique which unveiled a thrombosis of the left internal jugular vein.

She was discharged after antibiotic regimen to complete hematologic study in ambulatory, but was readmitted a few weeks later due to a new pleuritic pain episode which this time around was associated with high d-dimer levels on laboratory test. A computed tomography angiography of the thorax was performed and demonstrated a pulmonary thromboembolism in a right lower lobe segmental branch.

The presence of a positive lupus anticoagulant and a positive anti-cardiolipin antibody IgG was detected from the thrombophilia profile study, which was later confirmed in consultation with the remaining autoimmunity study negative.

Discussion

Antiphospholipid syndrome (APS) is an autoimmune disease that occurs with recurrent episodes of venous or arterial territory thromboses, as well as recurrent miscarriages.

This pathology can be classified as primary or secondary as it is associated or not with another systemic disease, more often lupus. Internal jugular vein thrombosis is an extremely rare vascular disease and is generally associated with prolonged catheterization, intravenous drug use or head and neck pathology, and its identification in the absence of these conditions should alert to an underlying primary cause; it assumes a high severity character associated with potentially fatal complications, namely pulmonary thromboembolism.

#435 - Case Report

AN UNUSUAL CASE OF PERICARDITIS IN AN INTERNAL MEDICINE DEPARTMENT

Giorgia Barbarisi, Martina Zavagli, Costanza Marchiani, Giulia Bandini, Paolo Bernardi, Elisa Cioni, Nicolas Palagano, Manfredi Gagliano, Iacopo Bertolotti, Felice Crudele, Paolo Mercatelli, Elisa Martinelli, Alberto Moggi Pignone
Careggi Hospital, Firenze, Italy

Introduction

Granulomatosis with polyangiitis (GPA) is an autoimmune small vessel vasculitis which is highly associated with anti-neutrophil cytoplasmic antibodies (ANCA). We present an uncommon case of GPA occurred in a young adult.

Case description

A 44-year-old man came at our emergency department complaining persisting fever, non productive cough, generalized malaise, anorexia and left chest wall tenderness.

Four weeks before the general practitioner suspected a community acquired pneumoniae so he prescribed antibiotics and a thorax x-ray that only showed cardiomegaly; at the emergency department the thorax-US showed a pericardial effusion so a pericardiocentesis was performed.

Physical examination revealed an ill-appearing patient with a respiratory noise reduction at the left pulmonary base.

Laboratory tests showed leukocytosis, normocytic anemia, thrombocytosis and increased phlogosis indexes (225mg/L C-reactive protein, 1073 ng/mL ferritin, 514mg/dL fibrinogen). The thorax x-ray showed a lobar consolidation in the left base-lung, while the echocardiography showed the recurrence of pericardial effusion. A treatment with ibuprofen and colchicine and an empiric antibiotic therapy were started without resolution of the fever.

The blood cultures, flue test, HIV ab, beta-D-glucan tests were negative and he resulted not responder at the quantiferon test. Because of the persistence of fever we performed a blood smear and an immunophenotypic analysis that were negative. The urine analysis demonstrated a sub-nephrosic proteinuria and microematuria.

We therefore suspected an auto-immune underlying process and the rheumatologic tests showed a positive rheumatoid factor and high titer C-ANCA ab.

The CT scan revealed an important pulmonary involvement with subpleuric multiple nodules, large alveolar opacities, a left sided pleural effusion and mediastinal lymphadenopathy. The facial CT scan detected phlogosis of the right-maxillary-sinus. The clinical findings were highly suggestive for GPA and, in agreement with the immunologist, we started ev corticosteroids. The patient underwent a rapid clinical and radiological improvement.

Discussion

Diagnosis of GPA can be delayed, especially if admittance synthoms are uncommon and can be measleded with the worsening of a previous clinical state. The diagnosis of GPA should be confirmed by biopsy, however, patients can be treated empirically if the clinical suspicion is high and a tissue diagnosis cannot be obtained in short time.

#436 - Medical Image

ALLERGIC CONTACT DERMATITIS FROM A HENNA TATTOO

Eduardo Cernadas¹, Dália Estevão¹, Josefina Rodrigue²

¹ Serviço de Medicina Interna, Centro Hospitalar Cova da Beira, Covilhã, Portugal

² Serviço de Imunoalergologia, Centro Hospitalar de São João, Porto, Portugal

Clinical summary

The authors present the case of a 15 years old male patient, who presented an allergic contact dermatitis after a Henna tattoo brush application. The burning and itching at the site began 5 days after the application, followed by a vigorous blistering reaction with tense bullae without surrounding inflammation in a geometric pattern that strictly mirrored the sites of application. The patient was treated with topical corticosteroids, and the lesions resolved, leaving an extensive postinflammatory hyperpigmentation.

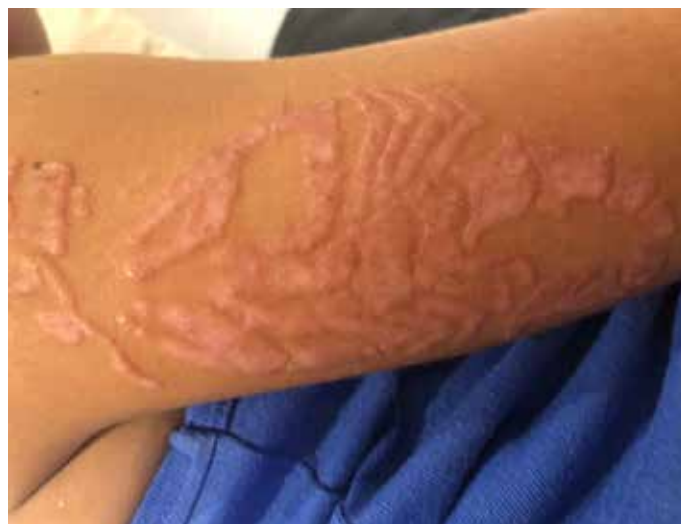

Figure #436.

#461 - Case Report

TWO PATIENTS, THE SPECTRUM OF THE SAME DISEASE

Ana Corte Real¹, Teresa Mendonça², Fátima Farinha²

¹ Centro Hospitalar do Oeste - Hosp. Caldas da Rainha, Caldas Da Rainha, Portugal

² Centro Hospitalar do Porto - Hosp. de Santo António, Porto, Portugal

Introduction

IgG4-related disease (IgG4RD) is characterized by fibro-inflammatory infiltrates, with increased number of IgG4+ cells present in tissue, usually with elevated serum IgG4. The exact etiology and fisiopathology is unclear. Frequently affects the lymph nodes, pancreas, salivary and lacrimal glands, but it can involve almost any tissue.

Case description

Case 1

A 21 year-old woman, followed by us due to a triple positive Antiphospholipid syndrome, started to refer episodes of migraine-like headache, progressively more intense and frequent, refractory to treatment (valproat semisodic and rozatriptan). Head CT and angio-CT were normal, but MRI showed fronto-parietal deposition of paramagnetic substance in inter-hemiferic falx and tentorium cerebelli. Lumbar puncture (LP) showed intratecal IgG4 production (0.56 mg/dL, N<0.35) and serum IgG4 was elevated (329 mg/dL, N<89). She had non productive cough, without dyspnea, and torax CT showed migratory peribroncovascular pulmonary nodular opacities. Bronchoalveolar lavage showed presence of IgG4 (0.53 mg/dL).

Case 2

A 23-year-old woman, previously followed by us due to a mixed connective tissue disease and elevated IgG (1650 mg/dL), start referring occasional headache episodes but the neurological exam, head CT and MRI were normal. 1.5 years later she referred episodes of painful proptosis and edema of the right eye and bitemporal

headache. Head CT and orbital MRI, showed a inflammatory/infiltrative lesion (2.7x1.3cm) at lacrimal gland. Biopsy referred lymphoplasmacytic infiltrate but citometry and molecular study showed policlonal background. Seric IgG4 was 160 mg/dL and LP showed a border line IgG4 level (0,39).

Any of both patients presented alterations compatible with infection or other autoimmune disease in all exams. We assumed IgG4RD and started prednisolone 1mg/kg/day, with clinical and radiologic improvement, and posterior tapering to 5-10mg/day.

Discussion

This 2 cases illustrate a broad spectrum of this rare and recently described disease. In case 1, although we don't have a meningeal biopsy, the evidence of intratecal IgG4 production and radiologic finds strongly suggests the diagnosis. In case 2, the lacrimal biopsy didn't show strong IgG4 presence but the molecular analysis with linfoplasmocytic policlonal infiltrate don't favor linfoproliferative hypothesis. IgG4RD may have important morbi-mortality. We must have it in mind so we can make the diagnosis, treat properly and improve patient's prognosis.

#464 - Case Report

A CASE OF PERNICIOUS ANEMIA WITH HEMOLYTIC ANEMIA IN THE YOUNG ADULT

Andreia Freitas, Joana Mascarenhas

Centro Hospitalar Vila Nova de Gaia/Espinho, Vila Nova De Gaia, Portugal

Introduction

Pernicious anemia (PA) is a megaloblastic anemia caused by the deficiency of vitamin B12. Intrinsic factor antibodies inhibit the absorption of the vitamin and parietal cell antibodies destroy the cells leading to atrophic gastritis. PA may be associated with production of red blood cell (RBC) antibodies and to autoimmune hemolytic anemia (AIHA), but in some cases PA patients with positive direct antiglobulin test (DAT) may have hemolysis without the involvement of an autoimmune mechanism.

Case description

A 24-year-old female was admitted to the emergency service due to lipothymia and dizziness. Physical examination was normal except for generalized pallor. Analytically the patient had 3.5g/dL of hemoglobin (Hb) and mean corpuscular volume of 104fL. Serological test revealed an elevated lactate dehydrogenase (2155 IU/l) and indirect bilirubin (0.91mg/dL) and haptoglobin <10mg/dL, suggesting hemolysis. Levels of vitamin B12 (30mg/dL) and folic acid (30mg/dL) were very low. DAT test and monospecific DAT test with anti-IgG were positive, and same test with anti-C3d was negative. The patient was admitted to an internal medicine ward due to hemolytic anemia. During hospitalization, 3 units of RBCs were transfused and vitamin B12, iron and folic acid supplementation were initiated. The cause of hemolytic anemia was unclear and therefore immunosuppressive therapy was not administered. Five days after admission, the patient was discharged

with 9.3g/dL of Hb and posteriorly followed in outpatient regimen. Gastric parietal cell and intrinsic factor antibodies, later available, were both positive. Upper gastrointestinal endoscopy revealed atrophic gastritis of the body with multifocal intestinal metaplasia and inflammatory lymphocytic infiltrate. The patient was then diagnosed with PA. With monthly vitamin B12 injections the hemolytic signs disappeared and it was therefore concluded that the hemolytic anemia was caused by PA. One year after discharge, the patient had Hb 14.6g/dL.

Discussion

This patient presented anemia mainly caused by malabsorption of vitamin B12, which leads to inhibition of DNA synthesis and to immature and ineffective erythropoiesis. The positive DAT status may be derived from non-specific autoantibodies. Its mechanism is still unclear. A hypothesis is that the increase of older erythrocytes increase the number of binding IgG antibodies. It is important to carefully assess PA patients with hemolysis and positive DAT status for the prevention of unnecessary steroid therapy.

#486 - Case Report

IMMUNE-MEDIATED NECROTIZING MYOPATHY UNDER STATIN TREATMENT

Sabela Castañeda Pérez, Alejandro García Espona - Pancorbo, Sergio Moragón Ledesma, Alejandro Parra Virto, María Victoria Villalba García, Blanca Pinilla Llorente

Hospital General Universitario Gregorio Marañón, Madrid, Spain

Introduction

Idiopathic inflammatory myopathies (IIMs) are a group of autoimmune diseases that typically course with proximal muscle weakness associated with specific antibodies. If not properly addressed since the very first moment, this group of pathologies can progress to systemic affectation to other organ systems with high morbidity and even mortality. We focus in one specific subcategory called Immune-Mediated Necrotizing Myopathy (IMNM), historically misdiagnosed because of its similar features with well-known polymyositis. This entity is becoming nowadays more popular due to the actual importance of histopathology. IMNM is an acute or subacute presentation of severe proximal symmetric weakness and high elevation of muscle enzymes levels, with a mean CPK value of 10,000 IU/L at initial presentation, with specific antibodies anti-SRP and anti-HMGCR. Last one appears classically after statin exposure, and the persistence of the symptoms is the rule even after discontinuation of the medication.

Case description

We herein report a presentation of IMNM in an adult with medical antecedents of hypertension, diabetes type 2 and dyslipidemia receiving oral antidiabetic drugs, antihypertensive and lipid-lowering agents (simvastatine and ezetimibe), with progressive apparition of proximal weakness, dysphagia and dark urine coloration. CK serum levels reached 16533 U/L while initial

autoimmunity test were in normal range. All serological analyses to search an infectious agent were negative. The EMG study showed a symmetrical affectation of numerous muscle groups, as the nuclear magnetic resonance confirmed later. He showed no clinical improvement despite of the discontinuation of the statin. Matching all this clinical, laboratory and clinical features, a serum sample was sent to a specialized laboratory that finally confirmed the presence of anti-HMGCR antibodies. We finally end up to the diagnosis of a statin-induced up to the diagnosis of a statin-associated anti-HMGCR necrotizing myopathy and start treatment with immunosuppression with steroids and azathioprine as immunosuppressant, with a great clinical

Discussion

In conclusion, for people under statin treatment who develop a progressive myopathy and for those with necrotizing myopathies with the suspicion of an immune-mediated process we should not forget to test for the anti-HMGCR antibody to arrive to the most complete differential diagnosis.

#502 - Case Report

REYNOLDS SYNDROME: A RARE, BUT CHALLENGING ENTITY

Joana Paixão¹, Sandra Santos¹, Telma Alves¹, João Gonçalves¹, Dilva Silva¹, Fátima Silva¹, Jorge Fortuna¹, Pedro Ribeiro¹, Armando Carvalho^{1,2}

¹ Centro Hospitalar e Universitário de Coimbra, Coimbra, Portugal

² Clínica Universitária de Medicina Interna, FMUC, Coimbra, Portugal

Introduction

Reynolds Syndrome (RS), whose prevalence is unknown due to its rarity, consists of a combination of scleroderma, mainly in the Limited Cutaneous Systemic Sclerosis form (CREST syndrome) and primary biliary cholangitis (PBC). Although generally considered an autoimmune disorder, other etiologies including genetics have been considered. About 25% of CREST patients have positive antimitochondrial antibodies (AMA), the PBC serologic marker; however, it is much infrequently to find a patient with PBC with scleroderma (prevalence 2.5-3%).

Case description

In this case series, we characterized, patients with RS followed in 2018 appointments, highlighting presentation signs and symptom, relevant exam findings and therapeutic approach. Six female patients with a mean age of 57 years were followed in Autoimmune consultations. Although all patients presented Raynaud's phenomenon (RF) at the first visit, in 2 of them, this was not the referral reason: in 1 patient there was esophageal dilatation on routine chest CT, which suggested CREST and the other, an autoimmune study requested in the context of severe pulmonary thromboembolism, pointed out RS hypothesis. Facial telangiectasias were evident in 2 patients, and one had associated sclerodactyly. It was also noted that 1 patient presented SLE with

secondary Sjogren's syndrome. Analytically, in all cases, alkaline phosphatase and hyperbilirubinemia values were increased, but only 3 patients had transaminases and γ GT above normal. None of them had pruritus complaints or relevant changes in imaging exams. Positivity for anti-nuclear, anti-centromere and AMA (anti-PDH-M2) antibodies was common to all, with expressive titers. Capillaroscopy showed megacapillaries, architecture disturbance with avascular areas and, in 2 patients, associated spontaneous hemorrhages, confirming active scleroderma pattern. Of the 2 patients who were submitted to manometry, only 1 showed a major peristalsis disturbance. Currently, 2 patients are under bosentan due to digital ulcers, being the remaining clinically and analytically controlled with hydroxychloroquine and/or pentoxifylline.

Discussion

RS constitutes a challenge not only given the importance of early diagnosis but, essentially, due to the meticulous need of follow-up. RF must always be etiologically explained, to exclude secondary origin given the precocity of this clinical manifestation. Considering that specific antibodies presence may precede CBP and CREST clinical, their prompt detection implies rigorous monitoring.

#510 - Case Report

IATROGENIC BULLOUS PEMPHIGOID

Catarina Sofia Martins Nóbrega, Ana Margarida De Abreu Temtem, Jessica Chaves, Catarina Miriam Capelo Freitas, Filipe Pernet, Maria Da Luz Reis Brazão

Hospital Central do Funchal, Funchal, Portugal

Introduction

Bullous pemphigoid (BP) is an acquired autoimmune skin disease that involves the formation of subepidermal bullae. It afflicts mainly the elderly population and its aetiology is unknown in most cases. Some associations have been made with environmental elements, cancer, other autoimmune disease or even medication.

Case description

The authors present the case of an 85 year-old male patient, with personal history of Parkinson disease and extensive polypharmacy. The patient initiated treatment with carbidopa/levodopa/entacapone the previous week and went to the Emergency Department (ER) with an extensive bullous dermatosis, with pruritic plaques and pimples surrounded by a reddish halo, without mucosal involvement. He was medicated with both topical and systemic corticoid treatment concomitant with flucloxacillin. A favourable outcome was attained.

Discussion

Several studies associate BP to neurological disorders like Parkinson, multiple sclerosis, epilepsy and stroke although the mechanism of such association remains unknown. Likewise, BP is also related to an extensive catalogue of drugs, including levodopa.

The authors bring forth such this clinical vignette as reminder of this rare condition and of its potential precipitating factors. They also prompt the necessity of an early diagnosis and proper medication as means of reducing more serious complications.

#511 - Case Report

RED SKIN... OMINOUS PROGNOSIS!

Silvia Santos Balhana, Luisa Leal Costa, Raquel Santos, Carla Noronha, Francisco Pestana Araújo, José Lomelino Araújo
Hospital Beatriz Ângelo, Loures, Portugal

Introduction

Dermatomyositis is a myopathic autoimmune connective tissue disease that presents with classic dermatologic findings. Up to 30 percent of adult-onset cases may represent a paraneoplastic syndrome warranting a thorough work-up for malignancy, mostly breast, lung, and colorectal cancers.

Case description

We report a case of a 54 year-old caucasian female, active smoker (20 cigarettes a day for the last 30 years) and without other known exposures or relevant diseases, presenting with an 8 months evolution of pruriginous rash in the photoexposed areas, proximal myalgia, fatigue and productive cough.

Physical examination revealed a rash with heliotrope, neck shaped "V" erythema; infiltrative eritemato-violaceous plaques of the face, upper limbs, abdomen and lateral region of the thighs; and positive Gowers' maneuver.

Laboratory tests showed elevated creatine kinase and aldolase; erythrocyte sedimentation rate of 116 mm/1st h; and positive anti-nuclear antibody (1:640, speckled); although negative anti-Jo1, anti-MDA5 or Anti-TIF1- γ . Dermatomyositis was confirmed through skin biopsy showing a vacuolar interface dermatitis with keratinocyte necrosis. Electromyogram and muscle biopsy were not performed. Oral prednisolone was started and elicited a prompt response.

Paraneoplastic dermatomyositis was considered a possibility and complementary workup were performed. Chest X-ray revealed a left paracardiac mass, which was further characterized by CT-scan showing a massive mass of the mediastinum, measuring 71 x 89 x 62 mm, and involving the left pulmonary artery. No evidence of metastases was seen. The patient was submitted to bronchofibroscopy and endobronchial ultrasound with biopsy that revealed a neuroendocrine carcinoma of the lung (small cell type), with a Ki67 of 97%, conferring a worse prognosis.

Discussion

The association of dermatomyositis with lung neuroendocrine carcinoma is extremely rare. A recent review of the Medline database, through the PubMed website, reported only 16 cases of dermatomyositis associated with lung neuroendocrine tumor from 1945 to 2015.

#516 - Abstract

HIGH PREVALENCE OF FIBROMYALGIA SYNDROME AMONG ISRAELI NURSES

Jenan Awesat, Tali Shafat, Boris Shvarts, Yauheni Makulin, Dan Buskila, Leonid Barski

Soroka University Medical Center, Beer Sheva, Israel

Background

Objectives: Stress has extensively been shown to trigger fibromyalgia syndrome (FM). Nursing is associated with high levels of stress. Our hypothesis was that nurses suffer from an increased prevalence of FM symptoms, and that these symptoms correlate with the levels of stress to which they are exposed in the course of their occupation.

Methods

The study was conducted as a targeted survey distributed to nursing staff in Soroka University Medical Center. Participants were asked to answer a questionnaire evaluating symptoms of FM, based on the current diagnostic criteria, which include the widespread pain index (WPI) and the symptom severity scale (SSS). Participants were further questioned regarding stressful experiences during their work and about post - traumatic symptoms as well as regarding work performance and motivation.

Results

206 participants completed the study questionnaire (84.5% females and 15.5%). Twenty (9.7%) participants of the sample, including 19 females and one male, fulfilled criteria for diagnosis of FM reaching rates among females and males of 10.9% and 3.1% respectively. The prevalence of FM in our study was related to age with the highest prevalence in the older age groups ($p=0.012$). FM symptoms were strongly correlated with work related stress and were strongly correlated with Post Traumatic Stress Disorder (PTSD) related symptoms. Work-performance parameters did not show a significant correlation with FM parameters.

Conclusion

FM is highly prevalent among nursing staff. Our findings point towards the possibility that work-related stress and traumatic events may play a major role in the development of FM symptoms among individuals working as nurses. With aging and increased work years this relation is even more significant.

#532 - Case Report

COEXISTENCE OF MULTIPLE SCLEROSIS AND SYSTEMIC LUPUS ERYTHEMATOSUS: A CASE REPORT AND LITERATURE REVIEW

Carlota Tuñón De Almeida, Álvaro Nava Rebollo, Víctor Madrid Romero, Sara Muñoz Alonso, Juan José Torres Ramos, Victoria Palomar Calvo, Carlos Aldasoro Frias, Montserrat Chimeno Viñas, Luis Miguel Palomar Rodríguez

Complejo Asistencial de Zamora, Zamora, Spain

Introduction

Multiple sclerosis and systemic lupus erythematosus are relatively common autoimmune diseases, most frequently in young women. Occurrence of both diseases simultaneously has occasionally been reported within some families affected with autoimmune disorders. We here present a case of a young woman with a history of multiple sclerosis since 9 years of age who went on to develop systemic lupus erythematosus at 25, with family history of mother diagnosed also of both diseases and sister with systemic lupus erythematosus.

Case description

We report a 32-year-old woman with family history of mother with multiple sclerosis and systemic lupus erythematosus and sister with only systemic lupus erythematosus. First, she presented in 1986 at the age of 9 years, an episode of sensorimotor weakness on the right side. The patient was diagnosed with relapsing–remitting multiple sclerosis, according to McDonalds 2010 diagnosis criteria. At the age of 22, the patient started treatment with subcutaneous interferon(INF)-beta 1a for a duration of three years.

At the age of 25, she suffered lupus pneumonitis and nephrotic syndrome with mild deterioration of renal function. Antinuclear antibodies (ANA) and anti-dsDNA antibody were positive with low levels of C3, so diagnostic criteria of systemic lupus erythematosus were met. Lupus nephritis was confirmed by renal biopsy.

Discussion

There are clinical overlapping features between both autoimmune diseases which can make challenging the diagnosis of multiple sclerosis in a patient with systemic lupus erythematosus. At the case here reported, both diagnoses can be made with reasonable confidence because the neurologic symptoms appeared many years before the systemic inflammatory signs.

According to the literature, the incidence of both diseases is increased in relatives, as we can see in this case, and it's rarely reported to coexist in a single patient. Several studies show a genetic predisposition in the occurrence of both multiple sclerosis and systemic lupus erythematosus, suggested by a frequent association with certain HLA haplotypes.

In conclusion, exceptional cases like the one here exposed can be used to investigate genetic factors that can defeat the apparent incompatibility of the two diseases and thus help elucidate their pathogenetic mechanisms.

#551 - Abstract

BILATERAL HAND EDEMA, THE DISCRETE SYMPTOM UNDER THE REMITTING SERONEGATIVE SYMMETRICAL SYNOVITIS WITH PITTING EDEMA SYNDROME (RS3PE)

Joao Luis Modesto Dos Santos, Judith Poblet Florentín, Sara Pérez Ricarte, Francisco Javier Annicchero

Complejo Hospitalario de Navarra, Pamplona, Spain

Background

The aim of this study is to report a series of two cases with the Remitting Seronegative Symmetrical Synovitis with Pitting Edema Syndrome (RS3PE) and to assess clinical and epidemiological features in order to provide more information about this unknown and underdiagnosed syndrome.

Methods

A descriptive study of two cases of the RS3PE syndrome is presented. Analysis of both cases was centred in clinical and epidemiological features, also focusing on laboratory findings and complementary exams excluding malignancy-related pathology. Information about treatment initiation and tapering is also provided.

Results

The two patients reported with RS3PE were elderly Caucasian males (73 and 83 years-old) living in rural areas of Navarra (Spain) and presenting with symptoms onset during summer and autumn. Both patients had cardiovascular risk factors and in both cases at least one thromboembolic event was described in the ten years preceding the RS3PE with no coagulation disorder found.

Involvement of both hands and upper extremities was similar, without any signs of girdle weakness or low extremity affection. Febriculae were present in only one of the subjects although both presented mild elevation of the erythrocyte sedimentation rate, that was above the 50 mm/h in both cases (66 and 53, respectively). Rheumatoid factor or anti-citrullinated peptide antibodies were negative in both cases, neither finding any association with other autoimmune disorders of the connective tissue. Malignancy was actively pursued with no findings in complementary tests nor in follow up.

Treatment with 0.5 mg/kg/day of prednisone was initiated in both cases with complete clinical remission in the following 72 hours. Follow up for the next year provided no data of relapses although corticosteroids tapering was initiated and finally suppressed.

Conclusion

The RS3PE syndrome must be contemplated in the differential diagnose of physicians assessing elderly patients, mainly males from rural areas, presenting with bilateral pitting edema of both hands and articular symptoms, involving predominantly the upper extremities. No specific biomarkers have been described in RS3PE although blood tests might present data of inflammatory reaction in the absence of rheumatoid arthritis biomarkers. Clinical

suspicion is reaffirmed when a rapid and complete clinical recovery is obtained with corticosteroids, although long term follow up is recommended due to its role as a paraneoplastic syndrome.

#562 - Case Report

HEMOLYTIC ANEMIA, THROMBOCYTOPENIA AND ACUTE KIDNEY INJURY: IMMUNOALLERGIC REACTION TO RIFAMPIN

Ana Sá, Vanessa Palha, Narciso Oliveira, Teresa Pimentel

Hospital de Braga, Braga, Portugal

Introduction

Rifampin is a semisynthetic antibiotic derived from rifamycins, developed for the treatment of tuberculosis. When given daily, possible adverse effects include allergic reactions, rashes, abdominal discomfort and hepatotoxicity. However, when administered intermittently it can produce more serious adverse effects, such as immunomediated reactions by IgG and IgM directed to erythrocytes, platelets and other cells that express antigen I, such as renal tubular epithelial cells. We present the case of a patient with severe immune-mediated reaction under treatment with rifampicin for treatment of latent tuberculosis.

Case description

A 39-year-old woman, started rifampin 4 months earlier for treatment of latent tuberculosis, being treated before that with isoniazid, stopped because hepatotoxicity. She went to the emergency department having fever, hematemesis and petechiae. On physical examination she was hypotensive, had right conjunctival suffusion and scattered petechiae on the face, chest, abdomen and limbs. Blood tests: anemia (Hb 12.0g/dL), severe thrombocytopenia (platelets <10/uL), acute kidney injury (creatinine 1.2mg/dL), hypokalemia (K 3.1mmol/L), hyperbilirubinemia and elevation of ALT and AST. In the first days of hospitalization, severe hemolytic anemia (Hb 8.2g/dL), severe thrombocytopenia and worsening renal function (creatinine 7.1mg / dL) developed, maintaining diuresis. Rifampin was immediately stopped. Remaining study: normal blood smear, negative viral serology, positive direct Coombs test, ANA 1/160, without consumption of complement. Urine, urocultures, blood cultures and CT scan had no abnormal finding. Pulses of methylprednisolone and immunoglobulin had been started, with readily improvement and after maintenance of oral systemic steroids. Until discharge, patient didn't have no new hemorrhages, fever and blood tests improved (Hb 10.1g / dL, platelets 315000 / uL, creatinine 1.3mg / dL). She had full recovery in less two months, being able to reduce steroids.

Discussion

There are some isolated reports of renal failure, hepatitis and hemolytic anemia after administration of rifampicin. Our patient stands out due to the severity of the clinical presentation, with simultaneously acute kidney injury, hepatotoxicity, anemia and

thrombocytopenia. Early diagnosis and timely suspension of rifampicin were crucial for the favorable clinical outcome. Detailed collection of pharmacological history is of chief importance.

#568 - Case Report

INTERMITTENT NEUROLOGIC DEFICITS – A CASE REPORT

Mariana Formigo, Gonçalo Castelo Branco, Ana Costa, David Paiva, Jorge Cotter

Hospital Senhora da Oliveira, Guimarães, Portugal

Introduction

Myasthenia gravis is a neuromuscular junction autoimmune disease in which antibodies are produced against nicotinic acetylcholine receptors.

Case description

A 77-year-old man with personal history of type 2 diabetes mellitus, dyslipidaemia and benign prostatic hypertrophy presented to the emergency department for sudden right palpebral ptosis associated with homolateral blurred vision. He was observed by ophthalmology who registered a decrease in right visual acuity. There were no other changes in neurological examination. An analytical and cerebral computed tomography (CT) study revealed no alterations. Oriented for internal medicine and ophthalmology appointments.

At the first Internal Medicine appointment, the patient didn't show any visual symptoms or neurological deficits. Several exams were performed, including cerebral magnetic resonance, carotid doppler, echocardiogram and extended analytic study with normal results.

New hospitalization due to left palpebral ptosis, imbalance, paraesthesia and dysphagia.

At the subsequent Internal Medicine appointment, the patient presented dysphagia improvement, visual acuity worsening, nasal voice, right palpebral ptosis and lower limbs paresthesias.

The patient had already performed endoscopy and colonoscopy without alterations. Electromyography revealed a slight severe axonal sensitive polyneuropathy.

At the last medical appointment, the patient recovered clinically without any complaint or neurological alteration. Assay of anti-acetylcholine receptor antibodies was positive and compatible with Myasthenia Gravis.

At the moment, the patient is waiting for autoimmune and paraneoplastic study, specifically, a cervicothoracic CT to exclude thymoma and a cystoscopy.

Discussion

Myasthenia Gravis presents a variable spectrum of clinical symptoms and evolution. Main etiological causes should be identified in order to implement treatment as soon as possible.

#579 - Abstract

BIOLOGICAL THERAPY AND MALIGNANT NEOPLASM - AN INTERNAL MEDICINE SERVICE CASE STUDY

Mariana Formigo, Hélio Martins, David Paiva, Sara Freitas, Pedro Cunha, Glória Alves, Jorge Cotter

Hospital Senhora da Oliveira, Guimarães, Portugal

Background

Biological therapy changed the way we treat autoimmune diseases, altering its evolution and the impact on patients' quality of life. The neoplasm risk of this treatment is controversial, since chronic inflammatory properties of these diseases are already prone to malignant development.

Methods

A retrospective and observational study of all patients oriented in the Autoimmunity Internal Medicine consultation from January 2004 to December 2018 was performed. The aim of this study was to understand the prevalence and characteristics of neoplasm complications in this population.

Results

A total of 433 patients was treated with biological therapy. 19 (4%) of these patients developed malignant neoplasms. There was a majority of female patients (84.2%, N=16) with an average age of 56 years old (minimum of 25 years). The most prevalent pathologies were rheumatoid arthritis (36.8%; N = 7), followed by ankylosing spondylitis (26.3%; N=5). Most of the patients (68.4%; N=13) were under treatment with etanercept. The average treatment time until neoplasm diagnosis was 4 years. A total of 20 neoplasms was observed with a majority of breast cancer (36.8%, N=7), followed by skin cancer (21.1%, N=4), central nervous system (10.5%, N = 2) and haematological (N=2), colon (5.3%, N=1), lung (5.3%, N=1); (5.3%, N=1), thyroid (5.3%, N=1) and uterus (5.3%, N=1). In this group of patients there were 2 deaths associated with an infectious complication.

Conclusion

The possible risk of malignant neoplasm development in patients previously treated with biological therapy cannot be excluded. The continuity or interruption of treatment is a complex decision, in which risks and benefits must be taken by a medical team and the patient.

#589 - Case Report

GIANT CELL ARTERITIS - CASE REPORT

Hilda Freitas¹, Natalia Oliveira¹, Antonio Cabral¹, Paulo Ferreira², Vanessa Machado², Cristina Ramalho²

¹ TrofaSaude Hospital Braga Sul, Braga, Portugal

² TrofaSaude Hospital Braga Centro, Braga, Portugal

Introduction

Giant Cell Arteritis (GCA) is a systemic vasculitis, of unknown cause, that predominantly involves temporal arteries and mainly affects patient >50 years. It is very commonly associated with a raised erythrocyte sedimentation rate (ESR), usually > 50mm/h, and can result in a wide variety of systemic, neurologic, and ophthalmologic complications. Temporal artery biopsy (TAB) remains the gold standard diagnostic test. The most feared complication of GCA, visual loss, is one potential consequence of such cranial arteritis.

Case description

The authors describe a clinical case of 78 years old men, autonomous, with a medical history of Hypertension, dyslipidemia, benign prostatic hyperplasia, peptic ulcer and Ex-smoker. Medication at home: acetylsalicylic acid, simvastatin, losartan, finasteride and tamsulosin. He went to emergency department because of greater agitation and refusal to feed. Referred from 1 month before periods of disorientation + right hemiparesis + imbalance in gait + dizziness + anorexia + body weight loss. Sometimes with headaches. No fever. Neurological examination: Glasgow 14, right hemiparesis + right fall when walking + dysmetria. Laboratory studies: ESR 83; PCR 5.19. CT and ECMR with lacunar infarcts. Echocardiogram, Carotid doppler without thrombotic sources. Sometimes referred vision changes, it was observed by ophthalmology: optic atrophy right eye. HIV and VDRL negative. Protein electrophoresis with polyclonal peak alpha 1 and 2 and beta, and immunological study negative (FR, ANA, ANCA, anti-dsDNA, anti-citrulline). He initiated pulses of methylprednisolone. There was clinical improvement, with normalization of reported complaints and changes detected, except for decreased vision, which he maintained. Refused TAB. Was discharged medicated with corticotherapy, oriented to Internal Medicine consultation where he keeps follow-up.

Discussion

GCA should be considered in the differential diagnosis of a new-onset headache and elevated ESR in patients >50 years. Corticotherapy are the mainstay of therapy. Risk factors for progression of visual impairment despite corticotherapy include advanced age, high ESR, and edema of the optic disc. Long-term follow-up is required to detect late recurrences. With proper treatment the prognosis is usually favorable. Visual changes are common and may be temporary or permanent.

#593 - Case Report

RARE CAUSE OF HYPONATREMIA: POLYGLANDULAR AUTOIMMUNE SYNDROME TYPE 2 / SINDROME SCHMIDT'S-CASE REPORT

Paulo Ferreira¹, Hilda Freitas², Natalia Oliveira², Vanessa Machado¹, Cristina Ramalho¹, António Cabral²

¹ TrofaSaude Hospital Braga Centro, Braga, Portugal

² TrofaSaude Hospital Braga Sul, Braga, Portugal

Introduction

Hyponatremia is defined as serum sodium below 135 mEq/L. Patients may be asymptomatic, or present unspecific symptoms, such as malaise or nausea. May be associated with many different conditions, making the differential diagnosis sometimes complex.

Adrenal insufficiency is a rare disorder, occurring in up to 144 people per million population.

The combination of autoimmune adrenal insufficiency with other autoimmune endocrine disorders is referred to as the polyglandular autoimmune syndromes types 1 and 2.

Case description

The authors describe a clinical case of a 55 years old man, with a medical history of Hiperuricemia. Without medication at home.

He was with sporadic nausea / vomiting, weight loss, tiredness and drowsiness.

Laboratory studies revealed hyponatremia. The further workup showed low levels of serum cortisol (and ACTH increased); cortisol dosing after administration of cosyntropine: in favor of adrenal insufficiency; Antithyroid Antibodies: TG N; TPO 68 (< 34); TSH 14.150 (0.27-4.2); T4 livre N; T3 T4 N; PTH N; Prolactin 19 (4-15.2); Adrenal autoantibodies positive. Tuberculosis, fungal infections, cytomegalovirus, HIV and syphilis were negative.

A Cranial Magnetic Resonance imaging revealed: "here is no significant deviation of the pituitary stem, which maintains normal morphology and caliber. It is observed an arachnoid cyst of the anterior slope of the sellar region, conditioning the molding of the superior slope of the pituitary gland. Absence of areas of hypocaptation in the glandular parenchyma. Correct individualization of the signal of the neurohypophysis in the posterior slope of the sellar region." Visual Campimetry - no changes. Studies for cancer were negative. The patient began hydrocortisone and levothyroxine hormonal reposition with improvement of the sodium levels. He became asymptomatic.

Discussion

The type 2 syndrome with primary adrenal insufficiency and autoimmune thyroid disease was formerly referred to as "Schmidt's syndrome". In young adults, the presence of nonspecific and mild symptoms, besides laboratory studies at the threshold of normal, can let pass potentially treatable conditions that can improve survival and life-quality for these patients. In these cases, the Internist assumes a preponderant role.

#602 - Case Report

CROHN'S DISEASE AND CANCA ASSOCIATED VASCULITIS-A CHALLENGE

Cristiana-Elena Vlad^{1,2}, Ioana Florea¹, Laura Florea^{1,2}

¹ Hospital "Dr. C. I. Parhon", Internal Medicine-Nephrology, Iasi, Romania

² Grigore T. Popa University of Medicine and Pharmacy, Internal Medicine-Nephrology, Iasi, Romania

Introduction

Crohn's disease is a chronic inflammation of the intestinal mucosa, which usually affect the terminal ileum and the perianal region. It exhibits common extraintestinal manifestations with the cANCA vasculitis: arthralgia, fever, skin changes and weight loss. cANCA is a necrotizing granulomatous inflammation, a pauci-immune vasculitis in small- and medium-sized blood vessels, without immune deposits and with anti-neutrophil cytoplasmic antibodies with specificity for proteinase 3 (PR3-ANCA).

Case description

A 70-year-old woman without medical history was admitted in our clinic for nasal obstruction and skin rashes. The clinical exam showed fever, maculopapular rash and oliguria. Laboratory results identified inflammatory syndrome, impaired kidney function (creatinine=6.2 mg/dl, BUN=51.4mg/dl), urinary protein excretion=1,55g/24 hours and microscopic hematuria. PR3-ANCA titer was 479 U/L (normal range < 7 U/L). Chest X-ray did not reveal pathological changes. The otorhinolaryngological examination detected multiple ulcerations of the lingual and jugal mucosa. Renal ultrasonography was normal, but anatomopathological examination showed "crescents", without immune deposits. Skin biopsy identified leukocytoclastic vasculitis of the small vessels with neutrophilic infiltrates. Granulomatosis with polyangiitis was diagnosed based on clinical, laboratory and histological findings. Patient was treated with prednisolone, cyclophosphamide, plasmapheresis. After 5 days of treatment, patient had diffuse abdominal pain and diarrheal stools (7-8 per day). Clostridium difficile (toxins A and B) was negative, and colonoscopy examination was performed and anatomopathological examination confirmed the Crohn's disease diagnosis. After 5-aminosalicylic acid, probiotics, enteral and parenteral nutrition, the clinical and biological evolution was improved.

Discussion

The association between Crohn's disease and cANCA's vasculitis is rare. Interdisciplinary management has led to a correct approach to this clinical case.

#614 - Case Report

SCLEROMYOSITIS WITH ANTI-SRP ANTIBODIES AND THERAPEUTIC DIFFICULTIES

Raja Amri, Wafa Garbouj, Zeineb Alaya, Haifa Tounsi, Imene Chaabane

Universitary Hospital Mohamed Tahar Maamouri, Nabeul, Tunisia

Introduction

Myositis with anti-signal recognition particle is distinguished by the severity of muscle damage and resistance to conventional therapies.

Few studies have been conducted on polymyositis with anti-signal recognition particle (anti-SRP) antibodies.

We report a new case of scleromyositis with anti-SRP antibody refractory to conventional treatments, and successfully treated with intravenous immunoglobulin.

Case description

A 65-year-old patient with systemic scleroderma diagnosed for 9 years, with sclerodactily, Raynaud's syndrom with digital ulcerations, gastrointestinal involvement (esophageal hypomotility) and cardiac involvement (tamponade).

The initial immunological assay found positive antinuclear antibodies at 1/320 with negative Rheumatoid factor, anti-ENA (extractable nuclear antigens) and anti-CCP (Anti-cyclic citrullinated peptide) antibodies.

During the follow-up and during a systematic immunoassay for control, the presence of anti-SRP antibodies suspected in front of a particular cytoplasmic fluorescence and confirmed by immunoenzymatic method made us suspect a myopathic attack, but the patient had no myalgia or muscle deficit and muscle enzymes was always normal.

Three months later, the patient had a predominant proximal muscle deficit in the lower limbs. The level of muscle enzymes was high, the electromyogram was normal and the neuromuscular biopsy showed an appearance of necrotizing myopathy associated with a regeneration process with no real inflammatory infiltrate.

In the presence of high dose corticosteroids and frequent relapses, the patient was initially treated with methotrexate secondarily associated with azathioprine and finally intravenous immunoglobulin (IV Ig). The evolution was marked by the clinical and biological improvement but in front of the suspensive effect, we were obliged to keep a low dose of corticosteroids in addition to methotrexate; azathioprine and IV Ig.

Discussion

The particularity of our observation is in the association scleroderma-polymyositis with the anti-SRP antibody, the later having announced the myopathy three months before the beginning of the symptoms. The detection of such antibodies with a symptomatology of myositis has a diagnostic and nosological interest and also therapeutic and prognostic.

#616 - Case Report

POLYMYOSITIS AND VIRAL HEPATITIS C: THERAPEUTIC DIFFICULTIES

Raja Amri, Wafa Garbouj, Zeineb Alaya, Haifa Tounsi, Aya Fraj, Imene Chaabane

Universitary Hospital Mohamed Tahar Maamouri, Nabeul, Tunisia

Introduction

The association between polymyositis and infection is rare but must be recognized because of poor prognosis and therapeutic difficulties. We describe a case of a polymyosites revealing a quiescent infection by the hepatitis C virus (VHC). The evolution and difficulties of treatment will be discussed by the authors.

Case description

A woman aged 62, with a history of hypertension under treatment, was admitted in pneumology for dyspnea exploration. The diagnosis of infectious pulmonary disease was made and the patient was treated with amoxicillin-clavulanic acid intravenously. Biology reported a myolysis with an elevation of creatinephosphokinases to eight times normal. As part of the etiological investigation of myolysis, adrug cause was eliminated. The thyroid status was normal. Antinuclear antibodies were positive at 1/640. Antibodies (native anti-DNA, soluble antinuclear antigen, anti-Jo1) and antineutrophil cytoplasmic antibodies (ANCA) were negative.

The diagnosis of atypical polymyosites was focused on proximal muscle deficit with myalgia, elevation of creatine phosphokinases, and myogenic involvement on electromyographic recording. Neuromuscular biopsy showed a discrete neurogenic attack without myogenic involvement.

As part of the pre-therapeutic assessment, the serology of VHC was positive. Corticosteroid therapy at a dose of 1mg/kg/day of prednisone equivalent was initiated pending the specific antiviral treatment.

The course was marked by the appearance of anemic cholestasis at four times normal and hepatic cytolysis at five times normal. Degression of corticosteroids was then initiated and treatment with pegylated interferon (IFN) and ribavirin was started.

Unfortunately, clinical and biological worsening of polymyosites was noted with rbdomyolysis at 10 times normal. The antiviral treatment was stopped at day 45 and intravenous immunoglobulin was prescribed, but the course was rapidly fatal following hepatocellular insufficiency and cataclysmic gastrointestinal bleeding.

Discussion

Our observation illustrates the therapeutic difficulties of polymyositis in HCV: Although corticosteroid therapy is effective on polymyositis, it can worsen CVH and should be used with caution. As for IFN, its action is even more complicated, it can either aggravate polymyositis by stimulating the immune response, or improve muscle damage due to the cytopathic role of the hepatitis C virus on the muscle.

#625 - Case Report

BERMUDA TRIANGLE: ANTIPHOSPHOLIPID SYNDROME- SYSTEMIC LUPUS ERYTHEMATOSUS -RENAL ARTERY STENOSISCristiana-Elena Vlad^{1,2}, Ioana Florea¹, Laura Florea^{1,2}¹ Hospital "Dr. C. I. Parhon", Internal Medicine-Nephrology, Iasi, Romania² Grigore T. Popa University of Medicine and Pharmacy, Internal Medicine-Nephrology, Iasi, Romania**Introduction**

Antiphospholipid syndrome (APS) is characterized by thrombotic episodes in arterial or venous circulation and high levels of antiphospholipid antibodies (aPL). APS may be primary or secondary(systemic lupus erythematosus-SLE). One third of SLE patients with positive aPL develop thrombosis during their follow-up and may affect any part of the renal vasculature.

Case description

A 50-year-old woman with history of systemic lupus erythematosus, treated by prednisone and hydroxychloroquine for 20 years was admitted in our clinic for elevated blood pressure and headache. The clinical exam showed BP: 240/130 mmHg, tachycardia, systolic-diastolic right periumbilical bruit, urine output <0.5 mL/kg/hour for 12 hours. Laboratory results identified inflammatory syndrome, impaired kidney function (creatinine 10 mg/dl, urea=300 mg/dl), normal urinalysis. Anti-dsDNA antibodies, ANA had high levels, C3/C4 had low levels and aPLs were positive. Renal ultrasonography identified a size difference between kidneys (right kidney: 110/65mm, left kidney: 80/45mm). Doppler ultrasonography and renal angiography showed 95% right renal artery stenosis. Acute kidney injury caused by APS was diagnosed based on clinical and paraclinical findings. Before percutaneous transluminal coronary angioplasty(PTCA), she did 3 HD sessions and was given anticoagulation therapy and 4 antihypertensive drug. After PTCA and due to improvement in renal function, HD was discontinued, the antihypertensive regimen was reduced, and corticotherapy was continued in combination with hydroxychloroquine, azathioprine.

Discussion

APS still poses a challenge to internists and nephrologists, and renal artery stenosis may be another manifestation of autoimmune disease. Interdisciplinary management has led to successful resolution of this clinical case.

#636 - Medical Image

CUTANEOUS THROMBOSIS IN ANTI PHOSPHOLIPID SYNDROME

Ricardo Taborda, Nuno Vieira E Brito, Pawel Sierzputowski, Paula Alcântara

Hospital de Santa Maria CHLN, Lisboa, Portugal

Clinical summary

A 36 years old African woman with ulcerated and thrombosed

lesions of the lower limbs and ears, alopecia, fever, weight loss, photosensitivity and rash with one month of evolution. The biopsy showed intravascular thrombus of all dermal vessels with necrosis and positive immunofluorescence for vasculitis. Further study revealed Lupus with Sjogren overlap and anti phospholipid syndrome. She began hypocoagulation with warfarin and pulses of methylprednisolone without improvement with a necessary increase in immune suppression with cyclophosphamide pulses after which the skin lesions improved and the patient was discharged to ambulatory.

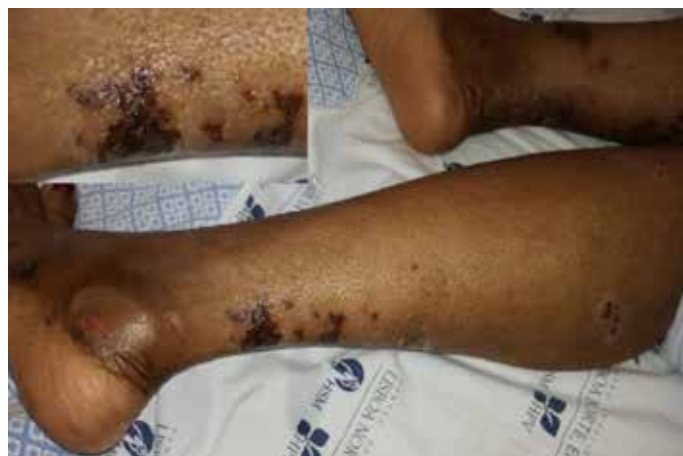

Figure #636.

#653 - Case Report

SARCOIDOSIS AND AUTOIMMUNE THROMBOCYTOPENIC PURPURA: RANDOM ASSOCIATION OR HEMATOLOGIC MANIFESTATION OF SARCOIDOSIS?Maroua Mrouki^{1,2}, Tayssir Ben Achour^{1,2}, Amal Baya Chatti^{1,2}, Yosra Cherif^{1,2}, Sara Hamrouni², Fatma Ben Dahmen², Meya Abdallah^{1,2}¹ Tunis El Manar University Faculty of Medicine of Tunis, Tunis, Tunisia² Regional Hospital Ben Arous, Internal Medicine Department, Ben Arous, Tunisia**Introduction**

Thrombocytopenia during sarcoidosis is a rare manifestation essentially secondary to hypersplenism or bone marrow involvement. Autoimmune thrombocytopenic purpura (ATP) has been rarely described associated with sarcoidosis.

Case description

Mrs. FR, aged 50, with a history of pulmonary tuberculosis 8 years ago, has been followed up for mediastino-pulmonary sarcoidosis with sinusal involvement for 3 years.

The diagnosis was based on cutaneous lesions such as lupus pernio and erythema nodosum of lower extremities, nasal obstruction, mediastinal and intraperitoneal lymphadenopathy And bilateral pulmonary infiltrates, increased angiotensin-converting enzyme (ACE) level and the presence of an epithelioid granuloma at salivary gland biopsy and nasal mucosa. She was

treated with oral corticosteroid and the evolution was, initially, favorable.

While the patient was taking 10 mg of Prednisone per day, she presented a great abundance epistaxis resisting to local treatment. Laboratory testing revealed thrombocytopenia at 3000el/mm³ and anemia at 5g / dl of hemoglobin. Myelogram, liver function test, LDH and complement were normal. Anti-nuclear antibodies, anticardiolipin and anti-β₂ GP1 were negative. There were no signs of infection. Abdominal ultrasound was normal. The diagnosis of ATP associated with a Sarcoidosis was set.

The patient was treated with tranexamic acid and had red blood cells transfusions. Prednisone was increased to 1mg / kg / day. The evolution was marked by a rise in platelet count within 72 hours and nasal bleeding stopped after 24 hours.

Discussion

Thrombocytopenia in sarcoidosis is explained by three mechanisms: hypersplenism, medullary invasion by granulomas or more rarely an immunological mechanism. ATP occurs during sarcoidosis in less than 2% of cases and is particularly severe, often complicated by hemorrhage and associated with a high mortality rate of up to 15% of patients. Sarcoidosis associated with ATP is characterized by severe systemic involvement and frequent relapses needing prolonged systemic treatment.

#666 - Case Report

REMITTING SERONEGATIVE SYMMETRICAL SYNOVITIS WITH PITTING EDEMA (RS3PE) SYNDROME IN A PATIENT WITH POLYMYALGIA RHEUMATICA

Afroditi Roumpou, Christos E Lampropoulos, Ioanna Papaioannou Argolidos General Hospital, Nafplion, Greece

Introduction

Remitting Seronegative Symmetrical Synovitis with Pitting Edema (RS3PE) is a rare syndrome with tenosynovitis of hands' flexor and extensor tendons with pitting edema. It is idiopathic or secondary to rheumatic diseases, malignancies or infections.

Case description

A 75-year old man presented symmetric, proximal weakness of limbs, arthralgias and morning stiffness the last year. Just before admission he developed hands edema. His medical history was free. Clinical examination showed muscle tenderness of shoulders, inability to arise from a sitting position, bilateral tenderness of metacarpophalangeal (MCP) joints, pitting edema of hands and pain during fingers' extension (tendonitis). Laboratory investigation revealed high ESR (107 mm/1h), anemia (Ht=31.3%) and ferritin (565 ng/mL). The rest of examinations were normal, as well as temporal artery biopsy. The patient was diagnosed as having polymyalgia rheumatica (PMR) with concurrent RS3PE. He was started on methylprednisolone 16 mg/day. After five days he had almost complete remission of symptoms and hands' edema.

One month later ESR was 18 mm/1h and Ht 39.6%. Six months after steroids discontinuation (treatment duration 12 months), the patient feels well with full agricultural activity.

Discussion

RS3PE is a rare syndrome with defined diagnostic criteria: bilateral pitting edema of hands, polyarthritis, age >50 years and negative RF. Polyarthritis involves MCP and proximal interphalangeal joints, wrists and shoulders with absence of erosions. Treatment consists of low dose steroids (10-15 mg/day) with rapid and complete remission with few recurrences. RS3PE and PMR share common features making difficult their differentiation. RS3PE responds dramatically to lower dose of steroids with shorter duration of treatment, is more common in males, it mainly involves wrists and hands instead of shoulder and pelvic girdle, is associated with HLA-B27 (PMR with HLA-DR4) and has an excellent long-term prognosis with fewer relapses. RS3PE may also be a paraneoplastic manifestation (solid or hematological malignancies). Successful treatment of malignancies led to regression of the syndrome. A useful differential diagnostic observation between idiopathic and paraneoplastic syndrome is the presence of systemic symptoms (fever, anorexia, weight loss) and poor response to low dose of steroids, which should alert physicians to the possible presence of an underlying malignancy.

#680 - Case Report

NON-INFECTIVE AORTITIS IN A PATIENT WITH SYSTEMIC LUPUS ERYTHEMATOSUS: ALL THAT GLITTERS IS NOT GOLD

Anastasios Stefanopoulos, Ioannis Mitrakos, Ioannis Poulos, Christos Serafeim, Dimitra Tsakiri, Christina Papadima, Pigi Konida, Georgios Mavras, Maria Pavlaki, Foteini Rozi General Hospital of Argos, Argos Greece, Greece

Introduction

Aortitis is defined as the inflammation of the aortic tissue and can occur in patients with inflammatory or autoimmune diseases. Giant cell arteritis as well as Takayasu arteritis are thought to be the most common autoimmune disorders that can cause a non-infective aortitis. The objective of this case report is to demonstrate a case of a non-infective aortitis in a patient diagnosed with Systemic lupus erythematosus (SLE) and highlight this potentially rare complication of SLE.

Case description

A 46-year-old Caucasian female with known history of SLE and Lupus nephritis and previous history of Pulmonary embolism presented to the Emergency Department of our clinic complaining of fever with chills as well as chest pain that was reflected to the back and to the abdomen. Symptoms had started approximately two weeks ago. On further questioning, she revealed that she was bitten by a tick a month ago and had received a course of antibiotics for five days due to fever which was presented after this bite-incidence. After two

weeks she started to present fever with chills. Physical examination was unremarkable. CTPA was negative for a new pulmonary embolism and the rest of the laboratory results were also within normal values. Based on the thought of a possible rickettsia infection an initial course of antibiotics was administered while waiting for the antibodies to confirm or reject this diagnosis. Antibodies were negative for rickettsia infection but the fever and the pain continued. An abdomen C/T was conducted and revealed an aortitis without the formation of an aneurysm. She was transferred to a rheumatology clinic for further consultation and management. Symptoms started to improve after one week of high doses of corticosteroids.

Discussion

Aortitis still remains a serious diagnostic challenge but it can be cured with the proper intervention. Clinical features of aortitis are nonspecific and may include fever, abdominal or chest pain. A high index of clinical suspicion is always needed for the diagnosis of aortitis and imaging techniques, such as computed tomographic angiography and magnetic resonance angiography, are helpful not only in diagnosis, but also in assessing disease activity and post-treatment follow-up.

#692 - Case Report

AN UNUSUAL PRESENTATION OF PURPURIC LESIONS IN THE LOWER LIMBS OF A MIDDLE AGED WOMAN

Gabriel Puche Palao, Francisco Javier Hernández Felices, Carlos Báguena Pérez-Crespo, María Del Carmen Hernández Murciano, Elena Del Carmen Martínez Cánovas, Ignacio Iniesta-Pino Alcázar, Vicente David De La Rosa Valero, Ana Martín Cascón, Lia Ferraro X, Mónica Martínez Martínez

Hospital General Universitario Reina Sofía, Murcia, Spain

Introduction

Purpuric lesions as paraneoplastic syndrome associated with lung cancer is a rare condition. Although the hematologic tumors are the most frequently tumors associated, sometimes we can find them associated to solid tumors.

Case description

A 62-year-old female patient was observed in our hospital with a 2-weeks history of purpuric lesions in the lower limbs. On examination there were no pathological findings. Blood levels of electrolytes, glucose, calcium, magnesium and transaminases were normal, as were the results of renal-function tests.

Discussion

Histopathology and immunohistochemistry studies were compatible with leukocytoclastic vasculitis. To conclude that a patient presents a primary cutaneous vasculitis, it is necessary to rule out involvement at the level of other organs, which requires a thorough anamnesis accompanied by a broad analytical study of the patient.

Using the recent algorithm proposed by Tamihiro Kawakami, the case was successfully addressed. Therefore, a large autoimmunity study was carried out including the determination of antineutrophil cytoplasmic antibody (ANCA), cryoglobulins, immunofluorescence, HIV, HBV, HCV serology, which turned out to be negative. Furthermore, chest x-ray and chest computed tomography were made, showing a large mediastinal mass compatible with lung carcinoma. A transbronchial biopsy of the mass was performed, with the anatomopathological diagnosis of squamous cell carcinoma.

Due to those findings, the patient was referred to the oncology service to decide the treatment scheme.

Our case shows how in the face of the negativity of all the autoimmunity, and given the anatomopathological findings without existing history of taking new drugs, we are faced with a paraneoplastic cutaneous primary vasculitis to an epidermoid carcinoma of the lung.

While it is true that there would be a last logical doubt to attribute such injuries to the recent intake of folic acid, but there are no cases reported in the literature to support this association.

The present case illustrates the nature of leukocytoclastic vasculitis as well as the challenge of identifying the cause of it. It is essential to carry out an exhaustive study on the existing heterogeneity in the group of vasculitis, making its approach complex.

#699 - Case Report

NECROTIZING AUTOIMMUNE MYOPATHY – A CASE REPORT

Andreína Vasconcelos¹, Carlos Rodrigues¹, Joana Ricardo Pires¹, Olinda Rebelo², João Fonseca¹

¹ CHBV, Aveiro, Portugal

² CHUC, Coimbra, Portugal

Introduction

Necrotizing autoimmune myopathy (NAM) is a rare subgroup of inflammatory myopathies characterized by severe subacute proximal and symmetrical muscle weakness, marked increases in creatine kinase (CPK) levels, and myocyte necrosis with no significant inflammation in muscle biopsies. Although it may be associated with the use of statins, tumours and connective tissue diseases, 50 % of the cases remain idiopathic.

Case description

A 51-year-old female presented with complaints of asthenia and proximal muscle weakness, over the last 6 weeks, with tremendous impact in her daily life. She also reported a 3-week long generalized muscle pain and denied other symptoms, the onset of new drugs, any epidemiologic relevant context, trauma history, previous episodes and family history of neuromuscular diseases. The patient was obese and had been previously diagnosed with hypertension, diabetes, dyslipidemia and Hashimoto's thyroiditis, to which she was medicated with perindopril, metformin/

sitagliptin, simvastatin and levothyroxine. Initial laboratory workup revealed a CPK of 18212 U/L, followed by prompt statins' discontinuation. Subsequent immunological workup was normal (including anti-signal recognition particle and anti-3-hydroxi-3-metilglutaryl-coenzyme A reductase) and the patient was negative for HIV, hepatitis B and C viruses and other potentially infectious agents. Body CT-scans failed to identify tumours or interstitial lung disease, and functional respiratory tests, electrocardiogram and echocardiogram were normal. Electromyography, however, revealed a 4-member myopathic pattern, and a subsequent muscle biopsy was compatible with necrotizing autoimmune myopathy. The patient started high-dose corticosteroids for 3 days (methylprednisolone 500 mg id) and then continued with 1 mg/kg id prednisolone plus methotrexate. She immediately noticed muscular improvement and CPK started dropping. Six months later, she was taking only 10 mg prednisolone a day, she was asymptomatic and her CPK values were normal.

Discussion

Although rare, NAM becomes a strong diagnostic hypothesis in face of proximal muscle weakness and very high CPK values, when no trauma history is known. It is an aggressive myopathy, so it urges recognition to start prompt immunosuppressive treatment. The widespread use of statins as cardiovascular risk controllers will make secondary NAM more frequent, and their reintroduction in these patients should be carefully considered.

#704 - Case Report

TAKAYASU'S ARTERITIS, A MASTER OF DISGUISE

Juliana Magalhães, José Pereira, Inês Antunes, Filipa Amorim, Ivone Barracha, Rosa Amorim

Centro Hospitalar do Oeste - Unidade de Torres Vedras, Torres Vedras, Portugal

Introduction

Takayasu's arteritis is a rare and chronic vasculitis, which mainly affects the aorta artery and its main branches. The onset of the disease usually occurs before 40 years old and mainly in women, and the early diagnosis requires a high clinical suspicion.

Case description

A 64-year-old woman with Rheumatoid Arthritis, referred from the Autoimmune Diseases consultation to the Emergency Department due to microcytic anemia, fever and weight loss with 3 months of evolution, with the suspicious of an infectious or neoplastic disease. With personal history of angiodysplasias of the small intestine, pulmonary tuberculosis, nodule in the right breast and left oophorectomy. At the observation, she had pallor, fever, BP: right upper limb - 130/56mmHg, left upper limb - 144/67mmHg, rheumatoid nodule in the right elbow, soft swelling in the MCP and IP joints of both hands. The laboratory tests showed hypochromic microcytic anemia (Hb 6.2g/dL), ESR

100mm/h and CRP of 28.1mg/dL. Chest X-ray had no changes. Other exams performed during hospitalization: negative microbial cultures; negative direct and cultural research of mycobacteria; negative viral serologies; endoscopic study without alterations; CT and MRI showed cyst with regular contours in the right ovarian; tumor markers with increased Ca 15.3 and ROME. Due to suspicion of gynecological neoplasia, she performed PET that documented "marked hypercaptation of FDG-F18 in the wall of large vessels and capturing changes of mild to moderate intensity in several joints (vasculitis of large vessels and arthritis/polymyalgia rheumatoid)". In the anamnesis she confirmed claudication. So Takayasu's arteritis was admitted and the patient started prednisolone and methotrexate, with improvement of symptoms, getting afebrile and lowering of inflammatory markers. Weeks later, she returned to ED because of a syncope, having performed CT pulmonary angiography for suspected pulmonary embolism (PE), which showed "apparent subtraction of left pulmonary artery contrast in relation to partial PE". Considering the diagnosis of vasculitis of large vessels, lung V/Q scintigraphy was performed, excluding the diagnosis of PE, assuming CT alterations in the context of the underlying pathology.

Discussion

The authors submit this case for the rarity of its association with rheumatoid arthritis, but also to highlight the diagnostic challenge due to the variability of systemic symptoms that are easily confused with other pathologies.

#706 - Abstract

PREDICTION OF IMMUNE-RELATED ADVERSE EVENTS INDUCED BY IMMUNE CHECKPOINT INHIBITORS BY MEANS OF A BATTERY OF AUTOANTIBODIES

Iñigo Les, Saioa Eguiluz, Cristina Sánchez, Pilar Anaut, Alicia Narro, Laura Puntí, Severina Domínguez, Ander Andía
Hospital Universitario Araba, Vitoria-Gasteiz, Spain

Background

The objective of this study is to assess the effectiveness of a battery of autoantibodies to predict the occurrence of immune-related adverse events (irAEs) in patients with cancer treated with immune checkpoint inhibitors.

Methods

Retrospective observational study recruiting patients with cancer monitored in the oncology outpatient clinic of a tertiary hospital. Variables potentially related to the occurrence of irAEs such as demographic, clinical and analytic data including an autoantibody battery integrated by ANA, ANCA, anti-thyroid antibodies and rheumatoid factor were analysed. Quantitative and categorical variables were expressed as mean±standard deviation and frequencies (%) and were compared using the Student's T, Pearson's χ^2 and Fisher's exact tests, respectively. Overall survival was analysed with the Kaplan-Meier and log-rank Mantel Cox tests.

Results

Sixty-nine patients (48 men, 21 women; 61.8±10.9 years at baseline), all of them diagnosed with a stage 4 solid organ cancer and treated with nivolumab, were followed for 12±10.3 months. The primary tumor was a non-microcytic lung carcinoma in 47 cases (68%), a melanoma in 11 (16%), a renal carcinoma in 9 (13%) and a head and neck cancer in 2 (3%). A total of 32 irAEs in 26 patients (37.5%) were detected, of which 8 were thyroiditis, 6 enterocolitis, 5 inflammatory arthritis, 4 dermatitis, 4 pneumonitis, 2 nephritis, 2 hepatitis and 1 autoimmune thrombocytopenia. The irAEs were more frequent in women (62% versus 27%, $p=0.006$) and in younger patients (with irAEs: 58.1±9.8, without irAEs: 64.1±10.9 years, $p=0.024$). In 26 patients (16 of them with and 10 without irAEs) the autoantibody battery was performed, being more frequently positive in patients with irAEs (with irAEs: 14/16 [87%], without irAEs: 3/10 [30%], $p=0.009$). The positive predictive value, negative predictive value and diagnostic accuracy of the battery were 82.3%, 77.8% and 80.8%, respectively. Among the 60 patients in whom the therapeutic response could be assessed, tumor progression occurred in 23 cases (38.5%) and was less frequent in patients with irAEs (with irAEs: 4/21 [19%], without irAEs: 19/39 [48.5%], $p=0.03$). Overall survival was better in patients who developed irAEs (HR 1.88, CI95% 1-3.55, $p=0.05$).

Conclusion

In our series, an accessible battery of autoantibodies (ANA, ANCA, anti-thyroid antibodies and rheumatoid factor) is a good predictor of irAEs. This promising tool is being evaluated in a prospective study conducted by our group (NCT03868046).

#716 - Case Report

THROMBOPHLEBITIS AS FIRST PRESENTATION OF SYSTEMIC LUPUS ERYTHEMATOUS

Rita Serejo Portugal, André Gonçalves, Teresa Filomena, Fátima Pimenta

Centro Hospitalar Médio Tejo, Torres Novas, Portugal

Introduction

Systemic lupus erythematosus (SLE) is a chronic inflammatory autoimmune disease characterized by multisystemic involvement that primarily affects young women. Patients with SLE have an increased risk for thrombosis. Arterial and/or venous thrombosis is a well-known clinical entity in SLE, with a prevalence >10%.

We present the case of a 40-year-old woman, who developed thrombophlebitis for the first time after giving birth and was eventually diagnosed with SLE.

As expected, there was a positive evolution with therapeutics with antimalarials and corticosteroids.

Case description

We present the case of a 40-year-old woman, lawyer, with known history of anemia and otherwise healthy, who had given birth 2

weeks before coming to the ER, a preterm labor due to premature placental abruption.

She resorted to the emergency department for edema and pain in the upper right limb alongside with facial edema on the homolateral side. Already during hospitalization she developed malar erythema. The upper limb ecodoppler confirmed right cephalic vein thrombophlebitis (CVT). Complementary explorations showed pleural and pericardial effusion, positive ANA (1/640) and DsDNA 769.30 U/L. Antiphospholipid antibodies were negative. After treatment with enoxaparin, NSAIDs, hydroxychloroquine, prednisolone and diuretics the patient's condition improved both clinically and radiologically.

After 2 months, at follow up, she had complaints of asthenia and photosensitivity but denied new signs of thrombosis, fever, arthralgias or edema. At this time we started reducing the dose of prednisolone.

Discussion

In systemic lupus erythematosus, phenomena of thrombosis such as CVT can be the initial form of presentation of the disease. The presence of antiphospholipid antibodies plays an important partial role in CVT; other phenomena, such as inflammatory processes, should also be taken into account.

#720 - Case Report

OPTIC NEURITIS: THINK ABOUT BEHÇET'S DISEASE!

Youssef Gharbi^{1,2}, Maroua Mrouki^{1,2}, Yosra Cherif^{1,2}, Amal Baya Chatti^{1,2}, Fatma Ben Dahmen², Meya Abdallah^{1,2}

¹ Tunis El Manar University Faculty of Medicine of Tunisi, Tunisi, Tunisia

² Regional Hospital Ben Arous, Internal Medicine Department, Ben Arous, Tunisia

Introduction

Optic neuritis (ON) is a common pathology in young patients and usually is the presenting manifestation of multiple sclerosis, however its association with Behçet's disease (BD) is unusual and controversial. Hereby, we report a new observation.

Case description

A 29-year-old man was followed-up for 9 years for recurrent bilateral posterior uveitis treated randomly with corticosteroids with frequent relapses. 6 years after the onset of the disease, the patient presented with visual field loss of the right eye. The visual evoked potentials (VEP) showed delayed VEP latency of the right eye. Although Orbito-cerebro-medullary MRI was normal, the patient had 5 boli of methylprednisolone at 1 g/day with partial improvement.

Recurrence of symptoms occurred a year later with severe left optic neuritis. The research of ANN, anti ENA and the investigation infectious were negative. At this stage, the patient signaled the occurrence of bipolar aphthosis which ceased with corticosteroids. The diagnosis of BD was set with a score of 6 according to the

International Criteria for BD. At this time, the patient presented a relapse of the uveitis with ischemic retinal vasculitis complicated with neovascularization. A retinal laser photo coagulation was required and the corticosteroid therapy was increased to 1 mg/kg/day associated with azathioprine 150 mg/day. Colchicine was stopped because of digestive intolerance. The evolution was marked by the stabilization of uveitis however a recurrence of the ON in the right eye was noted.

Discussion

Despite its low prevalence of ON during BD, several mechanisms can explain its occurrence in BD. This condition can be secondary to glaucoma, retinal ischemia or inflammation of the optic nerve by contiguity to posterior uveitis. In this patient, ischemic retinal vasculitis and the severity of the pan uveitis explained the occurrence of ON. Investigations to rule out other common etiologies of ON are needed but should not delay the treatment onset.

#726 - Case Report

SICCA SYNDROME AS THE PRESENTATION FORM OF MULTIORGANIC SARCOIDOSIS

Joana Pereira, Ana Ribeiro, Joanne Lopes, Patrícia Lourenço, Jorge Almeida

Centro Hospitalar São João, Porto, Portugal

Introduction

Sarcoidosis, a multiorgan condition, is a disease of unclear aetiology in which there is deposition of noncaseating granulomas in the affected structures. Lung is the most commonly affected organ, but in up to a third of the patients there are also extra-pulmonary manifestations. Liver is one of the extra-pulmonary structures most commonly impaired although the majority of patients are asymptomatic. The etiologic investigation of sicca symptoms can be challenging. Clinicians more commonly associate them to other diseases-mainly Sjögren Syndrome-but they may also be, rarely, the presentation form of Sarcoidosis when salivary glands are affected.

Case description

We report the case of a 44-year-old female with medical history of migraine. She presented with asthenia and periorbital edema, xerostomy, xerophthalmia and bilateral retromandibular tumefaction for the past 2 months. The investigation revealed elevated angiotensin-converting enzyme, mild elevation of liver enzymes, increased urinary calcium excretion and negative anti-SSA/Ro antibodies. Cervical ultrasound revealed 2 nodules in the parotid gland. Salivary glands scintigraphy showed hypocaptation in both parotid glands. Left parotid gland nodule was biopsied-non-necrosating granulomas. Liver ultrasound only showed mild steatosis; a biopsy was performed-granulomatous process. Both histologies were negative for acid-alcohol resistant bacilli. Thoracic computed tomography showed mediastinal, hilar and

subcarinal lymph nodes. The final diagnosis of liver, exocrine glands and pulmonary (stage 1). Sarcoidosis was established. She started treatment with corticosteroid-prednisolone 40mg/day and, after 3 weeks, the symptoms improved, the parotid swelling disappeared and the blood analysis also improved which allowed the tapering of the corticotherapy. She is corticoid-free for over 1 year, she remains asymptomatic and the liver enzymes and ECA level normalized.

Discussion

Sicca symptoms can be a manifestation of various diseases. Although they are usually associated with other conditions, clinicians must be aware that sicca symptoms might also be the presenting form of an otherwise asymptomatic sarcoidosis. Furthermore, this clinical case remembers that in sarcoidosis, multiple organ involvement can exist even in asymptomatic or mildly patients. It is important to keep in mind that even slight alterations of the blood panel analysis or vague non-specific complaints should alert the clinician to the possibility of organ impairment by this granulomatous process.

#733 - Case Report

THE SKIN IN INTERNAL MEDICINE - A CASE OF LÖFGREN SYNDROME

António Epifânio Mesquita^{1,2}, Lara Câmara¹, Catarina Patrício¹, Vítor Brotas¹

¹ Serviço de Medicina 2.3, Hospital Santo António dos Capuchos, Centro Hospitalar Universitário de Lisboa Central, Lisboa, Portugal

² Departamento de Fisiopatologia, NOVA Medical School, Universidade Nova de Lisboa, Lisboa, Portugal

Introduction

Sarcoidosis is a multisystem granulomatous disease of unknown etiology. There is cutaneous involvement in around 25% of cases. Therefore, it becomes essential to be familiar with the morphology of the skin lesions that can hide - in fact reveal - this diagnosis.

Case description

A 35 year-old woman came to our Internal Medicine Consultation with a 1 week history of symmetric tibiotarsal arthralgia, of inflammatory nature, asthenia and fatigue. She denied fever, night sweats, weight loss, abdominal pain, diarrhea or rash. She also denied the use of intravenous drugs, a high-risk sexual behavior, tick bites, or previous genitourinary or respiratory infections. She denied a personal or family history of psoriasis, ankylosing spondylitis, inflammatory bowel disease or systemic connective tissue diseases. On physical exam, swelling and pain of the tibiotarsal joints were noted. The patient did not have fever, adenopathy, organomegaly or rash. Blood analysis revealed elevated inflammatory markers and slight cholestasis. Infectious serologies were negative. Anti-nuclear antibody titers were positive at a 1:160 dilution; the rest of the autoimmune screen was negative. Abdominal Ultrasound showed moderate

homogenous hepatomegaly. Non-steroid anti-inflammatory drugs (NSAID's) were prescribed with partial relief. One week later, the patient presented with new-onset symmetrical painful subcutaneous violaceous skin nodules on the anterior surface of the shins, suggestive of erythema nodosum. Löfgren Syndrome was suspected and a thoracic Computed Tomography (CT) was ordered that showed multiple hilar and mediastinal adenopathies, thus confirming our hypothesis. We opted for a watchful waiting strategy and maintained treatment with NSAID's. In the following months there was progressive symptomatic resolution. At 7 month follow-up inflammatory markers and cholestasis parameters had normalized. Thoracic CT repetition revealed marked reduction of the adenopathies and absence of pulmonary involvement. One year after the diagnosis the patient is asymptomatic.

Discussion

Löfgren's Syndrome is an acute form of sarcoidosis characterized by the combination of erythema nodosum, hilar adenopathy and arthralgia. This presentation has 95% of diagnostic specificity and, in most cases, remits spontaneously without the need for treatment. In our case, the development of erythema nodosum immediately suggested the diagnosis. This underscores the importance that the skin has in the practice of internal medicine.

#747 - Case Report

CHURG-STRAUSS SYNDROME: A CLINICAL CASE

Ivone Melo Valadão¹, Paulo Ávila², Maria Benites², Almerindo Rego²

¹ Hospital Santo Espírito da Ilha Terceira, Angra Heroísmo, Portugal

² Hospital Santo Espírito da Ilha Terceira, Angra Do Heroísmo, Portugal

Introduction

Eosinophilic granulomatosis with polyangiitis (EGPA), also known as Churg-Strauss syndrome, is a complex multisystemic syndrome with heterogeneous presentation. Most often there is a clinical history of asthma or other atopic conditions and current presentation generally includes signs of cutaneous or pulmonary involvement. EGPA is classified as a small-vessel vasculitis associated with antineutrophil cytoplasmic antibodies (ANCA) and the hypereosinophilic syndromes (HESs) in which vessel inflammation and eosinophilic proliferation are thought to contribute to organ damage. Although still considered an idiopathic condition, EGPA is classically considered a Th2-mediated disease.

Case description

We present a 68-years old man resident in Australia and in holidays in the Azores. He was admitted in ER with complaint of acute mild fatigue, fever, inflammatory pain first localized at the right shoulder and then with evolution for polyarthralgias which began several days ago after arriving. His past medical history includes the diagnosis of asthma at 45-years old, nasal polyposis submitted

at surgery in the past and a history of a transient ischemic attack at 64-years medicated with acetylsalicylic acid and statin. Physical examination on admission showed no remarkable findings beside pain at passive mobilization of the upper and lower extremities. Blood test showed peripheral blood eosinophilia (4300/ μ L) and elevated IgE with no other abnormalities verified. Serologies, blood culture and stool parasites were excluded. A few days after hospitalization for further investigation, the patient developed skin lesions. The biopsy showed characteristics of a small-vessel vasculitis. After the diagnosis the patient started treatment with oral prednisone (1mg/Kg ideal body weight per day) with improvement of symptoms.

Discussion

Five-year survival rates in patients with EGPA have been improved by combination therapy of corticoids and immunosuppressants (cyclophosphamide for induction and azathioprine for maintenance therapy), especially in patients with poor-prognosis factors (i.e., involvement(s) of the gastrointestinal tract, heart, and/or kidney). Complete remission can be achieved in over 90% of these patients.

#759 - Case Report

WHEN THE TREATMENT BECOMES THE DISEASE: DRUG-INDUCED THROMBOTIC THROMBOCYTOPENIC PURPURA

Rui Seixas, Paula Pereira, Pedro Moreira, Armindo Ribeiro, José Sousa E Costa

Unidade Local de Saúde do Litoral Alentejano, Santiago Do Cacém, Portugal

Introduction

Nowadays there is an increasing number of medical treatments available, however the incidence of side effects grows at a parallel rate. Non-steroidal anti-inflammatory drugs (NSAIDs) are among the most common drugs prescribed making it important to be aware that these medications are a potential cause of thrombotic thrombocytopenic purpura (TTP).

Case description

An 85-year-old man with a medical history of arterial hypertension, medicated with losartan and hydrochlorothiazide, was admitted in the Emergency Room (ER) due to the sudden appearance of petechial lesions spread across the legs and bleeding gums for the last 4 days. He had come to the ER 5 days before due to edema and pain of the right hallux which was diagnosed as gout and treated with diclofenac and colchicine. These new symptoms had appeared the day after taking this medication. Clinical examination showed a well-nourished man with coughing and spitting bloody mucus and multiple petechial lesions spread across both legs below the knee. Blood pressure was 132/74 millimeters of mercury (mm Hg), heart rate of 64 beats per minute (bpm) and peripheral arterial saturation of 98%. While waiting for further medical evaluation he

lost consciousness and was taken to the emergency room where he had a sizeable hematochezia. He regained consciousness spontaneously. Blood test results showed thrombocytopenia with 2000 platelets, 7700 leukocytes and 12.2 grams of hemoglobin per deciliter (g/dL) and raised liver enzymes. Due to the hemorrhagic risk he was transferred to the Intensive Care Unit. A blood sample was collected prior to platelet transfusion to test for anti-platelet antibodies and viral serologies. Treatment was initiated with platelet transfusion (3 pools in total), methylprednisolone and human immunoglobulin. He showed poor initial response to the treatment. Bone marrow aspiration showed a high number of antiplatelet antibodies and the immune study revealed a strong positivity for antiplatelet antibodies specific for both diclofenac and colchicine. He maintained treatment with corticosteroids with progressive improvement of the thrombocytopenia and was transferred to the infirmary being discharged 8 days later with a platelet count of 232000.

Discussion

As doctors we prescribe medication to treat any number of conditions, but we should always be aware of the possible side effects of such treatments especially when dealing with older and more fragile patients.

#816 - Medical Image

ULCERATED SYSTEMIC SCLEROSIS

Ana Clara Dinis¹, Telma Elias¹, Isabel Martins¹, Fátima Pimenta¹, Lídia Caley², Daniela Brito²

¹ CHMT - Hospital de Abrantes, Abrantes, Portugal

² CHMT-Abrantes, Abrantes, Portugal

Clinical summary

Systemic sclerosis is a systemic disease, characterized by fibrosis and vasculopathy, with multiorgan involvement and variable morbidity. Cutaneous involvement is often present with digital ulcers refractory to usual therapy, sometimes causing significant functional limitation. These can evolve from sclerodactyly with superficial ulcers to ischemia, deep necrosis, gangrene, loss of substance, and consequent amputation of the fingers.

The authors present images that elucidate the temporal evolution (immediately before and after 6 days of treatment with Iloprost), with clinical improvement and cicatrization of the digital ulcers.

In 80 year old woman with systemic sclerosis, associated with Raynaud's phenomenon. Presence of fingers on puffy fingers.

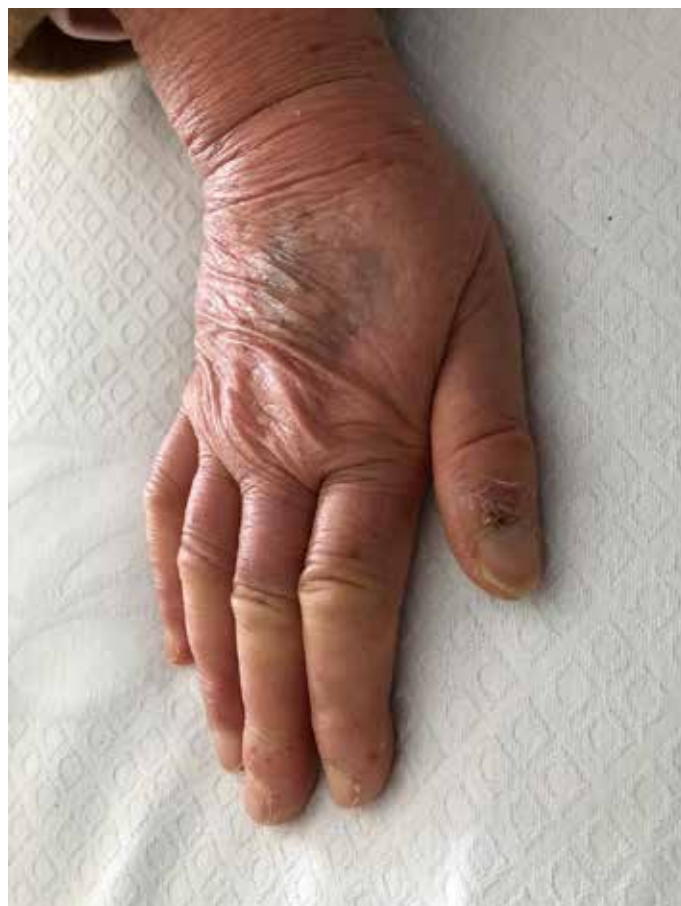

Figure #816. Digital ulcer before treatment with iloprost.

#817 - Case Report

ADULT ONSET STILL'S DISEASE: A CASE OF FEVER OF UNKNOWN ORIGIN

Christina Kotsiari, Dimitrios Tsiolpidis, Palmyra Tsiftsi, Chasan Ali, Bilal Bilal, Vasilios Tsipizidis, Asimina Migdalia, Berkay Mollagiousoufoglou, Theodoros Kostakis, Argyrios Tsatsakoulis, Paschalis Karagiozakis, Alexandros Kakaris, [Triada Exiara](#)
General Hospital of Komotini, Komotini, Greece

Introduction

Adult onset Still's disease (AOSD) is a rare entity, presenting with a wide spectrum of clinical and laboratory findings. In the absence of specific clinical or laboratory findings it is usually a diagnosis of exclusion.

Case description

A 67-year-old previously healthy female, was admitted with a two-month history of fever, weight loss, fatigue and generalized arthralgia. She had visited multiple hospitals, where she had already been treated with many antibiotics and non-steroid without any improvement in her symptoms. We proceeded with the search for infectious, neoplastic or autoimmune potential, but all those complementary studies turned out negative. Laboratory findings were in normal range except erythrocyte sedimentation rate and C-reactive protein. Cardiovascular and

neurological examinations were unremarkable. Transesophageal and transthoracic echocardiography was normal. Her blood, urine and sputum cultures showed no growth. Acid-fast bacillus smear and culture and quantiferon were negative. IgM CMV, EBV, HIV, hepatitis B and C were negative. Malarial parasite, Widal and Brucella serology was negative. CT-chest and abdomen showed multiple and generalized lymphadenopathy. Biopsy from axillary lymph was negative for malignancy. ANA, rheumatoid factor was negative. Her ferritin levels were >4000 ng/dl which were reconfirmed by second sample. Transferrin saturation was normal. She initiated therapy with corticoids, to which the patient responded with apyrexia and no arthralgic complaints. Six months later at the follow up the patient is in very good condition without any symptoms.

Discussion

AOSD presenting as fever of unknown origin could be a challenge for the physician to diagnose and manage timely.

#852 - Abstract

IMMUNE PROFILE AND CLINICAL CORRELATIONS IN SYSTEMIC LUPUS

Amel Rezgui, Maissa Thabet, Monia Karmeni, Jihed Anoun, Fatma Ben Fredj, Chedia Laouani

Université de Sousse, Faculté de Médecine de Sousse, Hôpital Sahloul, Service de Médecine Interne, Unité de Recherche de Gériatrie et Gériatrie Clinique, Sousse, Tunisia

Background

We aimed to analyse the clinical features, autoantibody profile and we searched for possible clinical correlations of Tunisian patients with newly diagnosed systemic lupus erythematosus (SLE).

Methods

Antinuclear antibodies (ANA) were detected by an immunofluorescence method, anti-dsDNA and anti-cardiolipin (aCL) antibodies by ELISA, antinucleosome and anti-extractible nuclear antigens (or anti-ENA : anti-Sm, anti-RNP, anti-SSA and anti-SSB) by immunodot.

Results

The mean age of the patients was 32,5 years and the sex-ratio F/M was 12. The most common initial features were haematological (71%) and cutaneous (54%) disorders. ANA were detected in 95,5%, anti-dsDNA in 89,7%, antinucleosome in 82,8%, anti-histones in 37,5%, anti-Sm in 47,5%, anti-RNP in 60%, anti-SSA in 66,7% and anti-SSB in 37,5% of patients. Hypocomplementemia and cryoglobulinemia were detected in 75 and 26% of the patients respectively. The significant clinical associations were those of cutaneous involvement and anti Sm, rheumatologic disorders and anti dsDNA, hypocomplementemia and neurolupus, and nephropathy and AAN's rate.

Conclusion

Our results confirm the clinical polymorphism of SLE, the high frequency of antinucleosome antibodies at time of diagnosis and the predominance of anti-SSA among anti-ENA antibodies.

#864 - Abstract

HIP INVOLVEMENT IN RHEUMATIC DISEASES

Safa Rahmouni, Maroua Slouma, Rim Dhahri, Leila Metoui, Najeh Boussetta, Nour Gueddiche, Feida Laajili, Imen Gharsallah, Bassem Louzir

Military Hospital of Instruction of Tunisi, Tunisi, Tunisia

Background

Hip involvement is responsible of functional impairment in patients with chronic inflammatory rheumatism (CIR).

This study aimed to describe the epidemiological and clinical characteristics of hip involvement and to determine factors associated to hip involvement in patients with rheumatoid arthritis RA and spondyloarthritis (SA).

Methods

A retrospective study conducted including 192 patients: 82 patients were diagnosed with RA and 110 with AS. We reviewed the medical records of all patients. Measure of disease activity used were the Bath Ankylosing Spondylitis Disease Activity Index (BASDAI) for SA and Disease activity score (DAS28-ESR) for RA.

Results

The mean age was 48.45 + 13.9 years. Sex Ratio was 1.06. Disease duration was 109+ 69 months.

High activity of disease was noted in 53.6% of the cases (45.12% in RA and 63.76% in SA).

Among the 190 patients, 51 had hip involvement (26.56%). It was more frequent in patients with AS than in RA (39.09% vs 9.75, p=0.00).

Bilateral hip involvement was noted in 72.54 % cases.

Hip involvement was diagnosed at the time of the diagnosis of CIR in 54.9% (25% in RA vs 76.47% in SA, p=0.079). For the other patients, the average delay between the hip involvement and the diagnosis of CIR was 36.7 months (65.14 months in RA vs 31.65 months in SA, p=0.062)

MRI was necessary in 39.21 % of cases

The mean C reactive protein and erythrocyte sedimentation were 29.48 mg/dL and 38.27 mm/h respectively. Patients with hip involvement didn't have higher inflammatory biomarkers (ESR : 28.22 mm/h vs 29.22 mm/h, p=0.979; CRP: 55.01 mg/dL vs 36.36 mg/dL, p= 0.096).

Hip involvement was more common in smokers (41.07% vs 20.58, p=0.003) and in patients with high disease activity (35.8% vs 15.71%, p=0.005)

Sex, age, disease duration were not significantly associated with hip arthritis.

Regarding patients with RA, all patients with hip involvement had

blood type O positive ($p = 0.034$), and had more active disease (DAS28 = 6.25 vs 5.07, $p = 0.016$).

Total hip arthroplasty were required in ten patients (five in RA and five in SA)

Conclusion

Our study showed that hip involvement is frequent in patients with in AS and RA. It may occur at any time of the disease progression. Smoking and high disease activity were associated with hip disease.

Its management must be early and adapted to prevent structural damage and the prevent the need for hip replacement surgery.

#865 - Case Report

HYPOGLYCEMIA IN PRESENCE OF ANTI-INSULIN RECEPTOR ANTIBODIES

Joao Frutuoso, Patricia Soares, Margarida Lopes, José Vaz
ULSBA, Beja, Portugal

Introduction

Hypoglycemia is often medical induced or due to malnourishing. There is a rare type of hypoglycemia due to autoimmune mechanisms. Although generally related to insulin antibodies, there are some cases related to anti-insulin receptors which have an ill-defined mechanism.

Case description

82-year-old patient, female, with heart failure, primary biliary cirrhosis, seropositive rheumatoid arthritis, Sjogren syndrome, osteoporosis, hypertension and atrial fibrillation. Since the patient was mostly asymptomatic in the last few years, in terms of rheumatoid arthritis, the attending physician was reducing corticotherapy.

She was admitted in the emergency room due to pneumonia. In the initial checkup, beside dyspnea, rhonchus and fever, hypoglycemia was detected without any antidiabetic medication or malnourishing.

The pneumonia was easily dealt with intravenous antibiotics.

In order to study the hypoglycemia lab works were preformed (Insulin, proinsulin, cortisol, ACTH, cromogranine A, NSE 5-HIAA, somatostatin, IGF-1 and IGF2 with normal serum values, Anti insulin antibodies were negative, anti-insulin receptor were positive- two fold the reference range), Ct scan showed no suspicious lesions, with an unsuspecting pancreas. Further study was performed with a PET scan with ^{68}Ga -DOTANOC, that showed no insulinomas.

Although the anti-insulin antibodies were negative the patient started prednisolone 1mg/kg/day with no recurrence of hypoglycemia.

Discussion

Autoimmune hypoglycemias are rare, and occur more frequently in younger patients with Japanese ancestry and/or Graves disease.

It was possible that due to longstanding immune suppression, the disease manifested in later life.

#867 - Abstract

COMORBIDITIES IN PATIENTS WITH CHRONIC INFLAMMATORY RHEUMATISM: RHEUMATOID ARTHRITIS AND SPONDYLOARTHRITIS

Safa Rahmouni, Maroua Slouma, Rim Dhahri, Leila Metoui, Najeh Boussetta, Nour Gueddiche, Feida Ajili, Imen Gharsallah, Bassem Louzir

Military Hospital of Instruction of Tunisi, Tunisi, Tunisia

Background

It is known that chronic inflammatory rheumatism (CIR) are associated with an increase in the prevalence of comorbidities. This study aimed to determine the frequency of comorbidities to assess factors associated to comorbidities in patients with rheumatoid arthritis RA and spondyloarthritis (SA)

Methods

The study included 192 patients.: G0 including patients with RA and G1 patients with AS.

Measure of disease activity used were the Bath Ankylosing Spondylitis Disease Activity Index (BASDAI) for SA and Disease activity score (DAS28-ESR) for RA. For each patient we screened for history or current evidence of comorbidities :Ischaemic cardiovascular disease (myocardial infarction, stroke), cancers, gastrointestinal diseases (diverticulitis,ulcers), infections (hepatitis, tuberculosis), osteoporosis and depression.

Results

The mean age was 48.45 ± 13.9 years. Sex Ratio was 1.06. Disease duration was 109 ± 69 months.

Biological treatments were prescribed in 40.62%. Steroid treatment was used in 95.1% of G0 with an average dose of 9.42 mg.

High activity of disease was noted in 53.6% of the cases (45.12% in G0 and 63.76% in G1.

Among the 190 patients, comorbidities were noted in 35.93% (G0: 39% (n=32) G1: 33.6% (n=37); $p=0.55$)

Ten patients (5.26%) had more than two comorbidities and 25.52 % had only one comorbidity.

Osteoporosis was the most frequent comorbidity noted in 23.43% (G0: 38% (n=31) G1: 13% (n=14); $p=0.002$). Ischaemic cardiovascular disease was noted in four patients: myocardial infarction (three patients), stroke (one patient). Depression was observed in 8.33% ((G0: 10.1% (n=9) G1: 6.36% (n=7); $p=0.045$). Latent tuberculosis infection was noted in 9.37 G0: 9.75% (n=8) G1: 9.09% (n=10). Seven patients had hepatitis (B and C). Two patients with RA had cancer (gastric lymphoma and endometrial cancer).

The mean C reactive protein and erythrocyte sedimentation were 29.48 mg/dL and 38.27 mm/h respectively.

Patients with comorbidities didn't have higher inflammatory biomarkers (ESR: 35.91 mm/h vs 39.57mm/h , $p=0.406$; CRP: 28.31 mg/dL vs 30.10 mg/dL, $p=0.784$).

Comorbidities were more common in patients having biological therapy (44.87% vs 28.97, $p=0.023$)

Sex, age, disease duration, smoking status were not significantly associated with comorbidity.

Conclusion

Our study showed that comorbidity is frequent in patients with CIR. It seems to be more common in patients having biologics which could be explained by the severity of the disease. Osteoporosis was the most frequent comorbidity.

#869 - Case Report

OVERLAPPING DIFFICULTIES: TREATMENT AND DIAGNOSIS CHALLENGES

Joana Isabel Marques, Sara Mendonça Freitas, Silvia Santos Balhana, Ana Grilo, Ana Isabel Reis, Fernando Martos Gonçalves, José Lomelino Araújo

Hospital Beatriz Ângelo, Lisboa, Portugal

Introduction

The major autoimmune hepatic diseases are autoimmune hepatitis (AIH), primary biliary cirrhosis (PBC) and primary sclerosing cholangitis (PSC). Overlap syndromes occur in 3-7% of cases. The diagnosis of these syndromes requires identification of manifestations, laboratory abnormalities, immunology, imageology or biopsy findings that meet criteria for both conditions.

Case description

The first case reports a 38-year-old woman, diagnosed at age 11 with Crohn's disease and at age 16 with PSC. By that time, there was evidence of cholestasis and imaging evidence of stenosis that led to the use of ursodeoxycholic acid with signs of improvement. At age of 18, laboratory data revealed a deteriorating cholestatic pattern but also evidence of hepatic cytolysis. Immunology revealed only positivity to antinuclear antibodies (ANA), titre 1:160, homogeneous pattern. A liver biopsy was performed that showed severe hepatitis with bridging necrosis and periportal inflammatory infiltrate leading to the diagnosis of AIH. Steroid and azathioprine was associated to treatment regimen. Persistence of clinical and laboratory abnormalities led to the start of mycophenolate mofetil. As the disease progressed the patient underwent liver transplantation at the age of 37. Most recent imaging shows recurrence of PSC in the transplanted liver.

The second case refers to a 35-year-old man diagnosed at 27 years old with AIH. He presented with abdominal pain and jaundice. Laboratory results showed hepatic cytolysis with no remarkable abnormalities in the image exams. The biopsy revealed moderate

inflammation and mild fibrosis, confirming the diagnosis. At the age of 33 a pattern of cholestasis was verified, and immunology revealed ANA, titre 1:640, 3E (BPO) pattern, with positive anti-liver soluble antigen and anti-mitochondrial antibodies, leading to diagnosis of PBC. Initially was medicated with azathioprine and corticoids, but due to deteriorating of cytocholestatic was changed to mycophenolate mofetil and low dose corticoids, remaining stable.

Discussion

Autoimmune liver disease overlap syndromes are a real challenge regarding diagnostic and therapy. These clinical reports remind us of the importance in keeping regular follow-up and additional study although there is an established diagnosis, as both cases had significant impact in treatment choice. The first case reflects the difficulties in the therapeutic management and the possibility of recurrence even after transplantation.

#879 - Case Report

VOGT-KOYANAGI-HARADA DISEASE IN ITS INCOMPLETE FORM: A CASE REPORT

Victor Bemfica¹, Renata Fachada^{1,2}, Bianca Feldman¹, Rafaela Mamfrim¹, Thales Rizzi¹, Thaisy Secco¹, Luiza Flores¹, Rodrigo Freitas^{1,3}, Suzete Barros¹

¹ Hospital Municipal Miguel Couto, Rio De Janeiro, Brazil

² Fundação Técnica Souza Marques, Rio de Janeiro, Brazil

³ Instituto Nacional de Infectologia Evandro Chagas, Rio de Janeiro, Brazil

Introduction

Vogt-Koyanagi-Harada Disease (VKHD) is a rare granulomatous inflammatory disease and an important cause of noninfectious uveitis. Prevalence varies worldwide affecting, more frequently, individuals of pigmented skin, such as persons of East Asian, Middle Eastern, Hispanic, and Native American descent. It affects pigmented structures, such as eye, inner ear, meninges, skin and hair.

Prompt diagnosis followed by an early treatment with corticosteroids and immunosuppressive agents is most often ensued by good visual outcomes and thus avoid complications.

Case description

A 40-year-old brown woman, without previous comorbidities, sought medical attention reporting a seven-day history of a frontal headache with a pulsatile, intense and constant character, evolving with bilateral blurred vision and conjunctival hyperemia. She didn't present any other signs or symptoms, despite an underlying report of flu-like symptoms two weeks before the headache onset. Cranial CT and a Magnetic Resonance Angiography was performed without evidence of any specific alterations. Fundoscopy showed a papillary edema with bilateral serous retinal detachment and normal intraocular pressure. A cerebrospinal fluid screening showed normal opening pressure, hyperproteinorrachia, mononuclear pleocytosis, normal glycorrachia and a negative and

thorough investigation for most related infectious agents. After the screening findings in addition with the clinical presentation, VKHD in its incomplete form became the imperative diagnosis and high-doses of corticosteroids therapy was initiated and sustained.

The patient evolved with a good visual outcomes and symptoms remission, being discharged from hospital with an ambulatory follow up.

Discussion

VKHD is an autoimmune inflammatory condition mediated by T cells that target melanocytes, generally after a viral trigger, in the presence of HLA-DRB1*0405 allele. There are four different phases: prodromal, uveitic, convalescent, and recurrent, with extraocular manifestations including headache, meningismus, hearing loss, poliosis and vitiligo, to varying degrees. A severe bilateral, granulomatous panuveitis associated with serous retinal detachment, causes a significant impact for patient's life.

There are no laboratory tests that diagnose VKHD, rather, the diagnosis is clinical. Early diagnosis coupled with corticosteroids to achieve expeditious inflammation control, followed by long-term corticosteroid-sparing immunomodulatory treatment is the ideal goal.

#881 - Case Report

SYSTEMIC LUPUS ERYTHEMATOSUS AND EBV INFECTION

Francisco Pombo, Marina Mendes, Juliana Lopes, André Paupério, Pedro Lopes

Centro Hospitalar do Tâmega e Sousa, Penafiel, Portugal

Introduction

Systemic lupus erythematosus is an autoimmune disease that can affect every organ, with multiple manifestations. It can range from mild symptoms to severe life threatening conditions. In this case we report one patient who had a lupus diagnosis in the context of EBV infection.

Case description

We report a case of a 50 years old female, with prior medical history of epilepsy since childhood, presenting to the emergency department with fever, cough, myalgias, bleeding oral ulcers and submandibular adenopathies with 3 weeks evolution. The workup included a complete blood count, which revealed severe pancytopenia. There was a high sedimentation velocity (66mm) with negative C-reactive protein, high lactic dehydrogenase and ferritin and normal kidney, liver and thyroid function. Bone marrow aspiration showed normal karyotype and the presence of anomalous granulocytic and erythrocytic precursors. Chronic Epstein-Barr virus (EBV) infection was documented with positive IgG and negative IgM, with 2.5x10³ copies/mL by PCR. Other infections such as HIV, HCV, HBV, adenovirus, enterovirus, cryptococcus, rickettsia, borrelia, leishmania and tuberculosis

were all excluded. Immunological analysis showed a highly positive titer for anti-dsDNA (296UI/mL) and complement consumption (C3 24mg/dL; C4 <5mg/dL). A CT scan showed small pleural and pericardial effusions. With all the characteristics present, the diagnosis of systemic lupus erythematosus was made. Initial treatment with corticosteroid pulses and immunoglobulins had no clinical response. An axillary lymph node excisional biopsy was performed showing histiocytic necrotizing lymphadenitis. After completion of 12 days therapy with anakinra, with no clinical response, and after exclusion of the presence of B-cell lymphoma, therapy with rituximab was introduced. After 27 days, there was a deterioration of the clinical condition due to septic shock associated to hospital acquired pneumonia. Admitted to the ICU, the patient eventually die

Discussion

Infection with EBV is an environmental risk factor for the development of lupus. Even though it is an ubiquitous infection, in this particular case, we were able to detect the presence of the virus by PCR. It is thought that patients with lupus have an abnormal response to the infection, resulting in autoimmunity several years later. Lupus has a wide range of manifestations and prognosis. In this case, our patient had a severe clinical condition with rapid evolution from first symptoms to death.

#882 - Case Report

ANTERIOR ISCHEMIC OPTIC NEUROPATHY ASSOCIATED WITH GIANT CELL ARTERITIS

Daniela Antunes, Joana Cordeiro E Cunha, Andreia Coutinho, Carla Pinto, Augusto Duarte

Centro Hospitalar Médio Ave, Famalicão, Portugal

Introduction

Giant cell arteritis (GCA) is a systemic vasculitis that arises in the elderly, can occur with systemic, neurological and ophthalmologic complications. Anterior Ischemic optic neuropathy (AION) is in most cases associated with atherosclerotic disease, being only in 5% associated with GCA.

GCA is the most common primary vasculitis in the elderly, and the typical pattern is characterized by the presence of cranial ischemic manifestations such as headache, claudication of the jaw or visual loss. It is often associated with rheumatic polymyalgia (PMR), a disease that affects the shoulders and proximal portions of the arms in individuals over 50 years of age.

Case description

The authors present the case of an autonomous 78-year-old woman with a history of atrial fibrillation, essential hypertension and dyslipidemia, followed by outpatient clinic of pain due to osteoarticular disease. She was admitted to the emergency department due to a decrease in the visual acuity of the left eye with 24 hours of evolution and holocranial pressure type headaches with irradiation to the jaws that did not improve

despite previously prescribed analgesia. She reported for 6-months headache and osteoarticular pain in the scapular region that limited the activities of daily routine. She was diagnosed as anterior ischemic optic neuropathy by the ophthalmologist. She took a pulse of Intravenous methylprednisolone at 15 mg/kg for the first three days and then continued with prednisolone 60mg daily. Laboratory findings indicated normocytic normochromic anemia with hemoglobin of 10.3 g/dl; C-reactive protein of 20 mg/dl; erythrocyte sedimentation rate 40 mm; immunological study (antibodies against neutrophilic cytoplasmic antigens and antinuclear antibodies) negative; serologies for human immunodeficiency virus, hepatitis B, hepatitis C negative; normal vitamin B12 and increased ferritin. Temporal artery biopsy was compatible with GCA. Brain and orbital magnetic resonance imaging showed multiple foci of hypersignal bilateral protrusions translating lesions of ischemic nature and sequelae of infarction into territory of the left cerebral artery in the parietal lobe. The cardiovascular causes of AION were excluded. There was no recovery of visual acuity and diabetes developed by the corticosteroid therapy.

Discussion

GCA should be considered in the differential diagnosis of headache in the elderly, requiring a high degree of suspicion, with visual complications being preventable with early diagnosis and early therapy.

#895 - Case Report

MORE THAN A PNEUMONIA

Vera Seara, Marta Rafael Marques, Susana Marques De Sousa, Juliana Chen Xu, Cristina Marques, Teresa Pinto
CHPVVC, Vila Do Conde, Portugal

Introduction

Variable common immunodeficiency (VCI) is a primary immune disease, characterised by decreased IgG, IgA and IgM concentration and decreased or absent response to immunisations, in the absence of another immunodeficiency state. The age of diagnosis is variable, usually occurring in the 3rd to 5th decades of life.

Case description

The authors present the case of a 40-year-old male, independent, with past medical history of recurrent infections: community acquired pneumonia 1 year ago, requiring hospitalisation in the intensive care unit; chronic rhinosinusitis, diagnosed in childhood and with episodes of annual exacerbations; acute otitis media and urinary tract infections. There was no use of chronic medication. The patient went to the emergency department after two days of malaise, fever and headache symptoms. In the initial evaluation, he presented hypotension, tachycardia, fever and reduction of the vesicular murmur on the right base on the pulmonary auscultation was noted. He was admitted with a diagnosis of community acquired pneumonia, with hypoxemic respiratory failure. He

completed a 7-day cycle of empirical antibiotic therapy with amoxicillin/clavulanic acid and azithromycin and microbiology tests showed no growth. The blood tests with viral markers were negative and CT scan showed residual pneumonic infiltrates in the lower lobe of the right lung, with no other significant changes. Given the past medical history of recurrent infections, more exams were made, and revealed a decrease in IgG, IgA and IgM immunoglobulin values, a decrease in IgG subclasses, a decrease in gamma-globulin in protein electrophoresis and a very low response to tetanus and diphtheria vaccine. On the flow cytometry immunophenotyping of lymphocytes, there were CD4 T cell lymphopenia, B cell lymphopenia and decreased memory B cells. With diagnosis of VCI, after resolution of the infection, he was discharged and referred to the clinical immunology clinic.

Discussion

VCI is the most common form of severe antibody deficiency, but it presents a complexity of clinical manifestations and complications. It should be considered a diagnostic hypothesis, if there is a strong medical history of recurrent infections in young and apparently immunocompetent patients. The therapeutic approach consists of immunoglobulin replacement.

#906 - Case Report

TWO RARE CASES OF OVERLAPPING AUTOIMMUNE DISEASES: SYSTEMIC SCLEROSIS + AUTOIMMUNE HEPATITIS AND POLYARTERITIS NODOSA + SYSTEMIC LUPUS ERYTHEMATOSUS

Cristina Silva, Sara Freitas, Glória Alves, Jorge Cotter
Hospital da Senhora da Oliveira, Guimarães, Portugal

Introduction

The overlap between autoimmune diseases is a manifestation of their complex physiopathology. The overlap of Systemic Sclerosis (SS) with Autoimmune Hepatitis (AIH) and Polyarteritis Nodosa (PAN) with Systemic Lupus Erythematosus (SLE) are rarely described in literature.

Case description

A 73 years old female was diagnosed with CREST syndrome at 30. She is under antiplatelet aggregation and calcium channel blocker and she was submitted to cervical sympathectomy for Raynaud's phenomenon control. She remained stable until March 2013, when a medium effort dyspnea started. Thoracic high resolution computed tomography showed ground glass opacification; bronchofibroscopy documented a neutrophilic alveolitis. She started cyclophosphamide. At the same time, she presented with elevation of aminotransferases, bilirubin, gammaglutamyltransferase and alkaline phosphatase, hypoalbuminemia and positive antinuclear (1/640) and anti-smooth muscle antibodies. The liver biopsy was compatible with AIH. She started corticosteroids with resolution of liver enzymes

abnormalities. Posteriorly, she received maintenance treatment with azathioprine, which had to be suspended after acute pancreatitis. After that, it was decided to start mycophenolate mofetil, with resolution of liver and pulmonary abnormalities.

A 50 years old female was diagnosed with PAN in 2006, when she was hospitalized because of tetraparesis and weight loss. At that time, it was documented acute axonal polyneuropathy, systolic blood pressure >190 mmHg, weight loss >10% of body weight, livedo reticularis, cerebral involvement and small vessels vasculitis in muscle biopsy. She received cyclophosphamide and corticosteroids as induction therapy and she started intensive motor rehabilitation, with progressive recovery of the performance status. Posteriorly, she received maintenance therapy with azathioprine. She remained asymptomatic until 2013, when it appeared erythematous lesions in the face and scalp. Skin biopsy was compatible with lupus discoid. She also presented with positive antinuclear (1/320) and anti-dsDNA antibodies and low C4. The diagnosis of SLE was established and she started hydroxychloroquine with disappearance of skin lesions.

Discussion

The overlap between AIH and connective tissue diseases like SS is rare. The reported cases are mainly of limited SS and the diagnosis of SS generally precedes the diagnosis of AIH, as in our case. The overlap between PAN and SLE is even rarer – to our knowledge this is the second case report.

#909 - Case Report

MULTIPLE MYELOMA ASSOCIATED POLYMYOSITIS – A CASE REPORT

Cristina Silva, Joana Mendonça, Clarisse Neves, Sara Freitas, Glória Alves, Jorge Cotter

Hospital da Senhora da Oliveira, Guimarães, Portugal

Introduction

Idiopathic inflammatory myopathies (IIM) are a group of rare and heterogeneous diseases, which includes polymyositis (PM). PM is a subacute proximal myopathy and its association with malignancy is well established. Therefore, screening of the most commonly associated neoplasms is prudent, with at least comprehensive history and examination and age appropriate screening; the utility of further tests is not yet clarified.

Case description

A 43 years old male, with no relevant personal history, was admitted to the Emergency Department because of generalized muscle weakness and paresthesia of the upper limbs that started in the previous week. It was documented elevated creatine kinase (12812 UI/L) and transaminase elevations 10 times the ULN. He was submitted to intravenous fluid therapy, with resolution of rhabdomyolysis and hepatic cytolysis in a few days and progressive improvement of general condition and muscle strength. Electromyography showed “evident myositic/myopathic

abnormalities of the proximal muscle masses of the upper and lower limbs, possibly suggesting a metabolic/inflammatory process without active muscle necrosis”. Muscle biopsy revealed “increased diameter variability of atrophied fibers with rounded or angled contours, without inflammatory infiltrates”. Liver biopsy showed “a very discrete reactive chronic inflammatory process – nonspecific aspects, probably resulting from a previous more intense hepatocyte stress/lesion”. Immunological study and viral serologies were negative. He continued the follow up in the Internal Medicine Outpatient Clinic, with fluctuating complaints of proximal muscle weakness, without any other symptoms or signs. The most common malignancies were screened. Almost a year later, a monoclonal IgG kappa light chain band was detected in immunoelectrophoresis. Bone marrow aspirate showed 11% of plasmocytes. Immunophenotyping of peripheral blood and bone marrow cells revealed 0.5% plasmocytes, 47% of them with phenotypic abnormalities – strong CD38 expression/CD138+/CD19-/CD56+/CD10-/CD20-/low CD45 expression/CD117-. The diagnosis of IgG kappa type multiple myeloma was established and the patient was referred to Hemato-Oncology.

Discussion

The association between IIM and increased risk of cancer is well-known and the risk of malignancy is highest in the year prior and the year after IIM onset. This case intends to illustrate that association, which may occur several months to years after the diagnosis of PM.

#938 - Case Report

INFLAMMATORY MYOSITIS PRESENTING AS A MUSCULAR MASS

Ana Ferreira, Jaime Oliveira, João Ramos, Patrícia Lourenço, Jorge Almeida

Centro Hospitalar Universitário de São João, Porto, Portugal

Introduction

Inflammatory myopathies are classified by clinicopathological characteristics. This allows the distinction from other systemic diseases which is crucial to define therapeutic strategies.

Case description

Woman, 53 years old, with no previous diseases, presents to the ER with a 5-day history of a swollen on the left forearm and paresthesias on the territory of the cubital and median nerves. She denied any new pill ingestion, fever, trauma or animal bites. She had a tumefaction on the left forearm’s proximal third, 3x4 cm, warm, tender, only with limitation in the extension of the elbow. Radial and cubital pulses were both palpable. Analytically, with no elevation of C-reactive protein, normal liver panel and renal function, LDH 171U/L, CK 114U/L, mioglobin 23.4 ng/ml. Ultrasound: muscular edema. She was discharged home with corticotherapy and anti-inflammatory. An autoimmune study was performed in ambulatory: sedimentary rate 10mm/1st; normal

proteinogram; ANA, anti-ML and anti-ENA antibodies were negatives; myositides associated antibodies – anti-Mi-2 borderline, remaining autoimmunity: negative. She returned to the ER 2 days later with exacerbation of the inflammatory signs. She still had no alterations in inflammatory analytical parameters, muscular enzymes and no evidence of compartment syndrome. She was admitted in the internal medicine ward. Forearm roentgenogram: no fracture, gas or other alterations. MRI: no expansion lesion and signal alteration of the braquiorradial muscle; but enlightenment after contrast-enhanced image suggesting myositis. Ultrasound-guided muscle core-biopsy (intervention radiology): fragments of striated muscle dissociated by fibroblast fusiform cells without atypia and low mitotic index. To study an eventual paraneoplastic process or a systemic inflammatory disease, a toracoabdominopelvic CT and mammography were performed: normal. Muscular biopsy was repeated, this time with collection of muscular fibers (plastic surgery) showed signs of myositis in a pattern of juxtaposition with the perimysium, with T CD4+ lymphocytes, in muscular tissue and adjacent fascia. She then started anti-inflammatory medication with reduction of the tumefaction and inflammatory signs and symptoms improvement.

Discussion

We did not have the diagnosis of a specific type of myositis; however several factors indicated muscular inflammation. We remember the possibility of development to a compartment syndrome, as well as the remote likelihood of being part of a paraneoplastic syndrome.

#941 - Case Report

POLYMYALGIA RHEUMATICA – A DIAGNOSTIC CHALLENGE

Rita Varudo, Rosa Alves, Tiago Ferreira, Tiago Judas

Garcia de Orta Hospital, Almada, Portugal

Introduction

Polymyalgia Rheumatica is a common chronic inflammatory condition from unknown etiology, many times misdiagnosed since is a diagnosis of exclusion and through the inexistence of specific diagnostic exams. Corticotherapy is considered the right treatment and the fast response to lower doses of corticosteroids is considered pathognomonic.

Case description

We present a case of a 75-year-old woman, with clinical history of primary hyperparathyroidism, conditioning hypercalcemia and widespread osseous pain, submitted to parathyroidectomy, diabetes mellitus type 2, chronic kidney disease (CKD), anemia of chronic disease and pulmonary thromboembolism. The patient was selectively hospitalized with general condition depression, lumbalgia and worsening anemia. She had already done a bone scintigram where was identified a lytic thoracic vertebrae lesion. In admission the subject revealed pain in the lumbar spine,

pelvic and shoulder girdle. The blood test revealed normocytic normochromic anemia requiring a transfusion support, high levels of erythrocyte sedimentation rate (ESR) and parathyroid hormone, changes that have taken place in a CKD context, having the patient initialized treatment with folic acid and erythropoiesis stimulating agents.

The CT scanning of the spine showed the existence of multiple fractures in the bones and serious spinal stenosis, without surgical indication. After neoplastic and infection causes excluded and having pain symptoms involving the pelvic and shoulder girdle, aggravated anemia and high levels of ESR, polymyalgia rheumatica was accepted as a hypothesis and a low dosage of corticoid was initiated, resulting in an improvement in blood test and clinic results.

Discussion

This case shows the difficulty that sometimes is involved in polymyalgia rheumatica diagnosis, being necessary a large degree of clinical suspicion in the presence of manifestations common to many pathologies.

#943 - Medical Image

RHEUMATOID ARTHRITIS HAND DEFORMITY

Joana Ribeiro, Tiago Silva, Iurie Pantazi, Rita Gomes

Unidade Local Saúde Guarda, Guarda, Portugal

Clinical summary

Rheumatoid Arthritis (RA) is a chronic inflammatory systemic disease that affects all organs, including joints, particularly the small joint of the hand and wrist.

The hand deformities have a functional impact on daily life and are an early sign of disease severity. The functional hand limitation depends on the activity of the disease that is reversible and responsive to treatment and the tissue damage that is irreversible and cumulative over time.

These hands belong to a 63-year-old woman, diagnosed long-term RA, medicated with systemic glucocorticoids. She has severe hand deformation characteristic from RA, such as radial deviation of wrist, ulnar deviation of metacarpophalangeal joint and Z-thumb, Swan Neck and Boutonnière deformation.

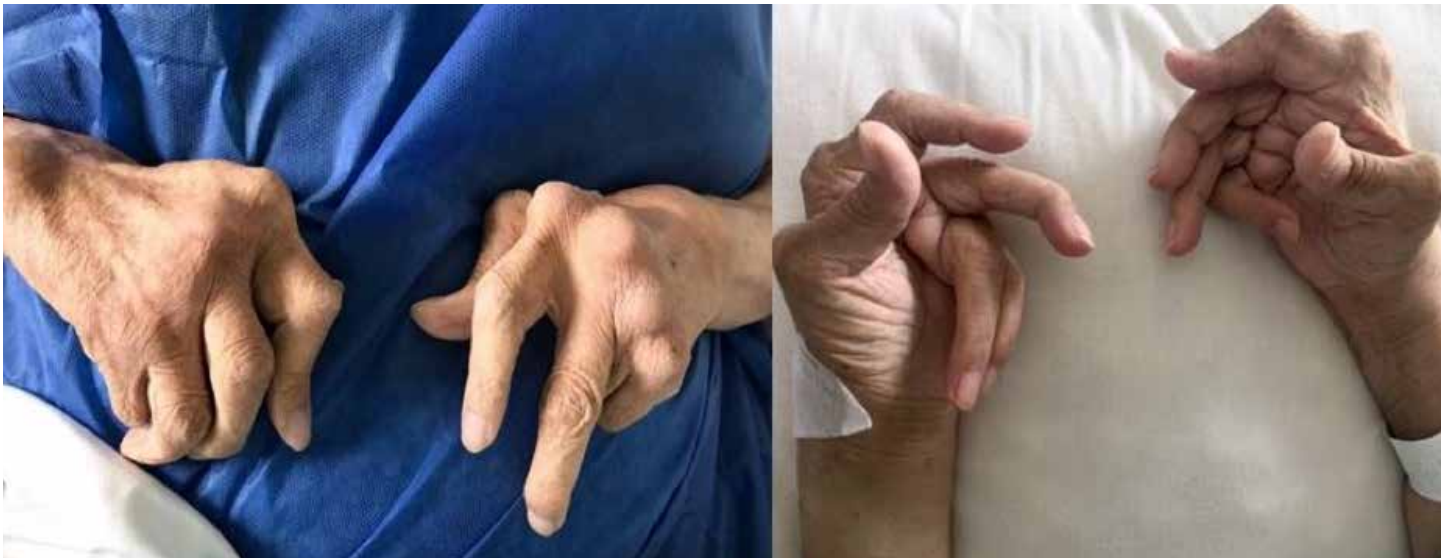

Figure #943.

#946 - Case Report

THE SCHMIDT'S BEHIND THE TAN

Gabriela Venade, Sofia Costa Martins, Luis Costa Matos, Cátia Figueiredo, Catarina Almeida, Nídia Oliveira, António Correia
Centro Hospitalar Tondela Viseu, Viseu, Portugal

Introduction

Autoimmune polyglandular syndrome type 2 (APS2), also known as Schmidt's syndrome is defined by the presence of Addison disease associated with autoimmune thyroid disease and/or type 1 Diabetes Mellitus. This can be associated with other autoimmune disorders like vitiligo. It is rare, affecting about 1.4-2 cases /100000 inhabitants.

Case description

We present a 41-year-old woman with history of hypothyroidism of unknown aetiology and vitiligo. She went to the emergency department because she had asthenia which was getting worse in the previous months. She had also anorexia, nausea and had lost 6Kg in a year. She denied other complaints and was exhausted because she couldn't find a reason for her situation. On physical examination we observed that she had cutaneous hiperpigmentation and when we questioned about that she said that it wasn't her habitual skin color. She had also vitiligo lesions on the face, hands and underarms. Had a hypotensive profile (106/77 mmHg) with no other positive findings on the physical exam. She had slight hyponatremia (Na 133 mEq/L), hyperkalemia (K 4.8mEq/L) and had no leukocytosis or anemia. Serum cortisol was 3.3ug/dL (4.3-22.4), urine free cortisol 52 ug/24h (28-214), ACTH > 2000.0 pg/mL (4.7-48.8). Quantiferon TB was negative and adrenal ultrasound showed no haemorrhage, infiltrates or masses. Antiperoxidase antibody was positive. The 21-hydroxylase and 17-alpha-hidroxyase antibody are still pending. HbA1c was 5.1%, anti-transglutaminase and anti-endomysial antibodies were all negative. Patient started treatment with prednisolone and fludrocortisone with good clinical response.

Discussion

This case aims to alert to the need for high clinical suspicion in the diagnosis of Addison Disease. Since it is a rare autoimmune disease it is important to search for other associated autoimmune diseases in order to exclude an APS2, which was the case of our patient that had vitiligo and hypothyroidism of unknown aetiology.

#960 - Case Report

POLYMYALGIA RHEUMATICA: AN UNCOMMON PRESENTATION

Marta Fonseca, Mário Ferreira, Zélia Neves, João Machado
Hospital Prof. Doutor Fernando Fonseca, Amadora, Portugal

Introduction

Polymyalgia Rheumatica (PM) is an inflammatory disease of the peri-articular structures, characterized by morning pain and stiffness of the proximal muscles, affecting the hip and shoulder girdles. Pelvic girdle is sometimes also damaged. Laboratory findings show a rise in inflammation markers. It is more common in the elderly, especially women. It is frequently associated with giant cells arteritis and malignancy should be excluded. Despite being a common illness, the diagnosis is often forgotten and the treatment delayed. The use of corticosteroids is the treatment of choice, with a rapid clinical response.

Case description

74-year-old man comes to the hospital for evaluation of asthenia, 10% weight loss and weakness of the pelvic girdle for 6 months. The clinical observation revealed cervical and supraclavicular adenopathies and muscular weakness of the hips. No other force deficits, articular or muscular pain were observed. Laboratory findings revealed normocytic and normochromic anaemia, elevated erythrocyte sedimentation rate and C-reactive protein and hypoproteinaemia. Auto-immunity, infectious, endocrine and

metabolic studies were all negative. Thorax, abdominal and pelvic TC scan showed only the palpable adenopathies and endoscopic study excluded gastrointestinal malignancy. The biopsy of an axillar lymph node revealed unspecific inflammation, also negative for malignancy. Peripheral blood immunophenotyping test revealed a 1% clone of T cells, suspicious of lymphoproliferative disease, later excluded with a bone marrow biopsy.

The search of a neuro-muscular disease showed negative muscular enzymes and antibodies, electromyogram and muscular biopsy results were compatible with unspecific inflammatory illness.

After excluding the major differential diagnoses, it was decided to try a prednisolone treatment trial. The patient showed a clear and rapid clinical improvement in the first 48 hours, assuming the diagnosis of PM. In the follow-up months the symptoms have subsided, as well as the laboratory findings.

Discussion

This clinical case illustrates an uncommon PM's presentation, predominantly with muscle weakness instead of pain, affecting the pelvic girdle, with adenopathies and weight loss, suggestive of other important diseases with the need of an exhaustive differential diagnosis. It is important to highlight the importance of a close follow-up on these patients, given the frequent recurrences and development of other conditions.

#967 - Case Report

ANTI-MPO VASCULITIS WITH LUNG-KIDNEY SYNDROME PRESENTATION

Bárbara Soeiro¹, Juliana Sá², José Calheiros¹, Alexandre Vasconcelos¹, Inês Moreira¹, Elena Molinos¹, Rui Araújo¹

¹ ULSM - Hospital Pedro Hispano, Matosinhos, Portugal

² Centro Hospitalar Cova da Beira, Covilhã, Portugal

Introduction

Pulmonary-renal syndrome refers to the combination of diffuse alveolar haemorrhage and rapidly progressive glomerulonephritis. It has a fulminant course if left untreated and early recognition is crucial since mortality can reach 25–50%.

Case description

We report the case of a 73-year-old male, with a history of arterial hypertension, cigarette smoking of 100 packs/year and ischemic cardiopathy.

He was transferred to our hospital with a diagnosis of bilateral pneumonia, on the 3rd day of antibiotherapy. Fifteen days previous to the initial admission he described a self-limited cold (sneezing, earache and odynophagia). 2 days before admission he started a cough, with "brown" sputum, progressive dyspnoea evolving to minimal effort exertion and fever (axillary temperature: 38,5°C). On the course of 24-hour of inpatient care he developed severe respiratory failure arriving to our emergency room with PaO₂/FiO₂ ratio of 64. Endotracheal intubation was performed, mechanical ventilatory support was initiated and he was admitted

to our Intensive Care Unit. Blood tests showed anaemia of 7,4g/dL of haemoglobin, acute kidney injury with estimated glomerular filtration rate (eGFR with CKD-EPI) of 17.1 mL/min/1.73m² and urine analysis with microscopic haematuria and proteinuria, a 13780/uL leukocyte count with relative neutrophilia and a C-reactive protein (CRP) of 17,7mg/dL. Computed tomography of the chest showed diffuse bilateral interstitial infiltrates and haemoptysis were objectivated. A pulmonary-renal syndrome was presumed, with two life-threatening features: alveolar haemorrhage and likely glomerulonephritis, and the patient was started on plasma exchange and 3-day high-dose corticosteroid pulse (then maintenance), followed by 4 weeks of rituximab. Renal biopsy showed pauci-immune crescentic glomerulonephritis ANCA-MPO titers were positive for 1/320, making the definite diagnosis MPO-ANCA vasculitis. He required mechanical ventilation for 11 days and 3 days of haemodialysis. The total time of hospitalization was 34 days. At 3 months follow-up he had complete pulmonary recovery and partial renal function stabilization (eGFR with CKD-EPI of 34 mL/min/1.73m²).

Discussion

ANCA-MPO vasculitis can present slowly over months or explosively over days. In this case the clinical suspicion and severity stratification led to prompt diagnosis of lung-kidney syndrome and initiation of immunosuppressive therapy with good final outcome.

#984 - Abstract

THE RED CELL DISTRIBUTION WIDTH IS A POTENTIAL PREDICTOR OF RESPONSE TO METHOTREXATE IN RHEUMATOID ARTHRITIS

Erika Zecca, Mattia Bellan, Daniele Soddu, Alessandro Croce, Ramona Bonometti, Roberta Pedrazzoli, Daniele Sola, Mario Pirisi, Pier Paolo Sainaghi

Università del Piemonte Orientale UPO, Novara, Italy

Background

The red cell distribution width (RDW) is an unconventional biomarker of inflammation. We aimed to explore its role as a predictor of treatment response in Rheumatoid Arthritis (RA).

Methods

N.= 82 RA patients (55 females), median age 63 years [52-69], were selected by scanning the medical records of a rheumatology clinic, to analyse the associations between baseline RDW, disease activity scores and inflammatory markers, as well as the relationship between RDW changes following methotrexate (MTX) and treatment response.

Results

The lower was median baseline RDW, the greater were the chances of a positive EULAR response at three months, being

13.5% [13.0-14.4] among those with good response, vs. 14.0% [13.2-14.7] and 14.2% [13.5-16.0] ($p=0.009$) among those with moderate and poor response, respectively. MTX treatment was followed by a significant RDW increase ($p<0.0001$). The increase of RDW was larger among patients with good EULAR response, being progressively smaller in cases with moderate and poor response (1.0% [0.4-1.4] vs. 0.7 [0.1-2.0] vs. 0.3 [-0.1-0.8]; $p=0.03$).

Conclusion

RDW is a strong predictor of early response to MTX in RA, outperforming classical inflammatory markers. RDW significantly increases after MTX initiation in parallel to treatment response, suggesting a role as a marker of MTX effectiveness.

#986 - Case Report

MONOSTOTIC PAGET'S DISEASE: A CAUSE OF BONE PAIN

Margarida Viana Coelho, Domingos Sousa, Sergio Antunes Da Silva, Rui Marques Osorio, Ana Isabel Rodrigues, Rita Martins Fernandes

Centro Hospitalar Universitário do Algarve, Internal Medicine Department, Hospital de Faro, Faro, Portugal, Faro, Portugal

Introduction

Up to 40% of patients with Paget disease of the bone seek medical care with complaints of bone pain. Most often the first clue for Paget's disease of bone is an abnormal radiograph with an elevated serum alkaline phosphatase level in a patient with bone pain. The physician has to confirm that an isolated elevation in the alkaline phosphatase is not of hepatic origin. An elevated serum alkaline phosphatase with a normal GGT or 5'-nucleotidase should lead to an evaluation for bone diseases.

Case description

A 86-year-old man presents to our internal medicine consult with complaints of a knee pain during the past 3 months. The pain was characterized as deep, aching discomfort that persists through the day and at rest and is not relieved by acetaminophen.

At physical examination the right leg was three centimeters shorter than the left. And there was also an anterior bowing of the tibia and femur.

Laboratory liver-function tests and other routine laboratory tests were normal with exception of the total serum alkaline phosphatase level that was 385 U per liter (reference range, 40 to 125). Radiography of the proximal right femur shows cortical thickening and prominent trabecular pattern (Fig.1). The patient started treatment with bisphosphonate. At sixth months there was a normalization of serum alkaline phosphatase and clinical sustained improvement.

Discussion

In the present case, the disease is localized to a long bone with presence of bowing deformity, caused by enlarging and

abnormally contoured bones, which was considered to be the cause of increased mechanical stress and pain.

The typical radiographic findings (bone expansion and an abnormal trabecular pattern) of Paget's disease of bone, an elevated alkaline phosphatase level and a localized pain, suggested increased metabolic activity, therefore the patient started treatment with bisphosphonate with a good outcome.

We call attention to Paget disease of bone because it occurs in an aging population that also has an increased prevalence of malignancy, osteoarthritis, and osteoporosis. Although the diagnosis can be evident from radiographic findings, we should keep in mind that the differential diagnosis includes metastatic disease, osteomalacia, osteosarcoma and giant cell tumors of bone.

#994 - Case Report

THE IMPORTANCE OF THE EXTENSION STUDY

Víctor Mato, María Toledano, Cristina Ausín, Neera Toledo, María Victoria Villalba, Blanca Pinilla

Hospital General Universitario Gregorio Marañón, Madrid, Spain

Introduction

We present a case of a 60-year-old male referred to the autoimmune and systemic diseases consultation for further study because of retroperitoneal fibrosis and inflammatory pseudotumor in both kidneys.

Case description

60 year-old male with previous history of dyslipidemia, diabetes type II, reactive arthritis, polymyalgia rheumatica, severe pericardial effusion, lacunar stroke and mandibular granuloma.

He was admitted in urology department because of left flank pain and soft tissue mass around the kidney. In that admission it was shown atypical retroperitoneal fibrosis and inflammatory pseudotumor in both kidneys.

He was referred to autoimmune and systemic diseases medical consultation for further study. There, supplementary tests were checked:

- Abdominal ultrasonography: bilateral pyelocaliceal ectasia and hyperechogenic tissue around both kidneys.
- Abdominopelvic CT-scan: perirenal bilateral soft density tissue that infiltrates both renal sinus. Splenomegaly (16cm) and multiple mesenteric adenopathies.
- Blood tests: fibrinogen 701 mg/dL, positive ANA (1/320), C-reactive protein 2.9 mg/dL, IgG4 0.168g/L.
- Renal biopsy: findings compatible with inflammatory pseudotumor.
- Renogram and renal gammagraphy: normal kidney function.
- Negative mycobacterium in urine tests.

So, we established the differential diagnosis between mycobacterial infection, oncohematologic diseases as lymphoma, idiopathic retroperitoneal fibrosis or IgG4 related disease (IgG4-RD).

The histological samples of the mandibular granuloma were checked by the anatomical pathology department and they saw IgG4/IgG relationship > 40%, fibrosis, obliterative phlebitis and lymphoplasmacytic infiltrate. This findings confirmed the diagnosis of IgG4-RD, so we started treatment with prednisone and azathioprine.

Two years after, the patient is admitted in the ICU department because of a bilateral bronchopneumonia. Then, a chest CT-scan is done where it is shown images compatible with aortitis. Days after, he dies due to septic shock.

An autopsy is done, which shows acute bronchopneumonia and findings compatible with IgG4 disease with low inflammatory activity but large fibrosis in kidneys, suprarenal glands, thyroid, pericardium, pleura as well as thoracic and abdominal aortitis.

Discussion

We present the case of a 60 year-old male with diagnosis of IgG4-RD and renal, aortic and vascular involvement. After patient's death because of an infection, an autopsy is done which show silent and multiorgan involvement due to IgG4-RD.

#996 - Case Report

ASYMMETRIC LEG EDEMA: AN UNCOMMON PRESENTATION FOR A RARE CONDITION CONTRIBUTING TO WORSENING RENAL FAILURE

Diogo Antão, Valentina Tosatto, Lourenço Cruz, Torcato Marques, Cristiano Cruz, Paula Nascimento, André Almeida, Rita Barata Moura

Unidade Funcional de Medicina 4 - Centro Hospitalar e Universitário Lisboa Central, Lisbon, Portugal

Introduction

Vasculitis are defined by the presence of inflammatory cells in the vessel walls that damage its structure. There are plenty of clinical presentations depending on the size of the affected vessels. It's important to keep these medical conditions in mind to get to the right diagnosis.

Case description

A 77 years-old woman, presented at the ER with a 10 days history of a painful pitting asymmetric right leg edema, with no increased temperature or redness. She reported a 15kg weight loss over the previous year (65->50kg). She had a previous medical history of ischemic cardiomyopathy, arterial hypertension, stage IV chronic kidney disease (diagnosed 2 years before), normocytic anemia and neuropsychiatric disease (pre-frontal and fronto-temporal subcortical dysfunction). She presented with a tympanic temperature of 37,5°C and her blood tests indicated renal dysfunction (Scr 1.95 mg/dL) and elevated C-reactive protein (90 mg/dL). Urinalysis showed leukocyturia and hemato-proteinuria. The patient then got admitted to the Internal Medicine Unit for further clinical investigation. Urine and blood cultures were

negative. Ultrasound examination excluded venous obstruction in both legs, and, thoracic, abdominal and pelvic CT-scans were negative for space-occupying lesions. 24h-urine analysis showed predominantly non-albuminuric proteinuria (1370mg). Erythrocyte sedimentation rate was also high (120 mm). Urine microscopy showed acanthocytes, erythrocyte casts and tubular renal cells. MPO-ANCA (1297,7 UQ), ANA, TPO, rheumatoid factor and β 2-microglobulin were positive; IGRA was also positive. Anti-dsDNA, PR3, PLA2R, CCP and GBM antibodies were all negative. The patient underwent a course of glucocorticoids and began isoniazide as treatment for latent TB. The renal biopsy showed a necrotizing crescentic vasculitis and 60% of interstitial fibrosis. Given the excellent response to the glucocorticoids, immunosuppressive therapy with cyclofosfamide and azathioprine was started after 3 weeks. The patient was discharged pending follow-up assessment at the Internal Medicine Outpatient Clinic.

Discussion

Even though long-term renal dysfunction is mostly associated with arterial hypertension and Diabetes Mellitus, vasculitis are very important to keep in mind as potential causes of renal impairment. As in the case mentioned, these conditions may also present with constitutional symptoms and raised markers of systemic inflammation.

#1002 - Case Report

DOUBLE ANTIBODY DISEASE

Elsa Araújo, Manuel Barbosa, Bárbara Sousa, Marta Pereira, Joana Fontes, Joana Silva, António Ferro

Unidade Local de Saúde do Alto Minho, Viana Do Castelo, Portugal

Introduction

Rapidly progressive glomerulonephritis (RPGN) is a clinical syndrome manifested by features of glomerular disease in the urinalysis and by progressive loss of renal function over a comparatively short period of time.

Case description

A 90 year-old woman with history of hypertension presented to the emergency department (ED) with complaints of anorexia and fatigue that had been worsening in the previous month, but especially in the previous days.

Physical examination showed skin pallor with no other remarkable findings. Her admission labs revealed anemia (hemoglobin 8.5 g/dl), acute kidney injury (AKI) (creatinine (Cr) 6.05 mg/dl and urea 232 mg/dl), hyperkalemia and metabolic acidemia. Urine sediment revealed the presence of proteins, leukocytes and erythrocytes. Renal ultrasound showed kidneys with a slight increase in size and parenchyma with preserved thickness.

The patient was hospitalized for AKI and nephritic syndrome. Renal function worsened during her stay with a maximum Cr value of 8.16 mg/dl. As hypervolemia, metabolic acidemia and hyperkalemia developed, she was started on hemodialysis.

The etiological study showed proteinuria in the 24 hours of 1.2 g. Erythrocyte sedimentation rate was 87 mm. Anti-myeloperoxidase antineutrophil cytoplasmic antibody (MPO-ANCA) and anti-glomerular basement membrane antibody (anti-GBM) were positive. Thoracic computed tomography was performed, which ruled out pulmonary involvement. These results led to the diagnosis of crescentic glomerulonephritis due to small-vessel vasculitis of MPO-ANCA and anti-GBM with exclusive kidney involvement. The patient was started on methylprednisolone 500 mg daily for 4 days followed by cyclophosphamide.

Renal biopsy was performed, which showed 67% of fibrocellular crescents and interstitial fibrosis in 20%.

Treatment was considered successful as this 90-year-old patient partially recovered her renal function and clinical stability without further need for dialysis.

Discussion

Untreated RPGN typically progresses to end-stage renal disease so early diagnosis and early initiation of appropriate therapy is essential to minimize the degree of irreversible renal injury. Our patient, despite the histological result showing fibrocellular and fibrous crescents, showed clinical improvement after therapy was initiated.

Despite long term survival will always be limited given the age of the patient, follow up and search for new symptoms are necessary given the possibility of systemic involvement.

#1039 - Case Report

A RARE CASE OF ISOLATED LOWER LIMB VASCULITIS IN A YOUNG FEMALE

Waqar Haider Gaba, Ahmad Thaer Mahdi, Mariam Ghareeb Al Mansoori

Sheikh Khalifa Medical City, Abu Dhabi, United Arab Emirates

Introduction

Isolated arteritis of the lower limb vessels is rare. Vasculitis of the lower limbs can occur in Takayasu's Arteritis (TA) or Giant Cell Arteritis (GCA). We present a case of young lady with lower limb vasculitis and remarkable outcome with systemic steroids.

Case description

A 41-years-old lady visitor from Indonesia presented with bilateral foot pain and reduced mobility for the last 3 weeks. She denied any constitutional symptoms, involvement of upper limbs, headache or visual loss. Her past medical history includes hypertension and nonsmoker. Her BP was 150/80 in both arms, regular pulse at 80/minute with no bruit. Her right foot had bluish discoloration over the first three toes and the arch of the plantar surface. Pulses were palpable except right posterior tibial artery. Bloods were normal except ESR at 45 mm/hr and CRP of 5.6 mg/L. CT Aortogram and its branches were normal including renal arteries. CT angiography of the lower limbs showed bilateral marked distal posterior tibial artery narrowing or spasm with lack of opacification on arterial and

venous phase consistent with either spasm or thrombosis. Arterial Doppler showed patent right anterior tibial artery with sharp monophasic flow but absent right distal posterior tibial artery. Vascular surgeons ruled out acute limb ischemia and advised no surgical intervention. Rheumatologists advised Vasculitis screen which was all negative. Angiogram demonstrated beaded right tibio-peroneal artery and anterior tibial artery along the whole length of the artery. Right posterior tibial artery was seen up to the mid segment followed by skip lesion and then it was occluded with no blood supply reaching the toes neither the arch. Left posterior tibial artery was not well visualized with beaded appearance and skip lesion compatible with vasculitis. She was started on pulsed methylprednisone IV daily with remarkable improvement over the next 3 days. She was fully mobile and asymptomatic when discharged after 5 days with tapering course of oral steroids for a month and follow up with Rheumatology in her home country.

Discussion

Takayasu's arteritis should be considered in differential diagnosis of unexplained lower limb ischemia. In our case young age, claudication of lower limbs, rapidly progressive disease, raised inflammatory markers and characteristic imaging features favored more towards Takayasu's Arteritis. Early diagnosis allowed rapid initiation of steroids which helps in early recovery and avoids surgery.

#1044 - Case Report

CARDIAC ARREST – A MANIFESTATION OF A GRANULOMATOUS DISEASE

Madalena Lobao, Márcia Pereira, Rui Malheiro, Francisca Martins
Centro Hospitalar Universitário de Lisboa Central, Hospital dos Capuchos,
Lisbon, Portugal

Introduction

Manifest cardiac involvement occurs in about 5% of patients with sarcoidosis. The 3 main manifestations of cardiac sarcoidosis (CS) are conduction abnormalities, ventricular arrhythmias, and heart failure.

Case description

We hereby present the case of a 67-year-old male with various cardiovascular risk factors that was found in cardiac arrest due to monomorphic ventricular tachycardia. A successful cardioversion was performed at the site and he was brought to our emergency department. His EKG was compatible with a past inferior infarction. The patient was stabilized and admitted for further monitoring and evaluation. Angiographically there were no signs of coronary disease, his left ventricle systolic function was 51% and an implantable cardioverter defibrillator was placed. The patient claimed of night sweats for 6 years and of fatigue in the last 2. In his physical exam there were no palpable lymph nodes; relevant were multiple indolent thickened circular lesions of skin in the (thorax and back) that he claimed having for a decade. He

had not travelled recently and from his familial history his mother suffered from sarcoidosis.

An AngioCT ruled out pulmonary embolism but revealed mediastinal lymphadenopathies and a few pulmonary micronodules. A cardiac MR (CMR) showed a delayed non ischemic enhancement of the inferior wall (basal segment and septum) as well as para-aortic and hilar lymphadenopathies. Sarcoidosis and lymphoproliferative disease were the most likely hypothesis. A transbronchial biopsy was performed and epithelioid non-caseating granulomas with rare multinucleated giant cells were identified suggesting sarcoidosis. A Positron-emission (PET) CT documented metabolic active mediastinal lymphadenopathies and granulomatous cardiac disease in activity (septum, left ventricle and right atrium). He was started on steroids; his fatigue has improved but due to persistent activity signs methotrexate has been added.

Discussion

Sarcoidosis is a multisystem, granulomatous disease. Its etiology is unknown but familial clustering (as in this case) indicates a strong genetic element. Cardiac symptoms were dominant. His Angiotensin-converting enzyme levels were normal (low diagnostic value as biomarker). Having excluded coronary disease, an unexplained ventricular tachycardia, a histological diagnosis of extracardiac sarcoidosis together with sarcoidosis consistent patterns in CMR and PET CT the diagnosis of CS was made without the need for performing an endomyocardial biopsy.

#1052 - Case Report

WEBER CHRISTIAN DISEASE - A CASE REPORT

Cátia Ribeiro Santos, Ana Luísa Albuquerque, Helena Carrondo, Célio Fernandes

Centro Hospitalar de Leiria - Hospital de Santo André - Medicina Interna II, Leiria, Portugal

Introduction

Weber Christian disease is a skin condition that features recurring inflammation in the subcutaneous fat layer of the skin and systemic symptoms. The diagnosis of Weber-Christian disease is a diagnosis of exclusion with a lobular panniculitis without vasculitis in histopathology.

Case description

We report a case of a 80 year old man presented with two-month history of fever, constitutional symptoms and relapsing nonsuppurative nodular panniculitis. On examination a febrile patient with pallor and multiple firm tender lumps in the right lateral thoracic region as well as in anterior abdominal wall with mild erythema in overlying skin associated. Analytically increased inflammatory parameters (leukocytes and CRP) raised sedimentation rate and anemia. Negative antinuclear antibody and anti-double strand DNA, normal immunoglobulin assay

and normal C3 and C4. TORCH screening was negative. Fungal and bacterial cultures from the nodules revealed no growth. Echocardiogram showed no vegetations and thoracic, abdominal and pelvic CT scan it was normal. Biopsy of the thoracic and abdominal nodules demonstrated a lobular panniculitis without vasculitis confirmed the diagnosis. Our patient improved following corticosteroid treatment for 4 weeks with no activity reported and no appearance of any new swellings.

Discussion

The importance of the case described is to remember that rare diseases occur and their diagnosis is only made when thinking about chance and differential diagnosis. Despite the rarity of this and other pathologies we must have them present at the time of diagnosis, since the absence / delay in the diagnosis of these pathologies interferes with the quality of life of patients.

#1054 - Case Report

A HIDDEN DIAGNOSIS BEHIND IRON DEFICIENCY ANAEMIA

João Pedro Pais¹, Ana Sofia Matos¹, Ana Nascimento¹, Francisco Teixeira Da Silva¹, Miguel Romano¹, Rui Silva², Francisca Cardoso¹, Diana Guerra¹

¹ Unidade Local de Saúde do Alto Minho, Viana Do Castelo, Portugal

² Centro de Medicina de Reabilitação de Alcoitão, Alcoitão, Portugal

Introduction

The presence of gastric antral vascular ectasia is a rare cause of upper gastrointestinal bleeding, endoscopically described as “watermelon stomach”. This entity is described in many systemic diseases, such as systemic sclerosis (SS). SS is a multisystemic disease characterized by disseminated vascular dysfunction and progressive fibrosis of all organs and systems. The gastrointestinal tract is involved in 90% of the cases.

Case description

We present the case of a 59-year-old male with a diagnosis of idiopathic pulmonary fibrosis, identified two years ago. Two months before our first evaluation, the patient perceived increased fatigue and loss of weight. In the blood tests, it was identified iron deficiency anaemia and he started treatment with oral iron supplementation, without clinical or analytical improvement. Associated with these symptoms, he also referred hoarseness, non-productive cough, rest dyspnoea, episodes of Raynaud phenomenon with cold temperatures and increased thickness of his fingers during the previous six months. The patient denied epigastric pain, nausea, bowel movement alterations, fever or nocturnal hypersudoresis. Objectively, he presented with face and chest telangiectasias, sclerodactyly and diminished respiratory sounds in both pulmonary bases. In the endoscopic study, it was observed a pattern of “watermelon stomach”. The patient was treated with intravenous iron supplementation, with clinical improvement and analytical resolution of the iron deficiency

anaemia. With a suspicion of SS, an immunological study was made (anti-nuclear, anti-centromere and anti-Scl70 antibodies), which came negative. The capillaroscopy revealed an active sclerodermic pattern, with diminished number of capillaries, disorganization of capillary architecture, giant capillaries and capillary haemorrhages. Additionally, the pulmonary function was assessed, revealing a discrete restrictive pattern and a severely diminished diffusion capacity for carbon monoxide. With the clinical alterations and the results of the complementary tests, a diagnosis of SS was made with cutaneous, gastrointestinal and pulmonary involvement.

Discussion

The diagnosis of SS can be quite challenging. A high suspicion is needed in order to identify the disease in an early stage and ensure a better quality of life to the patient. SS has a poor prognosis and when the pulmonary system is involved, it entails an even worse prognosis.

#1056 - Case Report

LARGE-VESSEL VASCULITIS – A CLINICAL CASE

João Pedro Pais¹, Miguel Romano¹, Rui Silva², Ana Nascimento¹, Ana Sofia Matos¹, Francisco Teixeira Da Silva¹, Francisca Cardoso¹, Diana Guerra¹

¹ Unidade Local de Saúde do Alto Minho, Viana Do Castelo, Portugal

² Centro de Medicina de Reabilitação de Alcoitão, Alcoitão, Portugal

Introduction

Large-vessel vasculitis (LVV) are a group of idiopathic inflammatory diseases characterized by granulomatous inflammation of medium/large calibre arteries. The two main LVV are giant cell arteritis (GCA) and Takayasu arteritis (TA). Although epidemiologically different, both entities present with constitutional symptoms and the differential diagnosis can be challenging.

Case description

A 57-year-old man with a medical history of dyslipidaemia and benign prostatic hyperplasia, presented in the emergency department with cervicalgia in C7-D1 level, with irradiation to the paravertebral muscles and dorsal spine, with three weeks of evolution. He also complained of fever, fatigue and loss of weight (about 4 kg). The physical examination was normal. In the blood tests, it was identified a normocytic and normochromic anaemia, elevated levels of C reactive protein and ferritin and a high erythrocyte sedimentation rate. The patient was hospitalized. Transthoracic echocardiogram excluded endocarditis and imaging study excluded osteomyelitis and spondylodiscitis. Symptomatic treatment with non-steroid anti-inflammatory drugs (NSAID) was initiated, with clinical improvement and the patient was discharged from the hospital while waiting for the realization of positron emission tomography scan (PET). Two weeks after discharge, the

patient was re-evaluated, referring sporadic episodes of fever and cervical pain, even with NSAID therapy. Objectively, there was asymmetric radial pulses and a higher arterial pressure in the right arm (over 10 mmHg). The PET showed increased uptake values along the aorta, brachiocephalic trunk, subclavian, brachial and common carotid arteries, which suggested a diagnosis of a LVV. The angiographic study did not show signs of stenotic lesions. Treatment with prednisolone (50 mg/day) was started, with clinical improvement. After starting corticoid tapering there was a clinical worsening. Methotrexate was initiated with success.

Discussion

The differential diagnostic between GCA and TA can be challenging. In the clinical case, the epidemiologic characteristics suggested GCA as the most probable diagnostic. However, the clinical features observed suggested that TA could also be the culprit. The absence of the usual features of both entities (involvement of cranial branches originated from the aortic arch for TA and presence of stenotic lesions in angiographic study in TA) made it impossible to discriminate between the two disorders.

#1067 - Case Report

REFLEX SYMPATHETIC DYSTROPHY - A CASE REPORT

Carolina Morna, Nuno Gonçalves, Jessica Chaves, Carolina Barros, Tiago Esteves Freitas, Maria Luz Brazão
Hospital Central Funchal, Funchal, Portugal

Introduction

Complex regional pain syndrome (CRPS) is a chronic pain condition characterized by a continuing regional pain disproportionate in time and degree to the usual course of any known lesion, with predominance of sensory, autonomic, motor and dystrophic signs and symptoms. It is a disorder of a body region, generally of the limbs, and frequently begins after a fracture, soft tissue injury or surgery. CRPS type I (also known as reflex sympathetic dystrophy) corresponds to patients without evidence of peripheral nerve injury. The Budapest Consensus Panel proposed diagnostic criteria for CRPS requiring at least one symptom in each of the four categories and one sign in at least two of the four categories.

Case description

A 55-year-old female, working as a cocker, presented with pain in her left arm, described as a stinging sensation that exacerbated by movement and contact. On numeric rating scale (NRS), she reported the intensity of pain being 8, especially of the metacarpal. She had a two-month history of treatment with non-steroid anti-inflammatory drugs (NSAIDs) and analgesics and there was no evidence of any severe injury.

Physical examination revealed swelling of the back of the left hand with predominance of the metacarpophalangeal (MCP) joints, increased sweating, allodynia (pain due to a stimulus that does not usually provoke pain), hyperalgesia (extreme pain response to a

minimally painful stimulus), muscle wasting and weakness of the same hand.

X-ray examination of her left hand showed signs of patchy osteopenia, with a noticeable loss of bone density of the 1° MCP and joint space narrowing of the carpal. It also showed degenerative changes of trapezometacarpal joint with calcification (justa-articular). Echography showed no sign of synovitis; edema of the periarticular soft tissue; median nerve with normal dimensions and echo-structure at the entrance of carpal tunnel, without apparent compression. A presumptive diagnosis of CRPS type I was made based upon clinical suspicion.

It was the third month of disease and the treatment was pregabalin and analgesics in combination with physical therapy, with the patient reporting improvement.

Discussion

The aim of this report was to present a patient with CRPS type I with emphasis on diagnosis and the complexity of the treatment of this pathology.

#1069 - Medical Image

SYSTEMIC SCLEROSIS AND RAYNAUD SYNDROME

Catarina Marques, Domingas Pereira, Rita Calixto, José Vaz
Hospital José Joaquim Fernandes, Beja, Portugal

Clinical summary

We report a case of an 81 years old female, sent by the family physician with a suspected diagnosis of Systemic Sclerosis and Sjogren Syndrome with pulmonary involvement. At examination, the patient presented features suggestive of Raynaud's Syndrome, later confirmed by capillaroscopy and a thickening and tightening of the skin of the fingers, compatible with collagen infiltrate. She was recommended to place arteriodilators - transdermic nitroglycerin on the back of each hand and additionally captopril was replaced by a calcium channel blocker - nifedipine (first line in the treatment of pulmonary hypertension). This image shows the abnormal accumulation of fibrous tissue on the skin, causing it to harden to the point that the patient's fingers became bent and lost their mobility.

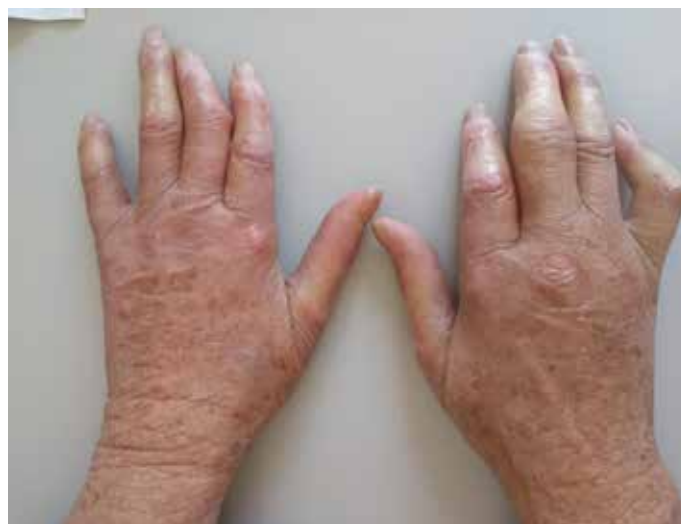

Figure #1069.

#1077 - Case Report

A CASE OF LATE-ONSET NEUTROPENIA INDUCED BY RITUXIMAB

Ana Rita Oliveira Rego, Isabel Fonseca Silva, Sofia Mendes, Sara Vieira Silva

Centro Hospitalar Universitário do Porto, Porto, Portugal

Introduction

Rituximab is a monoclonal antibody directed against the CD-20 antigen that is used in the treatment of several autoimmune diseases. Late-onset neutropenia (LON) is defined as an unexplained absolute neutrophil count (ANC) of $< 1,5 \times 10^9$ starting from 4 weeks up to 12 months after rituximab infusion. It is an emerging side effect of rituximab therapy and the mechanism of development and incidence are not fully known, although there are reports in up to 27% of patients. Many factors seem to be linked to more susceptibility to develop neutropenia following rituximab treatment such as polymorphisms in FCGR3.

Case description

Woman, 50 years old, with systemic lupus erythematosus, rheumatoid arthritis and dermatomyositis. Treated chronically with methotrexate, hydroxychloroquine and rituximab (last administration 4 months before admission). She was admitted in the emergency department with a fever that lasted for 4 days and a light sore throat. No other symptoms were reported. No relevant findings in the physical examination. Blood count revealed a severe neutropenia of 300 neutrophils/mL, with no other blood abnormalities, and an elevated C-reactive protein of 85.62 mg/dL. It was assumed a case of severe neutropenic fever in a patient with several autoimmune disorders and therefore empiric treatment with imipenem and filgrastim was initiated. The patient was stable throughout the hospital stay and had no exacerbations of the autoimmune disorders. Microbiologic studies were negative namely respiratory viruses, cytomegalovirus, Epstein-Barr virus, parvovirus and HIV.

Besides Rituximab, no other potential causes of neutropenia were found. As described by the literature, it was assumed as a case of late-onset neutropenia induced by rituximab.

The patient was discharged after 7 days of antibiotherapy with sustainable apyrexia and normal neutrophils count.

Discussion

Although there is a lot of misunderstanding of how a monoclonal antibody against lymphocyte B cells can cause neutropenia the true is that late-onset neutropenia is a more and more recognized side effect of this therapy. It is important to be aware of this side effect to prevent severe complications and therefore patients treated with Rituximab need a regular complete blood count even months after the last administration.

#1091 - Case Report

CARDIAC AND NEUROLOGICAL INVOLVEMENT IN ANTIPHOSPHOLID SYNDROME: A CASE OF A WOMAN WITH NON-BACTERIAL THROMBOTIC ENDOCARDITIS AND COGNITIVE IMPAIRMENT

Eleftheria Ztriva, Georgia Kaiafa, Georgios Polychronopoulos, Areti Sofogianni, Dimitrios Pilalas, Christos Savopoulos

Propaedeutic Department of Internal Medicine, AHEPA University General Hospital, School of Medicine, Aristotle University of Thessaloniki, Greece, Thessaloniki, Greece

Introduction

Antiphospholid syndrome (APS) is a systemic autoimmune disease that is characterized clinically by recurrent episodes of thrombosis and pregnancy complications and the presence of antiphospholipid antibodies –anticardiolipin, lupus anticoagulant and anti-b2-glycoprotein- in patients' serum. Here we present the case of a 47-year old woman with APS and cardiac and neurological involvement.

Case description

A 47-year old woman, with free medical history, presented to the emergency department with complaints of cognitive deterioration over the last 4 years. Blood tests revealed pancytopenia, positive anticardiolipin IgM and IgG antibodies and high lupus anticoagulant ratio. MRI brain scan revealed multiple ischemic lesions. In the one-month later follow-up visit, medical examinations revealed pancytopenia. The patient had developed Livedo reticularis and reported fever since 24 hours. A Transthoracic Echocardiogram (TTE) showed bicuspid aortic valve with an echo-dense mass 17x10 mm attached to the large cusp, causing severe aortic valve regurgitation. A Transesophageal Echocardiogram (TEE) confirmed these findings. Two pairs of blood cultures showed negative results for microorganisms, verifying the presence of sterile vegetation. High titers of IgM and IgG anticardiolipin antibodies were consistent with APS. The

patient was treated with intravenous methylprednisolone and immunoglobulin followed by Rituximab iv infusion. A week later, the patient developed significant respiratory deterioration and was transferred to the Intensive Care Unit, where she died.

Discussion

The case of our patient fulfilled the Sidney criteria of APS diagnosis which require the presence of at least one of the clinical criteria (vascular thrombosis) and at least one of the laboratory criteria (detection of antiphospholipid antibodies). Heart valve disease is the most frequent cardiac manifestation in APS and involve sterile vegetations, possibly formed due to the deposition of circulating immune complexes. The mitral and aortic valves are mostly affected. In our case, according to the Duke criteria, a number of separate blood cultures, in addition to the TTE and TEE results verified the presence of sterile vegetation and established the diagnosis of non-bacterial endocarditis related to the APS. Cardiac involvement in APS demands early diagnosis and treatment, as far as close follow-up, in order to reduce cardiovascular mortality associated with the syndrome.

#1092 - Case Report

“WHAT’S THAT ON YOUR FACE SIR?” – PIECING THE CLUES OF THE CLINICAL PICTURE TO OBTAIN THE DIAGNOSIS; A CASE REPORT

Sri Karpageshwary K

Singapore General Hospital, Singapore, Singapore

Introduction

The crux of an internist is essentially that of an investigator, to link the clinical clues to reach a unifying diagnosis for the presenting complaint. However, the links are not always brought forward by the patient in the history; hence it is the duty of the physician to sieve the critical information to solve the puzzle. Here we describe the case of a male patient who presented with typical symptoms of heart failure, but an unusual rash prompted further investigations resulting in the diagnosis of Systemic Lupus Erythematosus (SLE).

Case description

A 63-year-old male with past medical history of non -ischaemic cardiomyopathy of unknown aetiology, Stage 2 chronic kidney disease and anaemia was admitted under the Department of Internal Medicine in a tertiary institution for symptoms of shortness of breath, orthopnoea and lower limb oedema corresponding to an exacerbation of heart failure.

On further examination hyperpigmented scaly macules were noted over his face and back dating 6 months prior to admission for which he was applying topical agents from a private practitioner. Initial differential based on the appearance included seborrheic dermatitis and psoriasis although there were no supporting joint involvement at that juncture.

Further investigations were prompted including skin biopsies and

an autoimmune panel, in lieu of the atypical presentation of the skin lesion, while simultaneously addressing his fluid overload with intravenous furosemide.

Workup established the cumulative diagnosis of SLE with skin lesions defined as discoid lupus, kidney disease stemming from Class IV lupus nephritis revealed post renal biopsy and the development of autoimmune haemolytic anaemia during his inpatient stay. It is also postulated that his cardiomyopathy may be a result of previous myocarditis. Patient is now scheduled for monthly intravenous cyclophosphamide.

Discussion

The diagnosis of SLE becomes second nature after each system involvement have been elicited. However, the arduous task is in the journey to work up not only the clinical presentation but all the patient's symptoms to leave no stones unturned to elicit the system involvement where the role of an internist becomes vital.

#1095 - Case Report

MY PATIENT HAS AN ANCA-POSITIVE IGA NEPHROPATHY: ARE WE FACING A NEW DISEASE?

Maria Cynthia Fuentes-Lacouture¹, Camilo Cortés², Julián Naranjo-Millán¹, Manuel Huérfano-Castro²

¹ Fundación Cardioinfantil, Bogotá D.c, Colombia

² Hospital Universitario Mayor Méderi, Bogotá D.c, Colombia

Introduction

Rapidly progressive glomerulonephritis (RPGN) occurs in less than 10% of patients with IgA nephropathy. Histology is characterized by the presence of crescents in the kidney with IgA deposits in immunofluorescence. Rarely, the presence of circulating anti neutrophil cytoplasmic antibodies (ANCA) in serum has been found in some cases, without being able to establish if we are facing up an association or if it is new autoimmune entity.

Case description

A 57-year-old woman was admitted to the hospital because of headache and facial edema. Initial workup showed 3520 white blood cells/mm³ (67% neutrophils and 27% lymphocytes), 10.36 gr/dL hemoglobin and 315,000 platelets. Renal function tests showed a creatinine of 3.56 mg/dL and blood urea nitrogen of 40 mg/dL. Urine tests was positive for proteinuria. She also had hyperpigmented, pruritic plaques on skin of sun-exposed areas of both arms. ANAs, Anti Ro, Anti La, Anti Scl - 70, Rheumatoid Factor, Anti Citrullinated peptide, and tests for Hepatitis B and C, which are all negative. Renal function continued to deteriorate, and RPGN was considered. We requested vasculitis tests, performed renal biopsy and initiated treatment with high-dose corticosteroids. Serum p-ANCA returned positive, and renal histology showed glomerulonephritis with extracapillary proliferation and crescents, immunofluorescence was positive for IgA deposits. The skin biopsy was positive for lymphocytic

infiltration. A final diagnosis of IgA nephropathy associated with p-ANCA was made and cyclophosphamide was initiated. Patient remains asymptomatic until today.

Discussion

IgA nephropathy is a rare cause of RPGN, appearing in less than 10% of these cases. However, a percentage of patients with an aggressive course are associated with the presence of anti-neutrophil cytoplasmic antibodies (ANCA), with a faster renal deterioration and the requirement of renal replacement therapy in a shorter time since diagnosis. It is unknown if this association has a pathophysiological basis, or if it is a new isolated entity. It's opportune diagnosis through immunological tests and renal biopsy can prevent patient of requiring RRT in the future. Treatment with high-dose steroids and cyclophosphamide appears effective if started early. We present the case of a patient who debuted with RPGN, in whom IgA nephropathy and p-ANCA were documented, who had a favorable outcome after the administration of cyclophosphamide for 6 months.

#1100 - Case Report

GRANULOMATOSIS WITH POLYANGIITIS: A DEMANDING CHALLENGE

Carla Pereira Fontes, Filipa Martins Duarte, José Moura Meireles
Centro Hospitalar de Entre o Douro e Vouga (CHEDV), Santa Maria Da Feira, Portugal

Introduction

Granulomatosis with polyangiitis (GPA), formerly known as Wegener's granulomatosis, is a rare systemic disorder characterized by necrotizing granulomatous inflammation and pauci-immune vasculitis of the small and medium-sized blood vessels, affecting mainly the respiratory tract and kidneys. In most cases, it's associated with antineutrophil cytoplasmic antibodies (ANCA).

Case description

A 79-year-old woman, with hypertension and dyslipidemia, presented to the emergency department with an eight-month history of nonspecific constitutional complaints of fever, anorexia and unintentional weight loss of 10 Kg. She also experienced an episode of central retinal artery occlusion in the right eye two-month before admission. Ambulatory work-up disclosed iron deficiency anemia, with no suspicious lesions on digestive endoscopic studies. Despite oral iron replacement, hemoglobin levels remained low, requiring sequential blood transfusion. Additionally, concurrent elevation of C-reactive protein and erythrocyte sedimentation rate, as well as nonoliguric acute kidney injury were noted. Over the next days, the patient's status worsened, with new-onset dyspnea and hypoxemia. A thoracic computed tomography (CT) scan was performed showing bilateral pleural effusion and alveolar infiltrates, without pulmonary nodules or lymphadenopathies. A positive MPO-ANCA was

apparent, but the remaining immunologic study, including PR3-ANCA, was negative. Tests for human immunodeficiency virus, hepatitis B and C virus were negative. At this point, a systemic disease with renal and respiratory involvement was considered and intravenous pulses of methylprednisolone administered. Subsequent respiratory exacerbation with hemoptoic sputum was observed, and a new CT showed more bilateral consolidations and larger pleural effusion. Bronchofibroscopy excluded lesions and inflammatory signs of the bronchial tree; bronchoalveolar lavage was negative for *Mycobacterium tuberculosis* and other agents. Renal biopsy was performed and histological study revealed granulomatous vasculitis associated to pauci-immune crescentic glomerulonephritis. After induction therapy with cyclophosphamide and corticotherapy, the patient showed a continuous improvement in renal function and respiratory symptoms along with anemia stability.

Discussion

GPA remains a clinical challenge due to a widely variable spectrum of clinical presentations. Early diagnosis and treatment are essential for minimizing irreversible organs damage and death.

#1118 - Case Report

COULD IT BE JUST LUPUS?

Inês Goulart, Joana Rosa Martins, Filipe Filipe, Ana Bento Rodrigues, Ryan Costa Silva, Alba Janeiro Acabado, Paulo Cantiga Duarte

Centro Hospitalar Lisboa Norte, Lisboa, Portugal

Introduction

Systemic lupus erythematosus (SLE) is an autoimmune disease characterized by clinical and laboratorial manifestations (2012 SLICC criteria), which include inflammatory polyarthritis.

Case description

The authors present a case of a 30-year-old woman, from Cabo-Verde, with a previous diagnosis of SLE, that had two previous hospitalizations, a recent one caused by disease exacerbation. She was started on azathioprine as a steroid-sparing agent, due to rupture of the right semimembranosus tendon secondary to high corticoid doses, that was later tapered.

During tapering, she developed oligoarthritis with functional impotence of the shoulder, wrist, right hip and knee, associated with increased local temperature, thrombocytopenia and increased C reactive-protein (20mg/dL). She was hospitalized and put on empirical antibiotic therapy with ceftriaxone and flucloxacillin.

A knee arthrocentesis was performed, which revealed purulent synovial fluid, with subsequent isolation of *Neisseria gonorrhoeae*. Three days after, synovial fluid was drawn from the right elbow without agent isolation. The patient later developed fever, exuberant arm and right forearm edema, with rising inflammatory parameters. Antibiotic coverage was broadened

with meropenem and vancomycin due to the hypothesis of cellulitis post arthrocentesis. An echocardiogram was done to exclude endocarditis.

On the 17th day of antibiotic therapy, fever reappeared along with leukopenia with neutropenia, thrombocytopenia and complement consumption, with no rise of acute phase reagents. It was admitted a SLE flare and gammaglobulin was initiated (for 5 days) with subsequent improvement of leukopenia and thrombocytopenia and complement rise.

At the 24th day a toxidermia caused by prolonged antibiotic therapy was admitted after the appearance of non-pruritic urticarial exanthema. She made a posterior switch to levofloxacin with good outcome.

Discussion

The authors with this case pretend to alert to the importance of the differential diagnosis in cases of polyarthritis in patients with autoimmune diseases (such as SLE), presenting a case of a *N.gonorrhoeae* septic arthritis with some further complications.

#1129 - Abstract

RA PROGNOSIS AND IMMUNOLOGICAL FACTORS: THE IMPACT OF ACPA AND RF.

Haifa Hajji, Maroua Slouma, Rim Dhahri, Leila Metoui, Najeh Boussetta, Nourhouda Gueddich, Faïda Ajili, Imen Gharsallah, Bassem Louzir

Hopital Militaire de Tunis, Tunis, Tunisia

Background

There are well-documented associations between RA prognosis and immunological factors¹

Methods

We conducted a retrospective study including patients with rheumatoid arthritis according to 2010 ACR/European League Against Rheumatism (EULAR) criteria. For each patient we collected following data: age, the disease activity score (DASESR), the inflammatory biomarkers C-reactive protein (CRP) and erythrocyte sedimentation rate (ESR).

Results

Ninety two patients were included. The mean age was 54.13 years. Sex ratio M/F was 0.27. The average duration of the disease was 101.511 months. Rheumatoid factor and ACPA were positive in 42 and 61 patients with a mean value of 303.09 and 118.455 respectively. The patients were under steroid treatment in 94.6%. The mean dosage was 9.54 mg/d. Methotrexate was prescribed in 96.7% cases and TNF blockers in 48.1% cases.

The mean CRP and ESR were 26.665 mg/l and 42.198 mm/1h respectively. Mean DAS28-ESR score was 5,066. Thirty eight patients had high disease activity (DAS28-ESR>5.1) and twenty four were in remission (DAS28-ESR<2.6). The DAS28-ESR was higher in patients with RF (5.35 vs 4.808, p=0.06) and ACPA (5.08

vs 4.78, $p=0.395$). Levels of CRP and ESR were not significantly increased in patients positive for ACPA (53.7% vs 46.29%, $p=0.171$, 79.76% vs 20.83%, $p=0.219$). The use of biological treatments was more frequent among patients positive for FR (56.75% vs 43.24%, $p=0.211$) and ACPA (78.37% vs 21.62%, $p=0.330$). The use of steroids was more frequent in patients with ACPA (75.94% vs 24.05%, $p=0.007$).

Conclusion

Our study showed that seropositivity for ACPA and RF is associated with a higher disease activity, steroids prescription, raised inflammatory biomarkers and more frequent use of DMARDs. However, this association is not significant except for steroid prescription. Seronegative RA does not appear to be a benign subtype.

Reference

1. Manfredsdottir VF, Vikingsdottir T, Jonsson T, Geirsson AJ, Kjartansson O, Heimisdottir M, et al. The effects of tobacco smoking and rheumatoid factor seropositivity on disease activity and joint damage in early rheumatoid arthritis. *Rheumatology* 2006;45(6):734-40.

#1135 - Case Report

FEVER OF UNKNOWN ORIGIN AND ACUTE MYOCARDIAL INFARCTION: A SINGLE PROCESS OR TWO INDEPENDENT PROCESSES

Marta Bacete Cebrián, Jesús Baltasar Corral, Cristina Llamazares Mendo, Eduardo Luis Peñaloza Martínez, María Mercedes Ferreiro-Mazón Jenaro, Guillermo Soria Fernández-Llamazares, Nuria Gabarró López, María Gómez Antúnez
Gregorio Marañón General University Hospital, Madrid, Spain

Introduction

ANCA-positive vasculitis can cause fever of unknown origin (FUO) and infrequently causes ischemic heart disease. We present a case of FUO and acute myocardial infarction (AMI) secondary to ANCA vasculitis.

Case description

A 73-year-old Moroccan male (last trip 45 days before) with vitiligo and a post-traumatic splenectomy, came to our hospital with a one-month history of daily fever up to 39°C. It predominated in the evening and associated constipation, abdominal pain, proximal pain in the lower limbs and constitutional syndrome. He denied toxic habits or other epidemiological background. Physical examination was normal. Blood test showed neutrophilia, elevation of acute phase reactants (platelets, CRP, fibrinogen), normal procalcitonin, normal renal function and dissociated cholestasis. Serial blood cultures, BAAR and PCR in sputum were negative. The chest and abdominal x-ray and the transthoracic echocardiogram had no pathological findings. Gastroscopy showed esophagitis due to

hiatal hernia, the colonoscopy was normal. PET-CT with uptake in thyroid, liver and minimal in right upper pulmonary lobe. It was completed with hepatic MRI (normal) and thyroid ultrasound (solid nodule with biopsy with non-specific follicular atypia). The study is extended with autoimmunity: P-ANCA Positive 1/20, Anti-Myeloperoxidase (MPO) antibodies > 134.00 IU / mL, Anti-SSA / RO antibodies > 100.00 Positive, Anti-Nuclear antibodies IFA Positive 1/320 mottled pattern. Electromyogram with pattern of myositis and predominantly axonal polyneuropathy. Skeletal muscle biopsy was normal. During his stay the patient developed an AMI without ST elevation with anterior descending artery and circumflex lesions in coronary angiography. It was initiated methylprednisolone boluses, achieving the remission of fever and a clear improvement in the general condition of the patient. Surgical revascularization of coronary lesions is performed. The patient received maintenance treatment with prednisone and mycophenolate, with remission of all the symptoms.

Discussion

We have a patient with general, digestive, muscular and CNS involvement, in whom infectious pathology has been ruled out, which is due to ANCA positive vasculitis, and an AMI with clinical improvement after the start of immunosuppressants. After a review of scientific literature, it has been found that coronary involvement is rare in ANCA vasculitis and there have been no reported cases of AMI in anti-MPO positive vasculitis, being this the first case described.

#1153 - Medical Image

KUMMELL DISEASE, COMPLICATION OF LONG TERM USE OF STEROIDS

Maria Manuel Costa¹, Catarina Bastos², Joana Rodrigues³

¹ Hospital São Sebastião, Oliveira De Azemeis, Portugal

² Hospital São Sebastião, Santa Maria Da Feira, Portugal

³ Hospital São Sebastião, Vila Nova De Gaia, Portugal

Clinical summary

50-year-old woman, history of systemic lupus erythematosus under long-lasting systemic corticosteroid therapy, totally dependent. Hospitalized due to infectious respiratory episode. During hospitalization, for persistent complaints of low back pain with poor response to analgesic therapy. A computerized tomography was performed on the spine where gas bubbles within the D12 vertebral body were identified, suggesting Kummell disease.

Kummell disease, or avascular necrosis of the vertebral body, presents the vertebral osteonecrosis with compression deformity, intravertebral vacuum cleft, and exaggerated kyphosis weeks to months after a minor traumatic injury. This rare disease is usually associated with aging population and osteoporosis, which has a high risk for long term use of steroids.

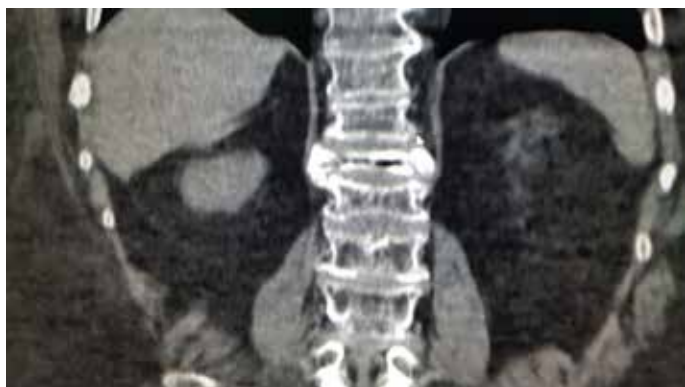

Figure #1153. Avascular necrosis of the vertebral body.

#1184 - Abstract

IS THERE AN ASSOCIATION BETWEEN B-CELL COUNT AND RADIOGRAPHIC PROGRESSION IN PATIENTS TREATING RITUXIMAB?

Anastasia Pivanova

V. A. Nasonova Research Institute of Rheumatology, Moscow, Russia,
Moscow, Russia

Background

Background: Rheumatoid arthritis is a chronic autoimmune disease characterised by inflammation of the synovial tissue and destruction of the underlying cartilage and bone. The goal of antirheumatic treatment is not only to attenuate the clinical symptoms of joint inflammation, but also to inhibit the progression of joint destruction. Rituximab - it is a chimeric monoclonal antibody that targets the CD20 molecule expressed on the surface of B cells. It has been successfully used to treat rheumatoid arthritis, and it is worth noting that its antidestructive effect sometimes does not meet the clinical.

Objective: To study the impact of B-cells depleting therapy (RTM) on joint destruction in correlation with B-cells counts.

Methods

Materials and methods: The study included 61 RA pts (average disease duration $10,1 \pm 7,7$ y., mean DAS28 $6,3 \pm 0,94$, RF-positive - 87%, ACCP-positive 93%) undergoing RTM therapy. Clinical effect was scored by EULAR criteria, radiographic progression was assessed using Sharp/van der Heijde (SvH) modified scoring method. B-cell level was measured with flow cytometry.

Results

Results: By Week 48 after 2 RTM course good response was documented in 29,7% pts, good and satisfactory - in 85,3%; remission was achieved in 14,6% pts. There was no radiographic progression in remission pts., in 83% of pts with low disease activity and in 33% - with moderate disease activity. Of note, further progression in joint space narrowing was more pronounced than bony tissue destruction - in 32% and 25 %m respectively. Clinical and anti-destructive effects were often dis-matching: bone destruction was abrogated without any clinical improvement in

54% of pts. There was no significant difference in clinical effects of RTM dosing regimens (1000mg x2 or 500mg x2). More potent anti-destructive effect was documented in pts getting higher RTM dose values. No significant influence of B-cells depletion on radiographic progression of the disease was noticed. Although, in RA pts achieving remission B-cell depletion was more notable as compared to pts with active disease.

Conclusion

Conclusion: Therapeutic effect of two dosing regimens was similar, but the protective effect against bone destruction was more pronounced with higher RTM doses. Radiographic progression did not show any correlation with the degree of B-cells depletion. Most pronounced B-cells depletion was documented in pts achieving remission.

#1185 - Abstract

BIOLOGICAL AGENTS – EXPERIENCE OF A PRESCRIBING CENTRE

Regina Costa, Ana Borges, Lèlita Santos

Coimbra Hospital and University Centre, Coimbra, Portugal

Background

Biological agents (BA) enhance or replace conventional immunosuppressive therapies therefore having a major impact on inflammatory symptoms and radiological damage of systemic autoimmune diseases (SAID). The goal of this study was to characterize the patients and their pathologies treated in a reference national prescribing centre of BA.

Methods

Retrospective observational study carried out through the analysis of the digital clinical data of all patients with a prescription of BA between October 2017 and June 2018 and a quarterly follow-up in the SAID clinic. The statistical analysis was performed using the SPSS statistical package version 25 and Microsoft Excel 2018.

Results

85 patients were included: 68.2% (n=58) women with mean age of 54.4 years. The most prevalent disease was rheumatoid arthritis with 32.9% (n=28), followed by psoriatic arthritis (16.5%, n=14) and ankylosing spondylitis (15.3%, n=13). The mean duration of disease was 12.4 years. The most prescribed agents were the anti-TNF. Of these, the most prescribed was etanercept with 43.5% (n=37), followed by infliximab (23.5%, n=20) and adalimumab (10.6%, n=9). While some patients were simultaneously treated with conventional immunosuppressive drugs, 69.4% had BA as monotherapy with good results, with 50.6% of the patients having no disease progression from the start of BA. Very few adverse effects were reported: only 8.2% were registered, the most common being skin reactions at the injection site. No cancer has been diagnosed so far following therapy with BA.

Conclusion

Over the years there has been an increase in the prescription of BA, which was noticeable in this centre and consistent with the practice of other centres described in the literature. These drugs have started to be used earlier and with more localized attainment of disease, though we are still behind concerning topic.

#1201 - Case Report

NON-OBSTRUCTIVE PANCREATITIS: A DIAGNOSTIC CHALLENGE

Mariana Silva Santos, Daniela Luz Silva Rodrigues, Helder Santos, António Cardoso, Fátima Campante
Centro Hospitalar Barreiro-Montijo, Barreiro, Portugal

Introduction

Pancreatitis is mostly caused by vesicular lithiasis and alcohol abuse, however, it may be caused by less common disorders, such as hypertriglyceridemia and IgG4 related pancreatitis. While its pathogenesis is yet to be understood, IgG4 related disease (IgG4-RD) is an increasingly recognized immune-mediated systemic inflammatory condition. Several specific organ pathological processes sharing clinical, serologic and pathologic characteristics were proven to be related and, therefore, it is important to be aware of this disorder. IgG4-RD may involve virtually any organ but pancreatitis is the most frequent manifestation.

Case description

We bring you the case of a 59 years old woman with history of breast cancer, asthma and rheumatoid arthritis under leflunomide. The patient went to the emergency room (ER) because of a dull pain in the upper abdomen, radiating to the back and associated with nausea and vomiting. The pain had been present for about 3 months and there was no relation to feeding or to gastrointestinal symptoms. Additionally, during the previous month, the patient had been presenting intermittent fever. The patient had been at the ER several times recently with the same complaints, but blood tests and abdominal ultra-sound were normal and the patient's symptoms would improve with symptomatic treatment. At the present ER visit, liver and pancreatic tests were normal but sedimentation velocity and C reactive protein were high. The CT scan revealed non-obstructive pancreatitis. Blood tests were performed, revealing normal triglycerides and calcium levels, as well as normal liver and pancreatic tests. IgG4 levels were high. The patient recovered well over a week, with no complications.

Discussion

The pancreatitis etiology hypothesis were toxicity caused by leflunomide or IgG4 autoimmune pancreatitis. Several months after suspending leflunomide, the patient had a new episode of acute pancreatitis and, therefore, IgG4-RP diagnosis was assumed. Currently, the patient is performing tests in order to look for other organ involvement.

IgG4-RD is characterized by mass-forming sclerosing lesions,

elevated serum IgG4 and tissue infiltration by IgG4-positive plasma cells, causing tumor-like hypertrophy of the affected organs that may be confused with a malignant neoplasm. Furthermore, there is some evidence (although controversial) that IgG4-RD is related to a higher risk of cancer. Conversely, history of cancer seems to be associated with higher risk of developing IgG4-RD.

#1222 - Case Report

VASCULITIS: THE SNEAKY DISEASE

Catarina Fernandes Medeiros, David Ferreira, Ana Massano, Jorge Garcia, Rita Serras Jorge, Fátima Pimenta
Médio Tejo Hospital Center, Abrantes, Portugal

Introduction

Vasculitis is defined by the presence of inflammatory leukocytes in vessel walls with reactive damage. They may occur as a primary process or secondary to other disease. With a great variety of symptoms and signs, a detailed history, a careful physical examination and adequate laboratory testing are crucial for a correct diagnosis.

Case description

72 years-old man, had a 7 months history of cough, with mucopurulent sputum, and fever mostly at evenings, that came several times to the emergency department, being diagnosed with pneumoniae and took several antibiotics without resolution of the symptoms. Two weeks after that the patient started complaining of paraesthesia in his left hand, foot and progressive muscular weakness in right arm. He confirmed to have had asthenia, anorexia, fatigue to small efforts, weight loss and frontal headaches. On physical examination he had muscular weakness in the right arm (Grade 3+/5) with atrophic interosseous muscles in the hand.

Blood counts showed a leucocytosis ($12 \times 10^9/L$), increased in erythrocyte sedimentation rate (120 mm/h) and C-reactive protein (13.7 mg/dL), creatinine and urine analysis were normal. Brain magnetic resonance revealed "supra and infratentorial pachymeninges, falx and tent of cerebellum thickening, which suggested meningitis or systemic disease". The lumbar puncture showed proteins increasement. Blood, urine and spinal fluid culture were negative. Thoracic tomography displays "bilateral and symmetrical reticular pulmonary opacities with ground-glass". Electromyography shows "generalized severe sensory-motor axonal polyneuropathy with asymmetry of the upper limbs, suggestive of vasculitic nature". By then, further laboratory tests were positive for anti-neutrophil cytoplasmic antibody (ANCA) and anti-myeloperoxidase antibody (MPO). After this we excluded malignancies (normal positron emission tomography). With the diagnose of MPO-ANCA associated vasculitis the patient started a remission-induction treatment with cyclophosphamide and prednisolone, which ceased the fever, but without immediately neurological improvement.

Discussion

ANCA-associated vasculitis is a rare disease, theoretically it can affect all systems. Neurological involvement in the course of ANCA-associated vasculitis is not uncommon, but demands a high degree of suspicion. In this case 7 months of unspecific and systemic symptoms difficult the diagnose. Early diagnosis and appropriate treatment are vital to avoid neurological relapses and sequelae.

#1223 - Abstract

ARE NEUTROPHIL- AND PLATELET-TO-LYMPHOCYTE RATIOS CORRELATED WITH DISEASE ACTIVITY IN SPONDYLAORTRHITIS?

Maroua Slouma, Safa Rahmouni, Rim Dhahri, Leila Metoui, Najeh Boussetta, Nour Gueddiche, Feida Laajili, Imen Gharsallah, Bassem Louzir

military hospital of instruction of tunis, Tunis, Tunisia

Background

Platelet-to-lymphocyte ratio (PLR) and neutrophil-to-lymphocyte ratio (NLR) have been reported to reflect the inflammatory response and disease activity in a variety of diseases.

This study aimed to assess the value of PLR and NLR as markers to monitor disease activity in spondyloarthritis (SpA).

Methods

A retrospective study including patients with spondyloarthritis (SpA) according to Assessment of Spondyloarthritis International Society Criteria.

For each patient we measured the PLR and NLR.

Spondylitis Disease Activity Index (BASDAI) was used to assess disease activity.

The Bath AS Metrology Index (BASMI) was used to evaluate spinal mobility.

A radiological assessment of the spine was performed using the Modified Stoke AS Spine Score (mSASSS) and The Bath Ankylosing Spondylitis Radiology Index (BASRI-s).

Results

112 patients were included (82 male and 20 female). The mean age was 43.78±12.91 years. The mean age at diagnosis was 37.8±13.45 years. The mean BASDAI was 4.075±2.36. The mean of C-reactive protein (CRP) and erythrocyte sedimentation rate (ESR) were 31.28±47.25 mg/dL and 36.21±27.18 mmH.

The mean BASRI-s and mSASSS were respectively 3.99±2.96 and 10.26±15.41.

The mean PLR and NLR were respectively 149.36±72 and 2.29±1.84.

Smokers had lower PLR (160.37 vs 134, p=0.05).

We found a correlation between PLR and NLR (r=0.601, p=0.00).

A positive correlation was found between PLR and these parameters :CRP (r=0.453, p=0.00), ESR (r=0.341, p=0.00) and BASMI (0.130, p=0.02).

There was a negative correlation between body mass index and PLR (r=-0.216, p=0.038).

However, no correlation was found between PLR and BASDAI.

BASRI-s, mSASSS were not correlated to the PLR or NLR.

Conclusion

According to the present study, PLR was correlated to acute phase reactants (ESR, CRP).

Another important finding was a negative but weak correlation between BASDAI and NLR. This contrasts with previous studies¹.

Further studies with larger patient populations and longer follow-up periods should be designed to enlighten the relationships more precisely.

Reference

1. İnal EE, Sunar İ, Sarataş Ş, Eroğlu P, İnal S, Yener. M. Arch Rheumatol. 2015;30(2):130-7.

#1226 - Abstract

THE IMPACT OF BODY MASS INDEX IN ANKYLOSING SPONDYLITIS

Maroua Slouma, Safa Rahmouni, Rim Dhahri, Leila Metoui, Najeh Boussetta, Nour Gueddiche, Feida Laajili, Imen Gharsallah, Bassem Louzir

Military Hospital of Instruction of Tunisia, Tunis, Tunisia

Background

In rheumatoid arthritis, increased adiposity is protective against radiological progression. In ankylosing spondylitis (AS), the prevalence of obesity and its relationship to disease-specific features are not known.

We aimed to study the effect of the overweightness and obesity on disease activity in ankylosing spondylitis

Methods

Demographic data and disease characteristics were collected from 112 patients with AS.

Disease activity, symptomatology, and functional disability were examined using standard AS questionnaires.

Body mass index (BMI) was classified according to the World Health Organization classification as either below weight (<18.49 kg/m², normal weight (18.50 – 24.99kg/m²), overweight (25.00 – 29.99kg/m²), or obese (≥ 30kg/m²).

Results

Of the 112 patients, 72.32% were men. The mean age was 43.78±12.91 years. The mean age at diagnosis was 35.08±12.56 years.

The mean BASDAI score was 4.07±2.36. The disease was active (BASDAI>4) in 56.4% of cases.

The mean BMI was 25.35 ± 4.59kg/m². Below weight, normal weight overweight and obesity were observed in 5.2%, 44.8%,

33.3% ,16.6% respectively. One patient had class III obesity , two had class II and thirteen had class I(11.6%).

Women had higher BMI (27.04 vs 24.69kg/m², p=0.024).

We found a positive correlation between BMI and following parameters: age (r=0.258, p=0.011), age at diagnosis (r=0.34, p= 0.01), lumbar bone mineral density (r=0.433, p= 0.00) and Erythrocyte sediment rate (ESR) (r=0.547, p=0.000).

However, a negative correlation was found between BMI and platelet to lymphocyte ratio (r=-0.216, p=0.038)

No significant correlation was found between BMI and the following parameters: BASMI, BASDAI, BASFI, mSASSS, BASRI and C-reactive protein levels.

Conclusion

Our study demonstrated that overweight and obesity are frequent in patients with AS.

A high BMI seemed to be associated with inflammation notably ESR. And it was correlated to lumbar mineral density.

Interestingly we found a correlation between BMI and platelet to lymphocyte ratio which is known to be related to inflammatory diseases.

Otherwise, we failed to find a correlation between BMI and disease activity (BASDAI).

Previous studies evaluated body composition in AS and suggested an absence of or a poor relationship between disease activity, particularly inflammatory cytokines, and soft tissue composition.

#1236 - Abstract

AUTO-ANTIBODIES AND EXTRA-ARTICULAR MANIFESTATIONS IN PATIENTS WITH RHEUMATOID ARTHRITIS

Safa Rahmouni, Maroua Slouma, Rim Dhahri, Leila Metoui, Najah Boussetta, Nour Gueddiche, Faïda Laajili, Imen Gharsallah, Bassem Louzir

Military Hospital of Instruction of Tunisi, Tunisi, Tunisia

Background

Rheumatoid arthritis is a systemic inflammatory disease. The inflammatory process can spread to other systems and organs, causing extra-articular manifestations of RA (ExRA).

Some predictors of ExRA have been identified such as auto-antibodies (rheumatoid factor (RF), anti-cyclic citrullinated peptide antibody (anti-CCP), and antinuclear antibody (ANA))

The aim of this study was to determine the relationship between auto-antibody and the presence of ExRA.

Methods

In this retrospective, we enrolled 92 patients with RA.

Demographic data and disease characteristics were collected.

The extra-articular manifestations studied were rheumatoid nodules; cardiac and pulmonary manifestations ,chronic disease anemia; scleritis; episcleritis; sicca syndrome, Sjögren's syndrome and osteoporosis.

The patients were divided into two groups: G1 with ExRA and G0 without ExRA.

Results

Of the 92 patients, 78.3% were women with a mean age of 54.13±12.9 years.

The mean disease duration was 101.51±101 months.

The mean DAS28 was 5.06 and 52.8% had active disease (DAS28>5,1).

ExRA manifestations were found in 68 patients (73.9%):

Rheumatoid nodules (12.2%), sicca syndrome (67.8%), scleritis (27.8%), episcleritis (3%), cardiac rhythm disorders (2.2%), conduction disorders (3.4%), mitral valve disease (3.4%) pericarditis (2.2%), interstitial pneumonia (7.6%), pleural effusion (1.1%), chronic disease anemia (44.6%),osteoporosis (33.3%) and Sjogren's syndrome (4.34%)

Anti-CCP-positivity was found in 71.87% of patients in G1 compared to 75% in G0 (p=0.784).

RF positivity was found in 53.03% of patients in G1 compared to 33.33% in G0 (p=0.116).

Patients with ExRA had more frequently ANA (16.98% vs 0%, p=0.071)

Patients in G1 had higher titers of anti-CCP, but this difference was not significant (120.15UI vs 112.47 UI, p=0.784).

No difference was found between the two group concerning the titers of RF (299.53UI vs 312.77UI, p=0.935).

Rheumatoid nodules were found to be associated with high levels of RF (761.16 UI vs 262.33UI, p=0.044)

Pulmonary involvement was more frequent in patient RF positive (66.66% vs 40.98%, p=0.033).

Conclusion

In our study, extra-articular manifestations were frequent.

Rheumatoid factor seemed to be associated to pulmonary involvement and rheumatoid nodules. Antinuclear antibody were frequently positive in patients with extra-articular manifestations. However anti-CCP was not associated to ExRA.

#1237 - Case Report

BEHIND APPEARANCES - SYSTEMIC LUPUS ERYTHEMATOSUS VERSUS RHEUMATOID ARTHRITIS

Ancuta Nistor¹, Mirela Parvu^{2,1}, Ildiko Scheip¹

¹ County Emergency Clinical Hospital Tg.Mures, Targu Mures, Romania

² University of Medicine, Pharmacy, Sciences and Technology Tg.Mures, Targu Mures, Romania

Introduction

Systemic lupus erythematosus (SLE) and rheumatoid arthritis (RA) are autoimmune diseases with different clinical and serological features affecting various organs and systems. "Rhus" is a term used to describe patients with coexistence of RA and SLE.

Case description

A 21 year old patient from urban area, came in the rheumatology service in April 2018 with an inflammatory polyarthritis syndrome in the small and large joints of hands and feet, with stiffness (150 minutes) and functional impotence, fatigue. From the patient's history, we retain appendectomy (2011), *Helicobacter pylori* (2014), RA with secondary antiphospholipid syndrome (June 2015), for which there are several treatment regimens in progress but the patient interrupts the treatment on her own initiative.

Objective Examination: discrete malar rash, postoperative scar in the right iliac fossa, hands: rheumatoid arthritis stage II / III appearance with multi-level arthritis: bilaterally metacarpophalangeal (MCF), bilateral radiocarpian (RC), metatarsophalangeal (MTF), proximal interphalangeal (IFP) - bilateral foot and dorsal-lumbar dextroconvex scoliosis.

Biologically we have mesenchymal inflammation and increased titre of the following antibodies: anti-protein citrulline (ACPA), anticardiolipin (ACA), antinuclear (AAN), anti-DNA double stranded. No other serological pathological changes.

Comparative hands radiography: detect joint-space narrowing with marginal erosions, comparative leg radiography: arthritic lesions at the metatarsal and proximal interphalangeal joints. Musculoskeletal ultrasound detecting joint inflammation with active synovitis at the small joints of the hands and the RC joints. Chest X-ray show typical images for pulmonary fibrosis.

Discussion

The presence of autoimmune serology for RA and SLE requires differential diagnosis and a complex therapeutic approach. Low compliance / adherence to the initial treatment, early onset of RA, rheumatoid arthritis associated / complicated with systemic manifestations requires a complex multidisciplinary approach to establish the diagnosis / treatment and careful monitoring of the patient to adjust medication and prevent complications.

#1243 - Case Report

SARCOID PANNICULITIS

Francisca Martins, Joana Barbosa, Joana Ferrão, Miguel Martins, Lara Câmara, António Mesquita, João Queirós, Rui Malheiro
Centro Hospitalar e Universitário Lisboa Central, Lisboa, Portugal

Introduction

Sarcoidosis is a systemic granulomatous disease capable of affecting virtually any organ system. Skin involvement can have multiple manifestations and different responses to treatment, placing the disease in the group of the "great imitators".

Case description

We report the case of a 36-year-old caucasian female patient that was first seen by internal medicine due to pain and inflammatory signs of the tibiotarsal joints for 7 days, developing walking impairment within the first 48 hours, which confined her to a wheelchair. She reported pain at rest, mainly overnight, and

morning stiffness lasting over 2 hours. There was no history of trauma, recent infections, travel or risk behaviour for sexually transmitted diseases. She worked as a health care professional, had no past medical history, no record of drugs addiction or medication use, and had no allergies known to date.

Physical examination revealed exuberant inflammatory signs in both feet, tibiotarsal joints and lower third of the legs, pain was present at rest and with passive or active joint movement. She had no lymphadenopathy or other visible changes. The patient was promptly admitted for further investigations and treatment.

Admission bloods showed an elevated erythrocyte sedimentation rate (71 mm/h) and C-reactive protein (159 mg/L), normal serum angiotensin converting enzyme and protein electrophoresis. The autoimmune studies were negative for HLA B27, antinuclear antibodies, anti-citrullinated protein antibodies and rheumatic factor. Screenings for tuberculosis and other infectious diseases were also negative.

TT joint ultrasound showed signs of panniculitis and there was bilateral hilar lymphadenopathy on the chest x-ray. A chest CT scan revealed a classic "123 sign" with bilateral hilar and paratracheal lymphadenopathy. To confirm the diagnosis and exclude other causes of lymph node enlargement, an endobronchial ultrasound and multiple biopsies were performed, confirming the presence of non-caseating granuloma.

She was started on prednisolone (0.5 mg/kg/day) with remarkable improvement of the soft tissue inflammatory signs and regained ability to walk.

Discussion

Panniculitis is an uncommon presentation of sarcoidosis, so medical awareness of these rare symptoms was key to a correct diagnosis and prompt treatment of an incapacitating condition.

#1246 - Abstract

OBESITY AND KNEE'S OSTEOARTHRITIS

Salma Athimni, Maroua Slouma, Rim Dhahri, Leila Metoui, Imen Gharsallah, Bassem Louzir
Military Hospital, Tunisi, Tunisia

Background

Osteoarthritis affecting knees is considered as a major cause of disability. The association between obesity and knee osteoarthritis was proven.

The aim of this study was to assess the overweight's impact on functional activity and the radiographic stage in patients suffering from knee's osteoarthritis.

Methods

A comparative prospective study was performed, 50 patients suffering from knee's osteoarthritis (M) and 50 safe controls (C). We did collect the following data for the patients of (M) group: age, body mass index (BMI), the functional impact evaluated by the Western Ontario and McMaster Universities Index of arthritis (WOMAC)

and the Knee X-rays score by Kellgren-Lawrence (KL) classification. We classify the BMI for the OMS definition: (1) Normal weight if the BMI was between 18.5 and 25 kg/m² (2) pre-obesity if BMI between 25-30 kg/m² and (3) obesity if the BMI \geq 35 kg/m².

The WOMAC index contains 24 questions, 5 related to pain (scored on 20), 2 to stiffness (scored on 8) and 17 to physical function (scored on 68).

The Kellgren and Lawrence (KL) classification include 5 X-ray grades (0 to 4) of osteoarthritis on the right and the left knee. The higher score was considered in each patient.

Results

The mean age was 61.64 \pm 10.72 years. The sex ratio M / F was 0.19. The BMI average was 31.18 \pm 6.19 kg/m². It was significantly higher on the (M) group (30.5 vs 27.2 kg/m², p: 0.007). The pre-obesity was more noticed in the (M) group (36% (n=18) vs 9% (n=5); p=0.05). The obesity rates were superior on the (M) group: (22% (n=11) vs 4% (n=2); p=0.047). Regarding the KL classification: 8% of the patients had a stage 2; 52% had a stage 3 and 40% a stage 4. There was a positive correlation between the BMI and functional impact of knee's osteoarthritis: WOMAC pain (r=0.243; p=0.046), WOMAC function (r=0.385; p=0.03) and normalized WOMAC (r=0.289; p=0.022).

There was no difference in BMI between different KL stages: stage 2 (26.45 kg/m²), stage 3 (31.69 kg/m²) and stage 4 (31.49 kg/m²); (p=0.714).

Conclusion

Overweight is a prognostic factor that appears to be responsible of a predominant functional impact in patients with knee's osteoarthritis. In our study, BMI was correlated to a deeper functional impact (with superior WOMAC index). However, overweight had no influence in the radiographic stage

#1254 - Abstract

AURICULAR IMPEDANCE IN THE DIAGNOSIS OF KNEE'S OSTEOARTHRITIS: A COMPARATIVE STUDY

Salma Athimni¹, Maroua Slouma¹, Rim Dhahri¹, Leila Metoui¹, Imen Gharsallah¹, Bassem Louzir¹, Alia Fazaa², Kaouther Ben Abdelghani², Ahmed Laater²

¹ Military Hospital, Tunisi, Tunisia

² Mongi Slim Hospital, Marsa, Tunisia

Background

According to the auricular diagnosis system in the traditional Chinese medicine, the areas of the auricle where decreased electrical skin resistance and heightened tenderness correspond to specific area soft the body where some pathological conditions exist.

The aim of this study was to assess the electrical conductivity corresponding to the specific area of the knee, in patients suffering from knee's osteoarthritis, comparing to a control group.

Methods

A comparative prospective study was performed, 50 patients suffering from osteoarthritis of the knee and 50 safe controls. Electrical conductivity in the knee's area was measured in both groups. Pain intensity and functional impact were assessed by VAS pain and WOMAC index in the patient group. Knee X-rays were scored for Kellgren-Lawrence grade

Results

The mean age of the participants in the experimental group and control group was 61.64 \pm 10.72 years and 56.57 \pm 15.35 years respectively. The sex ratio M / F in the two groups was 0.19. The osteoarthritis of the knee was bilateral in 74% of the cases. Electrical skin resistance was significantly decreased in the specific area in the experimental group (80%) comparing to the control group (20%) (p=0.0001). Gender and age were not associated with the result of the electrical conductivity in both groups. Moreover, duration of knee pain and VAS were not associated with lower skin conductivity. The electrical conductivity was associated with the WOMAC score concerning Function (p<0.05) in patients with bilateral osteoarthritis. However, there was no significant correlation with the items Pain and Stiffness of the WOMAC score. Decreased electrical skin resistance was significantly associated with advanced stages of knee's osteoarthritis. The conductivity of the Knee zone exhibited a sensitivity of 82%, a specificity of 80%, and a PPV of 80.3%.

Conclusion

This randomized controlled study showed that patients suffering from knee's osteoarthritis had decreased electrical conductivity in the specific area of the knee. Electrical skin resistance measurement provides good sensitivity, specificity, and predictive value in patients with knee's osteoarthritis. Such findings can advance our knowledge for diagnosing patients with knee's osteoarthritis. Further studies should be conducted to ascertain the diagnostic value of electrical skin resistance measurement in knee's osteoarthritis.

#1257 - Abstract

FIBROMYALGIA AND CHRONIC INFLAMMATORY RHEUMATISMS

Salma Athimni, Maroua Slouma, Rim Dhahri, Leila Metoui, Imen Gharsallah, Bassem Louzir
Military Hospital, Tunisi, Tunisia

Background

Pain is the main symptom in chronic inflammatory rheumatism (CIR). Patients with fibromyalgia (FM) have a sleep disorder, generalized pain, and fatigue that can affect their general wellbeing and their perception of joint pain. As a consequence, the disease activity index could be overestimated.

The objective of the present study was to assess the prevalence of fibromyalgia in CIR and the impact of CIR on disease activity.

Methods

This was a cross sectional study of 54 patients with CIR: rheumatoid arthritis (RA) (ACR/EULAR criteria 2010) and spondylarthritis (SA) (ASAS 2009) between January and March 2019. We collected epidemiologic, therapeutic and disease-related data. The screening was using the FIRST (5items/6) and the diagnosis was confirmed by ACR criteria fibromyalgia 2010 graduated on 31.

Results

Fifty-four patients were recruited: 19 presented with RA and 35 with SA. The mean age was 46 ± 2.6 years. The sex ratio was 1.61. The mean onset disease was 5 ± 0.8 years. Twenty patients (37%) were receiving conventional treatment: DMARDs or NSAID and 34 (64%) were under biological treatment.

34 (63%) patients fulfilled the ACR criteria fibromyalgia and the mean score was at 16.79 ± 2 . The frequency of FM was 68% in RA (6 men and 7 women) patients and 60% in SA patients (15 men and 6 women). The mean ACR score in RA and SA was respectively at 20.1 and 14.74. The mean DAS 28-ESR rate was at 3.65 ± 1.02 and the mean ASDAS-CRP rate at 3.04 ± 1.15 . There was no difference regarding disease activity between patient with and without fibromyalgia.

In patients with RA, there were no difference between patients with and without FM regarding following parameters: DAS 28-ESR (4.01 vs 3.05, p: 0.19); DAS 28-CRP (4.93 vs 4.30, p: 0.332); global health assessment (7.4 vs 7, p: 0.965); tender joints (11.3 vs 8.4, p: 0.514); positive ACPA (10 vs 2, p: 0.137) positive rheumatoid factor (8 vs 4, p: 0.475). Therefore, a higher number of swollen joints (SJ) was noticed in patients with FM (11 vs 4; p=0.015).

Conclusion

The frequency of FM seemed to be higher in patients with CID than in the general population. Our results showed no influence of the coexistence of fibromyalgia on the disease activity. nevertheless, a higher number of swollen joints is associated with FM. A larger study with an important patient's number is required.

#1266 - Case Report

OSTEOGENESIS IMPERFECTA : A SURPRISING REVELATION IN ADULT

Tayssir Ben Achour^{1,2}, Yosra Cherif^{1,2}, Maroua Mrouki^{1,2}, Mohamed Sami Zrida^{1,2}, Fatma Ben Dahmen¹, Meya Abdallah^{1,2}

¹ Tunis El Manar University Faculty of Medicine of Tunisia, Tunisia, Tunisia

² Regional Hospital Ben Arous, Internal Medicine Department, Ben Arous, Tunisia

Introduction

Osteogenesis imperfecta (OI) is a scarce inherited connective tissue disorder that cause skeletal abnormalities, bone fragility and deformity. Most fractures of vertebral bodies, hips and feet occur in childhood. We report a new case in a 59-year-old patient.

Case description

A 59-year-old female patient with a family history of multiple fractures and medical history of hypothyroidism admitted to the department of Internal Medicine for diabetic ketoacidosis. The physical examination revealed blue-grey sclera in both eyes, bone deformity of the phalanges and dentinogenesis imperfecta. Since the age of 5, she experienced repeated and multiple fractures. Moreover, she complained of bilateral hearing loss. Laboratory assessment revealed 25-OH vitamin D deficiency at $4.46 \mu\text{g/l}$ without phospho-calcic disorder. The bone mineral density was assessed and revealed osteoporosis. The patient was diagnosed with OI type 1. She was treated with vitamin D, calcium and bisphosphonates.

Discussion

OI is a hereditary disorder characterized by fragile bones and dentin dysplasia. A thorough clinical examination and earlier diagnosis and management may help patients.

#1284 - Case Report

SARCOIDOSIS OF THE BREAST - A RARE CASE REPORT

Daniela Da Costa Cardoso, Helena Temido, Lèlita Santos, Armando Carvalho

Centro Hospitalar e Universitário de Coimbra, Coimbra, Portugal

Introduction

Sarcoidosis is a multi-systemic inflammatory disease that can affect any organ, but it mainly involves the lungs and intrathoracic ganglia. Its main feature is the presence of non-caseous granulomas, although they are not specific to this disease. Breast involvement in sarcoidosis is rare and there are very few documented cases. It presents with a wide clinical spectrum, and is usually asymptomatic (50% of cases) at the time of diagnosis.

Case description

A 62-year-old woman was referred to the Internal Medicine clinic for bilateral painless breast nodules with no inflammatory signs, nipple discharge or associated skin lesions. The patient also referred evanescent erythematous and painful nodules on the anterior surface of both tibias, present for over a year.

Mammogram and breast ultrasound showed multiple bilateral nodules, with no radiographic features of malignancy. A mammary MRI showed bilateral nodules of suspicious morphology and enhanced kinetics. The complete blood count, protein electrophoresis and autoimmunity panel (ANAs, ENAs, dsDNA, ASCAs and pANCA) were normal. The throat swab for group A beta-hemolytic streptococcal infection, antistreptolysin titer, quantiferon and serologies for viral hepatitis or Human Immunodeficiency Virus were negative. SACE level was 73,7U/L. Biopsies were performed to clarify the diagnosis: the cutaneous biopsy showed granulomatous inflammatory infiltrate suggestive of erythema nodosum; the excisional mammary biopsy revealed

confluent, not necrotizing epithelioid granulomas, allowing for the diagnosis of mammary and cutaneous sarcoidosis. Ae thoracic CT-RAS and respiratory function tests excluded pulmonary involvement.

The patient was started on oral corticosteroids, with lesion regression.

Discussion

The diagnosis of isolated extrapulmonary sarcoidosis is challenging due to its rare presentation and non-specific histology. A high level of clinical suspicion is essential for early diagnosis. Exclusion of other (more serious) causes for nodules such as infection and malignancy is also crucial for a correct diagnosis.

#1300 - Abstract

PAPABLE PURPURA: CLINICAL AND ETIOLOGICAL CHARACTERISTICS

Nour Elhouda Guediche, Salma Dghaies, Samah Sayhi, Najah Boussetta, Maroua Slouma, Rim Dhahri, Faïda Ajili, Bassem Louzir
The Military Hospital of Tunisi, Tunisi, Tunisia

Background

Palpable purpura (PP) is a common clinicopathological entity which represents a challenge in term of etiologic diagnosis. It ranges in severity from a self-limited skin disorder to a life-threatening disease with prospect of multi-organ failure.

This work was undertaken to study clinical and histologic features of patient with PP and to establish the etiologic profile of PP in an internal medicine department.

Methods

A retrospective and descriptive study was conducted on adult patients hospitalized to explore PP from 2000 through 2018. We assessed clinical and histological features to reach a specific etiologic diagnosis.

Results

A total of 46 patients (25 men and 21 women; sex ratio=1.19) presenting with PP were identified. The mean age was 52.2 years. PP was petechial in 27 cases and necrotic in 14. It was located at lower limbs in 91.3% of cases. Eight patients presented a bleeding syndrome (digestive bleeding: n=4, macroscopic hematuria: n=4, hemoptysis: n=1). Systemic involvement occurred in 69.5% of patients: articular (n=21), renal (n=13), digestive (n=10), neurologic (n=11), pulmonary (n=5), cardiac (n=3). Skin biopsy, performed in 63.6%, revealed leucocytoclastic vasculitis in 30.4% of patients. Direct immunofluorescence study was positive in 12 cases. There was no significant benefit of skin biopsy in term of etiologic diagnosis (p=0.4). The average time for etiologic diagnosis was 12.7 days. Systemic diseases were the most frequent causes of PP (56.5%). Systemic vasculitis occurred in 15 patients as follows: IgA vasculitis (n=6), undetermined vasculitis (n=3), granulomatosis with polyangiitis (n=2), cryoglobulinemic

vasculitis (n=2, one of them was associated to HCV infection) and polyarteritis nodosa (n=1), microscopic polyangiitis (n=1). PP was related to cutaneous vasculitis in connective tissue disease in 8 cases: Sjögren syndrome (n=4), systemic lupus erythematosus (n=2) and rheumatoid vasculitis (n=2). Sarcoidosis occurred in one patient. Two cases of hereditary recurrent fever were noticed. Drug-induced vasculitis was identified in 7 cases. Five patients had septic vasculitis. In 5 cases (10.9%), the PP etiology remained undetermined. Bed rest was advocated in all patients. Colchicine was used in 8 cases and 23 patients had specific treatment. Complete recovery was observed in 69.5% of patients.

Conclusion

Etiologic diagnosis was determined in most patients in our study (89.1%), with a higher frequency of systemic diseases, which may be related to a selection bias.

#1304 - Abstract

CLINICAL AND BIOLOGICAL STUDY OF INFLAMMATORY IDIOPATHIC MYOPATHIES

Nour Elhouda Guediche, Salma Dghaies, Najah Boussetta, Samah Sayhi, Rim Dhahri, Maroua Slouma, Faïda Ajili, Bassem Louzir
The Military Hospital of Tunis, Tunis, Tunisia

Background

Inflammatory idiopathic myopathies (IIO) are characterised by a proximal muscular weakness associated to characteristic cutaneous lesions in the case of dermatomyositis (DM) and antisynthetase disease (ASD). The aim of this study was to describe the clinical, biological and therapeutic features in patients with IIO.

Methods

We underwent a retrospective and descriptive study of 14 patients with IIO who were hospitalized in the department of internal medicine from 2010 to 2018. Diagnosis was made with Peter and Bohan criteria. We studied clinical, biological and therapeutic features

Results

The mean age was 48 years old [20-77]. Sex ratio was 1.8 (9M/5F). We assessed 8 cases of dermatomyositis and 6 cases of polymyositis (3 of whom had ASD). All patients had myalgia and proximal muscle weakness. The electromyogram showed a myogenic pattern in 9 cases. The cutaneous signs were as follow: heliotrope rash (n=8), periungueal erythema (n=5), Gottron papules (n=5), mechanic's hands (n=3), Raynaud phenomenon (n=2), panniculitis (n=1). Dysphagia was observed in 5 patients, only one patient had swallowing disorder. Articular involvement was found in 6 patients. Six patients had pulmonary involvement resulting in dry cough and exercise dyspnea. The chest X-ray showed an interstitial syndrome in 5 cases, in which thoracic CT showed diffuse infiltrative lung disease. In pulmonary function

tests, a restrictive ventilatory disorder was described in 4 cases. One patient had cardiac involvement, in which echocardiography showed dilated cardiomyopathy with global hypokinesia of the left ventricle and cardiac MRI revealed myocarditis. Serum creatinine-kinase level was elevated in all cases with an average of 2185 IU/L. Anti-nuclear antibodies were positive in 5 patients with anti-Jo1 in 4 patients and anti-OJ in one patient. Myopathy was paraneoplastic in 4 patients (breast cancer, nasopharyngeal carcinoma, glioblastoma, pulmonary carcinoma). Twelve patients received corticosteroids, in combination with methotrexate (n=5) and azathioprine (n=1). Three patients received pulses of cyclophosphamide and 2 others had immunoglobulin therapy. One patient received anti-CD20 therapy. The evolution was favorable in 8 patients. Two patients had died.

Conclusion

In our study, DM was the most common IIO. Pulmonary involvement during this condition is a factor of worse prognosis requiring rapid management. Searching for an associated cancer at diagnosis and even during the follow up must be a priority.

#1305 - Abstract

HLA TYPING IN ETIOLOGICAL DIAGNOSIS OF UVEITIS

Nour Elhouda Guediche, Najah Boussetta, Yousra Ben Ariba, Rim Dhahri, Maroua Slouma, Faïda Ajili, Bassem Louzir

The Military Hospital of Tunis, Tunis, Tunisia

Background

HLA typing is an important feature in understanding the pathogenesis of several rheumatic disorders, particularly the spondyloarthropathies (SPA).

The aim of our study was to evaluate the role of HLA typing (B27, B51) as a diagnostic test in patients with uveitis.

Methods

It was a retrospective, descriptive and monocentric study of 31 cases of non-infectious uveitis who were hospitalized in the internal medicine department of the Military hospital of Tunis during 2018. Serological study of the expression of the antigens (Ag) B27 and B51 has been realized among our patients through a technique of complement-dependent microlymphocytotoxicity.

Results

The uveitis was anterior in 41.9% of cases. It was unilateral in 77.4% of cases and acute in 93.5% of cases. Etiology was found in 45.2% of our patients. A systemic disease was the cause of uveitis in all cases. The result of HLA types showed a significant association between the anterior uveitis and the HLA B27 (p=0.04). This association was more marked in patients with SPA (p=0.01). For the distribution of Ag B51, 22.58% of cases were positive for this marker. Furthermore positivity of this Ag was statistically correlated with chronic uveitis (p=0.01).

Conclusion

According to our study the utility of HLA testing is limited as a diagnostic test in patients with uveitis. The HLA B 51 typing showed no considerable value in the etiological diagnosis of uveitis. However the HLA typing could be useful in some cases especially the research of HLA B27 in the anterior uveitis associated to SPA.

#1308 - Medical Image

CUTANEOUS MANIFESTATIONS OF AN AUTOIMMUNE DISEASE

Sara Joana Faria¹, Ana Costa¹, Teresa Mendonça²

¹ Hospital Distrital da Figueira da Foz, Coimbra, Portugal

² Centro Hospitalar e Universitário do Porto, Unidade de Imunologia Clínica, Porto, Portugal

Clinical summary

Male, 82 years old, developed progressive thickening of the skin (thighs, abdominal wall, trunk and limbs) and thoraco-abdominal discomfort due to the extrinsic compression, dyspnea, postprandial infarction and eructations. At physical examination: presence of morpheaform plaques – confluent, non-symmetrical, some sclerotic and others atrophic, with poorly defined erythematous border areas, involving more than 80% of the body surface. Not present: sclerodactyly; telangiectasia; digital ulcers/pitting scars; puffy fingers; calcinosis cutis; facial sclerosis. Immunological markers and systemic involvement were negative. Clinical findings favored Generalized Morphea and the skin biopsy confirmed it. Patient started Prednisolone (PDN) 1mg/kg/day at weaning, with symptomatic improvement.

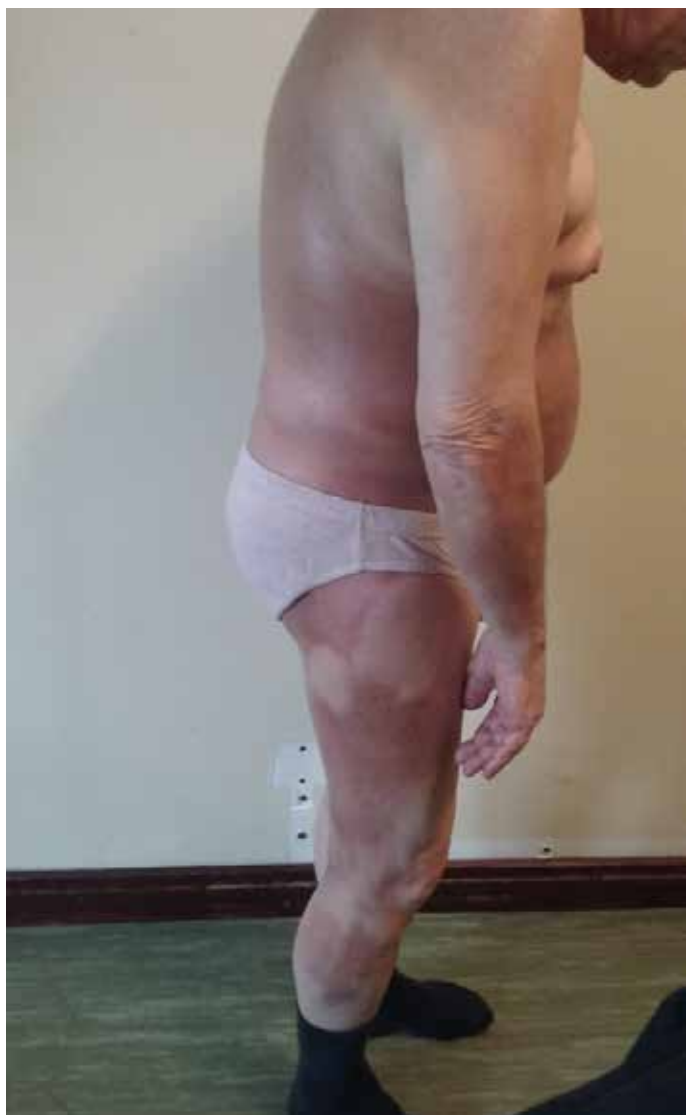

Figure #1308. Generalized morphea.

#1310 - Abstract

PREDICTIVE VALUE OF ANTI-CENTROMERE ANTIBODIES IN AUTOIMMUNE DISEASES: ANALYTICAL STUDY IN A SPECIALIZED CENTER

Sara Joana Faria¹, Ana F. Costa¹, Fábio Almeida¹, Carlos Vasconcelos²

¹ Hospital Distrital da Figueira da Foz, Coimbra, Portugal

² Centro Hospitalar e Universitário do Porto, Unidade de Imunologia Clínica, Porto, Portugal

Background

Anti-centromere antibody (ACA) is a type of anti-nuclear antibody (ANA) considered specific for systemic sclerosis (SSc). Despite this, it is occasionally detected in primary biliary cirrhosis (PBC), primary Sjogren's syndrome (SS) and rheumatoid arthritis (RA).

The objective of this study was to analyze positive ACA's patients and determine ACA's predictive value (PV) for autoimmune diseases (AID), namely SSc.

Methods

A retrospective, observational study, included patients (n=168) from an AID's reference center, with more than 18 years old and with ACA measurement, by immunofluorescence (IF), equal or greater than 240 U/mL, from January 2007 to December 2017. Data collection included age, sex, clinical diagnosis, other immunological markers and organ repercussion.

Results

Of the 149 patients included (19 patients followed in other hospital were excluded), 94% were female and the mean age of the first symptoms was 46.98 (18 to 77) years. The ANA titles were equal or bigger than 1/1280 U/mL in 75.2% (n=112) samples and 85.9% (n=128) had a centromere pattern in IF. The associated antibodies were: antimitochondrial in 20 cases, rheumatoid factor in 20, anti-SSA in 6, anti-dsDNA in 4, anti-RNP in 3, Scl-70 in 2 and anti-Sm in 1 case. 91 (61%) patients developed scleroderma, 18 (12.1%) PBC, 18 (12.1%) SS and 5 (3.4%) RA.

Capillaroscopy had revealed a sclerodermic pattern in 36 patients (39.6%). About organ repercussion: all had Raynaud Phenomenon (RP), 60 (65.9%) cutaneous alterations, 52 (57,1%) musculoskeletal pain, 35 (38.5%) pulmonary hypertension (PH), 19 (20.9%) altered respiratory function tests, 21 (23.1%) pulmonary fibrosis and 21 (23.1%) gastrointestinal disease.

ACA had a positive PV (PPV) of 85% for AID (61% for SSc). The mean time from symptoms to diagnosis was of 2.2 years. Using the Mann-Whitney test, it was found a statistically significant association between ACA values >258 U/ml and SSc (p<0.05), but not significant with other autoimmune diseases. Moreover, there is a statistically significant relationship regarding ACA titles in scleroderma's patients and cutaneous involvement, RP and fibrotic changes in computed tomography (not with PH).

Conclusion

Positive ACA's patients have a greater chance of developing AID, specially SSc and should be closely monitored. ACA titles > 240U/ml in our sample had a PPV of 85% for AID. ACA assay is specific for SSc and its levels are associated with an increase in cutaneous and pulmonary involvement.

#1317 - Abstract

EMERGING ROLE OF VITAMIN D IN AUTOIMMUNE DISEASES: AN UPDATE ON EVIDENCE AND THERAPEUTIC IMPLICATIONS

Giuseppe Murdaca¹, Alessandro Tonacci², Simone Negrini¹, Monica Greco¹, Matteo Borro¹, Francesco Puppo¹, Sebastiano Gangemi³

¹ Clinical Immunology Unit, Department of Internal Medicine, University of Genoa and Ospedale Policlinico San Martino, Genoa, Italy

² Clinical Physiology Institute, National Research Council of Italy (IFC-CNR), Pisa, Italy

³ School and Operative Unit of Allergy and Clinical Immunology, Department of Clinical and Experimental Medicine, University of Messina, Messina, Italy

Background

Vitamin D plays a key role in calcium homeostasis and, thus, provides an important support in bone growth by aiding in the mineralization of the collagen matrix. However, vitamin D performs various immunomodulatory, anti-inflammatory, antioxidant and anti-fibrotic actions. Autoimmune diseases result from an aberrant activation of the immune system, whereby the immune response is directed against harmless self-antigens. Does vitamin D play a role in the pathophysiology of autoimmune diseases? And, if so, what is its role? In the last decade, researchers' interest in vitamin D and its correlations with autoimmune diseases has considerably increased.

Methods

We conducted a literature review, covering the period January 1, 2009 through March 30, 2019, in PubMed. We analyzed more than 130 studies in order to find a correlation between vitamin D levels and its effect upon several autoimmune diseases.

Results

The analysis demonstrated an inverse association between vitamin D and the development of several autoimmune diseases, such as SLE, thyrotoxicosis, type 1 DM, MS, iridocyclitis, Crohn's disease, ulcerative colitis, psoriasis vulgaris, seropositive RA, polymyalgia rheumatica.

Conclusion

International multicenter study could allow us to confirm the data already present in the literature in the single clinical studies and to evaluate when to effectively supplement vitamin D in patients who do not take corticosteroids.

#1323 - Case Report

A MYSTERIOUS CALF

Diogo Drummond Borges¹, Rita Vieira Alves¹, Inês Figueiredo¹, Madalena Vicente¹, Sara Castro¹, Filipa Lourenço¹, Margarida Antunes¹, Ana Lladó¹, Heidi Gruner¹, António Panarra¹, Maria Francisca Moraes-Fontes²

¹ Serviço de Medicina Interna 7.2, Hospital Curry Cabral, Centro Hospitalar Universitário de Lisboa Central, Lisboa, Portugal

² Unidade de Doenças Auto-Imunes, Hospital Curry Cabral, Centro Hospitalar Universitário de Lisboa Central, Lisboa, Portugal

Introduction

Myalgia is a common phenomenon in our daily routine, even more so if you are a sportsman. Nonetheless it may reveal a serious underlying condition, namely rare small-vessel vasculitis. Antineutrophil cytoplasmic antibody (ANCA)-associated vasculitis (AAV) encompasses granulomatosis with polyangiitis, microscopic polyangiitis (MPA) and eosinophilic granulomatosis with polyangiitis.

Case description

We present a 77-years-old man, former surgeon, with known medical history of severe atherosclerotic disease of the carotid arteries. He was very fit and jogged for 20 minutes every day. Three months earlier he presented to another hospital with excruciating bilateral calf pain of sudden onset, present at rest and relentless. Doppler ultrasound of the lower limbs and electromyography and CT imaging were normal. Laboratory tests had revealed a normochromic normocytic anemia, normal white cell differential count, raised C-reactive protein (75,5 mg/L) and ESR (38 mm/h). He had been treated with prednisolone 30 mg per day with relief but became symptomatic upon steroid tapering. He was referred to our unit. He denied fever, weight change, appetite loss, joint pain, skin rash, or urinary symptoms. Recent episodes of epistaxis and the presence of inflammatory markers lit the autoimmune spark. ANCA-MPO antibody with a titre of 1170.9 UQ was detected. He was symptom free after methylprednisolone pulses followed by rituximab (1 g administered twice, 7 days apart), maintenance therapy with mycophenolate mofetil and low dose prednisolone (5 mg/day). Nasal mucosa and calf muscle biopsies failed to reveal abnormalities. At 9-month follow-up ANCA titre was down to 84.2 UQ, with no anemia and a normal PCR. The treatment was well tolerated with no complications. There was no evidence of renal involvement.

Discussion

This report illustrates the importance of a detailed and careful clinical observation. There were no consumptive symptoms. The details of his calf pain were unusual, and atypical for atherosclerotic disease. A necrotizing vasculitis of perimysial blood vessels was first on our list of differential diagnosis even though it has been very rarely reported in AAV. Notwithstanding the nature of his symptoms, the muscle biopsy was normal, a finding which may be explained by the fact that the biopsy was

only performed after induction therapy. AAV is a rare diagnosis which might be uncovered by a simple symptom such as myalgia.

#1329 - Case Report

WINTER IS HERE: SEVERE ANEMIA IN RHEUMATOID ARTHRITIS

Diogo Drummond Borges¹, Ema Leal¹, Rita Vieira¹, Madalena Vicente¹, Sara Castro¹, Ana Ladó¹, Filipa Lourenço¹, Margarida Antunes¹, Heidi Gruner¹, Maria Francisca Moraes-Fontes², António Panarra¹

¹ Serviço de Medicina Interna 7.2, Hospital Curry Cabral, Centro Hospitalar Universitário de Lisboa Central, Lisboa, Portugal

² Unidade de Doenças Auto-Imunes, Hospital Curry Cabral, Centro Hospitalar Universitário de Lisboa Central, Lisboa, Portugal

Introduction

Rheumatoid arthritis may be associated to severe anemia in exceptional circumstances namely macrophage activating syndrome or autoimmune hemolytic anemia (AIHA). The latter includes Cold Agglutinin Disease (CAD) mediated by an auto-antibody targeting red blood cells at a temperature lower than 37 degrees Celsius.

Case description

We present a 78-years-old caucasian man with longstanding hypertension, obstructive uropathy subjected to lithotripsy and chronic renal disease (ClCr 30 mL/min) and a recent diagnosis of late onset deforming rheumatoid arthritis (anti-CCP -; rheumatoid factor + 140 UI/mL) successfully treated over the past year with hydroxychloroquine 400mg and prednisolone 5mg per day. He had been extensively investigated for previous macrocytic anemia (Hb ± 10 g/L) with no evidence of blood loss or inflammation. Physical examination, CT imaging and endoscopic procedures failed to reveal neoplasia. The bone marrow examination and biopsy were normal. Macrocytosis had prompted folate supplementation and a switch from methotrexate and salazopyrine to the current medication. In November 2018, he presented to the emergency department with extreme fatigue and dizziness. Laboratory tests revealed the following abnormalities: Hb 5.7 g/L, MCV 101.2 fL, reticulocyte count 137.60x10⁹/L, LDH 323 U/L, Bilirubin 1.29mg/dL, C-reactive protein 95.9mg/L, ESR 83 mm/h and a high ferritin (440 ng/mL, ULN 350). Urine haemoglobin was negative. Total and differential white cell and platelet counts along with triglycerides (163 mg/dL) were normal. Despite 13 blood transfusions he remained severely anemic; a low haptoglobin (1.14mg/dL) together with a positive direct Coombs test (C3d positive) clinched the diagnosis of autoimmune-mediated hemolysis. A cold agglutinin was then identified overnight. Warming measures were undertaken and the Hb rose to 8 g/L allowing for discharge.

Discussion

The association between rheumatoid arthritis and CAD is rarely described^[1-3]. In retrospect, we believe the cold season aggravated

anemia and, as expected, there was a positive response to cold avoidance. CAD is mediated by an IgM antibody and we speculate that in this patient it may be associated to the rheumatoid factor. CAD is a rare diagnosis that should however be considered in all patients with AIHA.

References

1. Rheumatology. 2008;47(5):734-735;
2. Journal of Clinical Rheumatology. 2009;15(7):p. 375;
3. Case Rep Rheumatol. 2015;2015:823563.

#1333 - Case Report

ACUTE PULMONARY EMBOLISM AS THE INITIAL MANIFESTATION OF ANTIPHOSPHOLIPID SYNDROME - CLINICAL CASE

Hilda Freitas¹, Natalia Oliveira¹, Antonio Cabral¹, Paulo Ferreira², Vanessa Machado², Cristina Ramalho²

¹ TrofaSaude Hospital Braga Sul, Braga, Portugal

² TrofaSaude Hospital Braga Centro, Braga, Portugal

Introduction

Antiphospholipid syndrome (APS) is an autoimmune multisystem disorder characterized by arterial, venous, or small vessel thromboembolic events in the presence of persistent antiphospholipid antibodies. Occurs as a primary condition or in the setting of an underlying systemic autoimmune disease. Patients with APS may develop various lung manifestations including pulmonary thromboembolic disease.

Case description

The authors describe a clinical case of a 49 years old men with a medical history of Psoriasis and Smoker. He was a long distance truck driver. Medication at home: methotrexate. He went to the Emergency Department for lateral thoracalgia after a trip of 20 hours. Laboratory studies: D-dimers 900. Angio CT thorax: "small thrombus at the right upper lobe. Small pleural effusion on the left". During hospitalization, the patient underwent echo-guided thoracentesis: non-infected exudate with > 82% mononucleate. Echocardiogram normal. He presented a favorable evolution. Maintained follow-up in consultation. Autoimmunity study showed persistently positive Lupus Anticoagulant. Pleural fluid with negative cytology for malignant cells; BK search: negative. Bronchoscopy, endoscopy, and colonoscopy with no relevant changes. He is asymptomatic. No pleural effusion. We want that the patient remain anticoagulated, ad eternum.

Discussion

The authors intend to show the importance of even when symptomatology fruste (pain in an upper limb after driving for 20 hours), can hide the great masker of Medicine - thromboembolism. They also show the importance of even when a diagnosis is made, it is necessary to go further, and to know the reason for its existence.

The detection of APS was decisive in the decision of the treatment time, with the serious consequences of being able to have new PE if he had suspended anticoagulation after 6 months. The Internist was, is, and will be, the eternal guardian of the patient.

#1340 - Case Report

TO BE, OR NOT TO BE INFECTIOUS - THE VALVULAR QUESTION

Salvador Morais Sarmiento, Madalena Lobao, Marta Moitinho, Hugo Inácio, Miguel Sousa Leite, Ana Brito, Daniela Marto, Andreia Amaral, Sofia Mateus, Dina Pita, Catarina Salvado, Maria José Goes

Centro Hospitalar e Universitário Lisboa Central, Hospital de Santo António dos Capuchos, Lisbon, Portugal

Introduction

Nonbacterial thrombotic endocarditis (NBTE) is a rare condition, most commonly diagnosed post-mortem, with no sex predilection, affecting patients between the fourth and eighth decades of life. These sterile vegetations are often associated with malignancies, systemic lupus erythematosus (SLE) and antiphospholipid antibody syndrome (APS).

Case description

A 42-year-old caucasian woman was admitted for study, presenting as a case of fever, asthenia, myalgia and sweating since she was bitten on her right leg by her cat two months prior. She tried two courses of antibiotics (flucloxacilin and amoxicillin-clavulanate) with little improvement of her symptoms. Her past medical history was significant for APS (diagnosed by persistently positive antiphospholipid antibodies, lower extremity deep vein thrombosis and recurrent miscarriages) and for SLE (polyarthralgia, leucopenia, antinuclear and anti-dsDNA antibodies), for which she was on long-term warfarin and hydroxychloroquine (HCQ). International normalized ratio (INR) values over the past 6 months were within the therapeutic range. A wide variety of exams was performed during her admittance: blood work, blood and urine cultures, comprehensive testing for various infectious agents, whole-body CT imaging and ultrasound of the lower limbs, with no findings suggestive of a likely cause. The only relevant finding was a non-obstructive pedunculated mass on the right atrium, inserted near the aortic valve, detected by transthoracic echocardiogram (TTE) and confirmed by transesophageal echocardiogram and magnetic resonance, which nature could not be determined. The patient underwent a long course of intravenous antibiotics (gentamicin, doxycilin and ceftriaxone), as well as anticoagulation therapy with low molecular mass heparin in therapeutic dosage. During the follow-up the patient remained asymptomatic and the repeat TTE did not reveal any signs of the previously known valvular mass.

Discussion

The definitive diagnosis of NBTE can only be established by direct

analysis of surgical specimens. However, a presumptive diagnosis may be considered, provided that some key aspects of this condition are present – detection of a valvular vegetation, absence of systemic infection and suggestive risk factors (in this case, SLE and APS). A high index of suspicion is paramount for early diagnosis and directed treatment. In this case, lifelong anticoagulation is indicated; HCQ and corticosteroids may have important roles in the treatment.

#1342 - Abstract

HEMOPHAGOCYTIC SYNDROME: A CASE SERIES OF THREE PATIENTS

Georgios-Charis Paskalis¹, Christina-Chrysanthi Theocharidou¹, Zacharo Sachla¹, Thomas Chatzikonstantinou², Vasiliki Tsoutsouli¹, Konstantinos Gkogkos¹

¹ Internal Medicine Clinic of G.Papanikolaou General Hospital, Thessaloniki, Greece

² Hematology Clinic of G.Papanikolaou General Hospital, Thessaloniki, Greece

Background

Hemophagocytic syndrome is a disease, which is induced by macrophage activation and is expressed as a multisystem inflammation. It can be inherited or secondary to infections, autoimmune diseases or malignancies. Diagnosis is based on a combination of clinical and laboratory criteria, as a single pathognomonic finding does not exist. Most cases are treated with corticosteroids, etoposide and cyclosporine along with treatment of the underlying disease. We aim to present three cases of secondary hemophagocytic syndrome.

Methods

We report three patients, 64, 72 and 67 years old, two men and one woman. All cases met the diagnostic criteria at the time of diagnosis. The underlying diseases were lymphadenopathy (possible Systematic Lupus Erythematosus), seronegative rheumatic arthritis and Staphylococcus aureus infection, respectively.

Results

The first patient was transferred to the Intensive Care Unit one month after admission due to severe respiratory infection and immunodeficiency (severe neutropenia and immunosuppressants), where he died due to septic shock. The second patient improved significantly and was discharged 90 days after admission. Nevertheless, we were informed that she passed away at home two weeks later by unknown cause. The third patient was discharged 110 days after admission. Since then, he has experienced two relapses which were promptly recognized and successfully treated, thanks to high suspicion and training of the patient.

Conclusion

Hemophagocytic syndrome is a life-threatening disease that can be secondary to various underlying situations. These cases

point out the need for high suspicion, prompt diagnosis and often aggressive treatment. We finally emphasize that, provided successful initial management, close long-term follow up after discharge is absolutely essential.

#1365 - Case Report

IDOPATHIC RETROPERITONEAL FIBROSIS (ORMOND'S DISEASE) AS A TRANSIENT RISK FACTOR FOR VENOUS THROMBOEMBOLISM.

Rubén Alonso Beato¹, Francisco Galeano Valle^{1,2}, Pablo Demelo Rodríguez^{1,2}, Jorge Del Toro Cervera^{1,2}

¹ Hospital General Universitario Gregorio Marañón, Madrid, Spain

² Instituto de Investigación Sanitaria Gregorio Marañón, Madrid, Spain

Introduction

Idiopathic retroperitoneal fibrosis (IRF) is a disease of unknown etiology characterized by sclerotic tissue in the retroperitoneum that encases adjacent structures. We present a case of IRF presenting with bilateral deep venous thrombosis (DVT) and pulmonary embolism (PE).

Case description

A 59-year-old male with past history of newly diagnosed arterial hypertension presented to the Emergency Department due to a 10-day history of increased volume of the left lower extremity, abdominal pain and dyspnea. Physical examination revealed heart rate 125 bpm, blood pressure 135/83 mmHg, generalized abdominal tenderness and increased volume of the left lower extremity. Laboratory test showed creatinine 7.66 mg/dl, potassium 7.1 mmol/l, pH 7.31, D-Dimer 42,118 ng/mL, C-reactive protein (CRP) 24.2 mg/dL, erythrocyte sedimentation rate 23 mm and 14,600 leukocytes/mm³. A urinary catheter was placed and creatinine normalized in 48 hours. A doppler-ultrasound showed bilateral DVT in lower extremities, from the common femoral vein to the infrapopliteal veins, and enoxaparin was started. A CT disclosed bilateral PE and an infiltrative retroperitoneal mass compressing both common iliac veins and renal hilums. Serum IgG level was 0,13 g/L. A (PET/CT) excluded malignancy and inflammatory activity. Immunosuppressive treatment was started with prednisone 50 mg/day for one month, followed by tapering dose. A CT scan performed three months later showed resolution of the retroperitoneal fibrosis. At that point blood tests showed 8,900 leukocytes/mm³, CRP 0,4 mg/dL and normal renal function. The patient received anticoagulation with acenocoumarol for 6 months.

Discussion

IRF or Ormond's disease is a rare fibro-inflammatory process in the retroperitoneum. Pathophysiology remains unclear, but IRF and IgG4-related disease (IgG4RD) share a common autoimmune etiology that may suggest a certain spectrum.

Imaging by CT scan and MRI scan are useful for diagnosis and evaluation of the fibrosis degree. PET-CT is useful to rule out malignancy, and to monitor the response to immunosuppressants.

Retroperitoneal biopsy remains controversial but is strongly advised when first-line therapy fails.

Regarding treatment, first-line therapy is a 0.5-1 mg/kg/day prednisolone followed by tapering doses, with no consensus on the duration of treatment. In our case, the retroperitoneal mass and the inflammatory state were considered the provoking factors for DVT and therefore, anticoagulation was withdrawn 6 months after the episode.

#1367 - Case Report

A CASE OF PERNICIOUS ANEMIA

Olga Cristina Pires, Joana Morais, Ana Isabel Andrade Oliveira, Inês Burmester, Paulo Gouveia, Maria João Regadas, António Oliveira Silva

Hospital de Braga, Braga, Portugal

Introduction

Pernicious anemia is a megaloblastic anemia caused by the deficiency of vitamin B12. Is one of the hematologic manifestations of chronic auto-immune gastritis, in which the immune system targets the parietal cells of the stomach or intrinsic factor itself, leading to decreased absorption of vitamin B12. Vitamin B12, which is absorbed in the terminal ileum as a complex with intrinsic factor secreted by parietal cells of the stomach, is a crucial vitamin for DNA synthesis.

Case description

A 64 years old man refers complaints of anorexia, asthenia and weight loss of 8 kg in two months. He denied abdominal pain, change in bowel habits, diarrhoea, constipation, fever or hypersudoresis, dyspnea, orthopnea, nocturnal paroxysmal dyspnoea, palpitations, cutaneous changes, easy bleeding and axillary or inguinal masses. Laboratory tests showed pancytopenia (hyperchromic macrocytic anaemia, leukopenia with neutropenia and lymphopenia and thrombocytopenia), with severe vitamin B12 deficiency. Marked macrocytosis, anisopoikilocytosis with presence of target cells, dacaryocytes, schizocytes and basophilic punctuation with presence of immature granulocytes was showed in peripheral. Colonoscopy did not present alterations. Endoscopy revealed atrophic and erythematous gastropathy, without other alterations. Intrinsic factor antibodies were negative. No other nutritional deficits were observed. Anti-parietal cell antibodies were positive. Viral serologies were requested with negatives results (CMV, EBV, Parvovirus, HBV, HCV, HIV). The serum samples of the patient were assayed for the presence of antinuclear antibodies (ANA), antineutrophil cytoplasmic antibodies (ANCA), anti-mitochondrial antibodies (AMA) and anti-smooth muscle antibodies (ASM) which were negatives. No alterations were observed in the haemoglobin chains analysis. After vitamin B12 therapy, an improvement in the hemoglobin and platelet values was observed.

Discussion

Vitamin B12 deficiency is a common cause of megaloblastic

anemia. This clinical case aims to illustrate the importance of thinking about various differential diagnoses in presence of a magaloblastic anemia, when associated with systemic complaints, not neglecting the pernicious anemia as one possible etiology.

#1377 - Case Report

ACQUIRED HEMOPHILIA A: WHEN A LIFE-THREATENING CERVICAL BLEEDING LEADS TO RE-EVALUATION OF HEMOSTATIC AND IMMUNOSUPPRESSIVE THERAPY.

Dúlio Teixeira Passos¹, Vilma Salgado¹, Ana Cardoso¹, Nuno Jacinto¹, Eunice Parcelas², Artur Pereira³, Fátima Rodrigues³, Paula Rocha^{1,4}, João Meneses Santos^{1,4}, Cristina Catarino³, Rui M. M. Victorino^{1,4}

¹ Department of Internal Medicine II, North Lisbon University Hospital Center - Santa Maria Hospital, Lisbon, Portugal

² Department of Immunohemotherapy, West Lisbon Hospital Center - São Francisco Xavier Hospital, Lisbon, Portugal

³ Department of Immunohemotherapy, North Lisbon University Hospital Center - Santa Maria Hospital, Lisbon, Portugal

⁴ Medicine II University Clinic, Faculty of Medicine - University of Lisbon, Lisbon, Portugal

Introduction

Acquired hemophilia A (AHA) is a rare and potentially severe bleeding disorder caused by circulating autoantibodies directed against factor (F) VIII. It is more common in elderly and associated with cancers, autoimmunity, medications, infections, pregnancy and the post-partum period, although, idiopathic cases still represent more than half of the cases.

Case description

A 79-year-old woman with hypertension, dyslipidemia and hyperuricemia was admitted due to spontaneous hematoma of the thigh. There was no history of trauma, anticoagulant or antiaggregant therapy and no personal or family history of bleeding. She had a severe anemia (hemoglobin 6.7 g/dL), with an isolate prolonged activated partial thromboplastin time (>100/29 sec). Computer tomography scan of the limbs was performed and confirmed an extensive hematoma of the thigh with extension to the ankle. The FVIII titration was performed and revealed low FVIII activity (< 1%) with high-titer of inhibitors of FVIII (471 Bethesda units/mL) that confirmed the diagnosis of AHA. The patient was transfused with packed red blood cells and initiated bypassing agents with recombinant activated factor VII (rFVIIa). Immunosuppressive therapy was initiated with prednisolone 1 mg/kg. She kept developing multiple scattered hematomas and on the 5th day developed a left cervical hematoma with airway compression, requiring orotracheal intubation under sedation and bronchofibroscopy control. She was admitted to the intensive care unit and started hemostatic control with activated prothrombin complex concentrate (APCC; FEIBA®) and immunosuppression with cyclophosphamide (CTX) 100 mg/day and rituximab (RTX)

600 mg/week. Clinical remission and a negative titer of inhibitors of FVIII were achieved in the five weeks. Immunosuppression with CTX and RTX was maintained for 6 and 4 weeks, respectively, and afterwards prednisolone for additional 12 weeks. The etiological study excluded active infection as well as autoimmune or neoplastic disorders and thus idiopathic AHA was diagnosed.

Discussion

AHA is an under-recognized but reversible acquired coagulopathy which requires a high index of suspicion for early diagnosis and prompt recognition with appropriate management. Both hemostatic and immune therapy impose considerable risks and require close monitoring to control risk of recurrence estimated between 8-30%.

#1382 - Case Report

EORA VS RS3PE SYNDROME

Daniela Meireles, Flávio Pereira, Joel Pinto, Paulo Almeida, Joana Neves

CHBV - Aveiro, Aveiro, Portugal

Introduction

Elderly onset rheumatoid arthritis (EORA) and RS3PE syndrome (Remitting Seronegative Symmetrical Synovitis with Pitting Edema) are rheumatological entities with similar clinical presentations in patients older than 65 years with an important systemic component: constitutional symptoms, high sedimentation rate and periarticular edema.

Case description

An 84-year-old male went to the Emergency Department due to exuberant edema of the hands and feet with 2 months of evolution and bilateral inflammatory gonalgia. He presented asthenia, anorexia, weight loss (10 kg in 2 months) and fever. Also, palpable pericentromeric axillary and inguinal lymph nodes, mobile and painless. The blood analysis showed hypochromic normocytic anemia, sedimentation rate of 110 mm/h with reactive C protein of 16 mg/dL. Anticitrulin antibodies, HLA-B27, rheumatoid factor, complement, anti-nuclear antibodies and anti-neutrophil cytoplasmic antibodies were negative. He presented interferon gamma release assays (IGRA) positive but without evidence of active infection. Radiographs of the affected joints did not show periarticular erosive lesions. Previously as an outpatient he had already performed endoscopy, colonoscopy, echocardiogram, prostate and thyroid ultrasound that were normal. The thoracoabdominal computed tomography showed axillary, periaortic and right pulmonary hilum adenopathies. Axillary lymph nodes were excised and showed reactive lymphadenitis, with negative tuberculosis research. Neoplastic and active infectious disease were excluded and was decided to initiate prednisolone 20 mg/day, concomitantly with treatment of latent tuberculosis. As we didn't obtain complete resolution of symptoms, the hypothesis of syndrome RS3PE became less probable, and was assumed to

be seronegative EORA. After 6 months of follow-up, the patient maintains rigidity with weight recovery, without asthenia, fever or anemia and VS of 44 mm/h. Maintained follow up in consultation of Internal Medicine and Rheumatology while steroids tapering and methotrexate (10mg/week).

Discussion

The initial diagnostic hypothesis of RS3PE required a broad study, since it is associated to multiple neoplastic and infectious pathologies, which were excluded. Given that idiopathic RS3PE could not be assumed, because it did not resolve the condition with corticoid therapy, the diagnosis of seronegative EORA was assumed, due to compliance with the criteria. EORA is a serious disease with high morbidity and mortality and should be diagnosed and treated early.

#1416 - Case Report

A HOSTILE TAKEOVER

Diogo Drummond Borges¹, Rita Alves¹, Madalena Vicente¹, Sara Castro¹, Filipa Lourenço¹, Margarida Antunes¹, Ana Lladó¹, Miguel Verdelho², Mario Góis², Heidi Gruner¹, Maria Francisca Moraes-Fontes³, António Panarra¹

¹ Serviço de Medicina Interna 7.2, Hospital Curry Cabral, Centro Hospitalar Universitário de Lisboa Central, Lisboa, Portugal

² Serviço de Nefrologia, Hospital Curry Cabral, Centro Hospitalar Universitário de Lisboa Central, Lisboa, Portugal

³ Unidade de Doenças Auto-Imunes, Hospital Curry Cabral, Centro Hospitalar Universitário de Lisboa Central, Lisboa, Portugal

Introduction

Occam's razor principle states that "simpler solutions are more likely to be correct than complex ones". In this case we were bestowed with a clinical picture that did not fit a single diagnosis. Goodpasture syndrome (GPS), also known as anti-glomerular basement membrane disease, a small vessel vasculitis, belongs to the autoimmune universe we are still discovering.

Case description

We present a 72-years-old caucasian woman, with known medical history of type 2 diabetes, hypertension, dyslipidaemia, nasal polyps and a longstanding sicca syndrome. An isolated episode of hemoptysis and epistaxis led to investigation a few months earlier, with angio-CT revealing left pleural effusion and peribronchovascular thickening, which was assumed as a consequence of respiratory infection. For the past year, she referred migratory arthralgia, myalgias, weight loss and lower limbs edema. Her recent laboratory findings revealed deteriorating renal function with deteriorating creatinine clearance (CrCl 48 - 23 mL/min). CT imaging and endoscopic studies failed to demonstrate neoplasia. She was referred to our unit. Initially, laboratory findings, hypergammaglobulinemia (IgG 1733mg/dl) and ANA 1/640, alongside with xerostomia and xerophthalmia were compatible with Sjogren's Syndrome. Immunological

evaluation revealed antimyeloperoxidase antineutrophilic cytoplasmic antibody (MPO-ANCA) positivity (4194.1 UQ), as well as anti-glomerular basement membrane (anti-GBM) antibody (436.5 UQ). Small vessel vasculitis was subsequently confirmed with renal biopsy showing destruction of small vessel walls and interstitial inflammation and bleeding as well as extensive acute tubular necrosis. The linear deposition of IgG lambda and kappa chains in capillary walls clinched the diagnosis of GPS. Dialysis was induced and the patient received plasmapheresis, corticoids and cyclophosphamide. Antibodies count lowered and symptoms regressed. Nevertheless, there was no recovery of renal function and the patient remained on dialysis.

Discussion

While Sjogren's syndrome is not infrequent, encountering an overlap with ANCA MPO and GBM vasculitis may be considered a remarkable finding with only a few cases ever being reported. In the same fashion, the severity of renal involvement led us to believe that Sjogren was only an accomplice and the culprit was still at large. Anti-GBM vasculitis proved to be a hostile takeover and a diagnostic delay may have contributed to the suboptimal outcome.

#1423 - Abstract

CLINICAL SIGNIFICANCE OF ANTI-NUCLEOSOME ANTIBODIES IN PATIENTS WITH SYSTEMIC LUPUS ERYTHEMATOSUS

Isabel Serrano García, Alba Pérez Linaza, Susana Fabiola Pascual Pérez, Nuria Avilés Méndez, Fermin Medina Varo
Puerta del Mar Hospital, Cádiz, Spain

Background

Nucleosomes are the fundamental subunit of chromatin. Anti-nucleosome antibodies have been detected in 48-80% of patients with systemic lupus erythematosus (SLE).

Previous studies have shown that the specificity of these antibodies is similar to the specificity of Ab anti-dsDNA, and their presence is related to lupus nephritis. However, the diagnostic value of these antibodies is not fully established

Methods

89 patients were selected retrospectively from Hospital Puerta del Mar, Cádiz, with anti-nuclear antibodies with a homogeneous staining pattern titre \geq 1:640, from November 2017 to December 2018.

The presence of Ab anti-nucleosome and/or anti-dsDNA was determined, and 4 groups were established: 1) Ab anti-nucleosome+, anti-dsDNA-, 2) Ab anti-nucleosome +, anti-dsDNA+, 3) Ab anti-nucleosome-, anti-dsDNA+, 4) Ab anti-nucleosome-, anti-dsDNA-. In addition, those patients diagnosed with SLE (n= 53), the association of anti-nucleosome antibodies with clinical parameters was evaluated.

Results

Of the total of patients (n=89) 44 had Ab anti-nucleosome . Of these, 23 had only Ab anti-nucleosome (group 1), while 21 also had AB anti-dsDNA (group2). 16/89 patients only had Ab anti-dDNA (group 3).

For the diagnosis of SLE:

Ab anti-nucleosome: Se=66%, Sp=75%, PPV=79,5% and NPV=60%

Ab anti-dsDNA: Se=64,2%, Sp=91,7%, PPV=91,9% and NPV=63,5%.

According to clinical manifestations, 35/44 patients with Ab anti-nucleosome were diagnosed with SLE, while 9 patients had other diagnoses.

Proteinuria was present in: 23/35 patients with anti-nucleosome+ compared to 5/15 patients with anti-nucleosome - ($p<0.5$)

Proteinuria was also present in 12/16 patients from group 1, 7/19 patients from group 2 and 6/15 patients from group 3.

Hematologic affectation was present in: 26/35 patients with anti-nucleosome+ compared to 6/15 patients with anti-nucleosome

The patients with only positive Ab anti-nucleosome had SLICC values greater than patients with only Ab anti-dsDNA ($p<0.05$). In addition the patients from group 1 had greater SLICC values than patients from group 3 ($p<0.05$).

Conclusion

These antibodies have less specificity and PPV than Ab anti-dsDNA. 69% of patients diagnosed with SLE were both AB anti-nucleosome+ and anti-dsDNA-, so the presence of only Ab anti-nucleosomes must be considered in patients with suspected SLE.

The presence of Ab anti-nucleosome had a positive relation according to greater SLICC. For this reason, Ab anti-nucleosome could have prognostic value for patients with SLE

#1426 - Case Report

SEVERE ANEMIA AS THE FIRST MANIFESTATION OF GIANT CELL ARTERITIS

Ana Oliveira Monteiro, Inês Branco Ferreira, Ismael Carneiro, Margarida Freitas Silva

Centro Hospitalar e Universitário de São João, Oporto, Portugal

Introduction

Giant cell arteritis (GCA) is a chronic granulomatous vasculitis of medium and large arteries. It mainly involves the extracranial branches of arteries originating from the aortic arch. It is a rare, underdiagnosed and occurs primarily in the elderly. The classic clinical features include fever, asthenia, weight loss, headache, claudication of the jaw, rheumatic polyarthralgia and visual changes. The presence of anemia is common at diagnosis, however severe anemia as a form of presentation is rare.

Case description

A 83-year-old man was admitted at the hospital due to fever (maximum of 38.5°C), asthenia and unquantified weight

loss, lasting more than 1 week. Laboratory tests revealed normochromic normocytic (N/N) anemia (Hemoglobin (Hb) 6.6 g/dL, mean corpuscular volume 94.9 fL, mean corpuscular hemoglobin 28.4pg), without iron deficiency or criteria of intravascular hemolysis. Leukocyte formula, platelets, and coagulation study were normal. Sed rate (SR) of 140 mm/1h, low reticulocyte index and elevated ferritin (871.9 ng / mL) were observed, suggesting inflammation. The study of fever excluded infectious, immunological or neoplastic causes, including the endoscopic study of the digestive tract and thoracic-abdominal-pelvic Tc. There wasn't evidence of blood loss and permanently low Hb values, with an inadequate post-transfusion rise. As a complication on the 6th day of hospitalization, the patient presented amaurosis and temporal and parietal left cephalgia, with no pain at temporal palpation. On suspicion of giant cell arteritis, he initiated pulses of methylprednisolone 1 g/day. The evaluation by fundoscopy confirmed the diagnosis of Anterior Ischemic Optic Neuropathy. A temporal biopsy was performed, which confirmed the diagnosis of GCA. After the beginning of steroid therapy, there was a clinical improvement, with a slight recovery of vision and a sustained rise in Hb (9.0 g/dL).

Discussion

GCA is an underdiagnosed disease, even in patients with typical signs and symptoms. Severe anemia, as in the case reported, as a form of presentation is rare and this diagnosis should be considered in elderly patients if excluded other causes of N/N anemia in the presence of elevated SR.

#1429 - Case Report

STROKE IN HEPARIN-INDUCED THROMBOCYTOPENIA – A CASE REPORT

Teresa Martins Mendes, Sofia Garcês Soares, Ana Filipa Leal, Diana Pereira Anjos, André Paupério, Mari Mesquita
Centro Hospitalar Tâmega e Sousa, Penafiel, Portugal

Introduction

Heparin-induced thrombocytopenia (HIT) is an immune complication of heparin therapy caused by IgG antibodies to complexes of platelet factor 4 (PF4) and heparin which bind to activated platelets resulting in a prothrombotic condition associated to both venous and arterial thrombosis. HIT is characterized by a fall in the platelet count 5 to 10 days after starting heparin but it can sooner when the patient received this drug in the previous 3 months. Prophylactic doses and unfractionated heparin are thought to be a greater risk for HIT rather than therapeutic concentrations and low molecular weight heparin (LMWH), respectively. 4Ts scoring system gives a pre-test probability using four features: degree of thrombocytopenia, timing of the onset, presence of new or progressive thrombosis and whether an alternative cause of thrombocytopenia is likely. Once the diagnosis is suspected, immediate discontinuation of heparin is needed and an alternate anticoagulant must be started.

Case description

A 69-year-old woman was submitted to total knee replacement and had prophylactic doses of LMWH for 12 days. The day after discharge from the Orthopedic Department, she presented in the Emergency Room with aphasia and right hemiparesis. Cerebral tomography scan showed recent ischemic infarctions in the left frontal, parietal and temporal lobes. She had a platelet count 28,000 without other analytical abnormalities. She was admitted in a Stroke Unit for further study, which revealed positive anti-PF4 autoantibodies, negative platelet antibodies and a carotid blood clot at the duplex sonography. Human Immunodeficiency Virus, Hepatitis B and C virus were negative; folic acid and B12 vitamin were within normal range. Transthoracic and transesophageal echocardiographies were normal. 24-hour Holter monitoring showed sinus rhythm. A diagnosis of stroke in HIT was made so LMWH was discontinued and she started fondaparinux with clinical and analytical improvement. Two weeks after discharge, she had 148,000 platelets and a normal duplex sonography. Three months later, she started a vitamin K antagonist without complications.

Discussion

The present case highlights a rare condition associated to a drug widely used in hospital settings. It is advised that patients who start any heparin have a known baseline platelet count. Clinicians must be alert to this condition and suspend heparin as soon as the diagnosis is suspected.

#1446 - Case Report

AN ATYPICAL CASE OF GUILLAIN-BARRÉ SYNDROME - PHARYNGEAL-CERVICAL-BRACHIAL VARIANT

Gabriela Pereira, Ana Cardoso, Margarida Rocha, Ussumane Embaló, Jorge Cotter
Hospital Senhora da Oliveira, Guimarães, Portugal

Introduction

Guillain-Barré syndrome is a rare autoimmune disease of the peripheral nervous system, rapidly progressive and usually manifests as muscle weakness that begins in the lower extremities, and eventually the entire body can become paralyzed.

Case description

We present a case of a young man, 19 years old, with asthma, with no other pathological history.

He came to the Emergency Department due to dysarthria, dysphagia to solids and force deficit in the left upper limb with about 24h of evolution, without alterations of sensitivity. He reported acute gastroenteritis about 1 week ago.

The computerized angiotomography of supra-aortic vessels and brain cranium showed no alterations. A lumbar puncture was performed and the results of the meningoencephalitis panel were negative.

He was admitted for surveillance and study.

On the second day, he was admitted to the Intensive Unit Care because of the progressive clinical aggravation with development of flaccid tetraparesis with predominance in the upper limbs, dysarthria, severe dysphagia for solids and liquids, and restrictive pulmonary syndrome requiring continuous aspiration of secretions and a nasogastric tube for feeding.

He performed magnetic resonance imaging of the head and the spine that had no changes. Electromyography was compatible with severe neurogenic alterations, more pronounced at the level of the upper and distal limbs, with low amplitude of motor waves. Immunoglobulin was started at the second day because of high suspicion of Guillain-Barré Syndrome. All cultural examinations were negative, except, *Campylobacter jejuni* PCR was positive in the feces. Serotypes of atypical agents and autoimmunity were negative. Also anti-glycoside antibodies were negative.

The clinical situation stabilized and began to improve after the 3rd day of treatment. Percutaneous endoscopic gastrostomy was required due to severe dysphagia.

He was discharged after 26 days and admitted to a rehabilitation center for physical and motor rehabilitation, as well as speech therapy.

After 1 year of follow-up and rehabilitation, the patient recovered muscle strength of the four limbs and has no speech changes, however, still maintains some dysphagia for solids and liquids.

Discussion

The present case illustrates a variant of Guillain-Barré with an atypical presentation in adulthood, however, there are a few cases reported with this presentation in children.

#1455 - Case Report

INTERSTITIAL PNEUMONIA WITH AUTOIMMUNE FEATURES

Susana Pardo Sanchez, Andres Enriquez Gomez, Pablo Demelo Rodriguez, Jorge Del Toro Cervera, Francisco Galeano Valle, Isabel Jimenez Hinarejos, Blanca Pinilla Llorente, Maria Toledano Macias

HGU Gregorio Marañón, Madrid, Spain

Introduction

“Interstitial pneumonia with autoimmune features” (IPAF) is a research classification proposed as an initial step to uniformly define, identify and study patients with interstitial lung disease (ILD) that have features of autoimmunity, yet fall short of a characterizable connective tissue disease. We present a case of a 62-year-old male diagnosed with Interstitial Pneumonia with Autoimmune Features.

Case description

A 62-year-old male with dyspnea presented to the emergency department due to a 1-year history of progressive dyspnea on

minimal effort and low fever. He admitted having arthralgias with less than 60-minute morning stiffness in interphalangeal joints and shoulders, and retrosternal pleuritic chest pain. He denied having arthritis, myalgias, Raynaud, esophageal reflux or cutaneous symptoms. Physical examination revealed temperature 36°C, blood pressure 110/50 mm Hg, heart rate 70 bpm, bilateral dry crackles and skin paleness. A chest x-ray, echocardiogram and a spirometry were normal. Laboratory tests showed normocytic and normochromic anemia and elevated acute phase reactants (C-reactive protein 14.9 mg/dL, erythrocyte sedimentation rate 105 mm). Autoimmunity showed: c-ANCA (antineutrophil cytoplasmic antibody) 1/20, ANA (antinuclear antibody) 1/320 with nucleolar pattern and anti-dsDNA 43 UI/mL. A chest CT showed interstitial pneumonia with non-specific interstitial pneumonia (NSIP) pattern, bronchiectasis and mild pericardial effusion and thickening. The patient was diagnosed with IPAF and was treated with corticosteroids, with follow-up in outpatient clinic.

Discussion

The term "IPAF" was chosen to highlight the distinct nature of this subset of ILD. Several requirements must be fulfilled for the classification of IPAF: evidence of interstitial pneumonia by imaging and/or by lung biopsy; known causes for interstitial pneumonia must have been excluded; and patients do not meet criteria for a characterizable connective tissue disease. The classification criteria are then organized around three domains: a clinical domain; a serologic domain and a morphologic domain. To be classified as IPAF, the patient must meet all of the requirements and have at least one feature from at least two of the three domains.

Overall, the long-term prognosis of patients with IPAF is less severe than that of idiopathic pulmonary fibrosis, but the patient should be followed for sufficiently long for possible systemic manifestations to become apparent.

#1458 - Medical Image

BITTERSWEET

Francisca Beires¹, Ana Isabel Lopes¹, Raquel Basto², Sofia Moreira-Silva¹

¹ Hospital Pedro Hispano, Matosinhos, Portugal

² IPO de Coimbra, Coimbra, Portugal

Clinical summary

A 44-old woman, without family history of neoplasm nor autoimmune disease presented with gonalgia with irradiation to both legs within 4 days and appearance of non pruriginous lesions on the 4 extremities. No fever, constitutional symptoms, autoimmune symptoms and no contact with animals, history of recent travel, insect bites or outdoor activities were reported.

Maculopapular flat erythematous lesions were visible on both arms and of both thighs and both knees had inflammatory signs. Cutaneous biopsy of the lesions was suggestive of Sweet

Syndrome (SS) and no secondary disease was uncovered.

SS is a neutrophilic dermatosis, which inflicts predominantly women. It is associated with inflammatory, infectious diseases or neoplasm, being an important clue that shouldn't be ignored.

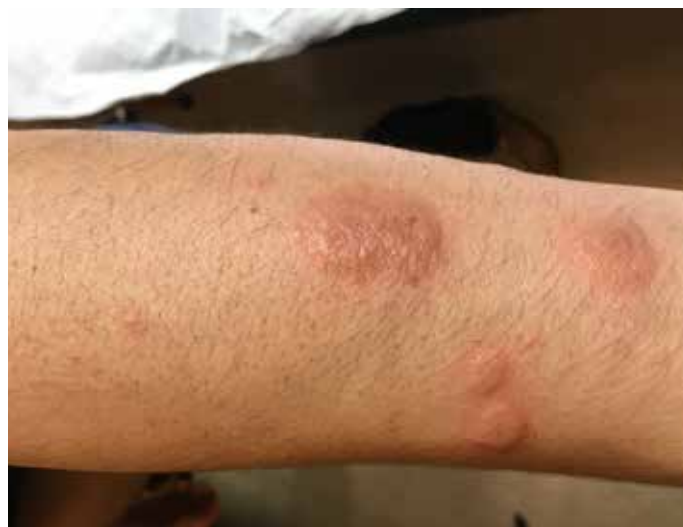

Figure #1458. Erythematous papules.

#1481 - Case Report

OSTEONECROSIS OF FEMORAL HEAD ASSOCIATED WITH GLUCOCORTICOID THERAPY IN VOGT-KOYANAGI-HARADA SYNDROME

Amanda Saavedra Calé¹, Renata Fachada¹, Rafaela Mamfrim¹, Adriana Castro¹, Milena Rangel¹, Álli Gomberg¹, Larissa Rodrigues¹, Thales Rizzi²

¹ Hospital Municipal Miguel Couto, Rio De Janeiro, Brazil

² Hospital Municipal Miguel Couto, Rio De Janeiro, Brazil

Introduction

Vogt-Koyanagi-Harada syndrome (VKHS) is a multisystem autoimmune disorder which affects tissues containing melanocytes and represents an important cause of noninfectious uveitis that may evolve with rapid loss of vision.

Corticosteroid during the acute phase has a good therapeutic response, but in long-term or short-term exposure to high doses may develop serious side effects, as osteonecrosis of femoral head (ONFH)

Case description

A 19 years old woman was admitted with progressive visual loss, frontal headache and orbicular pain. Eye exam reveal an impairment vision, optic disc hyperemia and intraocular pressure of 10 mmHg. Cranial Computed Tomography was normal and ultrasound showed a serous retinal detachment.

Therapy with high-dose of intravenous methylprednisolone 1g/day was established for 5 days and she evolved with a reduction of anterior chamber inflammation, improving her vision.

After a month, she developed the same symptoms and was submitted to a new cycle of pulse therapy, with no recovery of her clinical state. In order of her recurrence, the Rheumatology Service initiated an intravenous cyclophosphamide pulse therapy associated with high dose of glucocorticoid.

Despite the clinical improvement, she developed side effects as weight gain, acne, hirsutism and after 5 months, developed a hip pain and limitation of hip range movement.

Magnetic resonance imaging evidenced bilateral femoral head osteonecrosis. Once the nonsurgical management was not successful, core decompression was well performed with resolution of symptoms.

Discussion

Systemic corticosteroid improves visual prognosis and reduce recurrence of uveitis in VKHS. However, its side effects may develop serious sequel as ONFH and efforts should be made to an early diagnosis and treatment to preserve the hip joint.

Nonsurgical management includes restricted weight-bearing, pharmacological agents and biophysical measures to provide pain relief and prevent progression to subchondral fracture and collapse. Some cases demands a surgical procedure as core decompression that decreases the intraosseous pressure in the femoral head, increasing blood flow to the necrotic area stimulating neobone formation.

Despite the risks, treatment with corticosteroids is recommended and physicians should recognize the side effects to guarantee an early approach to minimize the damage and sequels.

#1506 - Case Report

BEHIND A PLEURAL EFFUSION

Joana Raquel Monteiro, Sónia Santos, Ana Ponciano, Vera Frazão Vieira, Fernanda Pinhal, José Leite, Célio Fernandes
Centro Hospitalar de Leiria, Leiria, Portugal

Introduction

Systemic erythematosus lupus is an immunomediated chronic disease with a variable evolution and highly prevalent among women.

Case description

A 49-year-old male presented at emergency department with bilateral thoracic pain with pleuritic characteristics, dorsal irradiation, dizziness, asthenia, anorexia with a month of evolution, besides lost of 10Kg in two weeks, night sweats and an isolated feverish peak.

On physical examination he presented with tachycardia, decreased vesicular murmur on both lungs and basal crepitations. Blood gas analysis - PaO₂ 60 mmHg. Blood tests - leukopenia 3300/uL with lymphopenia 500/uL; microcytic anemia Hb 10.9 g/dL; peripheral blood smear with discrete hypochromia and microcytosis; C-reactive protein 53.4 mg/L; sedimentation rate 93 mm; D-dimers 10209 ng/mL.

Computed tomography angiography - without thromboembolism, bilateral pleural effusion with bigger extension at right side with condensation and passive collapse of the adjacent lung. Polished glass pattern on the middle lobe probably of inflammatory cause. After empiric antibiotherapy with piperacillin/tazobactam, he presented mild improvement.

A month after, he was again admitted to the emergency department with the same complaints associated to malar rash, polyarthralgia with nocturnal predominance and morning stiffness.

The further study showed: iron deficiency 6.9 umol/L, ferritin 585.5 ng/mL; negative troponin and normal electrocardiogram; normal B12 vitamin, folic acid, plasma protein electrophoresis, serum immunofixation, C3, C4, thyroid function; negative blood cultures; bronchoalveolar lavage and tracheobronchial aspirate without microbiological isolation; anti-nuclear antibodies >1/1280 homogeneous with positive mitosis; negative Anti-dsDNA, lupus anticoagulant, antiphospholipid antibody; positive anti-histones and anti-nucleosomes; rheumatoid factor 16 UI/mL; negative Mantoux test; normal echocardiogram; normal colonoscopy and upper digestive endoscopy; abdominal and pelvic computed tomography without alterations.

It was concluded that he had classification criteria of systemic erythematosus lupus, he was medicated with hydroxychloroquine and naproxen and kept follow-up in auto-immune diseases department.

Discussion

This case shows the importance of differential diagnosis, clinical suspicion and the need of persistent investigation.

#1529 - Case Report

CLASSIC LÖFGREN'S SYNDROME

Rita J. Rodrigues, Raquel Viana, Paula Gonçalves Costa, Marta Costa Gonçalves, Alcina Ponte
Hospital of Santo André - Hospital Center of Leiria, Leiria, Portugal

Introduction

Löfgren's syndrome is a distinct phenotype of sarcoidosis that is present in less than 5-10% of the patients. It has an acute presentation that is characterized by the classic triad of erythema nodosum, hilar adenopathies and migratory polyarthralgia. Fever may also be present, giving the diagnosis a specificity of 95% when all four symptoms are present.

Case description

An healthy 38-year-old man presented to the Emergency Department complaining about polyarthralgia for the last 6 days, with involvement of both tibiotarsal joints and several right hand joints (wrist, metacarpophalangeal and proximal interphalangeal joints). He also mentioned fever on the previous 2 days. He had no complaints concerning other organs or systems and no relevant epidemiological context. On the physical examination, the patient was feverish and had inflammatory signs in his ankles and right

hand. Laboratory exams revealed leukocytosis and increased C-reactive protein. Chest ray showed hilar engorgement and no parenchymal alterations. He was then referred to Internal Medicine consultation, under non-steroidal anti-inflammatory drugs. On the first clinical exam, the patient had marked bilateral oedema and erythema nodosum in both lower limbs and also arthritis' signs in both wrists, tibiotarsal joints and right elbow. He was submitted to an additional analytical study that excluded other pathologies. Thoracic computed tomography revealed some small unspecific pleural thickening, ganglionic formations at the pre-tracheal level (the largest with 22 mm diameter) and also left and right hilar adenopathies. The diagnosis of Löfgren's syndrome was considered and the patient was seen frequently at office visits for monitoring. A week later he had gait limitation due to articular involvement of the knees, so he started supportive treatment with corticosteroid therapy with progressive clinical and radiological improvement over 3 months even with treatment taper. After 2 years from the onset of the disease, there is no recurrence of the symptoms.

Discussion

Löfler's syndrome is one of the few clinical presentations of sarcoidosis that allow a clinical diagnosis, dispensing confirmatory biopsy, although the exclusion of other relevant pathologies is needed. The treatment is supportive and the prognosis is excellent with spontaneous remission occurring in 6-8 weeks up to 2 years.

#1532 - Medical Image

EXUBERANT BULLOUS PEMPHIGOID

Isabel De La Cal Caballero, Ana Patricia Gomes, Pedro Lito, Ricardo Gomes, José Proença, Leopoldina Vicente
Centro Hospitalar Universitário Cova da Beira, Covilhã, Portugal

Clinical summary

Bullous pemphigoid is an inflammatory, subepidermal, blistering disease. It is characterized by the presence of inflammatory, blistering, and sometimes erosive mucocutaneous lesions. Autoantibodies are produced for specific antigens of the epidermal basement membrane zone.

A 53 year-old female patient, presenting with itching associated with blisters and urticarial lesions, which had been present for three weeks. The blisters with serous content were located on erythematous or apparently healthy skin, there were also lichenified plaques mostly on limbs.

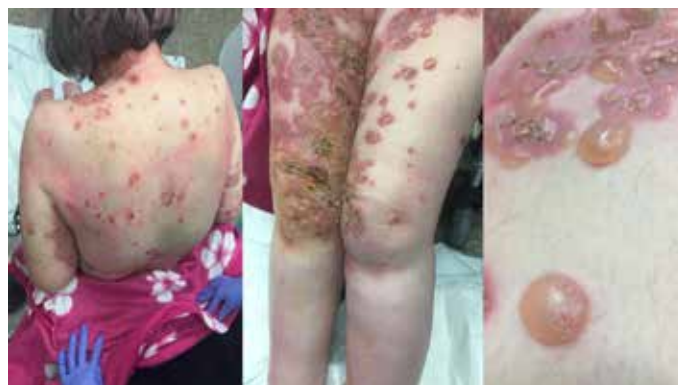

Figure #1532.

#1552 - Case Report

WARM AUTOIMMUNE HEMOLYTIC ANEMIA AS PRIMARY CLINICAL MANIFESTATION OF SYSTEMIC LUPUS ERYTHEMATOSUS

Thales Oliveira Rizzi¹, Aniello Montouri¹, Carmello Conti², Amanda Saavedra¹, Rafaela Mamfrim¹, Bianca Feldman¹, Thaisy Secco¹, Luiza Flores¹, Victor Bemfica¹

¹ Hospital Municipal Miguel Couto, Rio De Janeiro, Brazil

² Universidade Estácio de Sá, Rio De Janeiro, Brazil

Introduction

Systemic lupus erythematosus (SLE) is an autoimmune disease with variable multisystem involvement and heterogeneous clinical features, including hematological disorders.

The autoimmune hemolytic anemia (AIHA) may be the primary clinical manifestation of SLE, characterized by destruction of red blood cells due to binding by immunoglobulin and/or complement with the erythrocyte surface membrane.

Case description

A 34 year old woman, admitted with a 12-month history of polyarticular arthralgia of multiple joints (without inflammatory features), fatigue and vertigo. The patient was pale, jaundice, hypotensive, tachycardic and with hepatosplenomegaly.

Screening tests showed hemoglobin 4.6 g/dL, with macrocytic red cells (110.6 fL), a increased red cell distribution width (28.2%), normal white blood cell and platelets. The patient received 3 units of red blood cell transfusion and supportive treatment.

Anemia investigation showed evidences of hemolysis: reticulocytosis, low serum haptoglobin levels, increased unconjugated bilirubin and lactate dehydrogenase levels, positive direct Coombs test (warm type antibodies). Associated with peripheral blood analysis with polychromasia and reticulocytes and aspiration of bone marrow with hypercellularity and erythroid hyperplasia with a myeloid/erythroid ratio of 1:1.

SLE was confirmed with exams that reveal a elevated titer of serum anti-dsDNA antibody (1/160), antinuclear antibody (1/640), proteinuria and retinal involvement.

Treatment with Dexamethasone (0.5 mg/kg/day) was started, without success, and later associated with immunoglobulin (1 g/

kg) for 5 days. The patient evolved with clinical improvement and continued outpatient treatment with rheumatologist.

Discussion

AIHA should be considered as one component of a multisystemic disease secondary to immune system dysfunction; in 5 - 43% of cases a underlying systemic disease can be identified as responsible for the hemolytic condition, as SLE.

Corticosteroid is the first-line treatment, in case of a failure, immunosuppressive drugs, splenectomy, Rituximab (monoclonal antibody), Danazol, immunoglobulin and hematopoietic stem cell transplantation can be done.

Therefore, AHAI is a rare and potentially serious disease so the diagnosis should alert to the possibility of a associated systemic disease. The prognosis is worse in presence of a baseline disease. It shows the importance of a clinical and laboratory tracing to identify pathologies, like infectious, autoimmune disease and neoplasias.

#1567 - Case Report

CUTANEOUS PANNICULITIS: WHAT IF IT WAS LUPUS?

Kefi Asma, Kammoun Sonia, Fatima Jaziri, Elleuch Mounia, Marwa Fliss, Khaoula Ben Abdelghani, Sami Turki, Taieb Ben Abdallah Charles Nicole Hospital, Tunis, Tunisia

Introduction

Lupus panniculitis or deep lupus erythematosus affects 1% of patients with systemic lupus erythematosus (SLE). It can occur during the course of the disease or precede other manifestations. We report a new observation of lupus panniculitis in our department.

Case description

Patient HK, 21 years old, followed 3 years ago for a SLE. The diagnosis was based on photosensitivity, oral ulceration, polyarthritis, proliferative and diffuse glomerular nephropathy, autoimmune haemolytic anemia, and anti-nuclear positive antibodies with positive anti-DNA and anti-nucleosome antibodies. She was admitted for exploration of a painful swelling of the right calf. The examination noted an indurated, infiltrated, hyperpigmented plaque, including some atrophic zones with an inflammatory and sensitive periphery. She had no clinical or biological signs of lupus flare. The infectious investigation was negative. Doppler ultrasound did not indicate superficial or deep vein thrombosis. The biopsy showed lobular panniculitis associated with a lymphocytic infiltrate. Immunohistochemistry showed a vascular deposition of IgM and C3. The patient had evolved well under synthetic antimalarials.

Discussion

The lupus panniculitis is characterized by an appearance of indurated plaques with atrophic evolution, pigmented, located

mainly in the upper part of the body: back, facial, cervical and deltoid region. The case of our patient is atypical by the location of the panniculitis (lower limb). Other etiologies causing panniculitis in a lupus patient include traumas, infections, neoplasia, or an associated syndrome of anti-phospholipid antibodies. Diagnosis confirmation is given by histology. Treatment is based on photoprotection and synthetic antimalarials.

Lupus panniculitis is a rare disease, which poses the double problem of integration within the panniculites in general and within lupus disease.

#1569 - Case Report

NECROTIZING AUTOIMMUNE MYOPATHY

Carla María Martín-Abreu, Ana María Godoy-Reyes, Paula Reyes-Suárez, Víctor Vera-Delgado, Lourdes González-Navarrete, Candelaria Martín-González, Carmen Nieves Hernández-León, Sonia García-Hernández, Emilio González-Reimers Hospital Universitario de Canarias, La Laguna, Spain

Introduction

Necrotizing autoimmune myopathy (NAM) is an uncommon, aggressive form of immune-mediated myopathy, that can be associated (although not necessarily) with statin intake and 3-hydroxymethylglutarylcoenzyme A reductase (HMGR) antibodies.

Case description

A 70-year-old man presented with a three-week history of severe myalgia and weakness. Physical examination was consistent with mild to moderate tetraparesis, especially affecting proximal muscles. Blood analysis were notable for hypertransaminasemia (ASAT 579 U/L, ALAT 481 U/L), LDH 1440 and raised creatin kinase (CPK) of 13 393 U/L. He also reported a remote history of statin intake at least a pair of years ago, that was not associated with any symptom. Autoimmune profile showed positivity for antinuclear, anti-Ro52 and anti-signal recognition particle (SRP) antibodies. A necrotizing myopathy was observed in deltoid muscle biopsy. A total body computed tomography (CT) did not reveal underlying neoplastic disease, and the patient was placed on corticosteroids (1.5 mg/kg) and azathioprine, 2.5 mg/kg after an initial treatment with 1 g methylprednisolone for three days and intravenous immunoglobulins. After initial worsening, the patient's condition progressively improved, being able to eat again without aid, and to regain walking ability. Immunosuppressive treatment was tapered. During the evolution the patient developed hairy leukoplakia in the tongue with a positive PCR-EBV (he reported a risky sexual behavior some weeks before), and a retrosternal mass that was operated on, histological analysis revealing a thymic hyperplasia and a benign cyst. Some physical features consistent with acromegaly led us to perform an oral glucose tolerance test, that showed increased growth hormone levels, and a magnetic resonance scan of the pituitary gland showing a pituitary microadenoma that has not changed in further controls.

Discussion

Clinical and histologic features of this patient are consistent with NAM, including the past use of statins, something recorded in some cases of this potentially lethal disease that usually requires intravenous immunoglobulins, intensive rehabilitation and a combination of immunosuppressive therapy. Other unusual features include a small microadenoma and an analytical profile consistent with acromegaly, that does not play a role in his clinical picture, and a thymic hyperplasia and cyst, not associated with myasthenia.

#1578 - Abstract

SYSTEMIC LUPUS ERITHEMATOSUS: A CRITICAL APPRAISAL OF CLINICAL PRACTICE GUIDELINES WITH THE AGREE II INSTRUMENT

Sergio Palacios-Fernandez¹, Margarida Oliveira², Mario Salcedo³

¹ Hospital Universitario San Juan de Alicante, Alicante, Spain

² Hospital Pedro Hispano, Unidade Local de Saúde de Matosinhos, Matosinhos, Portugal

³ Hospital Universitari i Politècnic La Fe, Valencia, Spain

Background

Systemic lupus erythematosus (SLE) is a systemic disease of great clinical complexity and in some cases life threatening consequences. Treatment includes a variety of drugs like biological and non biological immunosuppressive treatments, which implies complex management and potential toxicity. In the last 10 years several guidelines dedicated to the management of lupus have been published in different parts of the world. Our aim is to critically compare the methodological quality of these guidelines.

Methods

Selection of clinical guidelines

We analysed all clinical guidelines published between January 2010 and December 2018 referring to the management and treatment of SLE.

Analysis and comparison of methodological quality.

To analyze and compare the methodological quality of each clinical guideline, we used the Appraisal of Guidelines for Research and Evaluation II (AGREE II) tool, which has been developed by the AGREE Enterprise to assist authors and reviewers of clinical practice guidelines to verify that they are complete and transparent.

Results

Five clinical guidelines were included: Latin-American CPG (PACPG-LES), British CPG (GBRS-LES), a French guideline (NPDC-LES), a Spanish guideline (CPG-LES) and the European League Against Rheumatism guideline (EULAR-LES).

Quality evaluation using the AGREE II tool shows most guidelines reach 60% of the total score in most domains, being considered adequately addressed. The results in the different domains were:

Scope and Purpose This domain received a good result in all the appraised guidelines, with a median score of 88% (range 100 for the CPG-LES - 61.9 for the NPDC-LES).

Stakeholder Involvement: the median score on this domain was 66.67% (range 100% for CPG-LES and 59.5% for NPDC-LES and PACPG-LES).

Rigor of development: the median score was 74.1%, and only NPDC-LES was under 60%. CPG-LES and GBRS-LES scored highest.

Clarity of presentation: This is the domain in which guidelines performed better, with a median percentage of 80.95%. None of them scored less than 60%.

Applicability: It is the worst scored domain in all the evaluated guidelines, with a median score of 30.3%. Only GBRS-LES and CPG-LES scored over 60%

Editorial independence: The median score is 89.28 and only NPDC-LES scored under 60%

Conclusion

With all domains considered, we judge EULAR-LES, GBRS-LES, CPG-LES and PACPG-LES should be recommended for use without modifications. Finally, NPDC-LES is a low methodological quality guideline, so we don't recommend its use.

#1580 - Case Report

VOGT-KOYANAGI-HARADA - A CASE REPORT

Luisa Costa, Ana Rodrigues, Andreia Silva, Carolina Ferreira, Carla Lima, Miguel Oliveira, Sérgio Lemos

Centro Hospitalar Tondela-Viseu, Viseu, Portugal

Introduction

Vogt-Koyanagi-Harada disease (VKH) is a multisystem disorder that typically presents with bilateral, chronic granulomatous panuveitis associated with central nervous system, auditory, and integumentary manifestations. VKH is an autoimmune, inflammatory disorder mediated by CD4+T cells that target melanocytic antigen. The association between VKH and Graves' Disease, Hashimoto Thyroiditis and IgA Nephropathy has been reported.

Case description

54-year-old woman, with Graves' disease, presented to the emergency department with headache, tinnitus, photophobia and visual blurring. On examination, her blood pressure was 250/150 mmHg, visual acuities were 2.5/10 in both eyes, fluorescein angiography showed multiple leakage points, and optical coherence tomography showed gross macular edema and retinal pigment epithelial detachment (PED). These features were compatible with the diagnosis of acute VKH.

Laboratory studies identified the presence of renal failure (creatinine 6.3 mg/dL), the ultrasound image showed small kidneys, thinning of the parenchyma and its hyperechogenicity, so kidney biopsy was not performed.

The remain complementary exams showed no alterations. The patient received treatment with immunosuppression (prednisolone and mycophenolate mofetil), with improvement of PED, and started chronic hemodialysis for end-stage renal disease 4 months after the diagnosis.

Discussion

It is very important the awareness for this syndrome since the prompt diagnosis allows appropriate early treatment with corticotherapy which can lead to a better visual outcome.

#1601 - Case Report

PANCYTOPENIA WITH INTRAMEDULLARY HEMOLYSIS AS A PRESENTATION OF PERNICIOUS ANEMIA

Dúlio Teixeira Passos¹, Patrícia Semedo¹, Ana Cardoso¹, Vilma Salgado¹, Nuno Jacinto¹, Paula Rocha^{1,2}, João Meneses Santos^{1,2}, Rui M. M. Victorino^{1,2}

¹ Department of Internal Medicine II, North Lisbon University Hospital Center - Santa Maria Hospital, Lisbon, Portugal

² Medicine II University Clinic, Faculty of Medicine - University of Lisbon, Lisbon, Portugal

Introduction

Pernicious anemia (PA) is an autoimmune disease characterized by gastric atrophy and vitamin B12 (B12) malabsorption in the presence of intrinsic factor and/or parietal cells antibodies. The disease incidence peaks at the age of 60 and presents with hematologic and/or neurologic manifestations. We present a case where pancytopenia and intramedullary hemolysis were prominent.

Case description

A 58-year-old African men was admitted with fatigue, dizziness, asthenia, anorexia and weight loss in the last month. Physical examination was unremarkable apart from pallor and jaundice. Laboratory evaluation revealed severe pancytopenia: an hypochromic macrocytic anemia (hemoglobin 5.8 g/dL, hematocrit 18.6%, VGM 98.7 fL, CMHG 30.9 g/dL, RDW 30.5 CV%), leukopenia ($2.08 \times 10^9/L$) with neutropenia ($0.91 \times 10^9/L$) and thrombocytopenia ($137 \times 10^9/L$) and hemolysis with hyperbilirubinemia (total bilirubin 2.46 mg/dL and unconjugated bilirubin 2.07 mg/dL, elevated LDH (9700 U/L)) and decreased haptoglobin <10 mg/dL. Direct antiglobulin test was negative and the reticulocyte index was 0.19%, with peripheral blood smear with anisocytosis, poikilocytosis, schizocytes, drop cells, elliptocytes, macroovalocytes, rare erythrocytes with basophilic dotting, without blasts. The myelogram revealed moderately hypercellular bone marrow with inversion of the myeloid/erythroid ratio (1:5) and signs of megaloblasts. The etiological study revealed, a severe B12 deficiency (<100 pg/ml) with normal folic acid and iron studies. The antibodies for intrinsic factor were positive, but the anti-parietal cell antibodies and the remaining autoimmunity workup

were negative. Viral serologies and noninvasive Helycobacter (H.) pylori test were negative. Upper digestive endoscopy and biopsies showed moderate chronic gastritis with moderate atrophy of the fundus and extensive intestinal metaplasia; no H. pylori bacilli were observed. The diagnosis of PA was confirmed and the patient started parental B12 with improvement of the pancytopenia and disappearance of hemolysis pattern.

Discussion

B12 deficiency usually presents as macrocytic anemia although pancytopenia can be the presenting feature in around 10-30% of cases. Moreover intramedullary hemolysis with unconjugated hyperbilirubinemia and haptoglobin reduction can occur as illustrated in this case.

#1602 - Case Report

BILATERAL INTERSTITIAL LUNG INFILTRATES?

Grissell Starita Fajardo, Maria Aroca Ruiz, Miguel Martinez La Calzada, Irene Gonzalez Niño, Yasmina Sarhane Salvi, Andres Gonzalez García

Hospital Ramon y Cajal, Madrid, Spain

Introduction

When approaching a patient with rapidly progressive interstitial lung infiltrates, we must reconsider the clinical scenario, which implies going back to basics. In order to do so, we must perform, when possible, a new detailed anamnesis, complete physical exam, search for details and signs that could have gone unnoticed in the initial evaluation.

The presence of bilateral alveolo-interstitial infiltrates forces us to rule out other causes, such as: decompensation of heart failure, Infectious causes (Legionella, Mycoplasma, Virus, SARS), alveolar hemorrhage, eosinophilic pneumonia, cryptogenic organized pneumonia, hypersensitivity pneumonitis, respiratory distress, also other known causes of pulmonary edema and bilateral non-cardiogenic opacities: drugs, inhaled toxins and systemic autoimmune diseases such as DM / PM undiagnosed, AR, Sjögren, SLE.

Case description

74 years old male, who presents fever and minimal effort dyspnea. This process had began one month prior as progressive asthenia, cough and expectorating. Previously, he had been admitted for 4 days for bilateral pneumonia, for what he received iv ceftriaxone for 4 days, followed by cefditoreno for 10 days, without any improvement.

He was admitted to the Internal Medicine department, with progressive worsening of his condition despite broad-spectrum antibiotic therapy, IV corticosteroids and bronchodilators. Thus, he was transferred to the ICU with an initial diagnosis of acute respiratory failure secondary to bilateral non-cardiogenic infiltrates, without micromicrobiological affiliation. He required

OTI, mechanical ventilation and ventilation in prono in 3 separate occasions. Upon admission to the ICU, Voriconazole and Ganciclovir were added, still no significant improvement.

Discussion

In the presented case, our patient had mechanic's hands. All the microbiological screening was negative, the echocardiogram without relevant findings. We isolate anti PMSCL75; antibody that has been associated to syndromes of overlap, DM/PM, and to systemic sclerosis, so when suspected of pulmonary involvement secondary to immune-mediated disease, it was decided to start bolus of methylprednisolone. On the 2nd day, Azathioprine was added with very good tolerance and evolution, He was discharged from the ICU to the internal medicine ward on conventional supplemental oxygen therapy. After completing diagnosis test, he was transferred to a recovery unit to continue rehabilitation, where he fully recovered from the ICU sequelae.

#1623 - Abstract

AUTOIMMUNE INNER EAR DISEASE IN A SYSTEMIC IMMUNE-MEDIATED DISEASES UNIT

Renata Ribeiro^{1,2}, Joana A. Duarte¹, Marta C. Amaral^{1,2}, José Delgado Alves^{1,2}

¹ Systemic Immune-mediated Diseases Unit (UDIMS) | Department of Medicine IV, Hospital Professor Doutor Fernando Fonseca, Amadora, Portugal

² Chronic Diseases Research Center (CEDOC) | NOVA Medical School, Universidade Nova de Lisboa, Lisbon, Portugal

Background

The autoimmune inner ear disease (AIED) represents less than 1% of all cases of sensorineural hearing loss. It develops from weeks to months and has a progressive, usually bilateral asymmetrical course. It usually presents between the 3rd and 6th decade of life as a primary condition of the inner ear or, in up to 1/3 of cases, secondary to a systemic autoimmune disease. The antibody most frequently determined is against a heat shock protein (HSP70) of the inner ear, currently considered a non-pathogenic epiphenomenon.

Methods

Retrospective analysis of a cohort of patients with suspected AIED referred from the otorhinolaryngology department to a systemic immune-mediated diseases unit from March 2013 to October 2018.

Results

Twenty-three patients were included, 14 (60.9%) women, with an average age of 49,1±17,4 years-old. Eighteen (78.3%) presented with sudden deafness, in 56.5% (n=13) of cases bilateral. The time from the onset of symptoms to the diagnosis was 45,4±96,9 days and 87% (n=20) had accompanying vestibular symptoms. Thirteen

(56.5%) patients had positive antinuclear antibody and twenty-one (91.3%) had at least one antibody anti-HSP70 determination, 9 positive and 12 negative. Patients with positive anti-HSP70 had this antibody measured 152±215 days after symptom onset, whereas patients with negative anti-HSP70 had antibody assessed after 631±862 days. Twenty (87%) patients were prescribed either systemic or intra-tympanic steroids. Only one patient had complete resolution of hearing loss after steroid treatment, 6 were non responders. The majority had a fluctuant course of symptoms and audiogram findings. Seven (30.4%) patients had an associated systemic autoimmune disease: 2 systemic lupus erythematosus (SLE), 2 systemic sclerosis, 1 mixed connective-tissue disease, 1 antiphospholipid syndrome and 1 seronegative arthritis. In this smaller group patients were mostly women (71.4%; n=5) with predominantly sudden onset (85.7%; n=6) and bilateral (85.7%; n=6) symptoms. Steroid response was not higher and to 6 of the 7 patients an additional immune modifying drug was associated with no better outcome.

Conclusion

In this cohort suspected AIED was the presenting form of 5 different systemic autoimmune diseases. When associated with a systemic disease patients had predominantly bilateral symptoms with a sudden onset. Steroid response was low and might not be an exclusion criteria. In the absence of a single diagnostic or prognostic test, a great suspicion index is needed.

#1629 - Case Report

IMMUNE-MEDIATED INNER EAR DISEASE

Ana Chora Sousa, Francisco Dias Claudio, Rita Ribeirinho, Tiago Tribolet Abreu

Hospital do Espírito Santo de Évora, Évora, Portugal

Introduction

Immune-mediated inner ear disease (AIED) is a rare condition and the pathogenetic mechanisms remain unclear. An uncontrolled attack against inner ear antigens, resulting in both T-cell responses and autoantibody development has been proposed as the pathogenetic mechanism. This immunological process may result in cochlear and vestibular insults. Systemic autoimmune diseases coexist in 15-30% of patients.

Case description

We describe a 22-year-old woman who presented with a 2-year history of bilateral, asymmetric and sudden hearing loss, more exuberant in the right ear, with progressive aggravation. With the exception of tinnitus, other symptoms were denied. Besides an aunt with ankylosing spondylitis, there was no past medical or familiar history. Bilateral sensorineural hearing loss at 40db was documented. The autoimmune panel was negative for antinuclear antibody, anticardiolipin, antiβ2glycoprotein1, rheumatoid factor, smooth muscle, antimicrosomal, antigliadin and antiLMK antibodies. The antiHSP70 (heat shock protein) antibodies were

positive. Circulating immune complexes levels and erythrocyte sedimentation rate were normal. Fluorescent treponemal antibodies absorption test was negative. Initial approach included corticosteroid (deflazacort 1 mg/Kg/day for 1 month and slow weaning). During the follow-up, the patient reported an improvement with the therapy and a relapse of the hearing loss with the corticosteroid reduction below 30mg/day. Therefore, the corticosteroid dose was increased and a steroid-sparing agent was included (azathioprine 50mg/day). A close collaboration with otolaryngologists and regular audiometry re-evaluation was maintained.

Discussion

Our aim is to report this case of AIED in order to alert for an early identification of this rare disease since a prompt medical treatment might result in acceptable hearing outcomes. Moreover, many cases might remain un-diagnosed due to the fact that specific diagnostic tests are not currently available. The clinical expression of AIED shows a progressive bilateral and asymmetric sensorineural hearing loss profile, progressively developing between 3 and 90 days, which typically benefits from immunosuppressive therapy, mainly with corticosteroids. The hearing deficit sometimes presents threshold fluctuations. In about 50% of the AIED patients, hearing loss is also associated with vestibular symptoms, such as imbalance and motion intolerance, ataxia and positional or episodic vertigo.

#1639 - Case Report

FEVER OF UNKNOWN ORIGIN

Cristina Lojo Cruz, M^a Esther Sánchez-García, Eduardo Gañán-Moreno, M^a Asunción Navarro-Puerto, Isabel Melguizo-Moya, Jose Antonio Mira-Escarti

Hospital Universitario Ntra Sra de Valme, Sevilla, Spain

Introduction

A healthy 31-year-old man was admitted because of periodic episodes of fever, shivers and night sweats. He also complained about weight loss, headache, myalgias and evanescent cutaneous rash during the feverish peaks with asymptomatic intercrisis periods. He was hospitalized in 2006 because of fever with clinical resolution after doxycycline therapy.

Case description

Physical examination only revealed a mild tachycardia. He presented microcytic hypochromic anemia which required blood transfusions and intravenous iron supplements. White blood cells and platelets counts, coagulation tests, complement and serum immunoglobulins were in the normal range. Erythrocyte sedimentation rate (ESR) was 166 mm/h and plasmatic C reactive protein (CRP) was 150 mg/dL. Biochemistry showed a mild hypertransaminasemia. Complete autoimmunity panel was negative. Extensive microbiological serologies only revealed positive IgG for cytomegalovirus and Epstein-Barr virus

with negative Mantoux test and urine, stool and serial blood cultures. Echocardiography, chest and abdominal computed tomography (CT) scans, cranial and bowel magnetic resonance imagings, esophagogastroduodenoscopy and colonoscopy were performed with normal results. Positron emission tomography with CT revealed increased contrast uptake at femurs and axial bone marrow and bone marrow aspiration study was made to ruled out hematological malignancies.

Autoinflammatory disease genetic study showed a heterozygous mutation in tumor necrosis factor (TNF) receptor superfamily member 1A gen (TNFRSF1A; arginine-to-glutamine missense mutation at amino acid 92, R92Q mutation) and he was diagnosed of TNF receptor-associated periodic syndrome (TRAPS).

A treatment with oral prednisone 20 mg/day was started with partial clinical response. For this reason, subcutaneous anakinra with progressive dosage increments from 100 mg to 150 mg daily was added to allow steroids withdrawal. After a follow up of one year he is asymptomatic and CPR, ESR as well as plasmatic amyloid A levels are normal.

Discussion

TRAPS is a rare disorder caused by mutations in the TNFRSF1A gene. It is generally inherited in an autosomal dominant manner with incomplete penetrance. R92Q is a variant associated with a mild TRAPS phenotype with a late onset of the symptoms thus diagnosis is a medical challenge. TNF receptor-1 participates in the inflammatory response promoting a permanent inflammation which cornerstone treatment is interleukin 1 blockage.

#1678 - Case Report

PRIMARY ANTIPHOSPHOLIPID SYNDROME ONLY WITH EXTRA-CRITERIA MANIFESTATIONS

Bárbara Saraiva, Ivanna Ostapiuk, Francisco Lopes Morgado, Susana Abreu, Nadedja Ptlog, Celestina Blanco Torres, Joana Vedes

ULS Guarda, Guarda, Portugal

Introduction

Livedo racemosa (LR) is the most frequent cutaneous manifestation of the Antiphospholipid Syndrome (APS). It differs from the livedo reticularis not only by the morphology of the irregular and discontinuous circles, their distribution (trunk and / or buttocks, in addition to the limbs), but also by their clinical significance (presence of vasculitis) and prognosis (association to vascular events), namely the Sneddon's syndrome.

Case description

We present the case of a 15-year-old girl referenced by confirmed positivity of the lupus anticoagulant. Antiphospholipid antibodies (AFL) were requested by the Physiatrist for the recurrence of peripheral facial paresis (7 and 14 years), with no specious explanation. The history of livedo reticularis in the mother and

stroke in the 6th decade in 3 relatives on the maternal side. She had LR on the back of her arms and thighs. No arthritis, Raynaud or sicca symptoms, No erythema malar, blots or adenopathies. No valvulopathy. ANAs - and initial capillaroscopy with nonspecific alterations. Aggravation of livedo, appearance of Raynaud blue and posterior capillaroscopy suggesting an autoimmune disease, with signs of endothelial activity. Requested skin biopsy, which Dermatology chose not to perform. Due to the characteristics of livedo, exuberance, capillaroscopic alterations and family history of stroke, it was decided to antiaggregate and immunomodulate the patient. Livedo was frankly improved. It was recently tested the ANAs (160), with two standards.

Discussion

Livedo racemosa is not currently included in the SAF classification criteria. However, several authors have proposed its inclusion, as it is the most significant of the extra criteria manifestations. Confirmation by cutaneous biopsy of the presence of vasculitis has been recommended in RL patients, due to its prognostic importance in relation to future cerebrovascular ischemic events. It was not possible to prove it in our patient, but the capillaroscopy demonstrated the presence of endothelial dysfunction.

The strong association between LR and stroke is so significant that it was proposed for the diagnosis of APS, even in the absence of AFL positivity (seronegative APS). Endothelial cells interact with AFL to generate vasoconstriction associated with LR and enable arterial thrombosis. Taking into consideration these evidences, we allowed ourselves to diagnose an APS in this patient, despite presenting only extra criteria manifestations.

#1683 - Case Report

GRANULOMATOSIS WITH POLYANGIITIS WITH CENTRAL NERVOUS SYSTEM INVOLVEMENT

Lúisa Pina Marques, Samuel Fonseca, Elsa Meireles

Centro Hospitalar Entre Douro e Vouga, Santa Maria Da Feira, Portugal

Introduction

Granulomatosis with polyangiitis (GP) is a systemic disease. It is characterized by necrotizing inflammation with granuloma formation, of small to medium vessels, most frequently involving respiratory tract and kidneys. Neurologic involvement is common, occurring in about 20 to 50% of patient, but central nervous system (CNS) lesions is reported in only 2-13% of the cases.

Case description

The authors describe a case of a 76-year-old woman who was admitted to the hospital with a 4-week history of constitutional symptoms with fever, anorexia and asthenia. There were no associated symptoms such as cough, abdominal pain or lower urinary tract symptoms. On admission, she was febrile, with a blood pressure of 161/78 mmHg and oxygen saturation on room air was 94%. There was no evidence of pulmonary and cardiac murmur

alterations, lymphadenopathy, hepatosplenomegaly, or skin lesion. Neurologic examination revealed a right homonymous hemianopia and slight decrease in left leg strength. Laboratory investigations revealed an elevated erythrocyte sedimentation rate and C-reactive protein; renal function was normal and urinary sediment showed no abnormality. Computed tomography scan reported right pleural effusion combined with multiple bilateral pulmonary nodular lesions. Magnetic resonance imaging of the skull showed multiple areas with restricted diffusion in the white matter of the radiated crowns, left hippocampus, thalamus, left lenticular region and posterior lenticular region and in right caudate nucleus.

A lung biopsy was performed and the pathological findings demonstrated a granulomatous inflammation without necrosis. Serum proteinase 3 cytoplasmic antineutrophil cytoplasmic autoantibody was elevated. The diagnosis of GP with pulmonary and CNS involvement was established, and immunosuppressive therapy with cyclophosphamide and pulses of methylprednisolone was started.

There was significant improvement of the inflammatory syndrome, with resolution of the fever and regression of the pulmonary lesions. There was no improvement of the neurological condition.

Discussion

GP with CNS lesions is uncommon and always poses a great diagnostic challenge. Differential diagnosis of fever and lung nodules included tuberculosis, sarcoidosis, fungal infection, vasculitis and malignancy. Its low incidence combined with manifestations that overlap with other diseases results in difficulty diagnosing GP. Early diagnosis and immunosuppressive therapy are essential for a favorable outcome.

#1684 - Case Report

RIFAMPICIN-MEDIATED THROMBOCYTOPENIA, HEMOLYTIC ANEMIA AND ACUTE KIDNEY INJURY

João Alexandre Tavares¹, José Mariz², Jorge Teixeira²

¹ Centro Hospitalar de Setúbal, Setúbal, Portugal

² Hospital de Braga, Braga, Portugal

Introduction

Rifampicin (RF) has been used as first line treatment of Tuberculosis. Its most common side effect is liver toxicity, which often leads to suspension or replacement of the drug. Despite being less common, RF-mediated acute kidney injury (AKI) has been described, usually as a readministration. It has a benign course with complete resolution of AKI at 90 days in 96% of cases, after suspension. According to the literature, AKI is an immune-mediated phenomenon. Other immune-mediated phenomena include hemolytic anemia, thrombocytopenia or intravascular disseminated coagulation. The literature suggest that these reactions are associated with anti-rifampicin antibodies with cross-reactivity against antigens located in the erythrocyte surface or the walls of renal tubules.

Case description

We describe a case of a 39-year-old woman with a diagnosis of latent tuberculosis. Initially treated with Isoniazide for two months and suspended due to liver toxicity. After the resolution of the hepatitis, RF was started. No relevant past history, no allergies or chronic medication. Admitted in the Emergency Department with a history of 2 episodes of hematemesis. She also complained of generalized petechiae including mouth and tongue. She had a lab work from 15 days earlier with no relevant changes. She repeated the labs which showed a severe thrombocytopenia (unmeasurable platelets), non-oliguric AKI (creatinine of 1.8 mg/dL) and a normocytic/normochromic anemia of 11 g/dL with criteria for hemolysis. A broad panel of labs was collected, including auto-immune antibodies and infectious serologies. Over the first days patient had a worsening of the anemia, with a minimum of 8.1 g/dL as well as a worsening of the renal function with a creatinine of 7.1 mg/dL without criteria for dialysis. She had platelet pool transfusion. Patient was started on IV Immunoglobulin as well as high-dose corticosteroids. Imaging studies of the thorax, abdomen and pelvis showed no changes. She was kept stable and eventually all the changes started to resolve and she was discharged after 3 weeks with a normal renal function, no anemia or thrombocytopenia, with an exclusion diagnosis of RF-mediated reaction.

Discussion

Despite the absence of renal biopsy to confirm the presumptive diagnosis, RF-mediated reaction is supported by the literature, as well as the course of the disease. High dose corticosteroids have shown to decrease the rate of progression to dialysis and a quicker normalization of the normal function.

#1686 - Case Report

SMALL VESSEL VASCULITIS - AN UNCOMMON PRESENTATION

David Lopes Sousa, Joana Paixão, Jorge Fortuna, Joana Coelho, Pedro Ribeiro, Armando Carvalho

Centro Hospitalar e Universitário de Coimbra, Coimbra, Portugal

Introduction

Anti-neutrophil cytoplasmic antibodies associated vasculitis include microscopic polyangiitis, granulomatosis with polyangiitis and eosinophilic granulomatosis with polyangiitis, and predominantly affect small vessels. The most commonly affected organs are the lungs and the kidneys.

Case description

We report the case of 62-year-old man with a 3-month history of nocturnal fever, malaise and weight-loss. He had no accompanying symptoms and his physical examination was otherwise unremarkable. He had regular pneumology consultations for post-inflammatory lung fibrosis following H1N1 influenza 5 years before this episode and had completed 2 courses of broad-

spectrum antibiotics. At his hospital admission, he presented with normochromic normocytic anaemia and elevated erythrocyte sedimentation rate (ESR) and C-reactive protein (CRP), with normal differential white blood cell count and renal function. Further studies excluded infection and solid organ neoplasm and bone marrow biopsy excluded primary haematological disease. An auto-immunity panel was ordered, revealing elevated IgE, strong positivity for perinuclear anti-neutrophil cytoplasmic antibodies (pANCA) and anti-myeloperoxidase (MPO) antibodies. Bronchial biopsy showed eosinophilic inflammation. Lung biopsy was not obtained due to excessive bleeding during the procedure. A diagnosis of primary pANCA vasculitis was made, and the patient started on 1 mg/kg of prednisolone with clinical improvement and remission of fever. At 1-month follow-up he was asymptomatic and started on azathioprine. At 1-year follow-up the patient maintained clinical remission and normalization of ESR.

Discussion

Although an adequate tissue biopsy was not obtained, a diagnosis of pANCA vasculitis was made based on clinical presentation, laboratory findings and exclusion of other probable causes. Induction treatment with isolated glucocorticoid was decided due to the absence of target-organ damage.

#1697 - Case Report

REFRACTORY PARANEOPLASTIC DERMATOMYOSITIS AFTER BREAST CANCER TREATMENT

Mafalda Corrêa Figueira, Margarida Lopes Madeira, Gonçalo Amaral Mendes, Bárbara Lobão, José Pedro Villa De Brito, Ermelinda Pedroso

Centro Hospitalar de Setúbal, Setúbal, Portugal

Introduction

Dermatomyositis (DM) is an inflammatory connective tissue disease, causing both myositis and typical cutaneous manifestations such as heliotrope rash, gottron papules and shawl sign. It may be associated with malignancies, which may be present in 15 to 30% of patients with this condition.

Case description

The authors are presenting a clinical case of a 63-year old woman who was diagnosed with breast cancer (3° degree invasive carcinoma) and, at about the same time, who appeared with cutaneous manifestations of DM. She had heliotrope rash, gottron papules and exuberant shawl sign and after laboratory analysis she was diagnosed with anti-p53 positive dermatomyositis. She underwent neoadjuvant chemotherapy, mastectomy, lymph node removal and to 18 courses of trastuzumab. Although she attained a disease free interval of three years by now, she maintains exuberant cutaneous manifestations of DM. After an initial course of oral and topical corticosteroids she initiated oral methotrexate (MTX) with no clear benefit. After

switching to subcutaneous MTX also with little response, she started intravenous immunoglobulin (IVIG). During this first course of IVIG we had to interrupt the therapy due to fever and the patient was maintained on prednisolone, subcutaneous MTX and hydroxychloroquine. After being admitted to an Internal Medicine ward for another course of IVIG that was successful, she was maintained on IVIG monthly (2g/Kg divided in four days) with clinical stabilization. Four months after beginning IVIG treatment she had a new episode of fever and hypotension that resolved with hydration and antipyretics. No infection was diagnosed at this time.

Discussion

The association between breast cancer and DM is described in the literature, as is the association of relapses of DM and the recurrence of cancer. The positivity of anti-p53 is linked to the presence of cancer associated myositis and it is postulated that there may be an association with more invasive types of cancer. It is interesting that despite remission of breast cancer this patient continued to have such aggressive cutaneous manifestations of DM, not only relapsing but sometimes clearly refractory to therapy. More studies with longer follow-up are needed to understand if there is a subset of patients in which refractoriness and relapsing of DM may or may not mean an increased risk of cancer relapse.

#1707 - Case Report

OVERLAP SYNDROME VERSUS UNDIFFERENTIATED CONNECTIVE TISSUE DISEASE

Bárbara Saraiva, Ivanna Ostapiuk, Francisco Lopes Morgado, Celestina Blanco Torres, Joana Vedes
ULS Guarda, Guarda, Portugal

Introduction

Systemic autoimmune diseases are sometimes presented at the onset, with symptoms, signs and laboratory findings that do not allow them to be classified according to the internationally defined criteria for each of them and / or gather findings that show in several of these entities, speaking in these cases in Overlap or in Undifferentiated Connective Tissue Disease (UCTD). This occurs in 15 to 25% of patients.

Case description

We report the case of a Caucasian woman, 46 years old, referred to in 2014 as a Raynaud (fR) phenomenon in the hands since 2013, morning pains in the spaces between the metacarpophalangeal joints and the fingers in "sausage", with incapacity to place the rings for 1h. Also reported were complaints of xerostomia, postprandial infarction with belching, and frequent painful digital cracking in the hands. Personal history of psoriasis, self-limiting 10 years ago and chilblains from the toes since adolescence. The presence of telangiectatic nasogenian erythema, marbled hands, dry tongue

and cleft in the pulp of the 1st finger of the right hand was observed. From the complementary study, we highlight a capillaroscopy suggestive of early systemic sclerosis (ES), hiatal hernia and esophagitis, with normal manometry, significant decrease of basal salivary secretion, mild concentric pericardial effusion, hypocomplementemia and elevated muscle enzymes with normal electromyography. Normal VS, without cytopenias and negative autoantibodies. She did not tolerate hydroxychloroquine (for epistaxis and headache) nor methotrexate. Without fR, fissures or interdigital pain, under amlodipine 5mg, colchicine 0.5mg, ranitidine 150mg, cholecalciferol, sun protection and naproxen 500mg in SOS.

Discussion

In the case of this patient, the presence of symptoms and signs associated with several autoimmune diseases (ES, Sjögren's Syndrome, Systemic Lupus Erythematosus and Polymyositis), does not meet, however, criteria for classification for any of these diseases. The main complaints were controlled with symptomatic treatment and the pericardial effusion disappeared under colchicine. It maintains hypocomplementemia. Systemic autoimmune diseases establish a diagnostic and classification challenge. More important than labeling the syndrome is to provide the patient with the treatment of the clinical symptom presented. The greater of these UCTD eventually develops into a classifiable autoimmune disease.

#1722 - Medical Image

SARCOID ARTHRITIS

Ioannis Raftakis, Monica N. Ferreira, Jonathan Krygier, Prochore Kamgang, Valerie Badot
CHU_Brugmann, Brussels, Belgium

Clinical summary

A 39 years African man with biopsy proven sarcoidosis, long standing lupus pernio, presented with swelling of the hands and feet.

X-rays were compatible with soft tissue swelling, cysts formation and resorption of the distal tuft.

Ultrasound revealed active synovitis, tenosynovitis and dactylitis in hands and feet.

PET scan revealed mediastinal lymph nodes, as well as lymphadenopathy in the supraclavicular areas.

Laboratory tests showed increased phase reactants (ESR and CRP) and treatment was started with steroids and methotrexate.

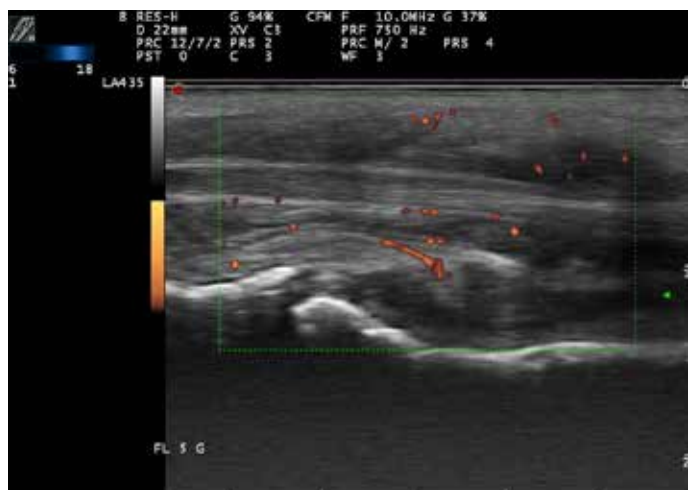

Figure #1722. Active synovitis and tenosynovitis 5th digit.

#1758 - Case Report

SYSTEMIC LUPUS ERYTHEMATOSUS, ANTIPHOSPHOLIPID SYNDROME AND HASHIMOTO THYROIDITIS OCCURRING IN A PATIENT WITH NIEMANN-PICK DISEASE: A CASE REPORT

Wafa Baya, Imen Ben Hassine, Fatma Ben Fredj Ismail, Jihed Anoun, Monia Karmani, Amel Rezgui, Chedia Laouani Kechrid
Internal Medicine Department, Sahloul University Hospital, Sousse, Tunisia

Introduction

Acid sphingomyelinase-deficient Niemann-Pick disease (NPD) is a lysosomal lipid storage disorder with autosomal recessive inheritance. The broad clinical spectrum of this disorder may overlap with that of systemic lupus erythematosus (SLE), hindering differential diagnosis.

Case description

A 40-year-old woman with a familial history of NPD was diagnosed with a NPD type B at the age of ten. She presented hepatosplenomegaly with hemolytic anemia. A bone marrow aspirate confirmed the diagnosis then. Acidum folicum supplementation was administered.

Twenty years later (2008), she presented arthralgia of the big joints with dyspnea. Physical examination found a persistent hepatosplenomegaly and crackles at lung auscultation. Laboratory investigations revealed severe anemia related to active hemolysis, lymphopenia, thrombocytopenia and a positive direct Coombs' test. C4 level was low. C4 level was normal. Antinuclear antibodies were positive in the range of 1:1600 with a positive anti-nucleosome antibody. IgG anti-cardiolipin and IgA anti-beta 2 glycoprotein antibodies were positive and persistent after 12 weeks. Furthermore, we found a highly increased TSH level with positive anti-thyroid peroxidase antibody. She was diagnosed with SLE and Hashimoto disease. She was treated with Prednisone, Chloroquine, Aspegic and Levothyroxine.

In 2015, she presented with acute dyspnea. Chest high-resolution computed tomography imaging showed diffuse infiltrative lung disease with left segmental pulmonary embolism. Anticoagulant therapy was initiated.

Discussion

SLE may mimic or be mimicked by several systemic disorders, including lysosomal storage disorders.

This is the second case of coexistence of SLE with antiphospholipid syndrome and type B NPD.

#1765 - Case Report

COMPLETE REITER SYNDROME

Ballesteros-Chaves Label, Palomar-Muñoz Carmen, Perez-Vazquez Gloria, Gil-Gascon Jose Manuel, Bianchi-LLave Jose Luis
Hospital Punta Europa- Servicio Andaluz de Salud, Algeciras, Spain

Introduction

The complete Reiter Syndrome is an infrequent entity, is only seen in 33% of cases. This syndrome can simulate many types of oligoarthritis, and it is the most common cause of arthropathy in the young. Reiter Syndrome is a reactive arthritis in the group of spondyloarthropathies associated with HLA-B27.

Case description

19-year-old male with no relevant medical history, consulting with arthralgias, and asthenia, without fever, mainly in ankles and heels. Referring enteric disease with diarrheic stools, followed with conjunctivitis in right eye, month before. Later the patient commented repetitive balanitis. The blood test showed elevation of reactants of acute phase, as well as HLA-B27 positive. Serotypes of hepatotropic viruses and parvovirus were negative, and also the microbiological study of balanopreputial exudate.

Discussion

Reiter Syndrome is characterized by ocular manifestations conjunctivitis or uveitis, reactive arthritis and urethritis, this term is reserved for cases with the classic triad. The exact cause of reactive arthritis is not known. Most commonly, this syndrome occurs in men before 40 years and can develop after infection with Chlamydia, Campylobacter, Salmonella and Yersinia. The diagnosis is based on clinical features. The goal of treatment is to relieve symptoms and treat any underlying infection. Reactive arthritis can disappear in about 3 to 4 months, but up to half of those affected experience recurrence of symptoms for several years, and can become chronic.

#1773 - Case Report

SYSTEMIC SCLEROSIS, A DELAYED DIAGNOSIS OF A SEVERE MULTISYSTEMIC DISEASE - A CASE REPORT

Lorrane Viana, Mariana Maranhas, Carolina Amado, Ana Oliveira, Margarida Coelho, Mariana Sousa, Rosa Jorge
Centro Hospitalar do Baixo Vouga, Aveiro, Portugal

Introduction

Systemic sclerosis (SSc) is a rare multisystemic disease with an autoimmune (AI) background, characterized by progressive fibrosis of the skin, internal organs and vasculopathy. It is classified based on the extent of skin involvement: diffuse cutaneous SSc (dc SSc) and limited cutaneous SSc (lc SSc). The last may display features of the CREST Syndrome (Calcinosis, Raynaud's Phenomenon (RF), Esophageal dysmotility (ED), Sclerodactyly and Telangiectasia).

Case description

53 year old female admitted with a three month history of dyspnea, orthopnea, and paroxysmal nocturnal dyspnea associated with atypical chest pain and non-controlled hypertension. She also referred skin thickening of the face, hands and feet and finger changes, evolving over 6 years, compatible with Raynaud's Phenomenon F on both hands, which the patient attributed to her work activity, cod fish dry. Later, she admitted dysphagia to liquids, with frequent gagging over the last years. Physical examination revealed hypertension, skin induration of the hands, wrists and feet, mask-like face with microstomia and malar telangiectasia, calcinosis on the 3rd and 4th fingers of the right hand and pulmonary rales. Laboratory tests showed type 1 respiratory failure and a positive AI study for antinuclear antibody, anti-RNA polymerase III (rp-11 and rp-155) and anti-mitochondrial M2 antibody. Thorax radiography revealed left pleural effusion and bed-side echocardiography a reduced ejection fraction (EF) and probable myocardial fibrosis (MF), associated with mild pericardial effusion (PeE), with no signs of pulmonary hypertension. Thorax CT scan showed a reticular interstitial pattern on upper and lower segments and. A moderate restrictive defect associated with a low DLCO was obvious on spirometry. Cardiac MRI revealed preserved EF, mild PeE and no signs of MF. Furthermore, it also revealed an enlargement of distal esophagus. The esophageal-gastric transit only demonstrated hypotonic gastric peristalsis, with need to perform endoscopic study and esophageal manometry, already pending. Cappilaroscopy showed a scleroderma early pattern.

Discussion

Although SSc is uncommon, it has a high morbidity and mortality. Improved understanding with an integrated multidisciplinary approach is essential for promptly and effectively recognize, evaluate, and manage complications and limit end-organ dysfunction. In this case report, the diagnostic delay diffculted the patient's management with a subsequent increased morbidity.

#1784 - Case Report

PAGET DISEASE, MALIGNANT DEGENERATION

Ballesteros- Chaves Isabel, Palomar- Muñoz Carmen, Perez- Vazquez Gloria, Gil- Gascón Jose Manuel, Bianchi- Llave Jose Luis
Hospital Punta Europa- Servicio Andaluz de Salud, Algeciras, Spain

Introduction

Sarcomatous degeneration in Paget Disease is the most serious complication, with an incidence lower than 1% and a high mortality that is not always accompanied by analytical alterations, which makes its diagnosis difficult.

Case description

68-year-old man, ex-smoker, diabetic and dyslipidemic, with Paget Disease who received several lines of treatment. He reported weight loss, anorexia and generalized pain that worsened rapidly until that confined him to a wheelchair. Blood test showed globular sedimentation rate 29mm/h, C-reactive protein 3.73 ng/dl, but alkaline phosphatase, proteins, seric calcium, phosphorus, and tumor markers were all negative. CT, Gastrosocopy, fibrobronchoscopy and MRI were realized without pathological finding excepting polyostotic disease. In later weeks, a painful mass appears in right thigh, a biopsy was performed showing a sarcoma.

Discussion

Paget Disease is a disorder without known cause. In Spain the prevalence is 1% in the population over 55 years. Among the complications associated with this disease, malignant degeneration occurs in less than 1% of patients mainly in males and patients with polyostotic disease. The most frequent cell types are osteosarcoma (50-60%), fibrosarcoma (20-25%) and chondrosarcoma (10%). It is accepted an increased globular sedimentation rate or alkaline phosphatase related with the presence of sarcoma, but in our case the biological tests were negative that is exceptional and made the diagnosis difficult.

#1797 - Case Report

A RARE CAUSE OF ABDOMINAL PAIN

Joana Milho, Ana Rita Lambelho, Sofia Guerreiro Cruz, Ana Pinheiro Sá, José Barata
Hospital Vila Franca de Xira, Vila Franca De Xira, Portugal

Introduction

Periaortitis is a rare chronic inflammatory condition characterized by inflammation and fibrosis surrounding the aorta and iliac arteries that has various clinical presentations: inflammatory abdominal aortic aneurysms, periaortic retroperitoneal fibrosis or isolated periarotitis. It may be idiopathic or secondary to other causes like autoimmune disease, malignancy, infections or drugs.

Case description

We present a case of a fifty four year old man, previously healthy.

He presented to the emergency department complaining of lower back and abdominal pain and weight loss for the last three weeks. The initial laboratory evaluation showed: hemoglobine 13.4 g/dL; leucocytes $8.7 \times 10^3 /\mu\text{L}$, C- reactive protein 3 mg/dL, elevated erythrocyte sedimentation rate (20mm); normal renal function. Abdominal contrast-enhanced CT scan showed peri-aortic fibrosis of the infra-renal aorta and iliac arteries, with an extension of 5 cm. The patient was admitted to further investigation, which demonstrated the presence of a positive cytoplasmic antineutrophil cytoplasmic antibody (cANCA) and anti-proteinase 3 antibodies (anti-PR3); the rest of autoimmune workup and serological tests for syphilis, brucella and HIV were negative.

It was admitted the diagnosis of periaortitis with retroperitoneal fibrosis and the patient was started on high dose steroid therapy with symptomatic remission; then he was medicated with methotrexate with slow tapering of steroid therapy.

At six months follow-up the patient remained asymptomatic and repeated the CT scan which demonstrated reduction of the fibrosis.

Discussion

Periaortitis is an idiopathic immune mediated condition, sometimes associated with autoimmune disease, that most commonly occurs in men (2:1) from 40 to 60 years of age. Although the patient has only aortic involvement without any organ dysfunction, the positivity of c-ANCA should alert for this case as possible first manifestation of an ANCA vasculitides.

#1801 - Case Report

ELASTIC PSEUDOXANTOMA: CASE REPORT

Ballesteros- Chaves Isabel, Palomar- Muñoz Carmen, Perez-Vazquez Gloria, Gil- Gascon Jose Manuel, Bianchi- Llave Jose Luis Hospital Punta Europa- Servicio Andaluz de Salud, Algeciras, Spain

Introduction

The elastic pseudoxanthoma is an hereditary disease of the connective tissue characterized with progressive calcification and fragmentation of the elastic fibers of different tissues (skin, eyes and cardiovascular system). It is not usually suspected, therefore the interest in presenting this case, as early diagnosis helps prevent future complications that these patients may develop.

Case description

56-year-old woman with hypertension, consulted with visual loss acuity and subcutaneous nodules. Subsequently appeared transient motor deficit and hearing loss so we realized a CT scan was that showed systemic atherosclerosis, and an eye fundus that showed striae angiodes. With the clinical suspic of elastic pseudoxanthoma, a genetic study is requested that was positive. The patient received intravitreal treatment with ranibizumab and strict control of cardiovascular risk factors.

Discussion

The elastic pseudoxanthoma is a hereditary systemic disease characterized by generalized elastorhexis of the elastic fibers with calcification, and systemic manifestations. Cutaneous manifestations are the first manifestation, and the earliest ocular manifestation is an alteration of the retinal pigment, the most characteristic is the presence of "angioid striae" (not pathognomonic). The connective tissue disorder in the most severe forms, like intermittent claudication, arterial aneurysms, coronary heart disease, hypertension, atherosclerosis and cerebrovascular accidents.

#1807 - Abstract

POLYPHARMACY IN SLE

Joao Teixeira, Miguel Martins, Catarina Costa, Sofia Pinheiro UDAI - HSAC, Lisboa, Portugal

Background

Systemic Lupus Erythematosus (SLE) is a multiorgan disease and despite new treatments still frequently presents with systemic manifestations.

As such, the need for pharmacological intervention is still quite common, and polypharmacy in this group of patients is one of the major causes for morbidity.

We set out to characterize and study polypharmacy in the SLE patients of our Medical Unit

Methods

Retrospective cohort study in which we analyzed the data from a small sample (simple random sampling, 100 patients) from a population of individuals followed in a specialized consultation of Autoimmune Diseases with an establish diagnosis of SLE. We collected data pertaining to: present use of glucocorticoids (CGs), disease-modifying antirheumatic drugs (dMARDs), and of medication which main indication does not pertain to SLE. We also established the present disease activity score of each patient (SLEDAI-2k).

We defined polypharmacy as the use of 3 or more pharmaceuticals, at least 1 of which belonging to the class of dMARDs or GCs

Results

Of the 100 individuals, 94% are female (n=94), with a median age of 56 years old, and average disease duration of 8 years. The simplified distribution of present use of medication is as follows: 85% used dMARDs, 44% used GCs, 23% used SSRIs, 16% used NOACs, 42% used oral antidiabetics and 71% used antihypertensive medication. In this sample, 37% had used some type of antibiotic medication in the last 12 months.

Polypharmacy of 3 or more pharmaceuticals of the previous groups was present in 65% of the individuals. Polypharmacy was present in 66.6% of patients in clinical remission (SLEDAI = 0, n=42/63), 62% of patients with low activity (SLEDAI 1-4, n=18/29) and 62,5% with high activity score (SLEDAI= 4, n=5/8).

Conclusion

The number of individuals subject to polypharmacy is still substantial in a relatively young population. This pattern holds independently of the disease activity score. This study demonstrates the need to review and adapt our therapeutic strategies, in order to reduce and even suspend all the non-necessary pharmacological treatment, in order to avoid increasing the risk of side effects and consequent increased morbidity

#1819 - Medical Image

A PROBABLE CASE OF COMPLEX REGIONAL PAIN SYNDROME

Nuno Pina Gonçalves, Lídia Teixeira, Ricardo Figueira, Mário Rodrigues, Carolina Morna

Hospital Central do Funchal, Funchal, Portugal

Clinical summary

A 56 years old woman presents oligoarthritis of the wrists and right knee, with x-rays showing calcification of the triangular ligaments and the meniscus. She is diagnosed with calcium pyrophosphate deposition disease and treated with colchicine with good response. After four weeks, diffuse and persistent left hand pain ensues, associated with skin redness, edema, hyperhidrosis, functional impairment and allodynia. She is thought to have type I complex regional pain syndrome and hands x-ray are again performed, showing patchy bone demineralization (which supports the diagnosis) but also left hand carpalis with erosions of the metacarpophalangeal joints (against the diagnosis). She is medicated with gabapentin and tramadol and awaits for a bone scintigraphy to help clarify the diagnosis.

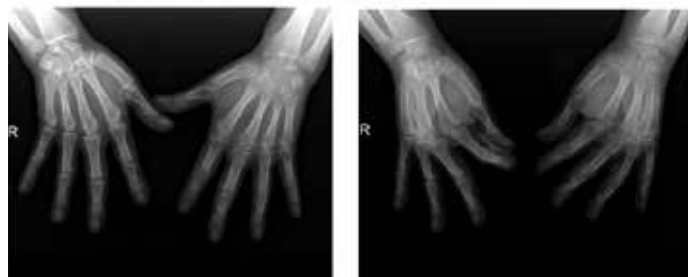
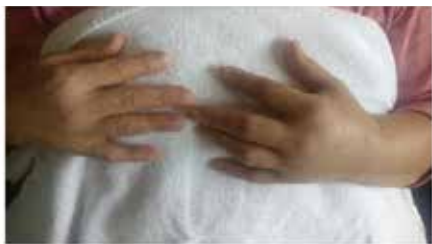
Figure #1819.

#1825 - Case Report

LUNG ADENOCARCINOMA AND POLYARTHRITIS

Nuno Pina Gonçalves, Lídia Teixeira, Ricardo Figueira, Mário Rodrigues

Hospital Central do Funchal, Funchal, Portugal

Introduction

Malignant neoplasms can trigger a set of immune-mediated mechanisms that manifest by the most varied signs and symptoms, called paraneoplastic syndrome (PS). Although rare, paraneoplastic polyarthritis can be one of such syndromes.

Case description

A 53 years old man with a history of chronic smoking and alcohol consumption has a sudden onset of inflammatory polyarthralgia of the knees, elbows and small joints of the hands, associated with weight loss (15 Kg in 3 months), without fever, rash or other symptoms. Medicated with etoricoxib 90mg and pregabalin 75mg id, without response. Observed by Rheumatology after 6 months and admitted due to persistence of polyarthralgia and having new onset of anaemia (haemoglobin 5.4 g/dL). Physical examination showed symmetrical polyarthritis of the knees, elbows and small joints of both hands. Regarding the work-up: laboratorial results showed iron deficiency anaemia, ferritin 3340ng/dL, reactive C protein 199mg/L and erythrocyte sedimentation rate 95mm; bone marrow examination suggestive of an inflammatory state; Immunologic and serologic studies were negative; synovial fluid examination from the left knee with hypercellularity (27840/mm³) without presence of microcrystals; x-rays of the hands, endoscopic studies and thoracoabdominopelvic computed tomography (CT) without any findings; neck CT with an accessory spinal adenopathy on the left side. The patient was given 3 blood units and medicated with sulfasalazine 1g bid, prednisolone 60mg id and iron supplementation. He was evaluated by hematology and otorhinolaryngology and was thought to have chronic disease anaemia without evidence of other causes. Indication for surveillance and imaging re-evaluation is given and the patient is discharged with close follow-up on consultation. After 5 months, polyarthritis gets worse and a left retromandibular mass with 5cm is detected. He is re-admitted, with new CT scans showing a jugulodigastric mass and multiple pulmonary and hepatic nodules. A neck biopsy is performed (positive for adenocarcinoma of the lung) and he is transferred to the oncology ward to initiate chemotherapy, dying after only 2 cycles

Discussion

A sudden onset of symmetrical, seronegative, non-erosive polyarthritis can be a PS. Although more common in leukaemia/lymphomas, lung neoplasms are another known cause. A high index of suspicion is mandatory for the diagnosis of the primary neoplasm since its treatment results in regression of the clinical manifestations.

#1827 - Abstract

EVOLUTION OF NON-INFECTIOUS INTERMEDIATE, POSTERIOR OR PANUVEITIS DEPENDING ON TREATMENT: A RETROSPECTIVE OBSERVATIONAL STUDY

Mathilde Leclercq¹, Vincent Langlois², Nicolas Girszyn¹, Ygal Benhamou¹, Julie Gueudry¹

¹ CHU Charles Nicolle, Rouen, France

² Hôpital Jacques Monod, Le Havre, France

Background

Non-infectious uveitis are a major cause of legal blindness in the developing countries. New monoclonal antibodies, such as anti-TNF alpha, appeared to be effective in intraocular inflammation improvement. However, therapeutics strategies between monoclonal antibodies and disease-modifying antirheumatic drugs (DMARD) have not been yet established.

Methods

The aim of this retrospective study was to describe and compare efficacy and safety of DMARD (methotrexate, mycophenolate mofetil, azathioprine) and monoclonal antibodies (anti-TNF alpha and anti-IL6 agents) in patients with non-infectious intermediate, posterior or panuveitis. We compared the efficacy and safety based on 3 criteria: i) ocular inflammation, ii) relapse rate and iii) corticosteroid sparing.

Results

Among the seventy-nine patients included, 36 were treated with monoclonal antibodies and 39 with DMARD. Demographics characteristics, uveitis etiologies and ophthalmologic features were comparable between the two groups at treatment's beginning. Patients treated with monoclonal antibodies were previously exposed to DMARD and had a longer exposition to corticosteroid ($p=0.03$). Visual acuity was improved in both groups ($p=0.84$). Moreover, both groups showed an improvement of intraocular inflammation ($p=0.89$) and macular edema ($p=0.29$). Relapse occurred in 15 patients treated with monoclonal antibodies (42%) and 19 treated with DMARD (49%) ($p=0.7$). Median time to relapse was 29 months for monoclonal antibodies and 41 months for DMARD ($p=0.77$). There was no difference on corticosteroid sparing ($p=0.26$); 8 patients treated with monoclonal antibodies and 5 in DMARD group had withdrawal corticosteroid treatment. Also, safety was similar between the two groups, 31% patients treated with monoclonal antibodies and 13% in DMARD group developed infectious diseases ($p=0.09$). Two patients in each group developed a cancer. No risk factor was associated with monoclonal antibodies treatment (demographics characteristics, uveitis etiologies, ophthalmologic features at diagnosis).

Conclusion

Our study reveal that monoclonal antibodies are as efficient as DMARD for ocular inflammation, relapse rate and corticosteroid sparing in non-infectious intermediate, posterior or panuveitis.

#1830 - Abstract

PATIENT-REPORTED OUTCOMES AND ITS CORRELATION WITH THE MOST USED CLINICAL INDEXES IN RHEUMATOLOGY: WHEN INFORMATION COLLIDES

Catarina Ambrósio, Paulo Vilas-Boas, Carolina Mazedo, Gisela Eugénio, Anabela Barcelos

Centro Hospitalar Baixo Vouga, Aveiro, Portugal

Background

Patient-Reported Outcomes (PROs) are becoming increasingly relevant nowadays. With pain as the fifth vital sign, the role of pain visual analogue scale (pVAS) in the evaluation of rheumatic patients is of paramount importance. Nevertheless, some issues may arise when the results are in conflict with other disease activity indexes, which are widely used in clinical trials and clinical practice being decisive to the therapeutic choice of each patient. The aim of this work was to evaluate, in a cohort of rheumatic patients, the correlation between pVAS and clinical indexes of disease activity (DAS28-3v and BASDAI) and quality of life ((EuroQol-5D (EQ-5D)) usually used in daily practice.

Methods

A total of 174 patients (80 Rheumatoid Arthritis (RA); 46 Axial Spondyloarthritis (axSpA); 43 peripheral Psoriatic Arthritis (PsA)) were enrolled. Socio-demographic data was collected from patient's clinical records. Disease Activity Score 28 with 3 variables (DAS28-3v) was performed to all RA and PsA patients, while Bath Ankylosing Spondylitis Activity Index (BASDAI) was used in axSpA patients. pVAS and EQ-5D were also performed in all patients.

Results

RA-group had a mean age of 60.4 years, DAS28-3v of 3.01, pVAS of 3.67 and EQ-5D of 7.64. Pearson's correlation test was positively weak for pVAS/DAS28-3v ($\rho = 0.44$) as well for pVAS/ EQ-5D ($\rho = 0.49$), pVAS/age ($\rho = 0.20$) and DAS283v/EQ-5D ($\rho = 0.57$). In the PsA-group, the mean age was 52.1 years, with correlation's results similar to the previous group: pVAS/DAS28-3v ($\rho = 0.11$), pVAS/ EQ-5D ($\rho = 0.60$), pVAS/age ($\rho = 0.11$) and DAS283v/EQ5D ($\rho = 0.43$). Nevertheless, when we analyze axSpA-group (mean age of 43.8 years), we found a strong correlation between pVAS and BASDAI ($\rho = 0.73$), pVAS and EQ-5D ($\rho = 0.73$), and BASDAI and EQ-5D ($\rho = 0.73$). No correlation was found between pVAS and patient's age ($\rho = 0.09$).

Conclusion

In this study, a strong correlation between PROs and clinical indexes was only found in the axSpA-group (as expected, since BASDAI is also a numeric rating scale / VAS dependent index, unlike DAS28-3v). As this discrepancy between PROs and disease activity indexes may have therapeutic clinical implications, it is extremely important to evaluate the need for maintenance / enhance the patient global assessment in these indexes.

#1831 - Abstract

DRUGS USED IN AUTOIMMUNE DISEASE WITH END-STAGE RENAL DISEASE – A TOUGH CHALLENGE FOR THE INTERNIST

Ana Rita Lambelho, Márcia Pacheco, Carina Graça, Joana Milho, Denise Lopes, Ana Pinheiro Sá, José Barata
Hospital Vila Franca de Xira, Vila Franca De Xira, Portugal

Background

Autoimmune disease is often associated with kidney damage and it may also occur in patients with established kidney disease. In this context, its therapeutic approach is conditioned by the alteration of the metabolism of the drugs used, with consequent increased risk of adverse effects and iatrogenesis.

Methods

This review aims to synthesize the pharmacokinetics, dosage and toxicity of the drugs used in autoimmune disease in patients with end-stage renal disease. The reviewed drugs include non-steroidal anti-inflammatory drugs (NSAIDs) and disease-modifying antirheumatic drugs (DMARDs), both conventional and biological agents.

Results

In patients undergoing dialysis, the use of NSAIDs and Methotrexate is absolutely contraindicated. On the other hand, Leflunomide and Cyclosporine can be used without dose reduction, and Leflunomide presents as a first-line DMARD in end-stage renal disease.

There are other DMARDs that can be used with dose reduction on dialysis. In the case of Azathioprine the dose should be reduced by at least 50%. It is also advisable to reduce the dose of mycophenolate mofetil, starting with 250 mg 2 times a day and, in case of tolerance, increase to 500 mg 2 times a day. For cyclophosphamide, the dose should also be reduced by at least 50% and administered after the dialysis session. The maximum dose of sulfasalazine is 500 mg per day.

Most biological DMARDs agents can be used without dose modification. However, biological agents with a molecular weight of <60 kDa (eg anakinra and tofacitinib) are the exception and their dose should be reduced. The drugs that have the best safety profile in renal disease are rituximab and tocilizumab, with a greater experience in its administration.

Conclusion

In patients with renal disease, drug doses should be adjusted to renal function and nephrotoxic drugs should be avoided. Furthermore when renal function degrades it is often necessary to switch drugs because of this, which complicates the management and is a common problem in the follow-up of these patients. In conclusion, an in-depth knowledge of the drugs used in patients undergoing dialysis is necessary to avoid iatrogenesis in this population.

#1834 - Case Report

IGG4 RELATED DISEASE WITH MULTISYSTEM INVOLVEMENT. CASE REPORT.

Marta Mendes Valentim¹, Catarina Moreira Neto¹, Ana Gameiro¹, Aluixa Lozada²

¹ Internal Medicine Department, Hospital Distrital de Santarém, Santarém, Portugal

² Anatomic Pathology Department, Hospital Distrital de Santarém, Santarém, Portugal

Introduction

Immunoglobulin G4-related disease is a fibro-inflammatory condition commonly with multisystem involvement. The authors report a IgG4 related disease with cutaneous, lymphatic, pulmonary, bone marrow and hepatic involvement.

Case description

A 41-year-old male with pruritic skin lesions, diarrhea and jaundice, was diagnostic with a nonspecific granulomatous disease; with extense involvement: cutaneous (leukocytoclastic vasculitis), pulmonary (fibrosis with lymphoplasmacytic and neutrophilic infiltrate), mediastinal lymph nodes (necrotizing lymphadenitis) and bone marrow (granulomatous myelitis) evidenced by the biopsy.

Due to clinical worsening, with onset of abdominal pain and with the following laboratory alterations: cytocholestatics, amylase 382U/L, lipase 890 U/L and inflammatory parameters elevated. A CT body scan were performed showed: "Diffuse thickening of the interlobular septa with micro nodules with centrilobular distribution and thickening of the peribroncovasculares bundle. Large adenopathies in the hepatic hilum, celiac trunk, peripancreatic, lombo-aortic and cardio-phrenic. Slight homogeneous hepatosplenomegaly. The patient was admitted for acute pancreatitis with hepatic failure and coagulopathy, initiating: hydration, Piperacillin-Tazobactam and corticosteroids; with stabilization and normalization of the analytical alterations. Other analytical studies were performed, with evidence of: C4 consumption, polyclonal gammopathy (IgG 2683 mg/dL, IgG1: 1387 mg dL, IgG2: 396 mg/dL, IgG3: 189 mg/dL , Ig G4: 961.3 mg/dL, IgD and IgE), B2 microglobulin elevated, haptoglobin 352 mg/dL, positive cryoglobulins and autoimmune antibody panel negative. Hepatic biopsy was performed shows: moderate chronic hepatitis with mild and focal hepatitis, moderate lobular component with focal necrosis and moderate fibrosis, with morphological alterations compatible with IgG-related hepatitis.

Discussion

The authors present this case due to the difficulty of the differential diagnosis between: IgG4 related disease versus Sarcoidose with an overlap of small-vessel cryoglobulinemic vasculitis. IgG4 related disease is a rare, multisystemic, granulomatous disease of difficult diagnosis for which a high index of clinical suspicion is required.

#1838 - Case Report

GRANULOMATOUS DISEASE: AN UNUSUAL PRESENTATION

Joana Rita Lopes, Rui Files Flores, Maurício Peixoto, Guilherme Alpedrinha, Sofia Caridade
Hospital of Braga, Braga, Portugal

Introduction

Granulomatous diseases include several etiologies ranging from infections to neoplastic and immunologic diseases. Ganglia involvement is common be it localized or in specific ganglia. These findings, alongside other semiologic, analytic, imagiologic and anatomopathological data are essential for definitive diagnosis. We present an enigmatic case of disseminated granulomatous disease.

Case description

53-year old woman, housekeeper, with history of arterial hypertension and dislipidemia, sent to an Internal Medicine consultation for granulomatous disease of the parotid gland. Complaints of a 6 month long localized discomfort linked to a right sided facial tumefaction, with a 2-year history. Patient denied constitutional symptoms and weakness. Denied other systemic or organ related complaints. No history of contact with individuals with tuberculosis. The physical examination showed a dense 100x50 millimeter (mm) right sided facial mass, non adherent to deep muscle planes. No palpable ganglia chains on the head or neck. Blood tests showed elevated angiotensin converting enzyme (ACE 97 U/L) and positive proteinase 3 anti-neutrophil cytoplasmic antibodies (PR3-ANCA). Infectious blood serology and immunologic study was negative. Thoracoabdominal and pelvic computed tomography showed mediastinic, retroperitoneal, inguinal and iliac-obturator chain adenomegalies, relatively symmetrical pulmonary hilum adenomegalies, mesenteric 43 mm mass and hepatic and splenic nodules. Positron emission tomography showed overlapping metabolic activity, also present in bone tissue. No structural anomalies were found on bronchofibroscopy. Direct examination and microbiology for koch bacillus on bronchoalveolar lavage and aspirate was negative. Ultrasonnd guided aspiration puncture of inguinal ganglia showed granulomatous lymphadenitis. The patient was proposed for a therapeutic test with corticotherapy, with clinical outcomes yet to be revealed.

Discussion

We present the case of an asymptomatic patient with an insidious disseminated granulomatous disease, associated with high ACE and positive PR3-ANCA. Based on clinical context and negative blood tests we excluded infectious causes. We excluded presence of neoplastic cells in the parotid gland and inguinal ganglia through histology and bronchoalveolar samples through cytologic testing. With these facts in mind, the therapeutic test with corticotherapy arises as a key factor towards reaching the final diagnosis.

#1845 - Case Report

THE PIECES OF THE PUZZLE

João Olivério Albuquerque Ribeiro, Ana Rita Ferro, Filipa Sousa, Sónia Santos, Eurico Oliveira, António Correia
Centro Hospitalar Tondela-Viseu, Viseu, Portugal

Introduction

One of the richest aspects of Internal Medicine is the research and diagnosis area. It is up to the internist to study the patient, to correlate the several manifestations that, facing the separation of knowledge between the many Medical Specialities, is one of the noble aspects of the Internal Medicine Speciality. The present case is an example of the complexity of a patient, that could have gone under the radar for a long period, had it not crossed with the Internal Medicine.

Case description

The patient attends a basic emergency department, due to a painful edema and erythema of the lower limbs, without fever and 5 days of evolution. It was assumed to be a cellulitis, and amoxicillin-clavulanate and Ibuprofen was prescribed. The lesions progressed, with the association of nodules, and expanding to the upper limbs, motivating another emergency episode. There was a relative neutrophilia and elevation of the CRP, without leucocytosis. There was also apparent a hilar growth on a thorax X-ray. Due to suspicion of Nodous erythema the patient initiated corticotherapy, being oriented to an Internal Medicine consult with new blood samples and a CT-Scan.

One month later, the patient returns to the emergency department due to right omalgia and bilateral hip pain. There was no evidence of infection or traumatism, and the patient was admitted, maintaining the corticotherapy, with improvement of the situation. He was discharged keeping the orientation to the consult.

Facing the improvement of the clinical situation, weaning of the corticoids was started, with a new relapse of the erythema, motivating a new access to the emergencies, but already with the results of the CT-scan, that revealed several paratracheal and subcarinal ganglionar formations.

In this context it was possible to gather the pieces, associating the nodous erythema with the arthritis and the adenopathies, the diagnosis of Loeffgren Syndrome was achieved, and the patient remains being followed in the Internal Medicine Consult.

Discussion

The present case shows, in sequence, the isolated manifestations that define the Loeffgren Syndrome, manifesting themselves individually. Initially the Nodous erythema, to which was posteriorly added the acute arthritis and finally, through the complementary study, the evidence of adenopathies. The importance of the patient's holistic evaluation is highlighted, with the necessity of association of the several signs and symptoms.

#1855 - Case Report

A STRANGE CASE OF DISSEMINATED SUBCUTANEOUS NODULES

Ricardo Ambrosio Rodrigues¹, Rui Nogueira², Rafael Silva³, José Carlos⁴, João Rocha Gonçalves³, Dilva Silva³, Jorge Fortuna³, Armando Carvalho³

¹ Department of Internal Medicine, Coimbra Hospital and University Center, Lisboa, Portugal

² Department of Nephrology, Coimbra Hospital and University Center, Coimbra, Portugal

³ Department of Internal Medicine, Coimbra Hospital and University Center, Coimbra, Portugal

⁴ Department of Dermatology, Coimbra Hospital and University Center, Coimbra, Portugal

Introduction

Lupus panniculitis (LP) is an unusual form of cutaneous lupus, rarely described as the first presentation of systemic lupus erythematosus, it usually presents as subcutaneous nodules or plaques. Antimalarial drugs are first line treatment options. Systemic corticosteroids are also commonly employed and show good results, particularly in the presence of systemic lupus erythematosus.

Case description

A 35-year-old women present with multiple erythematous subcutaneous painful nodules, initially restricted to her arms and with a migrant rhythm. Two months later the number of nodules increased exponentially and started affecting other parts of her body, associated with severe asthenia and arthralgias with inflammatory rhythm.

The nodules had a progressive evolution, starting as indurated plaques that would become warm and tender as time went on, followed by hardening and fibrosis. At the end there would be scarring of the dermis, with skin deformation, being this the main complaint of the patient. Different nodules presented themselves at different stages.

Initial empirical treatment with nonsteroidal anti-inflammatory drugs proved unsuccessful.

Blood work showed leukopenia with neutropenia, a positive titer for ANA with a positive anti-SSA. Nodule biopsy showed inflammatory infiltrate compatible with lupus panniculitis.

Initial treatment with hydroxychloroquine and prednisolone proved unsuccessful and control was finally achieved with topical tacrolimus, chloroquine and prednisolone, after several different treatment regimens were attempted including methotrexate.

Discussion

This case illustrates a rare first manifestation of SLE, with a challenging diagnosis. Lupus panniculitis is by itself a rare cutaneous manifestation of SLE even more so as the presenting manifestation. It also illustrates the challenge in achieving a stable treatment regiment.

#1856 - Case Report

STATUS INFLAMATIONE - CARDINAL SIGNS OF INFLAMMATION AND A SYSTEMIC PRESENTATION

Maria Sousa Uva, Mariana Lessa Simões, Pedro Alves Silva, Viorela Bianca Cristea, Luis Brito-Avô, Luiz Menezes Falcão
Hospital de Santa Maria, Lisbon, Portugal

Introduction

Crowned Dens Syndrome (CDS) is a rare syndrome, characterized by severe acute or recurrent axial neck pain, neck and shoulder stiffness, and associated fever. It is caused by calcium phosphate crystal deposition in and around the atlanto-axial articulation. Being a benign entity with a good prognosis when diagnosed and treated early, failure to do so can lead to paraparesis and, in more severe cases, death.

Case description

A 74 year old caucasian male presented to accident and emergency with a 7 day history of shortness of breath, fatigue and tachypnoea. 2 days prior to this presentation, he was prescribed amoxicillin/clavulanate and azithromycin for a suspected lower respiratory tract infection.

He was known to have hypertension, type 2 diabetes, atrial fibrillation, aortic stenosis, 100 pack year history of smoking and marked active alcohol consumption.

On examination, he was very agitated and acutely disorientated. He was haemodynamically stable, afebrile. On auscultation he had widespread bilateral pulmonary crackles. His left knee was oedematous, inflamed, painful and with crepitations on active movement. He had neck stiffness and severe pain on rotation, flexion and extension of the neck. Kernig and brudzinski were negative. The remaining physical examination was otherwise normal.

Blood tests showed 21,200 leucocytes with 16,300 neutrophils. C-reactive protein was 31.8 mg/dL with an elevated erythrocyte sedimentation rate of 120 mm. Uric acid was normal.

Arthrocentesis of the left knee revealed birefringent intracellular crystals compatible with calcium pyrophosphate, and diagnosis of pseudo-gout of the knee was made. We requested plain joint radiographs, and a computer tomography (CT) of the cervical, thoracic and lumbar spine. The CT revealed calcium pyrophosphate crystal deposition of the odontoid process, giving us the diagnosis of CDS. The patient was started on colchicine 1mg TDS, and was asymptomatic and afebrile 48h after initiating treatment.

A repeat CT scan 3 months after discharge showed complete regression, and a crystal-free odontoid process. The patient remains asymptomatic.

Discussion

The importance of recognising CDS lies in the resemblance of its symptoms and signs with those of meningitis, cervical discitis, temporal arteritis or polymyalgia rheumatica. The relatively benign course of the illness with prompt diagnosis and treatment

further accentuates the need to raise awareness of this syndrome when approaching a patient with neck pain or stiffness.

#1861 - Case Report

CUTANEOUS POLYARTERITIS NODOSA. CASE REPORT

Marta Mendes Valentim¹, Catarina Moreira Neto¹, Ana Gameiro¹, Aluixa Lozada²

¹ Internal Medicine Department, Hospital Distrital de Santarém, Santarém, Portugal

² Anatomic Pathology Department, Hospital Distrital de Santarém, Santarém, Portugal

Introduction

Cutaneous Polyarteritis nodosa (CPAN) is a rare, benign and unknown etiology form of vasculitis relating to small or medium sized arteries. Clinically manifested with: subcutaneous nodules, livedo reticularis, cutaneous ulcers or even necrosis. It is distinct from the systemic form by lack of extracutaneous involvement. The authors present a case report of a CPAN.

Case description

A 76-year old man, with history of hypertension and post-hemicolectomy status (polypoid villous tumor); was admitted due to fever accompanied by skin lesions and elevation of inflammatory parameters. The patient referred also an upper respiratory infection autolimited, 1 week ago. On the physical examination evidence of nodular cutaneous lesions suggestive of erythema nodosum with bilateral petechial border predominantly on the anterolateral side of the legs, but also on the abdomen, forearms and hands. He also presented inflammatory signs in the left knee without apparent joint effusion. From the initial analytical study, neutrophil-labeled leukocytosis, elevated CRP and increased levels of anti-streptolysin O titre, were evidenced.

Ceftriaxone and clindamycin were started. Poor evolution at the third day with worsening of the cutaneous clinic and with elevation of inflammatory parameters as well as functional impotence of the left knee associated with lymphangitis on the left leg; antibiotic therapy was changed to piperacillin-tazobactam assuming a septic arthritis. The study was complemented with the performance of the biopsy of the skin lesions, with evidence of septal panniculitis with vasculitis. Because of suspicion of a multisystemic PAN involvement, body TC scan and angio-TC scan were performed: without any pathological alterations. Temporal biopsy were performed without evidence of inflammation. Prednisone 60 mg per day was initiated, with a good clinical response and analytical normalization.

Discussion

The authors present a cPAN case with arthritis, a rare and benign cutaneous vasculitis, with a distinct course from systemic PAN. There are several criteria to make the differential diagnosis between these two entities that should be known; cause the prognostic, the severity and the evolution of both are different.

#1916 - Case Report

MANIA AS THE FIRST MANIFESTATION OF GRANULOMATOSIS WITH POLYANGIITIS

Ana Vera Cruz, Maria Maragarida Pereira, Marta Cerol, Ricardo Gasparinho, Petra M. Pego

Hospital de Santarém, Santarém, Portugal

Introduction

Granulomatosis with polyangiitis (GPA) is a small-vessel vasculitis that occurs most commonly in white older adults, affecting both sexes equally.

It causes granulomata and vasculitic lesions predominantly in upper respiratory tract, lungs and kidney. Patients may present with constitutional symptoms, arthralgia, upper and lower respiratory symptoms, urinary abnormalities, purpura and neurologic dysfunction. Peripheral nerves are more often involved than central nervous structures.

Case description

A 42-year-old man with type 2 diabetes, without previous psychiatric history was admitted as an inpatient to a psychiatric ward for a first manic episode with psychotic symptoms (grandiose, persecutory and erotomaniac delusions) not fully consistent with a psychiatric disorder and resistant to drug therapy. At the second day in he presents with cough and rhinorrhea. An initial chest radiograph showed bilateral pulmonary nodules. A chest computerized tomography (CT) scan revealed multiple nodular lesions in both lungs.

Percutaneous CT guided pulmonary biopsy was performed. Histology was compatible with granulomatous disease and vasculitis affecting small and medium vessels.

Magnetic resonance imaging of the brain showed central nervous system vasculitis.

When questioned referred polyarthralgias with inflammatory rhythm with 15 year evolution course affecting coxofemoral, wrists and metacarpophalangeal joints bilaterally. Involvement of other organs was excluded.

The diagnosis of GPA was established and prednisolone and cyclophosphamide were initiated with an improvement of both systemic and psychiatric symptoms.

Discussion

Acute psychiatric symptoms are a rare form of presentation of GPA. The only way to treat this patient in the proper way was to look further than the obvious, identifying other symptoms that acted as "red flags" leading to the final diagnosis.

This case raises awareness for the possibility of psychiatric manifestations of autoimmune diseases that may go unnoticed and emphasizes the importance of multidisciplinary approach to systemic diseases.

#1921 - Case Report

CASE REPORT OF KAWASAKI DISEASE IN 16-YEARS-OLD GIRL

Daniel Monge Monge, Alba Varela García, Ana Suero Roiz, Rodrigo Martínez Prado, Paula Goicoechea Núñez, Samuel Puente Fernández, Eva Ferreira Pasos

General Hospital of Segovia, Segovia, Spain

Introduction

Kawasaki disease is an acute, self-limited febrile illness of unknown cause that predominantly affects children < 5 years of age. The diagnosis is based on the identification of principal clinical findings and the exclusion of other clinically similar entities.

Case description

A 16-years-old girl presents to the emergency department for fever up to 39°C, arthralgias, two episodes of bilious vomiting. She also had headache and erythema in trunk and extremities.

She had as the only antecedent helicobacter pylori infection three years ago. She reported no drug allergies. No contacts with similar symptoms were identified. She had not travelled recently. She denied using drugs. She had not taken any medication. She has not had sexual relationships. She had no animal exposure.

In the initial evaluation, her temperature was 38.6°C, blood pressure at 88/60mmHg, pulse was measured at 130 beats per minute and blood oxygen saturation at 100%. A physical examination revealed diffuse maculopapular eruption in trunk and legs, erythema on the cheeks, conjunctival injection, cervical and supraclavicular non pathological adenopathies.

The laboratory findings revealed leukocytosis 12,018/mm³ with neutrophilia, normocytic normochromic anemia, prothrombin activity 59%, metabolic acidemia, elevation bilirubin levels 3.5 mg/dl, PCR 25 md/dl, procalcitonin 2.22. She initially was treated with broad spectrum antibiotics with no response.

On the third day at her hospital admission she started with cough and sore throat, edema on the hands and strawberry tongue.

All serology requested for Epstein barr virus, HIV, herpes virus, cytomegalovirus, and other viral infections were negative, as well as serology for atypical respiratory pathogens, and also serology for rickettsial infections. Blood, urinary and throat cultures were also negatives. All blood tests for autoimmune diseases were negative. In this case of persistent fever, other differential diagnoses were considered. At this point we suspected KD, and she was given IVIG and aspirine with great improvement and disappearance of fever. Echocardiogram was normal.

Discussion

Our differential diagnosis was made with mainly infective and autoimmune diseases and they could not prove and we established the diagnosis of KD because could explain all her symptom, and the clinical criteria for KD are met.

#1922 - Case Report

GLOMERULONEFRITE PAUCIIMMUNE: A CLINICAL CASE

Inês Gonçalves, Laura Costa, Filipa Pinho, Camila Oliveira, Francisco Gonçalves, Luisa Pinto, António Silva
Hospital de Braga, Braga, Portugal

Introduction

Systemic vasculitis is characterized by inflammation and necrosis of blood vessels. The kidney is often affected, especially by small vessels vasculitis. Among these, forms associated with anti-neutrophil cytoplasmic antibodies (ANCA) present as crescentic glomerulonephritis with necrosis, without deposits of immunocomplexes.

Case description

We report the case of a 59-year-old, female, patient who was referred to the emergency department for lower limb edema, increased abdominal perimeter and decreased diuresis. She had no other complaints and no recent drug onset. Referring to a personal history of chronic alcoholic liver disease. From the physical examination, ascites, edema and a petechial rash of the lower limbs stood out. The patient had an acute renal injury (creatinine 4.3 mg/dl, urea 80 mg/dl), decreased albumin (2.8 g/dl), compensated metabolic acidosis, without hepatic cytolysis or cholestasis. Urine type II with erythrocytes. Abdominal and pelvic ultrasound showed a distorted liver, with a heterogeneous aspect, furthermore large volume ascites and kidneys with loss of parenchymal-sinusal differentiation. The patient was hospitalized for investigation and as a differential diagnosis, it was considered a pre-renal (hepatorenal syndrome) and renal intrinsic (pathology of vessels, glomeruli or tubules) cause.

In the study, ANCA-MPO positive (643.8 U/ml) was identified, without consumption of complement, elevation of the circulating immunocomplexes, or alterations in the protein electrophoresis. A urine study was repeated, which revealed proteinuria (1 g in 24 hours) and maintenance of erythrocytes, without cylinders. He performed a renal biopsy that was compatible with pauci-immune necrotizing glomerulonephritis. He initiated pulses of methylprednisolone 1g, followed by prednisolone 1mg/kg/day and cyclophosphamide. During hospitalization, the patient maintained diuresis and did not need renal replacement therapy. With the therapy, she presented an improvement of the renal function and continued follow-up in consultation of internal medicine and nephrology.

Discussion

Vasculitis of small vessels should be considered in the diagnosis of acute renal injury since the early initiation of treatment is associated with a better prognosis.

#1951 - Medical Image

TAKAYASU ARTERITIS

Elsa Meireles, Mafalda Mourisco, Manuela Alves

Centro Hospitalar De Entre o Douro e Vouga, Santa Maria Da Feira, Portugal

Clinical summary

A previously healthy 42-year-old woman presented with constitutional symptoms, fever and blood pressure that was difficult to control. The laboratory results showed anaemia of chronic inflammation, elevated erythrocyte sedimentation and C reactive protein levels. Large vessel arteritis was the most probable aetiological diagnosis that was diagnostic by PET with FDG. MRA revealed a completely stenosis of the internal carotid. The patient began receiving immunosuppressive therapy with prednisolone and methotrexate, and the blood pressure gradually decreased to below 130/70 mmHg. Takayasu's arteritis is a form of vasculitis that chiefly affects the aorta and its major branches in young women. Vascular stenosis may progress silently, owing to the development of collateral circulation.

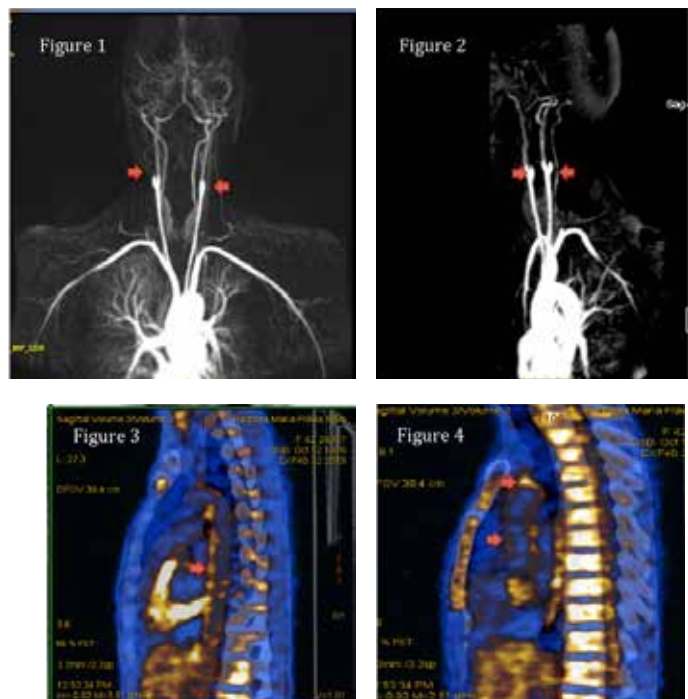


Figure #1951. Panel 1 and 2: MR angiography showed thickening and narrowing of common carotid artery and bilateral occlusion (arrows) of the internal carotids. Panel 3 and 4: whole body positron emission tomographic (PET) scan shows increased ^{18}F -FDG uptake in the ascending aorta in the aortic arch and descending aorta (arrows).

#1961 - Abstract

CLINICAL PARAMETERS THAT ARE ASSOCIATED WITH A HIGHER CHANCE OF AXIAL SPONDYLOARTHRITIS IN PATIENTS WITH INFLAMMATORY BOWEL DISEASEElena Belousova¹, Alfiya Odintsova², Diana Abdulganieva¹, Mikhail Protopopov³¹ Kazan State Medical University, Kazan, Russia² Republican Clinical Hospital, Kazan, Russia³ Charité Universitätsmedizin, Berlin, Germany**Background**

Spondyloarthritis (SpA) is the most common extraintestinal manifestation (EIM) of IBD, affecting up to 40% of patients. Diagnostics and management of patients with IBD and SpA are challenging. In this study, we aimed to assess factors associated with a higher chance of axial SpA in patients with IBD.

Methods

The observational cross-sectional study included 91 patients with a definite diagnosis of IBD and chronic back pain (duration > 3 months): ulcerative colitis (UC) - 52 (57.1%), Crohn's disease (CD) - 39 (42.9%). Males - 47 (51.6%), mean age - 40.2 ± 11.7 years, duration of IBD - 7.7 ± 7.6 years. Inflammatory back pain (IBP) was classified according to ASAS criteria (2009). If SpA was suspected, patients underwent X-ray and/or MRI of sacroiliac joints. The SpA was diagnosed according to ECCO recommendations. All patients diagnosed with SpA also fulfilled ASAS criteria for axial SpA. Univariate logistic regression analysis was performed to assess the factors associated with a higher risk of the presence of axial SpA.

Results

IBP was present in 39 (42.9%) patients with IBD. A total of 26 (28.6%) patients were diagnosed with axial SpA, among them 14 (15.4%) patients with radiographic axial SpA. In the univariate logistic regression model 4 factors were associated with a higher chance of SpA diagnosis: arthritis - OR 10.77 [95% CI 2.26-44.2], arthralgia - OR 4.12 [95% CI 1.55-10.95], IBP - OR 8.07 [95% CI 2.80-23.23], uveitis - OR 19.2 [95% CI 2.18-169.13]. Patients with CD have a higher chance of axial SpA diagnosis - OR 2.92 [95% CI 1.14 - 7.48] compared to UC.

Conclusion

A higher chance of axial SpA was associated with the presence of arthralgia, arthritis, IBD, uveitis and diagnosis of CD.

#1969 - Medical Image

RHEUMATOID HAND

Sónia Coelho, Catarina Dionísio, Clara Jorge, Pedro Carlos, Rita Silva, Carla Gonçalves, Leopoldina Vicente
Centro Hospitalar Universitário Cova da Beira, Covilhã, Portugal

Clinical summary

A 47-year-old woman was admitted to the hospital for evaluation of ascites. She was diagnosed with peritoneal carcinomatosis from recurrent left ovarian cancer. Her medical history included chronic hepatitis C, hyperthyroidism and rheumatoid arthritis, which was diagnosed 16 years before and left untreated for 15 years. Currently she was taking hydroxychloroquine 200 mg/day and prednisolone 5 mg/day. On examination, she presented with a swan neck deformity (hyperextension of the proximal interphalangeal joint and flexion of the distal interphalangeal joint) of the second to fifth fingers of both hands and a duckbill or Z-thumb deformity (hyperextension of the interphalangeal joint of the thumb with flexion of the metacarpophalangeal joint) affecting the left thumb.

#1970 - Abstract

HOSPITALIZATION FOR IVIG THERAPY

Catarina Nazário Marouço, Diogo Drummond Borges, Ema Leal, Inês Figueiredo, Marília Fernandes, Ana Taulaigo, André Teixeira, Margarida Antunes, Filipa Lourenço, Ana Lladó, Sara Guerreiro Castro, Heidi Gruner, António Panarra
Hospital Curry Cabral, Lisboa, Portugal

Background

The clinical use of intravenous immunoglobulin (IVIG) has been successful in a wide range of autoimmune and inflammatory diseases, usually as a steroid-sparing agent and rarely as a first-line therapy. Its use is limited to only a few selected patients, due to its high cost, finite supply and the need for infusions in consecutive days, which is time consuming for patients.

Methods

The authors carried out a retrospective evaluation of the clinical records of all patients admitted to the Internal Medicine ward during a 63-month period (from January 2014 to March 2019), who were treated with IVIG. The patients were characterized according to age, gender, ethnicity, length of stay, the reason for IVIG administration, the number of administrations and clinical outcome.

Results

Twenty-two hospitalizations, comprising 18 individual patients were included, with an average age of 45,1 years (minimum age of 19 and maximum of 78 years), an average length of stay of 15,45 days and a mortality of 22.2% (median age 36,6 years). The cause for IVIG treatment was Autoimmune Thrombocytopenia in

4 hospitalizations (1 of which was a readmission), Autoimmune hemolytic anemia in 3, Systemic Lupus Erythematosus in 3 (1 case of pericarditis and 2 cases of nephritis), Dermatomyositis in 9 (4 of which were readmissions in a patient with paraneoplastic dermatomyositis), Behçet in 1 and Antisynthetase Syndrome in 1. In 1 case there was not a final diagnosis as the patient died early in the diagnostic course. IVIG was administered in average for 5 days. Besides IVIG, all patients received concomitant treatment with corticosteroids in varying dosages. Apart from the 4 patients who died, all patients improved significantly in their clinical status, as assessed by their assistant physician during the hospital stay.

Conclusion

The patients were admitted not because of the administration of IVIG, as it can be done in the Outpatient Clinic, but due to a significant worsening of their clinical status. IVIG is an alternative to other available therapeutic agents in some conditions or in patients with concomitant neoplastic conditions in which the use of other immunosuppressants is contraindicated.

#1976 - Case Report

ANTIPHOSPHOLIPID SYNDROME AN ENTITY TO CONSIDER IN CARDIOVASCULAR EVENTS

João Araújo, André Pinto, Mariana Guerra, Rita Fideles, Munica Costa, Ivone Barracha, Rosa Amorim
Centro Hospitalar do Oeste - Unidade de Torres Vedras, Torres Vedras, Portugal

Introduction

Antiphospholipid syndrome (APS) is an acquired autoimmune disease of blood coagulation. It manifests as recurrent venous and arterial thrombosis, as well as pregnancy-related complications such as miscarriage and stillbirth. The diagnostic criteria require one clinical event and positivity for two antibody blood tests confirming the presence of either lupus anticoagulant or anti- β 2-glycoprotein-I.

Case description

The authors present a case report of a 50 years old male which recurred at the Emergency with an episode of syncope with head trauma. He had a medical history of hypertension, hyperlipidemia and myocardial infarction in the previous 5 months with PCI. At the physical exam the patient presented Glasgow score 15, eupneic, SpO₂: 98%, BP: 106/68 mmHg, HR: 85bpm. Afebrile. Cardiopulmonary Auscultation: with no relevant alterations. Neurologic exam without any relevant abnormality. Normal arterial blood gas analyses. ECG with sinus rhythm, without other alterations. Blood sample with normal hemogram, without leucocytosis, neutrophilia, CRP or myocardial necrosis factors. D-Dimers 768 ng/mL. Head CT with right frontal intraparenchymatous hemorrhage with 39 mm, incipient peripheral edema. To exclude other causes of syncope, it was performed Angio CT of Thorax, Abdomen and Pelvis which was

unreliable of Pulmonary Embolism, later confirmed by Ventilation Perfusion Lung Scintigraphy, and that also revealed abdominal aortic stenosis. An Eco Doppler of arteries and veins of lower limbs was performed and revealed arterial stenosis and occlusion. During the internment he was tested for lupus anticoagulant which presented positive, anti- β 2-glycoprotein-I, anti-cardiolipin antibodies, factor V Leiden and prothrombin G20210A which presented all negatives. It was also performed tests for sexual transmitted diseases, all of them with negative results.

Discussion

Patient was dismissed from the hospital with only antiplatelet drug therapy due to the persistence of intracranial hemorrhage in the control head CT and maintained follow-up in Internal Medicine consultation for further institution of hypocoagulation therapy. It was confirmed APS with other positive lupus anticoagulant 1 month after hospital discharge.

The APS is a medical entity that should be equated in the differential diagnosis in every patient that presents with venous and arterial signs of thrombosis. Its early treatment can prevent major adverse outcomes that can compromise the life of a patient or create serious life disabilities.

#1981 - Case Report

VASCULITIS IN THE ELDERLY

Cláudia Amorim Costa¹, Maria Rato², Fernando Nogueira², Pedro Ribeiro Soares², Frederico Rajão Martins², José Marques², Bruno Bésteiro², Isabel Camões², Jorge Almeida²

¹ IPO de Coimbra, Coimbra, Portugal

² CHUSJ, Porto, Portugal

Introduction

Vasculitis is defined by the presence of vascular lesion with vessel's damage, bleeding and obstruction, conducting to tissue's ischemia and necrosis, induced by the inflammatory response. It's a severe disease that needs a quick diagnosis and medical intervention, as it can be fatal. This clinical case shows the necessity of a high degree of suspicion, the diagnostic complexity and the need of a clinician's holistic approach.

Case description

Eighty five years old female patient, with hypertension and dyslipidemia, admitted in the ward due to constitutional symptoms associated with lower limbs edema and productive cough for several months, worsening in the last 2 weeks. On physical examination: skin pallor, hypotension, tachycardia, basal crackles on pulmonary auscultation and peripheral edema. Analysis showed type 1 respiratory failure, normocytic/normochromic anemia, iron deficiency, elevated sedimentation rate, positive ANCA-MPO, acute kidney injury and urinalysis showed leukoeritrocyturia and mild proteinuria. EKG showed de novo atrial fibrillation. Thorax radiography showed bilateral infiltrations and thorax CT showed extensive alveolar patches, suggestive of alveolar hemorrhage.

Fibroscopy presented bright red blood with dispersed clots and the bronchoalveolar lavage (BAL) was negative for BK and it was isolated E. coli and K. pneumonia. It was assumed lung-kidney syndrome – ANCA-MPO positive vasculitis. The patient was treated with 3 pulses of methylprednisolone followed by prednisolone, plasmapheresis and cyclophosphamide. It was initiated prophylaxis with sulfamethoxazole and trimethoprim and antibiotics directed at the BAL isolates. The patient kept hemodynamically stable, without hemoptysis. Due to the hypoxemic respiratory failure, needing oxygen at 45-50%, it was carried out a computed tomography angiography that showed a pulmonary thromboembolism in the upper and middle lobes of the right lung and in the inferior left lung; the echocardiogram appeared without evidence of right ventricle overload; the lower limbs echodoppler showed no evidence of deep venous thrombosis. Despite the vascular pulmonary involvement, it was initiated hypocoagulation with unfractionated heparin, with progressive improvement of the hypoxemia

Discussion

Lung-kidney syndrome is associated with high morbidity and mortality, mostly due to alveolar hemorrhage and immunosuppression, what is particularly problematic in the elder patients, as we can observe by the complexity of this case.

#2002 - Abstract

THE BREATHING IN CHRONIC RHEUMATOID DISEASES

Haifa Hajji, Maroua Slouma, Rim Dhahri, Leila Metoui, Najah Boussetta, Nourhoda Guediche, Faïda Ajili, Imen Gharsallah, Bassem Louzir

Hopital Militaire de Tunis, Tunis, Tunisia

Background

Respiratory involvement is a frequent extra-articular manifestation in chronic rheumatoid diseases (CRD) and it has polymorphic clinical manifestations.

Methods

The study included patients diagnosed with rheumatoid arthritis (RA) according to 2010 ACR/EULAR criteria and those with Spondyloarthritis (AS) according to the ASSAS Criteria. This study included 159 patients divided in two groups: 91 patients with RA and 68 patients with AS. Disease activity was measured by DAS28-ESR (RA) and BASDAI (SA). To diagnose pulmonary involvement we used: X-ray, high-resolution computerized tomography (HRCT) and pulmonary function testing (PFT).

Results

The mean age was 48.235 years. The sex ratio M/F was 0.76. The average disease duration was 103.77 months. Smoking was noted in 46 cases. The patients were under methotrexate (n=102), biological treatments (n=62) and steroid (n=101). Mean DAS28-

ESR score for patients with RA was 5.1. Mean BASDAI score was 4.95. The mean C-reactive protein and Erythrocyte sedimentation rate was 30.48 mg/l and 41.03 mm/1h.

Among the 159 patients, lung involvement was noted in 23.27% cases (n=37): 24 RA and 13 AS.

Twenty nine patients were asymptomatic. The most frequent symptoms were: cough in 2 cases and dyspnea in 6 cases. Chest X-rays were abnormal in 28 cases (21RA, 7SA) showing: a reticular and linear opacification (5cases), pleural effusion (2cases), interstitial syndrome (20cases) and pulmonary nodule (1case). HRCT revealed pulmonary damages in 24 cases: airway disease with areas of mosaic perfusion and bronchiolectasis (n=1), ground-glass opacities (n=1), emphysema (n=1), nodular lung disease (n=8), interstitial pneumonitis (n=8), bronchiolitis (n=5) and pleural effusion (n=1). PFT showed a restrictive process in 10 cases and an obstructive process in 3 cases.

In patients with RA, disease activity score (DAS28-ESR) was higher in patients with pulmonary involvement (5.65 vs 4.85, p=0.015). The existence of inflammatory syndrome was more frequent in patients who had lung manifestations (69% vs 42%, p=0.084).

Conclusion

Pulmonary involvement in patients with chronic rheumatoid diseases is not uncommon. It may occur at any time of the disease progression. Our study highlighted the effect of disease activity on lung involvement, and showed that inflammatory markers may have a relevant effect on pulmonary function.

#2006 - Case Report

AN ATYPICAL AND ACUTE ONSET OF MIXED CONNECTIVE TISSUE DISEASE AFTER CHILD DELIVERY: A CASE REPORT

Eduardo Rios Lasso, Hans-Jörg Meier-Willersen, Fikret Düzgün
Hospital Sankt Vincentius, Speyer, Germany

Introduction

Mixed connective tissue disease (MCTD) is a rare autoimmune disease of unknown etiology which shows clinical signs of systemic lupus erythematosus, scleroderma, and Polymyositis. It usually starts at the age of 15 to 25 but can occur at any age being more common in females. Typical is the presence of high level of anti-U1-RNP Antibodies.

Case description

We present a case of a 28-year-old female who developed nausea, vomiting, and diarrhea two days after the delivery of her first child through C-Section. Pregnancy was normal. Symptoms were initially seen as gastroenteritis. After three weeks of being treated symptomatically, she came to our Hospital. Tests for an infectious cause in stools were negative. By admission, she was cardiopulmonary stable and had pain in all extremities and edema in both hands in addition to all the other symptoms. Blood test results showed high LDH 323 U/L (normal < 250 U/L) and CRP

2.27 mg/dl (normal < 0.05 mg/dl). The echocardiography showed a pericardial effusion, the abdominal ultrasound a wall thickening of the entire small intestine with ascites. The MRI Sellink confirmed the abdominal sonographic findings, and with an Ileocolonoscopy and Gastroscopy, a chronic inflammatory bowel disease was ruled out.

Under the presumption of an autoimmune disease, ANA and ANCA were tested. Titers for ANA were 1:5120. It was decided to treat with steroids 250 mg i.v., per day. Shortly thereafter diarrhea, nausea, and vomiting disappeared. However, the patient still developed hydronephrosis in both kidneys and dysphagia. As a follow-up, the ANA Profile 3 was tested using the original blood sample. Nucleosome, Histone, Anti-Sm, dsDNA and anti-U1-RNP were positive. Based on these findings we diagnosed the mixed connective tissue disease. We started an immunosuppression therapy with cyclophosphamide according to the Euro-Lupus scheme with a total of 6 Cycles. The dose of steroids was gradually reduced. Cyclophosphamide was well tolerated. Within the first weeks, all symptoms including Hydronephrosis entirely disappeared. After cyclophosphamide we started maintenance therapy with azathioprine.

Discussion

Although a trigger is not known, we know that several autoimmune diseases manifest after pregnancy. There is no standard therapy for this condition. It is treated with steroids and immunosuppressive drugs. The aim of this case report is to provide more details to support the development of clear scientific guidelines helping doctors to manage this disease.

#2011 - Case Report

A SURPRISING CAUSE OF POLYADENOPATHY WHILE ON BIOLOGIC THERAPY

Adina Ciucu, Tabita Lungu, Gabriela Voicu, Gabriela Udrea
Dr.I.Cantacuzino Clinical Hospital, Bucharest, Romania

Introduction

The age of innovation in rheumatology definitely began in 1990 with the development of the first anti-tumor necrosis factor therapy and the following discovery of other biologic drugs. With no doubt, these new molecules have transformed the treatment of inflammatory diseases for millions of people. However, the mechanism by which these drugs work are still not fully understood and the complications of their administration are still being discovered.

Case description

We present the case of a 47 years old male patient, diagnosed with ankylosing spondylitis more than a decade ago, for which he had been receiving anti-tumor necrosis factor alpha therapy for the last 8 years. He came to his follow-up appointment complaining of loss of appetite, important weight loss, fever and productive cough for about 2 months.

The administration of the biologic agent was stopped immediately, the main concern being tuberculosis, as our country is an endemic one.

Clinical examination revealed only some bibasal lung crackles and tachycardia. Laboratory results showed normochromic normocytic anemia, leukopenia, moderate elevated acute phase reactants and high levels of lactate dehydrogenase.

On chest radiography multiple basal bilateral micronodules were visible, while the ultrasonography and the following computed tomography showed multiple profound adenopathies and moderate hepatosplenomegaly.

The anatomopathology report of one adenopathy revealed a large cell lymphoma aspect, so the patient was readmitted in order to start the treatment. During the formalities the patient became aggressive, a medical incident took place—a nurse was injured so the patient was tested for any transmissible infectious diseases. The HIV test came back positive, and the CD4 cell count was 3/mm³. The antiretroviral therapy was started immediately but with no success, the patient dying within weeks from the diagnosis.

Discussion

Biologic agents are important innovative drugs leading to dramatic improvements in patients care, while being extremely complex. For that reason, their administration should always require careful assessment of the immunosuppression status, not only at therapy initialization but during its course as well.

#2030 - Case Report

CELIAC DISEASE DURING PREGNANCY - AN UNDERESTIMATED DIAGNOSIS

Cátia Da Cruz Correia^{1,2}, Ana Alves Oliveira¹, Maria Augusta Borges²

¹ Hospital Distrital de Santarém EPE, Santarém, Portugal

² Centro Hospitalar Lisboa Central - Maternidade Alfredo da Costa, Lisboa, Portugal

Introduction

Celiac disease (CD) is an immune-mediated disorder, where the ingestion of gluten proteins induces T-cell mediated inflammation in the small-bowel and an autoimmune response to self-proteins. This disorder has been associated with fertility problems and worse pregnancy outcomes. Women with infertility have 3.5 times higher odds of having CD. There is also an association with miscarriages and premature delivery.

Case description

Case 1

A 43 years old woman with antiphospholipid syndrome with obstetric complications (one fetal death and one severe fetal growth restriction with pre-eclampsia) develops low ferritin levels. Further studies showed positive IgA anti-transglutaminase antibodies (ATA) and anti-gliadin antibodies (AGA). A duodenal biopsy confirmed the diagnosis of CD and started a gluten-free diet. On the third spontaneous

pregnancy she was started on low molecular weight heparin, low dose acetylsalicylic acid and folic acid. She had an elective CS at 40 weeks giving the birth to a healthy, normal weight, baby.

Case 2

A 28 years old woman with a personal history of iron deficiency anemia, 2 early spontaneous miscarriages and a family history of Hashimoto's thyroiditis, hypertension and diabetes is referred to the antenatal clinic in her third pregnancy. At 14 weeks she presents with fatigue and hair loss. Laboratory studies reveals vitamin D and folic acid deficiency. Positive IgA ATA e AGA suggest CD. This diagnosis is confirmed by genetic markers (HLA-DQB1*02:01 and DQA1*05:01). The patient followed a gluten-free diet completing the pregnancy without complications.

Case 3

A 10 weeks pregnant, 30 years old, woman with an obstetric history of 3 miscarriages after in-vitro fertilization, is referred to the internal medicine clinic with suspected CD (anemia and positive IgA ATA). Further laboratory studies reveal positive IgG and IgA AGA but negative IgG ATA. An endoscopy for confirmation of the diagnosis is scheduled for after birth. Currently the patient is 34 weeks pregnant, with an uncomplicated pregnancy.

Discussion

The diagnosis of CD is still underestimated. Despite conflicting data regarding the risk of infertility and pregnancy complications, screening for CD should be considered in women with recurrent pregnancy complications. The possible complications are illustrated in these cases, supporting that early diagnosis can improve pregnancy outcomes.

#2031 - Case Report

A CASE REPORT OF DRESS INDUCED BY PIPERACILLIN-TAZOBACTAM

Joana Cordeiro Cunha, Ana Lima Silva, Renato Nogueira, Andreia Coutinho, João Correia Cardoso, Luís Madureira, Jorge Salomão, Augusto Duarte

Centro Hospitalar do Médio Ave, Vila Nova De Famalicão, Portugal

Introduction

Drug reaction with eosinophilia and systemic symptoms (DRESS) is a rare and potentially life-threatening, drug-induced hypersensitivity reaction. Clinical presentation includes rash, eosinophilia, atypical lymphocytosis, and internal organ involvement. Antiepileptic agents and allopurinol are the most frequently associated reported drugs; there are also reports of antibiotic induced-DRESS, most frequently sulfonamides, but also other classes, as beta-lactams. Reaction typically begins two to six weeks after the initiation of the offending drug, thus presenting a latency considerably longer than in most other drug hypersensitivity reactions.

Case description

45-year old male. Admitted to the surgical ward due to colon cancer with retroperitoneal invasion, complicated by abscess. The patient

underwent successful colectomy and resection of the invaded structures and initiated intravenous piperacillin-tazobactam. 23 days after admission, the patient develops malaise and tachypnea, followed by rash that initiated on the right shoulder, hematochezia, fainting sensation and discomfort during piperacillin-tazobactam infusion. Postoperative complications were excluded, piperacillin-tazobactam was suspended, and internist consultation was requested to diagnostic clarification and treatment. The rash progressed to the trunk, abdomen, face and superior and inferior limbs to form a diffuse, confluent and exfoliative erythema. The patient also developed fever, tachycardia and rales on pulmonary auscultation. Blood analysis showed pronounced eosinophilia, atypical lymphocytosis and elevation of alkaline phosphatase; urinalysis showed hemato-proteinuria; the thoracic CT scan showed bilateral pleural effusion and pneumonitis. The patient was diagnosed with DRESS induced by piperacillin-tazobactam, with lung, renal, hepatic and gastrointestinal involvement. Prednisolone was started, with prompt clinical improvement. The relationship between piperacillin-tazobactam and DRESS was presumed due to consistent temporality between the initiation of the drug and the development of the reaction, and the absence of administration of other drugs reported to be associated with DRESS.

Discussion

Reported DRESS associated-mortality varies between 5 to 10 percent. In cases of severe organic involvement, systemic corticosteroids must be instituted promptly. This case presents an infrequent etiology of a low-incidence syndrome, presenting with some uncommon clinical findings.

#2034 - Case Report

GASTRIC ADENOCARCINOMA PRESENTING AS SEROPOSITIVE RHEUMATOID ARTHRITIS

Manuel Silvério António^{1,2}, Federica Parlato³, Pedro Silva Gaspar^{3,4}, Patrícia Martins^{1,2}, Maria Margarida Andrade³, Arderius Miguel⁵, Braz Sandra^{3,4}, Rui Victorino³

¹ Serviço de Reumatologia e Doenças Ósseas Metabólicas (Director: Prof. Doutor João Eurico da Fonseca), Hospital de Santa Maria, Centro Hospitalar Lisboa Norte, Lisboa, Portugal

² Unidade de Investigação em Reumatologia, Instituto de Medicina Molecular, Centro Académico de Medicina de Lisboa, Faculdade de Medicina, Universidade de Lisboa, Lisboa, Portugal

³ Serviço de Medicina 2 (Director: Prof. Doutor Rui M. M. Victorino), Hospital de Santa Maria, Centro Hospitalar Lisboa Norte, Lisboa, Portugal

⁴ Faculdade de Medicina, Universidade de Lisboa, Lisboa, Portugal

⁵ Serviço de Medicina 3 (Directora: Dra. Glória Nunes da Silva), Hospital Pulido Valente, Centro Hospitalar Lisboa Norte, Lisboa, Portugal

Introduction

Rheumatologic paraneoplastic syndromes occur in less than 10% of malignant diseases and are often a diagnosis of exclusion. Paraneoplastic arthritis (PA) is classically described as an acute asymmetric polyarthritis with negative rheumatoid factor (RF)

and anti-cyclic citrullinated protein (CCP) antibody. However, recently published data demonstrated that PA, although rarely, can present a rheumatoid arthritis (RA) pattern and be associated with RF and anti-CCP antibody positivity.

Case description

A 64-year-old-male patient with unremarkable past medical history, presented with a 6-month history of symmetric debilitating polyarthritis involving the wrists, metacarpophalangeal joints, proximal interphalangeal joints and ankles. He also complained of vomiting, progressive fatigue and unintentional weight loss with the same time of duration. Laboratory results showed microcytic and hypochromic anaemia (haemoglobin 7.9 g/dL) and elevated C reactive protein (17.3 mg/dL) and erythrocyte sedimentation rate (94 mm). Serologic workup revealed RF (215 UI/mL) and anti-CCP antibody (156.9) positivity. X-rays of the affected joints were normal, without erosions. Upper endoscopy showed a stenotic lesion of the body and gastric antrum and biopsies findings were consistent with adenocarcinoma. Gastric carcinoma was staged as T3N2M1 and the patient was started on palliative chemotherapy and immunotherapy. He was also treated with corticosteroid with good response but polyarthritis relapsed when this medication was stopped. Corticosteroid was reintroduced, in association with hydroxychloroquine, with complete resolution of the arthritis.

Discussion

This case demonstrates a unique phenotype of PA presenting as classical seropositive RA (RF and anti-CCP antibody positivity). The rapid onset of polyarthritis, associated gastric and constitutional symptoms and the close temporal relationship between the onset of arthritis and the other clinical manifestations led us to assume the diagnosis of PA. We intend to highlight the importance of considering an underlying neoplasia, particularly in male patients aged >50 years, who present with abrupt onset polyarthritis and systemic symptoms, even in those with seropositive RA-like arthritis. To the best of our knowledge, this is the fifth case of PA with a RA-like pattern and positive anti-CCP antibody.

#2045 - Case Report

RECURRENT MISCARRIAGE AND THROMBOSIS – A TYPICAL CASE OF ANTI-PHOSPHOLIPID SYNDROME

Cátia Da Cruz Correia, Ana Cristina Mestre, Ana Alves Oliveira
Hospital Distrital de Santarém EPE, Santarém, Portugal

Introduction

The anti-phospholipid syndrome (APS) is characterized by thrombosis and/or pregnancy morbidity with persistent presence of anti-phospholipid antibodies. Depending on the past medical and obstetric complications of APS low-dose acetylsalicylic acid with or without low molecular weight heparin (LMWH) are used during pregnancy to improve outcomes and prevent thromboembolic disease.

Case description

A 27-year-old Caucasian woman, with a personal history of idiopathic thrombocytopenic purpura in 2012 treated with prednisolone for 2 years and no recurrence of thrombocytopenia is referred to the internal medicine outpatient clinic for preconception counseling. She had two previous second trimester fetal deaths in 2016 and 2018, with histopathology revealing a poor maternal vascular perfusion of the placenta. In clinic the patient complained of a 1-year history of edema of the left leg and a chronic ulcer after an insect bite. A venous Doppler was performed showing an old ileo-femoro-popliteal thrombus with recanalization. She had previously performed some laboratory tests that revealed a slightly elevated lupus anticoagulant antibody. The diagnosis of obstetric and thrombotic APS was further supported by the presence of positive anti- β_2 glycoprotein I and anti-cardiolipin IgG and IgM antibodies. At the time of the first appointment there was suspicion of a new pregnancy and after confirmation she was started on LMWH and low-dose acetylsalicylic acid. Currently she is 34 weeks pregnant, with no complications of APS and no adverse effects of the therapy. For confirmation of obstetric APS she will repeat the study after delivery.

Discussion

This case highlights the importance of early recognition of APS as a cause of recurrent miscarriage and adverse pregnancy outcomes. It was not possible to confirm the diagnosis during pregnancy, since pregnancy itself can lead to positive antibodies, however due to the typical clinical findings it was decided to treat the patient as if the diagnosis was confirmed. Adequate treatment led to a, so far, successful pregnancy.

#2063 - Case Report

SERONEGATIVE RHEUMATOID ARTHRITIS, A DIAGNOSIS CHALLENGE

Pedro Gomes Santos, Mihail Mogildea, Carolina Soares Oliveira, Júlio Lemos Teixeira, Pedro Martins Dos Santos, José Moreno, António Veiga Moura
Hospital de Faro, Faro, Portugal

Introduction

Rheumatoid arthritis (RA) is an inflammatory chronic disease with a world prevalence of 1%, of unknown cause. Polyarticular synovitis is the main presentation of RA, causing incapacitation and articular destruction if left untreated. The higher mortality rate in patients with RA is due to the polyarticular disease and the higher cardiovascular risk (coronary disease and heart failure).

Case description

Male, 51 years old, independent for ADLs, past medical history of hemoglobin S carrier. The patient complaint of muscular weakness and pain in all four limbs, mainly at the shoulder girdle, polyarthralgia and morning stiffness in the hand articulations, elbows and shoulders, with progressive worsening. The patient

also referred episodes of painful swelling of the right foot and knee, without other symptoms. The lab results showed a normocytic normochromic anemia, C-reactive protein 209 mg/L, sedimentation rate 106 mm/1sth, and normal rheumatoid factor, anti-CCP antibody and antinuclear antibodies. Negative HIV, HCV, HBV, tuberculosis, toxoplasmosis and syphilis serology. Normal electromyography and abdominal/renal/pelvic ultrasound. Due to the polyarthralgia with inflammatory characteristics, acute-phase proteins elevation, without other analytical markers, the patient was diagnosed with seronegative rheumatoid arthritis. The treatment was initiated with prednisolone 20 mg daily, granting significant symptomatic relief, however the patient didn't tolerate corticotherapy reduction. We chose to initiate methotrexate 15 mg weekly, being then able to reduce the dosage of prednisolone to 10 mg daily.

Discussion

The patient had polyarthralgia with inflammatory characteristics and acute-phase proteins elevation, scoring 7 points in the EULAR classification criteria. Historically the RA is associated with an elevated rheumatoid factor, however it is only present in 80% of the patients. The anti-CCP antibody has a 93-98% sensitivity although is only found in 75% of the cases. Almost 15% of the patients with RA are seronegative due to the absence of these two markers (rheumatoid factor and anti-CCP antibody), reinforcing the need of an exhaustive clinical evaluation when diagnosing RA.

#2071 - Case Report

DIFFUSE CUTANEOUS SCLERODERMA: A CASE REPORT OF A RAPIDLY PROGRESSIVE DISEASE WITH A UNUSUAL ANTIBODY PROFILE

Mariana Cristina Quaresma, Nuno Pereira, Ridhi Ranchor, Carina Andrade, Isabel Almeida, Fátima Farinha, Ana Vigário, João Araújo Correia
Centro Hospitalar do Porto, Porto, Portugal

Introduction

Systemic Sclerosis is an autoimmune disease characterized by overproduction of collagen, resulting in fibrosis and vasculopathy of the microcirculation, with multiorgan manifestations. Exposure to certain environmental factors and lung cancer may act as triggers, as it may coexist with other autoimmune diseases.

Case description

The authors present a case report of a 55-year-old male, smoker and professional painter with complaints of fatigue, generalized arthralgias, intense pruritus and progressive thickening of the skin, developing over a 3-month period. He also mentioned unintentional weight loss, erectile dysfunction and digital colour changes when exposed to cold. On physical examination, extensive symmetrical thickening of the face, hands, arms, trunk, legs, dorsal and abdominal areas was evident, and Raynaud

phenomena was also present.

The autoantibody profile revealed a homogeneous ANA immunofluorescence pattern, and positivity for both anti-scl70 and anti-centromere antibodies. Rheumatoid factor, anti-U1RNP, anti-RO/SSA and anti-LA/SSB antibodies, were negative. Although pro-BNP was slightly raised, echocardiography was normal with an estimated pulmonary artery pressure of 25mmHg. Other laboratory workout was irrelevant with normal urine analysis and kidney function. Lung function tests had a mild obstructive pattern and a normal DLCO. High resolution CT scan of the lung revealed paraseptal emphysema and a 4 mm nonspecific lung nodule of the upper lobe, but extensive workout excluded other causes of scleroderma. Skin biopsy and capillaroscopy showed typical changes. The patient was diagnosed with rapidly progressive diffuse cutaneous scleroderma with extensive skin thickening (Rodnan score 21 over 51) and associated vasculopathy. He was started on cyclophosphamide according to the institution protocol. Due to an increase in Rodnan score and major disability a trial of rituximab was made after expert consultation.

Discussion

We present this case because of the rarity of the profile of autoantibodies and the rapidly progressive clinical presentation. The patient is stable with close monitoring of lung, cardiac and renal function, but disease progression and response to treatment in unpredictable.

#2087 - Case Report

HEERFORDT SYNDROME: A RARE PRESENTATION OF SARCOIDOSIS

Rui Soares Correia, Ricardo Lavajo, Filipe Rodrigues, Miguel Silva, Carla António, Marlene Delgado
Centro Hospitalar de Tondela-Viseu, Viseu, Portugal

Introduction

Sarcoidosis is a multisystemic disease of unknown etiology characterized by tissue infiltration with noncaseating granulomas and can involve all organ systems to a varying extend and degree, but the most frequently affect sites are the lungs, lymph nodes, skin, eyes and liver. Spontaneous resolution of the disease is common, but progressive and disabling organ failure can occur in up to 10% of patients.

Case description

A 49 year old woman with no remarkable medical history was admitted to our hospital with left peripheral facial paralysis and left parotid hypertrophy. A few days later the right side of her face and the right parotid gland were also affected, without signs of ocular impairment. Electromyographic evaluation showed moderate peripheral paralysis more serious on the left. Parotid gland biopsy showed granulomatous chronic sialadenitis suggesting Sarcoidosis. The patient then started treatment with a short burst of glucocorticoids and integrated a rehabilitation program. A few

months later, the patient presented with parotid swelling again and left anterior uveitis, the urine workup showing hypercalciuria so there was a need to start glucocorticoid therapy (prednisolone 40 mg daily for 4 weeks and reducing the daily dose progressively after) with clinical and electromyographic improvement. After stopping glucocorticoid therapy, recurrent uveitis and systemic signs of disease started appearing: pulmonary impairment (HRCT-scan initially showed infra-centrimetric mediastinal lymph nodes now was showing stage II pulmonary impairment associated with small airway obstruction but without any symptoms), Cardiac impairment (asymptomatic right branch bundle block not present before and with a normal echocardiographic and 24 h Holter evaluation without history of syncope) and Thyroid gland impairment (negative antibody hypothyroidism, an US-scan that showed a small and heterogenous thyroid gland and a normal hypothalamo-pituitary-adrenal axis function). Because of recurrent uveitis the patient was dependent on glucocorticoids so there was a need to start immunosuppressive therapy with methotrexate in order to achieve symptomatic remission, normalization of calciuria, normal thyroid gland function and normal pulmonary function tests, such as imagiological stability of pulmonary lesions.

Discussion

This case stands out because of the Heerfordt syndrome that is a rare presentation of sarcoidosis and by progression of the disease with multisistemic involvement under glucocorticoid therapy.

#2095 - Abstract

INFECTIOUS INTERCURRENCES RELATED TO BIOLOGICAL THERAPY

David Paiva, Hélio Martins, Mariana Formigo, Glória Alves, Sara Freitas, Jorge Cotter
Hospital Senhora da Oliveira, Guimaraes, Portugal

Background

Biological therapy increasingly assumes a fundamental role in the treatment of autoimmune diseases, modifying their evolution and the quality of patients life. Therefore, it is very importance to study the possible adverse effects of this therapy. The prevalence of infectious interurrences related to this type of therapy is described in the literature. In this study we intend to analyze their prevalence in our population.

Methods

A retrospective and observational study was carried out in patients with autoimmune diseases who were undergoing biological therapy between January 2014 and December 2018 at internal medicine consultation.

Results

A sample of 433 patients under biological treatment with mean age at the time of diagnosis of 50.5 years and an average time

of therapy of 5.1 years (minimum 1 year and maximum of 15 years). The majority infectious complications (N=79, 18.2% of patients) that leading to stop or discontinuation biological therapy corresponded to upper respirator infection (32.7% / 22.1%), followed of urinary tract infections (8.7%). Of all the complications, 63.3% required antibiotic therapy and 24% (N=19) needs hospital admission. As baseline, 48.1% (N=38) had ankylosing spondylitis, 24.1% (N=19) and 20.3% (N =16) psoriatic arthritis. The most commonly biological therapy used to treat our patients were etanercept (57%, N=45) and adalimumab (21.5% (N = 17)).

Conclusion

With this study, it was possible to characterize our population under biological therapy and their respective infectious interurrences and demonstrate their clinical importance in the follow-up of these patients.

#2120 - Case Report

CEREBRAL SINUS VENOUS THROMBOSIS: A MANIFESTATION OF ANTIPHOSPHOLIPID SYNDROME IN A PATIENT WITH COMPLETE GONADAL DYSGENESIS

Federica Parlato¹, Pedro Silva Gaspar^{1,2}, Manuel António³, Sandra Braz^{1,2}, Rui Victorino¹

¹ Serviço de Medicina 2, Hospital de Santa Maria (Director: Prof. Doutor Rui M. M. Victorino), Centro Hospitalar Lisboa Norte, Lisboa, Portugal

² Faculdade de Medicina, Universidade de Lisboa, Lisboa, Portugal

³ Serviço de Reumatologia e Doenças Ósseas Metabólicas (Director: Prof. Doutor João Eurico da Fonseca), Hospital de Santa Maria, Centro Hospitalar Lisboa Norte. Unidade de Investigação em Reumatologia, Instituto de Medicina Molecular, Centro Académico de Medicina de Lisboa, Faculdade de Medicina, Universidade de Lisboa, Lisboa, Portugal

Introduction

Cerebral sinus venous thrombosis (CSVT) is a rare form of venous thrombosis (VTE), but nevertheless one of the most common causes of stroke in young women. Complete gonadal dysgenesis (CGD) is a rare congenital disorder of sex development characterized by normal female genitalia and fibrotic non-productive gonads in which hormone replacement therapy (HRT) is crucial to induce secondary sex characteristics. We describe a case of a patient with CGD in whom CSVT was the first manifestation of antiphospholipid syndrome (APS).

Case description

A 49 years old 46, XY patient with CGD undergoing HRT was admitted to the emergency ward complaining right sided, pulsating headache, nausea, vomiting and decreased visual acuity for the previous five days. Physical exam was unremarkable, without neurologic deficits. Blurred optic disc edges on ophthalmologic evaluation suggested increased intracranial pressure. Brain CT venography revealed thrombosis of the right lateral and left transverse sinus and filling defects of right

internal jugular vein (IJV). Brain MRI confirmed right lateral sinus thrombosis, extending to right IJV. Treatment with low molecular weight heparin and acetazolamide was started with progressive symptomatic improvement. The patient was discharged after bridging to warfarin. An extensive hypercoagulable workup at presentation and 12 weeks later revealed a lupus anticoagulant (LAC) screen positive with Diluted Russell Viper Venom Time confirmation that led to the diagnosis of APS. Thoracic, abdominal and pelvic CT-scan excluded malignancies. HRT was stopped.

Discussion

CSVT is a multifactorial condition with gender-related specific causes. Despite the potential increased risk of venous thrombosis associated with HRT and gonadal tumors in patients gonadal dysgenesis, we didn't find in literature any report of CSVT and APS associated with CGD.

#2123 - Case Report

RELAPSING MARANTIC ENDOCARDITIS IN APS - SLE - TROMBOPHILIC PATIENT

Mafalda Corrêa Figueira, Margarida Lopes Madeira, Gonçalo Amaral Mendes, Bárbara Lobão, José Pedro Villa De Brito, Ermelinda Pedroso

Centro Hospitalar de Setúbal, Setúbal, Portugal

Introduction

Marantic endocarditis (ME) may occur in patients with systemic lupus eritematosus (SLE) and antiphospholipid syndrome (APS) as well as in patients with mucin producing cancers. The presence of an inherited thrombophilic state, such as MTHF gene mutations, may potentiate its appearance. Heart valve disease is the most common presentation, may implicate valve plasty or replacement and even culminate in severe heart failure.

Case description

A 19-year old woman was diagnosed with APS when she underwent initial investigation of two ischemic strokes. She had very high titers of antiphospholipid antibodies and was also found to have a MTHF gene mutation with resulting hyperhomocysteinemia. She had no sequelae and only attended medical follow-up for one year. She abandoned the consultations, stopped warfarin and had a third ischemic stroke. During this inpatient stay she was found to have 4 positive criteria for SLE. She had cardiac ultrasound (US) and was diagnosed with ME, already with signs of valve perforation. She resumed her therapy and was maintained on corticosteroids (CS), hydroxychloroquine (HCQ) and warfarin. Regular US follow-up was done and the size of thrombotic mass was stable although INR values were very difficult to control. During two years she was anticoagulated with vitamin K antagonist (VKA) with INR values being mostly out of the target value. Due to this INR lability VKA were switched for rivaroxaban. Four months after this switch we observed an increase in endocardial thrombotic mass, which attained 30mm x 6mm, causing significant mitral insufficiency,

severe heart failure symptoms and the need for surgery. The patient had the thrombotic mass surgically removed and her mitral valve repaired and was maintained on anticoagulation with low molecular weight heparin (LMWH) since surgery. One year after surgery she complained of worsening heart failure symptoms and transesophageal echocardiogram revealed a new thrombotic mass causing severe mitral insufficiency. She is now under CS; HCQ, LMWH and aspirin, waiting for valve replacement. If recurrence will ensue she'll undergo course of Rituximab.

Discussion

This case is interesting because of the exuberance, recurrence and refractoriness of this ME that may be explained on the basis of the multifactorial etiology of her hypercoagulable state. Studies are needed to evaluate the benefit of immunosuppressant therapy in refractory and recurrent ME as well as the role of different anticoagulant therapies.

#2127 - Abstract

HISS – HEART INVOLVEMENT IN SJOGREN SYNDROME – STUDY PROJECT AND PRELIMINARY DATA

Liliana R Santos¹, Joana Rigueira², Afonso Nunes Ferreira², Ana Almeida², Ana Paula Vilas³

¹ Serviço de Medicina 2B. Hospital de Santa Maria - Centro Hospitalar e Universitário Lisboa Norte, Lisboa, Portugal

² Serviço de Cardiologia – Hospital de Santa Maria / Centro Hospitalar Universitário Lisboa Norte, CCUL, CAML, Faculdade de Medicina da Universidade de Lisboa;, Lisboa, Portugal

³ Serviço de Medicina 2B. Hospital de Santa Maria - Centro Hospitalar e Universitário Lisboa Norte, Lisboa, Portugal, Lisboa, Portugal

Background

Primary Sjögren's syndrome (SS) is a chronic autoimmune exocrinopathy. Still, more than one third of patients also present extraglandular manifestations, namely cardiac.

Aim: To study the usefulness of echocardiographic (ECHO) modalities in a population of SS patients without cardiovascular risk factors.

Methods

Pulsed color doppler ECHO was performed in a small cohort of patients (10 women, mean age 57,2 ± 13 SD) with SS according to the European criteria. Left ventricular dimensions and interventricular septum and posterior wall thickness at the end of diastole were measured in order to calculate the fractional shortening. Parameters of RV and LV diastolic function (E/A ratio) were evaluated and pulmonary artery systolic pressure was estimated by the peak regurgitation velocity from the tricuspid valve plus the estimated right atrial pressure. The acceleration time of the pulmonary flow at the end of VD was obtained. Valve lesions were determined by continuous and color doppler. Pulsate

tissue doppler (E/E') was also determined. During this prospective study, a complete medical assessment was done and patients answered a questionnaire on their quality of life (Minnesota questionnaire). Blood tests were done and included cardiac biomarkers (Tnl, NT-pro BNP), autoimmune biomarkers (ANA, anti-Ro/SSa, anti-La/SSb) and markers of cardiovascular risk (HDL and LDL cholesterol and triglycerides). 6-minute-walk test (6MWT) results were also analyzed.

Results

Only 2 patients had mild mitral valve regurgitation. Mild pericardial effusion was found in another 2. None of our patients had PSAP >35 mmHg but 2 had pulmonary flow at the end of VD lower than 120 ms, suggestive of pulmonary hypertension. Half of the patients had decreased volume of the right atrial. In 9/10 patients there was an increase in the ratio E/E' (average of 11; normal value <8). In the 6MWT, patients walked in average 450m with a decrease in peripheral saturation from 98% to 96% and increase of 1,5 points in fatigue and dyspnea scales. Only 2 patients had an increased NT-ProBNP (> 125 ng/dL) and they also had the highest levels of anti-Ro and/or anti-La antibodies.

Conclusion

Our study includes a small number of patients, still the findings support the hypothesis that patients with SS and no clinically apparent heart disease may present patterns of diastolic dysfunction. Pulmonary valve doppler might be useful to predict pulmonary hypertension in SS patients with normal PSAP.

#2137 - Case Report

ADENOPATHIES, SIMILAR PRESENTATION - 2 DIFFERENT DIAGNOSES

Margarida Temtem, Catarina Nóbrega, Rubina Miranda, Ana Célia Sousa, Maria Da Luz Brazão
Central Hospital of Funchal, Funchal, Portugal

Introduction

The onset of adenopathies reflects, more frequently, the activation of the immune system, a controlled increase of the lymphocytes and macrophages in response to an antigen, however, adenopathies may represent other etiologies.

Case description

Case 1

Female, 79 years old, caucasian, presented an ulcerated lesion in the left cervical region with cutaneous fistulas and adenopathies. Blood tests: sedimentation rate (SR) 83 mm, adenosine desaminase 71.5 U/L, reactive c protein 69.26 mg/L. Serologies for hepatitis B, C, HIV, Bartonella-negatives. Thoraco-abdominal computed tomography (TA-CT): "diffuse fibrointerstitial changes. Subsegmental depolarized glass changes in the upper pulmonary lobes". CT of the neck: "multiple cervical adenomegalies, twice in parotid, importants by their number and size." She initiated

ciprofloxacin for lymph node excision. Due to slow progression, antibiotic therapy was prolonged by a further 15 days and then flucloxacillin for one month. Exsudate culture was negative. The excision of the left cervical adenopathy and bilateral cervical skin was made. Pathological anatomy (PA): "chronic inflammatory process with epithelioid granulomas, focal necrosis and presence of Langhans-type multinucleated giant cells that involve the lymph node, soft tissues and dermis". The treatment for tuberculosis was started with anti-bacillary and she improved favorably.

Case 2

Female, 31 years, caucasian, was forwarded to emergency department for painful cervical and supraclavicular adenopathies with 1 week of evolution. Objectively: bilateral and supraclavicular cervical adenopathies, hard, adhering to the deep planes and painful. Blood tests: SR 57mm, serologies for CMV, EBV, hepatitis B, C, HIV, herpes simplex and toxoplasma gondi-negatives. TA-CT: "prominent adenopathic conglomerates on transverse cervical topography in the transition to the base of the neck. Adenomegaly is also observed in upper mediastinal topography". She did an incisional biopsy of a left cervical node. PA: "fragment of necrotic tissue with fibrous septa limiting nodules. Bulky cells with nuclei with prominent "Hodgkin's" nucleolus are observed, this is suggestive of classic Hodgkin's lymphoma, nodular sclerosis." She initiated direct treatment with good response.

Discussion

Adenopathies are often a warning sign for several pathologies. A high index of suspicion is necessary but also a complete anamnesis and physical examination, as well as appropriate complementary exams to reach definitive diagnoses.

#2138 - Abstract

LIVING WITH RA: HOW IT AFFECTS QUALITY OF LIFE

Paulo Vilas-Boas, Carolina Mazedo, Bernardo Figueiredo Santos, Rita Cunha, Gisela Eugénio, Maria Céu Morais, Ana Águeda, Inês Cunha, Catarina Ambrósio, Renata Aguiar, Anabela Barcelos CHBV, Aveiro, Portugal

Background

Patients with Rheumatoid arthritis (RA) have a decreased quality of life in several levels, such as sleep quality, psychological well-being and disability degree. Disease Activity Score of 28 joints (DAS28) is widely used as an indicator of RA disease activity and response to treatment. In this study we aim to understand how this score compares with several patient-reported outcome measures (PROMs) (sleep quality disability level, anxiety, depression, and fatigue).

Methods

A total of 40 RA patients took part in this observational study. A standardized questionnaire was used to register socio-demographic parameters. Pain intensity was described through

the pain visual analogic scale (pVAS). All patients answered a Health Assessment Questionnaire (HAQ), a Hospital Anxiety and Depression Scale (HADS), a fatigue scale (FACIT) and a Pittsburgh Sleep Quality Index (PSQI) questionnaire. Inflammatory parameters values (c-reactive protein (CRP) and erythrocyte sedimentation rate (ESR)), as well as the number of swollen and painful joints were collected through the clinical process. Subsequently, DAS 28 and DAS28-4V were calculated. Statistical differences between variables were assessed through the most adequate statistical tests. $p < 0.05$ was considered significant in all analysis.

Results

Regarding disease activity, a statistically significant association was found with both DAS28/HAQ ($p=0.03$) and DAS28/PSQI ($p=0.045$). No association was found between DAS28 and other PROMs (HADS-A ($p=0.278$), HADS-D ($p=0.400$) and FACIT ($p=0.285$)). While comparing PROMs with DAS28-4V, association was observed between DAS28-4V/HAQ ($p=0.01$), DAS28-4V/PSQI ($p=0.041$) and DAS28-4V/FACIT ($p=0.091$). No association was found between DAS28-4V/HADS-A ($p=0.116$) and DAS28-4V/HADS-D ($p=0.9$).

Conclusion

DAS28 and DAS28-4v showed a strong association with a few, but not all PROMs. Both disease activity markers showed a correlation with sleep quality and disability degree, and DAS28-4v also showed association with fatigue. DAS28 correlation with HAQ is already known. In this study it is implied that RA disease activity also has a strong relation with sleep quality. We should be aware that patients with higher disease activity can suffer a non-repairing sleep with all the complications underlying it, and should be treated accordingly. More studies with larger samples are needed to confirm this assumption.

#2139 - Case Report

IGG4 RELATED-DISEASE EYELID PSEUDOTUMOR

Sara Moutinho-Pereira, Ana Jerónimo, Filipe Andrade, Raquel Machado Neves, Sara Alves Pereira

ULSM - Hospital Pedro Hispano, Matosinhos, Portugal

Introduction

Immunoglobulin G4-related disease (IgG4RD) is an increasingly recognized immune-mediated condition where patients present with tumors in different organs and/or lymphadenopathy. Initial observations were made in patients with autoimmune pancreatitis (AP), subsequently classified as Type 1 AP. The eye was the first extra-pancreatic location of IgG4-RD to be described, eyelids being most commonly affected. Asthma and allergic rhinitis (AR) are commonly associated conditions. Half of the patients with eye involvement have systemic disease, being at a higher risk of non-Hodgkin lymphoma development when compared to those with

pancreatic involvement. Criteria for IgG4-RD diagnosis include the presence of specific histological patterns and IgG4 infiltration with distinct IgG4/total IgG ratios that vary according to the affected organ.

Case description

A 24-year-old male with medical history of AR, presented with a lobular polypoid lesion in the inferior eyelid, with no other symptoms. Physical examination was otherwise unremarkable. The growth of the tumor motivated its total excision, with tissue biopsy showing an intense lymphoplasmocitary inflammatory infiltrate and venulitis lesions with neutrophilic infiltrates around vascular walls, without associated necrosis or granulomas. Immunohistochemistry was positive for IgG4 plasmocytes. IgG plasma levels were normal, including IgG4 and remaining subclasses, with an elevation of IgE, consistent with AR background. Despite normal IgG4 levels, plasma IgG4/IgG ratio was 9%. Abdominal ultrasound identified a gallbladder polyp but no other abnormalities. A diagnosis of IgG4-RD pseudotumor was established and the patient maintains clinical follow-up.

Discussion

In 40% of patients with IgG4-positive tissue biopsies, IgG4 plasma levels are normal, which might indicate initial stages of IgG4-RD. Our patient had a plasma IgG4/IgG ratio >8%, a cut-off of clinical relevance for its high sensitivity for disease progression. Clinical association with AR was also present. Criteria for IgG4-RD will be discussed, including organ-specific IgG4/IgG ratios, as well as histological findings. Corticosteroids are the treatment of choice, which was not necessary, as the lesion was completely removed and there were no signs of systemic involvement. Nevertheless, close monitoring is imperative to evaluate disease progression as well as the risk of developing lymphoproliferative disease, reported to be higher in patients with eye involvement.

#2143 - Abstract

REUMATHOID ARTHRITIS: A DESCRIPTIVE ANALYSIS OF A POPULATION

Catarina Duarte Santos, Pedro Neves Tavares, Carla Falcão, Miguel González Santos, Rita Rodrigues, Miriam Magalhães, Alcina Ponte

Centro Hospitalar de Leiria, Leiria, Portugal

Background

Rheumatoid arthritis (RA) is a chronic autoimmune inflammatory disease that typically affects small and medium-sized joints, symmetrically.

The disease is characterized by inflammation of the synovial tissue of multiple joints, leading to tissue destruction, pain, deformity and reduced quality of life of the patient, if not treated in a timely and appropriate manner.

Morning stiffness, joint edema and, in later stages of the disease, functional disability are the most frequent complaints.

It affects mainly female individuals and the most frequently affected age group is over 60 years of age.

Methods

The aim of this analysis was to describe the demographic and clinical characteristics of RA patients followed in an autoimmune consultation.

Were reviewed, retrospectively, all cases of rheumatoid arthritis, followed in autoimmune consultation during the period from January 2013 to December 2018.

Results

In this analysis the authors characterized a population of 237 patients by gender, showing that 167 patients were female; regarding age, demonstrating that 94 patients were between the ages of 51 and 60, 52 patients between the ages of 60 and 70 and 37 between 71 and 80; and therapy: 212 patients were undergoing DMARDs and 25 undergoing biological therapy.

Conclusion

Despite the small sample, it was possible to verify some trends that are in agreement with what is described in the literature. Most of the patients were female and the peak age of incidence was between 50 and 60 years old.

#2158 - Medical Image

PSORIATIC ARTHRITIS WITH EXUBERANT CUTANEOUS MANIFESTATIONS.

Danay Perez Mijenes, Alexandre Vasconcelos
Ulsm Hospital Pedro Hispano, Matosinhos, Portugal

Clinical summary

A 44-year-old man, referred to the External Consultation of Internal Medicine for a symmetrical oligo arthritis, with a predominance of distal interphalangeal joints, hyperkeratosis and nail pitting accompanied by axial attainment, unilateral sacral ileitis, HLA B27 positive and negative rheumatoid factor. At the same time, there was an exuberant picture of infiltrated skin plaques with adherent scaling, affecting all of the upper and lower limbs, sensation of pruritus and cutaneous xerosis with PASI: 22. Psoriatic arthritis assumed with exuberant cutaneous involvement. He initiated immunosuppressive treatment with adalimumab and topical with cipotriol / betamethasone gel 50 mcg /0.5 mg/g. Documented clinical improvement after 3 weeks of treatment. Waiting for phototherapy.

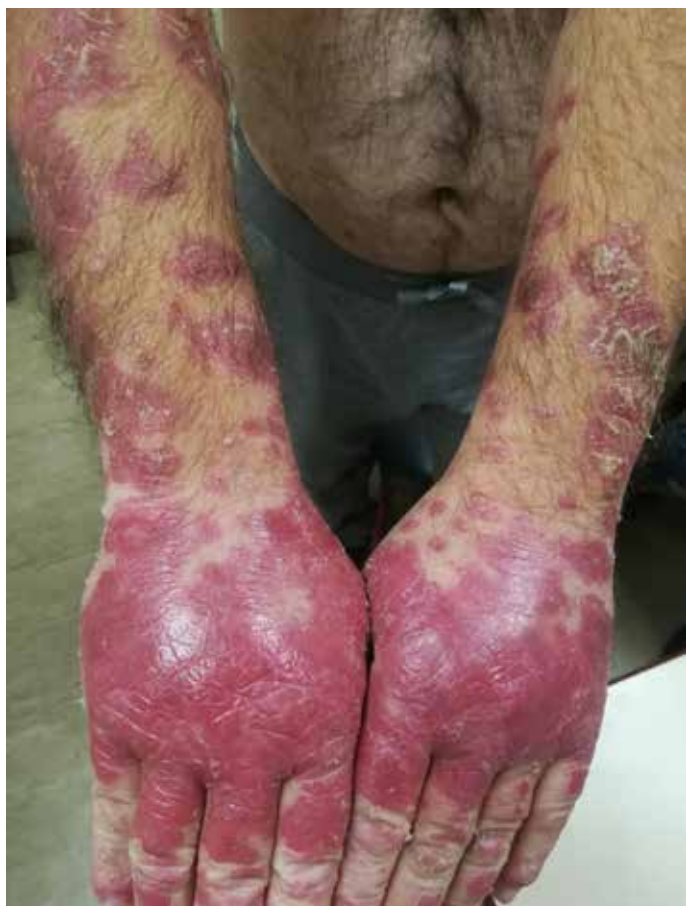

Figure #2158. Skin psoriasis on upper limbs.

#2160 - Case Report

PSORIFORM ERYTHRODERMA: A PARADOXICAL REACTION TO GOLIMUMAB

Sofia Xavier Pires, Marta Cunha, Glória Alves, Jorge Cotter
Hospital Senhora da Oliveira, Guimarães, Portugal

Introduction

Golimumab is a humanized monoclonal antibody, inhibitor of tumor necrosis factor alpha (TNF- α), which forms stable complexes of high affinity with soluble or transmembrane TNF- α . It is recommended for the treatment of rheumatoid arthritis, psoriatic arthritis and ankylosing spondylitis. Its mechanism of action is not fully understood, but its side effects are widely known, namely erythema of the puncture site, licheniform eruption, erythema multiforme, lupus erythematosus and exanthematous pustulosis, as well as reactivation of herpes simplex and tuberculosis. Paradoxically, one of the side effects may be aggravation or induction of psoriasis.

Case description

A 32-year-old female patient was diagnosed with ankylosing spondylitis in June 2017. The presentation of the disease was insidious, with talagias at rest and axial stiffness with seven years of evolution. The diagnosis was established according to clinical, radiological (pelvic resonance with subchondral

edema), and immunological criteria (HLA B27 positivity). At the moment of diagnose, ASDAS score was >3 and moderate to severe pain was reported despite naproxen therapy. Golimumab 50 mg was initiated with monthly subcutaneous injection. Two administrations were performed, both without local reaction at the puncture site. At the ninth week of administration, the patient presented with erythematous-scaling plaques scattered around the trunk, limbs and scalp. The lesions were found to be compatible with plaque psoriasis. Golimumab was switched to etanercept and after one month of treatment, the patient presented total regression of the cutaneous lesions. After 18 months of treatment she remains asymptomatic without axial stiffness, tendinitis or pain. No more cutaneous alterations were observed.

Discussion

Golimumab-induced psoriasis is a rare but previously described paradoxical adverse effect. The importance of this clinical case is related to its rarity, and the difficulty in choosing a new immunomodulator for continuity of therapy.

#2161 - Abstract

BIOLOGICAL THERAPY - AN INTERNAL MEDICINE SERVICE EXPERIENCE

Hélio Martins, David Paiva, Mariana Formigo, Sara Freitas, Pedro Cunha, Glória Alves

Hospital da Senhora da Oliveira - Guimarães, Guimarães, Portugal

Background

Biological therapy, revolutionize the treatment of autoimmune disease, changing their evolution and impact on quality of life.

Methods

Was conducted a retrospective and observational study of all patients undergoing biological therapy since January of 2004 to December 2018 that was accompanied in the consult of internal Medicine/Autoimmune diseases.

The main objective was to evaluate the demographic and clinical characteristics of the patients and their respective treatment, the infectious, neoplastic and cardiovascular complications based on the information of the personal clinical process.

Results

Was obtained a sample of 433 patients under biological therapy, mean age on the date of diagnose of 40.9 years and present mean age of 50.5 years, the majority of the patients was female gender (67.3%, n=292). The majority (46.9%, n=203) presented ankylosing spondylitis, followed by rheumatoid arthritis and psoriatic arthritis in 24.2%, n=105 and 11.1%, n=48, respectively. The biological therapy more commonly used was etanercept (42.2%; n=183), adalimumab (21.7%, n=94) and golimumab (12.7%, n=55).

The mean time of disease evolution was of 2.8 years, with mean age at the beginning of biological treatment of 43.4 years and the duration on treatment was of 5.1 years.

During the treatment with biological therapy was verified neoplasia in 19 patients, 84.2%, n=16 was female gender, with mean age of 56 years. This patients had, at the time of diagnose of the autoimmune disease a mean age of 49.5 years, had initiated biological therapy 2.9 years after diagnose, had a mean age of 56 years by the time of diagnose of neoplasia after a mean time of 4 years under biological therapy. The most prevalent neoplasia was de breast cancer in 38.6%, n=7 patients, followed by the skin and central nervous system cancers in 21.1%, n=4 and 10.5%, n=2, respectively.

Was verified infection and the need to interrupt biological therapy in 18.2%, n=79. There was need to hospitalise 19 patients (4.39%) and use of antibiotic therapy in 29 patients (6.7%).

There was 4 major cardiovascular events among the studied population (0.9%) not associated with mortality.

There was 6 deaths in this sample (1.4%) which 3 (0.7%) patients due to infections. There's no record of deaths because of neoplasia.

Conclusion

The study permitted to character and to monitor the population under biological therapy. The adverse events found were in agreement with the with the international literature publish at the time of the study.

#2166 - Case Report

CUTANEOUS BULLOUS LESIONS: WHEN CAUSE MATTERS

Tatiana Salazar, Isabel Freitas, Diana Fernandes, Celeste Guedes, Carla Melo

Centro Hospitalar do Médio Ave, Vila Nova De Famalicão, Portugal

Introduction

Cutaneous vasculitis can occur as a consequence of multiple disorders and is characterized by a wide variety of clinical findings. Because other diseases may present with similar clinical features, histopathologic examination is essential for confirming the diagnosis. Patients with skin vasculitis are at risk for vasculitis involving other organs. In addition, the cause of cutaneous vasculitis is not always immediately clear. The performance of a thorough patient history and physical examination will guide the selection of the appropriate laboratory and radiologic studies for patient evaluation.

Case description

74-year-old man with a history of hypertension, smoking, active alcoholism and chronic obstructive pulmonary disease. Admitted due to painful and pruritic bullous lesions at feet and knees with about 10 days of evolution (image). No history of fever, clinic of infection, recent use of drugs other than bronchodilators (tiotropium bromide and combination of fluticasone with salmeterol) or other systemic symptoms. Analytically without anemia, thrombocytopenia or elevation of C-reactive protein or sedimentation rate. It was thought to be ulcerated lesions of

bullous vasculitis with associated necrosis, and the patient was admitted for study and treatment with prednisolone 1mg/kg/day. He had a negative anti-nuclear antibodies (ANAs), anti-neutrophil cytoplasm antibodies (ANCA), extractable nuclear antigens (ENAs) and rheumatoid factor. HIV, HCV and HBV viruses were also null. Histology of cutaneous biopsy documented lesions of leukocytoclastic vasculitis without immunocomplexes deposits in immunofluorescence. The patient presented considerable improvement throughout the follow-up, without recurrence after 6 months of steroid therapy.

Discussion

Cutaneous vasculitis of small vessels is a disorder characterized by leukocytoclastic vasculitis and, by definition, there is no involvement of other organs. It can occur due to numerous factors including drugs, infections, systemic diseases or in the context of paraneoplastic syndrome. A triggering factor is not evident in about one-third to one-half of patients (idiopathic small vessel vasculitis). This entity usually resolves within a few weeks and therefore the approach involves excluding an identifiable cause and symptomatic treatment. Steroid therapy in a way to try to stop progression is reserved for patients who develop complications such as bleeding blisters, ulceration or chronic or recurrent disease in which was the case.

#2181 - Case Report

SYSTEMIC SCLEROSIS AND AUTOIMMUNE HEPATITIS - A RARE ASSOCIATION

Inês Cunha, Joana Andrade, Ana Filipa Viegas, Vera Romão, João Tavares, Cláudia Martins

Centro Hospitalar Tondela Viseu, Viseu, Portugal

Introduction

Hepatic involvement in patients with systemic sclerosis (SSc) is rare. Although autoimmune hepatitis (AIH) shares clinical and immunological features with connective tissue diseases, there are just over a dozen cases reported of AIH in patients with SSc.

Case description

A 45-year-old woman with limited cutaneous SSc was hospitalized due to ascites. In the previous months, she presented a progressive elevation of transaminases coincident with the introduction of methotrexate, which was suspended, without normalization of liver function.

Abdominal ultrasound revealed signs suggestive of chronic hepatopathy. Infectious causes, metabolic disorders and thrombotic causes were ruled out. Anti-mitochondrial, anti-actin, anti-LKM-1, anti-SLA/LP, anti-MPO and anti-PR3 antibodies were negative and a slight increase of IgG and IgA (<1.5x ULN) was observed with normal IgM. Liver biopsy revealed aspects suggestive of AIH and cirrhosis (with a MELD of 10 and signs of portal hypertension) and she started prednisolone and mycophenolate mofetil with a decrease of transaminases levels.

However, in the following months, she developed refractory ascites and was submitted to several paracenteses. She was hospitalized with aggravated ascites, asthenia and acute dyspnea. Chest x-ray revealed diffuse bilateral cotton-like infiltrates. *Staphylococcus aureus* and *Pneumocystis jiroveci* were isolated in bronchoalveolar lavage and tracheobronchial secretions and she started cotrimoxazole. She started vomiting and diarrhea associated with antibiotic intolerance. At 10th day of cotrimoxazole, she was admitted again. Ascites was aggravated. Exams revealed aggravated thrombocytopenia and acute renal failure. Cotrimoxazole was discontinued. Spontaneous bacterial peritonitis was excluded. She was diagnosed with hepatorenal syndrome and started terlipressin and albumin. She developed sudden severe ARDS with chest x-ray suggestive of *Pneumocystis jiroveci* infection and initiated atovaquone and meropenem. Despite the measures taken, the death was verified in 24 hours.

Discussion

Although the association is rare, AIH should be considered in patients with SSc with impaired hepatic function, because its timely treatment has a huge prognostic impact. This case also highlights the complex approach of these patients and the impact of opportunistic infections in patients with autoimmune pathology, immunosuppressive therapy and other concomitant conditions of morbidity.

#2184 - Case Report

RHEUMATIC POLYMYALGIA- A CLINICAL SYNDROME

Magda Ferreira Costa

Hospital Senhora da Oliveira, Guimarães, Portugal

Introduction

Rheumatic polymyalgia (RP) is the most common inflammatory disease in elderly. Heterogeneous clinical presentation that mimics autoimmune, infectious, endocrine or neoplastic diseases difficult the diagnosis

Case description

Woman, 85 years old, autonomous until 1 month before admission. During this period she appealed multiple times to the Emergency Department, having been medicated symptomatically and completed two cycles of antibiotic therapy with amoxicillin/clavulanate and levofloxacin due to generalized asthenia interspersed by periods of fever and apirexia.

Due to lack of improvement, with reference to symmetrical polyarthralgias at the scapular waist and pelvic girdle, as well as generalized myalgia and sustained fever with 3 days of evolution, the patient was hospitalised. It was documented an increase in sedimentation speed (99 mm/h) and C reactive protein (210 mg/L). In favour of the diagnosis: age over 50 years, evolution time greater than two weeks, scapular waist and pelvic girdle involvement, as well as acute phase markers evidence. No signs

or symptoms of infection, Giant Cell Arteritis (GCA) or neoplasia were found. Corticoid therapy was instituted with functional gain and analytical improvement.

Discussion

RP is a prevalent disease among elderly and may cause significant functional limitation in patients. The course of the disease is very heterogeneous and unpredictable. Simultaneously, about 30% of these individuals can develop GCA, that's why suspicion should be high and signs and symptoms kept in mind in order to avoid consequences such as blindness.

#2212 - Abstract

IS A GOOD NIGHT SLEEP RELEVANT TO RHEUMATOID ARTHRITIS PATIENT'S QUALITY OF LIFE? HOW SLEEP DISTURBANCES ASSOCIATE WITH OTHER PROMS

Carolina Mazedá, Paulo Vilas-Boas, Bernardo Figueiredo Santos, Rita Cunha, Gisela Eugénio, Renata Aguiar, Ana Águeda, Catarina Ambrósio, Inês Cunha, Maria Céu Morais, Anabela Barcelos
Centro Hospitalar Baixo Vouga, Aveiro, Portugal

Background

Patients with Rheumatoid arthritis (RA) have a decreased quality of life in several levels, such as sleep quality, psychological well-being and disability degree. To understand the patient's perspective there is an increasingly interest in their quality of life assessment. In this study we aim to compare several patient-reported outcome measures (PROMs) (sleep quality disability level, anxiety, depression, and fatigue) between a RA cohort and a healthy control group. We also analyze how sleep quality compares with other PROMs.

Methods

A total of 40 RA patients and 40 age and sex matched healthy controls agreed to participate in this cross-sectional study. A standardized questionnaire was used to register socio-demographic parameters. Both groups answered a Health Assessment Questionnaire (HAQ), a Hospital Anxiety and Depression Scale (HADS), a Fatigue Scale (FACIT) and a Pittsburgh Sleep Quality Index (PSQI) questionnaire. The RA group also completed a pain visual analogic scale (pVAS). Differences between groups were assessed through Mann-Whitney test or independent samples T-Test for continuous variables and Chi2 test or Exact Fisher test for categorical variables, as adequate. Kruskal-Wallis test was used to evaluate differences regarding sleep quality. $p < 0.05$ was considered significant in all analysis.

Results

The RA group (\bar{x} =64.5years, s =12.33 years, male to female ratio 2.64:1) showed worse mean scores in FACIT, HADS-A, HADS-D and PSQI (34.25±8.21; 7.64±4.17; 6.62±3.50 and 8.35±3.67;

respectively) compared with the control group (44.86±2.41; 3.17±3.15; 3.00±3.46 and 4.40±2.42, respectively) ($p<0.05$). Regarding sleep quality in the RA group it was found a statistically significant association between PSQI/FACIT ($p=0.015$). No association was found between PSQI and other PROMs (HADS-A ($p=0.792$), HADS-D ($p=0.563$), HAQ ($p=0.854$) and pVAS ($p=0.130$)), nor between PSQI and socio demographic variables (age, sex, BMI, civil and employment status).

Conclusion

Despite the limited sample it was possible to observe overall worse PROMs scores in the RA group compared with the control group. In this study it is implied that sleep quality has a significant association with daily fatigue. However, no correlation was found between sleep quality and other PROMs (disability level, anxiety and depression). Individual coping mechanisms may explain these differences.

#2215 - Case Report

CHRONIC HIP AND LUMBAR PAIN – A CASE OF PAGET’S DISEASE

Diana Pessoa, Carolina Pereira, Irene Verdasca, Ana Carolina Vasques, Claudio Gonçalves Gouveia, Luis Maia Morais, Susana Ramos Jesus, Ana Leitao, Candida Fonseca, Luis Campos
Centro Hospitalar Lisboa Ocidental, Lisboa, Portugal

Introduction

Paget’s disease is a disorder of bone remodelling, which causes an imbalance between formation and reabsorption, with bone thickening and bone marrow fibrosis. Its prevalence increases with age and male sex. Without treatment, the lesion increases by 0.8 cm/year. Clinical manifestations preferentially affect the axial skeleton, but it is often asymptomatic until complications of the disease, such as bone deformities, stress fractures, or symptoms through compression of the bone (osteoarthritis of adjacent bones or root compression) are manifested. In advanced stages, it can culminate in Paget sarcoma. Alkaline phosphatase is the main marker of activity and allows to evaluate the therapeutic response. The x-ray is diagnostic, and bisphosphonates are first-line therapy.

Case description

We present a case of a 70-year-old man with history of hypertension, dyslipidemia, hyperuricemia, and past smoking habits, with bone pain in the hips bilaterally, (but worst at the right) and lumbar spine with about 20 years of evolution. This pain had mechanical characteristic, worsens throughout the day, with functional limitation and need for analgesic medication. He had increased alkaline phosphatase (202 U/L), uric acid (6.1 mg / dL), and radiograph of the pelvis with important structural alteration of the bones, asymmetrical, predominating to the right, with bone expansion. CT scan with morpho-structural alteration involving L1 as well as both iliacs, a large part of the wings of the sacrum and

the left femoral head, with expansion of the bone limits, trabecular disorganization and pseudolitic areas (Paget’s disease probably in L1 and in the pelvis). Scintigraphy with increased osteoblast activity with features that suggest Paget’s disease in L1 and right hip.

He was treated with zoledronic acid with regression of pain and decrease of alkaline phosphatase.

Discussion

The aim of the therapy is to improve symptoms, decrease bone turnover and consequently delay the progression of the disease. Bisphosphonates are a safe, effective and well tolerated choice. It is a diagnosis that often goes unnoticed given the nonspecific complaints and the indolent installation of the disease, but which, if diagnosed and treated, substantially improves patients’ quality of life, and prevents complications, both neurological and degenerative, and the most fearsome, osteosarcoma.

#2218 - Case Report

VASCULITIS - A CONSEQUENCE OF THE DISEASE OR THE CURE?

Carolina Sequeira, Marta Custódio, Ana Paula Antunes, Tânia Strecht, Ana Gorgulho, Inês Vicente, Alexandre Fernandes, Jana Zelinová, Anabela Marques, Guiomar Peres
Cascais Hospital, Cascais, Portugal

Introduction

Leukocytoclastic vasculitis (LV) is a histopathologic term that describes a neutrophilic small vessels vasculitis. According to its etiology, it can be classified into idiopathic (up to 50% of cases) or secondary to drugs, infection (viral, mycobacterial, fungal, protozoal or helminthic), malignancy or connective tissue disorders. Skin manifestations are the leading presentation, ranging from palpable purpura, typically bilaterally on dependent areas of the body, to hemorrhagic vesicles, pustules, nodules and bullae, although it might include systemic involvement. It is histologically characterized by neutrophilic infiltrate and fibrinoid necrosis of small vessels, most often superficial post-capillary venules.

Case description

A 53-year-old man with squamous cell lung carcinoma underwent chemotherapy with carboplatin and vinorelbine one week before presentation. He was admitted to the Emergency Department for fever and cough for two days. Laboratory tests revealed anemia, leukopenia with neutropenia and marked elevation of C-reactive protein. Chest X-ray was consistent with right lower lobe pneumonia. He was empirically treated with vancomycin plus piperacillin/tazobactam and switched to flucloxacillin plus ceftazidime after isolation of methicillin-sensitive *Staphylococcus aureus* in the sputum samples. Six days after hospital admission, he presented petechiae of the lower limbs, infra-umbilical region and axilla, evolving to palpable purpuric lesions and blistering. Skin biopsy revealed LV.

Discussion

LV is a rare condition (studies report an incidence of 10 to 45 cases per million persons per year). It can be associated to systemic disorders or drugs. Suspected diagnosis should guide a detailed clinical history and physical examination, aiming to identify the etiology and guide the management of the patient. Skin biopsy of the lesions is fundamental to the correct diagnosis. Prognosis depends both on the underlying cause and on the organ involvement, being favorable when it is limited to the skin and only a minority may evolve to chronicity. In this case, we cannot identify the etiology undoubtedly, since our patient had two potential causes: the underlying neoplasm and the chemotherapy. Due to his immunosuppression state, we treated only with topical corticosteroid, with partial progressive remission of the lesions.

#2220 - Abstract

CORRELATIONS BETWEEN AUTOANTIBODIES EVOLUTION AND THERAPEUTIC IN RHEUMATOID ARTHRITIS

Inês Cunha, Joana Andrade, Ana Filipa Viegas, Mónica Teixeira, Ângela Mota, Sara Machado, Vera Romão, Cláudia Martins, João Tavares, Lúcia Rodrigues

Centro Hospitalar Tondela Viseu, Viseu, Portugal

Background

Analyze the existence of correlations between rheumatoid factor (RF) and anti-citrullinated protein antibodies (ACPA) and therapy [glucocorticoids (GC), conventional synthetic disease-modifying antirheumatic drugs (csDMARDs) and biological DMARDs (bDMARDs)] in patients with rheumatoid arthritis (RA).

Methods

Retrospective study of patients with RA (n=46) followed in a central hospital. Statistical analysis was performed with SPSS.

Results

The \bar{x} age was 67.02 ± 12.04 years and the \bar{x} follow-up time was 15.37 ± 10.74 years. 50.00% were receiving GC (39.13% of these ≥ 7.5 mg prednisolone/day). 84.78% had been under csDMARDs and 23.91% under bDMARDs.

8.70% were not currently medicated, 4.35% were under GC only, 30.45% csDMARDs only, 32.61% GC+csDMARDs, 2.17% GC+bDMARDs, 10.87% csDMARDs+bDMARDs and 10.87% GC+csDMARDs+bDMARDs.

The \bar{x} initial RF was 90.47 ± 98.85 IU/ml [3.5-392]. 19.6% were negative (-), 36.96% low positive (+) and 43.48% high positive (++) (>3 times the upper limit of normal). The \bar{x} current RF is 56.84 ± 80.50 [3.5 - 405.5] (41.30% -, 36.96% +, 21.74% ++). The \bar{x} initial ACPA was 285.80 ± 946.30 [0.1-6395] (41.30% -, 2.17% +, 56.52% ++) and \bar{x} current ACPA is 207.33 IU/ml [0.3-1558] (43.48% -, 6.52% +, 50.00% ++).

73.91% of patients decreased the titers of RF and 50.00% the titers of ACPA. Among patients who achieve a decrease in RF,

52.9% were under GC, 88.2% under csDMARDs and 26.5% bDMARDs. 43.5% of patients who decreased ACPA were under GC, 91.3% under csDMARDs and 34.8% bDMARDs.

Patients who had GC compared to those who did not had higher initial RF (\bar{x} 110.34 vs 70.61, $p=0.181$), current RF (58.58 vs 55.10, $p=0.886$) and current ACPA (257.83 vs 156.83, $p=0.374$), but lower \bar{x} initial ACPA (177.07 vs 394.52, $p=0.447$).

Those who were under csDMARDs had lower initial (79.72 vs 150.41, $p=0.188$) and current RF (\bar{x} 43.39 vs 131.80, $p=0.079$), but higher initial (319.08 vs 117.09, $p=0.618$) and current ACPA (213.54 vs 172.73, $p=0.797$).

Patients under bDMARDs had higher initial RF (\bar{x} 96.17 vs 88.68, $p=0.831$) but lower current RF (29.80 vs 65.35, $p=0.210$) and lower initial (173.92 vs 320.96, $p=0.739$) and current ACPA (173.36 vs 218.01, $p=0.739$).

Conclusion

Higher titers of RF and ACPA are usually associated with severe disease requiring aggressive therapy. Although the decline in titers after therapy that occurred in most patients may reflect an improvement, clinical manifestations and the quality of life should not be overlooked.

#2223 - Abstract

HYPONATREMIA, LIPID PROFILE AND ERYTHROCYTE ENZYMES IN CARDIOVASCULAR DISEASE IN PSORIATIC PATIENTS

Angela Gil^{1,2}, Andreia Matos^{1,2}, Ana Isabel Teixeira^{3,4}, Paulo Filipe⁴, Manuel Bicho^{1,2}

¹ Genetics Laboratory and Environmental Health Institute-ISAMB, Faculdade de Medicina da Universidade de Lisboa, Lisboa, Portugal

² Instituto de Investigação Científica Bento da Rocha Cabral, Lisboa, Portugal

³ Department of Dermatology, Centro Hospitalar do Porto, Porto, Portugal

⁴ Dermatology Research Unit, Instituto de Medicina Molecular, Universidade de Lisboa, Lisboa, Portugal

Background

Sodium is stored in the subcutaneous and muscular extracellular tissue, and the increase in extra-renal tissue has been associated with hypertension (HT), autoimmune diseases and the body's defense against infections. Studies pointed to the association of sodium in erythrocytes and hypertension. Therefore, we aimed to evaluate the sodium blood levels and erythrocyte markers in psoriatic individuals with cardiovascular risk.

Methods

In a group of 53 psoriatic patients and 358 controls, 82 (22.9%) of them has HT, where determined the hyponatremia status, electrolytes, lipid profile, and erythrocyte parameters and its enzymes (acid phosphatase, $\mu\text{mol/gHb/h}$; transmembrane reductase (TRM, mmolferr/Lcell/h ; methaemoglobin reductase-

MHR, $\mu\text{mol/gHb/min}$). Psoriasis Area and Severity Index (PASI) was evaluated, being mild psoriasis for $\text{PASI} < 10$ and moderate/severe psoriasis for $\text{PASI} \geq 10$. Statistical analysis was chi-square test, mean comparisons and Spearman's correlation with significant value for $P < 0.05$.

Results

The mean levels of sodium for psoriatic patients were $136.0 \pm 23.9 \text{ mmol/L}$ (Hyponatremia $< 135 \text{ mmol/L}$). Patients with $\text{PASI} \geq 10$ had lower concentrations of sodium ($P = 0.041$) and higher LDL-cholesterol ($P = 0.026$) and bilirubin ($P = 0.023$). Sodium levels were reflected in a direct association with mean globular volume (fL) ($r = 0.348$, $P = 0.044$), mean globular hemoglobin (pg) ($r = 0.429$, $P = 0.011$), creatinine (mg/dl) ($r = 0.325$, $P = 0.036$), chloride (mmol/l) ($r = 0.472$, $P = 0.007$), osmolality (mOsmol / kg) ($P = 0.018$). For the lipid profile, PASI was directly correlated with total cholesterol/HDL ($r = 0.385$, $P = 0.027$) and inversely with HDL cholesterol ($r = 0.469$, $P = 0.006$). On the other hand, total cholesterol was directly correlated with erythrocyte enzymes (RTMH: $r = 0.358$, $P = 0.038$ and RTM: 0.375 , $P = 0.041$).

Conclusion

The results suggest a homeostatic electrolyte dysregulation, with enzymes and parameters associated with erythrocytes modulating this profile with repercussions on cardiovascular risk of psoriatic patients.

#2233 - Case Report

LEUKOCYTOCLASTIC VASCULITIS IN A PRIMARY SJOGREN SYNDROME

Pedro Gomes Santos, Mihail Mogildea, Carolina Soares Oliveira, Júlio Lemos Teixeira, Pedro Martins Dos Santos, José Moreno, António Veiga Moura

Hospital de Faro, Faro, Portugal

Introduction

Sjogren syndrome (SS) is an autoimmune disease characterized by a lymphocytic infiltration of the exocrine glands, mainly by CD4 T lymphocytes, resulting in symptoms of xerostomia and xerophthalmia. The SS may occur as a primary disease or in the presence of other autoimmune condition (rheumatoid arthritis, systemic lupus erythematosus, inflammatory myopathy or systemic sclerosis). Sjogren syndrome is the second most common autoimmune disease, more prevalent in women between 40 and 60 years old.

Case description

Female, 47 years old, caucasian, past medical history of congenital cognitive impairment. The patient was admitted at the hospital for the study of necrotic ulcers, with 8 months evolution, in both lateral and medial malleolar regions in the left leg and in medial malleolar region on the right leg. The bigger ulcer had 6 cm longer axis. The patient also referred a painful swelling, with nodular

consistence in the angle of the right mandible and a maculopapular rash in the lower limbs and abdomen, motivating several visits to the ER, where she was medicated with several antibiotics courses. There was also history of asthenia, night sweats and weight loss (8 Kg in 9 months), as well as xerostomia and xerophthalmia in the past 4 years. In the physical examination was evident a bilateral parotid enlargement, mainly on the right side, without any palpable lymphadenopathies. The lab results revealed a microcytic hypochromic anemia, C-reactive protein 40 mg/L, sedimentation rate 42 mm/1h, elevation of the rheumatoid factor, positive antinuclear antibody and anti-SSA and hypocomplementemia (C4). Negative HIV, HCV, HBV, tuberculosis, toxoplasmosis and syphilis serology. Thoraco-abdominopelvic CT scan revealed several enlarged lymph nodes near the root of the mesentery. Skin biopsies of the affected areas and parotid biopsies were performed, revealing leukocytoclastic vasculitis and parotid lymphocytic infiltration, respectively. The diagnosis of Sjogren syndrome with leukocytoclastic vasculitis was established and glucocorticoid therapy was initiated.

Discussion

Vasculitis is one of the most common manifestations of Sjogren syndrome, and when present is associated with a more severe disease. The presence of B symptoms made us suspect the concomitance of a B-cell lymphoma, which was not confirmed. The patient had typical Sjogren syndrome symptoms, however the diagnosis delay caused a deterioration in quality of life, reinforcing the need to raise awareness for this disease.

#2242 - Case Report

PODOCYTOPATHY PRESENTING AS NEPHROTIC SYNDROME IN A PATIENT WITH UNDIFFERENTIATED CONNECTIVE TISSUE DISEASE

Pedro Gaspar, Filipe Bessa, Pedro Meireles, Catarina Mota, Rui M. M. Victorino

Serviço de Medicina 2, Hospital de Santa Maria, Centro Hospitalar Universitário Lisboa Norte, Lisboa, Portugal

Introduction

The kidney is frequently involved in the clinical course of connective tissue diseases in which a wide variety of glomerular, tubulointerstitial and vascular lesions are observed. In undifferentiated connective tissue disease (UCTD) there is evidence that renal involvement is mild and there are limited detailed histopathological studies. We report an UCTD patient who developed nephrotic syndrome (NS) with podocytopathy on renal biopsy after more than 15 years of stable disease.

Case description

A 38 year old woman, with prior medical history of Graves' disease and UCTD since the age of 20, under hydroxychloroquine 200mg/day with occasional need of oral prednisolone (maximum of 20

mg/day), had a stable course of disease since presentation, with fluctuating polyarthralgia of the small joints of the hands and asthenia, and a persisting homogenous pattern of ANA (>1/280), with no other laboratory abnormalities. She was admitted with a two month clinical course of hypertension and in the last two weeks with fronto-parietal bilateral headache (worse in the morning), blurred vision, asthenia and lower limb edema. On physical examination, blood pressure 208/110 mmHg, bilateral malleolar oedema and normal fundoscopy. Laboratory findings were as follow: urea 23 mg/dL, serum creatinine 0.83 mg/d, albumin 1.9 mg/dL, proteinuria 5989 mg/24h, albuminuria 4488 mg/24h, total cholesterol 260mg/dL, triglycerides 321 mg/dL, normal C3 and C4. ANCA, anti-dsDNA antibodies, SSA and SSB, anti-phospholipid, HIV 1 and 2, HBV and HCV were negative. Renal ultrasound was normal. Renal biopsy showed fibrous thickening of Bowman's capsule and a slight increase in mesangial cellularity in 1 of 10 observed glomeruli, associated with vestigial granular mesangial deposits of IgA and C3. Electronic microscopy showed moderate podocyte effacement, reactive segments of basal membrane, light mesangial cell hyperplasia, with no subendothelial, intramembranous, subepithelial nor mesangial electron-dense deposits, suggestive of podocytopathy. NS was admitted and she started prednisolone and cyclosporine 5 mg/Kg bid, with clinical improvement and remission of proteinuria.

Discussion

Lupus podocytopathy (LP) is a newly identified non-antibody-mediated glomerulopathy in systemic lupus erythematosus, characterized by widespread podocyte foot process effacement. Although increasingly recognized, it lacks a standard definition and diagnostic criteria. To the best of our knowledge, this is the first case of LP-like-NS in an UCSD patient.

#2246 - Case Report

RELAPSING POLYCHONDritis AND NEUROLOGICAL COMPROMISE

Roberto Miguel Cataldi Amatriain, Adel Enrique Escobar Garcia, María José Rota, Franco Gustavo Amaro, Lorena Baez
Del Carmen Clinic, Zárate, Buenos Aires Province, Argentina

Introduction

Relapsing polychondritis is a rare disease of autoimmune nature of unknown etiology, characterized by inflammation and progressive and recurrent destruction of cartilage structures with multisystem involvement. The commitment of the central nervous system is very uncommon, represents 3-5% of cases, its form of presentation is very variable as cranial nerve palsy, myelitis, polyneuritis, meningitis, meningoencephalitis, vasculitis, pyramidal and extrapyramidal syndrome, seizures, rapidly progressive dementia, and limbic encephalitis.

Case description

We present an illustrative case of a patient diagnosed 10

months ago with relapsing polychondritis who developed rapidly progressive dementia and parkinsonian syndrome as form of presentation of neurological compromise.

Discussion

The affectation of the central nervous system by relapsing polychondritis is mainly clinical and is a challenge for its forms of variable presentation, obligating the differential diagnosis with multiple entities. The laboratories can be normal and the imagenological studies are inespecific. Early clinical suspicion and start of treatment with high doses of corticoids and immunosuppressive is critical in these patients, since they can decrease the disability and the mortality.

#2248 - Abstract

ANTI-PHOSPHOLIPID SYNDROME: CLINICAL AND LABORATORIAL CHARACTERIZATION OF A COHORT IN A PORTUGUESE HOSPITAL

María Fernanda Paixão Duarte, João Pedro Figueira, Maria Inês Xavier Ferreira

Hospital Prof. Dr. Fernando Fonseca, Lisboa, Portugal

Background

Antiphospholipid syndrome (APS) is characterized by single or multiple arterial or venous thrombosis and obstetric complications in the presence of antiphospholipid antibodies (aPL), particularly lupus anticoagulant (LA), anticardiolipin antibodies (aCL) and anti β 2 glycoprotein I (β 2 GPI) antibodies

Methods

Retrospective review of a cohort of 59 patients with primary and secondary APS according to the Sydney classification criteria followed-up from 2003 to 2018. Study of their clinical processes was carried out, focused on age of diagnosis, race, gender, associated autoimmune diseases, thrombotic event (arterial or venous) and obstetric morbidity. The different aPL were correlated with clinical data

Results

A Total of 59 patients, 49 were women and 10 were men. The median age at diagnosis was 39.2 years. Primary APS was diagnosed in 45 patients and secondary in 14 patients.

Lupus was present in 7 patients; overlap syndromes in 2 patients and Behçet's disease, Sjogren's syndrome, inflammatory bowel disease, polyarthritis and rheumatoid arthritis were presented in 1 patient each.

In relation to venous thrombosis 31 patients (52.5%) were diagnosed as thrombosis in the lower limbs, 2 patients in the vena cava and in 1 patient in the upper limbs.

Pulmonary embolism was diagnosed in 25 patients (42.4%). In 12 patients (20.3%), both events were detected. Venous thrombosis was recurrent in 4 patients.

Arterial thrombosis was present in 12 patients (20.3%): 3 as acute

myocardial infarction, 3 as cerebral infarction, 2 as upper limb ischemia, 2 as intestinal ischemia, 1 as lower limb ischemia and 1 as central retinal artery thrombosis.

Obstetric complications previous to treatment were observed in 14 women (10 early fetal losses; 5 late fetal losses; 3 premature births; 3 pre-eclampsia; 1 HELLP syndrome). During treatment 11 women had 15 pregnancies (13 of term and 2 preterm), all of them live births.

In the same patient there were events of arterial, venous thrombosis and obstetrical manifestations. There was only 1 death related to catastrophic APS.

Regarding laboratorial results, LA was positive in 55 patients (93%). aCL was positive in 7 cases and β 2 GPI was positive in 7 patients as well. Triple positivity of aCL, β 2 GPI and LA was found in 4 patients.

Conclusion

Follow-up of patients with APS is important in reducing morbidity, since it usually occurs in young patients.

In pregnancy, a better outcome is observed when the patients are treated. The most frequent antibodies was LA.



OTHER

#18 - Abstract

PROTECTING AND RESPECTING INDIVIDUAL DIGNITY AT END-OF-LIFE (PRESIDE) – A RESUSCITATION STATUS DISCUSSIONS AUDIT, AND BARRIERS TO THEIR OCCURRENCE

Norshima Nashi, Benjamin Hooi, John Soong
National University Hospital, Singapore, Singapore

Background

Discussion of resuscitation status with patients/families are not done consistently by doctors. A Korean study found that 64-70% of older patients do not wish for resuscitation in event of deterioration. In a study of 5 tertiary hospitals, resuscitation status was not documented in up to 97.5% of patients.

Methods

The aims of the study were to find out the proportion of suitable patients who had their resuscitation discussed, and barriers to their occurrence. A retrospective cross-sectional audit of 127 patients admitted to the medical service of an integrated hospital assessed the proportion of resuscitation status discussed for suitable patients (defined as patients who had poor premorbid states or had one or more irreversible organ dysfunction). An online survey was undertaken among junior doctors to find out the barriers to such discussions taking place.

Results

32.3% of patients fulfilled the criteria for having their resuscitation status discussed. Out of these patients, 48.7% did not have their resuscitation discussed. 100% of the participants responded to the survey. Participants demonstrated a positive attitude towards discussion of resuscitation status. The most frequently identified barriers were lack of formal training, knowledge and confidence, difficulty in deciding patients' suitability for resuscitation, concern about difficult patients/families, insufficient time, and fear of inducing anxiety in patients/families.

Conclusion

There was a significant proportion of patients who did not have their resuscitation status discussed though they warranted it. Training should focus on imparting knowledge and communication skills. Senior doctors can facilitate this process by identifying if patients were suitable candidates for resuscitation.

#45 - Abstract

MULTI MORBIDITY IN ELDERLY PATIENTS – CROSS MACH STUDY IN GERONTOLOGY INSTITUTE

Lazo Jordanovski, Marika Ivanovska, Biljana Petreska Zovic, Jovanka Jakimovska, Lidija Miljkovic, Lidija Pavleska
PHI Specialized hospital for geriatric and palliative medicine 13 November, Skopje, Macedonia, Former Yugoslav Republic of

Background

Multi morbidity is defined as presence of two or more chronic medical conditions in individual. Multi morbidity is associated with decreased quality of life, increased healthcare utilization. Multi morbidity is defined as presence of two or more chronic medical conditions in an individual. Multi morbidity is associated with decreased quality of life, increased healthcare utilization. Multi morbidity is common in elderly patients. PHI Gerontology Institute 13 November in Skopje is institution where are hospitalized elderly patients above 65 years or younger patients with chronic progressive disease.

Methods

We create epidemiological cross-mach study and the aim of the study is to show number of patients hospitalized in PHI Gerontology Institute 13 November in Skopje, number and nature of their chronic medical conditions.

Results

191 patients, 65 males and 126 females were hospitalized in institution during this study. Average age of the patients was 77.4 years (from 27 to 96 years). Most of the patients have presence of two or more chronic medical conditions (94.7%). Most common conditions were arterial hypertension present in 58% of the patients, chronic hearth failure present in 54.9% , dementia present in 37.1%, fracture (most common hip fracture) present in 29.8%, diabetes melitus and stroke present in 28.2%. Other conditions like anemia, chronic kidney failure, chronic pulmonary disease, cancer, pressure ulcers, other neurological conditions were less represented. In average patients have around 4 chronic medical conditions.

Conclusion

Multi morbidity in elderly patients is associated with poor functional status, poor quality of life, poly pharmacy and elevated risk of death.

#55 - Case Report

COMMON VARIABLE IMMUNODEFICIENCY WITH GASTROINTESTINAL COMPROMISE: A CASE REPORT.

Diana Katherine Guavita

Fundacion Cardioinfantil, Bogota, Colombia

Introduction

The common variable immunodeficiency is part of the group of primary immunodeficiencies, occupying the second place in frequency, the first being the selective deficit of immunoglobulin A.

Case description

Patient without history starting at age 9 with diarrheic stools of secretory and osmotic features, otitis media and recurrent pneumonia. Esophagogastroduodenoscopy and colonoscopy show histological findings suggestive of autoimmune enteropathy, for which he received multiple management schemes without improvement. Tomography of the thorax evidences multiple pulmonary nodules; a fibrobronchoscopy plus biopsy was performed with a diagnosis of follicular bronchiolitis. Enter hospitalization for exacerbation of autoimmune enteropathy. It is carried again to endoscopic study, with absence of villi at the ileal level and second portion of the duodenum with pathology that reports lymphoid hyperplasia with atrophy of the crypts. A study of serum immunoglobulins with a slight decrease in IgG and IgM and Hepatitis B protective antibodies, diphtheria, pneumococcus, which are deficient despite having received immunizations. Common variable immunodeficiency is diagnosed with pulmonary and gastrointestinal involvement, treatment with immunoglobulin begins with resolution of pulmonary infections, however the gastrointestinal symptoms remained azatriopina was added with which the gastrointestinal symptomatology was stabilized.

Discussion

Common variable immunodeficiency is the most common primary immune deficiency in adults. The gastrointestinal compromise is around 10 to 20%. There is no specific therapy for gastrointestinal involvement, therapy can vary between anti-inflammatory or immunosuppressive drugs and survival is reduced, which shows the importance of knowing this pathology better in the future to offer more treatment options and improve the prognosis.

#124 - Abstract

BEWARE OF COMMERCIAL HAIR GROWTH TREATMENTS

Junji Tsukagoshi, Kando Kawahatsu, Tomohiro Mita, Satoshi Yuda, Ivor Cammack

Teine Keijinkai Hospital, Sapporo, Japan

Background

We describe a case of pericardial effusion causing cardiac tamponade, probably induced by minoxidil and finasteride, taken

for hair growth. These days, such prescription drugs are easily available online and we need to be aware of the potential for severe adverse effects.

Methods

A literature search was performed to evaluate the mechanism and incidence of the adverse effects of these drugs and to evaluate the current commercial market for these hair growth drugs.

Results

[Mechanism and adverse effects]

Both minoxidil and finasteride have known risk of pericardial effusion, but there is significantly more data for minoxidil with over 30 published case reports. An FDA review documented pericardial effusion in 1.7% and 0.21% of reported adverse effects in minoxidil and finasteride respectively. The two drugs were not co-administered in any cases, since their FDA-approved indications are different (minoxidil for hypertension and finasteride for hair growth and benign prostate hypertrophy). Finasteride blocks androgen conversion to dihydrotestosterone, and because dihydrotestosterone has negative effects on hair growth cycle and hair follicles, it promotes hair growth. However, the mechanism for pericardial effusion is unknown. Minoxidil is an ATP-sensitive potassium channel activator. A rare autosomal dominant disease called "Kantu syndrome", which causes hypertrichosis as well as pericardial effusion, is due to overstimulation of these same channels. This disease may provide a clue to minoxidil's hair growth effect.

Market:

The market for hair growth agents in 2016 was an estimated \$3.6 billion in the USA and \$617 million in Japan and both markets are forecast to grow. Same applies for the European market as well. Minoxidil tablets are not approved for hair growth in either country but are commercially available online.

Conclusion

Unapproved prescription drugs are widely used for hair gain with limited monitoring of adverse effects. In the illustrated case of pericardial effusion, this could have been fatal if the patient had continued treatment.

#136 - Abstract

ECHOGEOMETRIC INDICATORS OF MYOCARDIUM IN PATIENTS WITH CHRONIC KIDNEY DISEASE STAGE VOlimkhon Nadirkhanovich Sharapov^{1,2}, Botir Turgunpulatovich Daminov^{1,2}¹ Tashkent pediatric medical institute, Tashkent, Uzbekistan² Republican specialized scientific and practical medical center for nephrology and kidney transplantation, Tashkent, Uzbekistan**Background**

The most common cause of death for patients with chronic kidney

disease (CKD) are complications due to cardiovascular disease. Patients with CKD are classified as high/very high cardiovascular risk. The main and most significant cause of cardiovascular disorders in patients with CKD stage V is left ventricular myocardial hypertrophy (LVH), the development of which is accompanied by the occurrence of myocardial dysfunction. LVH is a risk factor for cardiac death of patients on HD.

Methods

We examined 37 patients with CKD stage V. The average age of patients was 45.5 ± 6 years. HD duration was 2.3 ± 1.1 years. All patients underwent bicarbonate programmed hemodialysis through arteriovenous fistula. Sessions of the HD were carried out 3 times a week for 4 hours. The initial mean systolic blood pressure (MAP) was 166.3 ± 11.2 mm Hg, the mean diastolic blood pressure (DBP) was 98.1 ± 7.3 mmHg. GFR was 7.4 ± 5.3 ml/min/1.73 m². Diagnosis of left ventricular hypertrophy of the left ventricle was carried out on the basis of a recommendation on the quantitative assessment of the structure and function of the heart chambers, according to which the LVMI was normally ≤ 95 g/m² for women and ≤ 115 g/m² for men. Thus, the normal geometry was considered by us with a normal value of LVMI and IRVT LV ≤ 0.42 ; concentric remodeling was evaluated by us with a normal value of LVMI and IRVT LV ≥ 0.42 ; concentric hypertrophy was considered by us with an increase in LVMI and IRVT LV ≥ 0.42 ; eccentric hypertrophy was regarded by us with an increase in LVMI and IRVT LV ≤ 0.42 .

Results

The data obtained indicate the presence of left ventricular hypertrophy and dilatation of the left and right ventricles of the heart in patients with CKD stage V without obvious pathological changes of the valve system in patients on programmed hemodialysis. Concentrated hypertrophy, eccentric hypertrophy and LV concentric remodeling were detected in the examined patients. 21 (56.7%) patients had LV concentric hypertrophy, 5 (13.5%) patients had LV concentric remodeling, 11 (29.7%) patients had LV eccentric hypertrophy. The average thickness of the interventricular septum averaged 12.1 ± 0.2 mm, the thickness of the posterior wall of the left ventricle - 11.2 ± 0.34 mm, LVMM - 267.9 ± 11.7 g, LVMI - 151.8 ± 5.7 g/m².

Conclusion

So, as shown by the results of our study, all patients with CKD stage V had LV hypertrophy, while more than half of the patients were diagnosed with concentric type of LV myocardial hypertrophy.

#172 - Abstract

INJURY PROFILE OF ELITE BASKETBALL PLAYERS IN LEBANON

Lana El Osta, Habib Aimé Hatem, Abdo El Hélou, Amine Wehbé, Nada El Osta

School of Medicine, Saint-Joseph University of Beirut, Beirut, Lebanon

Background

Basketball is one of the most popular and widely viewed sports worldwide. Despite the enormous growth of basketball practice in Lebanon, there appears to be little focus on associated injuries even at the professional level. This study aims to determine the prevalence and to describe the characteristics of musculoskeletal disorders among Lebanese elite basketball players.

Methods

A retrospective cross-sectional survey was conducted among an eligible study population of 225 Lebanese elite basketball players. Data were collected through an anonymous structured questionnaire assessing self-reported injury data from participants. A sports injury was defined as musculoskeletal condition that made the player completely abstains from training or competition in basketball for one day or more during the past year. Data were analyzed using descriptive statistics. The alpha error was set at 0.05.

Results

A total of 174 first division basketball players completed the questionnaire (response rate: 77.3%): 51.1% were female, and the mean age was 24.90 ± 5.43 years. They reported a total of 234 injuries, with a 1-year retrospective injury prevalence of 71.3% (95% confidence interval, 64.6%-78.0%). Thirty-nine respondents reported injuries to 2 body regions, and 27 reported injuries to more than 2 regions. Most of the damages affected the lower extremities (63.7%), mainly the ankle (28.2%), were associated with a sudden onset (65.0%), occurred during training session (59.4%), and in the middle of a League season (58.9%). Sprains (32.9%) and strains (30.8%) were the most common types of injuries. Players in the Forward position reported more injuries than players in other positions (-p-value-0.040).

Conclusion

Unfortunately, musculoskeletal injuries are prevalent in Lebanese elite basketball players. Future prospective studies in basketball are needed to identify groups of players at increased risk, in order to establish appropriate injury prevention strategies.

#182 - Case Report

ACUTE KIDNEY FAILURE AS THE FIRST MANIFESTATION OF ACETAMINOPHEN OVERDOSE.

Ilir Gjermeni¹, Eneida Hoxha¹, Irida Kecaj¹, Eliona Gjermeni², Mihal Tase¹

¹ University Hospital Center "Mother Teresa", Tirana, Albania; Tirana, Albania

² Specialties Health Center No.3, Tirana, Albania; Tirana, Albania

Introduction

Hepatotoxicity is the most studied feature of overdose by paracetamol, however the extrahepatic manifestations of acetaminophenic toxicity are not well described in the literature.

Acute kidney failure occurs in approximately 1-2% of patients with acetaminophen overdose. The relation between dose and nephrotoxicity is not clearly defined as in the case of hepatotoxicity.

Case description

74-year-old women patient urged in emergency as a result of an syncopal episode at home. At the emergency, the patient is in confusional condition with life parameters: TA 160/90 mm Hg, Fc 35 / min, O₂SAT 95%, ECG with block A-V gr III signs. In the biochemical emergency balance: Glyc 185 mg/dl; Urea 69 mg/dl; Creat 2.0 mg/dl; AST 75 U/l; ALT 60 U/l; Bili 0.4 mg/dl; INR 1.365; Na⁺ 133 mmol/l; K + 7.7 mmol/l; Cl - 106 mmol/l; Patient is treated for chronic pathology: HTA with ARB and HCT and DM with Insulin Lantus, Metformin, and Maninil. The patient says she has used regularly 5-6 g / day Paracetamol over the last 4 weeks due to articular pain. Fluid treatment was started, Insulin Rapid i/v + 5% glucose and NAC p.o. On the 3rd day of hospital treatment, the condition of the patient was aggravated by nausea, vomiting, and abdominal pain in the upper right quadrant. Biochemical Balance of Day 3: Glyc 192 mg/dl; Urea 86 mg/dl; Creat 2.4 mg/dl; AST 300 U/l; ALT 300 U/l; LDH 739 U/l; Bilir 0.6 mg/dl; Na + 143 mol/l; K + 5.0 mmol/l; Cl-99 mmol/l, negative HbSAg, anti-HCV negative. Fluid rehydration continued and a second cycle of NAC p.o. was repeated. On the 5th day of hospital treatment, a clinical improvement of the patient was noted, which was reflected in the following biochemical balance: Glyc 248 mg / dl; Urea 60 mg/dl; Creat 1.3 mg/dl; AST 203 U/l; ALT 483 U/l; Bilirubin 0.7 mg/dl; Na + 135 mol/l; K + 3.7 mmol/l; Cl-95 mm/. The patient left the hospital on the 10th day with normalized biochemical balance values.

Discussion

Nephrotoxicity caused by the use of acetaminophen without hepatotoxicity is rarely seen and is usually reversible. NAC therapy is recommended for the prevention of hepatotoxicity, literature has shown that NAC treatment can protect against hepatotoxicity, but this treatment is seen as ineffective to prevent nephrotoxicity.

The relation between dose and nephrotoxicity is not clearly defined as that in relation to hepatotoxicity. Acetaminophen-induced nephropathy may occur at doses lower than those seen with hepatotoxicity.

#214 - Case Report

PSYCHIATRIC DRUG OVERDOSE OR PHENOL INTOXICATION? - A CASE REPORT

Rita Avó-Baião, Diana Buendia Palacios, Carla Lopes, Sara Úria, Glória Silva

Centro Hospitalar Universitário Lisboa Norte - Hospital Pulido Valente, Lisboa, Portugal

Introduction

Intoxication by phenol, the toxic substance in carbolic acid, is becoming less common, as this compound is nowadays mostly

present only in industrial disinfectants, used to prevent animal infestations, mostly in rural settings. It has high toxicity even in small skin exposures, causing numbness, burns and eschar formation. Inhalation may cause respiratory tract irritation, oedema and pneumonia. For being highly lipophilic and easily absorbed by the central nervous system, it can cause nausea, headache and result in loss of consciousness, coma, respiratory depression, seizures and death.

Case description

We report a case of a 74- year-old woman found in her house by emergency services presenting altered state of consciousness (Glasgow Coma Scale 9), sphincter incontinence, hypertension and biliary vomit. In the emergency department, the patient presented dark extremities in upper limbs and oedema in the distal segment of the forearm, with no compromise in capillary vascular reperfusion, not appearing to have signs of arthritis or hypersensitivity. In toxic work-up, benzodiazepine and tricyclic antidepressants were positive in urine samples, cardiac assessment with EKG monitoring and flumazenil perfusion was started. In the remaining laboratory results, C reactive protein and leukocyte count were both elevated as well as creatine kinase. Chest X-ray showed no signs of pneumonia. After the patient regained consciousness, she revealed - besides taking antidepressants and benzodiazepines, as prescribed in non-toxic dosage by her family doctor - she had been manoeuvring Bicresol®, commonly known as creolin, a general-purpose disinfectant containing carbolic acid (70%) and sodium hydroxide (21%), without skin protection or face mask, and had been lying in her house for two days before emergency services had arrived. The patient recovered with no complications and was discharged after eight days of therapy with ceftriaxone as empiric therapy for aspiration pneumonia.

Discussion

Phenol usually first bleaches, then stains the skin dark and then it disappears as it is absorbed. On account of the patient's altered state of consciousness phenol poisoning was not recognized and, as the patient had been lying for two days in her house, rapid decontamination was not performed by emergency services at arrival. Urgent management should be provided by skin decontamination with polyethylene glycol or a glycerine solution and supplemental oxygen if the patient has respiratory distress.

#237 - Medical Image

IS THIS REALLY A LIPOMA?

Miriam Vieitez Santiago, Ana Isabel González-Torre González, María Elena Casuso Saenz, María Teresa Valiente Millán, Nuria Díez Herrán, Laura Gutiérrez Fernández, Raquel Jaso Tejera, Ana Campo Ruiz

Hospital Comarcal de Laredo, Laredo, Spain

Clinical summary

75-year-old female attends the internal medicine practice for right supraclavicular mass soft, about 2 cm, painless, not adhered to

deep planes and without inflammatory signs, of about 10 years of evolution that has been increasing in size slowly and progressively. She denies other clinical symptoms.

General surgical evaluation is requested. They are impressed with the lipoma and that no biopsy or further evaluation is required on their part.

Then we request ultrasound where a lesion of undetermined vascular malformative type with signs of thrombosis inside is observed.

Cervical MRI: distended venous structure with a partial repletion defect (internal thoracic vein), from the bifurcation of the right brachiocephalic trunk, compatible with a chronic partial thrombosis, with collateral formation.

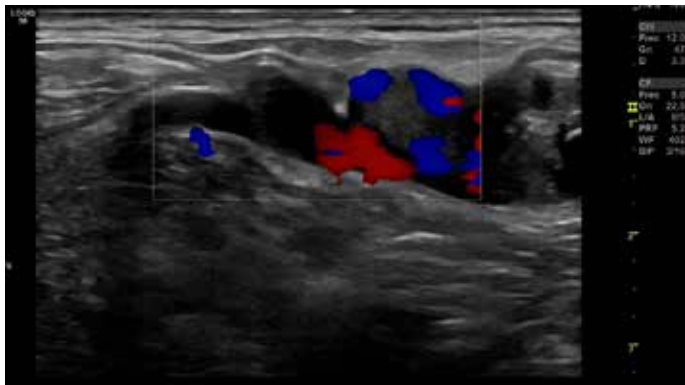


Figure #237. Right retroclavicular vascular malformation with thrombosis inside.

#278 - Medical Image

BULLOUS PEMPHIGOID WITH DIPEPTIDYL PEPTIDASE-4 INHIBITOR

Pamela Farah, Serge Barmo, Fady Haddad
Saint Joseph University, Beirut, Lebanon

Clinical summary

We show the case of a 76 year old female patient who presented a bullous pemphigoid induced by linagliptin, a dipeptidyl peptidase-4 (DPP-4) inhibitor.

The patient was born in 1942; she is known to have in her medical history arterial hypertension, treated with amlodipine and valsartan, dyslipidemia, treated with atorvastatin, Alzheimer disease, treated with memantine, and type 2 diabetes mellitus not well controlled despite insulin subcutaneous, which led her treating physician to add linagliptin in December 2017.

In June 2018, the patient presented to the emergency department for blisters on her chest, upper thigh, and face. Her current situation started 2 weeks earlier, when she presented a generalized pruritus, sores in her mouth and small blisters on the perioral region. She was treated

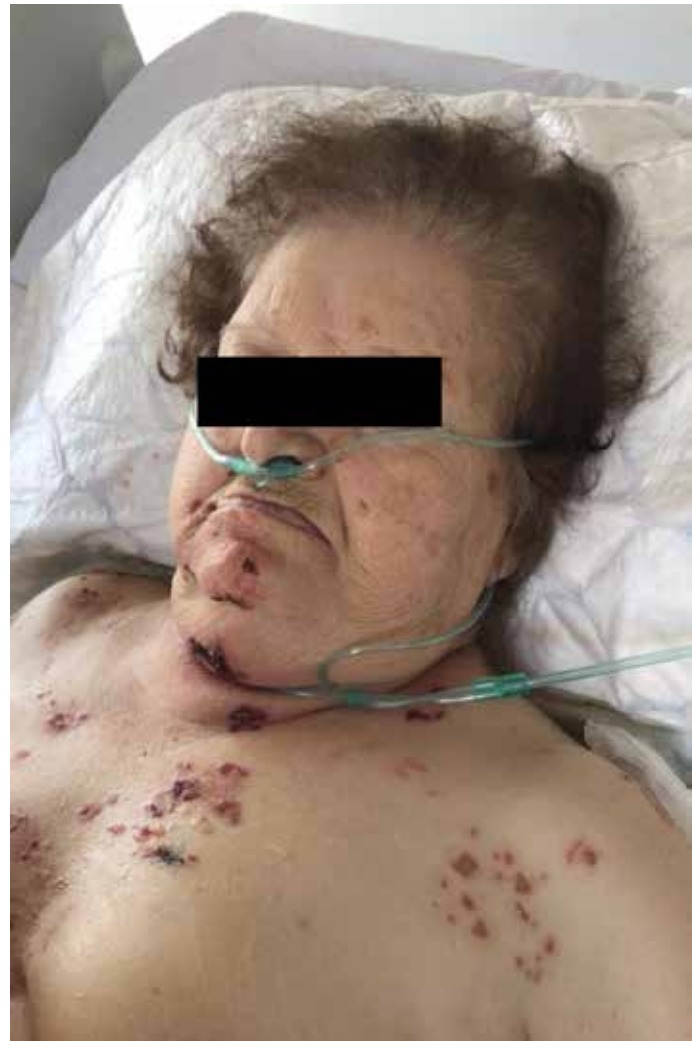

Figure #278. Bullous pemphigoid lesions.

#329 - Case Report

ANISOCORIA AND THE TONIC PUPIL

Andreea Constanta Stan, Momcilo Durdevic, Prasanta Basak, Stephen Jesmajian
Montefiore New Rochelle Hospital, New Rochelle, United States

Introduction

Described in 1931, Adie syndrome also known as the Holmes-Adie syndrome is a neurological disorder characterized by a tonically dilated pupil that reacts slowly to light but shows a more definite response to accommodation. It most commonly affects younger women (2.6:1 female preponderance) and is unilateral in 80% of cases. We present a case of incomplete Adie syndrome.

Case description

A 45 year old female presented to the outpatient medical clinic for weakness, body aches and nasal congestion for one week. Past medical history included nonalcoholic fatty liver disease and *H. pylori* gastritis. She was not on any regular medications, including any eye drops. She denied smoking, drinking alcohol or using illicit drugs.

Physical examination was remarkable for anisocoria: right pupil 5 mm, left pupil 3 mm. The right pupil had a sluggish reaction to direct and consensual light; the left pupil had a normal response. Both pupils constricted normally to accommodation. Fundoscopic exam was unremarkable. Extraocular movements were normal, no nystagmus was noted, visual fields were intact, and the rest of the neurological examination was unremarkable. Patellar reflexes were present. Apart from mild erythema of the nasal mucosa and pharynx, the rest of the physical examination was unremarkable. She was diagnosed with a viral upper respiratory tract infection, and anisocoria secondary to a tonic pupil.

Discussion

Adie syndrome is caused by damage to the postganglionic parasympathetic fibers of the eye, usually by a viral or bacterial infection. Pupillary findings are the result of inflammation and damage to neurons in the ciliary ganglion. Damage to the autonomic nervous system and dorsal root ganglia of the spinal cord can also occur, resulting in the loss of deep tendon reflexes and abnormalities of sweating. The tonic pupil may become miotic over time, which is referred to as "little old Adie's". Testing with low dose pilocarpine may constrict the tonic pupil due to cholinergic denervation supersensitivity, but not the normal pupil. The usual treatment is to prescribe reading glasses. The incidence of Adie's syndrome is 2:1000 population, and clinicians need to be aware of this non-life-threatening condition, so as to avoid unnecessary tests and imaging, which adds to the financial burden.

#359 - Abstract

MPV AND MORTALITY AMONG HEAVY ALCOHOLICS

Carla María Martín-Abreu, Iván Ribot-Hernández, Lourdes González-Navarrete, Paula Reyes-Suárez, Candelaria Martín-González, Ana María Godoy-Reyes, José Fernando Armas-González, Emilio González-Reimers

Hospital Universitario de Canarias, La Laguna, Spain

Background

Several relatively recent studies have pointed out the relationship of platelet size with increased mortality or adverse clinical course. Most of these studies have shown that increased MPV may be associated with a deleterious outcome in different settings such as sepsis or neoplasia, whereas other researchers have found just the opposite. In inflammatory conditions there is an altered secretion of several cytokines, some of them exerting a marked influence on platelet biogenesis, and/or on platelet activation and aggregation. Alcoholism is a chronic situation characterized by a protracted low-grade inflammation. The aim of this study is to analyze the relationships of MPV with tumor necrosis factor (TNF)- α , interleukin (IL)-6 and IL-8.

Methods

We study 184 patients admitted to our hospital due to organic problems related to alcohol consumption and then followed-up

for a median period of 42 months (interquartile range=12.75-88 months). Serum TNF α , IL-6 and IL-8 were determined by ELISA.

Results

We found that MPV was inversely related to TNF- α , ($\rho=-0.34$), and directly to IL-8 ($\rho=0.32$, $p<0.001$ in both cases) and to IL-6 ($\rho=0.15$; $p=0.046$). Most alcoholics continued drinking the follow-up period. Reduced MPV was related both with short-term (<6 months) and long-term mortality (92 patients died during the follow-up period), in this last case showing an independent prognostic value assessed by Cox regression analysis, although after the variables "drinking relapse" and "deranged liver function".

Conclusion

Therefore, our results suggest that inflammatory cytokines, especially TNF- α and IL-8 are strongly related to MPV. A low MPV is associated with a poor prognosis among alcoholics.

#364 - Case Report

A RARE CAUSE OF ACUTE HEPATOTOXICITY

Sara Santos¹, Mónica Pedro², Sara Gomes², Célia Carmo², Fátima Campante²

¹ Centro Hospitalar Barreiro-Montijo, Setúbal, Portugal

² Centro Hospitalar Barreiro - Montijo, Setúbal, Portugal

Introduction

Amlodipine, is a calcium channel blocker agent, with a widely known antihypertensive effect, commonly used and safe.

In very rare cases (1 in 10000), it can cause hepatitis as a side effect.

In scientific literature the authors only find a few descriptions of cases of acute liver damage induced by such medication in such a short period of usage.

The authors therefore present a case of acute hepatitis after amlodipine introduction.

Case description

79 years old, male patient, with a known history of hypertension, diabetes mellitus type 2 and chronic renal disease.

Usually medicated with carvedilol 6.25 mg 1id, candesartan 32 mg 1id, furosemide 40 mg 1id and linagliptin 5mg 1id.

The patient was hospitalised with the diagnosis of Bullous pemphigoid, for which he was being treated with glucocorticoids - oral prednisolone 80 mg/day.

With his medical history plus the treatment with glucocorticoids, there was an expected rise on his glycemic levels, therefore he was placed under insulin therapy, but also his blood pressure, which rose to a mean blood pressure of 120mmHg. For this reason amlodipine 5mg was introduced in scheme with his usual medication.

Even if the patient was asymptomatic, on the following days, his blood levels of hepatic enzymes which used to be in normal range values, started to rise, reaching a maximum peak of aspartate

transaminase 346 U/L, alanine aminotransferase 1584 U/L, Gamma-glutamyl transferase 517 U/L and alkaline phosphatase 172 U/L.

After amlodipine's withdrawal, there was a progressive decrease of these values.

Discussion

In literature there are a few case descriptions of acute hepatitis induced by amlodipine, cases like this one, might be under diagnosed, since in the majority of cases this medication is introduced in an ambulatory setting.

This patient was hospitalised and had serial blood analysis because of it, making it possible to detect in an early phase, avoiding a more serious complication.

The authors also think there might be an interaction between amlodipine and corticotherapy, that together can potentiate acute hepatotoxicity, since both are metabolised by the liver and there is yet another a case report published regarding this likely interaction.

#369 - Case Report

DRUG-FEVER: A CHALLENGING DIAGNOSIS DURING THE COURSE OF AN INFECTION

Inês Pinheiro, João Paulo Vilas-Boas, Marta Oliveira, Ana Erica Ferreira, Clarinda Neves, Rosa Jorge

Centro Hospitalar Baixo Vouga, Aveiro, Portugal

Introduction

Drug fever is a common condition characterized by a febrile response when drugs are administered and in the absence of other conditions. There are a few pathophysiologic mechanisms that have been identified; when it overlaps with the course of an infection, drug fever may deceive the clinician into believing that the antimicrobial therapy is unsuccessful. Special attention is paid to the role of antimicrobial agents in drug fever.

Case description

A 76 year-old woman, with a past history of recurrent lower limb infections, was hospitalized due to a cellulitis of the right lower limb. Three days before, the patient went to the hospital and she was diagnosed with erysipela and medicated with amoxicillin/clavulanic acid. The treatment was changed to piperacilin-tazobactam 4500 mg 6/6h and the patient had periodic evaluation by Dermatology. Although the inflammatory signs have reduced throughout time and the inflammatory biomarker C-Reactive Protein showed a slow but progressive decline, the fever recurred after 2 weeks of antibiotherapy. Therefore, Clindamycin was added on the 14th day of hospitalization and a septic screening was performed, including a local ultrasound and CT, to exclude abscess or osteomyelitis. Both results, cultures (blood and urine) and imaging study, were negative. Considering the improvement of cellulitis and the exclusion of other causes of infection, we assumed that the fever could be related to the use of Piperacilin.

Thus, piperacilin-tazobactam and clindamycin were suspended. The patient remained fever free for the rest of hospitalization (more than 72 hours after antibiotherapy was discontinued) and without evidence of skin inflammatory signs.

Discussion

Despite its common occurrence, drug fever is frequently underrecognized, underreported and misdiagnosed. Therefore, it can leads to an overutilization of medication and an elevation of the costs of hospitalization. The problem is bigger when drug fever is caused by antibiotics, during the course of an infection, because it can mislead clinicians into believing that the treatment is failing and other antibiotics are needed. The diagnosis should only be made after scrutinizing clinical presentation, medication history and laboratory results. According to current literature, piperacilin is the β -lactam antibiotic that is most related to the development of drug fever (around 35%). This case report shows an example of the difficulty of managing these cases and the need of high suspicion to consider this diagnosis.

#375 - Case Report

A CASE OF PRURIGO NODULARIS AND METHOTREXATE TOXICITY: A HAZARDOUS MISUNDERSTANDING

Mariana Brandão, Telmo Borges Coelho, Mariana Fidalgo, Maria Alves, Paula Ferreira, Manuela Sequeira, Vítor Paixão Dias

Centro Hospitalar Vila Nova de Gaia/Espinho, Vila Nova De Gaia, Portugal

Introduction

Prurigo nodularis (PN) is a rare impairing skin disorder occurring in patients with severe chronic pruritus due to persistent scratching. Low-dose methotrexate (MTX) is a therapeutic option for recalcitrant cases but can be associated with severe multisystemic toxicity.

Case description

We report the case of a 70-year-old female, with a history of depression, type-2 diabetes, chronic kidney disease and an underlying severe form of PN, refractory to previous therapies, for which she had recently been prescribed MTX (10 mg weekly, with folic acid supplementation). Unfortunately, she misunderstood the posology and took 10 mg of MTX daily for an entire week. The patient then presented to the emergency room with worsening pruritus and new-onset fever, odynophagia and painful oral cavity lesions. Physical examination disclosed multiple symmetric violaceous and pruritic skin nodules, exhibiting a typical PN distribution pattern and 'butterfly' sign [images]. Oral cavity inspection revealed mucositis with overlapping candidiasis. Laboratory tests showed acute kidney injury (serum creatinine: 3.4 mg/dl, GFR: 13 ml/min) along with leukopenia (white blood count (WBC): 610/ul) and elevated C reactive protein (CRP: 26 mg/dl). The patient was started on corticosteroids and empirical antimicrobial therapy with renal dose adjustment. Following

admission, she was febrile and developed severe pancytopenia (Hb 7.3 g/dl, WBC 430/ul, platelet count 14.000/ul) with need for transfusion support. Renal function progressively worsened (peak serum creatinine: 5.5 mg/dl) with metabolic acidemia and oligoanuria, requiring catheter-based dialysis, with subsequent recovery. Myelosuppression gradually recovered, and blood counts and CRP were within the normal range at the time of discharge. Skin and mucosal lesions also showed dramatic improvement [images].

Discussion

The described patient showed multiple MTX-related complications (oral mucositis, myelosuppression, renal dysfunction, alopecia), illustrating how challenging the use of immunosuppression can be. Severe MTX toxicity is more likely when renal impairment is present or if MTX is taken daily instead of weekly, as the patient inadvertently did. Nephrotoxicity occurs rarely with low-dose MTX therapy, but probably contributed to the patient's renal function decline in this setting. The reported case also illustrates the importance of effective communication with patients when introducing new therapeutic schemes, so that information isn't "lost in translation".

#402 - Case Report

WHEN IATROGENIC COMPLICATES HOSPITALIZATION - HEMATOMA BY ADMINISTRATION OF LOW MOLECULAR WEIGHT HEPARIN

Cármem Resende Ferreira, Mário Monteiro, Alexandra Dias, Daniela Brito, Fernanda Coutinho

CHMT - Centro Hospitalar Médio Tejo, Abrantes, Portugal

Introduction

Iatrogeny refers to the state of a disease, adverse effects or complications, caused or resulting from medical treatment. In a 1981 study one third of the diseases in a university hospital were iatrogenic (about 10% major, and 2% of patients died) and complications were more strongly associated with drugs exposure. In 2000, there were 225,000 iatrogenic deaths in the United States, the third leading cause of death.

Case description

A 81-year-old woman, with hypertension, dyslipidemia, ischemic cardiomyopathy, atrial fibrillation, type 2 diabetes mellitus and hypothyroidism, went to the emergency department with cough, dyspnea and fever. She presents signs of respiratory distress, at pulmonary auscultation with bilateral fervor. Analytically, there was an increase of inflammatory parameters and type 2 respiratory failure in gasometry. Chest X-ray documented an infiltrated at the bases. Diagnosed pneumonia, was performed a septic screening and started a empirical antibiotic therapy, without microbial isolation. On the 9th day, abdominal pain started, with cutaneous hematomas scattered through the abdominal wall and palpable

mass at the level of the hypogastro. She performed an abdominal-pelvic tomography scan and was documented "mass involving the rectus abdominis muscle suggestive of neoplastic lesion or large volume rectal hematoma (20x18x9.6 cm)". The abdomino-pelvic ultrasound confirmed the hematoma. In this context, anticoagulation was suspended with low molecular weight Heparin (LMWH) and prolonged hospitalization for surveillance of the clinical picture. Serial imaging tests were performed, always without evidence of active bleeding. During the hospitalization she presented several infectious interurrences. Due to prolonged immobilization, she needed rehabilitation treatment. After partial resorption of the hematoma it was discharged without hypocoagulation due to the increased risk of hemorrhage and follow-up and follow-up in an internal medicine appointment.

Discussion

This clinical case alerts to the importance of iatrogenesis in hospitalized patients, caused either by therapeutic measures or by complementary diagnostic tests, which is a reason for hospitalization prolongation and the development of nosocomial infections. LMWH is commonly used as thromboprophylaxis or anticoagulation in patients. Although generally considered safe, several cases of catastrophic hemorrhage have already been reported and are already associated with an increase in hemorrhagic events.

#405 - Case Report

LYELL'S SYNDROME AND ANTIBIOTICS

Catarina Cabral, Joana Alves Vaz, Maria Manuela Soares, Isabel Madruga

Hospital de Egas Moniz - Centro Hospitalar de Lisboa Ocidental, Lisboa, Portugal

Introduction

Lyell's syndrome, or toxic epidermal necrolysis, is a rare, potentially life-threatening mucocutaneous disease, usually provoked by a drug and characterized by acute necrosis of the epidermis. It is preceded by fever, general malaise, and other flu-like symptoms. Bullous and erosive lesions involve oral, ocular, and genital mucosae and vast areas of the skin with extensive dermoepidermal detachments.

Case description

73 year-old, caucasian, female. Personal background of arterial hypertension, dyslipidemia and Bell's palsy. Medicated with losartan, bisoprolol, acetylsalicylic acid, simvastatin and pantoprazole. No allergies described. Patient resorts to the Emergency Room (ER) complaining of cough and dyspnea for 2 weeks. She was diagnosed with a community acquired pneumonia (CAP) and discharged with amoxicillin/clavulanate and azithromycin. After a second administration, the patient noticed appearance of mouth ulcers, a maculopapular rash and generalized extensive blisters, returning to the ER. It was

detected round macules and papules with a central target, some with a central or peripheral blister; erosions of the oral mucosa; ocular exudate; palpebral erythema and edema. The patient was admitted for etiologic study and treatment. Due to the progressive deterioration of the rash and the respiratory function the patient was transferred to the Intensive Care Unit (ICU). During the patient's stay at the ICU, it was verified the loss of 36% of epidermis, mostly regarding the axillar, palmar and soles of feet bilaterally. The CAP progressively deteriorated, evolving into acute respiratory distress syndrome, with the necessity of endotracheal intubation and ventral decubitus. The patient completed a course of 8 days of meropenem, linezolid and 5 days of oseltamivir, but there was no isolation of pathogenic agents. The evaluation by Ophthalmology detected palpebral lesions and keratitic ulcers of the cornea. There was complete recovery of the pneumonia and the patient maintained follow-up on Pneumology, Internal Medicine and Ophthalmology.

Discussion

The drugs most frequently incriminated in Lyell's syndrome are nonsteroidal anti-inflammatory drugs, chemotherapics, antibiotics, and anticonvulsants. Even though this is a rare condition, it is important to recognize that the administration of the most dispensed antibiotics could be in its origin. Furthermore, a rapid response assumes major importance, given the great mortality associated with this entity.

#422 - Case Report

A LATE REACTION - WAITING FOR AN ADVERSE EFFECT

Maria Vilela, Cláudia Maio, Carla Melo

Centro Hospitalar do Médio Ave, Vila Nova De Famalicão, Portugal

Introduction

Adverse reactions to any medication, although commonly, are not always immediate. Sometimes the secondary effects only present itself after days, weeks or even several months of initiating that particular drug. Therefore, a high level of alert should be in any clinician mind when presented with a signal or symptom without any other more fitting explanation.

Case description

A 65-year-old woman with a history of controlled arterial hypertension presents to the Emergency Department with a pruriginous erythematous maculopapular rash, in the anterior cervical area, that started the previous week. The patient denied any change in food habits, hygiene products and detergents. She also denied contact with animals, chemicals and travels to other countries. She had started to take spironolactone, as prescribed by her physician, in the past 3 months, in detriment to an angiotensin-converting-enzyme inhibitor (ACE-I) that she used to take. The rash was soft, hot and had irregular borders clinical examination. The patient's laboratory results did not report any irregularity. She

was advised to stop taking spironolactone and resume the ACE-I that was previously prescribed. After 2 weeks she was contacted and reported that the rash had resolve 2 days after stopping spironolactone. After a 1-year follow-up, she denied resuming the spironolactone and having more similar episodes.

Discussion

Although the frequency is not defined, an erythematous maculopapular rash is a rare adverse reaction to spironolactone and one of the most benign secondary effects. There are no precautions described when prescribing spironolactone to cutaneous afflicted individuals. A thorough clinical history should be taken and if any suspicion of iatrogeny arises, the drug should be, if possible, suspended or switched.

#497 - Abstract

SAFETY AND EFFICACY OF OUTPATIENT FOLLOW-UP FOR REFERRED PATIENTS WITH UNDIAGNOSED FEVER

Yukinori Harada, Mikako Masuda, Takanobu Hirosawa, Hiroshi Takase, Kohei Morinaga, Michihiro Nin, Taro Shimizu
Dokkyo Medical University, Shimotsuga-Gun, Japan

Background

The safety and efficacy of outpatient follow-up for referred patients with unexplained fever remain unclear. Therefore, we conducted this study to determine the admission rate, diagnostic rate, and outcome of referred patients with unexplained fever during outpatient follow-up.

Methods

We conducted a retrospective cohort study. We included patients referred to the outpatient department of the diagnostic medicine of our university hospital for unexplained fever between October 2016 and September 2017. Exclusion criteria were recurrent fever or admission for fever evaluation prior to referral. The decision of admission and choice of treatment were left to the discretion of the physician following the assessment of the severity of the condition and needs of the diagnostic tests. However, in general, antibiotics were not prescribed to patients without bacterial infection and were discontinued at the time of the referral visit when no bacterial infection was found. The outcomes of interest in this study were the ratio of admission for diagnosis (excluding patients admitted after diagnosis), the ratio of patients followed up as outpatients without diagnosis, the ratio of defervescence during follow-up in patients followed up as outpatients without diagnosis, and the total duration of fever in patients followed up as outpatients without diagnosis.

Results

A total of 84 patients were included. Seventeen (20%) patients were diagnosed during outpatient follow-up: 12 had infectious diseases, three had noninfectious inflammatory diseases, and two

were classed as miscellaneous. In the remaining patients without a diagnosis, six (7%) were admitted due to a worsened condition and five (6%) lost to follow-up. A total of 56 patients (67%) were followed up as outpatients without a diagnosis. Among them, none died, and fever resolved in 53 during follow-up with or without treatment (95%). Fever sustained for 3 weeks the least in 63% of these 53 patients, but almost all reported defervescence within 8 weeks. These patients were either not treated ($n = 17$; 32%) or treated using acetaminophen or nonsteroidal anti-inflammatory drugs ($n=32$; 60%), antibiotics ($n=3$; 6%), or Chinese herbal medicine ($n=1$; 2%).

Conclusion

Follow-up of patients referred for unexplained fever in an outpatient setting is safe and effective.

#534 - Medical Image

ONE OF THE OLDEST CLINICAL SIGNS

Diogo Faustino, Liliana Antunes, Isabel Baptista

Central Lisbon University Hospital Centre - S. José Hospital, Lisbon, Portugal

Clinical summary

86-year-old man, long time smoker, previously diagnosed with metastatic lung adenocarcinoma. Admitted with a respiratory infection that improved with treatment. On physical examination, he showed exuberant finger clubbing (shown on image). Initially described by Hippocrates on a patient with empyema and one of the oldest clinical signs, it comprises an enlargement of the distal phalanges with an angle of Lovibond (between the proximal fold and nail) $> 180^\circ$. While unknown, the most widely accepted mechanism involves a right-to-left shunt with circulating megakaryocytes bypassing the pulmonary circulation, depositing in distal capillary beds (i.e. upper digits) and producing vascular and mesenchymal growth factors which induce hypertrophy and hypervascularization of the distal phalanges.

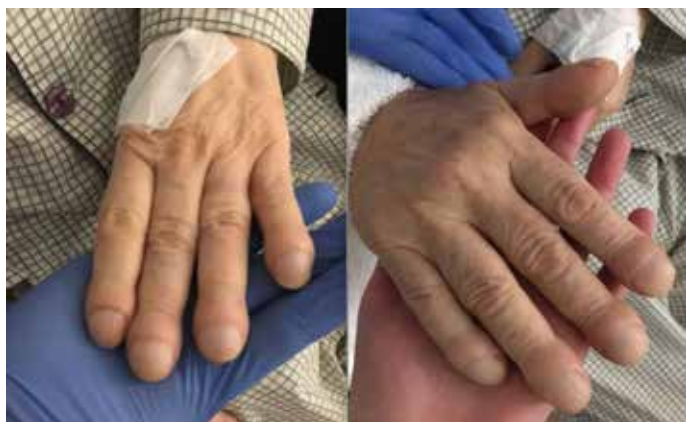

Figure #534. Finger clubbing. Distal phalangeal hypertrophy on both hands.

#563 - Abstract

QTc INTERVAL. HEART DISEASE, DEMENTIA AND DRUGS

JL Hernandez, P Cuadros, G Orbe, I Corcuera, A Montero

Alto Deba Hospital, Mondragon, Spain

Background

To determine the QTc interval associated factors in our patients

Methods

We realized a retrospective review of 500 medical records of our center. Inclusion criteria were patients of any age and sex and exclusion criteria were cases with pacemaker use, ionic disorder, thyroid disease, class Ia, Ib and III antiarrhythmic drugs. It was not considered as drugs interaction (DI) if association was defined by clinical protocols.

We collected diagnoses at discharge, laboratory data, prescribed medication and QTc interval (QTc-I) calculated by Bazett formula. We look for a relationship between QTc-I, common diagnoses and drug interactions (DI). We specially identified DI that involve the QT-I, as the patients with multiple DI.

There were obtained epidemiological and analytical data from medical records and statistical significance was established for p value < 0.05

Results

Cases were: 251 men and 249 women. Mean age was 76.5 years old who consumed a mean of 7.1 drugs. The mean QTc-I was 457ms and was prolonged in 88 patients with previous or current heart failure (HF) (470 ms; $p: 0.0027$), 91 cases with atrial fibrillation (AF) (472 ms, $p: 0.0002$), 230 with high blood pressure (HBP) (472 ms, $p < 0.02$), the group with amiodarone use ($p: 0.0008$) and 117 patients with anticoagulation (458ms, $p < 0.02$).

Furthermore, QTc-I was normal in patients with bronchopathy, diabetes mellitus, hypoxemia, anemia, renal failure, oxygen supplementation, drugs for dementia, beta-blockers or calcium channel blockers use or other frequent clinical conditions. Antidepressants or neuroleptics use without significative DI did not have prolonged QTc-I either.

Surprisingly, in 130 cases with dementia, average QTc-I was 464 ms ($p: 0.02$) and was very associated with antidepressants and neuroleptics use as well as multiple drug interactions ($p: 0.0001$ in all cases).

Conclusion

Acquired prolonged QTc-I was associated with heart failure and very likely structural heart disease. Drugs or interactions did not justify it because were uncommon. In contrast, dementia cases prolonged QTc-I only was associated with drug interactions. Heart disease or other comorbidities did not explain changes in QT in this patients because its incidence was not high.

#571 - Case Report

IDIOSYNCRATIC REACTION TO SULFASALAZINE: THE IMPORTANCE OF A DETAILED CLINICAL HISTORY

Diana Pinho Santos, Adelino Carragoso, António Correia
Centro Hospitalar Tondela-Viseu, Viseu, Portugal

Introduction

Sulfasalazine is an anti-inflammatory drug used in the treatment of many rheumatic diseases. However, it is associated with a high incidence of idiosyncratic adverse events, with a frequency up to 30% of adverse events within the first 3 months of treatment. Treatment should be started at low doses with gradual increase, always under concomitant surveillance and laboratory monitoring, minimizing adverse effects.

Case description

A 55-year-old woman was admitted to the hospital with a 6-day history of high fever and evanescent rash of the trunk and limbs. Her medical history was unremarkable except for a recent diagnosis of rheumatoid arthritis for which she was treated with sulfasalazine 500 mg twice daily for the three weeks before this admission. On examination, she had fever (T 38.5°C) and a diffuse non-pruritic maculopapular rash covering her trunk and limbs. A full blood count showed leukopenia (3 G/L), without eosinophilia, and thrombocytopenia (114 G/L). Liver function tests showed aspartate-amino-transaminase 14x upper limit of normal, alanine-amino-transaminase 24x upper limit of normal, alkaline phosphatase and gamma-glutamyl-transferase 10x upper limit of normal, without hyperbilirubinemia, with normal coagulation and renal function, and C-reactive protein 8.80 mg/L. Other tests including iron kinetics, ceruloplasmin, autoimmunity and infectious serologies were normal. Bacterial cultures of urine and blood were sterile. Imaging tests including chest x-ray and abdominal ultrasound showed no changes. Diagnosed probable idiosyncratic reaction to sulfasalazine, the drug was withdrawn, and supportive therapy was instituted. Fever subsided two days later, the rash resolved and blood tests steadily improved. She was discharged and one month later she remained asymptomatic, with normalization of laboratory parameters.

Discussion

We report this case to highlight the significance of a detailed drug history whenever a patient presents with pyrexia of unknown origin and systemic manifestations. The spectrum of adverse reactions is varied, and some are severe, such as marked changes in liver function tests. In addition, many times drug reaction can be confused with a simple infectious intercurrent delaying its suspension which is crucial to avoid more severe conditions such as DRESS, Stevens-Johnson Syndrome and Lyell Syndrome.

#598 - Case Report

ADVERSE DRUG REACTION WITH EOSINOPHILIA AND SYSTEMIC SYMPTOMS: DRESS SYNDROME- CLINICAL CASE

Hilda Freitas¹, Natalia Oliveira¹, Antonio Cabral¹, Paulo Ferreira²,
Vanessa Machado², Cristina Ramalho²

¹ TrofaSaude Hospital Braga Sul, Braga, Portugal

² TrofaSaude Hospital Braga Centro, Braga, Portugal

Introduction

Drug reaction with eosinophilia and systemic symptoms (DRESS) is a rare, potentially life-threatening, drug-induced hypersensitivity reaction that includes skin eruption, hematologic abnormalities (eosinophilia, atypical lymphocytosis), lymphadenopathy, and internal organ involvement (liver, kidney, lung). DRESS is characterized by a long latency (two to eight weeks) between drug exposure and disease onset.

Case description

The authors describe a clinical case of 88 years old women, autonomous, with a medical history of Ischemic cerebrovascular disease, dyslipidemia, degenerative osteoarticular disease and congestive heart failure. Medication at home: Etoricoxib, Sertraline, Rosuvastatin, Bromazepam, Buspirone and Clopidogrel. She went to the the emergency department for Congestive Heart Failure Decompensated with Edema of the Lower limbs with about 8 days of evolution and dyspnea for efforts in progressive aggravation. Good response to diuretic therapy.

During the first days of hospitalization, she was subfebrile and generalized pruritic cutaneous rash appeared; eosinophilia was documented. She had hepatocellular dysfunction and acute renal injury. Statin was stopped. Skin biopsy was performed. Testing for Epstein-Barr virus (EBV), cytomegalovirus and human herpesvirus were negative. Mycoplasma pneumoniae serology and blood cultures were negative. Cutanea Biopsy: "epidermis with spongiosis and superficial dermis with edema and infiltrate of mononuclear cells and some eosinophils. The changes are consistent with toxicodermia. "She presented a favorable clinical and analytical evolution after the introduction of corticotherapy. Later she began a different statin, different from the previous one. It maintains follow-up in consultation of Internal Medicine, being asymptomatic.

Discussion

An early diagnosis and immediate suspension of drugs involved are therefore imperative. However, there are no established diagnostic criteria for DRESS syndrome, which is based on clinical and laboratory changes. Immediate withdrawal of the causative drug and initiation of adequate medical treatment is the mainstay in the management of DRESS syndrome.

DRESS syndrome is a pathology that puts the patient's life at risk. Its mortality rate is high, estimated at close to 10%. Hepatic and cardiac failure are the main complications that lead to the death of these patients.

#599 - Case Report

HEPATITIS DUE TO MUSHROOM YUN ZHI WEN CONSUMPTION- CLINICAL CASE

Hilda Freitas¹, Natalia Oliveira¹, Antonio Cabral¹, Paulo Ferreira², Vanessa Machado², Cristina Ramalho²

¹ TrofaSaude Hospital Braga Sul, Braga, Portugal

² TrofaSaude Hospital Braga Centro, Braga, Portugal

Introduction

Mushroom poisoning occurs frequently, but serious toxicity is uncommon. There are 12 groups of identified mushroom toxins with 14 described clinical syndromes. Defining which clinical syndrome predominates, initiating general supportive care, and administering any specific treatments for that syndrome are the key steps in the recognition and management of mushroom poisoning.

Yun Zhi (*Coriolus versicolor* mushroom) has non-specific immunomodulatory properties and is therefore used as a nutritional adjuvant for balancing the immune system. Composition of *Coriolus versicolor* Polysaccharides, proteoglycans, enzymes and secondary metabolites (terpenes, alkaloids, steroids) are the main components responsible for their immunomodulatory activity. The above maximum daily intake should not be exceeded.

Case description

The authors describe a clinical case of a 73 years old woman, autonomous and independent, with a medical history of Crohn's disease; Medication at home: mesalazine, pantoprazol, prednisolon.

She was with complaints of generalized asthenia, anorexia, associated with abdominal discomfort, and without changes at intestinal transit. Since then she began mushroom intake in capsules by indication of the daughter. Appearance from that time of diarrheal, 7-8 daily, without blood, mucus or pus. No fever. She turned to the Emergency Department. She had hepatocellular dysfunction and thrombocytopenia. Normal abdominal ultrasound. She presented favorable clinical evolution. When discharge date she was with normal intestinal transit. There was normalization of liver enzymes and platelet counts. It maintains follow-up in consultation of Internal Medicine, being asymptomatic.

Discussion

Mushroom ingestion occurs frequently, but serious toxicity is uncommon. In most cases, the specific species of mushroom consumed is unknown. When serious mushroom poisoning does occur, it typically results from misidentification by amateur foragers.

The authors intend with this case to recall the importance of the clinical history, reminding that often, if not questioned, the patient will not talk about the intake of mushrooms.

#608 - Case Report

VORICONAZOLE AND HALLUCINATIONS

Sara Muñoz Alonso, Victoria Palomar Calvo, Víctor Madrid Romero, Carlota Tuñón De Almeida, Esther Fraile Villarejo, Montserrat Chimeno Viñas, Luis Miguel Palomar Rodríguez
Complejo Asistencial de Zamora, Zamora, Spain

Introduction

Visual hallucinations can be due to a many etiologies, among the drug are found antifungals such voriconazole. The visual hallucinations are described as an adverse effect. There are some cases published in the literature of visual hallucinations in patients with malignant haematological disease receiving voriconazole for the treatment of pulmonary aspergillosis.

Case description

A 58 years old, male, smoker and a drinker of 4-5 beers a day. He is hypertensive and in 2017 have presented an episode of cerebral ischemia in the lacunar territory. He gone to hospital with a right eye infection with a high suspicion of evolution to fungal keratitis and endophthalmitis.

On 72 hours after admission, he says he sees images of men when he closes his eyes and these images disappear with the eye opening. He is anxious and the situation causes great discomfort. No other associated symptomatology.

The physical, analytical and cranial CT scan do not present relevant findings. He is on oral treatment with prednisone (40 mg/24h), doxycycline (100 mg/24h), voriconazole (200 mg/12h) and valacyclovir (500 mg/12h) and topical vancomycin, voriconazole, ceftazidime, chlorhedine and atropine. Given the suspicion of hallucinosis due to voriconazole, the treatment is discontinued and the symptoms disappear after 24 hours

Discussion

Visual hallucinations with voriconazole are described in the cases report and pharmacokinetic studies^{2,6,7,8}. This visual disturbance has been described as enhanced light perception, blurred vision, photophobia or color vision changes. Although this reversible and temporary visual disturbance.

There have been few cases report in the literature and were found immunosuppressed patient and visual hallucinations in pulmonary aspergillosis therapy with voriconazole.

This disturbance is related to the high plasma concentration voriconazole, to the interaction with cytochrome P450, to direct effect toxic voriconazole on the retina and individual variation..

This case report don't have immunosuppression. The visual disturbance is different etiologies: direct toxic effect fluconazole on the retine in eye with infectious disease and probably high plasma concentration voriconazole (we not be document).

There are authors who recommend information patients with probable visual reversible disturbances if they receive voriconazole.

#638 - Abstract

THYROID DYSFUNCTION OF A CHILD WHOSE MOTHER UNDERWENT EXAMINATION USING OIL-SOLUBLE IODINATED CONTRAST MEDIUM (LIPIODOL)

Tadashi Hongyo, Yukimitsu Sawai, Yasuyuki Ueda

Osaka University Graduate School of Medicine, Suita, Japan

Background

There are occasional reports suggesting that administration of Lipiodol, an iodinated agent used in examinations such as hysterosalpingography (HSG) induces thyroid dysfunction not only to the mother but also to the fetus and the newborn. We examined the influence of Lipiodol on child's thyroid function in mice by administering Lipiodol to its mother.

Methods

12 week-old ICR female mice were intraperitoneally administered with Lipiodol once before mating, and the thyroid uptake rate of I-131 (74 kBq/mouse) in their newborn mice was examined 24 hours after oral administration of I-131. The dose of Lipiodol used was either equivalent to that used in humans (0.2 mL/kg BW) or its 1/2 or 1/10 amount. When the offspring mice reached 4 weeks of age, serum TSH and FT4 were measured by ELISA method. The number of mice in each experiment was 6 or more.

Results

When Lipiodol (0.2 mL/kg BW) or its 1/2, 1/10 amount were administered intraperitoneally before pregnancy (5 days before gestation), thyroid uptake rate of I-131 in 5-day-old infants decreased to 24.4%, 24.0% and 58.7% compared to control, respectively. There was no change in TSH level in infant mice at 4 weeks of age, but a significant decrease in FT4 was observed.

Conclusion

These results suggest that the amount of Lipiodol used in examinations should be kept as little as possible, and that thyroid function in children born after examinations using Lipiodol needs to be carefully observed.

#654 - Case Report

"DOCTOR, MY TONGUE IS SUDDENLY SWOLLEN!": TWO CASE REPORTS OF ACE INHIBITOR-INDUCED ANGIOEDEMA AND REVIEW OF LITERATURE

Dolores González Vázquez, Marta Rafael Marques, Maria Alexandra Duarte, Susana Marques De Sousa, Catarina Patronillo, Lilian Maia, Teresa Pinto

Centro Hospitalar Póvoa de Varzim, Vila do Conde, Porto, Portugal

Introduction

The multidirectional mechanism of action of angiotensin converting enzyme inhibitors (ACEI) makes these drugs the

most commonly used in vascular diseases. Unfortunately, in this pharmacological group, the effect of bradykinin is not limited only to beneficial activities, it may also contribute to the appearance of some adverse effects, such as cough or angioedema (AE). AE by ACEI occurring in 0.1-0.7% of patients taking ACE inhibitors. The increased use of ACE inhibitors since the 1980s has led to a parallel increase in adverse effects, notably angioedema. Risk factors are: female gender, > 65 a, smokers, other previous allergy, diabetes, obesity or obstructive sleep apnea syndrome (OSAS). The role of genetic factors has also been discussed.

Case description**Case 1**

A 72-year-old man, who was referred to the emergency department (ED) for swelling of the tongue 3 hours ago, described similar episodes in recent years (edema of the lips and tongue and edema of the face). History of arterial hypertension, diabetes mellitus (DM). Chronically medicated with enalapril, insulin, metformin, carvedilol, simvastatin. He presents asymmetric edema of the tongue, without airway compromise, without auscultatory and hemodynamically stable changes. He was medicated with corticoid and antihistamine. The first episodes of edema were related to the beginning of the treatment with ACEI. The drug was replaced with calcium channel antagonist, without new episodes until now.

Case 2

A 78-year-old man with hypertension, DM, dyslipidemia (DL) and ischemic heart disease. Usually medicated with acetylsalicylic acid, rosuvastatin, lisinopril, carvedilol and insulin, goes to the ED due to edema edema from the left tongue to the oropharynx, without reaching the uvula, without dyspnea or dysphagia. He was treated with clemastine and methylprednisolone. Once other causes were excluded, AE was probably a result of ACEI. The drug was replaced by a calcium channel blocker.

Discussion

At present, the therapeutic safety of elderly patients is especially important, where the geriatric population increases rapidly. AE due to ACEI is usually treated in the ED with corticosteroids and antihistamines, although these therapies are totally ineffective, which may contribute to the delay in the administration of targeted treatment.

Knowledge of drugs developed in recent years that inhibit the conversion of cininogens into kinins (eg, ecallantide) or act as selective bradykinin B2 receptor antagonists (icatibant) is critical.

#689 - Case Report

TOXIC EPIDERMAL NECROLYSIS DUE TO ALLOPURINOL

Ana Morais Alves¹, Sofia Perdigão¹, Ana Rafael², Cristiana Sousa¹, Paula Vaz Marques², Francisco Esteves²

¹ Centro Hospitalar de Trás os Montes e Alto Douro, Chaves, Portugal

² Centro Hospitalar de Trás os Montes e Alto Douro, Vila Real, Portugal

Introduction

Toxic Epidermal Necrolysis (TEN), Lyell's Syndrome, is a rare and severe mucocutaneous reactions characterized by extensive necrosis and detachment of the epidermis frequently triggered by medication. TEN involves detachment of more 30% body surface area (BSA), occurs in any age and is more common in women. TEN was high morbimortality.

Case description

A 68-years-old woman with history of hypertension, hyperuricemia, auricular fibrillation under anticoagulation, heart failure and epilepsy. Presents at urgency due to painful diffuse exanthema, fever, malaise, myalgia and bilateral purulent conjunctivitis with 3 days of evolution; she started 8 days ago allopurinol. Physical exam with facial erythema, bilateral purulent conjunctivitis, oral mucosa with hemorrhagic erosion, ear phlyctena, diffuse exanthema with phlyctenas on thorax involving limbs and palms; tender skin to the touch; Nikolsky sign on abdomen and hands; fever, tachycardia and tachypnea. Blood test with thrombocytopenia, acute kidney injury, glycosuria, electrolytes, hepatic function, coagulation without alterations; urine test with leucocytes; thorax radiography without acute lesions. It was ordered blood and urine cultures, suspended allopurinol and started empiric antibiotic with amoxicillin clavulanate and fluid therapy. Ophthalmology excluded corneal involvement and otorhinolaryngology confirmed hemorrhagic erosions on oral mucosa, palate and arytenoids. She presented mucocutaneous lesions of 35% BSA, fever and recent introduction of allopurinol so after other causes excluded, it was assumed TEN, the prognostic score SCORTEN was 3, started also corticoid, silver sulfadiazine and chlorhexidine. She developed sepsis due to urinary infection a klebsiella pneumoniae multisensitive and progress of mucocutaneous lesions. It was added immunoglobulin's and moved to a burn unit, where she was during a month, initially septic shock with multiple organ dysfunction with necessity of invasive ventilator support and large spectrum antibiotics then she had a favourable evolution and began the re-epithelialization, she needed physical rehabilitation due to prolonged hospitalization and complications.

Discussion

The prognosis and severity of TEN depends upon the amount of skin detachment and complications, prognostic SCORTEN was 3 with 50% of mortality and she had complication: septic shock. Although bad prognosis and gravity of disease she recovered, it is important an initial aggressive approach and the reference to experienced burn units.

#723 - Abstract

LOW ALT LEVELS AND MORTALITY IN INPATIENTS

Derya Kayas, Betül Türker Çavusoglu, Süleyman Ahabab, Fatih Türker, Esra Ataoglu

Haseki Training and Research Hospital, Istanbul, Turkey

Background

ALT value is the cheapest laboratory parameter used in the diagnosis and follow-up of the patient. It is related to liver damage, viral hepatitis, alcohol, some drugs, NAFLD, obesity, autoimmune hepatitis, metS, celiac disease and increased muscle damage ALT. The extremely low ALT value may reflect the aging process and may be the clinically significant feature of increased frailty in older adults. In our research we examined the relationship between low level ALT level and mortality

Methods

In the first six months of 2014, 1164 patients, 593 women and 571 men aged over 18 years, who were admitted to the internal medicine clinic of Haseki Training and Research Hospital were included in our study. Their 4-year mortality was analyzed. Comorbidities and alanine aminotransferase (ALT) and other biochemistry parameters were recorded using hospital data. Hospital serum ALT value above 35 and patients with chronic liver disease and malignancy were excluded from the study.

Results

A total of 943 over 18 years old patients of which 593 female and 571 male were included in our study. Their 4 years of mortality level was analyzed. Comorbidities and their effects were evaluated. The patients who have chronic liver disease and whose level of ALT is above 35 were not included in our study. The risk of mortality was found to increase with age (57.10 ± 18.06 ; 72.92 ± 13.29 p: 0.001>). The ALT value was found to be statistically lower in patients with exitus during 4 years of follow-up (16.22 ± 7.50 14.79 ± 7.0 p: 0.003, respectively) All patients were sorted from small to large according to ALT level.

Conclusion

Situations where ALT activity is lower than normal are less researched and published.

In our study, we found that serum ALT levels were associated with mortality at the end of the fourth year of follow-up of patients treated in the internal medicine clinic. In our study, although age and ALT level were negatively correlated, long-term 4-year mortality was associated with mortality independent of age in the first 25% of the lowest ALT level. When ALT level mortality was evaluated in patients over 65 years of age, low ALT level was not significant. In these patients, the major factor influencing mortality was advanced age. In patients under 65 years of age, low ALT levels, independent of age, increased mortality significantly. Increased fragility risk is important for mortality. It is important to have a biomarker to detect this beforehand.

#750 - Medical Image

A RARE CAUSE OF ABDOMINAL ANGINA

Diana Martins Oliveira, Inês Nunes, Patrícia Dias, Armando Carvalho

Coimbra University Hospital, Coimbra, Portugal

Clinical summary

The median arcuate ligament (MAL) syndrome is a rare condition that results from the compression of the celiac axis, causing symptoms like postprandial abdominal pain, epigastric bruit or weight loss, more common in females aged 40-60; symptoms can persist from 3 months-10 years. 77-year-old woman came to the emergency room for epigastric pain. She reported episodic epigastric pain and nausea without vomiting since the age of 45, with spontaneous resolution. Blood tests and abdominal ultrasound were normal. An abdominal angio-CT was performed: high-grade stenosis of the celiac axis origin, due to extrinsic compression by the MAL was identified. We adopted a watchful waiting approach. Surgery is the only effective approach, but angioplasty or endovascular stenting can be considered.

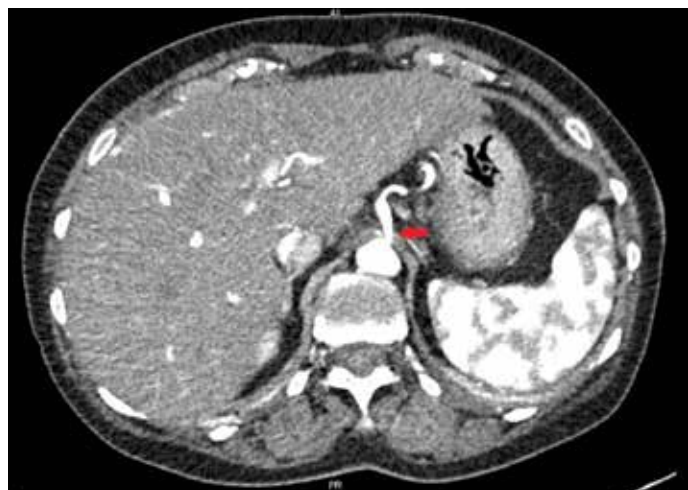

Figure #750.

#757 - Abstract

DETECT SUBCLINICAL HYPOTHYROIDISM IN PATIENTS WITH CKD TREATED IN PD AND CARDIAC ALTERATIONS.

Virginia H Sánchez-Hernández¹, Marcela Avila², Ramón Paniagua², Carmen Mora², Carmen Prado²

¹ Hospital General de México, México, Mexico

² Unidad de Investigación Médica en Enfermedades Nefrológicas, Hospital de Especialidades, CMN Siglo XXI, México, Mexico

Background

Subclinical hypothyroidism is the most frequent thyroid dysfunction described as a clinical problem in patients with chronic kidney disease (CKD), the prevalence increases especially in patients on peritoneal dialysis (PD), these patients are susceptible to develop different cardiac disorders.

Methods

Objective: Detect the presence of subclinical hypothyroidism in patients with CKD treated in PD and cardiac alterations.

Methods: Design Cross-sectional study, patients with PD onset of less than 6 months were studied; plasma determination of thyroid hormones, thyroid stimulating hormone (TSH), total triiodothyronine (T3T), free triiodothyronine (T3L), total thyroxine (T4T), free thyroxine (T4L) by radioimmunoassay, 12-lead electrocardiogram and echocardiogram with echocardiograph type 3D

Results

Results: Ninety-six patients, sixty men and thirty-six women were studied, with mean age of 47.1 years, body mass index of 25.3 Kg/m², systolic blood pressure 135.2 mm Hg, and diastolic blood pressure of 82.6 mm Hg. Forty-seven (49.9%) of them were diabetic and 83 (86.4%) were on the continuous ambulatory peritoneal dialysis program (CAPD). 30.2% of them had T3T <0.6 ng/mL, only 5.2% had TSH ≥ 4.5 μU/mL, in correlation analysis we found an association over posterior wall in diastolic and systolic blood pressure, and T3T with p <0.000, T4T and ratio of E/A wave with p 0.05, the posterior wall in diastole with TSH p 0.02, the association between diabetic and non-diabetic patients with the posterior wall in diastole was associated with value of p 0.05, septum in diastole value of p 0.02, E/E' p 0.04, lower vena cava pressure p 0.01, T3T p 0.003

Conclusion

Subclinical hypothyroidism is present in 53% of patients with CKD in PD, the most frequent cardiac alterations found were left ventricular mass growth and left ventricular diastolic dysfunction, which is a long-term contributing factor to heart failure, one of the main causes of mortality in Mexico.

#776 - Case Report

CONSEQUENCES OF MISCOMMUNICATION AND IATROGENIA

Sofia Tavares¹, Vanessa Chaves¹, Marta Marques², Inês Ferreira¹, Filipe Conceição¹

¹ Centro Hospitalar São João, Porto, Portugal

² Centro Hospitalar Póvoa de Varzim / Vila do Conde, Póvoa De Varzim, Portugal

Introduction

Methotrexate is widely used in the treatment of autoimmune diseases. Rarely, it can be associated with severe side effects such as myelosuppression with pancytopenia and agranulocytosis, hepatotoxicity, pneumonitis and renal toxicity.

Case description

Fifty-four year-old man with psoriasis recently prescribed with 7.5 mg 12/12h once per week. About 10 days after the start of the treatment he developed purpuric lesions and fatigue, and decided to

stop the treatment. Four days after he presented in the Emergency Department in septic shock with an extended bilateral pneumonia, with several organ failures: kidney (creatinine 4,2 mg/dL), respiratory (PaO₂/FiO₂ 232), cardiovascular (hypotension, Lactate 6 mmol/L) and pancytopenia with neutropenia (hemoglobin 7 g/dL; 0 neutrophils e platelets <10.000 uL). C reactive protein of 562 mg/L. Medical treatment was immediately started with crystalloids, antibiotics (linezolid and meropenem) and granulocytes growth factors. There was no need of vasopressors. Methotrexate dosing was low. Myelogram revealed a hypocellular bone marrow without other anomalies. After discussion it with the patient we realize he had misunderstood the dermatologist instructions and he had been taking methotrexate daily.

Prophylaxis against opportunistic infections were started. No bacteria were isolated in blood or sputum samples. Urinary antigens for Pneumococcus and Legionella pneumoniae were negative. Epstein Barr virus, herpes simplex virus and citomegalovirus serology's were also negative. Although cardiovascular, renal and hematologic dysfunction improve. Respiratory dysfunction persisted and CT show several areas with ground glass opacity. A methotrexate-induced pneumonitis was suspected and empiric treatment with prednisolone 1 mg/Kg/day was started, with subsequent clinic improvement.

Discussion

Doctor-patient communication is essential and when it fails, it can lead to life-threatening iatrogenic complications.

#785 - Abstract

CLINICAL CHARACTERISTICS AND OUTCOMES FOR PATIENTS WITH A SEPSIS-RELATED DIAGNOSIS IN MULTIDISCIPLINARY HOSPITAL IN LATVIA

Laura Puceta^{1,2}, Uga Dumpis^{1,2}

¹ Pauls Stradins Clinical University Hospital, Riga, Latvia

² University Of Latvia, Faculty Of Medicine, Riga, Latvia

Background

Sepsis and septic shock are life threatening emergency conditions induced by infection with increasing reported incidence, which is likely associated with greater recognition, aging population with significant comorbidities. It is common cause of hospitalization and impose a growing burden on healthcare services. Although true incidence is unknown estimates indicate that sepsis is a leading cause of critical illness and mortality worldwide. Limited data are available on characteristics and outcomes of sepsis and septic shock in Latvia.

Methods

In retrospective cohort study we enrolled 159 patients with sepsis-related ICD-10 codes upon discharge, admitted to clinical university hospital in Latvia between September 2017 and February 2018. Demographic data and information on risk factors, clinical characteristics, diagnostics and mortality were collected and analysed.

Results

Majority of patients (59%) had community-acquired sepsis. The most common causes of admission were infectious (41%), cardiovascular (18%) diseases and neurological conditions (17%). Referrals from long-term care facilities and other hospitals were 8% and 11%, respectively. Respiratory tract infections, particularly pneumonia, urinary tract and abdominal infections were the most common sites of origin. The rate of positive blood cultures was 60% with predominance of methicillin-sensitive *S.aureus*, being the most common microorganism in community-acquired, healthcare-associated and hospital-acquired sepsis groups, and *E.coli*. No multiresistant bacteria were detected in community-acquired sepsis patients. The hospital mortality rate was 51%, in cases of septic shock – 91%. The comorbidity score in non-survivor group was significantly higher (p<0.001).

Conclusion

The mortality rates are considerably higher than demonstrated in other studies, furthermore, the number of patients enrolled indicates that sepsis and septic shock cases are underreported on a national level. Sepsis diagnosis should always be considered in severely ill patients not only if signs of infection are obvious, but also in cases with manifestations of organ dysfunction. Awareness of public and medical society should be raised to facilitate the early recognition of sepsis and organ failure, thus improving outcomes.

#820 - Abstract

PARTICULARITIES OF ERYTHEMA NODOSUM IN TUNISIA: A DESCRIPTIVE STUDY

Maissa Thabet, Monia Karmani, Jihed Anoun, Fatma Ben Fredj, Amel Rezgui, Chedia Laouani

Université de Sousse, Faculté de Médecine de Sousse, Hôpital Sahloul, Service de Médecine Interne , Unité de Recherche de Gériatrie et Gériologie Clinique, Sousse, Tunisia

Background

Erythema nodosum, a painful disorder of the subcutaneous fat, is the most common type of panniculitis. It may be the first sign of a several diseases. The diagnosis is based on symptoms. We aim to study the features, common causes and treatment of Erythema nodosum.

Methods

It's a descriptive and retrospective study of clinical and paraclinical features and therapy approach of cases of erythema nodosum seen in the internal medicine department of Sahloul's university Hospital (Tunisia) over a period of 10 years.

Results

A total of 95 patients were included in these analyses, with a mean age of 40 years (16-78) and a male-to-female ratio of 1:8. There was a history of erythema nodosum in 26% of cases.

The nodules occurred most over on the legs symmetrically

(96%). The most common associated symptoms were joint pain (65%) and fever (29%). The triggers of erythema nodosum in this study included streptococcal infection (n=40), medicines (n=11), Behçet's disease (n=7), Sarcoidosis (n=5), tuberculosis (n=5) and pregnancy (n=2). Erythema nodosum was idiopathic in 28% of cases. Under bed rest, anti-inflammatory drugs and treatment of underlying condition, the nodules resolved in an average of 32 days. Recurrences had occurred in 21.4% of cases in a delay of 7 months.

Conclusion

Causes of erythema nodosum are variable from a country to another. In Tunisia the most common cause is streptococcal infection, while tuberculosis is becoming less frequent.

#848 - Abstract

PHYSIOPATHOLOGICAL CONSIDERATIONS ON THE TEMPERATURE COMPLEXITY ANALYSIS. AN ALTERNATIVE APPROACH TO CLINICAL THERMOMETRY

Paula González¹, Borja Vargas¹, Ana Colás², Andrea Perez¹, Luis Vigil¹, Manuel Varela¹

¹ Hospital Universitario de Móstoles., Madrid, Spain

² Hospital Universitario 12 de Octubre., Madrid, Spain

Background

Body thermoregulation is a complex systemic process regulated by numerous factors, which dynamically balance the central and peripheral components. New mathematical approaches based on nonlinear dynamics could bring more information about body homeostasis offered by temperature behavior.

Approximate Entropy (ApEn) is used for assessing the complexity of this type of physiological signals. It has been widely used in the analysis of time series in cardiovascular and heart rate (HR) dynamics and their relationship with cardiovascular dysautonomy. Recently ApEn has been introduced in the field of thermometry. Our research attempts to determine its relationship with sympathovagal disbalance of difficult assessment in the clinical practice.

Methods

Prospective observational study in healthy controls and outpatient diabetic patients from our hospital. 24 hour records of the tympanic (Tc) and distal skin (Tp) temperature were collected through continuous monitoring with a holter device. Index of comorbidity, diabetes and symptoms of dysautonomia were collected. We performed Semmes-Weinstein monofilament, 128hz tuning fork testing and a battery of autonomic function tests. ApEn was analyzed over sections of 720 minutes without disconnections

Results

We collected 16 series of 24 hours from 14 healthy individuals and 2 patients with diabetes. None of them had symptoms

of dysautonomia or physical examination findings. Due to disconnections in one series, 15 uninterrupted sections were used for ApEn analysis.

Individuals with pathological values in the deep breathing test (2 diabetic patients and 2 healthy controls) showed significantly lower ApEn Tc than individuals with normal results in the breathing test ($t=-3.74, M=0.27$ vs 0.71 $p=0.03$). Only one diabetic patient had abnormalities in the HR response to standing but ApEn Tp showed significant correlations with this test in the whole sample ($r=0.82$ $p=0.04$). No pathological values were found in handgrip, orthostatic blood pressure or Valsalva tests. Their correlations with ApEn showed congruent trends but did not show significance.

ApEnTc was significantly lower in diabetic patients than in healthy individuals ($t=-5.07, M=0.25$ vs 0.69 $p=0.02$).

Conclusion

Complexity of body temperature regulation seems to be correlated with other measures of autonomic function. Analysis of body temperature time series may offer information about subtle disturbances of autonomic nervous system.

#891 - Abstract

BEHCET'S DISEASE AND COMORBIDITIES

Najeh Adaily, Jihed Anoun, Maissa Thabet, Imen Saoud, Fatma Ben Fredj, Monia Karmani, Amel Rezgui

University of Sousse, Department of Internal Medicine Sahloul, Geriatric UR17SP06, Sahloul Hospital, Faculty of Medicine of Sousse, Sousse, Tunisia

Background

Behçet's disease is a multi-systemic inflammatory vasculitis, affecting the young adult with predilection. The clinical expression of this disease is dominated by cutaneo-mucous, ocular, neurological and vascular involvement. The comorbidities associated with this disease are obviously important to consider in the management of these patients.

Methods

This is a retrospective study over a period of 26 years, from 1993 until 2019, twenty patients with Behçet's disease, requiring hospitalization in the internal medicine department of the hospital Sahloul Sousse (Tunisia).

Results

There were 5 women (25%) and 15 men (75%) with an average age of 40 years with extremes of 21 and 65 years. The average duration of disease progression was 13 years with extremes of 2 and 33 years. Cutaneous and mucosal involvement was present in all patients as aphthosis and / or pseudo folliculitis. Vascular involvement was noted in 65% of cases: 7 cases of deep vein thrombosis of the lower limbs, 2 cases of pulmonary embolism,

one case of cerebral venous thrombosis, 3 cases of aneurysm. Ocular involvement was observed in 60% of cases including 7 cases of retinal vasculitis, 3 cases of uveitis, one case of episcleritis and one case of proliferative diabetic retinopathy. Eleven patients had neurological involvement (55%), 7 of which were behcet-specific, one case of brain abscess, one case of arachnoidocele, one case of diabetic neuropathy and one case of cervico-brachial neuralgia. Five of our patients were hypertensive (25%). An endocrino-metabolic problem (diabetes and / or dyslipidemia) was noted in 5 cases (25%). Hematologic involvement accounted for 20% of cases including 2 cases of iron deficiency anemia, 2 cases of hyperlymphocytosis. Respiratory disease was observed in 3 patients (15%). Two patients (10%) had kidney damage in the form of renal lithiasis and diabetic nephropathy. An anxiety disorder was noted in only one case. Only one patient had digestive vasculitis. No cardiac, hepatic, ENT or genitourinary involvement was noted.

These comorbidities were assessed by the Cumulative Illness Rating Scale (CIRS) score: all patients had a moderate to severe disorder (> or = 2) of at least one organ or system. the comorbidity score was 4 with extremes of 2 and 7 systems achieved. The total comorbidity score was between 3 and 17 with an average of 8.

Conclusion

Chronic conditions, including systemic diseases such as behcet's disease, rarely occur in isolation. Cumulative comorbidities are associated with a po

#892 - Case Report

CEREBRAL VASCULITIS WITH PLAUSIBLE DUAL ETIOLOGY

Najeh Adaily, Jihed Anoun, Imen Saoud, Maissa Thabet, Monia Karmani, Fatma Ben Fredj Ismail, Chadia Laouani

University of Sousse, Department of Internal Medicine Sahloul, Sahloul Hospital, Faculty of Medicine of Sousse, Sousse, Tunisia

Introduction

Cerebral vasculitis (CV) is a rare condition. They may be part of systemic, infectious, neoplastic or toxic inflammation, defining secondary cerebral vasculitis. The etiological diagnosis is difficult especially when the VC is inaugural.

We report the case of dual etiologic cerebral vasculitis: an LES and a CMV infection.

Case description

It is a 23-year-old patient with no notable pathological history who was hospitalized for the treatment of inflammatory polyarthritis of the large joints and general deterioration of the condition in a fever setting. On examination she had a diffuse maculopapular rash and muscular deficit of the scapular and pelvic girdles. During her hospitalization, she had had a decline in vision with neuropsychiatric symptoms such as delusions and hallucinations. MRI brain showed an aspect of cerebral vasculitis. Retinal angiography showed arterial and venous vasculitis. In

biology she had leuco-lymphopenia, autoimmune haemolytic IgG anemia, hypocomplementemia and proteinuria at 0.5 g / 24h. Anti-nuclear Antibodies returned positive at 1/3200 with positive anti-nucleosome and anti-native DNA (> 200). Viral serologies (HIV, HCV, HBV and EBV) were negative. The CMV serology was in favor of an evolutionary infection.

Cutaneous biopsy + IFD revealed an aspect of leukocytoclastic vasculitis with a lupus band.

The diagnosis was cerebral vasculitis during SLE and progressive CMV infection.

The patient received high dose corticosteroids, boli of cyclophosphamide, ganciclovir and polyvalent human immunoglobulins. The evolution was gradually favorable.

Discussion

The etiological diagnosis of cerebral vasculitis remains laborious. Our case illustrates the diagnostic difficulties and highlights the seriousness of CMV infection in the LES.

#911 - Abstract

SOCRATIC'S MAIEUTIC IN TEACHING INTERNAL MEDICINE - A METHOD FOR LEARNING AND CONNECTING KNOWLEDGE IN A SAFE AND RESPECTFUL WAY

António Pais-De-Lacerda

Faculty of Medicine University of Lisbon, Lisbon, Portugal

Background

Small-group student's teaching of internal medicine in the last year of medical school is based on the discussion of the clinical issues of each case, elaborating differential diagnoses, and reviewing the topic(s) concerned. Medical 'pimping' has been a method often used by medical educators, reinforcing their hierarchical and knowledge power, much humiliating the students, and creating a traumatic and counterproductive environment of learning. We intended to evaluate the usefulness / effectiveness of the Socratic's "maieutic" method, in which systematic (stress-free) questioning is used to build-up links of already known or investigated concepts.

Methods

Discussions of the patients' cases (often with multiple comorbidities) were conducted in 1.5h sessions, 3 times a week, in which the students were led to recall and interconnect pathophysiological and clinical concepts applicable to each situation. Every 15 days clinical vignettes were distributed to the students (covering other subjects not yet found in inpatients) with questions referring to the clinical status of the patients a few days later, so that each student should determine what could have happened to him, until that moment, when presenting symptomatology different from the inaugural one. Example: "Ten days later the patient is in an ICU, under mechanical ventilation and with acute renal injury. Explain what happened in the

meantime". Several paths/answers are possible - the student will have to study/learn and reconstruct logically the clinical evolution of the patient. The different possibilities were discussed in the next small-group session.

Results

At the end of the rotation of internal medicine teaching/learning period the students answered on the method that: They had managed to think about the patients' problems with concepts already forgotten; they better understood logical clinical reasoning; they understood and internalized better (than previously) different reasons leading to the same clinical problem; they felt a strong motivation for their study at home, investigating in a detective way the various possibilities that could lead to the evolution of the diseases.

Conclusion

The Socratic's method used in teaching internal medicine in the last year of medical school is feasible in small-group sessions, provided that questions are formulated so as to generate intuitive answers. This approach can also stimulate students' research and learning in their home study.

#1027 - Abstract

STUDY OF POST-TRAUMATIC STRESS IN HEALTH PERSONNEL WHO HAS PARTICIPATED IN EVENTS WITH MULTIPLE VICTIMS

Pascual Valdez, Bibiana Abaz, Virginia Babbino, Marcela Volpi, Gabriel Orlando

Vélez Sarsfield Hospital, Caba, Argentina

Background

In each catastrophe there are always sequels in the individual, in the community and in the environment, in the witnesses or in the health workers.

Objectives

To detect the prevalence of post-traumatic stress (PTS) and its consequences in health workers who have participated in an event with multiple victims (VM)

Methods

Self-administered survey of health workers linked to emergency care. Randomized sampling.

Results

128 professionals. Female predominance (59%). The average age was 36.6 years, and that of work in the emergency area: 18.2 years. 92.18% thought that at the time of the victims' attention, they felt that they were working as a team in their place of work. At 30 days, 94 people (73.43%) manifested symptoms of PTS, the most common being: recurring memories (46.87%), difficulty

falling asleep (23.43%), alteration in concentration (22.65%) and hypervigilance (26.56). 26.56% answered that the care of multiple victims affected their work. 18.75% said that the alterations listed above caused significant clinical discomfort, or deterioration in work, social or other areas of their lives. 83.30% of the respondents who presented symptoms requested psychological help, of which 54.99% obtained some final diagnosis (post-traumatic stress, anxiety disorder and normal response to this type of situation) and 23% had to continue with prolonged psychotherapy.

Conclusion

The prevalence of PTS is high after an VM, and in a good percentage it affects its daily task.

#1047 - Abstract

PROFILE OF SEPTIC PATIENTS ADMITTED IN INTERNAL MEDICINE WARD OF A SMALL HOSPITAL IN A CITY IN THE STATE OF SÃO PAULO, BRAZIL

Mario Angelo Cenedesi Junior^{1,2}, Alessandra Peçanha Viana¹, Renata Trivelato Felício Cenedesi³

¹ Senhor Bom Jesus Hospital, Monte Azul Paulista, Brazil

² Sao Paulo University, Ribeirao Preto, Brazil

³ Brazil University, Ribeirao Preto, Brazil

Background

Sepsis can be defined as a systemic response to an infectious disease, whether caused by viruses, fungi or protozoa. Manifesting itself as a clinical process of the same pathophysiological process, it is a challenge for the doctor of virtually all specialties, to give a prompt and fast treatment. Estimates indicate that there are approximately 600 million cases of sepsis in Brazil each year. Many studies the profile of patients care in ITUs, but have the risk studies the profile of patients in the patients of Internal Medicine Ward (especially considering the few available ICU beds, which are more suitable for more severe cases, such as septic shock). Thus, this study aims to show the profile of septic patients of a Internal Medicine Ward, a small secondary hospital in a small city in the state of São Paulo, Brazil.

Methods

It is a research of an observational nature. We analyzed the medical records of the patients who were hospitalized in the Internal Medicine Ward of our institution, with a clinical picture compatible with sepsis/septic shock, interned from October 2018 to April 2019.

Results

Of the 641 hospitalizations presented in the period, 13 patients presented sepsis / septic shock, corresponding to 2.02%. Women correspond to 61.5% of the cases, with the age range between 67-91 years. The main focus was pulmonary, with 07 cases, followed

by urinary focus (05 cases) and 02 cases with cutaneous focus (in one case we had pulmonary and urinary focus). All patients received protocol of volume expansion, collection of exams and antibiotic therapy in the first hour of arrival at the service. Of the 13 cases, 04 (30.8%) gave entry as septic shock, or evolved to, even with treatment. Regarding the resolution of the cases, 05 patients were discharged after hospitalization and treatment in our ward (with the problem solved), 05 were transferred to a larger service (going to ICU - all survived, receiving discharge) and 03 died in our ward.

Conclusion

We observed that our data are in agreement with the world literature on the subject, although there is little scientific data about septic patients hospitalized in Wards. From the observed and now known profile, we can reorganize the service, reallocating funds and human resources, and give continuous training to the professionals involved, in order to minimize the complications and deaths of this disease that is still the reason for so much discussion in the medical environment.

#1062 - Abstract

SPONTANEOUS HEMATOMAS IN ANTICOAGULATED PATIENTS

M. Purificación Sánchez Oliva, Marta León Tellez, Igor Andronic, Carlos Hernando Martín, Juan Carmona, Rubén Berriel, María José Redondo

Complejo Hospitalario de Soria, Hospital Santa Bárbara, Soria, Spain

Background

To describe the clinical characteristics of patients diagnosed with spontaneous muscular hematomas receiving anticoagulant treatment, as well as the predisposing factors and their therapeutic management.

Methods

Retrospective descriptive study of patients diagnosed in the Soria Healthcare Complex during 2018. Epidemiological data, comorbidity, anticoagulant treatment, location, diagnostic tests and treatment are analyzed.

Results

The median age was 85.5 years, 55% women and 45% men. Of them, they continued treatment with low molecular weight heparin at therapeutic doses a 36%, heparin and acenocoumarol a 27%, heparin and antiaggregation a 18% and a 18% was under treatment with apixaban. The most frequent triggering factor was heparin injection. 81% were hypertensive and 36% had chronic renal failure. The treatment was conservative in most cases. Invasive treatment was performed only in 2 patients, 18%.

Conclusion

Hematoma is more frequent in patients undergoing treatment with low molecular weight heparin and acenocoumarol (bridging

therapy) and in women over 85 years. Associated comorbidities are mainly arterial hypertension and renal failure. The size of the hematoma and the transfusion requirements are most related to the need for invasive treatment.

#1063 - Case Report

EXPRESSIVE EXERTIONAL RHABDOMYOLYSIS WITHOUT ACUTE KIDNEY INJURY

Carolina Morna, Jéssica Chaves, Carolina Barros, Tiago Esteves Freitas, Maria Luz Brazão

Hospital Central Funchal, Funchal, Portugal

Introduction

Rhabdomyolysis is a clinical syndrome characterized by striate muscle necrosis with release of intracellular contents into circulation. The level of serum creatine kinase (CK) is typically elevated and patients can present myalgia and myoglobinuria. There are some potential causes of rhabdomyolysis that can be divide in: traumatic, exertional and non-exertional non-traumatic. The severity of the condition varies from asymptomatic CK elevations to a life-threatening situation, with renal failure, compartmental syndrome or hydroelectric disturbance.

Case description

A 34-year-old male, healthy, amateur cyclist taking multivitamin and protein supplements. Presented to the Emergency Department with a sudden onset of severe muscle pain on the lower limbs, continuous at rest, that started after high intensity training (cycling), on day before admission. On physical exam the patient was afebrile, hemodynamically stable, only positive for a discrete splenomegaly and tenderness to palpation of the lower extremities, bilaterally, with palpable dorsal pedal and posterior tibial pulses. No trophic lesions or temperature asymmetry. Laboratory data on admission showed CK 40.900 UI/L, GOT 1800 UI/L, GPT 49 UI/L.

The patient was admitted with the diagnosis of rhabdomyolysis for monitoring and fluids. Serial blood samples showed a markedly enzymatic raise, with a CK peak at 128.010,00 UI/L and hepatitis pattern, with significant elevation of liver function tests at day 3: GOT 6307 UI/L and GPT 2076. INR and bilirubin were always at normal values, as renal function (creatinine 0.9 mg/dl). Hepatitis panel was negative. CT scan of lower limbs showed marked heterogeneity and enhancement of the muscle groups of thighs, legs, iliopsoas and gluteal muscles, with important edema. Viral serology and autoantibodies were negative. The electromyogram was normal.

The patient was discharged eight days later, with evident clinical improvement and normalization of the lab values.

Discussion

The aim of this report was to present a case of exertional rhabdomyolysis with a rare and extreme elevation of CK, without renal failure or other important complications.

#1073 - Case Report

AN UNCOMMON CAUSE OF POLYARTHRITIS: BASED ON A CASE REPORT

Ana Rocha Oliveira, Marcelo Sousa Aveiro, Carolina Amado, Mariana Silva Leal, Tatiana Rodrigues

Centro Hospitalar do Baixo Vouga, Aveiro, Portugal

Introduction

Polyarthritis is a condition that is referred frequently to Internal Medicine. The causes are various just like infections, autoimmune diseases, metabolic disorders, substances deposition, among others.

Case description

A 36-year-old man, has referenced to Internal Medicine by asthenia and polyarthralgias with inflammatory characteristics. History of dyslipidemia treated with atorvastatin 10 mg/day. At physical examination he presented with painful mobilization of the wrist, metacarpophalangeal, shoulder and knee joints. Laboratory tests showed hemoglobin 17.3g/dL, hematocrit 50%, VS and PCR elevated, saturation transferrin 98.15%, ferritin 702 ng/mL, without cholestasis. The immunological study was negative. The abdominal ultrasound and radiographic study of hands, shoulders and knees were normal. Genetic study confirmed hereditary haemochromatosis (HH), with the presence of the C282Y mutation in homozygosity of the HFE gene. Magnetic resonance showed iron overload in liver. Clinical improvement after anti-inflammatory and phlebotomie therapy.

Discussion

HH is an autosomal recessive genetic disorder and is characterized by iron accumulation in various tissues, resulting in tissue damage and organic functional compromise. Arthritis is a early symptom that can mimic another diseases like rheumatoid arthritis. Iron deposition in the joints is one of the factors associated with the development of arthritis in these patients, and phlebotomies have little influence on the improvement of joint symptoms. This case report alerts for a less frequent cause of polyarthritis, emphasizing the importance of the systematic approach of the differential diagnosis.

#1143 - Medical Image

A CASE OF TRICOLOR FINGERS

Catarina Cascais Costa¹, Joana Costa²

¹ Centro Hospitalar Baixo Vouga, Aveiro, Portugal

² Centro Hospitalar Universitário de Coimbra, Coimbra, Portugal

Clinical summary

Raynaud's phenomenon is a relatively common but often unrecognized clinical syndrome. The authors present the clinical case of a 73-year-old female patient who is followed for of asymmetric, migratory polyarthralgias, with morning stiffness at limbs and associated with complaints of Raynaud's phenomenon.

On objective examination she had facial telangiectasias, edema and rigidity of the hands. She had positive inflammatory markers, anti-nuclear antibodies, anti-centromere antibodies and a capillaroscopy compatible with autoimmune disease with active sclerosis component.

Differentiating between primary and secondary Raynaud's is important as secondary Raynaud's can be complicated by digital ischemia and gangrene whereas primary Raynaud's is generally a benign condition.

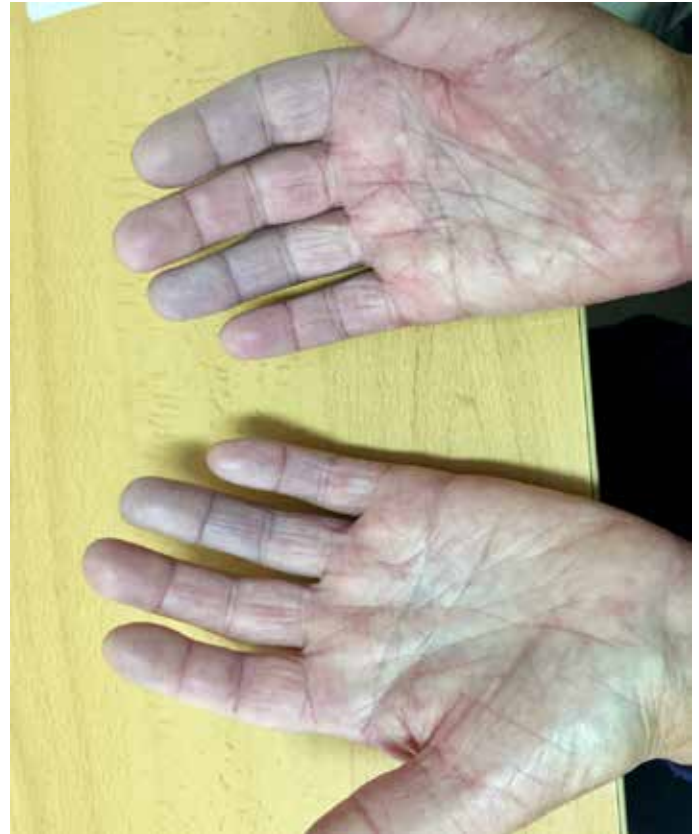

Figure #1143. Raynaud's phenomenon.

#1146 - Case Report

AGRANULOCYTOSIS INDUCED BY CLOZAPINE, A RARE AND POTENTIALLY FATAL SIDE EFFECT

Maria João Gomes, Inês Bargiela, Ana Sofia Ventura

Hospital Professor Doutor Fernando Fonseca, Amadora, Portugal

Introduction

Clozapine is an atypical antipsychotic and the only effective drug used in the treatment of resistant schizophrenia. However, its use is limited due to agranulocytosis side effect that can be severe and potentially fatal, although rare. Patients treated with clozapine need a leukogram with absolute count of neutrophils regularly, and in case of a low white-cell count, the drug administration should be immediately stopped. The incidence of this side effect increases with age and is more frequent in female patients.

Case description

The authors present a case of a 27-year-old male patient diagnosed with refractory schizophrenia, without other relevant diseases, treated with clozapine, in a total dose of 300 mg per day, which developed agranulocytosis, with neutrophil count of 0/L, for 10 days, despite the immediate suspension of the drug. He was medicated with a colony-stimulating factor (filgrastim) during this period, with a modest rising of the neutrophil count at day 11. Due to immunosuppression condition, the patient developed pultaceous tonsillitis managed with penicillin. Although antibiotic therapy, the patient presented with febrile neutropenia without no other signs of infection and from the list of complementary research carried out, a computerized tomography of the thorax showed a healthcare-associated pneumonia. He underwent a bronchoscopy, and the bronchoalveolar lavage did not identified any etiological pathogen, and he was treated with meropenem and vancomycin with recovery of the infectious condition and the number of neutrophil granulocytes.

Discussion

Agranulocytosis occurs in about 1% of patients treated with clozapine. With this case, the authors intend not only to highlight this possible side effect and related infectious complications and to emphasize the fact that pharmacological prescription is not a risk-free medical act. Therefore, the prescribing physician should always present all potential side effects of the drugs, even the rarest ones.

#1238 - Abstract

RESIDENT BURNOUT IN INTERNAL MEDICINE RESIDENTS OF MURCIA

Ignacio Iniesta-Pino Alcázar, María Del Carmen Hernández Murciano, Elena Del Carmen Martínez Cánovas, Carlos Báguena Pérez-Crespo, Gabriel Puche Palao, Vicente David De La Rosa Valero, Lia Ferraro, Mónica Martínez Martínez, Francisco Javier Hernández Felices, Ana Martín Cascón
Hospital General Universitario Reina Sofía, Murcia, Spain

Background

Our purpose is to measure, in residents of Internal Medicine of the Region of Murcia, the three aspects that make up the Burnout Syndrome:

- Emotional exhaustion: values the experience of being emotionally exhausted by the demands of work.
- Depersonalization: value the degree to which each one recognizes attitudes of coldness and detachment.
- Reduced personal and / or professional realization: evaluates feelings of self-efficacy and personal fulfillment at work.

Methods

Analysis of Maslach Burnout Inventory - human services survey (MBI-HSS) results applied to residents of Internal Medicine of the Region of Murcia through an anonymous online questionnaire.

Results

The instrument was applied to 29 residents (sample) out of a total of 48 (population), which constitutes 60.4% of the residents studied. Of these, 41.4% are male and 58.6% are female.

1. Results of the Maslach Burnout Inventory: It's observed that only 2 residents (6.9%) do not present compatible results with Burnout, the remaining 27 (93.1%) residents have burnout in at least one of the studied areas.
2. Results of the Depersonalization dimension: 15 residents are depersonalized (51.7%) and 8 are prone to depersonalization (27.6%).
3. Results of the reduced dimension personal or professional realization: 21 residents manifest reduced personal fulfillment (72.4%) and that 6 are prone to it (20.7%).
4. Results of the Emotional Exhaustion dimension: 17 residents show emotional exhaustion (58.6%) and 8 are prone to manifest it (27.6%).

Conclusion

The results collected show a high degree of burnout among residents of the Region of Murcia. It would be interesting to analyze these results in depth and compare them with residents of other specialties, and veteran internists to better understand the causes and be able to act on them.

#1245 - Case Report

ACCIDENTAL POISONING WITH METHOTREXATE

Marta Soares Carreira¹, Inês Albuquerque¹, Rita Silva², Rosa Margarida Cardoso³, Isabel Eira³, Ana Lima Silva⁴, Fernando Friões¹

¹ Centro Hospitalar Universitário de S. João, Porto, Portugal

² Centro Hospitalar do Nordeste, Bragança, Portugal

³ Hospital de Braga, Braga, Portugal

⁴ Centro Hospitalar do Médio Ave - Unidade de Famalicão, Famalicão, Portugal

Introduction

Methotrexate (MTX) is a folate antimetabolite widely used as a systemic immunosuppressive agent in autoimmune and oncologic diseases. MTX use can be associated with a variety of adverse effects over a wide range of severity. The risk of most side effects is influenced by the MTX dose and treatment regimen.

Case description

A 72-year-old male presented to our emergency department with a week onset diarrhea. No history of fever was reported. His medical history was notable for type 2 diabetes and hypertension. He also reported symmetrical aching and stiffness about the shoulders and hip girdle over the last three months and was started, by his private physician, on etorocoxib 90mg id and prednisolone 2,5mg id, and later, MTX 2,5mg id (cumulative

dose 43mg/m²). On physical examination, oral grouped vesicles and white plaques on the oral mucosa, palate and tongue were apparent. Relevant laboratory test results on admission were as follows: hemoglobin=10.1g/dl, WBC=1010/mm³ (700 neutrophils/microL), platelet counts = 180,000/mm³, urea = 155 mg/dl, creatinine=3.32 and C-reactive protein= 441.0 g/dL. The patient was started on aggressive fluid reposition with saline 0,9%, ciprofloxacin, fluconazole, acyclovir and folinic acid, with improvement of renal function and hematologic counts over the next three days. Herpes Simplex type 1 was identified on pharyngeal exudate and Streptococcus pneumoniae on one set of blood cultures although no infiltrate was found on plain chest radiograph. The patient completed 10 days of antibiotherapy. Subsequent autoimmunity testing was normal. A diagnosis of polymyalgia rheumatica was made and the patient was discharged on prednisolone 20 mg id. He was reevaluated 4 weeks later and reported significant improvement of pain and stiffness. His renal function and complete blood count were normal.

Discussion

Even though the patient presented a low cumulative dose of MTX, he suffered several side effects.

Although not common in low doses, myelosuppression is more likely if renal function is impaired, in the setting of an acute illness, addition of a nonsteroidal antiinflammatory drug or if MTX is taken daily instead of weekly. In this case, myelosuppression was a risk factor for opportunist infections such as Herpes Simplex, oropharyngeal candidiasis and streptococcal pneumonia. Diarrhea could be of infectious etiology but also a manifestation of neutropenic colitis. This case highlights the need to clearly explain the correct posology of prescribed medication.

#1273 - Case Report

VITAMIN B12 DEFICIENCY AND METFORMIN

Catarina Sousa Gonçalves, Nuno Reis Carreira, Marisa Teixeira Silva

CHULN, Lisboa, Portugal

Introduction

Diabetes Mellitus (DM) is an important and frequent pathology. DM is associated with acute and chronic complications. However, the treatment can be associated with iatrogenic side effects. In this sense, several studies have appeared in the area. Biguanides are the first line medicine in the management of type 2 diabetes.

In the last years, there has been some concern regarding the risk of vitamin B12 deficiency in people who take Metformin. Vitamin B12 has an important role in cellular metabolism, however, clinical B12 deficiency with classic haematological and neurological manifestations is relatively uncommon. B12 deficiency can affect individuals at all ages, but most particularly the elderly ones.

Some studies in elderly people show an association between long-term diabetic patients who take Metformin, and concomitantly suffer from hypothyroidism, with Vitamin B12 deficiency. The

explaining mechanism is not certain yet, but the studies mainly indicate to alterations in the small bowel that change the absorption of Vitamin B12.

Case description

A 80-year-old man presented with inflammatory polyarthralgia associated with joint stiffness and functional limitation accompanied by anorexia, a weight loss of 13 kg in 4 weeks and complaints of malaise and progressive fatigue. Medical history of diabetes mellitus, hypothyroidism, obesity, ischemic heart disease, heart failure, atrial fibrillation, obstructive sleep apnea and dyslipidemia. In lab tests presented with pancytopenia, normocytic and normochromic and Vitamin B12 deficiency. On neurologic examination there were a numbness and prickling in T1, L4 and L5 dermatomes.

The complementary lab tests were negative for viral serologies, autoimmune disease, including pernicious anemia. The imagiologic and endoscopic study were negative for neoplasm.

All Vitamin B12 deficiency causes were excluded, the hypothesis of deficiency associated with Metformin was clear. After the replacement of Vitamin B12 levels the signs on neurologic examination disappeared.

Discussion

We brought this case to illustrate the importance of a meticulous assessment when approaching patients with Vitamin B12 deficiency. Some common causes must not be forgotten, such as reduced oral intake or pernicious anemia, but also the patient's medication must be revised and reassessed.

#1278 - Medical Image

HUGE ABDOMINAL CYST

María Elena Casuso-Sáenz, Raquel Jaso-Tejera, María Teresa Valiente-Millán, Miriam Vieitez-Santiago, Laura Gutiérrez-Fernández, Nuria Díez-Herrán, Ana Isabel González-Torre-González, Ana Campo-Ruiz

Hospital de Laredo, Laredo, Spain

Clinical summary

A 64 year old female consulted in emergency because of progressive abdominal distension. She did not have interesting personal details. Examination disclosed unpainful abdominal distension, widespread dullness without collateral circulation or hepatosplenomegaly. A computed tomography (CT) (Imagen A) and magnetic resonance(MR) (imagen B) were requested. They revealed a huge cyst (31.1x17.5x36.3 cm) with a smaller cyst inside and bilateral hydronephrosis. In MR the cyst seemed to depend of right ovary. A hysterectomy, bilateral adnexectomy and omentectomy were performed. Surgical removed piece showed a 1,700 gr cyst with 10 litres fluid inside (36x26x8 cm) and pathological anatomy demonstrated a borderline mucinous, endocervical type, and grade I atypia, tumor of right ovary.

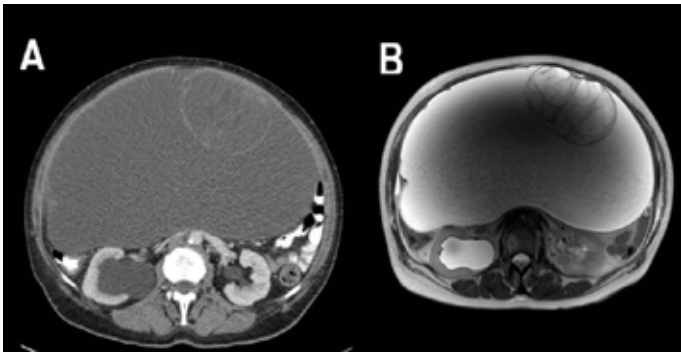


Figure #1278. Panel A: CT imaging gigant abdominal cyst with small cyst inside. Panel B: RM imaging huge cyst, bilateral hydronephrosis.

#1318 - Case Report

BRAIN METASTASES? THEY MAY NOT BE WHAT THEY SEEM

María Folgueras, Lucía Meijide, Vicente Santamaria, Jessica Paola Rugeles, Silvia Suárez, Carmen Yllera, Lucía Suárez, Claudia Morán, Sara Rodriguez, Carlota Argüello

Hospital Universitario Central de Asturias, Oviedo, Spain

Introduction

Tuberous sclerosis complex (TSC) is multisystemic genetic disease with autosomal dominant transmission and characterized by the development of many benign tumors in multiple organs with an increased risk of malign tumors. It's caused by mutation in the TSC1 gene or in the TSC2 gene.

It has an incidence of approximately 1 in 5.000 to 10.000 live births and the most common way of presentation is with epileptic crisis. The diagnosis is established by 2 major clinical criteria, the presence of 1 major clinical criteria and 2 or more minor criteria, or the identification of SC1 or TSC2 in a genetic test.

We present a patient with diagnosis of tuberous sclerosis at the age of 85 years old fulfilling 3 major criteria.

Case description

85-year-old woman went to the emergency department with dizziness and instability. She didn't report any other symptoms. She was seen by a neurologist who applied for a cranial TC appearing cranial blastic lesions and ventricular microcalcifications suggestive of metastases, so the patient was referred to Internal Medicine in order to do further investigations. Her medical history wasn't relevant.

On examination, she was hemodynamically stable, and the entire physical exam was normal. In order to locate a primary neoplasia, we requested the realization of:

- A full blood test that didn't reveal any abnormal data.
- A Cranial MRI which revealed cortical and subcortical lesions in both hemispheres that didn't had contrast enhancement and didn't showed an hyperintense signal in diffusion-weighted imaging excluding the possibility of metastases or ischemic pathology so the lesions could be cortical tubers instead.

- A full-Body-TC that revealed the presence of lymphangioleiomyomatosis (LAM), angiomyolipomas in both kidneys, and a lesion suggestive of primary renal neoplasia on the right kidney.

With all these data, the diagnostic suspicion of tuberous sclerosis was established by fulfilling 3 major criteria (LAM, angiomyolipomas, and brain tubers). As for the genetic test, TSC1 was tested being negative and we couldn't test TSC2 in our hospital.

Discussion

Despite TSC is usually diagnosed during childhood, the natural evolution of this disorder is variable so it could be diagnosed in adulthood. The most common manifestations in adulthood are skin lesions and neuropsychiatric symptoms. Our patient only had dizziness and no other symptoms were referred. Genetic counseling was carried out on her family despite not being able to determine the responsible gene.

#1322 - Abstract

THROMBOPROPHYLAXIS IN ACUTELY ILL MEDICAL PATIENTS: THE REALITY OF AN INTERNAL MEDICINE WARD

Luís Rocha, Lúcia Vieira, Sara Lopes, Filipe Breda, Vítor Paixão Dias

Centro Hospitalar Vila Nova de Gaia/Espinho, Vila Nova De Gaia, Portugal

Background

Venous thromboembolism (VTE) remains a major cause of long-term morbidity, functional disability and mortality in hospitalized patients. Evidence recommends stratification of thrombotic risk for all patients and the accordingly administration of thromboprophylaxis. More recently, a bleeding risk score was also developed.

This study aims to evaluate the suitability of pharmacological thromboprophylaxis of patients in an Internal Medicine ward of a tertiary hospital.

Methods

A retrospective analysis of patients admitted to an Internal Medicine ward between November and December of 2018 was performed. Patients under anticoagulant treatment, transferred from a surgical ward or electively admitted were excluded. Padua Prediction Score (PPS) and IMPROVE Bleeding Risk Score were calculated for all patients. Data was analysed using IBM SPSS Statistics 25.

Results

A total of 103 patients was included, of whom 51,5% (n=53) were women and 48,5% (n=50) were men, aging 30 to 98 years (M=73,3; SD=14,9) and hospitalized during 1 to 81 days (Mdn=12; IQR=12). According to PPS, 81,6% (n=84) of patients were at high risk of VTE. IMPROVE Bleeding Risk Score was also calculated

and, crossing these scores, 68.9% (n=71) had indication to pharmacological thromboprophylaxis. This indication was not followed in 15.5% (n=11) of patients; two of the cases were cirrhosis with International Normalized Ratio (INR) value greater than 1.5. On the other hand, 59.4% (n=19) of patients without indication to receive thromboprophylaxis had it prescribed. According to these scores, a total of 29.1% (n=30) of patients were not properly managed.

In this sample, 3.9% (n=4) of patients presented a VTE event while in hospital; all of them were under thromboprophylaxis. VTE events during the 90 days post-discharge were not reported. A haemorrhagic event occurred in 1.9% (n=2) of patients, one of whom was anticoagulated in prophylactic dose.

Conclusion

Risks associated with inadequate prescription of thromboprophylaxis are relevant and it's often difficult to distinguish the patients whose thrombotic risk surpasses the haemorrhagic one. In a ward of Internal Medicine, given the several comorbidities that each patient presents, this situation may become even more troubling. Therefore, validated risk assessment models may represent a helpful tool to the clinician; adherence to its application could be enhanced through, for example, the informatic implementation of its calculation upon hospital admission.

#1328 - Abstract

CONCORDANCE BETWEEN VENOUS THROMBOEMBOLISM RISK ASSESSMENT MODELS

Lúcia Vieira, Luís Rocha, Sara Lopes, Filipe Breda, Vítor Paixão Dias

Centro Hospitalar Vila Nova de Gaia/Espinho, Vila Nova De Gaia, Portugal

Background

Hospitalized patients present a greater risk of venous thromboembolism (VTE). Although several models were developed to stratify that risk, there are few studies comparing available risk assessment models (RAMs). This study intends to analyse the concordance between Padua, IMPROVE VTE, Geneva and Kucher scores.

Methods

A retrospective analysis of patients admitted to an Internal Medicine ward between November and December of 2018 was performed. Patients under anticoagulant treatment, transferred from a surgical ward or electively admitted were excluded. The referred RAMs were calculated for all patients. Data was analysed using IBM SPSS Statistics 25.

Results

A total of 103 patients was included: 51,5% (n=53) women and 48,5% (n=50) men, aging 30 to 98 years (M=73.3; SD=14.9) and hospitalized during 1 to 81 days (Mdn=12; IQR=12).

Of the included patients, 81,6% (n=84), 76,7% (n=79), 84,5% (n=87) and 22,3% (n=23) were classified as high-risk according to Padua, IMPROVE, Geneva and Kucher scores, respectively.

Through Cohen's kappa, concordance was assessed. Level of agreement was moderate between Padua and IMPROVE VTE scores ($k=0.619$, $p<0.001$), weak between Padua and Geneva scores ($k=0.553$, $p<0.001$) and minimal between IMPROVE and Geneva scores ($k=0.385$, $p<0.001$). Kucher score presented no concordance with IMPROVE ($k=0.161$, $p=0.003$), Padua ($k=0.122$, $p=0.010$) and Geneva scores ($k=0.016$, $p=0.708$).

Of the analysed patients, 3.9% (n=4) presented a VTE event while in hospital; all of them were classified as high-risk by Padua, 3 by IMPROVE and 1 by Geneva and Kucher scores. During the 90 days post-discharge, VTE events were not reported.

Conclusion

This study revealed a considerable variability between RAMs. Level of agreement was not strong between any pair.

Padua score, recommended by American College of Chest Physicians guidelines, was the only that predicted all reported VTE events.

Kucher score, despite its easier application, presented the weakest level of agreement with Padua and predicted only 1 of the 4 VTE events. This may be due to its lack of valorization of comorbidities, so common in patients in an Internal Medicine ward.

Geneva score includes 8 more elements than Padua, taking longer to calculate; however, in this analysis, it seems to present no advantage over Padua in the prediction of VTE events.

IMPROVE VTE score, the model that includes fewer elements, presented the strongest level of agreement with Padua and predicted more VTE events than Geneva and Kucher scores.

#1334 - Abstract

RELATIONSHIP BETWEEN HOSPITAL ADMISSIONS (HA) AND ENVIRONMENTAL FINE PARTICLE MATTER (PM) CONCENTRATIONS

Ana Teresa Marques Afonso, Néstor Vázquez Agra, Lucía Barrera López, Jonathan Geovany Montoya Valdés, Martiño Vidal Vázquez, Hadrian Pernas Pardavila, María López Rodríguez, Ariadna Helena Andrade Piña, Ignacio Novo Veleiro, Lara María Mateo Mosquera

Clinical Hospital of Santiago De Compostela, Santiago De Compostela, Spain

Background

Fine PM is a complex mixture of solid and liquid particles suspended in the air that may have an important role in exacerbation of some diseases. There are two main groups of particulate matter (PM₁₀ and PM_{2.5}) attending to diameter below 10 and 2.5 μm, respectively.

The aim of this study is to investigate a possible relationship between PM_{2.5} concentrations and HA.

Methods

Observational and retrospective study between number of daily HA in the internal medicine service of the hospital of Santiago de Compostela (SDC), Spain, during October 2018, and the average daily PM 2.5 concentration in urban area of the city.

Only inhabitants of urban area of SDC were included. Information of PM 2.5 concentration was gathered from "www.meteogalicia.gal" and the HA data from the hospital database (IANUS).

Number of HA and PM2.5 concentration as dependent and independent variables respectively.

We used SPSS for descriptive results and Python statistical libraries for multivariate analysis by using a vectorial autoregression model with Coin-Johansen test for stationarity and Granger causality test for causality described in "www.statsmodels.org".

Results

Fifty-nine HA were included, daily median: 2, mean daily PM2.5 concentration: 11.76 $\mu\text{g}/\text{m}^3$ (ES: 5.25). The main cause of hospitalization was respiratory infection and renal failure.

Graphs seem to show clinical correlation.

Multivariate analysis:

- Coin-Johansen test result (< 1) shows a stationarity model.
- Granger test results: PM does not Granger-cause HA: fail to reject at 5% significance level Test statistic: 2.530, critical value: 2.849, p -value: 0.072.

Conclusion

This study has several limitations as small sample size, few HA and short time of study. According to figures, it seems to be a clinically significant relationship between PM 2.5 concentrations and HA. It should be considered that results border on statistical significance despite the small sample size used.

#1359 - Case Report

MAY-THURNER SYNDROME: PULMONARY EMBOLISM AS PRESENTATION

Olga Cristina Pires, Ana Isabel Andrade Oliveira, Joana Morais, Inês Burmester, Paulo Gouveia, Maria João Regadas, António Oliveira Silva

Hospital de Braga, Braga, Portugal

Introduction

May-Thurner syndrome is a rare disease that causes deep vein thrombosis in young females. Deep vein thrombosis is caused by mechanical obstruction of the left common iliac vein by the right common iliac artery resulting in stasis rather than a primary hypercoagulable state, and is usually presents by lower limb edema.

Case description

A 22-year-old female with a past medical history unremarkable was in her usual state of health until two days before presentation

when she developed shortness of breath and pleuritic pain under her left breast. She denied recent leg edema. She has no history of thromboembolic disease. She smoked 5 cigarettes per day and was taking combined oral contraceptives but denied alcohol, or illicit drug use. She was tachycardic but normotensive. Her lungs were clear to auscultation bilaterally, her chest X-ray was clear, and her electrocardiogram revealed sinus tachycardia. A computed tomography scan of her chest with contrast revealed bilateral pulmonary emboli. She was admitted to the internal medicine department where she was started enoxaparin at therapeutic doses. Lower extremity doppler revealed acute deep vein thrombosis of common and internal iliac veins. Transthoracic echocardiogram showed no relief changes.

The abdominal venous phase computed tomography revealed the existence of compression at the level of left common iliac vein (May-Thurner syndrome) with associated thrombosis and eventual migration of the thrombus into the iliac vein common right. The vascular surgery team evaluated her and there was no need for additional care other than anticoagulation. Her hypercoagulability workup, which included lupus anticoagulant, anticardiolipin, homocysteine, and factor V Leiden, was negative. Her hospital course was favorable. He was switched from enoxaparin to edoxaban 60 mg per day. Consultations were scheduled for vascular surgery and internal medicine for reassessment and follow-up.

Discussion

This clinical case aims to highlight the importance of including May-Thurner syndrome in the differential diagnosis of pulmonary embolism in young woman. May-Thurner syndrome prognosis is very good if promptly identified and treated.

#1413 - Case Report

DRUG FEVER - A DIAGNOSIS TO BE CONSIDERED

Ana Rita Gigante, Eduarda Milheiro Tinoco, Filipa De Castro Lima, Teresa Shiang, Eloisa Silva, Carla Ribeiro, Manuela Vanzeller
Centro Hospitalar Vila Nova de Gaia/ Espinho, Vila Nova De Gaia, Portugal

Introduction

Although common, drug fever is often misdiagnosed. It is a diagnosis made by exclusion, complemented by therapeutic evidence with apyrexia after cessation of the drug. The underlying mechanisms include the altered thermoregulation, pharmacological action, idiosyncratic reactions or hypersensitivity mechanisms. Antibiotics, especially β -lactams, may give rise to this reaction.

Case description

A 35-year-old male with recent hospitalization for Cardiothoracic Surgery due to thoracic trauma, with multiple rib fractures, pneumothorax, lung abscess and pleural effusion on the right; previously treated with amoxicillin/clavulanate and clindamycin. He presented to the emergency department complaining

of dyspnea, cough with haemoptysis and worsening of right thoracalgia. At admission, he had a decrease breath sounds in the lower half of the right haemithorax. Laboratory results included anaemia, leukocytosis with neutrophilia, thrombocytosis and elevated C-reactive protein. Chest X-ray showed radiological deterioration due to increased shadowing in the lower half of the right lung field and thoracic CT with evidence of fractures from the 1st to 11th right ribs with significant non-alignment of the 9th rib and pulmonary abscess secondary to laceration in the right lower lobe with large same side pleural effusion. Thoracentesis revealed exudate bloody pleural fluid (pH 7.47; glucose 84mg/dL). Piperacillin/tazobactam was initiated. Pleural fluid isolate showed vancomycin-sensitive *Streptococcus sanguinis* therefore vancomycin was added to the regimen for 7 days. At the 17th day of antibiotic therapy with piperacillin/tazobactam only, he had fever again. There were no associated symptoms and radiological findings were unremarkable. Lab results revealed neutropaenia, but without elevation of inflammatory markers; and there was no microbiological identification in blood, urine or bronchial lavage. After the discontinuation of the antibiotic, fever receded without any other treatment.

Discussion

It is important to consider drugs as a cause of unknown origin fever, especially when prolonged treatment, in order to avoid prolonged hospitalization and antibiotics overuse, leading to an increased risk of adverse reactions or antimicrobial resistance.

#1440 - Case Report

A CASE OF AZITHROMYCIN-INDUCED LEUKOCYTOCLASTIC VASCULITIS

Gabriela Pereira, Ana Cardoso, Cristina Silva, Margarida Rocha, Ussumane Embaló, Jorge Cotter
Hospital Senhora da Oliveira, Guimarães, Portugal

Introduction

Drug-induced vasculitis affects a small group of patients and may be associated with arthralgia of the large joints, without renal impairment or hypocomplementemia and may have an acute, subacute or chronic course.

Case description

We present a case of a young man, 19 years old, with no relevant pathological history, who denied consumption of illicit substances and without epidemiological context, namely contact with animals. He came to the Emergency Department because of odynophagia and painful swelling in the left cervical region, which began about 7 days ago, and had been medicated by his Physician with azithromycin for 3 days. Subsequently 4 days ago, a cutaneous rash started on his lower limbs, which has been aggravated, with the appearance of some similar lesions in the upper limbs, sparing the other regions of the body, the palmar region and the plantar region. At admission, he was feverish and presented the

referred lesions with several evolutionary times, associated with arthralgias, especially in the ankles and knees with a 48h evolution. Analytically, it had mild leukocytosis and increased inflammatory parameters (CRP 45). Chest X-ray and urinary sediment without changes.

He was hospitalized for study and surveillance.

From the complementary study, he presented negative viral serologies, negative autoimmunity. Abdominal ultrasound with no evidence of organomegaly. Chest tomography without changes.

On the third day, skin biopsy was performed, which was compatible with reactive hyperplasia of the epidermis and presence of fibrosis and superficial peri-vascular mononuclear inflammatory infiltrate in the underlying dermis.

During hospitalization, he presented sustained apirexia after 48 hours of admission, with no new lesions, arthralgia resolution and urinary sediment serially tested without alterations. Due to benign evolution, it is discharged and is reassessed at 3 months with complete resolution of cutaneous rash and without further complications.

Discussion

Only a few cases of leukocytoclastic vasculitis induced by azithromycin have been reported. The present case showed that azithromycin, which is one of the most important oral antibiotics used for the treatment of an amount of different diseases, may lead to leukocytoclastic vasculitis.

#1465 - Case Report

CARBAMAZEPINE: AN UNUSUAL CAUSE OF LYELL SYNDROME

Rui M. Domingues¹, Joana Morais¹, Edgar Amorim², Cindy Tribun¹, André Santa Cruz^{1,3}

¹ Internal Medicine Department, Braga Hospital, Braga, Portugal

² Physical Medicine and Rehabilitation Department, Braga Hospital, Braga, Portugal

³ Life and Health Sciences Research Institute (ICVS), School of Medicine, University of Minho, Braga, Portugal

Introduction

Fever and exanthem are symptoms with a myriad of differential diagnosis. Lyell syndrome/toxic epidermal necrolysis is a severe mucocutaneous reaction, characterized by extensive necrosis and severe detachment of the epidermis.

Case description

A 34 years old woman, with history of major depressive disorder, tension headaches and allergy to aspirin, medicated with amitriptyline, fluoxetine and mexazolam, presented to the Emergency Room due to a 48-hours maculopapular rash and blisters affecting the face, torso and proximal third of the thighs. She developed odynophagia for 4 days before the admission, as well as fever (39°C) for 3 days before the admission. At physical examination, she had no difficulty in breathing, had normal

peripheral oxygen saturation, was normotensive, but febrile (39,4°C). She had a systolic murmur II/VI, a normal pulmonary auscultation, a painless abdomen, no peripheral oedema and negative meningeal signs. Oral examination revealed an exuberant yellow exudate over the throat, and ulcerations of the labial and oral mucosa. Most importantly, a maculopapular exanthem was visible, with distribution over the face, torso and proximal third of the thighs. Some big blisters were located in the face, neck and superior half of the chest with positive nikolsky sign. She could not open her eyes. Given the symptoms and area of skin affected, Lyell syndrome was the most likely diagnosis. However, infection was ruled out. She was immediately started on IV immunoglobulin (1 g/kg a day) for 3 consecutive days and was transferred to a burn unit. After initial assessment, no apparent cause was found. Only after her history was reviewed, it was discovered that she had started taking carbamazepine a couple of weeks prior to the initial symptoms. As her case evolved, she developed extensive lesions of the skin, gastrointestinal tract, genital mucosa and eyes and underwent amniotic membrane transplantation due to ocular lesions. Fortunately, she could recover, but permanent sequelae still exist: decreased visual acuity - 1/10 in each eye; dysgeusia and discomfort in swallowing, iron absorption deficit despite normal endoscopic exams, menstrual abnormalities and vaginitis.

Discussion

We consider this case relevant because carbamazepine is very rarely described as a pharmacological cause of Lyell syndrome in adults. The diagnosis and determination of the cause of Lyell syndrome require high clinical suspicion, making good history taking and complete physical examination the key.

#1473 - Medical Image

MAY-THURNER SYNDROME - UNUSUAL CAUSE OF ASYMMETRIC LOWER LIMB EDEMA

André Maia, Patrícia Chow Liu, Joana Liz Pimenta, Pedro Filipe Sousa, Sandra Alves Morais

Centro Hospitalar de Trás-os-Montes e Alto Douro, Vila Real, Portugal

Clinical summary

50-year-old male with alcoholic liver disease at a decompensated cirrhotic stage (CTP C, 11 points), presented acute swelling of the left lower limb, with no pain or signs of inflammation. Venous triplex US ruled out deep vein thrombosis (DVT). Abdominopelvic CT with contrast revealed a flaw of contrast flow in the left common iliac vein (LCIV) near its confluence into the inferior vena cava, without explicit endoluminal thrombi. An ilio-cavography showed an obstruction of proximal contrast flow in the LCIV, with shunting to collateral veins, suggesting May-Thurner Syndrome. This condition is caused by the compression of the LCIV by the right iliac artery leading to fibrosis and narrowing of the vein. In the absence of DVT, for patients with mild symptoms, treatment is conservative.

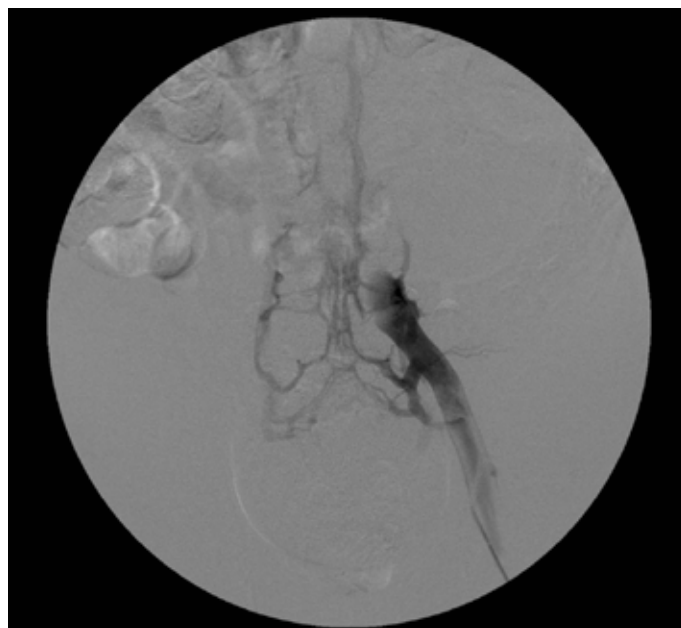


Figure #1473.

#1492 - Case Report

INVOLUNTARY INTOXICATION BY ARSENICUM ALBUM® + CHOLESTATIC JAUNDICE IN PATIENT WITH SCABIES AND CUSHING'S SYNDROME - CLINICAL CASE

Paulo Ferreira¹, Vanessa Machado¹, Cristina Ramalho¹, Hilda Freitas², Natalia Oliveira², Antonio Cabral²

¹ TrofaSaude Hospital Braga Centro, Braga, Portugal

² TrofaSaude Hospital Braga Sul, Braga, Portugal

Introduction

Cholestatic drug-induced liver injury (DILI) can be a diagnostic challenge due to a large differential diagnosis, variability in clinical presentation, and lack of serologic biomarkers associated with this condition. The associate mortality of cholestatic DILI can be as high as 10%, and thus prompt recognition and removal of the offending agent is of critical importance.

Arsenicum Album® is a product derived from arsenic, very popular in homeopathy. Obtained by very high temperature insulation of nickel, cobalt and steel contained in Arsenic.

Case description

The authors describe a clinical case of a 87 years old women, autonomous, with a medical history of hypertension, heart failure, atrial fibrillation, chronic kidney disease, dyslipidemia, hyperuricemia and Cushing's syndrome. Medication at home: amlodipine, transdermal nitroglycerin, carvedilol, furosemide, rivaroxaban, quetiapine, rosuvastatin, pantoprazole, allopurinol, calcium carbonate + cholecalciferol, and Arsenicum Album® from 1 month before. She had pruritus with 3 weeks of evolution. She had initially abdominal pain, and later diarrhea. Subsequently also with nausea / vomiting. She was initially medicated by her General Clinic Physician with benzyl benzoate on suspicion

of scabies; without resolution. Another doctor prescribed the patient 1 month before Arsenicum® (homeopathic product), and was taking an unknown dose. Laboratory studies: TGO 160; TGP 158; Bil Total 3.3; FA 1129; GGT 635; INR 1.3. She was observed by Dermatology that agreed that cutaneous lesions compatible with scabies. Therapeutic adjustments were made, including suspension of Medication. Was performed additional tests. Abdominal ultrasound: choledocholithiasis, indicating endoscopic retrogradated pancreatic cholangiography (ERCP). Additional analyzes, including virology and autoimmunity were negative. She made ERCP: extraction of the calculation. She had good evolution, with resolution of diarrhea, nausea and vomiting, and no pain complaints. With progressive resolution of pruritus. Scrapie rash dispersed in improvement.

Discussion

The authors intend to value the importance of harvesting in the clinical history of drug habits, including homeopathy and herbal products, their side effects and drug interactions. The plurality of associated pathologies is attractive to the internist; even when the cause seems detected, we must be aware of the various diagnostic possibilities, not neglecting the possibility of various problems.

#1501 - Abstract

FEAR AVOIDANCE BELIEFS : 100 INVESTIGATED PARAMEDICAL STAFF

Rim Dhahri¹, Béchir Assidi², Maroua Slouma¹, Leila Metoui¹, Nour Gueddich¹, Imene Gharsallah¹, Bassem Louzir¹

¹ Internal Medicine department, Military Hospital of Tunis, Tunis, Tunisia

² Military Nursing School, Tunis, Tunisia

Background

Therapeutic education is a continuous medical care process whose role in lower back pain has yet to be well defined. The aim of the present study was to describe the fear-avoidance beliefs In paramedical staff in regard to low back pain work and physical activity.

Methods

This is a cross-sectional study involving 100 paramedical staff with or without low back pain and practicing in the military hospital. The survey was done via an online questionnaire: The Fear-avoidance beliefs FABQ questionnaire which is a questionnaire developed and validated.

It evaluates 2 components: fears and beliefs about professional activities: FABWORK (7 items, score from 0 to 42), and beliefs about physical activities: FABPHYS (4 items, score from 0 to 24).

Results

The study population consisted of 44.2% nursing students, 42.9% nurses and 11.7% technicians. The average age was 28 years old with extremes ranging from 22 to 52 years old. A female predominance was noted (53.1%).

Low back pain was acute in 57.8% of the population, sub-acute in 26.6% and chronic in 15.6%. 81.8% had a history of low back pain during the previous year, of which only 28.6% consulted a doctor (34.6% ER, 38.5% Rheumatologist, 19.2% Orthopedic 3.8% Neurosurgery and 3.8 % staff doctor). 20.5% were on sick leave for low back pain, with an average duration of 8 days (range from 3 to 30 days).

The average scores of patients at FABQ were 10.28 for physical activities (FABQPA) and 21.2 for professional activities (FABQW). Thus the fears and beliefs of causality between work, physical activity and low back pain are quite pronounced in our population.

Conclusion

The role of fears and beliefs in the development of disability in low back pain has gained importance in recent years. It is important that this psychological factor be evaluated. FABQ is a reliable and valid measure, but more research is needed to establish scores to identify patients at risk.

#1513 - Abstract

FACTORS RELATED TO SPANISH INTERNAL MEDICINE PHYSICIANS BURNOUT

Cristina Macía-Rodríguez¹, Gemma Ortiz², Daniel Martín³, Javier Moreno⁴, Adrian Montaña⁵, Candido Muñoz⁶, Manuel Lopez Reboiro⁷, Adriana González-Munera⁸

¹ POVISA, Vigo, Spain

² Hospital de Terrassa-Consorci Sanitari de Terrassa, Terrassa, Spain

³ Hospital de Cruces, Bilbao, Spain

⁴ Hospital Universitario Miguel Servet, Zaragoza, Spain

⁵ Complejo Hospitalario Universitario de Badajoz, Badajoz, Spain

⁶ Hospital General de Cataluña, Barcelona, Spain

⁷ Hospital de Monforte, Monforte, Spain

⁸ Hospital General Universitario Gregorio Marañón, Madrid, Spain

Background

Burnout syndrome (BS) is a work-related illness in welfare societies and involves emotional exhaustion caused by chronic and demanding work. Workers in hospitals and health centers are one of the most affected groups. The prevalence is up to 50% and is related to work hours, lack of leadership and decrease in personal achievements. We believe that the work environment can be one of the main causes to develop the BS so it is not only important to identify the possible triggers as soon as they appear, but also to establish measures to solve them. The Maslach Exhaustion Inventory (MBI) is the most widely used questionnaire to assess BS.

Methods

We asked members from the Spanish Society of internal Medicine to perform an online survey. It is constituted of MBI questionnaires and short multiple-choice questions about working conditions. The survey was conducted by e-mail registry. In order to assess the factors related to BS we used a univariate and multivariate

analysis. We used SPSS version 22.0 for statistical data analysis.

Results

We registered 934 respondents, more than a half of the sample were females (58.8%) mean age of 42.3 y-o and had children 58.8%. Worked in a public hospital 82%, private hospital 11% and both 6.2%. Almost a fifth part (21.6%) of the respondents had 2 or more employment contract. Scoring-results in MBI questionnaire revealed burnout levels in a third of the sample. On univariate study, the development of BS has been related to age, having children, multiple job, number of patients per doctor, exceeding working hours, low incomes, career stagnation, physical and psychological aggressions and a poor work environment. BS is regarded as an outcome of sick leave and quitting medical profession. On multivariate analysis, independent factors for BS age (0.958 (0.940-0.977)), poor working environment (1.969 (1.350-2.873)), low incomes (1.801 (1.213-2.67)), physical and psychological aggressions (1.703 (1,204-2,410)) and career stagnation (2,778 (1,881-4,101)).

Conclusion

Levels of BS were detected in a third of respondents. Independent factors to develop are was related independently with age, poor working environment, low incomes, physical and psychological aggressions and career stagnation.

#1534 - Medical Image

PHYTOPHOTODERMATITIS BY A FIG TREE

Catarina Peliz Reigota, Helena Rodrigues, Filipe Vilão, Lèlita Santos, Armando Carvalho

Centro Hospitalar e Universitário de Coimbra, Coimbra, Portugal

Clinical summary

25-year-old male, presented to the Emergency Department with erythema, edema and bullae in linear and also bizarre configurations in the face, neck and left hand (sun – exposed skin), with 2 days evolution, after contact with fig tree. Lesions were not pruritic but painful. He had no other symptoms. He did not report chronic medication, diseases or allergies. He presented only with leukocytosis. The more probable diagnostic was Phytophotodermatitis which is a phototoxic reaction after topical exposure to the sap of fig trees that contains furocoumarins which are inactive alone, but 24 hours after exposure to UVA radiation, they are reported to induce this reaction. It might be misdiagnosed as allergic contact dermatitis or fungal skin infections.

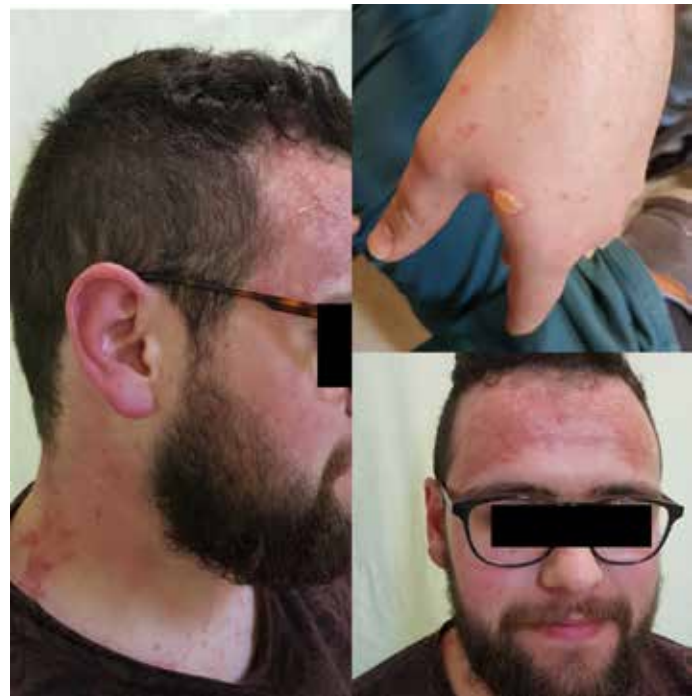

Figure #1534. Erythema, edema and bullae on sun - exposed skin.

#1549 - Abstract

SOCIALEPIDEMIOLOGIC PROFILE OF THE UNASSISTED RIVERSIDE POPULATION FROM AMAZONIAN REGION IN BRAZIL, RAISED BY VOLUTEERING HEALTH GROUP

Isabella Carinhani Bragheto, Jhenifer Nataly Moura França, José Anibale Rodrigues Junior, Giovanna Oncala Simão, Luisa Da Cunha Gobbo, Gustavo De Campos Olavarria, Fabiana Moreira Passos Succi, Bruna Albertini Reis, Otto Albuquerque Beckedorff, Henrique Ferreira Greco, Carlos Osvaldo Teixeira, Maria Aparecida Barone Teixeira

Faculdade São Leopoldo Mandic, Campinas, Brazil

Background

The Health Boat volunteering project aimed to provide medical and dental care, in a wholesome and humane form, to those with difficult access to healthcare. In July 2018, 22 students and 14 professors performed 2258 consultations for the riverside population of the Tapajós river, Brazil. The study intends to describe the epidemiological data of internal medicine consultations for the riverside population in Rio Tapajós.

Methods

Descriptive study, consisting of 318 patients, living in one of the 29 riverside communities along the Tapajós River, attended during the health expedition. The data were represented by absolute (n) and relative (%) frequencies.

Results

The sample was distributed in 40.25% (128) male patients and 59.75% (190) female patients. The age range varied from 2 to 98

years old. Of the diagnosis made, the most prevalent was systemic arterial hypertension 22.63% (62), type 2 diabetes mellitus 13.14% (36), cerebrovascular accident sequelae 3.65% (10), inguinal hernia 3.28% (9), scabies 2.55% (7). Among the symptoms reported, the most common were low back pain 19.43% (55), headache 11.66% (33), epigastralgia 9.89% (28) and dizziness 8.48% (24). About the occupation, 28,61% (91) of the patients undeclared their profession, 34.90% (111) work in the rural sector, 13.83% (44) are students, 10.37% (33) are retired, 4.71% (15) practice domestic activities and 7.54% (24) are service providers, being that 54,16% (13) of these work at the education sector. The individuals between the ages of 8 and 18 was enrolled in school. The staple diet is based on fish, chicken and cassava derivatives.

Conclusion

A high prevalence of chronic diseases such as systemic arterial hypertension and type 2 diabetes mellitus were the most prevalent disease, as in data observed in urban centers. The socioeconomic structure showed that children and adolescents are studying, while the economically active population works mainly at the agricultural sector. Occupational activities seem to play a strong correlation with the most prevalent symptoms and diagnoses. Inguinal hernia and low back pain are probably correlated with essentially agricultural labor. Lastly, headache and dizziness seem to be related to long period of sun exposure, as well as malnutrition. The expedition raised social-epidemiological data from isolated populations, revealing their realities. Moreover, provided an innovating experience for medical education, allowing comprehension of the practice of healthcare in a humane manner.

#1565 - Abstract

ETIOLOGICAL PROFILE OF ACUTE ALITHIASIS PANCREATITIS IN AN INTERNAL MEDICINE DEPARTMENT

Asma Kefi, Sonia Kammoun, Fatima Jaziri, Mounira Elleuch, Marwa Fliss, Khaoula Ben Abdelghani, Sami Turki
Charles Nicole Hospital, Tunisi, Tunisia

Background

Acute pancreatitis is an inflammation of the pancreas. It corresponds to a "self-digestion" of the pancreatic gland. Its outstanding etiologies are lithiasis migration, followed by chronic alcoholism. Nevertheless, pancreatitis can involve iatrogenic, metabolic, infectious or other causes. The aim of our work is to study the etiologies of pancreatitis in a department of internal medicine.

Methods

We collected observations from 12 hospitalized patients in our department between 1992 and 2016, who presented with acute pancreatitis. All patients underwent an interrogation and a complete examination as well as a lipid, phosphocalcic and abdominal ultrasound assessment. We excluded patients in whom lithiasis etiology was diagnosed.

Results

We retained the alithiasic origin in 9 patients (75%). There was an iatrogenic etiology with meglumine antimony in 3 patients treated for visceral leishmaniasis, including two immunocompetent patients and one kidney transplant recipient; a major hypertriglyceridemia in a type 1 diabetic patient; lupus pancreatitis in three patients; and a cytomegalovirus infection in another renal transplanted patient. Concerning the last case, pancreatic necrosis lapses were discovered during a diagnostic laparoscopy for abdominal adenomegaly where the biopsy revealed an epithelioid granuloma that led to the diagnosis of a ganglionic tuberculosis.

Conclusion

Our study concluded that the lithiasic etiology of pancreatitis is not the most frequent in the department of internal medicine, due to the fact that our patients belong to particular fields: autoimmune diseases, immunosuppression, etc. Nevertheless, it remains compulsory to look for obstructive or metabolic causes before thinking about other causes of acute pancreatitis.

#1607 - Abstract

CHARACTERIZATION OF OXYGEN THERAPY PROCEDURES IN AN INPATIENT DEPARTMENT OF INTERNAL MEDICINE

Alexandra Avila, Vanda Conceição, Nuno Vieira, Maria José Grade, Luisa Arez

Serviço de Medicina 3, Hospital de Portimão do Centro Hospitalar Universitário do Algarve, Portimão, Portugal

Background

Oxygen therapy is a frequent and fundamental treatment in Internal Medicine wards. However, several studies have shown that it isn't practiced according to the best care. The objective of this study is to evaluate the oxygen therapy procedures in our hospital's Internal Medicine wards, comparing them with the criteria established by the British Thoracic Society (BTS) in the consensus document "BTS guideline for emergency oxygen use in adult patients".

Methods

Observational analysis of patients hospitalized in a general internal medicine ward in our Hospital, in two days randomly selected. All patients admitted to Internal Medicine services were audited and data were collected on the prescription, administration and monitoring of oxygen therapy.

Results

Were included 132 patients hospitalized, 62 (47%) were males, the average age was 79.4 years, the average of Charlson Comorbidity index was 6 points; 42 (32%) of these patients were completely dependent and 29 (22%) had some degree of dependency of others for daily activities. Regarding to the main diagnosis, 51 (34%) had

a respiratory disease, 30 (23%) a cardiovascular disease, 28 (21%) a neurological diseases and 17 (13%) an infectious pathology. At the time of the study, only 22 (17%) patients had supplemental oxygen, 2 of them had simple mask, 1 had ventury mask and 19 nasal prongs. Only 13 had written prescription of supplemental oxygen with a saturation goal defined, of these, 12 patients had periferical saturation higher than 94%. One patient had long-term oxygen therapy (LTOT) and 4 had palliative oxygen use. We founded risk of hypercapnia in 10 of the patients who were with supplemental oxygen. Of all, 2 patients started oxygen without previous realization of arterial gasometry and 3 patients had PaO₂ higher than 75 mmHg in initial gasometry.

Conclusion

There was a right prescription of oxygen therapy in 10% of our sample, corresponding to 13 patients. The absence of monitoring of oxygen therapy with gasometry were the most frequent error. Another error founded in oxygen therapy procedures, particularly in fixed dose prescriptions, was that some patients were at risk of hypercapnia. Although recommended by the BTS, oxygen therapy prescriptions for SatO₂ range targets are still a minority.

#1651 - Abstract

ANTHRACYCLINE-INDUCED CARDIOTOXICITY IN THE CHEMOTHERAPY TREATMENT OF BREAST CANCER: PREVENTIVE STRATEGIES AND TREATMENT

Fengfeng Cai¹, Manuel Antonio Falar Luis², XiaoYan Lin³, Minghong Wang⁴, Lu Cai⁵, Chunmei Cen¹, Ewelina Biskup²

¹ Department of Breast Surgery, Shanghai, China

² Yangpu Hospital, Shanghai, China

³ Tongji University School of Medicine, Shanghai, China

⁴ Shanghai 200090, Shanghai, China

⁵ P.R. China, Shanghai, China

Background

Abstract. Anthracyclines are highly effective chemotherapeutic agents, used for a wide variety of malignancies. Cardiotoxicity is a well-recognized side effect of anthracycline therapy that limits the total amount of drug administered and can cause heart failure in some patients. Most experimental data support oxidative stress as the etiology of anthracycline-induced cardiotoxicity. The objective of this paper was to provide a review of the clinical classification, risk factors, monitoring and prevention of anthracycline-induced cardiotoxicity in patients with breast cancer.

Methods

A bibliographic search was performed in the Cochrane, Medline, PubMed, Scopus, Web of Science and Scielo databases. Databases were searched systematically using the following keywords: anthracyclines, breast cancer, risk factors, prevention, and treatment, combined with cardiotoxicity, cardiomyopathy or heart failure.

Results

In the early detection of anthracycline-induced cardiotoxicity symptoms, such as mild arrhythmia, atrial fibrillation, pericarditis, etc., anthracyclines should be discontinued by switching to a chemotherapy regimen without anthracyclines, and the necessary symptomatic treatment should be given.

When patients have symptoms of congestive heart failure, anti-heart failure treatments, such as converting enzyme inhibitors (ACEI), diuretics and β -blockers, can be given. A recent study showed that administration of ACEI or a combination of beta-blockers at the early detection of an anthracycline-induced cardiac insufficiency restored LVEF and reduced cardiac events.

Conclusion

The current research on anthracycline-induced cardiotoxicity is still unclear and there is no effective prevention method. Anthracyclines are one of the most important drugs in the treatment of breast cancer. Therefore, while using these drugs, the risk factors associated with cardiotoxicity should be considered, cardiac function should be accurately measured and the cumulative dosage should be limited; otherwise, a new anthracycline alternative or liposome may be used to reduce anthracycline-induced cardiotoxicity. The clinician should develop a rational chemotherapy regimen based on individual differences and general conditions, and closely monitor the cardiotoxicity response induced by chemotherapeutic agents, in combination with various other examinations. Prevention of chronic cardiotoxicity is difficult, but regimens for the administration of the anthracyclines using prolonged infusion carry a lower risk.

#1652 - Case Report

BILATERAL CHARCOT ARTHROPATHY: A TREATMENT CHALLENGE

Jorge A Ruivo, Joana Cabrita, Isabel Pinheiro
Centro Hospitalar Lisboa Norte, Lisbon, Portugal

Introduction

Charcot arthropathy (CA) is a condition that results in progressive destruction of bone and soft tissues, causing joint dislocations, pathologic fractures, and debilitating deformities. It can occur at any joint, however it occurs most commonly in the lower extremity, at the foot and ankle. Prevalence ranges from 0.1-13% in specialized foot clinics and bilateral disease occurs in less than 10% of patients. Any condition that causes sensory or autonomic neuropathy can lead to CA, including diabetes mellitus, syphilis, chronic alcoholism, meningomyelocoele, spinal cord injury, syringomyelia, renal dialysis, leprosy and congenital insensitivity to pain. Gout can trigger acute CA. Unperceived trauma/injury associated with the sensory neuropathy renders the patient unaware of the osseous destruction that occurs with ambulation. This microtrauma leads to progressive destruction and damage to bone and joints leading to gradual bone fracture, joint subluxation and possible skin ulceration.

Case description

63-year-old white male patient, writer, with prior history of hypertension, gout, syphilis treated 20 years ago and non insulin dependent diabetes mellitus with fifteen years of evolution. He developed diabetic neuropathy and plantar ulcer of the left foot complicated by gangrene of the second toe in 2017, for which he had to undergo amputation with partial resection of the second metatarsal. At that time, diagnosis of bilateral CA was made but the patient discontinued follow-up. Now, he was admitted for septic shock following methicilin sensitive *Staphylococcus aureus* infection of a plantar ulcer of the right foot and gout flare. Both feet were extensively deformed with osteoarticular destruction of the medium foot and he had plantar hyposthesia. Lab results revealed increased inflammatory parameters, and a syphilis serological scar. HbA1c 8,7%, uric acid 10mg/dl, with normal phosphorus, calcium, parathormone, folates and vitamin B 12. He was successfully treated with antibiotics, glycemic control and colchicine and he was referred to Orthopedics.

Discussion

We present the rare case of a patient with bilateral CA with two possible triggers, such as diabetes and gout, admitted with a serious infectious complication. The current therapeutic options for CA are addressed. The paramount message is that CA needs immediate diagnosis and prompt treatment of coexisting conditions, in order to avoid CA progression, unnecessary amputations and other potential fatal complications

#1674 - Abstract

10 YEARS OF SUMMER SCHOOL OF INTERNAL MEDICINE IN RETROSPECTIVE

Nuno Bernardino Vieira, José Mariz, Ricardo Louro, Maria João Lobão, Susana Marques, Zélia Lopes, António Martins Baptista
Núcleo de Estudos de Formação em Medicina Interna, Sociedade Portuguesa de Medicina Interna, Lisboa, Portugal

Background

The Portuguese Summer School of Internal Medicine (EVERMI) was born in 2010 with the aim of fostering a space for scientific updating and professional and personal enhancement of the residents of Internal Medicine in Portugal. In the year of its 10th edition, it is intended to take stock of the editions of EVERMI from 2010 to 2018 and to evaluate the degree of satisfaction of the Internal Medicine Residents (IMR) that participated in them.

Methods

A descriptive cross-sectional observational study with prospective data collection, including all IMR participating in the 2010 to 2018 editions of EVERMI. Demographic data were collected from the participants and applied to all of them a questionnaire assessing the degree of satisfaction of the trainees with their participation in the school.

Results

In the first 9 editions of EVERMI, participate 363 IMR from all over the country. The majority (62.5%) were in the first and second year of training. It should be noted that a total of 25 participants were from Spain (invited by the Spanish Society of Internal Medicine). Regarding the evaluation of the training, in a scale of 1 to 10, the participants classified EVERMI, on average, in the Scientific Update in Internal Medicine with 8.7 points; in Professional Valuation with 8.9 points; in Personal Valuation with 9.1 points; in the Establishment of Peer Relations with 9.4 points and in the Development of Team Work with 9.2 points. We also point out that of the total 363 participants, 96.7% considered that their expectations with EVERMI were fulfilled, and, 98.9% recommended to their colleagues the participation in this school.

Conclusion

EVERMI students have demonstrated a high degree of satisfaction with their participation in this training course. It is concluded that EVERMI is assumed after 10 years of existence as an important milestone in the training of young internists in Portugal.

#1702 - Medical Image

A PULMONARY POPCORN LESION

Helena Greenfield¹, Denise Magalhães¹, Andreia Vilas Boas²

¹ Hospital Pedro Hispano, Matosinhos Local Health Unit, Matosinhos, Portugal

² Hospital da Luz Arrábida, Vila Nova De Gaia, Portugal

Clinical summary

A hospitalized patient with constitutional symptoms and hydropneumothorax performed a computed tomography scan (CT), which revealed pleural thickening, a “popcorn” lesion in the left lower pulmonary lobe and an enlarged prostate gland. This led to the diagnosis of two synchronous neoplasms: prostatic and pulmonary adenocarcinoma. The case presents fascinating aspects, namely the diagnostic challenge. However, the most striking image is the 3cm lesion with popcorn calcifications, suggestive of hamartoma. Hamartomas are mostly incidental findings: CT allows the detection of intralesional fat and calcifications, present in a minority of lesions, which lead to the typical “popcorn” configuration. This is noteworthy as a pathognomic presentation of hamartoma: characteristic, but infrequent.

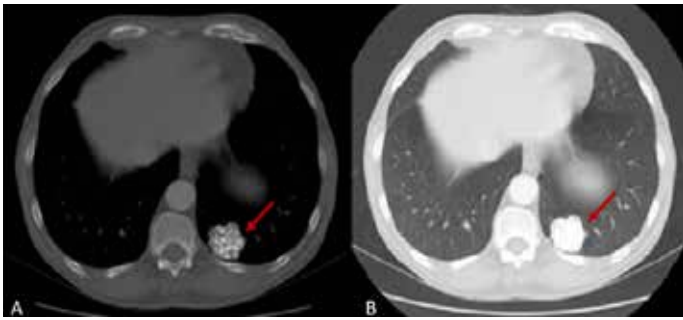


Figure #1702. Contrast-enhanced Computed Tomography in the axial plane (bone window (A.) and lung window (B.)). Well-circumscribed mass in the left lower lobe posterior segment, with lobulated margins, presenting popcorn like calcifications, suggestive of pulmonary hamartoma.

#1716 - Case Report

BONE PAIN IN THE ELDERLY - PAGET'S DISEASE?

Rui Domingues¹, Edgar Amorim², Joana Amorim¹, Cindy Tribuna¹, André Santa Cruz^{1,3}

¹ Internal Medicine Department, Braga Hospital, Braga, Portugal

² Physical Medicine and Rehabilitation Department, Braga Hospital, Braga, Portugal

³ Life and Health Sciences Research Institute (ICVS), School of Medicine, University of Minho, Braga, Portugal

Introduction

Paget's disease is a focal disorder of the bone metabolism, occurring in the aging skeleton. Bone remodeling is increased, which causes an overgrowth at a single or multiple sites, impairing its integrity. Usually affects the skull, pelvis and long bone of the lower extremities. Most patients are asymptomatic, so diagnosis is usually made on routine chemistry or imaging study requested by other reasons.

Case description

A 72 years-old man, with history of arterial hypertension, dyslipidemia, prostatic hyperplasia and traumatic fracture of the right femur, presented, in an appointment in 2015, with back pain which irradiated down the leg. He had experienced some improvement with physical therapy, but later the pain started to involve the right ilium and right knee and he started to experience numbness of the lower extremities with prolonged sitting. Physical examination showed tenderness in the region of lumbar and sacral spine. The diagnosis of osteoarthritis was assumed, NSAIDs were prescribed but to no avail. As complaints persisted, a MRI of the spine/pelvis was requested, it showed "(...)no expansion of the vertebral bodies, but doubts remain about D12 showing signs of Paget's disease. Right ilium showed cortical expansion and thickening suggestive of Paget's disease (...)". As no analytic abnormalities were found, new imaging exams were requested. Bone scintigraphy, pelvic CT and bone biopsy were performed, having both imagiologic exams shown suggestive abnormalities

of Paget's disease, bone biopsy was performed, but showed no histological signs of the disease. On following appointments, the patients maintained pain complaints, despite analgesic therapy. Endoscopic exams and PSA were normal. A trial with pamidronic acid was then started, with excellent results, as in the next appointment, the patient was in no pain and had increased his physical activity. In 2017, he presented again with the same pain, and risedronic acid was prescribed, resulting in amazing improvements once again. A relapsing remitting course of the pain was associated with therapy with bisphosphonates over the next couple of appointments.

Discussion

This case shows that we should consider the possibility of Paget's disease in an old patient, with atypical complaints, and no response to the usual therapy, even when there are previous traumatic injuries that could justify the complaints. As such, exams should be requested according to that diagnostic hypothesis. Treatment with bisphosphonates is usually effective.

#1746 - Medical Image

COMPLICATION OF PLACEMENT OF PERCUTANEOUS ENDOSCOPIC GASTROSTOMY.

Miguel Borges Da Silva, Albina Moreira, Inês Rolla

Hospital Pedro Hispano, Unidade Local de Saúde de Matosinhos, Matosinhos, Portugal

Clinical summary

We describe the case of a 49-year-old male, totally dependent on daily life activities due to multiple sclerosis. Due to inability to swallow, he underwent percutaneous endoscopic gastrostomy (PEG) placement. During the first 24 hours after placement of the device the patient presented distended and painful abdomen. Imaging tests revealed high volume pneumoperitoneum, with PEG well positioned in the gastric lumen, and it was not possible to detect the site of air leak that conditioned the pneumoperitoneum. Upper gastrointestinal endoscopy identified gastro-cutaneous fistula peri gastrostomy orifice. The holes of the fistula and gastrostomy were closed. This clinical case shows the presence of complications (although rare) of the placement of devices for feeding.

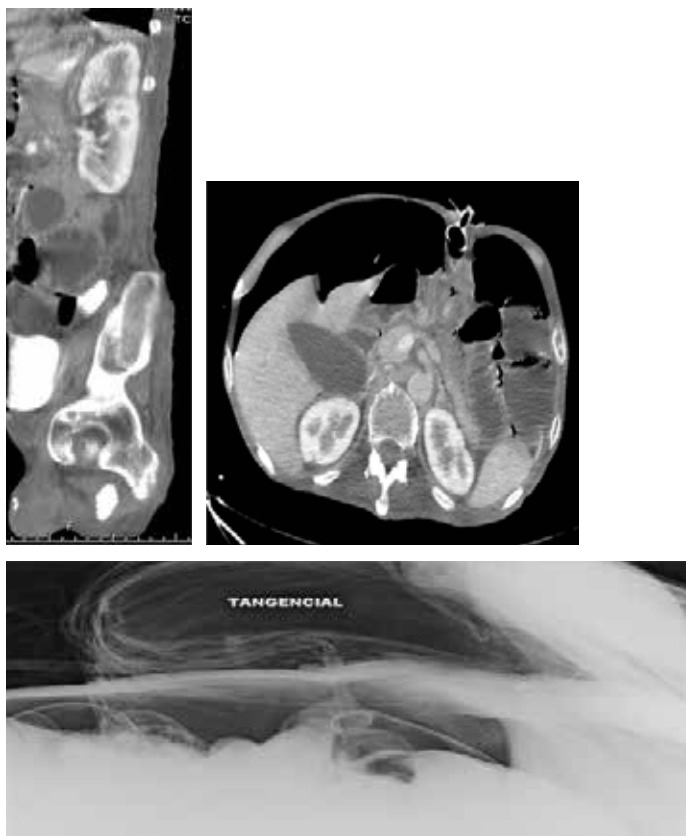

Figure #1746.

#1754 - Abstract

PLATELET DERIVED GROWTH FACTOR IN ALCOHOLICS

Ana María Godoy-Reyes, Víctor Vera-Delgado, Rosa Ros-Vilamajó, Paula Reyes-Suárez, Candelaria Martín-González, Esther Martín-Ponce, Camino Fernández-Rodríguez, Melchor Rodríguez-Gaspar, Emilio González-Reimers

Servicio de Medicina Interna. Hospital Universitario de Canarias, San Cristóbal De La Laguna, Spain

Background

Platelet derived growth factor (PDGF) promotes collagen deposition in the liver, acting on hepatic stellate cells. Despite this, low serum PDGF levels were reported in liver cirrhosis associated with hepatitis C or B infection, although some studies yield the opposite result. To our knowledge this has not been assessed in alcoholic cirrhosis.

Methods

In a series of 62 alcoholic patients consecutively admitted to our Internal Medicine service we determined serum levels of platelet derived growth factor (PDGF), as well as routine laboratory evaluation, tumor necrosis factor (TNF)- α , interleukin (IL)-6 and IL-8 as well as MDA levels.

Results

PDGF levels were significantly lower among patients (1074 ± 337

pg/ml vs 675 ± 466 pg/ml; $t=3.30$; $p<0.001$), especially among cirrhotics (549 ± 412 vs 778 ± 487 among non-cirrhotics; $Z=2.33$; $p=0.02$), and showed significant relationships with liver function (direct correlations with prothrombin activity ($\rho=0.50$; $p<0.001$) and inverse with bilirubin ($\rho=-0.39$; $p=0.002$)), and was also related to inflammation (IL-6, $\rho=-0.33$; $p=0.016$; IL-8, $\rho=-0.47$; $p<0.001$), and MDA ($\rho=-0.44$; $p<0.001$). It was also related to platelet count ($\rho=0.44$; $p<0.001$), and showed a trend to an inverse relationship with mean platelet volume ($\rho=-0.24$, $p=0.07$), that became significant when patients and controls were pooled together ($\rho=-0.38$; $p=0.001$).

Conclusion

Therefore, PDGF is decreased in alcoholics, more intensely in cirrhotics, and keeps a significant relationship with liver function impairment. These results are in contrast with the effects of PDGF on hepatic stellate cells, but they agree with some results obtained in patients with hepatitis B or hepatitis C chronic liver disease.

#1760 - Case Report

THE B12'S "COMPLEMENT"

Sara Augusta Ramos, Ivo Cunha

Hospital Pedro Hispano - ULSMatosinhos, Matosinhos, Portugal

Introduction

Vitamin B12 deficiencies are frequently found in the elderly. There seems to exist a relationship between vitamin B12 and the complement system, especially with low levels of C3.

Case description

We present a clinical case of a 86-year-old female, with a known history of episodic macrocytic anaemia and dietary restrictions, presented with a four days clinical picture of astenia, anorexia and jaundice in the last 24 hours. Analytically, with severe macrocytic anaemia [Haemoglobin (Hb) 4.4g/dL with Mean Corpuscular Volume (MCV) 112.5 fL], hyperbilirubinemia (Total Bilirubin 2.8 mg/dL), decreased haptoglobin (<8 mg/dL) and severe Vitamin B12 deficit (value <83 pg/mL). Peripheral blood smear with anisopoikilocytosis with macrocytosis, hypersegmented neutrophils and rare schizocytes. Negative direct and indirect Coombs test. The renal function and urinary sediment examination were normal. Secondary causes of hemolytic anemia were excluded. It was also documented C3 hypocomplementemia, with normal C4 levels, as well as, the Rheumatoid Factor and Erythrocyte Sedimentation rate. Upper Endoscopy showed atrophy of the gastric mucosa and lesions of chronic gastritis. Anti-gastric parietal cell antibodies and intrinsic factor antibody were negative. The patient started treatment with intramuscular cyanocobalamin, followed by oral replacement with recovery of the Hb and MCV values, as well as normalization of C3 levels.

Discussion

C3 hypocomplementemia associated with B12 deficit could be due

to impaired complement synthesis and reversible derangement. Normally the C4 is not affected and the rheumatoid factor is unchanged.

#1761 - Case Report

LIPIODOL EMBOLIZATION OF THE THORACIC DUCT – THE FINAL APPROACH OF REFRACTORY CHYLOTHORAX

Isabel Cruz Carvalho, Ana De Carmo Campos, Sara Sarmento, Teresa Fonseca

Centro Hospitalar de Lisboa Norte - Hospital Pulido Valente, Lisboa, Portugal

Introduction

Chylothorax (CT) results from lymph accumulation in the pleural space, usually due to trauma or obstruction of the thoracic duct. Malignancy is the most common cause of non-traumatic chylothorax (about 50% of all CT). Sarcoidosis and Tuberculosis are other common causes. Traumatic, iatrogenic or non-iatrogenic, causes are also frequent. Treatment of the underlying cause is usually the first approach to CT. The most successful conservative therapy in CT is associated with traumatic etiology and low output.

Case description

A 27-year-old woman had the recent diagnose of Sarcoidosis, after mediastinic node biopsy with a sarcoid granulomatous appearance. Despite corticosteroid therapy, there was a progressive decrease in the vesicular murmur in the left hemithorax, with hypotransparency in the chest X-ray compatible with pleural effusion. Thoracic CT scan confirmed a left pleural effusion, showing no alterations in the pulmonary parenchyma. Thoracentesis was performed with drainage of 480ml of citrus yellow liquid, with transudate characteristics. Microbiologic and cytopathological examination of the pleural fluid was negative.

Two days later, there was a recurrence of the left pleural effusion, and 600ml of pleural milky fluid were drained, with the following parameters – pleural liquid proteins/serum proteins 0.5, pleural liquid LDH/serum LDH 0.46, ADA negative, triglycerides 2382, and a cytology with predominance of lymphocytes (94%). An outpatient drainage device was placed, but the patient maintained a significative passive chylothorax drainage (50 to 200ml daily) during the next four months, despite being under therapy with octreotide and on a strict hypolipidic diet.

The therapeutic approach progressed for pleural talcage via left thoracoscopy, without resolution of CT.

Since it was a refractory CT to conservative therapy, it was decided to perform a lymphangiography, to clarify the leak zone. Lymph leakage was detected in the upper portion of the thoracic duct. After discussion of the case in a multidisciplinary team, it was decided to proceed to the embolization of the thoracic duct with Lipiodol, through an inguinal node puncture, with complete cure of CT.

Discussion

Lipiodol is an oil-based radio-opaque contrast agent, currently less used due to his adverse effects. Regardless, it remains the ultimate therapeutic approach of refractory CT and there is indication to repeat the procedure in case of relapse.

#1767 - Abstract

EARLY INTRA-HOSPITAL MORTALITY AT AN INTERNAL MEDICINE DEPARTMENT

João Cruz Cardoso, Mariana Moniz Ramos, Ana Filipa Matos
Hospital de Santarém, EPE, Santarém, Portugal

Background

In-hospital mortality is considered one of the measures to assess the quality of treatment provided to patients. This study aimed to understand the demographic and clinical characteristics of patients with early in-hospital mortality (within the first 72 hours) to better identify the patients who require the most care.

Methods

Retrospective observational study of patients admitted between January 1 and December 31, 2018 at an Internal Medicine Department of a District Hospital. We evaluated the age group, sex, provenance, priority in Manchester triage, use of Emergency Department (ED) and previous admissions, vital signs (fever, tachycardia, hypotension and hypoxemia), mortality rate and diagnoses associated with death.

Results

In 2018, 3108 patients were admitted, of which 556 died (a mortality rate of 17.89%). Of these patients, 210 (37.7%) died within the first 72 hours. The mean age was 82.7 years, of which 112 (53.33%) were female. 117 (55.71%) patients were from long-term care institutions. In the previous 10 days, 13.33% (n=28) of the patients have been discharged from an internal medicine ward and, in the preceding 14 days, 27.62% (n=58) of the patients were discharged from the emergency department. Patients were triaged as immediate (2.86%; n=6), very urgent (77.63%; n=163), urgent (19.05%; n=40) and standard (0.48%; n=1). At admission, 38 (15.24%) had fever, 61 (29.05%) tachycardia, 76 (36.19%) hypotension and 143 (68.10%) hypoxemia. The most frequent diagnoses were: Pneumonia (42.79%; n= 89), Urosepsis (16.35%; n=34), Cerebral Vascular Accident (7.21%; n=15) and Metastatic Neoplasia (6.25%; n=13). 105 (50%) patients died in the ED, after admission and before getting to a medical ward.

Conclusion

Patients who died within the first 72 hours of admission accounted for a significant proportion of the total number of deceased patients admitted to the Internal Medicine Department. They are mostly elderly and institutionalized, triaged as immediate and very urgent. In an appreciable number of cases, patients have been recently in the emergency department or discharged from a medical ward. The infectious pathology was the main responsible for the admission.

#1772 - Abstract

SEASONAL VARIABILITY AND WEEKEND EFFECT ON MORTALITY AT 72 HOURS AT AN INTERNAL MEDICINE DEPARTMENT

João Cruz Cardoso, Mariana Moniz Ramos, Ana Filipa Matos
Hospital de Santarém, EPE, Santarém, Portugal

Background

In-hospital mortality is considered one of the measures to assess the quality of treatment provided to patients. This study aimed to understand whether mortality up to 72h in an Internal Medicine Department presented seasonal variability or weekend effect.

Methods

Retrospective observational study of admitted patients between January 1 and December 31, 2018, at an Internal Medicine Department of a District Hospital. The mortality rate was evaluated up to 72 hours per month and per weekday.

Results

In 2018, 3108 patients were admitted, of which 556 died (a mortality rate of 17.89%). Of these patients, 210 (6.76%) died at the first 72h. The mean age was 82.7 years, of which 112 (53.33%) were female. 117 (55.71%) patients were from long-term care institutions. The number of admitted patients per month ranged from 198 (6.37%) in September to 303 (9.75%) in January. The months with the highest mortality rate up to 72h were June (10.83%; n=26) and January (9.4%; n=28) and the months with the lowest mortality rate were May (4.23%; n=11) and March (4.36%; n=13). Sunday (11.29%; n=351) and Saturday (13.51%; n=420) were the days with the lowest number of admissions and Tuesday (15.51%; n=482) and Friday (15.86%; n=493) the days with the highest number of admissions. The highest mortality rate up to 72 hours per day of admission occurred on Sunday (8.83%; n=31) and on Saturday (8.7%; n=36) and the day of admission with the lowest mortality rate was on Monday (5.15%; n=24) and on Tuesday (5.60%, n=29). One patient admitted at the weekend had a mortality rate of 8.7% (n=67) and one patient admitted on weekdays had a mortality rate of 6.12% (n=143).

Conclusion

The number of patients admitted in an Internal Medicine Department varies throughout the year, with the months of January and June presenting a higher mortality rate. Patients admitted at the weekend have a higher mortality rate than patients admitted during the weekday. Further research is needed to understand if there are independent and potentially modifiable variables.

#1793 - Case Report

DISEASES PIRATES

María Escamilla Espínola, María Rocío García Alonso, Miriam Corral De La Calle, Cristina Arroyo Álvarez, Marco Antonio Budiño Sánchez, Demetrio Sánchez Fuentes
Complejo Asistencial de Ávila, Ávila, Spain

Introduction

Ascorbic acid (AA) was first isolated in 1928 by Albert Szent-Gyorgyi. However, the secondary effects of this deficiency were well known in the 15th and 16th centuries among sailors who spent a lot of months at sea.

AA is absorbed in the distal small intestine and it is stored in brain, eyes, leukocytes and glands. Human organism is unable to synthesize it, for this reason we must obtain requirements from external sources. This vitamin has got an essential role in the hydroxylation of collagen and is also needed in synthesis of neurotransmitter.

Case description

A 50-year-old man went to the emergency service with progressive clinic since along time ago. He expressed an important weakness, pain in lower extremities, difficulty to walk and general malaise. He also referred orthopnea, fever and over the previous 6 months the patient had lost some of his teeth. He lived alone at home and didn't work because he was handicapped. He smoked 20 cigarettes per day and drunk around two glasses of wine. On physical examination observed multiples hematomas in lower extremities by capillary fragility, perifollicular hemorrhages, and purple ecchymosed in the internal face of legs and areas of gingival bleeding. Several teeth were absent. On neurological examination showed neuropathic pain and sensitivity alteration in the lower limbs.

The results of the primary laboratory evaluation revealed a macrocytic anemia; High-density lipoproteins (HDL) at 17 mg/dL and low protein level. Vitamin C in plasma was less than 0.10 mg/dL, vitamin D at 5.1 ng/ml, folic acid at 1.2 ng/dL and vitamin B12 level was normal. The skin biopsy showed evidence of follicular hyperkeratosis and perifollicular hemorrhages. The pathological characteristics give light an illness caused by vitamin C deficiency. The treatment was started with AA 100 mg three times daily.

Discussion

While uncommon, scurvy should be recognized as a disease each more frequently in develop countries, like so a general increased awareness can help shorten the time to diagnosis and effective treatment of this condition.

In our society, AA deficiency occurs mainly among drug and alcohol abusers, people with low economic status or who have a poor diet of fruits and vegetables. The prognosis of scurvy is reported to be excellent if it is to initiate the correct treatment with Vitamin C supplementation that can be provided oral or intravenous routes. Clinical resolution generally occurs over a period of days to weeks.

#1832 - Case Report

ACUTE GENERALIZED EXANTHEMATOUS PUSTULOSIS

Isabel Maria Pinheiro, Gonçalo Ruas, Luíz Menezes Falcão
Hospital de Santa Maria, CHLN, EPE, Lisboa, Portugal

Introduction

The term acute generalized exanthematous pustulosis (AGEP) was first proposed in 1980. Until then it was considered a variant of psoriasis. The clinical picture is characterized by the abrupt onset of erythema and edema in intertriginous areas or face, with cranio-caudal spread and the appearance of hundreds of small and non-follicular pustules. Cutaneous manifestations are accompanied by a fever higher than 38°C, pruritus and neutrophilia. The mean duration of pustules is nine days (between 4-14 days), followed by spontaneous resolution with medication suspension and desquamation. It is possible to occur polymorphism of the lesions, being able to observe erythema multiforme type lesions, purpuric lesions and leukocytoclastic vasculitis. The most common causes of AGEP are reactions to acute infections (enteroviruses), drugs and mercury. Approximately 90% of the cases are caused by medications and include antibiotics (macrolides and beta-lactams), antifungals, calcium channel blockers, carbamazepine, paracetamol and antimalarials.

Case description

68 years old white male admitted with fever, cutaneous erythema and multiple small and non-follicular pustules, after oral fucidic acid medication for otitis, diagnosed by a primary care physician. Cultures were performed. The diagnosis of AGEP was made and he started topical and intravenous steroids with optimal clinical response.

Discussion

The prognosis of AGEP usually is good as in the case described but the suspected medication must be immediately suspended, and corticosteroid therapy may be prescribed both topically and systemically. Antibiotics should only be used when the infection diagnosis is well documented.

#1848 - Case Report

MASSIVE CARDIAC ASCITES IN CHRONIC RIGHT HEART FAILURE

Rute Brás Cruz, Diogo J. Silva, Joana Cancela
Hospital Pedro Hispano, Matosinhos, Portugal

Introduction

Ascites is infrequently caused by congestive heart failure, and massive ascites occurs most frequently in patients with tricuspid valve disease and constrictive pericarditis. Dietary sodium restriction and oral diuretics are mainstays of treatment; As patient deteriorates, there is an emerging need for alternative treatments such as serial large-volume paracentesis (LVP) to alleviate symptoms.

Case description

A 56-year-old woman with history of multiple admissions for anasarca and cardiorenal syndrome due to decompensated heart failure, presented to the emergency department complaining of asthenia, shortness of breath, orthopnea, weight gain and increasing abdominal girth during previous months. At presentation she was pale, dehydrated, tachypneic, hemodynamically stable with a globose tender abdomen and abdominal wall and lower limbs edema. On the week before admission she was medicated with furosemide 180 mg iv and 80 mg per os and metolazone 2.5 mg three times a week plus furosemide 360 mg per os four times a week.

Admitted with a total body weight of 146 kg for diuretic optimization.

Despite multiple diuretic adjustments losing 11 kg during 9 days, she maintained large volume ascites. Large volume paracentesis (LVP) was attempted but neither an abocath nor instruments such as venous central catheters or a pleuracan were able to reach the ascitic fluid due to the thickness of the adipose panniculus. Interventional radiology placed a pigtail catheter into the left iliac fossa and daily drainage of 4 liters during 12 days was performed. Ascitic fluid showed a serum-ascites albumin gradient (SAAG) >1,1 g/dL compatible with congestive heart failure. Microbiological and cytopathologic analysis were negative. Oral diuretics were started as soon as the catheter was removed and patient maintained weight. Patient was discharged with 84 kg and a total loss of 62 kg.

Discussion

When patients do not respond to sodium restriction and diuretics, this approach can cause intravascular volume depletion without significant loss of ascitic fluid. In such cases serial total LVP can control fluid overload. The use of peritoneal catheters to continuously drain steady amounts of ascitic fluid has been generally used in malignant ascites, but when the ascites is massive, and the adipose panniculus does not allow to drain the fluid with other methods, the use of a pigtail catheter may represent a more convenient strategy.

#1857 - Case Report

SWEET TASTE HYPERGEUSIA IN A PATIENT WITH INDAPAMIDE-RELATED HYPONATREMIA: AN UNCOMMON ASSOCIATION

Pedro Gaspar¹, Filipe Bessa¹, Raquel Castro², Pedro Meireles¹, Federica Parlato¹, João Meneses¹, Rui M. M. Victorino¹, Catarina Mota¹

¹ Serviço de Medicina 2, Hospital de Santa Maria, Centro Hospitalar Universitário Lisboa Norte, Lisboa, Portugal

² Unidade de Saúde Familiar Reynaldo dos Santos, Póvoa De Santa Iria, Portugal

Introduction

Taste disturbance is an uncommon, although well-recognized, symptom of systemic diseases Like malignancies and metabolic

disorders that tend to alter the taste perception in a non-selective way. Sweet taste hypergeusia is a type of dissociated dysgeusia where there is increased acuity for sweet perception only. This finding has been described in cases where hyponatremia developed in the setting of syndrome of inappropriate secretion of antidiuretic hormone and lung cancer.

Case description

A 71 year old woman presented to our ward with a three week history of non-selective anorexia, asthenia, nausea and weight loss due to an unpleasant sweet taste in which all food was perceived as sweet. Her past medical history included essential hypertension and depressive syndrome. Current medications included perindopril, paroxetine and, for a few weeks prior to the beginning of symptoms, indapamide. On physical examination, no relevant findings. Laboratory was as follow: glucose 171 mg/dL, blood urea nitrogen 37 mg/dL, serum creatinine 1.2 mg/dL, Na⁺ 120 mmol/L, K⁺ 2.2 mmol/L, Zn²⁺ 16.6 µg/dL, Cu 142 µg/dL, serum osmolality 257mOsmol/Kg, urinary osmolality 133 mOsmol/Kg. Chest X-ray was unremarkable as were her body and head CT-scans. Considering the diagnosis of hyponatremia and hypokalemia secondary to indapamide intake, she was kept under surveillance while the drug was stopped and electrolyte correction was administered. Over the following days, sweet taste sensation lessened as Na⁺ concentration began to rise and finally disappeared when Na⁺ concentration normalized. She got discharged with losartan and amlodipine. Till now, her serum Na⁺ concentration remained at normal levels and the sweet taste did not recur.

Discussion

Although several case reports have shown the association mentioned above, in this patient no malignancy was found. The relationship between serum Na⁺ concentration and the indapamide introduction and withdrawal, the presence of hypokalemia and the following maintenance of normonatremia without water restriction favors the hypothesis of hyponatremia secondary to diuretic use. To the best of our knowledge, it is the first case report of sweet taste hypergeusia in the setting of hyponatremia secondary to indapamide use.

#1858 - Case Report

CUTANEOUS NECROSIS SECONDARY TO TERLIPRESSIN IN A PATIENT WITH LIVER DISEASE: A RARE ISCHEMIC COMPLICATION

Diana Pinho Santos¹, Filipe Nery², Diana Valadares²

¹ Centro Hospitalar Tondela-Viseu, Viseu, Portugal

² Centro Hospitalar Universitário do Porto, Porto, Portugal

Introduction

Terlipressin is a vasopressin analog used in the treatment of hypertensive upper bleeding of cirrhotic patients and hepatorenal syndrome. The commonest adverse effects include bradycardia,

diarrhoea, abdominal cramping and hyponatremia. Ischemic complications are rare but may be life threatening.

Case description

We report a case of a 71-year-old man with a recent hospitalized proved diagnosis of amiodarone- induced cirrhosis, which was previously given in the set of atrial fibrillation. He was admitted at intermediate care unit in the context of esophageal variceal bleeding that was controlled with endoscopic banding and terlipressin 1 mg 4/4h (total dose 13 mg). About 2 weeks later, he developed a hepatorenal syndrome (HRS) and terlipressin 1 mg 6/6h with albumin 30g/day was instituted. Four days after started treatment for HRS, hematomas and purpuric lesions appeared on the upper thighs and scrotum and generalized to limbs, trunk and abdominal wall with skin detachment at scrotum level. Rhabdomyolysis [Lactate dehydrogenase (LDH)- 723 U/L, creatine kinase (CK)- 10900 U/L] also was documented. Skin biopsy was performed and showed epidermis necrosis foci with vesiculation/detachment areas of the dermis and red blood cell extravasations with edema and homogenization of collagen of the papillary dermis, without vasculitis; direct immunofluorescence was negative. Epidermal necrosis was attributed to terlipressin that was withdrawn. The skin condition gradually improved and CK levels normalized.

Discussion

About 20 cases of cutaneous necrosis to terlipressin were described. The causal mechanism is unclear now, but it is supposed to result from compromised tissue oxygenation caused by microcirculatory failure. Dose-dependent effect has been proposed. Commonest involved areas are limbs, abdomen and scrotum. The causal relationship is based on temporal relation, lesion distribution and compatible biopsy. Although rare, the ischemic complications caused by terlipressin should be though.

#1866 - Medical Image

ERITEMA AB IGNE

Fabio Caleça Emídio, Sofia Amalio

Centro Hospitalar Universitário do Algarve, Faro, Portugal

Clinical summary

A 65-year-old woman, with medical history of insulin treated Type 2 Diabetes, atrial flutter and morbid obesity, was hospitalized for diabetic ketoacidosis, complicated by aspiration pneumonia, and with a recent hospitalization for elective cholecystectomy.

In order to control pre-surgery biliary colics, she was a frequent user of a heating pad in the abdominal region, leading to the appearance of an extensive erythema ab igne.

Erythema ab igne is a rare reticular pigmented dermatosis, caused by prolonged and repeated exposure to heat.

In this set of images we can visualize in detail the pigmented dermatosis as well as the small surgical incisions of previous laparoscopic cholecystectomy.

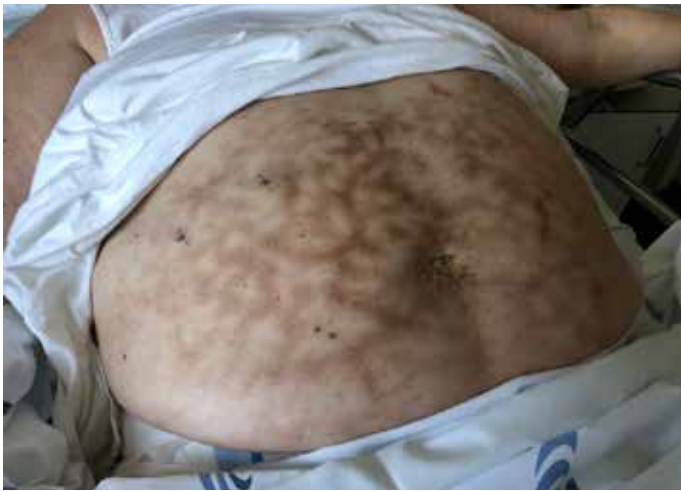

Figure #1866. Eritema Ab Igne.

#1873 - Case Report

LAMOTRIGINE-VALPROIC ACID INTERACTION - IT TAKES TWO TO TANGO

Vanessa Barcelos, Ana Carolina Ferreira, Marlene Estácio, Mariano Pacheco

Hospital Divino Espírito Santo, Ponta Delgada, EPE., Ponta Delgada, Portugal

Introduction

Lamotrigine is a common, newer generation anticonvulsant that has been widely used to treat a variety of conditions including bipolar disorder. It is effective and safe, however one of its common side effects is allergic skin rash, known to be dose- and titration-dependent.

Case description

The authors present a case of a 59-year-old woman who presented within two days after the start of flu like symptoms to her general practitioner. She had a history of bipolar disorder with introduction, in the week prior to the presentation, of sodium valproate (VPA) 500 mg twice a day and lamotrigine (LTG) 50 mg twice a day. In the first 24 hours after presentation she developed a pruritic morbilliform rash over the chest, arms and legs, without involving the mucous membranes. She stopped LTG and started systemic corticosteroids. After one week after presentation the rash didn't improve, spreading to the face, with rubor and edema and with a new bullous lesion in the hand. The lab results revealed only elevated transaminase levels (with an alanine transaminase four times higher than the normal range). Sodium valproate was immediately stopped for fear of the development of Steven Johnson Syndrome. After that there was regression of the lesions.

Discussion

The case shows the importance of slow titration, especially for patients started on lamotrigine with valproate, and supports the clinical evidence that a combination of LTG and VPA increases the frequency and severity of skin reactions.

#1876 - Medical Image

SCURVY

María Escamilla Espínola, María Rocío García Alonso, Miriam Corral De La Calle, Cristina Arroyo Álvarez, Marco Antonio Budiño Sánchez, Demetrio Sánchez Fuentes

Complejo Asistencial de Ávila, Ávila, Spain

Clinical summary

A 50-year-old man with important weakness, pain in lower extremities, difficulty to walk, orthopnea, fever and loss of some teeth. Among his personal history, some of the conditions he suffered from are HBV completely cured, deep vein thrombosis, pulmonary tuberculosis and neuropathy. He is a smoker and drinks around two glasses of wine daily. On physical examination, multiple hematomas in lower extremities, perifollicular hemorrhages, petechiae and coiled hairs were observed. Deterioration and loss of several teeth; and areas of gingival bleeding. A skin biopsy shows evidence of follicular hyperkeratosis and perifollicular hemorrhages. These pathological features are typical of vitamin C deficiency. An insufficient contribution of Vitamin C can produce a connective tissue disorder.

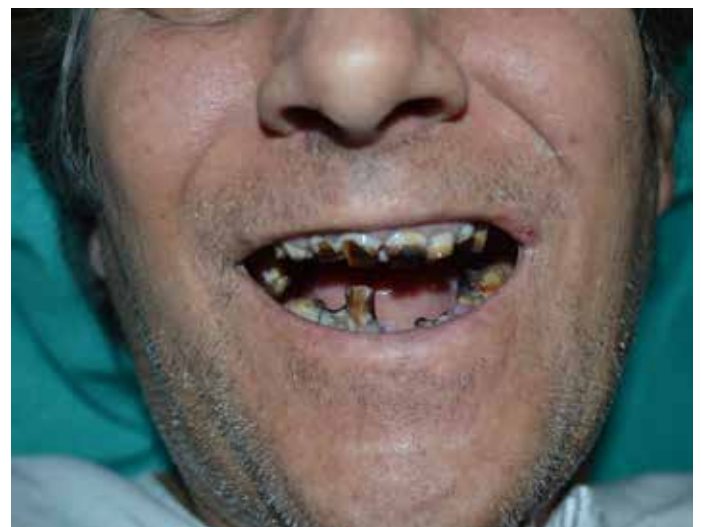

Figure #1876. Deterioration and loss of several teeth.

#1896 - Medical Image

PNEUMO-ORBIT, WHAT A SNEEZE CAN DO

Pedro Gaspar¹, Filipe Bessa¹, Pedro Meireles¹, Federica Parlato¹, Raquel Castro², Galini Vieira³, João Meneses¹, Rui M. M. Victorino¹, Catarina Mota¹

¹ Serviço de Medicina 2, Hospital de Santa Maria, Centro Hospitalar Universitário Lisboa Norte, Lisboa, Portugal

² Unidade de Saúde Familiar Reynaldo dos Santos, Póvoa De Santa Iria, Portugal

³ Hospital de Cascais, Lisboa, Portugal

Clinical summary

Pneumo-orbit is a condition that occurs following forceful injection of air into the orbital soft tissue. Although most cases

follows trauma or fracture of an orbital bone, non-traumatic cases, although rarer, have been described.

57 year-old male, no background, admitted in our medical ward with sudden-onset back-eye pain and proptosis of the left eye after containing a sneeze, without eye movement limitation and no loss of visual acuity. The brain-CT showed intra and extra-conical areas of pneumo-orbits foci in the left eye with a small area of papyraceous lamina dehiscence. He was kept in surveillance and undergo spontaneous resolution.

In the absence of local complications, conservative approach is usually enough as orbital emphysema should resolve on its own as the air is absorbed.

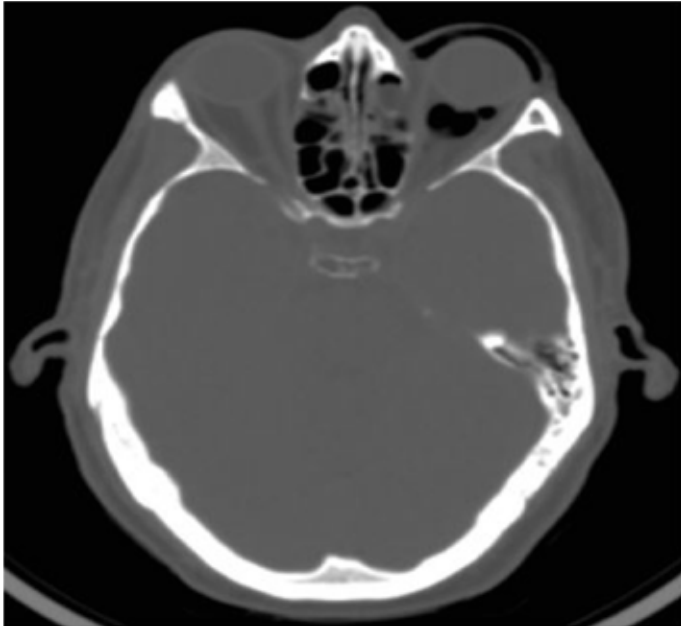


Figure #1896.

#1953 - Abstract

ENOXAPARIN: RISKS AND BENEFITS

Margarida Dias Agudo Gomes Neto, Sonia Serra, Jose Pedro Villa De Brito

Centro Hospitalar de Setubal, Setubal, Portugal

Background

Enoxaparin is an anticoagulant which is classified as a low weight molecular heparin. It is usually used in the prevention of thrombotic events mobility-impaired patients during acute disease as well as a substitute for oral anticoagulant therapy of ambulatory. A number of hemorrhagic complications are noted and described during its use and administration. These complications are mainly due to fluctuations of its bioavailability within the organism which can be altered by factors such as the form of administration or pharmacologic interactions.

Methods

Descriptive and retrospective study of patients admitted in a medicine service during 9 months which presented serious hemorrhagic

complications and were being administered with enoxaparin to confirm possible predisposing factors to their occurrence. Data were collected using SCLINICO and analysed using SPSS.

Results

The clinical processes of 11 patients were analysed, of whom 18,18% were men and 81,82% women with average ages of 74,75 years. They were admitted to a medicine service with an average length-of-stay of 25 days, 27,27% of the patients were anticoagulated with enoxaparin at therapeutic dose vs 72,73% at prophylactic dose. It was verified that hemorrhagic complications occurred after 10,36 days in average, 36,36% being abdominal hematoma, 9,09% retroperitoneal hematoma, 9,09% psoas muscle hematoma, 9,09% hematuria and 18,18% gastrointestinal bleeding. It was verified that 81,82% of the hemorrhagic complications resulted in significant decrease of hemoglobin value (<8mg/dl); 18,18% of the patients presented a reduced aPPT value whilst 81,82% presented a normal aPPT value; 27,27% presented thrombocytopenia while 72,73% presented normal values of platelets. It was observed that 63,64% of patients were under antibiotic therapy with piperacilin and 63,64% under systemic corticotherapy.

Conclusion

The majority of hemorrhagic complication occurred on average after 1 week of anticoagulation therapy and mostly on female and elderly patients. Pharmacologic interactions seem to have influence at our sample, with emphasis on piperacillin and systemic corticotherapy which is supported by literature.

#1958 - Case Report

A RARE ASSOCIATION OF GALLBLADDER CANCER AND ANCA- ASSOCIATED VASCULITIS: A CASE REPORT

Sarra Haddad¹, Amel Harzallah¹, Hayet Kaaroud¹, Maha Chiekh¹, Fathi Ben Hamida²

¹ Departement of Medecine A, Charles Nicole hospital, Tunis, Tunisia

² Laboratory of Renal Pathology LRPS001, Charles Nicole Hospital, Tunis, Tunisia

Introduction

ANCA-associated vasculitis is a severe autoimmune disorder characterized by inflammation and necrosis of small vessels. Its prognosis has been markedly improved by the introduction of immunosuppressive treatments. Nevertheless, this has been associated with an increased incidence of malignancy in this population.

Case description

We report the case of a 60- years-old women who was admitted to our department for intense asthenia, dyspnea and acute kidney injury. On admission, she had oliguria and microscopic hematuria. The initial laboratory tests showed serum creatinemia at 764

µmol/L, a proteinuria at 1,2 g/24 h and a biological inflammatory syndrome. The c-ANCA with anti- PR3 was positive. The thoracic CT showed right apical parenchymal condensation with eccentric excavation and pulmonary embolism of the middle lobar artery. Bronchoalveolar lavage did not show signs of intra-alveolar hemorrhage. The renal biopsy was not performed since the patient was on anticoagulant therapy. The diagnosis of ANCA-associated vasculitis has been made. The treatment consisted of intravenous pulse methylprednisolone, 500 mg daily for three days, followed by oral prednisone (1 mg/kg daily) associated with six pulses of cyclophosphamide (15 mg/kg/month). The evolution was favorable with clinical improvement and normalization of renal function. She was put under a maintenance treatment based on MMF (2 g daily). After a follow-up of 3 years, the patient presented weight loss and jaundice. Hepatic MRI was performed to demonstrate the presence of dilatation of the bile ducts upstream of suspicious thickening of the common bile duct. She had a surgical exploration finding an under hepatic mass with locally advanced. Histological examination concluded to a carcinoma of the gallbladder. The patient had external biliary drainage associated with palliative chemotherapy.

Discussion

The risk of malignancy in patient with ANCA-associated vasculitis is significantly increased. The most common tumors were skin tumors (excluding melanoma) and bladder tumors. Bile duct cancers were rarely associated with ANCA vasculitis. The role of cyclophosphamide has been well documented in several studies. Predictors of this complication were mainly high doses of cyclophosphamide and treatment duration of more than one year. But, are there other factors related to the disease itself that may be causing this complication?

#1964 - Case Report

DRESS SYNDROME: ALLOPURINOL

André Santos, Lénea Porto, Dora Gomes, Giovanna Ennis, Carolina Ferreira, Elisa Moreira, José Martins, António Correia
CHTV, Viseu, Portugal

Introduction

Drug reaction with eosinophilia and systemic symptoms (DRESS) syndrome is a complex entity with a broad spectrum of clinical features. Commonly presenting with fever, hematological findings (leukocytosis, eosinophilia, etc.), cutaneous manifestations, typically an urticarial, maculopapular eruption and, in some instances, vesicles, bullae, pustules, purpura and erythroderma. Visceral involvement (hepatitis, pneumonitis, myocarditis, pericarditis and nephritis) is the leading cause of morbidity and mortality in this syndrome. The clinical manifestations usually are not immediate and tend to appear 2 to 8 weeks after introduction of the triggering drug. The life-threatening potential of DRESS syndrome is high and multiple studies shown an estimated mortality of 10 percent.

Case description

86 years old women presented to the emergency department with hypotension and prostration with two days of evolution without fever or other infection suggestive symptoms. Known antecedents of atrial fibrillation, heart failure, arterial hypertension and gout with recent introduction of Allopurinol therapy 2 weeks before. The physical exam revealed an arterial pressure of 79/52 mmHg with a heart rate of 70bpm, diffuse non-pruritic rash with palmar-plantar involvement, without fever, suggesting an erythroderma. Blood analysis revealed leukocytosis ($16.70 \times 10^9/L$) with eosinophilia ($2.6 \times 10^9/L$), 11.6 g/dL of hemoglobin, SCr of 3.4 mg/dL (0.6mg/dL 1 month ago), GGT of 415 UI/L, alkaline phosphatase of 261 UI/L, AST of 522 UI/L, ALT of 849 UI/L and an ultrasensible-CRP of 7.0 mg/dL. Serologic screening for hepatitis, HIV, EBV, CMV, *Syphilis*, *Rickettsia* and *Toxoplasma* was non-reactive. Superior abdominal and renal ultrasound examination didn't show any relevant findings. With negative urine and blood cultures, a DRESS syndrome to Allopurinol suspicion was raised and the drug was withdrawn. The patient started an oral corticosteroid therapy with significant improvement of the skin rash and analytical reversion of the liver and kidney injury markers.

Discussion

Although DRESS syndrome is a relatively rare condition, Allopurinol is one of the most common causal drugs. Since Allopurinol is widely prescribed, special care should be given to any patient presenting with any suggestive symptoms of DRESS syndrome given it's high life-threatening potential and fast evolution rate.

#2050 - Case Report

ADULT STILL DISEASE

Ana Isabel Barreira, André Maia, Andreia Costa, Fernando Salvador
CHTMAD, Vila Real, Portugal

Introduction

Adult onset Still's disease (AOSD) is a rare systemic inflammatory disease with estimated incidence of 0.16 per 100000 inhabitants and bimodal distribution between 16-25 years and 35-45 years. Etiology remains unknown, although in some cases genetic factors may be involved. Common clinical manifestations include fever, maculopapular rash, arthralgia or arthritis, affecting 75-95% of patients.

Case description

47 year old female with history of reactive depression. She developed maculopapular exanthem affecting the lower limbs over 24-48h, which then extended proximally to the abdominal region. She was observed in the the emergnecy room (ER) and was medicated with bilastine and deflazacort 60 mg. Five days later, after transient recovery, she returned to the ER due to worsening symptoms and therapy was switched to topical corticoid. She

returned the next day for symptom persistence as well as fever, arthralgia and local inflammation signs affecting both knees and the right elbow, and was admitted for diagnostic workup. Blood tests revealed increased ALT (50% above upper normal limit [UNL]), CRP (10.8 mg/dL) and ferritin (3289 ng/mL). A working diagnosis of zoonosis was assumed prompting therapy with ceftriaxone and doxycycline. In the face of persisting symptoms further workup was undertaken, with consistently unremarkable results (autoimmunity, serology, microbiology, echocardiogram and chest-abdomen-pelvis computer tomography). AOSD was considered the most likely diagnosis and therapy with prednisolone (PDN) 1 mg/kg/day was started, with immediate and subsequent clinical improvement. After discharge she developed corticosteroid-induced psychosis and PDN dose was quickly decreased. She then had a relapse of AOSD and began therapy with methotrexate, attaining remission.

Discussion

This case illustrates the sharing of common features between AOSD and a vast list of diagnoses, warranting the exclusion of neoplastic, autoimmune or infectious diseases. AOSD diagnosis requires the fulfilling of at least five Yamaguchi's criteria, two of which must be major. The patient had five criteria – three major (fever, arthritis and maculopapular intermittent evanescent exanthem) and two minor (ALT 50% above UNL, ANA and RF negativity).

AOSD may assume three evolution patterns – single episode, intermittent, or chronic. Treatment is tailored to the severity of the manifestations and includes NSAIDs, corticoids, methotrexate and anti-TNF agents.

#2126 - Case Report

ANTIBIOTIC THERAPY - A TWO SWORD KNIFE

Margarida Dias Agudo Gomes Neto, Maria Caixas Lima, Sónia Serra, Jose Pedro Villa De Brito

Centro Hospitalar de Setubal, Setubal, Portugal

Introduction

Antibiotic therapy with Carbapenems and Glycopeptides are strong weapons against bacterial infections. Vancomycin is important against skin and soft tissue infections while Carbapenems are used against hospital infections by multi-drug resistant microorganisms or after therapeutical failure of the previous antibiotic treatments. Long term antibiotherapy can cause hematologic findings such as neutropenia and leucopenia. The discontinuation of the treatment is revealed as the normalization of the neutrophil and leucocyte levels.

Case description

Female, 62 years old with personal medical history of Bipolar Disease, Hypertension, Diabetes Mellitus type 2 and Hashimoto Thyroiditis. The patient was brought to the Emergency Unit

because of voluntary intoxication with benzodiazepines. During hospital admission was admitted to ICU with the need of a central venous line placement. During the hospitalization clinical inflammatory signs in the left hip region appeared together with fever and analytical inflammatory markers. Blood cultures isolated *Staphylococcus sensibile* to vancomycin and targeted therapy was started. Due to clinical deterioration an MRI was performed showing the presence of a high volume liquid collection in the inflamed region with aponeurosis discontinuity. A piomiositis was assumed by probable nosocomial etiology without clinical response to vancomycin in monotherapy. New blood cultures were collected and Meropnem was added to the therapy. The patient had a positive clinical and analytical outcome with the double antibiotic therapy. At the 28th day of therapy with Vancomycin and 18th of Meropnem a significant decrease in absolute leukocyte count to 2,000/mm³ with neutropenia of 23% neutrophils was noted. A blood smear confirmed the leukopenia. Due to the maintenance of leukopenia and clinical favorable outcome the antibiotic treatment was stopped with normalization of leukocyte and neutrophil levels until patients discharge.

Discussion

Meropnem is a potent therapeutical coverage against nosocomial infections. Association with vancomycin made possible a successful infectious outcome. The importance of infectious focus control should have been taken as the essential key to resolution of the focus, in order to decrease the long-term broad spectrum antibiotics and its consequences. This case alerts to the importance between risks and benefits of long-term antibiotherapy as well as the use of auxiliary therapies to minimize complications.

#2180 - Abstract

BACTERAEamia IN INTERNAL MEDICINE DEPARTMENT: A CASE SERIES

Carolina Gonçalves Carvalhinha, Daniela Abreu Silva
SESARAM, Funchal, Portugal

Background

Bacteraemia is the presence of bacteria in blood circulation. It is estimated that 12% of the bacteraemia are nosocomial infections and 15% are healthcare-associated infections. Most of the bacteraemia acquired in the community are secondary and frequently originated on a respiratory, urinary or skin focus. The mortality rate of this condition worldwide ranges from 3 to 35%. The purpose of this paper is to characterize the bacteraemia cases admitted in Internal Medicine Department at Funchal Central Hospital and compare it with the global panorama.

Methods

It's a retrospective and transversal study. There were considered all the patients admitted in Internal Medicine Department of Funchal Central Hospital who had a positive haemoculture for bacteria from 2016 to 2018. We excluded those patients whose haemocultures

were interpreted as contaminations by their attending physician and patients with no information regarding the episode in the process. The medical records of the patients included were reviewed and extracted information about sex, age, infectious focus, type of infection, microorganism, comorbidities, hospital admission in the last 90 days, invasive procedures in the last 30 days, antibiotherapy in the last 90 days and intra-hospital death.

Results

Out of the 750 haemocultures included, 289 (38.5%) were nosocomial infections. In 582 (77.6%) the patients were over 65 years-old. The infectious focus was respiratory in 322 (39.9%) and urinary in 312 (38.6%). *E.coli* was found in 76 (23.6%) cases of respiratory focus and in 208 (66.7%) cases of urinary focus. It were registered 557 (74.3%) cases of cardiovascular disease, 261 (34.8%) cases of diabetes, 215 (28.7%) cases of bedridden patients, 168 (22.4%) cases of antibiotherapy in the last 90 days and 154 (20.5%) cases of cerebrovascular disease. There were 203 (27.1%) deaths during the hospitalisation and 137 (67.5%) occurred between 2 to 30 days after blood sampling for haemoculture.

Conclusion

In this department, 38.5% of the bacteraemia were nosocomial. The most affected age bracket was over 65 years old. The most common focus were respiratory and urinary, being *E. coli* the most frequent microorganism for both. The most frequent comorbidities were cardiovascular disease, diabetes, bedridden patients, antibiotherapy in the last 90 days and cerebrovascular disease. The intra-hospital mortality rate was 27,1% and its peak was from day 2 to day 30 after haemoculture.

#2193 - Abstract

PAIN ASSESSMENT AND MANAGEMENT - AN OBJECTIVE ANALYSIS IN AN INTERNAL MEDICINE WARD

Joao Gamito Lopes, Lucas Diaz, Jose Sousa E Costa

Hospital do Litoral Alentejano, Santiago Do Cacém, Portugal

Background

Pain is a common experience for many patients admitted in the Medical ward and has been defined by WHO as the fifth vital sign. Efforts should be undertaken to address and improve the assessment and management of pain. The authors proposed to assess the pain in patients already admitted in the wards as well as if it is being managed accordingly. Also, try to identify risk factors for pain development.

Methods

Retrospective observational descriptive study with data collection in one day. No exclusion criteria. For pain assessment visual numeric scale and Pain Assessment in Advanced Dementia were used, for patients able to communicate and those unable to communicate, respectively. Data collection included demographic

(age, gender), admission diagnosis, if the patients were highly dependent, presence of a feeding tube, pressure ulcers, previous diagnosis of oncologic disease, chronically medicated to pain, medical and nursing record of pain assessment. Descriptive statistic was done on Microsoft Excel® worksheet. Fisher-test was used for nominal variables.

Results

We included 44 patients, mean age was 71.3 years old. (SD: 16,1) with no gender predominance. 73% (n=32) of the patients were able to communicate with 44% showing a degree of pain, 40% of them reporting severe pain. 42% (n=5) of the patients unable to communicate had pain, although none of them had severe pain. Overall 22,7% of the patients had no pain and no prescription in case of necessity. Medical records of pain assessment were present only on a minority of the patients (18%) regardless of patients' ability to communicate. Nurses pain assessment record was universal. No statistical significance was found between pain and proposed variables.

Conclusion

The authors found a significant amount of patients with pain. Past medical record or devices were not statistically related to the presence of pain, although it may be due to the small sample. It is obvious the lack of importance given by doctors to pain assessment records. Recommendation on education on pain assessment and management are addressed.

#2202 - Medical Image

THE NUTCRACKER

Fabiana Costa Pimentel, Lisete Nunes, Ivone Barracha, Rosa Amorim

Centro Hospitalar do Oeste - Torres Vedras, Torres Vedras, Portugal

Clinical summary

The Nutcracker phenomenon is a rare condition whose prevalence is unknown. It is characterized by the compression of the left renal vein (LRV) between the aorta and the superior mesenteric artery resulting in the elevation of the LRV pressure and the development of collateral venous circulation. It may consist of an anatomical imaging findings without clinical manifestations or associated with signs such as hematuria, orthostatic proteinuria, varicocele, among others.

Case report

Male patient, 24 years old, with no relevant personal history, hospitalized with the diagnosis of acute myocarditis and sepsis with a respiratory starting point. It was performed an Abdominal Angio-CT that revealed the anatomical finding of LRV stenosis in the mesenteric interaortic segment - Nutcracker Syndrome.

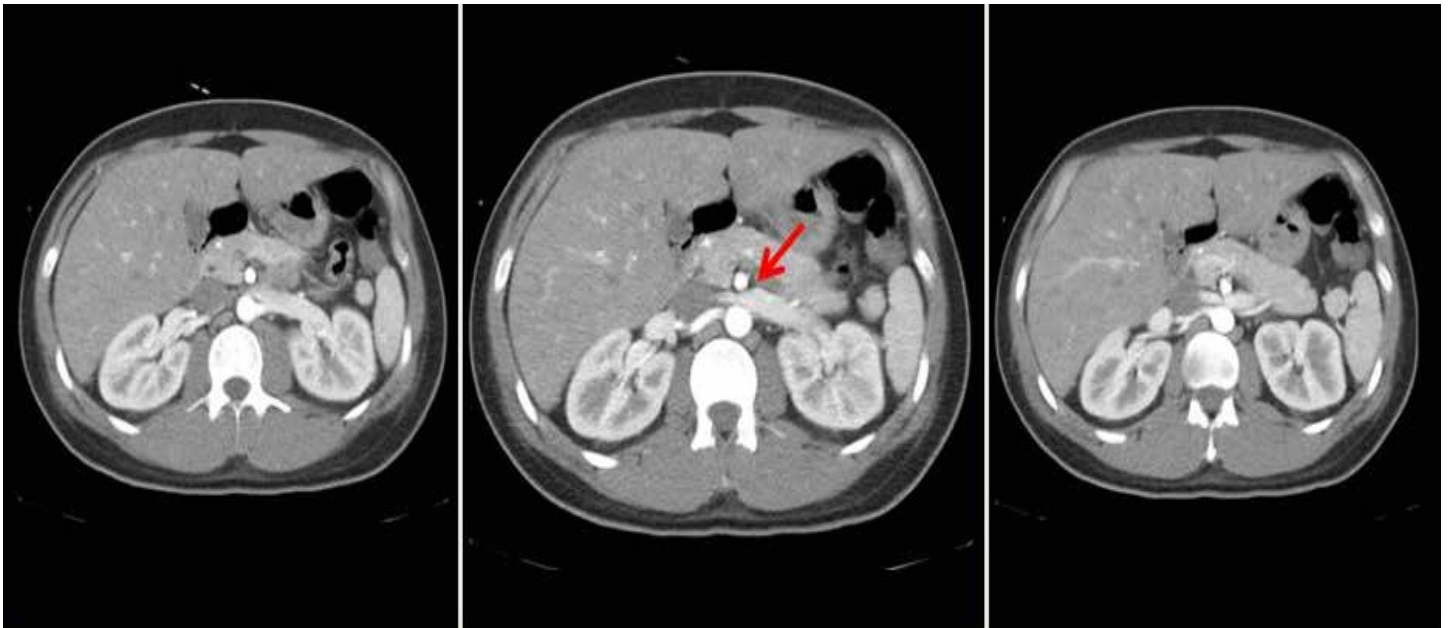


Figure #2202.

#2208 - Case Report

ENOXAPARIN INDUCED MACULOPAPULAR RASH

Margarida Lopes Madeira, Daniela Félix Brigas, Gonçalo Mendes, Mafalda Figueira, Francisca Santos, Diana Silva, Clara Rosa, Eugénio Nóbrega Dias, Ermelinda Pedroso
Centro Hospitalar de Setúbal, Setúbal, Portugal

Introduction

Low molecular weight heparins (LMWH) are widely used worldwide, as in cases of acute coronary syndrome, deep vein thrombosis or pulmonary thromboembolism. The adverse effects associated with these drugs are cases of severe bleeding, while skin reactions are rare.

Case description

The authors present the case of a 45-year-old woman with a personal history of obesity and hypertension who is admitted to the Internal Medicine service due to pulmonary thromboembolism, which is why she was treated with LMWH at a dose of 1mg/kg administered from 12 in 12 hours. On the 3rd day of hospitalization she developed pruritic maculopapular erythema in the thoracic and face regions, associated with dyspnea, although without stridor or edema of the tongue. Treatment with systemic corticosteroids and antihistaminic was initiated and all drugs administered during hospitalization except LMWH were discontinued. Symptomatology was improved, but there was little remission of erythema. Thus, it was decided to replace LMWH with a Direct Action Oral Anticoagulant, as a solution for her condition. At the outpatient clinic, the patient performed a challenge test with LMWH that proved to be positive, and the hypersensitivity reaction to this drug was confirmed.

Discussion

The major adverse events associated with LMWHs include hemorrhage, anemia, thrombocytopenia, elevation of serum transaminases, or hemorrhages at the sites of administration. Although rare cases of cutaneous adverse reactions (such as ecchymoses, plaques or erythematous nodules) have been documented, there is only one report of maculopapular eruption induced by LMWH in the literature. The suspected risk factors for the development of sensitization to LMWHs are female gender and obesity - which were present in this patient, as well as type 2 diabetes mellitus and prolonged intake of narcotic drugs. Thus, even though only 1% of the population suffers from cutaneous affections caused by drug iatrogeny, it is important to seriously consider the possible adverse effects of the above described LMWHs in a current context of polymedication.

Abadi, Noureddine: 244, 245, 739
Abadía Otero, Jesica: 373, 705
Abarca Casas, Laura: 48
Abarca, Laura Clara: 457
Abaz, Bibiana: 957
Abbes, Maissa: 833, 834
Abbey, Jessica: 13
Abdallah, Meya: 81, 163, 248, 607, 609, 854, 858, 886
Abdrakhmanov, Ayan: 54
Abdulganieva, Diana: 332, 919
Abecasis, Francisca: 204
Abelha Pereira, Filipa: 690
Abid, Rim: 470, 550
Abid, Rym: 547
Abrantes, Ana Rita: 480, 497
Abrantes, Catarina: 699
Abrantes, Tito: 809
Abrego Vaca, Luis Fernando: 544
Abreu Fernandes, José: 295, 546
Abreu, Ana: 523, 524, 529
Abreu, Diogo: 629, 680, 760
Abreu, Joana: 214
Abreu, João: 832
Abreu, João Pedro: 369, 516
Abreu, Luís: 173
Abreu, Nathalie: 553
Abreu, Susana: 905
Abreu, Tiago Tribolet: 184, 280, 904
Abril, Rita: 731
Acabado, Alba Janeiro: 878
Accordino, Silvia: 712
Achappa, Basavaprabhu: 219, 516, 670
Acharya, Mrinal: 735
Achega, Miguel: 517
Acosta, Caroliona: 65
Adaily, Najah: 384
Adaily, Najeh: 381, 955, 956
Adelantado Lacasa, Marta: 428, 429
Adragão, Francisco: 68, 124, 128
Adrião, Diana: 652, 806
Afonso, Ana Teresa: 340, 342
Afonso, Graça: 192
Afonso, Luis: 415
Afonso, Margarida: 540, 654
Afonso, Maria Carolina: 697
Agarwal, Mukesh Kumar: 398
Agarwal, Ritika: 398, 705
Aghemo, Alessio: 331, 335
Agonia, Isabel: 191
Aguado De La Fuente, Ana: 373
Águeda, Ana: 929, 933
Aguiar, Carolina: 196
Aguiar, João: 198, 249
Aguiar, José: 74, 97
Aguiar, Karolina: 470
Aguiar, Patrício: 321, 442, 608, 663
Aguiar, Renata: 929, 933
Aguiar, Sílvia: 87
Aguilera García, Selena Gala: 301
Aguinaga Perez, Aitziber: 428, 429
Aguirre, Diego José Gudiño: 416, 592
Agyei-Nkansah, Adwoa: 717
Ahabab, Süleyman: 952
Aibar, Jesus: 604
Ainabekova, Bayan: 64
Airaghi, Lorena: 357
Aires, Anabela: 764
Aires, Anabela Maria Paulo: 764
Aires, Elaine: 289
Ajili, Faida: 470, 550, 878, 887, 888, 921
Ajili, Fayda: 547
Ajili, Feida: 862
Akkan, Tolga: 235
Al Dhahir, Loay: 256
Al Mansoori, Mariam Ghareeb: 161, 872
Alaoui-Quesada, Aicha: 77, 685
Alaoui, Fatima Zahra: 829
Alarcón-Viejo, Carmen: 195
Alarcon, Nahir: 3
Alaya, Zayneb: 537
Alaya, Zeineb: 852, 852
Alba Fernandez, Jorge: 544
Albergo, Francesco: 377
Alberti Vich, Francesc: 759
Albuquerque, Alexandra: 15, 38, 145, 312
Albuquerque, Ana: 88, 174, 277
Albuquerque, Ana Figueiredo: 166, 270, 640
Albuquerque, Ana Luísa: 273, 589, 873
Albuquerque, Francisco: 124
Albuquerque, Inês: 201, 752, 960
Alçada, Filipa: 88, 273, 277, 607
Alçada, Martim Baltazar: 140, 310, 584
Alcalde Rumayor, Maria Consuelo: 456
Alcântara, Paula: 12, 401, 749, 828, 853
Aldama Martin, Arrate: 582
Aldámiz-Echevarría Lois, María Teresa: 433
Aldea, Anna: 584
Aldomiro, Fernando: 109, 164, 360, 517, 518, 523
Aldrete-Velasco, Jorge Antonio: 243
Aledón, Paula: 626
Alegria, Sofia: 95, 121
Aleixo, Rute: 750
Aleixo, Sara: 300, 529, 817
Alejandro De Oña, Álvaro: 270, 430
Alejandro, Álvaro: 602
Aleluia, Leonor: 388, 666
Alessi, Elena: 707
Alexandre, André Terras: 405

Alfaiate, Ana: 778, 789
Alfaiate, Joana Dias: 770
Ali, Chasan: 154, 157, 253, 254, 256, 451, 524, 860
Aliberti, Stefano: 86
Alimova, Dilorom: 535
Aliu, Filonid: 84
Alkhayyat, Nora: 397
Allaoui, Abire: 829
Allard, Sabine D.: 340
Almas, Aysha: 737
Almeida, Ana: 928
Almeida, André: 430, 522, 527, 871
Almeida, Ângela S.: 495, 650
Almeida, António Jorge: 363, 365
Almeida, Catarina: 343, 501, 793, 868
Almeida, Fábio: 889
Almeida, Hugo: 406, 815
Almeida, Isabel: 925
Almeida, Jorge: 80, 92, 145, 181, 182, 197, 201, 565, 590, 635, 674, 702, 747, 752, 840, 858, 866, 921
Almeida, Luis Reis De: 662
Almeida, Mariana Ferreira: 80
Almeida, Patrícia: 110
Almeida, Paulo: 133, 242, 272, 313, 721, 790, 801, 842, 894
Almeida, Penelope: 135
Almeida, Raquel: 458
Almeida, Sara Irina: 622, 811
Almendra, Luciano: 239
Almirall, Jordi: 455
Almuqbel, Daad: 397
Aloise, Monia: 331
Alomar, Mukhtar: 397
Alonso Beato, Rubén: 893
Alonso Muñoz, Jaime: 433, 491
Alonso Sardón, Montserrat: 406
Alonso-García, Gerardo: 420, 421
Alonso-Martínez, José Luis: 24, 24
Alonso, Blanca Rodríguez: 206
Alonso, Sara Muñoz: 43, 73, 102, 709, 848, 950
Alpagat, Gulistan: 231
Alpedrinha, Guilherme: 92, 275, 287, 915
Alpoim, Tiago: 92, 565
Alsuwayegh, Aseel: 397
Altay, Mustafa: 235
Alterini, Bruno: 44
Alvarado De La Hoz, Carlos Enrique: 618
Alvarez Pérez, Francisco José: 139
Alvarez, Rocío: 553
Alves Pereira, Sara: 929
Alves Santos, Filipa: 71
Alves Silva, Gonçalo: 543
Alves Silva, Pedro: 916
Alves Teixeira, João: 52, 611
Alves, Adelaide Pereira: 629, 630, 787
Alves, Adriana: 119, 162, 223, 676
Alves, Ana: 505
Alves, Ana Morais: 952
Alves, Ana Sofia: 440, 446
Alves, Eduarda: 637
Alves, Francisco Da Mata: 35, 35, 36
Alves, Glória: 167, 471, 850, 865, 866, 926, 931, 931
Alves, Joana: 515
Alves, José Delgado: 38, 305, 364, 414, 676, 717, 741, 839, 904
Alves, José Nuno: 159
Alves, Lucy: 297, 552, 622
Alves, Manuela: 574, 919
Alves, Maria: 121, 336, 684, 687, 945
Alves, Marina: 819
Alves, Miguel: 12, 14, 343, 585
Alves, Miguel Alexandre: 347, 372, 485, 641
Alves, Pedro: 192
Alves, Pedro Botelho: 600
Alves, Ricardo: 485
Alves, Rita: 387, 476, 552, 895
Alves, Rosa: 108, 522, 753, 867
Alves, Sandra: 126
Alves, Sandra Pinto: 582, 631
Alves, Sergio: 347, 372, 641
Alves, Telma: 353, 388, 846
Alvisa-Negrín, Julio: 107
Alwali, Yaser Hussein: 37
Amado, Carolina: 154, 472, 637, 910, 959
Amador, Ana Filipa: 674
Amal, Baya Chatti: 248
Amálio, Sofia: 449, 977
Amaral Mendes, Gonçalo Miguel: 136
Amaral Neves, Inês: 168
Amaral, Ana Beatriz: 303, 399, 578
Amaral, Andreia: 114, 210, 220, 476, 506, 525, 638, 658, 892
Amaral, Leonor Pereira: 255
Amaral, Maria: 367, 502
Amaral, Maria João: 272
Amaral, Marta C.: 717, 904
Amaral, Ricardo: 197, 225
Amaral, Sara: 795
Amaral, Teresa: 571
Amaro, Franco Gustavo: 937
Amaro, Mário: 132
Amaro, Mário Carlos: 510
Amato, Ripalta: 771
Amaya Marshall, Andrés Julián: 618
Ambrósio Rodrigues, Ricardo: 666, 808, 916
Ambrosio Rodrigues, Ricardo Ambrosio: 353
Ambrósio, Catarina: 913, 929, 933
Ambrósio, Isabel: 153
Amel, Rezgui: 384
Amin, Iqra: 737
Amodeo Oblitas, Christian Mario: 48

Amorim, Diana: 797
Amorim, Edgar: 788, 966, 972
Amorim, Filipa: 856
Amorim, Helena: 690
Amorim, Joana: 972
Amorim, Mário Jorge: 200
Amorim, Rosa: 220, 366, 498, 519, 521, 542, 608, 779, 816, 856, 920, 982
Amri, Raja: 537, 852, 852
Ananias Gonçalves, João: 573, 573
Anastasopoulou, Amália: 659
Anaut, Pilar: 856
Anaya, Fernando: 793
Ancusa, Oana Elena: 313
Andía, Ander: 856
Andrade Oliveira, Ana Isabel: 93, 191, 348, 893, 964
Andrade Piña, Ariadna Helena: 345, 479, 963
Andrade, Aurora: 60, 200
Andrade, Carina: 700, 925
Andrade, Carla: 181
Andrade, Cristina: 280, 281, 283
Andrade, Filipe: 328, 929
Andrade, Filipe Teixeira: 289
Andrade, Hugo Boechat: 504
Andrade, Joana: 773, 932, 935
Andrade, João: 350, 351
Andrade, José Luís: 525
Andrade, José Pedro: 217, 765
Andrade, Lília: 780, 781
Andrade, Luís: 343, 455
Andrade, Luís Silva: 67
Andrade, Margarida: 680, 683, 685, 696
Andrade, Maria Margarida: 369, 924
Andrade, Marta: 755
Andrade, Naima: 229
Andrade, Raul J.: 325
Andrade, Rodrigo Pereira: 155, 258, 462
Andrade, Rosana: 376
André, Diogo: 525, 662, 663
André, Maria Eugénia: 10, 11, 537, 594, 671, 772
André, Rui: 174
André, Teresa Raposo: 50, 104
Andresa, Ana: 619
Andrianesis, Vasileios: 411, 412, 781, 838
Andronic Andronic, Igor: 475
Andronic, Igor: 422, 718, 958
Androulakis, Nikolaos: 612
Ângela, Cristina: 28, 614
Angeletti, Alessia: 830, 830
Anjos, Diana Pereira: 896
Annicchérico-Sanchez, Francisco Javier: 24, 24
Anniccherico, Francisco Javier: 848
Anoun, Jihed: 276, 284, 378, 381, 384, 745, 761, 861, 909, 954, 955, 956
Anselmo, Mónica Palma: 569
Antão, Diogo: 430, 522, 526, 527, 821, 871
Antolí Royo, Ana Cristina: 85, 91
Antonakis, Andreas: 420, 612
António, Carla: 820, 820, 822, 823, 926
António, Manuel: 927
António, Manuel Silvério: 369, 683, 685, 696, 924
António, Sandra: 105, 337, 338, 623
Antunes Da Silva, Sérgio: 300, 392, 529, 817, 870
Antunes De Sá, Tiago Jorge: 139
Antunes Silva, Sérgio: 342, 475, 686
Antunes, Ana Cláudia: 354
Antunes, Ana Margarida: 374, 374, 487
Antunes, Ana Paula: 179, 282, 412, 413, 413, 460, 540, 572, 667, 763, 798, 934
Antunes, Daniela: 617, 618, 864
Antunes, Inês: 366, 442, 608, 856
Antunes, Joana: 290, 677, 680, 760
Antunes, Liliana: 146, 948
Antunes, Margarida: 532, 552, 764, 890, 891, 895, 920
Antunes, Nuno: 30, 447
Antunes, Rui: 510
Aoun, Antoine: 583
Aoun, Bernard: 373
Aounallah, Amina: 761, 765, 769
Aparício Martins, André: 507
Apaydın, Suheyla: 741
Apolinário, Isabel: 497, 652, 698
Aquino, Carlos Raúl: 701
Aragão, Irene: 223
Aranega Gonzalez, Raquel: 149, 441
Aranega, Raquel: 435, 439, 604
Aranha, Rita: 310, 584
Arapiles Muñoz, Adrian: 791
Araújo, Ana: 133, 480, 497, 721, 790, 801, 842
Araújo, Ana Rafaela: 129, 272, 298, 405, 661, 779
Araújo, Bárbara: 507
Araújo, Catarina: 647
Araújo, Cátia: 760
Araújo, Eliana: 133, 790
Araújo, Elsa: 68, 156, 174, 237, 754, 871
Araújo, Emanuel: 615
Araújo, Francisco: 106
Araújo, Francisco Pestana: 847
Araújo, Inês: 68, 124, 128, 128, 130
Araújo, Isabel Montenegro: 91, 93, 105, 167, 183, 224, 564
Araújo, João: 112, 920
Araújo, José: 432
Araújo, José Lomelino: 91, 93, 106, 160, 167, 224, 266, 272, 386, 643, 653, 847, 863
Araújo, Leuta: 362
Araújo, Manuel: 448, 763
Araújo, Miriam: 732
Araújo, Rosário: 112, 461

Araújo, Rui: 213, 227, 869
Aravantinou Fatorou, Aikaterini: 659
Ardérius, Miguel: 767
Arefiev, Mikhail N.: 194
Arenga, Marta: 173
Arévalo López, Ariadna: 499
Arez, Luísa: 71, 100, 118, 155, 160, 171, 258, 261, 262, 264, 385, 407, 462, 463, 468, 478, 632, 969
Arghir, Ioan Anton: 780
Arghir, Oana Cristina: 780
Argüello, Carlota: 746, 962
Argyropoulou, Despina: 654
Arias, Ana María Ruiz: 246
Arias, Ana Ruiz: 246
Arjona, Josefa Jiménez: 595
Arkesteijn, Astrid Joanne Vera: 439
Arkuch-Saade, María Eugenia: 77
Armas-González, José Fernando: 944
Arnáiz García, Ana María: 447, 450, 453
Arnold, Simone: 435
Aroca Ruiz, Maria: 903
Aronova, Eugenia: 831, 831, 831
Arrabal Díaz, Jose Manuel: 757
Arroyo Álvarez, Cristina: 975, 978
Arroyo, Cristina: 415
Arsenovic, Aleksandra: 556
Arumugam, Josephine: 724
Arva, Vígor: 26
Arvaniti, Pinelopi: 307, 316
Ascensão Margarida: 211, 641
Aslanoglu, Nuri: 15
Asma, Kefi: 901
Assia, Boulfkhad: 159
Assidi, Béchir: 967
Assis, Guilherme: 92, 131, 297, 349, 548, 565, 750
Assunção, António: 775
Assunção, António José Santos: 260
Asturias Saiz, Amelia: 582
Atanásio, Gabriel: 60, 812
Ataoglu, Esra: 952
Athayde, Carlos: 543, 719
Athimni, Salma: 884, 885
Augusto, Jean-François: 739
Aujla, Ravinder Singh: 398, 705
Aurélio, João: 407
Ausín García, Cristina: 270, 430, 759
Ausín, Cristina: 602, 835, 870
Aveiro, Fernando: 667
Aveiro, Mafalda: 251, 441, 563
Aveiro, Marcelo: 154, 472, 595, 637, 648, 959
Avgeri, Sofia: 138, 201, 520
Ávila Lara, Anabel: 836
Ávila, Alexandra: 100, 171, 261, 262, 385, 463, 463, 969
Avila, Gerson Emir: 338
Avila, Marcela: 953
Ávila, Paulo: 146, 459, 481, 520, 611, 859
Avilés Inglés, María Jesús: 486
Avilés Méndez, Nuria: 895
Avitabile, Emma: 50
Avó-Baião, Rita: 942
Aw, Clarissa Hui Wen: 266, 706, 708
Awesat, Jenan: 1, 560, 829, 847
Azariadis, Kalliopi: 307, 325
Azevedo, Ana Luísa: 788
Azevedo, Francisco: 232
Azevedo, Luísa: 691
Azevedo, Pedro: 708, 709
Azevedo, Pilar: 423
Azevedo, Teresa: 233
Azzabi, Samira: 120, 127
Azzam, Zaher: 22
Babbino, Virginia: 957
Bacete Cebrián, Marta: 426, 457, 605, 766, 790, 879
Bächli, Ciril: 231
Bachlitzanaki, Maria: 612
Bachrouch, Sabrina: 537
Badalamenti, Salvatore: 331
Badescu, Codruta: 69
Badescu, Codruta Minerva: 205
Badot, Valerie: 908
Baer, Dave: 1
Baez, Lorena: 937
Báguena Pérez-Crespo, Carlos: 271, 286, 410, 417, 456, 624, 762, 838, 841, 855, 960
Bahouth, Fadel: 22
Baikulova, Madina Khasanovna: 80
Bal, Andriy: 214
Balaceanu, Alice: 116
Balakrishnan, Tharmmambal: 246, 714
Balboa Barreiro, Vanesa: 499
Baldassarre, Maurizio: 320
Balde, Samba: 479
Baldeón Conde, Cristina: 447
Baldo, Maria João: 117
Baldo, Maria João Morgado Nabais: 106
Baleiras, Mafalda Miranda: 354, 390, 391
Balevski, Igor: 26
Balhana, Sílvia Santos: 847, 863
Balko, Aleksandr: 196
Ballesteros-Chaves, Isabel: 579, 580
Ballesteros, Rosa: 665
Ballmer, Peter: 148, 434
Balsano, Clara: 198, 712
Baltasar Corral, Jesús: 879
Baltazar, Ana Maria: 471
Balza, Pedro: 177, 178, 179
Bandeira, Adriana: 140, 189, 234, 250, 440, 507, 562, 569, 635, 776

Bandini, Giulia: 56, 843
Banerjee, Abhirup: 735
Bansal, P K.: 304
Baptista, Ana: 90, 678
Baptista, António Martins: 91, 93, 167, 224, 971
Baptista, Isabel: 146, 521, 535, 665, 948
Baptista, Lurdes: 544
Baptista, Mafalda: 776, 777, 796
Baptista, Maria João: 106
Baptista, Mário: 497
Baptista, Rui: 94
Baraças, Catarina Ala: 643, 681
Barata Moura, Rita: 522, 527, 871
Barata, Conceição: 142, 169, 170, 364, 405, 514, 523, 587
Barata, Érica: 229
Barata, José: 176, 294, 348, 362, 454, 541, 594, 676, 692, 910, 914
Barata, José Augusto: 538
Barata, Juliana Sofia De Jesus: 776, 777
Barata, Juliana Sofia Jesus: 796
Barata, Maria Conceição: 598
Barata, Melanie: 617
Barbaglia, Matteo Nazzareno: 311, 336
Barbarisi, Giorgia: 843
Barbedo, Marta: 455, 806
Barbieri Merlo, Diego: 793
Barbosa Martins, João: 51
Barbosa Prieto, Vanessa: 396
Barbosa, Ana: 59
Barbosa, Ana Castro: 357
Barbosa, Ana Luísa: 688
Barbosa, Ana Paula: 288
Barbosa, Ana Rita: 806
Barbosa, António: 117
Barbosa, Benilde T.: 540
Barbosa, Bruno: 174, 506
Barbosa, Joana: 884
Barbosa, Manuel: 68, 156, 174, 237, 754, 871
Barbosa, Manuel Martins: 812
Barbosa, Mário: 20, 31, 32, 35, 96
Barbosa, Mário Teixeira: 40, 56
Barbosa, Miguel: 271, 660
Barbosa, Miguel Trigueiro Rocha: 575
Barbosa, Sandra: 51, 294, 431
Barcelos, Anabela: 913, 929, 933
Barcelos, Vanessa: 978
Barchel, Dana: 31
Bargiela, Inês: 126, 401, 609, 959
Bargiela, Inês Soler: 310, 582, 631
Barmo, Serge: 943
Barraca, Daniel: 793
Barracha, Ivone: 366, 442, 519, 608, 779, 816, 856, 920, 982
Barradas, Ana Rita: 530
Barreira, Ana Isabel: 560, 980
Barreira, João: 541
Barreira, João Seabra: 176
Barreiro, Ana: 329
Barreiro, Ivo: 110, 511, 677
Barrera López, Lucía: 151, 345, 479, 963
Barreto, Paulo: 210, 220, 668
Barreto, Vasco: 650
Barreto, Vasco J.: 643, 681
Barrigoto, Cleide: 690
Barrios, Juan Francisco: 110, 323, 437, 701
Barrocas, Leila: 142, 364, 514
Barros, Andressa Braga: 229
Barros, Anilda: 99, 367, 575, 647, 675
Barros, Augusto: 240
Barros, Carolina: 464, 836, 874, 958
Barros, Carolina Vasconcelos: 425, 597, 774
Barros, Inês: 174
Barros, João Rodrigues: 6
Barros, Mary: 740
Barros, Nelson: 225
Barros, Rui: 573, 573, 597
Barros, Suzete: 863
Barroso, Ana: 629, 630
Barroso, Daniela: 690
Barroso, Maria Yolanda Torres: 592
Barroso, Sofia: 832
Barroso, Tiago: 38, 676
Barski, Leonid: 1, 557, 560, 829, 847
Bartalesi, Filippo: 44
Basa, Norina: 313
Basak, Prasanta: 943
Basaranoglu, Gokcen: 330
Basaranoglu, Metin: 329, 330
Basílio, Carla: 203
Bassetti, Stefano: 509
Bastardot, François: 712, 712
Basto, Marta: 652
Basto, Raquel: 898
Bastos Heitor, Susana: 180, 276
Bastos, Catarina: 128, 130, 879
Bastos, José Mário: 67, 455
Bastos, Juliana: 590
Batista, Ana Filipa: 290, 680, 760
Batista, Filipa: 629
Battikh, Riadh: 470, 547, 550
Bay, Marylène: 69
Baya Chatti, Amal: 607, 609, 854, 858
Baya, Wafa: 276, 284, 761, 765, 769, 909
Beauvillain, Céline: 739
Beça, Sara: 153
Beckedorff, Otto Albuquerque: 968
Beggiato, Eloise: 593
Beirão, Pedro: 709, 713
Beires, Francisca: 645, 650, 898

Beja, Mariana: 800
Beja, Marta: 681
Béjar-Valera, Javier: 420, 421
Belajouza, Colandine: 761, 765, 769
Belasova, Ligita: 178
Belém, Francisco Chambel: 211, 641
Belfiore, Anna: 45, 377, 749
Belhassen García, Moncef: 406
Belhassen, Moncef: 434
Belkacem, Raoua: 378
Bellan, Mattia: 50, 317, 336, 361, 448, 839, 869
Belmar Vega, Lara: 556
Belo, Adelaide: 379, 710
Belousova, Elena: 919
Belu, Anca: 324, 786
Belu, Daniela: 324, 786
Bemfica, Victor: 453, 504, 753, 863, 900
Ben Abdallah, Taieb: 901
Ben Abdelghani, Kaouther: 885
Ben Abdelghani, Khaoula: 901, 969
Ben Achour, Tayssir: 854, 886
Ben Ariba, Yousra: 888
Ben Dahmen, Fatma: 81, 163, 248, 607, 609, 854, 858, 886
Ben Fredj Ismail, Fatma: 276, 284, 761, 765, 769, 769, 909, 956
Ben Fredj, Fatma: 378, 381, 384, 745, 761, 861, 954, 955
Ben Hamida, Fathi: 979
Ben Hammouda, Rabai: 537
Ben Hassine, Imen: 276, 284, 745, 761, 765, 769, 909
Ben Hassine, Lamia: 120, 127
Benavente Fernández, Alberto: 720
Bendala Estrada, Alejandro: 466
Bendala Estrada, Alejandro David: 790
Benembarek, Karima: 244, 245
Benhamou, Ygal: 913
Benites, Maria: 859
Benites, Maria Guadalupe: 145, 419, 787, 788
Benmebarek, Karima: 159, 739
Bennetts, Joanne: 724
Benopoulou, Olga: 659
Berardi, Sonia: 320
Berbel, David: 649
Berenice Cedeño De Jesús, Sindy: 777
Berg, Karolin: 148
Bergas-Farrés, Alba: 610
Bergas, Alba: 649
Bernal Morell, Enrique: 410, 417
Bernardi, Paolo: 843
Bernardino, Andreia: 232
Bernardo, Ana: 97, 169, 170, 598
Bernardo, Teresa: 503, 710, 813
Berraondo, Pedro: 751
Berriel Martín, Ruben: 422, 475
Berriel, Rubén: 958
Bersenev, Evgeny Yu.: 101
Bertão, Manuela: 690
Bertelli, Cristina: 357
Bertoletti, Iacopo: 843
Bertrand, Jérôme: 188
Bessa, Filipe: 165, 936, 976, 978
Bessa, Isabel: 172, 511, 677
Bésteiro, Bruno: 80, 921
Bettencourt, Mónica: 179
Bettencourt, Paulo: 615
Bevc, Sebastjan: 2, 26
Beya Chatti, Amal: 163
Bezerin, Alexander: 800
Bhaskaran, Unnikrishnan: 670
Bianchi, Gino: 712
Bianchi-Llave, Jose Luis: 450, 451, 909, 910, 911
Bibi, Mário: 74, 76, 76, 88, 117, 166, 491
Bicho, Manuel: 20, 31, 32, 35, 40, 56, 288, 814, 936
Bilal, Bilal: 157, 254, 257, 445, 451, 524, 860
Bilreiro, Mariana: 597, 836
Biskup, Ewelina: 970
Bizarro, Rita: 177, 530, 574, 633, 634, 804, 818
Blanca, Deborah: 84
Blanco Portillo, Antonio: 716
Blanco Torres, Celestina: 319, 359, 527, 905, 908
Blanco, Ana: 329
Blanco, Juan Manuel: 356, 356
Blanco, Manuel Cayón: 246
Blanco, Rosário: 131, 531, 678, 679
Blasi, Francesco: 86
Blazquez-Saldana, Jaime: 2
Bleda, Enrique Mira: 563, 806
Blum, Claudine: 231
Boavida, Leonor: 290, 305, 452, 825
Bobbio, Flavio: 50
Boccatonda, Andrea: 53
Bocchi, Federica: 69
Boeva, Olga Igorevna: 80
Boffelli, Silvia: 320
Boin, Elena: 50
Boix, Vicente: 460
Boixeda, Ramon: 435, 439, 604
Bojinca, Mihai: 743
Bolado, Marta Esles: 360
Bölek, Hatice: 396, 483
Bollati, Valentina: 86
Bologna, Carolina: 143, 391, 534
Bolondi, Ilaria: 320
Bomers, Marije: 466
Boncoraglio, Maria Teresa: 676, 693
Bonfrate, Leonilde: 326, 749
Bonometti, Ramona: 839, 869
Bonora, Rodolfo: 86
Bonzini, Matteo: 86
Boquinhos, Ana: 540, 572

Boquinhas, Ana Teresa: 12, 585
Borges Da Silva, Miguel: 175, 361, 972
Borges Martins, José: 285
Borges, Alexys Reis: 443
Borges, Ana: 880
Borges, Diogo: 552
Borges, Diogo Drummond: 275, 374, 387, 532, 890, 891, 895, 920
Borges, Diogo Drummond: 729, 730
Borges, Filipa: 153
Borges, Isabel: 293, 296, 551, 694, 755
Borges, Joana: 368
Borges, João: 510
Borges, Maria Augusta: 923
Borges, Sara: 49
Borgognoni, Francesco: 64
Bornia, Jonatan: 205
Borque Sanz, Pablo: 544
Borro, Matteo: 890
Bosch Rovira, Maria Teresa: 759
Botelho, Carlota: 514
Boticário, Marina: 140, 310, 584
Boto, Paulo: 386
Bou, Ramon Nogué: 490
Boudaoud, Khalida: 244, 245, 739
Bouillon, Pierrette: 193
Boujon, Valerie: 193
Boukhris, Imen: 120, 127
Bouros, Spyridon: 659
Bousofara, Lobna: 761, 765, 769
Boussetta, Najah: 882, 883, 887, 888, 921
Bousstta, Najeh: 470, 547, 550, 861, 862, 878, 882
Boutali, Argyro: 157
Bouzaidi, Khaled: 537
Bova, Aleksandr: 100
Bracco, Christian: 792
Braço Forte, Cristina: 778, 789
Braga Mamfrim, Rafaela: 747
Braga, Carlos Galvão: 447, 614
Braga, Fátima: 643, 681
Braga, Joana: 182
Braga, Marta: 346, 638
Braga, Sara: 75, 801, 815
Bragança, Aurora: 112
Braghetto, Isabella Carinhani: 968
Brakemeier, Susanne: 22
Brambilla, Annamaria: 86
Branco, Ana: 103, 245
Branco, Catarina Castelo: 122, 822
Branco, Joana Afonso: 423
Branco, Tiago: 449, 678
Branco, Tiago J. F.: 471
Brandão, Ilídio: 497, 652, 698
Brandão, Mariana: 121, 336, 684, 687, 783, 945
Brandão, Paula: 174
Brandão, Sara: 547
Brandão, Teresa: 290
Brás Alves, Telma: 666
Brás, Ana Catarina: 241
Brás, Diogo: 97
Brás, Pedro: 87
Brás, Raquel Lopes: 359
Braz, Sandra: 369, 680, 683, 685, 696, 927
Brazão, Luz: 104, 178, 359, 597, 662, 663, 774
Brazão, Maria Da Luz: 240, 309, 504, 655, 736, 798, 836, 928
Brazão, Maria Da Luz Reis: 195, 243, 846
Brazão, Maria Luz: 50, 66, 177, 464, 525, 585, 667, 744, 787, 797, 874, 958
Brazão, Sofia: 592
Brazão, Sofia Gomes: 104, 293, 600
Brázio, Ana: 359
Breda, Filipe: 962, 963
Briega, Marta: 389
Brigas, Daniela: 136, 228, 677
Brigas, Daniela Félix: 132, 369, 393, 699, 983
Brignone, Chiara: 792
Brilland, Benoit: 739
Briongos Figuero, Laisa Socorro: 373, 705
Briosa, Alexandra: 64, 65, 95, 121, 654, 818
Brito-Avô, Luis: 916
Brito-Da-Silva, José: 96, 653
Brito-Silva, José: 603
Brito, Ana: 114, 210, 220, 476, 506, 525, 638, 658, 892
Brito, Daniela: 144, 479, 480, 497, 860, 946
Brito, Maria Teresa: 80, 674
Brito, Rebeca: 588
Brito, Sérgio: 721
Broa, Ana: 95, 654
Broa, Ana Luisa: 818
Brochado, Ana: 93
Brochado, Ana Isabel: 91, 167, 224
Brochado, Filipa: 688
Brochado, Marisa: 286, 345, 570, 644
Brockhattingen, Kristoffer K.: 212
Brogueira, Pedro: 632
Brotas, Vitor: 165, 858
Brovkina, Snezhana: 263
Brown, Jonathan: 731
Brox Torrecilla, Noemí: 270
Brucato, Antonio Luca: 378
Brum, Sandra: 278
Bruno, Gustavo: 97
Bruno, María Del Rosario: 205, 716
Buccella, Daniela: 712
Bucuras, Petru: 49, 71
Budde, Klemens: 22
Budiño Sánchez, Marco Antonio: 975, 978
Budiño, Marco Antonio: 415
Bueno Álvarez, Aurelio Juan: 450, 453

Bulacia, Adriana: 4
Buleu, Florina: 49, 71
Buonamico, Paolo: 377, 749
Burja, Sandra: 26
Burlone, Michela Emma: 311
Burmester, Inês: 93, 191, 315, 348, 407, 418, 893, 964
Buskila, Dan: 847
Bussi, Anna Rosa: 707
Bustamante Odriozola, Javier: 453
Buzzo, Marta: 216
Bystrianska, Natália: 304
Caballero Avendaño, Francisco Alejandro: 447, 450, 453
Caballero, Isabel De La Cal: 170, 173, 214, 659, 900
Cabral Ribeiro, Jorge: 700
Cabral, António: 44, 137, 147, 166, 247, 488, 600, 601, 748, 769, 850, 851, 891, 949, 950, 966
Cabral, Catarina: 418, 444, 581, 946
Cabral, Margarida: 811
Cabral, Mariana: 336, 795, 814
Cabral, Susana Lemos: 515
Cabreiro, Bruno: 57, 152, 616
Cabrera, Joana Aguiéiras: 192
Cabrera, Joana Andreia: 66
Cabrita, Carlos: 501, 651
Cabrita, Joana: 970
Cachado, Patrícia: 522, 527
Cadavez, Emanuel: 483, 660
Cadena, Ivan: 136, 186
Cadório, Carolina: 541
Caeiro, Alexandra: 438
Caetano, Joana: 38, 676
Caetano, Olinda: 788
Çagir, Büsra Betül: 235
Çagir, Yavuz: 235
Cai, Fengfeng: 970
Cai, Lu: 970
Caires, Joana: 117
Caixas Lima, Maria: 981
Caixas, Umbelina: 690
Caixeiro, Micaela: 290, 452
Çakal, Erman: 235
Calabuig Muñoz, Eva: 467, 467
Calaça, Sofia: 232, 291, 558
Calado, Rebeca: 697
Caldas, João Paulo: 590
Caldeira, Mónica: 585, 667, 744
Caldeiro, José: 214
Calderon, Hugo: 181, 274, 449
Calé, Amanda Saavedra: 898
Calé, Rita: 121
Caley, Lúdia: 288, 860
Calhau, João: 648
Calheiros Cruz, Gonçalo: 562
Calheiros, José: 869
Çaliskan Güzelce, Ezgi: 396
Çaliskan, Zafer: 483
Calisto, Raquel: 676
Calixto, Rita: 198, 249, 249, 875
Callejo Hurtado, Victoria: 456, 486
Caloska Ivanova, Viktorija: 84
Calugareanu, Stela: 337, 338, 623
Calvão, João: 182
Calvo, Maria Mercedes: 6
Calvo, Martina: 261
Calvo, Victoria Palomar: 43, 73, 102, 709, 848, 950
Camacho, Elvira: 494
Camacho, Óscar: 173
Câmara, Beatriz Brazão: 811
Câmara, Lara: 165, 565, 633, 858, 884
Cambelela, Nahete: 452
Camelo, Rita: 530, 538
Cámara, Luis Alberto: 261, 716
Camila Dias, Claudia: 371
Caminal, Luis: 746
Cammack, Ivor: 199, 462, 485, 940
Camo, Nanci: 716
Camões, Isabel: 921
Campinha, Sérgio: 630
Campanini, Mauro: 50
Campante, Fátima: 15, 37, 38, 82, 113, 134, 145, 162, 271, 312, 316, 317, 326, 434, 494, 502, 575, 603, 631, 636, 646, 843, 881, 944
Campelo, Pedro: 371, 501, 651
Campelos, Ana: 170
Campo Ruiz, Ana: 404, 942, 961
Campo, Cristina: 73, 322
Campos, Ana: 731, 810, 822
Campos, Ana Carmo: 135
Campos, Ana Luísa: 403, 464, 777
Campos, Andreia: 573
Campos, Isabel: 30
Campos, Isabel Durães: 55, 447, 614
Campos, Juliana: 128, 130
Campos, Luís: 32, 68, 124, 171, 240, 319, 354, 376, 390, 391, 448, 721, 763, 934
Campos, Sérgio: 542
Canadas, Joana: 136, 186
Canadas, Sónia: 124, 225, 687
Canário, Dolores: 639
Cancela, Joana: 426, 646, 976
Candeias, Carlos: 90, 171, 501, 651, 689
Canelas, Ana: 226
Canelas, Maria Ana: 496, 742
Canetta, Ciro: 712
Canha, Catarina: 351
Canha, Inês: 633
Canhoto, Diogo: 786
Cano Ballesteros, Juan Carlos: 259, 457

Canoso, Ana: 521, 531, 701
Cantante, Helena: 96
Cantillo, Ana: 261
Canziani, Lorenzo Maria: 398, 400, 436
Capdevila Morell, Josep Anton: 441
Capdevila-Pons, Olga: 610
Capdevila, Aina: 584
Capdevila, Josep Antoni: 439, 604
Capela, Carlos: 28, 72, 423, 461, 498
Capodaglio, Giulia: 9
Capón Sáez, Amaya: 724, 725
Cappadona, Rosaria: 9, 10
Cappugi, Chiara: 512
Capucho Pereira, Carolina: 448
Capurso, Michela: 377
Caraballo, Aurelia Elena Fuentes: 35, 35, 36
Caraceni, Paolo: 320
Caravelo, Oscar: 261
Cardim, Nuno: 19, 81
Cardoso Fernandes, Sara: 568
Cardoso, Adriano: 358, 480
Cardoso, Ana: 487, 490, 640, 894, 897, 903, 965
Cardoso, António: 162, 316, 317, 631, 843, 881
Cardoso, Filipa: 122, 186, 367, 668
Cardoso, Filipa Botelho De Viveiros: 115, 732
Cardoso, Francisca: 70, 755, 873, 874
Cardoso, Francisca Silva: 346, 350, 351, 696
Cardoso, Guilherme: 127
Cardoso, João: 336, 526, 617, 692, 795, 814, 823
Cardoso, João Cruz: 974, 975
Cardoso, Leila: 388
Cardoso, Maria Teresa: 182
Cardoso, Orlando: 796
Cardoso, Rosa: 512, 672
Cardoso, Rosa Margarida: 497, 539, 683, 960
Cardoso, Teresa: 440
Cardozo, Erick: 815
Carenzo, Luca: 400
Carias, Eduarda: 292, 563
Caridade, Sofia: 92, 275, 287, 915
Carlevaro, Lia: 65
Carlos, José: 916
Carlos, Pedro: 242, 335, 782, 794, 920
Carmen, Palomar- Muñoz: 451, 910, 911
Carmen, Palomar-Muñoz: 450, 909
Carmo, Célia: 21, 37, 944
Carmo, Eduarda: 228
Carmona García, Juan: 422, 475
Carmona, Cátia: 492
Carmona, Federico: 738
Carmona, Juan: 958
Carneiro, António: 540, 572, 573, 597, 727
Carneiro, Daniela: 476
Carneiro, Diogo: 161
Carneiro, Filomena: 82, 113, 134, 271, 636, 646
Carneiro, Ismael: 896
Carneiro, Joana: 388, 628, 809, 810
Carneiro, Liliana: 55, 116, 173, 180, 541
Carneiro, Patrícia: 219
Carneiro, Rui: 727
Carneiro, Rui Pimenta: 727
Carolina, Teresa: 179
Carragoso, Adelino: 280, 281, 283, 949
Carrascal, Andrés: 119, 227
Carrasco, Laura Rueda: 35, 35, 36
Carrascosa Porras, Miguel: 404
Carreira Da Costa, Catarina: 161
Carreira, Joana: 213, 274, 473
Carreira, Marta Soares: 145, 265, 960
Carreira, Nuno Reis: 164, 961
Carreira, Patricia: 474
Carreira, Pedro: 431, 599, 785
Carreira, Susana: 778
Carreiro, Carolina Teves: 148
Carreiro, Joana: 145, 146, 419, 459, 520, 787, 788
Carrington, Mafalda: 74, 97
Carrizo, Emilce: 716
Carro González, Andrea: 798
Carrola, Paulo: 363
Carrondo, Helena: 166, 270, 640, 873
Cartas-Verdugo, Marina: 194
Carvalhana, Sofia: 365
Carvalheiro, Mafalda: 755
Carvalhinha, Carolina Gonçalves: 981
Carvalho De Oliveira, Camila: 700
Carvalho E Marques, Pedro: 279
Carvalho, Ana Catarina: 823
Carvalho, Ana João: 354
Carvalho, Anabela: 650
Carvalho, Armando: 18, 95, 104, 120, 188, 278, 292, 293, 295, 308, 319, 351, 353, 368, 417, 484, 493, 507, 513, 540, 543, 546, 592, 600, 631, 666, 688, 719, 804, 846, 886, 907, 916, 953, 968
Carvalho, Carla: 814
Carvalho, Catarina: 15, 38, 145, 162, 312, 560
Carvalho, Cátia: 134, 177, 530, 538, 574, 633, 634, 768, 804, 818, 821
Carvalho, Cristina: 390
Carvalho, Daniela: 667
Carvalho, Diana: 133, 272, 298, 657
Carvalho, Diana Vale: 129
Carvalho, Eduardo: 211, 641
Carvalho, Inês: 142, 159
Carvalho, Inês Branco: 91, 93, 167, 224
Carvalho, Isabel Cruz: 135, 767, 974
Carvalho, Joana: 290, 305, 537, 620, 671, 772
Carvalho, Joana Azevedo: 414, 452, 839
Carvalho, João: 219
Carvalho, José Costa: 689

Carvalho, Maria Leonor Araújo: 658
Carvalho, Patrícia: 513
Carvalho, Pedro: 49, 129
Carvalho, Renata: 28
Carvalho, Rita: 88
Carvalho, Rita Ribeiro: 19
Carvalho, Rosa: 346
Carvalho, Rosa Macedo: 493
Carvalho, Rui: 481
Carvalho, Sofia: 49
Carvalho, Teresa: 721
Carvoeiro, Ana: 689
Carvoeiro, Ana Catarina: 625
Casado-Delgado, Cristina: 194
Casal, Mariela: 815
Casana, Maddalena: 398
Casano, Nicolò: 198, 712
Casanova, Daniela: 403, 464, 777
Casanueva Soler, Ofelia: 87
Casar Cocheteux, Clara: 479
Cascais Costa, Catarina: 239, 780, 781, 959
Casella, Antonio: 593
Casella, Francesco: 211
Casella, Maria Isabel: 632
Casimiro, Hugo: 213, 274, 473, 682
Casinos Isart, Gabriela: 149, 441
Casinos Isart, Gabriela Alexandra: 435
Casinos, Gabriela: 439
Casinos, Gabriela Alexandra: 604
Castagna, Rosa: 716
Castañeda Pérez, Sabela: 845
Castelbon, Francisco Javier: 751
Castellano-Nogales, Yolanda Raquel: 685
Castelluccio, Cecilia: 4
Castelo Branco, Gonçalo: 471, 849
Castelo Branco, Lília: 330, 414, 588, 782
Castelo Corral, Laura María: 499
Castelões, Paula: 652
Castilla Guerra, Luis: 141
Castillo, María Luisa Calvo: 723
Castioni, Julien: 712, 712
Castro Hernández, Iván: 467
Castro, Adriana: 898
Castro, Alexandra: 593, 841
Castro, Diana: 234, 440, 562
Castro, Diana Vieira: 569
Castro, Heloisa: 218
Castro, Hugo Raúl: 701
Castro, Ivo: 176, 285, 361
Castro, Jorge: 492, 546
Castro, Laura: 167, 299
Castro, Maria: 323
Castro, Maria João: 49, 197
Castro, Paula: 261
Castro, Raquel: 976, 978
Castro, Sara: 552, 890, 891, 895
Castro, Silvia: 115
Casuso Saénz María Elena: 404, 564, 943, 961
Cataldi Amatriain, Roberto Miguel: 553, 937
Catarino, Cristina: 894
Catorze, Nuno: 480, 497
Cavadas, Susana: 242, 313, 375, 779
Cavaleiro, Pedro: 811
Çavusoglu, Betül Türker: 952
Cebolais, Rita: 538, 821
Cecconi, Maurizio: 400
Cen, Chunmei: 970
Cenedesi Junior, Mario Angelo: 206, 295, 957
Centeno, Pablo: 716
Cepeda, MARIA: 707
Cerdeña, Pedro Laynez: 592
Cerezo, Ana Fernández-Rufete: 563, 806
Ceriani, Elisa: 79
Ceriani, Roberto: 331
Ceriz, Tiago: 641
Cernadas, Eduardo: 103, 223, 844
Cerol, Marta: 79, 215, 217, 681, 765, 819, 917
Cerqueira, Ana: 238
Cortal, Mariana: 254, 446, 446, 508, 614
Cervilla Muñoz, Eva: 54, 784, 803
Cesar, Rui: 296
Cesário, Vera: 198, 249, 249, 805
Ceschia, Nicole: 44
Cespiati, Annalisa: 357
Cetin, Cigdem: 758
Chaabane, Abir: 537
Chaabane, Imen: 537
Chaabane, Imene: 852
Chakraborty, Ananda Mohan: 236
Chalbi, Emna: 537
Chambino, Beatriz: 448, 763
Chan, Sónia: 625
Chatzigeorgiou, Armonia: 286
Chatzikonstantinou, Thomas: 892
Chatzopoulos, Georgios: 158
Chaves, António José: 50, 585, 744
Chaves, Catarina: 242, 335, 794
Chaves, Jéssica: 195, 240, 464, 744, 846, 874, 958
Chaves, Paulo Castro: 145
Chaves, Vanessa: 953
Chen Xu, Juliana: 101, 263, 279, 660, 713, 805, 865
Cheong, Nicholas: 266
Cheong, Nicholas Wong Wai: 139, 706, 708
Cherif, Eya: 120, 127
Cherif, Yosra: 81, 163, 163, 248, 607, 609, 854, 858, 886
Chernova, Anastasia: 756
Chi, Kyong-Choun: 586
Chiekh, Maha: 979

Chimeno, María Montserrat: 408
Chinchilla, Jesennia: 535
Chitti, Arturo: 335
Chivite, David: 37
Chong, Kwok Chin: 482
Chora, Inês: 143, 647
Chow Liu, Patrícia Liz: 483
Chow, Wan Cheng: 719
Christantonou, Georgios: 286, 289
Christodorescu, Ruxandra Maria: 71
Ciammaichella, Maurizio Maria: 7
Cibickova, Lubica: 230
Cidade, José Pedro: 543
Ciobanu, Ana: 47
Cioni, Elisa: 843
Cioti, Cristina: 780
Cipriano, Elia: 328
Circo, Eduard: 324
Cirelli, Camilla: 86
Ciria, Esther Hierro: 360
Cittone, Micol Giulia: 50
Ciucu, Adina: 922
Clara, Ana Rita: 131, 531, 679
Claro, Inês: 423
Cláudio, Francisco Dias: 184, 280, 639, 904
Clim, Andreea: 69, 205
Cobos Siles, Marta: 373, 705
Cocco, Giulio: 53
Cochicho, Joana: 222, 343, 350
Cochicho, Joana Gomes: 410
Codish, Shlomi: 1
Coelho, Ana Margarida: 414, 588, 782
Coelho, Angela: 101, 279, 660, 805
Coelho, Carolina: 177, 530, 538, 574, 633, 634, 804, 818, 821
Coelho, Carolina Nunes: 204, 337, 338, 623
Coelho, Daniela: 213, 227
Coelho, Joana: 208, 267, 541, 907
Coelho, Luís: 203
Coelho, Margarida: 470, 910
Coelho, Margarida Gonçalves: 330
Coelho, Rita Passos: 596, 746
Coelho, Sara: 615
Coelho, Sofia: 699
Coelho, Sónia: 115, 242, 335, 794, 920
Coelho, Susana Carvalho: 532, 539
Coelho, Telmo Borges: 67, 121, 336, 684, 687, 783, 945
Cogliati, Chiara: 211
Cohen, Eytan: 555
Coimbra, Alexandra: 109
Colapietro, Francesca: 331, 335, 400
Colás, Ana: 238, 408, 955
Colás, Juan Carlos: 408
Colmenero Camacho, Miguel: 141
Colombo, Massimo: 331, 335
Comenda, Eduarda: 96
Comi, Cristoforo: 841
Comola, Giulia: 50
Conceição, Filipe: 953
Conceição, Mariana: 405, 802, 803, 809, 810, 820, 820, 822
Conceição, Susana: 521
Conceição, Vanda: 100, 171, 261, 262, 385, 463, 969
Condado, Daniana: 177, 768
Conde-Martel, Alicia: 77, 78, 685
Conde, Mariana: 728
Constante, Mariana: 200
Constante, Mariana Batista: 530
Constantine, Shadia Santos: 745
Conti, Carmello: 900
Coppola, Maria Gabriella: 143, 391, 534
Corazza, Francis: 758
Corbella Virós, Xavier: 252, 610
Corbella, Xavier: 37, 649
Corcuera, I: 948
Cordeiro E Cunha, Joana: 864
Cordeiro, Filipa: 49
Cordeiro, Gustavo: 161
Cordeiro, Ricardo: 112, 779
Cordoba, Karol Marcela: 751
Corga Da Silva, Rogério: 214
Corral De La Calle, Miriam: 975, 978
Corrales Cuevas, Manolo: 703
Corraliza, Maria Luisa: 514, 598
Corrêa, João: 103, 223
Correia Azevedo, Pedro: 713
Correia Cardoso, João: 509, 923
Correia De Sá, Ana: 238
Correia, Ana Filipa: 104, 600
Correia, Ana Isabel: 494, 502
Correia, Ana Luisa: 104, 600
Correia, Ana Sofia: 55
Correia, António: 280, 281, 283, 285, 534, 793, 823, 868, 915, 949, 980
Correia, Cátia Da Cruz: 691, 923, 924
Correia, Dulce Rita: 202
Correia, Filipe: 168, 257
Correia, Joana: 174, 506, 802, 803, 809, 810
Correia, Joana Batista: 820, 822
Correia, João: 117, 124, 319, 527, 577, 598, 617, 687, 708, 709, 713
Correia, João Alves: 255
Correia, João Araújo: 135, 700, 925
Correia, José Bernardes: 104, 417, 600
Correia, Luís Marote: 240
Correia, Maria João: 32, 130, 171, 319
Correia, Rita: 594
Correia, Rita Reis: 10, 11
Correia, Rui Soares: 823, 926
Correia, Sandra: 28

Correia, Sara: 405, 587, 598
Correia, Sílvia: 797
Corte Real, Ana: 87, 438, 844
Corte-Real, Ana: 628
Corte-Real, Ana Sacchetti: 401
Cortés, Camilo: 877
Cortese, Silvia: 716
Cortez E Castro, Margarida: 814
Cortez-Pinto, Helena: 359
Corzo, Carmen: 142, 169, 169, 170, 405, 587
Costa E Silva, Margarida: 807
Costa Fernandes, Sónia Da: 101, 263, 279, 333, 620, 713
Costa Matos, Luis: 868
Costa, Ana: 476, 551, 553, 849, 888
Costa, Ana F.: 889
Costa, Ana Lúcia: 696
Costa, Ana Lúcia Mendes: 623
Costa, Ana Oliveira: 363
Costa, Ana Paula: 729, 730
Costa, Ana Rita: 553
Costa, Anabela: 721
Costa, Andreia: 827, 980
Costa, Andreia Rocha: 197
Costa, Artur: 211, 641
Costa, Carla Lemos: 516
Costa, Catarina: 508, 614, 822, 911
Costa, Christine: 813, 819
Costa, Cláudia: 285, 415
Costa, Cláudia Amorim: 921
Costa, David Rabiço: 314, 315
Costa, Diogo: 625
Costa, Emanuel: 508, 661
Costa, Emanuel Ferreira: 89
Costa, Fernando Teixeira: 567
Costa, Hugo: 678
Costa, Inês: 128, 521
Costa, Inês Nogueira: 752
Costa, Ingrid Da: 226
Costa, Joana: 199, 239, 326, 780, 781, 959
Costa, João: 319
Costa, José Faria: 363
Costa, Laura: 423, 698, 700, 918
Costa, Liliana: 237
Costa, Luís: 621, 696
Costa, Luisa: 75, 902
Costa, Luisa Leal: 847
Costa, Magda: 51, 431, 623, 627, 702
Costa, Magda Ferreira: 226, 933
Costa, Maria Manuel: 265, 879
Costa, Mariana: 344, 435, 443, 458, 674
Costa, Marta: 513
Costa, Miguel: 158, 262, 617, 693, 799
Costa, Miguel Homem: 667
Costa, Miguel Reis: 147, 785
Costa, Munica: 920
Costa, Mylene: 28
Costa, Octávia: 142
Costa, Paula Alexandra Gonçalves: 549
Costa, Paula Gonçalves: 269, 296, 899
Costa, Paulo: 573
Costa, Paulo Zoé: 577, 598
Costa, Raquel: 142, 156, 182, 237
Costa, Regina: 94, 95, 161, 880
Costa, Rita Amorim: 185, 824
Costa, Sara: 819
Costa, Susana: 644
Costa, Tiago: 742
Costa, Tiago Guimarães: 415
Costa, Vasco: 203
Costa, Vítor: 68, 237
Costa, Wildemar: 519, 816
Costa, Yessica: 113
Costanzo, Martina: 336
Costeira, Filipa: 89
Costelha, João: 237, 591
Cota, Pedro: 146, 459, 520
Coti Zelati, Giulia: 86
Cotter, Jorge: 51, 59, 167, 184, 224, 238, 294, 299, 403, 431, 456, 464, 471, 476, 495, 551, 553, 621, 623, 627, 650, 694, 702, 777, 834, 849, 850, 865, 866, 897, 926, 931, 965
Couselo, João: 252
Coupe, Michael: 52
Coutinho Flores Da Cunha, Luiza: 747
Coutinho Soares, Leonor: 690
Coutinho, Andreia: 509, 864, 923
Coutinho, Daniel: 144
Coutinho, Diana: 74, 169, 291
Coutinho, Fernanda: 144, 946
Coutinho, Joao: 621
Couto, Carlos: 795
Couto, Catarina: 376, 789
Couto, Couto: 639, 808
Couto, Joana: 625
Couto, Lénio P.: 717
Couto, Marta: 265
Covarrubias Flores, Dora Luisa: 836
Craciun, Ana: 129
Craveiro, Ana: 776, 777, 796
Craveiro, Nuno: 8, 14
Craviotto, Vincenzo: 331
Cravo, Márcia: 510
Creanga, Elena: 354, 758
Crevola, Martina: 336
Cristea, Viorela: 545
Cristea, Viorela Bianca: 130, 916
Croce, Alessandro: 317, 839, 841, 869
Cruciani, Adrian: 261
Crudele, Felice: 56, 843

Cruz, Ana Luísa: 58, 59, 454
Cruz, Ana Paula: 544
Cruz, Catarina Lizardo: 666
Cruz, Cristiano: 430, 522, 527, 871
Cruz, Fábila: 10, 11, 594
Cruz, Ines: 95
Cruz, Inês Esteves: 30, 228, 581
Cruz, Isabel Martins: 533
Cruz, Lourenço: 430, 522, 526, 527, 871
Cruz, Margarida: 154, 376
Cruz, Marli: 332, 573, 597, 755, 822
Cruz, Rute Brás: 646, 976
Cruz, Sofia: 294, 454, 676
Cruz, Sofia Guerreiro: 348, 362, 692, 910
Csecsei, Peter: 216
Csiszar, Beata: 216
Cuadros, P: 948
Cuenca Carvajal, Carmen: 270
Cuesta Marín, Alicia: 447
Cuesta-Frau, David: 488
Cunha Martins, Sónia: 153
Cunha, Alexandra Tenda: 808
Cunha, Ana: 11, 265
Cunha, Ana Sofia: 492
Cunha, Ângela: 802, 802, 803, 820, 820
Cunha, Catarina: 131
Cunha, Gonçalo: 124, 228
Cunha, Guilherme Violante: 140, 310
Cunha, Inês: 260, 625, 773, 929, 932, 933, 935
Cunha, Ivo: 241, 400, 557, 645, 973
Cunha, Joana: 542, 697
Cunha, Joana Cordeiro: 509, 923
Cunha, João: 783, 784
Cunha, Maria Margarida: 683
Cunha, Maria Ribeiro: 359
Cunha, Marta: 476, 931
Cunha, Pedro: 850, 931
Cunha, Rita: 446, 446, 614, 929, 933
Cunha, Vitória: 708, 709, 713
Curbelo, Jose: 389
Curcic, Ela: 586
Cusnir, Iuliana: 204, 337, 338, 623
Custódio, Marta: 282, 763, 934
Cysneiros, Ana: 789
D'Agnano, Salvatore: 792
D'Alfonso, Maria Grazie: 56
D'Aloisio, Giordana: 361
D'Ambrosio, Roberta: 107
D'Amico, Roberto: 707
D'Onofrio, Fabiana: 45
D'Orey, Francisco: 108, 522, 818
Da Costa Cardoso, Daniela: 804, 886
Da Costa, Inês Lopes: 68, 124, 535, 632
Da Cruz, Mariana: 376
Da Silva, Francisco Teixeira: 70, 696, 873, 874
Da Silva, Inês S F: 636, 799
Da Silva, Rafael Carlos: 751
Daadaa, Syrine: 761
Daher, José: 261, 716
Dalekos, George N.: 307, 316, 325, 446, 843
Damião, Filipe: 365
Damin, Carlos: 716
Daminov, Botir Turgunpulatovich: 941
Damotsev, Alexandros: 445
Daniel, Jorge: 332, 755
Daniel, Pascale: 754
Dantas, Jorge: 128
Dantas, Rosa: 233
Dantes, Elena: 780
Darbellay Farhoumand, Pauline: 733
Das, Shambaditya: 555, 735
Davidenko, Ilya: 263, 756
Dávila-Ramos, Melitón: 78
Dávila, Julio: 355
De Abreu, Tiago Tribolet: 639
De Almeida Garrett Soares Da Silva, Frederico: 160, 478, 632
De Almeida, Carlota Tuñón: 43, 73, 102, 709, 848, 950
De Andrés David, Carlos: 404
De Benedittis, Carla: 311, 336, 448
De Brito Dias, Ana Paula De Brito Dias: 578
De Campos, Dina Manuela Soeiro Marinho: 260
De Carmo Campos, Ana: 767, 974
De Carvalho, Armando: 566, 760
De Freitas, Ester Catarina Cabral: 523
De Geyter, Deborah: 465
De Giorgi, Alfredo: 9, 10
De La Hoz, César Alberto: 415
De La Rosa Valero, Vicente David: 271, 286, 410, 417, 456, 486, 624, 762, 838, 841, 855, 960
De La Torre Solís, Carlos: 422
De La Varga Martínez, Raquel: 495
De Lacerda, Noa: 3
De Lima, Taís Mendes: 229
De Los Rios De La Peña, Ricardo: 72, 469, 703, 703
De Luca, Claudio: 143, 391
De Matos, Andreia Margarida Margarida: 225, 547, 697
De Moraes, Margarida Melo: 409
De Nadai, Guendalina: 398, 436
De Rooij, Madeleine Larissa: 466
De Sá Pereira, Yolanda: 334, 621, 642
De Santos Belinchón, Sergio: 259, 457, 616
De Sena, Antonietta: 391
De Sena, Maria Antonietta: 143
De Sousa-Neves, Nuno: 528
De Sousa, Carina: 351, 484
De Vega-Ríos, Enrique: 389
De-Miguel-Yanes, Jose María: 560
Debska-Slizien, Alicja: 22

Decq Mota, Joana: 505
Defendini, Carolina: 59
Del Cerro, Eduardo: 3, 716
Del Medico, Marta: 211
Del Olmo, Lara Cantero: 206
Del Toro Cervera, Jorge: 48, 605, 784, 893, 897
Del-Castillo-Rueda, Alejandro: 428
Delerue, Francisca: 132, 708, 709, 713, 818
Delerue, Maria Francisca: 510
Delfs, Neele: 231
Delgado, Juan Mora: 246, 246, 595, 706, 723
Delgado, María Pilar: 356
Delgado, Marlene: 823, 926
Deliolanis, Ioannis: 411
Deluca, Claudio: 534
Demelo Rodríguez, Pablo: 48, 605, 784, 791, 793, 893, 897
Demirtas, Raziye Nesrin: 269, 270
Denguezli, Mohamed: 761, 765, 769
Deres, Laszlo: 216
Derma, Wasim Saeed: 37
Desena, Antonietta: 534
Devesa, Mariana: 93, 407
Deveza, Nuno: 515
Dghaies, Salma: 887, 887
Dhahri, Dr Rim: 878, 921
Dhahri, Rim: 470, 547, 550, 762, 833, 834, 861, 862, 882, 883, 884, 885, 887, 888, 967
Dhillon, Shubhkaran: 505
Di Ciaula, Agostino: 326
Di Francesco, Pietro: 79
Di Gregorio, Sara: 211
Di Palo, Domenica Maria: 326
Di Silvestro, Katharine: 210
Di Tommaso, Luca: 335
Diamantopoulos, Panagiotis: 659
Dias Antunes, Joana: 629
Dias Cunha, Ângela: 809, 810, 822
Dias Da Silva, Carlos: 319, 353
Dias Rodrigues, Gabriel: 86
Dias, Alexandra: 144, 770, 946
Dias, Ana Paula: 197
Dias, André: 487
Dias, Andreia: 747
Dias, David: 695
Dias, David Da Silva: 552
Dias, Diana Isabel: 108, 264
Dias, Eugénio: 136, 228, 369, 677, 699
Dias, Eugénio Nóbrega: 393, 983
Dias, Graça: 504, 655
Dias, Helena: 345, 644, 644
Dias, Helena Vieira: 286, 570
Dias, Liliana: 714
Dias, Luís: 55, 293, 303, 399, 447, 578, 607, 614, 694
Dias, Luís Monteiro: 346, 493, 638
Dias, Margarida Carmo: 629, 630
Dias, Nuno: 660
Dias, Patrícia: 953
Dias, Paula: 674
Dias, Rafael: 177, 179
Dias, Sara: 650
Dias, Vitor: 415
Dias, Vítor Paixão: 66, 67, 121, 336, 343, 455, 553, 617, 684, 687, 783, 806, 945, 962, 963
Díaz De Castellví, Sandra: 37
Díaz-Parreño Quintanar, Clara: 194, 195
Díaz, Andrea: 738, 738
Díaz, Francisco: 356
Díaz, Gonzalo: 110
Diaz, Lucas: 220, 550, 982
Diegues, Andreia: 57, 323, 782
Diegues, Andreia Cinara Branco: 208, 478
Díez Herrán, Nuria: 404, 564, 942
Díez Romero, Cristina: 433
Díez-Herrán, Nuria: 961
Dima, Nicoleta: 69, 205
Dimitrijevic, Zorica: 559
Dimitroulis, Dimitrios: 412
Dina, Ion: 116
Dinis, Ana Clara: 860
Diniz, M. João: 764, 764
Diogo Canudo, Diogo Canudo: 291
Diogo, Cláudia: 57, 616
Diogo, Cláudia Oliveira: 152
Diogo, Joana: 177, 530, 538, 574, 633, 634, 804, 818, 821
Dionísio, Ana: 335, 794
Dionísio, Ana Catarina: 245
Dionísio, Catarina: 782, 920
Do Nascimento, Priscilla Costa: 578
Do Rego, Ana Torres: 54
Do Rosário, Vanisa: 240
Dobao, Maria Luz: 25
DobelNiece, Lauma: 178
Dobos, Sebastian: 354
Dolcemelo, Lucas: 553
Domingos, António: 112
Domingues, Filipa: 290
Domingues, Kevin: 8, 14
Domingues, Patrícia: 431, 785
Domingues, Rui: 972
Domingues, Rui M.: 515, 788, 966
Domínguez, Severina: 856
Dominicé Dao, Melissa: 1
Doña, Alfredo Michan: 246
Donaire, David Mejias: 540
Donato, António: 679
Donato, Beatriz: 91, 167, 224
Dória, Maria Do Céu: 125, 298
Dos Anjos, Rafael Silva: 528

Dos Santos Marques, Rita: 277
Dos Santos, Daniel Ribas: 751
Dos Santos, Pedro Martins: 297, 622, 925, 936
Douki, Nabih: 378
Dradaki, Vicky: 380, 381, 382, 390
Dragan, Simona: 49, 71
Draganescu, Cristiana: 116
Dražilová, Sylvia: 427
Drever, Mariana: 65
Dri, Irini: 380, 381, 382, 390
Drieher, Jacob: 1
Drositis, Ioannis: 612
Dsouza, Nikhil Victor: 767
Duarte, Augusto: 58, 59, 454, 509, 617, 618, 697, 864, 923
Duarte, Cristina Maria: 503, 567
Duarte, Daniel: 112, 779
Duarte, Delfim: 840
Duarte, Fernanda Paixão: 523
Duarte, Filipa Martins: 877
Duarte, Frederico: 477
Duarte, Joana: 128
Duarte, Joana A.: 904
Duarte, Joana Alves: 293
Duarte, João: 5
Duarte, José: 639, 795, 808
Duarte, Josiana: 710
Duarte, Josiana Oliveira: 379
Duarte, Leila: 129, 569
Duarte, Maria: 168, 168
Duarte, Maria Alexandra: 951
Duarte, Maria Fernanda Paixão: 937
Duarte, Marta: 468
Duarte, Paula: 778, 789
Duarte, Paulo Cantiga: 468, 526, 878
Duarte, Pedro: 303, 399, 517, 578
Duarte, Rita Ribeirinho: 184
Duarte, Sara: 368, 470, 695
Duarte, Silvia: 660
Duarte, Tiago: 438
Ducla Soares, José Luís: 321, 442, 608, 663
Dueñas, Daniel Marín: 246, 706
Duh, Maria Montserrat: 435
Dumpis, Uga: 954
Duque, Sofia: 376, 390, 391, 721
Durán-Coyote, Salvador: 243
Duran, David: 628
Durão-Carvalho, Gonçalo: 695, 701, 809, 810
Durão, Sofia: 222, 695
Durdevic, Momcilo: 943
Durusu Tanriover, Mine: 396, 483, 715
Dutertre, Florence: 311
Dutschmann, Rita: 622, 811
Dutta, Ananta: 555, 735
Düzgün, Fikret: 922
Dvorakova, Monika: 503, 813
Ebbo, Mikaël: 743
Eça, Rosário: 52, 327, 611
Echchilali, Khadija: 829
Edígio, Inês: 124
Efe, Belgin: 269, 270
Egídio, Inês: 68
Eguiluz, Saioa: 856
Eira, Isabel: 28, 960
Eira, José Ribeiro: 560
Eiras, Eduardo: 143
Eiras, Ricardo: 747
Ekar, Robert: 2
Ekundi, Eliseu: 229
El Halli Obeid, Melina: 205
El Hérou, Abdo: 941
El Osta, Badi: 583
El Osta, Hazem: 582
El Osta, Lana: 582, 583, 941
El Osta, Nada: 582, 583, 941
Eliadi, Irene: 659
Elias, Adi: 22
Elias, Telma: 288, 860
Elisabe, Daniel: 716
Eliseu, António: 248, 339
Elkabli, Hassan: 829
Elleuch, Mounira: 969
Elvas, Ana Rita: 103
Elvas, Henrique: 121
Elvas, Henrique Rijo: 415
Elvira Laffond, Ana: 51
Embaló, Ussumane: 650, 897, 965
Emídio, Ana Catarina: 136, 213, 228, 274, 473, 682
Emídio, Catarina: 219
Emidio, Fabio Caleça: 770, 977
Ennis, Giovana: 281
Ennis, Giovana Clare: 506
Ennis, Giovanna: 534, 980
Enriquez De Salamanca, Rafael: 751
Enríquez Gómez, Andrés: 457, 897
Enríquez-Ramos, Scarlett: 243
Er, Chaozer: 139, 266, 307, 482, 706, 708
Eransus Garzaron, María: 428, 429
Erythropoulou, Anastasia: 465
Escamilla Espínola, María: 85, 91, 975, 978
Escamilla, María: 415
Escária, Susana: 598, 731
Escarigo, Conceição: 708, 709, 713
Escobar Garcia, Adel Enrique: 553, 937
Escobar-Arias, Fabio Hugo: 420
Escórcio, Sofia: 196
Escrihuela-Vidal, Francesc: 610
Escudero, Encarnación Moral: 563, 806
Esles Bolado, Marta Carmen: 87, 273

Esperança, Sofia: 89, 508, 661
Esperto, Helder: 239, 417, 592
Espinola-Klein, Christine: 61
Espinosa-Auni6n, Ruth: 195
Espinosa-Monroy, Inmaculada: 194, 195
Espinoza P6rez, Jos6 Alberto: 582
Esp6rito Santo, Catarina: 114, 525
Esp6rito Santo, Jo6o: 266, 386
Est6cio, Marlene: 978
Est6v6o, D6lia: 103, 223, 245, 844
Esteve Luque, Virginia: 252
Esteves Freitas, Tiago: 464, 874, 958
Esteves, Alexandra: 214, 625, 689
Esteves, Andre: 95, 654
Esteves, Francisco: 197, 225, 952
Esteves, Joana M.: 693
Esteves, Maria Cristina: 176, 285, 361
Estevinho, Fernanda: 328
Esther, Ramirez Ortiz: 728
Etogo-Asse, Frederique-Estelle: 333
Eug6nio, Gisela: 913, 929, 933
Eul6lio, Margarida: 58, 133, 152, 615, 766
Evangelista, Maria Do C6u: 211, 641
Evangelista, Vasco: 91, 93, 167, 224
Exiara, Triada: 154, 157, 253, 254, 256, 257, 445, 451, 524, 860
Fabbian, Fabio: 9, 10
Fachada, Renata: 453, 504, 747, 863, 898
Fagundes, Vitor: 157
Faizal, Baiju: 138
Fajardo, Grisell Starita: 433, 903
Falc6o, Carla: 252, 499, 669, 930
Falc6o, F6tima: 376
Falc6o, Luis: 160
Falc6o, Lu6z Menezes: 20, 31, 32, 35, 40, 56, 130, 545, 916, 976
Falc6o, Miguel: 220, 521, 542
Falcetta, Andrea Paolo: 792
Falsetti, Lorenzo: 216
Fangazio, Stefano: 361
Farah, Pamela: 754, 943
Faraldo, Selmira: 754
Faraone, Antonio: 512
Fargion, S6lvia: 347, 357
Faria Esteves, Andr6: 818
Faria, Catarina: 57, 152, 616
Faria, Catarina Ara6jo: 32
Faria, C6tia: 23, 141, 585
Faria, Domit6lia: 468
Faria, Luciana: 119, 223, 321, 589
Faria, Rita: 183
Faria, Sara: 227, 511, 677, 760
Faria, Sara Joana: 888, 889
Faria, Teresa: 425, 597, 774
Farias, Lais Ferreira: 751
Farinha, Ana: 699
Farinha, F6tima: 259, 700, 844, 925
Farinha, In6s: 353, 808
Fatta, Erika: 347, 357
Faustino, Diogo: 146, 521, 535, 665, 948
Favas, Catarina: 305
Fayos, Marina: 267, 268
Fazaa, Alia: 885
Fazendas, Paula: 65
Fazio, Martina: 311
Fedeli, Ugo: 9
Fedorov, Andrey A.: 101
Fehlmann, Christophe: 188, 733
Feij6o, Salvato: 799, 813, 819
Feldman, Bianca: 453, 504, 753, 863, 900
Felgueiras, Paula: 625, 689
Felip, Angela: 435, 439, 604
F6lix Paix6o, Joana Isabel: 666
Feng, Ding-Yun: 778
Fenoglio, Luigi Maria: 792
Fera, Manuela: 431, 785
Ferguson, David: 52
Fernandes, Alexandre: 934
Fernandes, Alexandre N.: 179, 282, 667, 763
Fernandes, Ana: 628
Fernandes, Ana Paula: 452
Fernandes, Andre: 272, 643
Fernandes, Andreia: 165
Fernandes, Catarina: 624
Fernandes, C6lio: 57, 141, 152, 166, 270, 352, 585, 607, 616, 640, 873, 899
Fernandes, Cristiana: 443, 516, 832
Fernandes, Diana: 252, 499, 669, 676, 697, 932
Fernandes, Diana Pires: 119, 227
Fernandes, F6tima: 613
Fernandes, Gisela: 610
Fernandes, Isabel: 544, 602
Fernandes, Ivone: 789
Fernandes, Jorge: 669
Fernandes, Jos6 Pedro: 104
Fernandes, L6liliana: 123, 673
Fernandes, Magda: 167, 299
Fernandes, Marco: 171
Fernandes, Marco Ferreira: 32
Fernandes, Mar6lia: 387, 532, 729, 730, 920
Fernandes, Mar6lia Andreia: 374, 374
Fernandes, Martinho: 494, 502
Fernandes, Mauro: 66, 797
Fernandes, Nuno: 218
Fernandes, Rita: 124, 463, 470, 529, 573, 687, 817
Fernandes, Rudi: 627
Fernandes, Rui: 238
Fernandes, Sara Lopes: 19, 140, 189
Fernandes, S6nia: 25, 190, 321
Fern6ndez Alam6n, Am6lia Inmaculada: 20

Fernández Carracedo, Eduardo: 430, 457
Fernández Castro, Iván: 479
Fernández Díaz, María Del Rocío: 720
Fernandez Fernandez, Paula: 149, 441
Fernandez Moreno, María Del Carmen: 141
Fernández Ontiveros, Sergio: 720
Fernández Ramos, Patricia De La Palma: 422
Fernández Roblas, Ricardo: 791
Fernández Rodríguez, Camino: 301
Fernández- Bravo, Irene García: 54
Fernández-Cotarelo, María José: 408, 488
Fernandez-Gil, Adela: 460
Fernández-Muñoz, Hermógenes: 421
Fernández-Muñoz, Hermógenes Francisco: 420
Fernández-Rodríguez, Camino: 973
Fernandez, Diana: 261
Fernández, Eduardo: 602, 835
Fernández, Ester Paula Fernández: 439, 455
Fernández, Paula: 435, 604
Ferrante, Chiara: 27, 593
Ferrão, Ana Ubach: 507, 635
Ferrão, Diana: 92, 181, 197, 565, 702, 747
Ferrão, Diana Seixas: 363, 365
Ferrão, Estela: 71, 155, 258, 462
Ferrão, Francisco: 11
Ferrão, Gonçalo: 217, 765
Ferrão, Joana: 633, 884
Ferrarini, Alessia: 830
Ferraro, José Luís: 91, 167, 224
Ferraro, Lia: 271, 286, 410, 456, 486, 624, 762, 838, 960
Ferraz, Lisa: 129
Ferraz, Mário: 487, 568, 669
Ferrel Beltran, Adrián: 759
Ferreira, Rute: 88
Ferreira De Almeida, Mariana: 182
Ferreira Pasos, Eva: 918
Ferreira Santos, Flávia Marília: 23, 589
Ferreira Silva, Nuno: 131
Ferreira, Afonso Nunes: 928
Ferreira, Álvaro: 625
Ferreira, Ana: 167, 866
Ferreira, Ana Carolina: 978
Ferreira, Ana Erica: 945
Ferreira, Ana Luís: 299
Ferreira, Ana Raquel: 129
Ferreira, Ana Teresa: 526
Ferreira, António Jorge: 786
Ferreira, Bernardo: 787, 788
Ferreira, Bruno: 348
Ferreira, Carla: 458
Ferreira, Cármen: 144, 479
Ferreira, Cármen Resende: 946
Ferreira, Carolina: 75, 534, 902, 980
Ferreira, Carolina Reis: 285
Ferreira, Cátia: 95
Ferreira, Daniel: 19, 182
Ferreira, David: 881
Ferreira, Diogo: 192
Ferreira, Duarte André: 66, 787, 797
Ferreira, Emanuel: 162
Ferreira, Érica: 314
Ferreira, Eugénia: 547
Ferreira, Filipa: 64, 65, 82, 121, 126, 766
Ferreira, Filipa Bordalo: 582, 631
Ferreira, Filipa Coroado: 314
Ferreira, Francelino: 326, 434, 603
Ferreira, Gisela: 637, 648, 661
Ferreira, Inês: 155, 201, 203, 354, 789, 953
Ferreira, Inês Branco: 840, 896
Ferreira, Irina: 523, 524, 529
Ferreira, Isabel: 218
Ferreira, Joana: 288, 431, 688, 785, 814
Ferreira, Jorge Silova: 334
Ferreira, Jorge Silva: 621, 642
Ferreira, José Miguel: 443
Ferreira, José Pestana: 747
Ferreira, Lurdes: 87
Ferreira, Mafalda: 239, 417, 592
Ferreira, Manuel: 696
Ferreira, Marcel Treptow: 504
Ferreira, Maria Inês Xavier: 523, 937
Ferreira, Mário: 123, 207, 673, 868
Ferreira, Marli: 822
Ferreira, Melanie: 291, 683
Ferreira, Miguel: 81
Ferreira, Nuno: 171, 721
Ferreira, Nuno Ribeiro: 32
Ferreira, Paula: 121, 336, 684, 687, 742, 783, 945
Ferreira, Paula Marques: 332, 755
Ferreira, Paulo: 44, 137, 147, 166, 247, 488, 600, 601, 748, 769, 850, 851, 891, 949, 950, 966
Ferreira, Paulo Carvalho: 257
Ferreira, Pedro: 391
Ferreira, Rogério: 566, 760
Ferreira, Ruben Duarte: 602
Ferreira, Rui: 87, 468, 511, 680
Ferreira, Rui C.: 26, 27
Ferreira, Rute: 74, 166
Ferreira, Rute Moraes: 76, 76, 117
Ferreira, Sara: 615
Ferreira, Sara Esteves: 233
Ferreira, Sofia: 332, 755
Ferreira, Sofia Dinis: 667
Ferreira, Sofia Patrícia Dinis: 243
Ferreira, Tânia: 510
Ferreira, Tânia Araújo: 122, 822
Ferreira, Teresa: 430, 522, 527
Ferreira, Tiago: 867

Ferreira, Vera: 87
Ferreira N., Monica: 908
Ferreiro Mazón, Mercedes: 427
Ferreiro-Mazón Jenaro, María Mercedes: 426, 605, 766, 790, 879
Ferro, Ana Rita: 915
Ferro, António: 871
Ferro, Daniela: 145
Ferro, Rita: 804, 820, 822
Fialho, Inês: 125
Fiarresga, António: 87
Fidalgo Silva, Mónica: 134
Fidalgo, Ana Paula: 185
Fidalgo, Mariana: 47, 103, 664, 945
Fideles, Rita: 920
Fierbinteanu, Carmen: 345
Figueira, João: 109, 523
Figueira, João Pedro: 937
Figueira, Mafalda: 136, 228, 393, 983
Figueira, Mafalda Corrêa: 372, 907, 927
Figueira, Ricardo: 912, 912
Figueiras, Mariana: 449
Figueiredo Costa, Ana: 629
Figueiredo, Adelaide: 176, 285, 361
Figueiredo, Ana: 353, 543, 666
Figueiredo, António: 460
Figueiredo, Armindo: 300, 342, 470, 475, 686, 695
Figueiredo, Carlos: 336, 692, 795, 814, 823
Figueiredo, Cátia: 501, 868
Figueiredo, Cátia Castanheira: 793
Figueiredo, Inês: 532, 890, 920
Figueiredo, Inês Ladeira: 503, 567
Figueiredo, Inês Rego: 374, 374, 387, 729, 730
Figueiredo, Manuel De: 412, 413, 413
Figueiredo, Sandra: 820
Filipe, Filipe: 878
Filipe, Paulo: 551, 936
Filipe, Paulo Leal: 755
Filipe, Ricardo: 385
Filipovsky, Jan: 82
Filomena, Teresa: 857
Fiori, Mauricio: 261
Fityan, Mohammad: 505
Fiúza, Tiago: 379, 503, 710, 813
Flacco, Maria Elena: 10
Fliss, Marwa: 901, 969
Florea, Andreea: 562
Florea, Ioana: 852, 853
Florea, Laura: 562, 852, 853
Florêncio, André: 185
Flores, Luiza: 453, 753, 863, 900
Flores, Rui: 30
Flores, Rui Files: 92, 275, 287, 915
Florescu, Andrei Georgian: 48
Flórez, Andres: 229
Florim, Sofia: 652
Florio, Lucia: 63
Florova, Etel: 575
Folgueras Gómez, María: 518, 798
Folgueras, María: 746, 962
Folino, David: 39
Fong, Kok Yong: 719
Fonseca, Cândida: 68, 124, 128, 130, 319, 448, 934
Fonseca, Helena: 29
Fonseca, Helena Martins Da: 25
Fonseca, Inês: 59
Fonseca, Isabel: 208
Fonseca, João: 152, 610, 615, 855
Fonseca, Luísa: 145
Fonseca, Margarida: 530
Fonseca, Margarida Rodrigues: 200
Fonseca, Marina Duque: 357
Fonseca, Marta: 123, 207, 673, 868
Fonseca, Ricardo: 251
Fonseca, Samuel: 133, 548, 906
Fonseca, Teresa: 135, 767, 974
Font, Carme: 604
Font, Resfa Garcia: 728
Fontanellas, Antonio: 751
Fonte, Joana: 700
Fontes, Carla Pereira: 133, 264, 339, 548, 877
Fontes, Joana: 174, 237, 871
Fontes, Luísa Fraga: 503, 567
Fontes, Mário: 162
Fontoura, Alexandre: 189
Formagnana, Pietro: 712
Formiga, Francesc: 37
Formigo, Mariana: 51, 431, 849, 850, 926, 931
Fortini, Alberto: 512
Fortuna, Ana: 501, 651
Fortuna, Jorge: 543, 545, 846, 907, 916
Foutsitsakis, Dimos: 289, 693
Fracanzani, Anna Ludovica: 107, 347, 357
Fraga, Matilde: 669
Fragiadis, Evangelos: 591
Fragioudaki, Sofia: 412
Fragoso, André: 292
Fraj, Aya: 852
França, Jhenifer Nataly Moura: 968
Francione, Paolo: 107
Francisco, José Teixeira: 619
Francisco, Luís: 634
Franco, Ana: 786
Franco, Fátima: 644
Franco, Sara: 566
Frazão, Vera: 23, 589
Freitas, Alexandra: 481
Freitas, Ana Raquel: 837
Freitas, Andreia: 9, 153, 845

Freitas, Bruno David: 105, 337, 338, 623
Freitas, Catarina Miriam Capelo: 195, 846
Freitas, Eduardo: 159
Freitas, Ema Da Conceição Abreu Ferreira Teles: 243
Freitas, Ester: 524, 529
Freitas, Hilda: 44, 137, 147, 166, 247, 488, 600, 601, 748, 769, 850, 851, 891, 949, 950, 966
Freitas, Isabel: 932
Freitas, Isabel Maria Dias Martins: 58, 59, 454
Freitas, João Miguel: 104, 359, 662, 663, 798
Freitas, Mariana Sousa: 409
Freitas, Marta Baptista: 365, 635
Freitas, Patrício: 177
Freitas, Paulo: 290, 452
Freitas, Rafael: 177
Freitas, Rodrigo: 863
Freitas, Sara: 224, 850, 865, 866, 926, 931
Freitas, Sara Mendonça: 432, 863
Frías, Carlos Aldasoro: 43, 102, 848
Friões, Fernando: 11
Friões, Fernando: 960
Frischia, Michelle: 37
Frisoni, Giovanni B.: 39
Frois Cunha, Inês: 775
Frutuoso, Joana: 498
Frutuoso, Joao: 452, 862
Fryszak, Zdenek: 230
Fuchs, Lior: 89
Fuentes Lacoutur, Maria Cythia: 399, 752, 877
Fujisawa, Mari: 485
Fujita, Isao: 310
Fulgencio Delgado, Ana: 777
Furlan, Ludovico: 84
Furtado, Ana Bastos: 741
Furtado, João: 543
Furtado, Sofia: 68, 124, 714
Furtado, Teresa: 339, 699
Gaba, WAQAR Haider: 161, 872
Gabara-Xancó, Cristina: 604
Gabarró López, Nuria: 803, 879
Gabella Martin, Miriam: 373, 705
Gabeta, Stella: 307
Gabriel, Gemma: 39
Gabielli, Armando: 830
Gachoud, David: 712
Gafarov, Valery: 23
Gafarova, Almira: 23
Gafner, Sandra: 231
Gagliano, Manfredi: 843
Gagliardi Alarcón, Lidia: 544, 724, 725
Gago, Tânia: 368
Gagulin, Igor: 23
Galanis, Konstantinos: 307
Galasso, Domenico: 311
Galasso, Soledad: 205
Galeano Valle, Francisco: 48, 605, 784, 791, 893, 897
Galindo Andúgar, María De Los Angeles: 194, 195
Galindo, Mervyn Steven: 110
Gallardo, M. Angeles: 303
Gallardo, María De Los Angeles: 149, 150, 328
Gallone, Gianluca: 84
Galvez, Raquel Rostro: 35, 36
Gama, Artur: 245, 335, 794
Gama, Guilherme: 145
Gama, Leonor: 474, 813
Gamboa Cunha, Rita: 254, 508
Gameiro, Ana: 183, 675, 688, 914, 917
Gameiro, Anton F. R.: 613
Gameiro, Rita Sousa: 835
Gammoudi, Rima: 761, 765, 769
Gampeta, Stella: 307
Gañán-Moreno, Eduardo: 905
Ganceanu-Rusu, Roxana: 69, 205
Gandara, Judit: 332, 755
Gangemi, Sebastiano: 890
Garay Airaghi, Victoria: 724, 725
Garbouj, Wafa: 852
Garça, Magda: 146, 419, 459, 520
Garça, Magda Joana: 481, 611
Garcez, Helena: 494
García Alonso, María Rocío: 91, 975, 978
García Ceberino, Pedro Manuel: 720
García Espona - Pancorbo, Alejandro: 845
García Fernández-Bravo, Irene: 48, 616
García García, Alejandra: 54, 255, 759, 791
García Morales, Natalia: 322
García Rodríguez, Magdalena: 404
García Vallejo, Jose María: 78
García Vidal, Olga Eulàlia: 435
García Villa, Jose Luis: 759
García Villafranca, Alba: 151, 479
García-Hernández, Sonia: 901
García-Prieto, Ana María: 793
García-Quintana, Antonio: 78
García-Villa, Adrian: 604
García-Villafranca, Alba: 340, 342
García, Ascensión González: 728
García, David: 112, 267, 268, 461
García, Esther: 626, 626
García, Jorge: 881
García, José: 571
García, Jose Alejandro Medina: 592
García, María: 99, 647, 675
García, Octavio Arce: 433, 544
García, Tamar Nunes: 410
García, Teresa: 336, 522, 527, 795
Garcinuño, María Angeles: 415
Garez Gomes, Sara: 113, 134

Garin, Nicolas: 311
Garnier, Antoine: 712, 712
Garrido, Jesus: 75
Gaspar, Alexandra: 677, 699
Gaspar, António: 447
Gaspar, Cátia: 173
Gaspar, Cátia Fava: 116, 180, 541
Gaspar, Elsa: 507
Gaspar, Pedro: 936, 976, 978
Gaspar, Pedro Silva: 165, 369, 680, 685, 924, 927
Gaspar, Tânia: 220, 521, 542
Gasparinho, Ricardo: 917
Gatselis, Nikolaos K.: 307, 325, 843
Gaudêncio, Margarida: 172, 290, 511, 677
Gavala, Cristina: 191
Gavina, Cristina: 681
Geers, Caroline: 465
Gennaro, Nicolò: 335
Gentili, Tamira: 216
Gentilli, Sergio: 361
Georgescu, Cristina Elena: 48
Georgescu, Doina: 313
Georgopoulou, Aggeliki: 411, 591
Gerardo, António Madeira: 800
Gerardo, Rita: 526, 814
Gerlach, Johanna: 193
Germano, Isabel: 122
Germano, Nuno: 438
Geva Robinson, Shahar: 89
Geyer, Martin: 16
Ghanayim, Tamer Hasan: 828
Ghannouchi, Neirouz: 761
Gharbi, Youssef: 607, 858
Ghariani, Najet: 761, 765, 769
Gharsallah, Imen: 470, 833, 834, 864, 862, 878, 882, 883, 884, 885, 921
Gharsallah, Imene: 547, 550, 762, 967
Gheorghe, Andrei Cristian Dan: 47, 48
Gheorghe, Gabriela Silvia: 47, 48
Ghilechi, Angela: 177, 530, 538, 574, 633, 634, 804, 818, 821
Ghinea, Mihaela Maria: 780
Ghinea, Mihaela-Maria: 302, 324
Ghosh, Soumitra: 236
Ghosh, Srabani: 236
Giamello, Jacopo Davide: 792
Giani, Tommaso: 512
Giannakoudakis, Emmanouil: 420
Giannis, Theofanis: 446
Giannone, Ferdinando Antonino: 320
Giannoulis, George: 307
Gião, Artur: 502
Gibert, Luis: 267, 268
Gibietis, Valdis: 90
Gigante, Ana Rita: 471, 807, 964
Gikopoulos, Antonios: 327
Gil-Díaz, Aída: 77, 78, 685
Gil-Gascon, Jose Manuel: 450, 451, 579, 580, 909, 910, 911
Gil, Angela: 936
Gil, João Caiano: 55, 119
Gil, Lucia: 339
Gilabert, Noemi: 389
Gilis, Roni: 89
Gill, Cara: 17
Giosia, Valeria: 378, 403, 422
Girão, Adriana: 208, 631
Girino, Margherita: 50
Girszyn, Nicolas: 913
Gisca, Eugeniu: 132, 510
Gjata, Margarita: 232
Gjermani, Eliona: 941
Gjermani, Ilir: 941
Gkogkos, Konstantinos: 286, 486, 536, 892
Gloria, Perez-Vazquez: 450, 451, 909, 910, 911
Gobbo, Luisa Da Cunha: 968
Godeev, Ivan G.: 194
Godinez, Luis Benjamín: 46, 110, 323, 432, 437, 701
Godinho, Carlos: 637
Godinho, Flávio: 242, 313, 842
Godoy-Reyes, Ana María: 901, 944, 973
Goes, Ana Teresa: 320
Goes, Maria José: 892
Goes, Teresa: 710
Gogas, Helen: 659
Goh, Jovina Summer: 266
Goicoechea Núñez, Paula: 918
Góis, Mario: 895
Gokalp, Deniz: 231
Gola, Mário: 770
Gold, Gabriel: 39
Goldberg, Elad: 555
Gologan, Elena: 302
Gomberg, Álli: 898
Gomes Da Silva, Maria: 624
Gomes Neto, Margarida Dias Agudo: 979, 981
Gomes Santos, Pedro: 297, 925, 936
Gomes, Ana: 94, 709, 713
Gomes, Ana Garrido: 105, 337, 338, 623
Gomes, Ana Oliveira: 746
Gomes, Ana Patrícia: 170, 214, 659, 900
Gomes, Ana Rita: 348, 692
Gomes, André: 192
Gomes, Bráulio: 808
Gomes, Clara: 11
Gomes, Daniel Costa: 636
Gomes, Dolores: 549
Gomes, Dora: 285, 534, 980
Gomes, Ernestina: 213
Gomes, Felisbela: 469

Gomes, Filipa: 241, 416, 590
Gomes, Francisco: 82
Gomes, Guilherme: 819
Gomes, João: 99
Gomes, João Filipe: 104
Gomes, Lúcia: 221
Gomes M., Ana Rita: 353, 666
Gomes, Maira Joao: 334
Gomes, Manuel Ferreira: 468, 526
Gomes, Mariana: 425, 597, 736, 774, 836
Gomes, Marta: 693
Gomes, Ricardo: 170, 173, 214, 659, 900
Gomes, Rita: 314, 315, 417, 867
Gomes, Rodolfo: 183, 835
Gomes, Rodolfo Viríssimo: 210, 564
Gomes, Rosa: 660
Gomes, Sara: 21, 37, 82, 636, 944
Gomes, Sónia: 782
Gomes, Tereza Cabral: 2
Gomes, Tiago T.: 26, 27
Gomes, Vânia: 346, 493, 638
Gómez Antúnez, María: 426, 605, 766, 790, 879
Gómez Huelgas, Ricardo: 422
Gomez, Carmen Cecilia: 752
Gompelman, Michelle: 466
Gonçalves Mendes, André: 118, 222
Gonçalves, Ana: 266, 530, 538, 818, 821
Gonçalves, Ana Maria: 622, 811
Gonçalves, Ana Teresa: 777
Gonçalves, André: 857
Gonçalves, António Maia: 485
Gonçalves, Carla: 920
Gonçalves, Catarina Sousa: 164, 961
Gonçalves, Diana: 18, 541, 666, 808
Gonçalves, Diana Leite: 208, 634
Gonçalves, Elsa: 347
Gonçalves, Ermelinda: 574
Gonçalves, Fernando: 49, 272, 432, 653
Gonçalves, Fernando Martos: 835, 863
Gonçalves, Filipa: 321, 663, 834
Gonçalves, Filipa Sousa: 442, 608
Gonçalves, Filipe: 476, 551, 623, 702
Gonçalves, Francisco: 94, 423, 698, 702, 918
Gonçalves, Gabriela: 218
Gonçalves, Helena: 225
Gonçalves, Inês: 423, 692, 698, 823, 918
Gonçalves, Joana: 189, 713, 776
Gonçalves, João: 183, 564, 666, 846
Gonçalves, João Rocha: 353, 543, 808, 916
Gonçalves, Lino: 94
Gonçalves, Lúcia: 218
Gonçalves, Maria Inês: 665
Gonçalves, Marta Costa: 269, 296, 899
Gonçalves, Nuno: 874
Gonçalves, Nuno Pina: 912, 912
Gonçalves, Rita: 173
Gonçalves, Sérgio: 297, 622
Gonçalves, Sofia: 178, 179
Gonçalves, Sofia Ramos: 177
Gonçalves, Tatiana: 292, 688
Gonçalves, Tiago: 717
Goncharova, Anna Ya.: 194
González Bores, Paula: 447
González Calle, David: 51
González Cantón, Joaquín: 305
González Fernández, Carmen Rosa: 453
Gonzalez García, Andres: 903
González Gutiérrez, Pablo: 564
Gonzalez López, Anunciación: 709
González Martínez, Marta: 447, 450, 453
Gonzalez Molina, Rocio: 841
Gonzalez Niño, Irene: 903
González Pascual, Andrea: 87, 273, 360
González Reimers, Emilio: 301
González-Aragonés, Eduardo: 685
González-Munera, Adriana: 967
González-Navarrete, Lourdes: 901, 944
González-Quintela, Arturo: 340, 342
González-Reimers, Emilio: 901, 944, 973
González-Sánchez, Luis Alonso: 195
González-Torre González, Ana Isabel: 404, 564, 942, 961
González, Florisa: 589
Gonzalez, Laura Virginia: 13
González, Pablo: 267, 268
González, Paula: 238, 408, 488, 955
Gonzalez, Victoria: 98
Gonzalo, María Antonia: 355, 356
Gonzalo, María Antonio: 356
Gor, Shivani: 209
Gordeev, Ivan G.: 83
Gorelik, Oleg: 31
Gorgulho, Ana: 282, 412, 413, 460, 492, 540, 546, 549, 763, 798, 934
Goric, Cleopatra: 537, 772
Gorjão Clara, João: 721
Gorman, Aine: 17, 151
Goteri, Gaia: 830
Goulart, André: 568, 669
Goulart, André Filipe: 225
Goulart, António: 278, 505, 656, 657
Goulart, Inês: 468, 526, 878
Gouveia, Carolina: 354
Gouveia, Claudio Gonçalves: 934
Gouveia, Cristina: 354
Gouveia, Cristina Carvalho: 240, 376, 391
Gouveia, Fabiana: 50, 104, 282, 359, 525
Gouveia, Paulo: 93, 191, 315, 348, 407, 418, 893, 964
Gouveia, Rita: 562

Gouveia, Teresa Vieira: 787
Graça, Carina: 914
Gracia, Antonio: 355, 356
Grácio, Rita: 252, 499, 669
Grácio, Rita Lizardo: 507, 635
Grade, Maria José: 71, 100, 118, 155, 171, 258, 261, 262, 264, 385, 462, 463, 463, 969
Grafia-Perez, Ignacio: 604
Grais, Ana: 458
Gramaça, João: 113, 134, 271, 646
Gramatnice, Alise: 535
Grammenou, Maria-Christina: 465
Granado, Joana: 519
Granados, Julia Gonzalez: 35, 35, 36
Granda Martín, María Jesús: 427, 616
Grandi, Mauro: 336
Granja, Cristina: 115, 181, 274, 449, 811
Grasso, Ernesto: 143, 391, 534
Grau, Josep Maria: 833
Greco, Henrique Ferreira: 968
Greco, Monica: 890
Greenfield, Helena: 116, 173, 180, 202, 257, 289, 426, 477, 541, 568, 591, 971
Grego, Manuela: 136, 186
Gregório, Tiago: 47
Grenha, Inês: 174
Gridneva, Galina: 837
Grilo, Ana: 432, 863
Grilo, Ana Maria: 412, 413, 492, 546
Grilo, Ines: 660
Grilo, Vilma Lais: 510
Grima, Bruno: 364, 839
Grimaldi, Lucia Donatella: 45
Groff, Andrew: 396
Groh, Matthieu: 743
Gromova, Elena: 23
Grosгурin, Olivier: 188
Gruner, Heidi: 275, 374, 387, 487, 532, 552, 721, 729, 730, 890, 891, 895, 920
Guavita Navarro, Diana Katherine: 396
Guavita, Diana Katherine: 940
Gueddich, Nourhoda: 878
Gueddich, Nour: 967
Gueddich, Nour El Houda: 120, 127
Gueddiche, Nour: 861, 862, 882, 883
Guedes, Anabela Malho: 251, 441, 563
Guedes, Carolina: 202
Guedes, Celeste: 697, 932
Guediche, Nour El Houda: 547, 550
Guediche, Nour Elhoda: 887, 888
Guediche, Nourhoda: 470
Guediche, Nourhoda: 921
Guerra, Diana: 70, 147, 158, 262, 346, 625, 689, 696, 785, 799, 873, 874
Guerra, Joaquin: 399
Guerra, Mariana: 353, 545, 920
Guerra, Marisol: 612
Guerra, Paula: 613
Guerra, Sónia: 809, 820, 822
Guerra, Sónia Isabel Silva: 802, 803
Guerra, Sónica: 810
Guerreiro Castro, Sara: 487, 532, 920
Guerreiro, António: 336, 692, 795, 823
Guerreiro, Inês: 615
Guerreiro, Luísa: 96, 676
Guerreiro, Renato: 128, 130, 319
Guerrero Sánchez, Francisca Maria: 554
Gueudry, Julie: 913
Guevara, Elvis: 708, 709, 713
Guevara, Elvis Arias: 746
Guia, José: 128, 130, 240, 390
Guida, Anna: 143, 391, 534
Guil García, María: 422
Guillem Tió, Lluïsa: 252
Guillén-Sacoto, M. Augusta: 238
Guimarães, Filipa: 143
Guimarães, Joana: 233
Guimarães, José Pedro: 49
Guimarães, Luísa: 321
Guimarães, Miguel: 807
Guinmapang, Euodia Padilla: 397
Guiomar, Ana: 278, 808
Guiomar, Verónica Botelho: 203
Gumusel, Ceren: 741
Gunathilake, Roshan: 384
Gupta, Amit: 398
Gupta, Veenu: 304
Gurov, Alexander A.: 101
Gussoni, Gualberto: 707
Gutierrez Cortizo, Eva Nadejda: 305
Gutiérrez Fernández, Laura: 564, 942
Gutiérrez Saborido, Daniel: 703
Gutiérrez Sánchez, María Del Carmen: 271
Gutiérrez-Fernández, Laura: 961
Gutierrez, Ruben Huamanchumo: 708
Guzzardi, Giuseppe: 361
Habor, Adriana: 87
Haddad, Fady: 943
Hadded, Sarra: 979
Haghighi, Eduardo Doutel: 538
Hajji, Haifa: 470
Hajji, Haifa: 878, 921
Halleck, Fabian: 22
Haller-Hester, Dagmar: 1
Halmer, Sarah: 52
Hamdi, Mohamed Salah: 120, 127
Hamrouni, Sara: 854
Hanachi, Sabah: 159, 244, 245, 739

Harada, Yukinori: 947
Hariz, Anis: 120, 127
Harlamov, Alexey: 756
Harzallah, Amel: 979
Hatem, Habib Aimé: 941
Hatton, Maria: 731
Hatzitolios, Apostolos: 158, 465
Haviv, Yosef S.: 557
He, Jianguo: 39
Heijden, Gert-Jan Van Der: 660
Heitor, Susana: 251
Heleniak, Zbigniew: 22
Henriques, Célia: 825
Henriques, Jorge: 99, 375, 657
Henriques, Tatiana: 66, 787, 797
Hernandez Araque, Sara: 63
Hernández Felices, Francisco Javier: 271, 286, 417, 486, 624, 762, 838, 841, 855, 960
Hernández Jiménez, Victoria: 85, 91
Hernández Martínez, Paula: 447, 556, 577
Hernández Murciano, María Carmen: 456, 486
Hernandez Murciano, María Del Carmen: 271, 286, 410, 417, 624, 762, 838, 841, 855, 960
Hernández-León, Carmen Nieves: 901
Hernandez-Quiles, Ruben: 460
Hernández, Astrid Paola: 111, 515
Hernandez, JL: 948
Hernández, José: 355, 356
Hernández, José Manuel: 356
Hernández, Sara: 355, 356, 356
Hernando Martín, Carlos: 422, 475, 958
Hernanz Roman, Lidia: 475
Herrera Abian, María: 724, 725
Herrera Rueda, Guillermo Andrés: 618
Herrera, Guillermo Andrés: 596
Herrmann, François: 39
Hhiorayan, Svitlana: 118
Hidalgo Armayones, Blanca: 305, 777, 792
Hinic, Vladimira: 509
Hipólito-Reis, Ana: 653
Hirosawa, Takanobu: 947
Hirota, Minoru: 19
Hlais, Sani: 582
Ho, Kayleigh Huimin: 482, 730
Hobohm, Lukas: 16, 21, 42, 46, 61, 62, 561
Hodorogea, Andreea Simona: 47, 48
Hofer, Markus: 148
Hojs, Radovan: 2
Holzwanger, Erik: 191
Homem, Rita: 68, 99, 124, 132, 204, 562, 647, 675
Hongyo, Tadashi: 951
Honrado, Teresa: 203
Hooi, Benjamin: 939
Horii, Joichiro: 310
Horta, Alexandra Bayão: 517, 532, 539
Horvath, Eموke: 13
Hořková, Eva: 236, 248
Hoxha, Eneida: 941
Hsieh, Chi-Jeng: 284
Huaman, Carla: 205
Huarte, Álvaro: 97
Huber, Ursula: 148
Huérfino-Castro, Manuel: 877
Iballesteros-Chaves: 909
Iacomini, Paolo: 669
Iakab, Noemi: 87
Iancu, Ovidiu Cosmin: 49, 71
Iglesias Sáenz, Daniel: 387
Iglesias, Violeta: 509
Ikeda, Masae: 19
Ilbay, Ahmet: 396
Ilharco, Marta: 731
Ilievskaa, Dima: 230
Illersberger, Sarah: 22
Imamura, Megumi: 745
Inácio, Hugo: 114, 210, 220, 476, 506, 525, 638, 658, 668, 892
Inácio, Isabel: 233
Iniesta-Pino Alcázar, Ignacio: 271, 286, 410, 417, 456, 486, 624, 762, 838, 841, 855, 960
Insuasty Enríquez, Jesús Solier: 618
Insuasty, Jesus Solier: 596
Iodice, Simona: 86
Iriarte, Adriana: 649
Isabel Teixeira, Ana: 936
Isabel, Ballesteros-Chaves: 450, 451, 910, 911
Isidoro, Rui: 537, 671
Isuz, Mariano: 716
Isvarlal, Pratima: 363
Iuculano, Federica: 347, 357
Ivanova, Catarina: 310, 584
Ivanova, Yulia: 736
Ivanovska Bojadziev, Biljana: 84
Ivanovska, Marika: 939
Ivo, Rita: 200
Izhakian, Shimon: 31
Izquierdo-Sanchez, Laura: 751
Izumi, Manabu: 662
Jacinto, Fernando: 744
Jacinto, Margarida: 184
Jacinto, Nuno: 487, 490, 894, 903
Jacinto, Nuno Boura: 640
Jácome, José: 574
Jain, Rohit: 303, 396
Jakimovska, Jovanka: 230, 939
Janakiram, Antony: 193
Jancar, Nina: 321, 442, 608, 663
Janeiro, Cláudia: 29, 52, 327, 469, 611
Janevska, Dafina: 84

Jaso Tejera, Raquel: 404, 564, 942, 961
Jaspe-Codecido, Alexis: 793
Jaziri, Fatima: 901, 969
Jeannin, Pascale: 739
Jerico, Daniel: 751
Jeridi, Maysam: 163
Jerónimo, Ana: 929
Jesenni Chinchilla, Jesennia: 656
Jesmajian, Stephen: 943
Jesus Pereira, Isabel: 371
Jesus, Claudia: 96
Jesus, Gorete: 648, 661, 691, 824
Jesus, Rafael Geraldo: 440
Jesus, Susana Ramos: 448, 934
Jimenez Alfonso, Andrés Fernando: 447
Jimenez Hinarejos, Isabel: 255, 897
Jiménez, Domingo García: 706
Jiménez, Víctor Rivas: 723
João Gomes, Maria: 126, 310, 582, 609, 621, 631, 642, 959
João, Isabel: 64
Jonet, Marta: 800
Joosten, Anneke: 326, 434, 603
Jordanovski, Lazo: 230, 939
Jordão, Nuno: 544
Jordão, Sofia: 491
Jorge, Catarina: 300, 342, 368, 470, 475, 529, 552, 686, 695, 817
Jorge, Clara: 242, 335, 782, 794, 920
Jorge, Rosa: 152, 314, 595, 648, 766, 910, 945
Jorge, Vanda: 240
Jotkowitz, Alan: 560
Juárez Comboni, Sonia Citlali: 243
Judas, Tiago: 108, 522, 753, 867
Junod Perron, Noëlle: 1
Junqueira, Vânia Mendes: 172, 628
Jurcut, Ruxandra: 116
K, Sri Karpageshwary: 876
Kaaroud, Hayet: 979
Kachan, Bogdan: 620
Kafri, Carlos: 89
Kahn, Jean Emmanuel: 743
Kaiafa, Georgia: 158, 876
Kajikawa, Yutaka: 19
Kakaris, Alexandros: 254, 860
Kalejs, Verners Roberts: 90
Kamer, Carolina: 751
Kamgang, Prochore: 908
Kammoun, Sonia: 969
Kampranis, Dimitrios: 286
Kang, Hyun: 258, 318, 586
Kang, Mei Ling: 719
Kanic, Vojko: 26
Kaniotis, Konstantinos: 445
Kaptanogullari Harmankaya, Ozlem: 741
Karadima, Dimitra: 327
Karadzova, Ana: 84
Karagiozakis, Paschalis: 154, 253, 254, 256, 257, 860
Karamanakos, Anastasios: 838
Karantoni, Eleni: 190
Karasek, David: 230
Karima, Benbarek: 559
Karima, Sifi: 559
Karmani, Monia: 276, 284, 745, 761, 909, 954, 955, 956
Karmeni, Monia: 378, 381, 384, 861
Katsaras, Matthew: 412, 781, 838
Katsaridis, Savvas: 154, 253, 254, 256, 257, 451
Katsiari, Maria: 201, 520
Kavousanaki, Melina: 420, 612
Kawahatsu, Kando: 940
Kayas, Derya: 952
Kazibwe, Josph: 52
Kazidaeva, Elena: 41
Kazineris, Dimitrios: 289, 693
Kebapci, Nur: 269, 270
Kecaj, Irida: 232, 941
Kechaou, Ines: 120, 127
Kefi, Asma: 969
Keller, Karsten: 16, 21, 42, 46, 61, 62, 561
Kenyeres, Peter: 216
Kermiche, Meriem: 772
Kerouaz, Nacera: 245
Keskek, Sakir Ozgur: 15, 580
Khalfallah, Narjess: 120, 127
Khallouf, Loura: 191
Khan, Hiba: 757
Kharrat, Ghada: 537
Kherad, Omar: 188
Khlebnikov, Vladimir A.: 83
Khoury, Johad: 22
Khovasova, Natalia: 383, 389
Kigitovica, Dana: 90
Kim, Beom Jin: 258, 318, 586
Kim, Jae Gyu: 318, 586
Kim, Sang-Jung: 258
Kirichok, Irina V.: 101
Kitouni, Yacine: 772
Klavina, Lizete: 571
Knoch, Anna: 498
Knurowska, Agata: 815
Kochmareva, Elena A.: 83
Kokorin, Valentin A.: 83, 101, 194
Koliaki, Chryssi: 411
Konida, Pigi: 854
Konsta, Maria: 380, 381, 382, 390
Konstantinou, Frosso: 659
Kontopodis, Emmanouil: 612
Kooli, Chakib: 120
Koolo, Chakib: 127
Kopecký, Jan: 236, 248

Koporulina, Marina: 332
Kostakis, Theodoros: 154, 254, 256, 257, 445, 451, 524, 860
Kotov, Sergei: 733
Kotova, Daria: 733
Kotsiari, Christina: 154, 157, 253, 254, 256, 257, 445, 451, 486, 524, 860
Kounouklas, Konstantinos: 190
Koursioupas, Georgios: 536
Kouzis, Panagiotis: 659
Kozak, Oliwia: 815
Kraege, Vanessa: 235, 712
Krause, Ilan: 555
Krel, Cvetka: 2
Krill, Kaleigh: 396
Krygier, Jonathan: 908
Krymov, Eldar: 23
Ksontini, Riadh: 311
Kumar, Vinod: 304
Kunimoto, Naohiko: 745
Kuschner, Pablo: 261, 716
Kuthiah, Navin: 139, 307
Kuzema, Viktorija: 568
L'Angiocola, Paolo Diego: 64
La Boria, Elisa: 712
La Féria, Pedro: 476
La Marca, Antonella: 771
Laajili, Faïda: 882, 883
Laajili, Feida: 861, 882
Laater, Ahmed: 885
Labrador, Nicolas: 389
Lacalzada, Miguel Martínez: 433, 544
Lacerda, António Pais De: 423
Lacerda, Catarina: 784
Lacerda, João F.: 695
Lacor, Patrick: 340, 465
Ladeira, Inês: 405, 807
Ladeira, Katia: 660
Ladó, Ana: 891
Laguzzi, Matias: 3
Lambelho, Ana Rita: 362, 910, 914
Lameiras Xete, Dora: 519
Lameiras, Catarina: 125, 183, 298, 564
Lameiras, Dora: 425
Lamelza, Juan: 3
Lampertico, Pietro: 107
Lampreia, Tânia: 172
Lampropoulos, Christos E.: 327, 380, 381, 382, 390, 436, 437, 606, 854
Landeiro, Luís: 532, 539
Lander, Mark: 724
Langlois, Vincent: 913
Lanier, Cédric: 1
Laouani Kechrid, Chadia: 745
Laouani Kechrid, Chedia: 276, 284, 761, 909
Laouani, Chadia: 378, 956
Laouani, Chedia: 381, 384, 861, 954
Lara-Doblas, Dolores Macarena: 194
Lara, Rafael Aragon: 35, 35, 36
Laranjeira, Álvaro: 14
Laranjinha, Joana: 491
Lasser, Luc: 758
Latorre Asensio, Maite: 577
Lavadinho, Isabel: 118, 222, 350
Lavajo, Ricardo: 926
Lavie, Carl J.: 16
Lavrador, Mariana: 239
Lázaro, Mário: 90, 131, 529, 531, 637, 678, 679, 817
Lazic Golubovic, Tamara: 556
Leal Santos, Marta: 487
Leal, Ana Filipa: 896
Leal, Bárbara: 648
Leal, Dina: 485
Leal, Ema: 532, 552, 891, 920
Leal, Filipa: 62, 157
Leal, Inês: 490
Leal, Mariana: 595, 691
Leal, Mariana Da Silva: 375
Leal, Mariana Silva: 154, 472, 637, 959
Leal, Nuno: 9, 153, 553
Leão Neves, Pedro: 292, 563
Leão, Rodrigo: 633, 634, 804
Leão, Rodrigo Nazário: 25, 29, 29
Leccardi, Stefano: 792
Lecheheb, Rayane: 244
Leclercq, Mathilde: 913
Lee, Chee Woei: 714
Lee, Eun Sun: 586
Leff, Darío: 261, 738
Legakis, Ioannis: 591
Leitão, Ana: 128, 130, 448, 721, 763, 934
Leitão, André: 173
Leitão, Filipa: 537, 671, 772
Leitão, Jorge: 292, 688
Leitão, Sara: 293
Leite, Inês Machado: 357
Leite, Joana: 57, 152, 616
Leite, José: 57, 152, 352, 616, 899
Leite, José Pedro: 208, 541, 634
Leite, Miguel: 114, 525, 638
Leite, Miguel Sousa: 210, 220, 476, 506, 658, 892
Lélis, Manuela: 309
Lemos, Carlos: 299
Lemos, Cláudia: 504, 655, 667
Lemos, Cláudia Isabel Góis: 243
Lemos, Joana: 501, 793
Lemos, José Alberto: 477
Lemos, Luís: 145
Lemos, Marcos: 588

Lemos, Sérgio: 75, 902
Lencastre, Luís: 485
León Téllez, Marta: 718, 958
León, Sandra Bello: 206
Lérias, Graça: 309, 425, 826, 832
Les, Iñigo: 856
Lessa Simões, Mariana: 663, 916
Lessa, José: 222
Leuschner, Pedro: 822
Lighezan, Daniel: 313
Lim, Rachel Wenrui: 714
Lim, Wan Tin: 714
Lima Silva, Ana: 58, 59, 454, 618, 923, 960
Lima, Ana: 688
Lima, Ana Lisa: 96, 603
Lima, Bárbara: 495
Lima, Carla: 75, 902
Lima, Cristina: 633, 634, 804
Lima, Filipa De Castro: 807, 964
Lima, Jandira: 493
Lima, Joana: 805
Lima, Joana C F: 198, 249
Lima, Ricardo: 807
Limão, Rita: 680
Lin, Wender: 4, 284
Lin, XiaoYan: 970
Lino Montenegro, Erick Alfonso: 453
Lito, Pedro: 214, 900
Liu, Patrícia Chow: 308, 370, 660, 966
Livshiz-Riven, Ilana: 31
lladó, Ana: 487, 532, 552, 729, 890, 895, 920
Llamazares Mendo, Cristina: 426, 433, 491, 605, 766, 790, 879
Llambi, Laura: 740
Lleo, Ana: 331, 331, 335
Llinàs Coronado, Esther: 387
Lo Surdo, Alessia: 211
Lobão, Bárbara: 372, 907, 927
Lobao, Madalena: 872, 892
Lobão, Maria João: 111, 492, 546, 570, 718, 971
Lobato, Luísa: 573
Lobo Antuñña, Marta: 791
Lobo-Martins, Soraia: 642
Lohse, Ansgar W.: 325
Lojo Cruz, Cristina: 905
Lojo, Cristina: 8, 149, 150, 303, 328
Lombardi, Rosa: 107, 347, 357
Lomeña Villalobos, Jose Antonio: 422
Lopera Marmol, Carlos: 149, 441
Lopera, Carles: 439
Lopera, Carlos: 435, 604
Lopes Delgado, João: 200, 530
Lopes Morgado, Francisco: 319, 359, 527, 905, 908
Lopes, Ana Isabel: 898
Lopes, Carla: 942
Lopes, Carlos: 423
Lopes, Cristina: 288
Lopes, Denise: 914
Lopes, Emília: 184, 627
Lopes, Inês: 367
Lopes, Inês Felizardo: 68, 124, 544
Lopes, Joana: 132
Lopes, Joana Rita: 92, 275, 287, 915
Lopes, Joanne: 858
Lopes, João: 568
Lopes, João Gamito: 220, 474, 550, 982
Lopes, João Madeira: 129, 569
Lopes, Juliana: 157, 864
Lopes, Kelly: 636
Lopes, Luís: 346
Lopes, Luísa: 189
Lopes, Manuel: 386
Lopes, Margarida: 452, 862
Lopes, Mariana: 543
Lopes, Marta Mendes: 125, 298
Lopes, Miguel: 808
Lopes, Natália: 127, 612
Lopes, Paula: 339, 431, 785
Lopes, Pedro: 533, 619, 864
Lopes, Ramiro: 501, 651, 689
Lopes, Sara: 962, 963
Lopes, Vítor: 332, 755
Lopes, Zélia: 549, 971
López Bernús, Amparo: 434
Lopez Castro, Jose: 722
López Delgado, Laura: 447
López Fernández, Dolores: 85, 91
Lopez Manchado, Juan Francisco: 206
Lopez Reboiro, Manuel: 967
López Ródriguez, María: 345, 479, 963
López-Soto, Alfons: 604
López, Antonio Mateo: 563, 806
López, Cesar Gerardo: 46
López, Jose Antonio Ortiz De Murua: 43
López, José Luis Calleja: 433
Lopez, Laia: 604
López, Rudy: 437, 515
Loureiro, Conceição: 177, 530, 538, 574, 633, 634, 804, 818, 821
Loureiro, Isabel: 688
Loureiro, Luis: 122
Loureiro, Luísa: 629, 760
Loureiro, Maria: 82
Loureiro, Maria José: 121
Lourenço, Célia: 721
Lourenço, Filipa: 275, 532, 552, 729, 890, 891, 895, 920
Lourenço, Filomena: 469
Lourenço, Jorge Vaz: 267, 474
Lourenço, José Manuel: 651
Lourenço, Maria Helena: 826

Lourenço, Patrícia: 615, 858, 866
Lourenço, Sílvia: 169, 169, 170
Louro, Alexandre: 537, 671
Louro, Emília: 697
Louro, Joana: 388, 498, 695, 809, 810
Louro, Marlene: 242, 782
Louro, Ricardo: 971
Lourtau, Gabriela: 3
Louzir, Baasem: 882
Louzir, Bassem: 470, 547, 550, 762, 833, 834, 861, 862, 878, 882, 883, 884, 885, 887, 888, 921, 967
Lozada, Aluixa: 310, 584, 675, 914, 917
Lozano-Loaiza, Eva: 579, 580
Lozano, Jose Fernando: 596
Lu, Huiyan: 714
Lucas, Ana Catarina: 221
Lucas, Filipa: 12, 343, 372, 585, 654
Lugarà, Marina: 143, 391, 534
Luiceanu, Alina Stefania: 48
Luís, Helena: 597
Luís, Helena Freitas: 359, 525, 836
Luís, Manuel Antonio Falar: 970
Lukina, Galina: 831
Lumbreras, Marta: 356
Luna Vela, Fredy Andrés: 229, 394, 395
Luna, Fredy Andrés: 394
Lungu, Tabita: 922
Luque-Amado, Carolina: 579
Luz, Inês: 423
Luzio, José Luiz: 115
Lygoura, Vasiliki: 307
Lymperopoulou, Aggeliki: 316
Lytvyak, Ellina: 325
Lyubavina, Natalia: 736, 775
Macau, Ricardo: 269
Macedo, Mario E.: 26, 27
Machado Neves, Raquel: 929
Machado-Silva, Clara: 92, 565, 702
Machado, Álvaro: 175
Machado, Bela: 588, 597, 836
Machado, Catarina: 419
Machado, Célia: 142
Machado, Filipe: 108
Machado, Filipe J.: 238, 837
Machado, João: 123, 207, 416, 435, 443, 458, 622, 627, 673, 811, 868
Machado, Jorge: 605
Machado, Márcia: 471
Machado, Sara: 935
Machado, Vanessa: 44, 137, 147, 166, 247, 488, 600, 601, 748, 769, 850, 851, 891, 949, 950, 966
Macía-Rodríguez, Cristina: 340, 342, 967
Maciel, Ana Catarina: 560
Maciel, Catarina: 481
Maciel, João: 55
Maciel, Rita: 238
Madaleno, João: 351
Madeira, Daniela: 401, 580
Madeira, Margarida: 132, 136, 228, 677, 699
Madeira, Margarida Lopes: 372, 393, 907, 927, 983
Madonna, Pasquale: 143, 391, 534
Madrid, Víctor: 408, 774
Madruga, Isabel: 200, 309, 418, 425, 444, 530, 826, 832, 946
Madruga, Jose Ignacio: 800
Madureira, Eugénia: 57, 208, 323, 330, 414, 478, 588, 782
Madureira, Luís: 923
Maese Rufino, Pedro J: 379
Maese, Pedro J.: 8
Maestre Orozco, Tamara: 447
Maffi, Gabriele: 357
Magalhães, Denise: 289, 426, 650, 671, 822, 971
Magalhães, Eunice: 776, 777, 796
Magalhães, Fernando: 446
Magalhães, Helena: 615
Magalhães, Juliana: 366, 442, 608, 856
Magalhães, Luis: 573
Magalhães, Manuel: 591
Magalhães, Mariana: 388
Magalhães, Mariana L. S.: 498
Magalhães, Miriam: 440, 562, 930
Magallanes, Leonardo Valente: 738
Magno Pereira, Vítor: 309
Magno, Sara: 123, 627, 673
Magueja, Carla: 721
Mahdi, Ahmad Thaer: 161, 872
Mahillo Fernández, Ignacio: 791
Maia Alves, Nuno Rodrigo: 358
Maia Santos, Lília: 786
Maia, Ana Maria: 279
Maia, André: 560, 728, 966, 980
Maia, Lilian: 263, 333, 951
Maia, Maria: 266, 272, 386
Maia, Maria De Araújo Barros: 160
Maia, Paulo: 288
Maia, Raquel: 839
Maia, Rosana: 147, 158, 262, 346, 785, 799
Maio, Cláudia: 58, 947
Maissa, Thabet: 378
Majob, Maria: 11
Major, Marinela: 344, 435, 443, 458, 674
Makaritsis, Konstantinos P.: 446, 843
Makarova, Ekaterina: 736, 775
Make, Kristine: 90
Mako, Katalin: 13
Makridou, Elisavet: 154, 253, 254, 256, 257
Makulin, Yauheni: 847
Malakhov, Konstantin Yu.: 101
Malakhov, Vladimir V.: 101

Maldonado, Isabel: 220, 521, 542, 701
Malesci, Alberto: 400
Malheiro, Filipa: 517
Malheiro, Joana: 5
Malheiro, Mariana: 569
Malheiro, Rui: 633, 872, 884
Malimon, Valentin V.: 83
Mallela, Venkata Ramana: 336
Malliarou, Eugenia: 411
Mallik, Ritwika: 209
Maltês, Sérgio: 68, 124, 128
Maltez, Fernando: 438, 457, 796
Malyarchuk, Viktor: 99, 375, 657, 801
Mamfrim, Rafaela: 453, 504, 753, 863, 898, 900
Mana, Fazia: 333, 465
Manata, Maria José: 457, 796
Manata, Pedro: 140, 458, 584
Mancuso, Yanina: 3
Mandal, Chirantan: 555
Mané, Fernando: 30, 498
Manfredi, Giulia Francesca: 361
Manfredini, Roberto: 9, 10
Manique, Inês: 669
Mann, Theresa: 724
Mano, Diana: 227
Manolev, Aleksandar: 84
Manrique Pérez, Juan Miguel: 406, 434
Mansilla Rodríguez, María Elena: 305, 371, 757, 777, 792
Mansinho, Kamal: 519
Manso, Helena: 387, 729, 730
Mantella Gorosito, Daniela: 3
Mantoan, Giorgio: 79, 86
Manuel Gonçalves, Inês: 700
Manuel Sanchez, Luis: 359
Manuel, Micaela: 593
Manuppelli, Vincenzo: 771
Manzoli, Lamberto: 10
Marado, Daniela: 543, 545
Maranduca, Minela Aida: 69, 205
Maranhas, Mariana: 910
Marçal, Rita: 218
Marcão, Isabel: 186
Marcelo-Ayala, Almudena: 560
Marchetti, Annalisa: 216
Marchiani, Costanza: 56, 843
Marçoa, Raquel: 807
Mares, Stepan: 82
Margalit, Ili: 555
Mari, Anna: 190
Maria, Bernardo: 621
Mariano, Gilda: 229
Marin Laut, Miguel: 554
Marín, Patricia Rubio: 246, 246
Marinheiro, Maria Rosário: 677
Marinho, Ana Vera: 115
Marinho, Ricardo: 122
Marini, Carmine: 198
Mariz, José: 217, 347, 906, 971
Marmolejo, Miguel Angel Sánchez: 728
Marote, Graça: 506
Marote, Sara: 609
Marouço, Catarina: 552
Marouene, Omar: 378
Marques Afonso, Ana Teresa: 151, 345, 479, 963
Marques De Sousa, Susana: 168, 620, 805, 865, 951
Marques Loureiro, Luís: 297
Marques Osorio, Rui: 392, 870
Marques-Vidal, Pedro: 69, 235
Marques, Ana: 64, 65, 95
Marques, Anabela: 934
Marques, Carlos: 526
Marques, Catarina: 875
Marques, Cristina: 620, 865
Marques, Cristina Moreira: 221, 369, 443, 516
Marques, Filipa: 128, 130
Marques, Herlander: 614, 638, 652, 700
Marques, Isabel: 407
Marques, Joana: 432
Marques, Joana Isabel: 863
Marques, Jorge: 30, 55, 447, 614
Marques, José: 92, 181, 565, 635, 702, 921
Marques, José Cunha: 197, 674, 747
Marques, José Da Cunha: 363, 365
Marques, Luísa Pina: 688, 906
Marques, Maria Inês: 596, 746
Marques, Marta: 953
Marques, Marta Rafael: 25, 190, 620, 805, 865, 951
Marques, Nadielli Carolina: 578
Marques, Paula: 127, 612
Marques, Pedro Madeira: 538, 682
Marques, Ricardo: 741
Marques, Roberto: 292
Marques, Roberto Calças: 251, 441, 563, 770
Marques, Rui: 260, 775
Marques, Salomé: 184, 456, 476, 621, 627
Marques, Susana: 132, 248, 369, 686, 699, 971
Marques, Tiago: 325
Marques, Torcato: 871
Marques, Vasco: 218
Marra, Alberto: 216
Marrero-Medina, Iván: 78
Marsala, Elisa: 86
Martín Casado, Manuel: 91
Martín Cascón, Ana: 271, 286, 410, 417, 456, 486, 624, 762, 838, 841, 855, 960
Martín Escudero, Juan Carlos: 373, 705
Martín González, María Candelaria: 301
Martín Higuera, Ester: 491

Martín Jiménez, Antonio: 495
Martín Pérez, Antonio José: 720
Martín Pérez, Magdalena: 379, 642, 750
Martín Salas, Carmen: 428, 429
Martín Zamorano, Marina: 703
Martín-Abreu, Carla María: 901, 944
Martín-Castillo, Antonio: 194
Martín-González, Candelaria: 107, 901, 944, 973
Martín-Ponce, Esther: 107, 973
Martín, Ana Isabel Rodrigo: 73
Martín, Cristina: 774
Martín, Daniel: 967
Martín, Sandra: 10, 11, 594
Martinelli, Elisa: 237, 843
Martínez Cánovas, Caridad Beatriz: 456, 486
Martínez Cánovas, Elena Del Carmen: 271, 286, 410, 417, 456, 486, 624, 762, 838, 841, 855, 960
Martínez Cánovas, María Josefa: 456
Martínez Cánovas, María Josefa: 486
Martínez Chinchilla, Juan: 554
Martínez De Las Cuevas, Gonzalo: 267, 268, 556, 577
Martínez De Viegol Agrafojo, Estefanía: 72, 469, 703
Martínez Hernández, Indra: 456, 486
Martínez La Calzada, Miguel: 903
Martínez Martínez, Daniel: 301
Martínez Martínez, Mónica: 271, 286, 410, 417, 486, 624, 762, 838, 841, 855, 960
Martínez Moreno, Nathalia Andrea: 618
Martínez Prado, Rodrigo: 918
Martínez Torrón, Alba María: 404
Martínez-Riera, Antonio: 107
Martínez, Elena Bello: 54
Martínez, Rodrigo: 707
Martinho, Teresa: 498, 695
Martinkova, Dominika: 427
Martins Do Vale, Francisco: 632
Martins Fernandes, Rita: 181, 274, 342, 392, 475, 686, 870
Martins Natal, Rebeca: 98, 505, 815
Martins Neves, Ana: 821
Martins-Mendes, Daniela: 496
Martins, Alexandra: 131
Martins, Alfredo: 822
Martins, Ana: 144
Martins, Ana Cristina: 278, 666
Martins, André Mendes: 357
Martins, Catarina: 423
Martins, Cláudia: 932, 935
Martins, Cristina: 18, 188, 308, 634
Martins, Fernanda: 271, 646
Martins, Francisca: 872
Martins, Francisca: 165, 502, 565, 609, 633, 884
Martins, Frederico Rajão: 770, 921
Martins, Hélia: 19, 140, 189
Martins, Hélio: 694, 850, 926, 931
Martins, Isabel: 860
Martins, Joana: 143, 671
Martins, Joana Rosa: 468, 526, 878
Martins, João: 150, 431
Martins, José: 534, 980
Martins, José João: 112, 461
Martins, Manuel Serrano: 519, 816
Martins, Mariana Ramos: 673
Martins, Marta Braga: 493
Martins, Marta Dalila: 155, 201, 789
Martins, Miguel: 609, 633, 884, 911
Martins, Patricia: 924
Martins, Paulo: 115, 225
Martins, Rita Tourais: 538
Martins, Rute: 192
Martins, Sara: 510, 776, 777, 796
Martins, Sara Raquel Pereira: 122, 490, 822
Martins, Sofia Costa: 868
Martins, Sónia: 386
Martins, Teresa: 457
Martins, Vítor: 8, 14
Martins, Yolanda: 108
Marto, Daniela: 114, 210, 220, 457, 476, 506, 525, 638, 658, 892
Marto, João Pedro: 171
Marton, Zsolt: 216
Martynov, Stanislav: 736
Mascarenhas, Joana: 845
Mascarenhas, Mário Rui: 288
Masood, Sadia: 737
Masotti, Michela: 712
Masrabaci, Yavuz: 279
Massano, Ana: 881
Massas, Margarida: 74, 97, 169, 170, 405, 587
Masuda, Kaihei: 462
Masuda, Mikako: 947
Matas, Ana: 833
Mateo González, Jose Ignacio: 404
Mateo Mosquera, Lara: 479
Mateo Mosquera, Lara Maria: 345, 963
Mateus, Ana Bela: 234, 821
Mateus, Catarina: 319
Mateus, Estela: 613
Mateus, José Eduardo: 60, 417, 592
Mateus, Sofia: 93, 114, 476, 525, 658, 892
Mateus, Sofia Mahomed: 210, 220, 506, 638
Matias, Carla: 637
Matias, Margarida: 145
Mato Jimeno, Víctor: 270, 427, 430
Mato, Víctor: 602, 870
Matos Costa, João: 458
Matos Gonçalves, André: 153
Matos, Ana Filipa: 361, 974, 975
Matos, Ana Sofia: 70, 696, 873, 874
Matos, Ana Sofia Costa: 346, 755

Matos, André Rebelo: 186
Matos, Andreia: 20, 31, 32, 35, 40, 56, 814, 936
Matos, César: 260
Matos, César Ricardo Coimbra De: 775
Matos, Maria Inês: 80, 182
Matos, Óscar: 537, 620
Matos, Tânia: 696
Matsuda, Josie Budag: 751
Matteucci, Luca: 378
Mattia, Bellan: 841
Maurandi, Javier Bernal: 433
Mauri Plana, Montserrat: 149
Mauri, Montserrat: 435, 604
Maurício, Joana: 68, 124, 180, 251, 276
Maury, Inês Pintado: 490
Mavras, Georgios: 854
Mawani, Minaz: 737
Mayet, Ahmed: 397
Mayor, Joana Sotto: 89, 508, 661
Mazariegos Cano, Joel Andrés: 447, 450, 453
Mazeda, Carolina: 913, 929, 933
Mazurkiewicz, Géry: 739
Mcneil, Susan: 384
Mean, Marie: 235
Medeiros, Catarina: 82
Medeiros, Catarina Fernandes: 881
Medeiros, Mariana: 530, 538
Medeiros, Paulo: 30, 55, 323, 447, 614
Medeiros, Paulo Duarte: 72, 461
Medeiros, Rita: 299
Medeiros, Teresa: 603
Medici, Francesco: 209
Medina Varo, Fermin: 895
Medrano, María José Díez: 206
Meier-Willersen, Hans-Jörg: 922
Meijide Rodríguez, Lucía: 518, 798
Meijide, Lucía: 746, 962
Meilande, Kitija: 90
Meireles, Daniela: 99, 129, 242, 272, 298, 313, 571, 657, 779, 842, 894
Meireles, Elsa: 574, 688, 906, 919
Meireles, José Moura: 264, 339, 877
Meireles, Pedro: 165, 936, 976, 978
Meireles, Pedro Antunes: 129
Meireles, Ricardo: 376
Melandri, Serena: 214, 768, 816
Melchio, Remo: 792
Melenovský, Vojtech: 236, 248
Melero-Martín, María Rosa: 560
Melguizo Moya, Isabel: 379, 905
Melguizo, Isabel: 8, 303
Meli, Rossella: 331
Melita, Catarina: 123, 673
Melnikov, Aleksandr: 41
Melo Valadão, Ivone: 859
Melo, Ana Teresa: 260
Melo, Carla: 617, 932, 947
Melo, João Daniel: 808
Melo, Luis: 19
Melo, Nuno: 590, 654
Melo, Priscila: 498
Mena, Ana Roldán: 723
Mendes, Adriano Pacheco: 118, 222, 350, 410
Mendes, Aline: 39
Mendes, Ana D.: 717
Mendes, André: 350, 410
Mendes, Bruno: 336, 611, 692, 795, 823
Mendes, Fernanda: 109
Mendes, Gonçalo: 132, 228, 393, 677, 699, 983
Mendes, Gonçalo Amaral: 372, 907, 927
Mendes, Inês: 106
Mendes, João: 290
Mendes, Marina: 619, 789, 864
Mendes, Marina Henriques: 533
Mendes, Marta Filipa Lemos: 497, 652, 698
Mendes, Orlando: 577, 598
Mendes, Rita: 666, 755
Mendes, Sofia: 875
Mendes, Teresa: 619
Mendes, Teresa Martins: 549, 789, 896
Mendes, Tiago: 156, 237, 812
Mendes, Vítor: 203
Mendonça, Alexandre: 190
Mendonça, Augusto: 350
Mendonça, Catarina: 125, 689, 756
Mendonça, Flávio Moniz: 156
Mendonça, Joana: 866
Mendonça, Pedro: 297
Mendonça, Teresa: 844, 888
Meneses, João: 129, 165, 976, 978
Meneses, Madalena: 293, 694
Menezes Pina, Sérgio: 756
Menezes, Maria: 278, 505, 656, 657
Menezes, Maria Bairos: 514
Menkov, Nikolay: 775
Mera, Eva: 377
Mercatelli, Paolo: 843
Mercer, Michael: 731
Merino-Lucas, Esperanza: 460
Merlaoui, Rayane: 244
Mertens, Rembert: 340
Mesecko, Veronika: 568
Mesquita, Alexandra: 681
Mesquita, Ana: 223
Mesquita, Anabela: 485
Mesquita, António: 633, 884
Mesquita, António Epifânio: 165, 858
Mesquita, Bruno: 612

Mesquita, Gonçalo: 321, 713
Mesquita, Gonçalo R.: 263, 333, 660
Mesquita, Inês B.: 799
Mesquita, Inês Batista: 285
Mesquita, Márcio: 742
Mesquita, Margarida: 181
Mesquita, Mari: 62, 155, 157, 201, 533, 549, 789, 896
Mesquita, Mónica: 126
Mesquita, Pedro: 327
Mesquita, Pedro Duarte: 52, 611
Mesquita, Raquel: 52, 327, 611
Mesquita, Teresa: 32, 171
Messias, António: 105, 183, 210, 564
Mestre, Ana: 79, 365
Mestre, Ana Cristiina: 691
Mestre, Ana Cristina: 924
Metoui, Dr Leila: 878, 921
Metoui, Leila: 470, 547, 550, 762, 833, 834, 861, 862, 882, 882, 883, 884, 885, 885, 967
Meuwissen, Annelies: 340
Midões, Carolina: 690
Migdalia, Asimina: 154, 157, 253, 254, 256, 257, 445, 451, 524, 860
Migliore, Elena: 792
Miguel, Arderius: 924
Miguel, Silvina: 805
Míguez Rey, Enrique: 499
Mihailovic, Tatjana: 368, 695
Mihon, Cláudia: 487, 568
Miján Caño, Paula: 195
Miján-Caño, Paula: 194
Milani, Olivia: 84
Milho, Joana: 362, 362, 910, 914
Milione, Hugo: 3
Milisenda, Jose César: 833
Miljkovic, Lidija: 939
Millán, Henry Augusto: 229, 394, 394, 394, 395, 395
Milonas, Dimitrios: 465
Milosevska Evrushoska, Despina: 230
Milyutina, Marina: 736
Minacapilli Manetti, Mauricio Luis: 740
Mineiro, Alexandra: 336, 795
Minerva, Francesco: 377, 749
Mingo, Amparo: 342, 475
Minguez Picasso, Marta: 273
Minisini, Rosalba: 311, 336
Miozzari, Hermès: 733
Mira Escarti, José Antonio: 139, 379
Mira-Escarti, Jose Antonio: 905
Mira, Jose Antonio: 8, 303
Mira, José Manuel: 408
Miragaia, Adélia: 354
Miranda, Gonçalo: 665
Miranda, Irene: 147, 785
Miranda, Marisa: 115
Miranda, Olinda: 59, 551, 553
Miranda, Olinda Lima: 623, 702
Miranda, Rubina: 798, 928
Miri, Sirine: 547, 550
Mirzaei, Masoud: 235
Mita, Tomohiro: 940
Mitrakos, Ioannis: 854
Mitsos, Aristotelis P.: 446
Mlikova Seidlerova, Jitka: 82
Moça, Rita: 590
Mocanu, Liliana: 302
Moço Coutinho, Ricardo: 674
Môço, Rui: 257, 649, 653, 672
Modesto Dos Santos, Joao Luis: 428, 429, 848
Moffa, Iginio Fusco: 64
Moga Lozano, Silvia: 422
Moggi Pignone, Alberto: 56, 843
Mogi, Yuhei: 199
Mogildea, Mihail: 925, 936
Mohammad, Ausaf: 17, 151
Moita, Filipa: 624
Moitinho, Marta: 476, 658, 892
Mokni, Sana: 761, 765, 769
Moleiro, Filipa: 96
Molina Llorente, Helena: 447, 450, 453
Molina-Molina, Emilio: 326, 377
Molinos, Elena: 869
Molins, Marta: 433
Mollagiousoufoglou, Berkay: 154, 253, 256, 257, 451, 524, 860
Mollagiousoyoglou, Berkay: 254
Molnar, Tihamer: 216
Mondragão, Ana: 343
Monge Monge, Daniel: 918
Monllor-Méndez, Jesús: 194, 195
Montañas Guimera, M^a Del Carmen: 668, 670
Montano-Loza, Aldo J.: 325
Montaño, Adrian: 967
Montano, Nicola: 79, 84, 86
Monte Faissol, Natalia: 747
Monteiro Ferreira, Inês: 458
Monteiro, Ana: 143, 501, 651, 752
Monteiro, Ana Margarida: 130, 545
Monteiro, Ana Oliveira: 840, 896
Monteiro, Catarina: 225
Monteiro, Cristina: 288
Monteiro, Joana: 491
Monteiro, Joana Raquel: 352, 899
Monteiro, José João: 49
Monteiro, Manuel: 714
Monteiro, Margarida: 164, 512, 517, 539, 683
Monteiro, Margarida Brito: 495, 599, 800
Monteiro, Maria José: 5
Monteiro, Mário: 144, 479, 946

Monteiro, Nadine: 96
Monteiro, Nuno: 506
Monteiro, Regina: 807
Monteiro, Renata Oliveira: 531
Monteiro, Rita: 177, 574
Monteiro, Rita Lencastre: 530, 538, 633, 634, 804, 818, 821
Monteiro, Rodrigo: 192
Monteiro, Rosário: 797
Monteiro, Silvia: 94
Monteiro, Sofia: 328
Montenegro Puche, Beatriz Elena: 495
Montenegro, Carlos: 502
Montero Alonso, Marta: 467, 467
Montero, A: 948
Montes De Oca Arjona, Montserrat: 554
Monti, Alice: 79, 84, 86
Monti, Manuel: 64
Monti, Matteo: 712
Montouri, Aniello: 900
Montoya Valdés, Jonathan: 479
Montoya Valdés, Jonathan Geovany: 151, 345, 963
Montrucchio, Giuseppe: 27, 593
Mora, Carmen: 953
Mora, Juan: 668, 670
Moradi, Behnam: 19, 140, 234, 250
Moraes-Fontes, Maria Francisca: 890, 891, 895
Moraes, Rodrigo: 344, 674
Moragón Ledesma, Sergio: 48, 430, 845
Moragón, Sergio: 602
Morais, Anabela: 728
Morais, Catarina: 568
Morais, Joana: 93, 191, 348, 407, 893, 964, 966
Morais, Joana Sousa: 315, 418
Morais, João: 19
Morais, Juvenal: 278, 505, 656, 657
Morais, Luís Maia: 763, 934
Morais, Manuel: 202
Morais, Maria Céu: 929, 933
Morais, Rui: 128
Morais, Sandra Alves: 308, 370, 966
Morales, Máximo miguelez: 416
Morales, Montserrat: 751
Morán Castaño, Claudia: 798
Morán, Claudia: 962
Morata, Carmen: 73, 322
Moreira Marques, Torcato: 430, 522, 527
Moreira-Silva, Sofia: 603, 898
Moreira, Albina: 175, 361, 972
Moreira, Ana Sofia: 113, 125
Moreira, Ana Teresa: 358, 480
Moreira, Cecília: 162
Moreira, Cláudia: 819
Moreira, Elisa: 534, 980
Moreira, Inês: 143, 605, 814, 869
Moreira, José Ilídio: 49
Moreira, Marta: 158, 262, 799
Moreira, Marta Andrade: 346
Moreira, Marta Isabel: 696
Moreira, Pedro: 859
Moreira, Sónia Bastos: 531
Moreira, Susana: 423
Morelli, Paola: 398, 436
Moreno Lucente, Isabel: 20, 402, 404, 477
Moreno-Gonzalez, Rafael: 37
Moreno, Javier: 967
Moreno, José: 925, 936
Moreno, María Pavón: 206
Moreno, Nuno: 55
Morgado, Gonçalo: 121
Morgado, José: 442
Morgado, Miguel: 754
Morganho, Armando: 179
Mori, Fabio: 56
Morinaga, Kohei: 947
Morlacchi, Letizia Corinna: 86
Morna, Carolina: 240, 425, 464, 597, 774, 874, 912, 958
Moroz, Viktoriya: 383, 389
Mortágua, Juliana: 217, 765
Mos, Liana Mioara: 377
Mosca, Ana Margarida: 112, 461
Moschou, Despoina: 659
Moscovici, Khen: 89
Moser, Stephan: 509
Mossel, Eric: 326
Mota, Ana Marta: 196
Mota, Ângela: 935
Mota, Catarina: 165, 936, 976, 978
Mota, Joana: 278, 656, 657
Mota, João: 221
Mota, Margarida: 192, 415, 553
Mota, Pedro: 81
Moteli, Daniela Adina: 49, 71
Moudatir, Mina: 829
Mounia, Elleuch: 901
Moura, Ana: 136
Moura, Ana Rita: 8, 14, 14
Moura, António: 501, 651, 689
Moura, António Veiga: 251, 441, 756, 925, 936
Moura, Diana: 23
Moura, José Pereira: 104, 600
Moura, Miguel: 685
Moura, Pedro: 214
Moura, Sofia: 364, 523
Moura, Teresa Souto: 115, 732
Mourão Carvalho, Nuno: 181
Mourisco, Mafalda: 688, 919
Mournoval Morales, Letizia Marie Silvie: 20
Mouro, Margarida: 144, 595

Moussiegt, Aurore: 743
Moutinho-Pereira, Sara: 929
Moutinho, Adelaide: 446, 614
Móz, Miguel: 49
Mrouki, Maroua: 81, 163, 248, 607, 609, 854, 858, 886
Muglia, Riccardo: 335
Muharremi, Shkelqim: 84
Muiña-Juárez, Begoña Soledad: 420, 421
Muiño Míguez, Antonio: 426, 766, 790
Mukhametova, Diliara: 332
Mula Falcón, Francisco: 139
Mulas, Violante: 336
Muller, Romain: 743
Muñoz Mendoza, Vanesa: 20, 402, 477
Muñoz, Candido: 967
Muñoz, Fabiana Santos: 673
Muñoz, Sara: 408, 774
Muntean, Mihaela: 313
Munteanu, Madalina Andreea: 102
Münzel, Thomas: 16, 42, 61, 62, 561
Murdaca, Giuseppe: 890
Muri, Thaddäus: 231
Murteira, Fábio: 553
Musa, Reem: 256
Mylona, Maria: 411, 412, 591, 781, 838
Mzabi, Anis: 378, 745, 761
Nabais, Inês: 68, 124, 128
Nadal Marti, Catalina Maria: 759
Naia, Leonor: 58, 152, 615, 766
Nakagawa, Urara: 745
Nanea, Ioan Tiberiu: 47, 48
Napato, Agostinho: 452
Naranjo-Millán, Julián: 877
Naranjo-Millán, Julián Alberto: 752
Naranjo, Julian Alberto: 399
Naranjo, Sócrates: 821
Naranjo, Sócrates Vargas: 234, 350
Narciso, Marco: 135
Narciso, Marco Ribeiro: 202
Nardini, Camilla: 404
Narro, Alicia: 856
Nascimento Fernandes, Alexandre: 460, 798
Nascimento, Ana: 70, 755, 873, 874
Nascimento, Bruna: 337, 338, 623
Nascimento, Joana: 407, 468
Nascimento, Margarida L.: 517
Nascimento, Paula: 430, 522, 527, 871
Nascimento, Rafael: 50, 104, 359, 662, 663, 798
Nashashibi, Jeries: 22
Nashi, Norshima: 939
Nasir, Noreen: 737
Natário, Ana: 699
Naumov, Anton: 383, 389
Navarro Puerto, M^a Asunción: 379, 905
Navarro-Castro, Antonio Miguel: 420, 421
Navarro, Beatriz: 213, 274, 473, 682
Navarro, Margarita: 584
Nazário Marouço, Catarina: 532, 920
Nechita Ferreira, Monica: 354, 748, 758
Nechita, Mariana Irina: 558
Neder, Rafael: 753
Negredo, Ana Isabel: 415
Negri, Luciano: 553
Negrini, Simone: 890
Nelaj, Ergita: 232
Nemeth, Almos: 216
Neogi, Subhasis: 555
Nery, Filipe: 977
Neto, Ana: 60, 200
Neto, Catarina Moreira: 675, 914, 917
Neto, Catarina Teles: 183, 688
Neto, Daniela: 184, 456, 476, 621, 627
Neto, Diana: 136, 228
Neto, Ema: 742
Neto, Isabel Galriça: 731
Neto, Manuela: 523, 524, 529
Neto, Margarida: 599, 775
Neto, Pedro: 648
Neto, Raul: 185, 652, 824
Neves, Ana: 222, 350, 410
Neves, Clarinda: 152, 314, 945
Neves, Clarisse: 184, 627, 866
Neves, Clarisse Coelho: 409
Neves, Joana: 894
Neves, João: 122, 822
Neves, Maria Conceição: 507
Neves, Marisa: 414, 839
Neves, Nuno Maia: 532, 539
Neves, Vasco: 97, 98, 169, 170, 505, 514, 598
Neves, Vasco Pinto: 665
Neves, Zélia: 123, 207, 673, 868
Nguyen, Luan: 771
Nicolae, Camelia: 102
Nicolau, Sara: 186, 535
Niculescu, Costin: 302
Niculescu, Zizi: 302, 324, 780, 786
Nieto Martinez, Sara: 556
Nikitin, Igor Gennadievich: 771
Nikolovska, Emilija: 84
Nin, Michihiro: 947
Nishiguchi, Sho: 511
Nistor, Ancuta: 883
Nitti, Cinzia: 216
Nobili, Lorenzo: 216
Nobre, Alexandre: 544
Nobre, Carla: 21
Nobre, Fernando: 544
Nóbrega, Catarina: 240, 736, 928

Nóbrega, Catarina Sofia Martins: 195, 196, 846
Nóbrega, José Júlio: 196
Nóbrega, Ranyére Silva: 528
Nogueira-Silva, Luís: 92, 182, 565
Nogueira, Ana Rita: 592
Nogueira, Carla: 779, 807
Nogueira, Fernando: 92, 181, 197, 565, 702, 747, 921
Nogueira, Fernando Miranda: 363, 365
Nogueira, Luís: 62, 157
Nogueira, Renato: 697, 923
Nogueira, Rui: 543, 916
Nogueiras Álvarez, Rita: 404
Noniashvili, Marina: 78
Nordin, Rafic: 721
Noreña, Iván: 394, 395, 399, 752
Noreña, Iván Enrique: 394
Noronha, Carla: 847
Noronha, Duarte: 179
Nortadas, Rita: 596, 708, 709, 713, 746
Nouira, Rafia: 761, 765, 769
Noureddine, Abadi: 559
Nouri, Nassim: 739
Novack, Victor: 89, 557
Novais, António: 721
Novo Veleiro, Ignacio: 151, 345, 479, 963
Novoselova, Anastasia: 43
Ntorlis, Kyriakos: 138, 520
Nunes, Ana: 454, 594
Nunes, Ana Luísa: 120, 493
Nunes, Carla: 386
Nunes, Filipa: 344, 443, 458, 674
Nunes, Francisco: 700
Nunes, Inês: 184, 953
Nunes, João Silva: 440
Nunes, Lisete: 982
Nunes, Margarida Pimentel: 91, 93, 167, 224
Nunes, Miguel: 502, 565, 633
Nunes, Sílvia: 471
Nunes, Sofia: 144
Nunes, Tomás: 94
Nuñez, Virginia: 740
Nuzzo, Marina: 377
Nzwalo, Hipólito: 282
Oberti, Giovanna: 107
Oblitas Béjar, Fireli: 387
Oblitas, Crhistian: 428, 560
Odintsova, Alfiya: 332, 919
Odzak, Andrea: 261
Offiah, Gregory: 17, 151
Ogando, Ana: 221, 369, 443
Ogbac, Frederick Elises: 397
Ogbac, Martin Kristoffer Elises: 397
Okabe, Taro: 662
Olavarría, Gustavo De Campos: 968
Olgado, Maria José Ruiz: 102
Oliva, Gabriella: 143, 391, 534
Olivari, Diletta: 830, 830
Oliveira E Silva, António: 112, 346, 461, 508, 638, 661
Oliveira Monteiro, Pedro: 182
Oliveira Silva, António: 89, 348, 493, 512, 672, 700, 893, 964
Oliveira, Ana: 182, 241, 365, 625, 910
Oliveira, Ana Alves: 691, 923, 924
Oliveira, Ana Andrade: 315, 407
Oliveira, Ana Isabel: 294, 348, 454, 594, 676
Oliveira, Ana Maria: 122, 822
Oliveira, Ana Rocha: 154, 637, 959
Oliveira, António Manuel Rosa: 243
Oliveira, Bárbara Fontes: 819
Oliveira, Camila: 698, 918
Oliveira, Carlos: 221, 369, 443, 516, 693, 832
Oliveira, Carolina Soares: 925, 936
Oliveira, Catarina V.: 667
Oliveira, Cátia: 30
Oliveira, Cátia Costa: 55, 447, 614
Oliveira, Diana Martins: 953
Oliveira, Eunice: 653
Oliveira, Eurico: 804, 915
Oliveira, Hugo: 605
Oliveira, Inês: 60, 200, 682
Oliveira, Iolanda: 232, 291, 405, 558, 587
Oliveira, Isabel Andrade: 418
Oliveira, Isménia: 266, 272, 643, 653
Oliveira, Jaime: 866
Oliveira, João Fonseca: 502
Oliveira, Liliana: 238
Oliveira, Margarida: 902
Oliveira, Mariana: 607
Oliveira, Marta: 945
Oliveira, Miguel: 902
Oliveira, Narciso: 72, 323, 461, 494, 498, 849
Oliveira, Natália: 44, 137, 147, 166, 247, 488, 600, 601, 748, 769, 850, 851, 891, 949, 950, 966
Oliveira, Nídia: 491, 650, 793, 868
Oliveira, Nidia Alexandra: 501
Oliveira, Pedro: 553
Oliveira, Rafael: 695, 701
Oliveira, Ricardo: 741
Oliveira, Ricardo Paquete: 364
Oliveira, Rita: 647
Oliveira, Soraia: 214
Oliveira, Susana: 825
Oliveira, Tatiana: 343
Onofras, Elena-Daniela: 205
Onwuteaka, Obinna Kevin Kenechukwu: 349
Oo, Than Zaw: 406, 714
Orantos, Marta Guisado: 337, 338, 623
Orbe, G: 948
Ordieres Ortega, Lucía: 48, 259, 457, 616, 793, 803

Oriente-Frutos, Laura: 195
Orlando, Gabriel: 957
Ormaechea, Gabriela: 63
Ornelas, Énia: 125, 298
Orsi, Emanuela: 357
Ortigão, Raquel: 650
Ortiz Carrera, Jon: 322
Ortiz Flores, Fernando: 577
Ortiz Llauradó, Gemma: 387
Ortiz, Alicia Laso: 563, 806
Ortiz, Gemma: 967
Ortiz, Jon: 73
Osman, Hartini Bte: 714
Osório De Castro, Adriana: 747
Osório, Rui: 113, 115, 125, 342, 475, 686, 689, 756
Ostad, Mir Abolfazl: 61, 62
Ostapiuk, Ivanna: 480, 577, 598, 905, 908
Osthoff, Michael: 509
Osuna Sánchez, Julio: 17, 233, 375
Otero Anton, Esteban: 342
Otero, Esteban: 340
Otero, Miriam: 3
Ozísik, Lale: 483
P. Ferro, Ana: 96
Pablos, Jose Luis: 474
Pacheco, Adriano: 234
Pacheco, Ana Ferreira: 549
Pacheco, Márcia: 914
Pacheco, Maria: 358, 480
Pacheco, Maria Helena: 177, 768
Pacheco, Mariano: 978
Pacheco, Tiago: 122, 186
Pacho Millan, Laura: 149, 441
Pacho, Laura: 435, 439, 604
Pack, Tiago: 336, 527
Padrão, Teresa Gantes: 532, 539
Padrosa, Joan: 833
Páez Guillán, Emilio Manuel: 151, 479
Paez-Guillán, Emilio: 340, 342
Pah, Ana-Maria: 71
Pais-De-Lacerda, António: 3, 202, 528, 645, 956
Pais, Ana Rita: 162
Pais, Carmem: 127
Pais, João: 74, 97
Pais, João Pedro: 70, 696, 755, 873, 874
Pais, Tiago: 57, 152, 616
Paiva, Carolina: 257, 426, 477, 568, 591
Paiva, David: 294, 403, 464, 476, 551, 553, 694, 777, 849, 850, 926, 931
Paiva, Paula: 537, 671
Paixão Ferreira, Margarida: 198, 249, 805
Paixão-Dias, Vítor: 496
Paixão, Anusca: 197, 225, 542, 612
Paixão, Joana: 199, 221, 239, 326, 388, 846, 907
Paker, Melisa Askim: 279
Palacios-Fernández, Sergio: 73, 322, 383, 460, 626, 902
Palacios, Diana Buendia: 942
Palagano, Nicolas: 843
Palavras, Maria: 607
Palavras, Maria João: 88, 141, 166, 270, 277, 589, 640
Palavras, Maria João Guerra Lopes: 273
Palha, Vanessa: 72, 461, 494, 498, 849
Pallotta, Enrico: 712
Palma, Carolina: 219, 248, 682
Palma, Carolina Carrilho: 213, 274, 473
Palma, Nuno Zarcos: 376
Palmeira, Mireille: 148
Palmese, Francesco: 320
Palmieri, Vincenzo Ostilio: 45, 377, 749
Palomar Calvo, Luis Miguel: 709
Palomar-Muñoz, Carmen: 579, 580
Palomar, Luis Miguel: 408, 774
Palomar, Victoria: 408, 774
Palricas, Ana: 176, 594
Panarra, António: 275, 387, 487, 532, 552, 568, 669, 729, 730, 890, 891, 895, 920
Pañagua, Paula: 3
Paniagua, Ramón: 953
Panigadi, Cristián: 261, 716
Panov, Dmitriy: 23
Pansare, Rahul Shashikant: 757
Pantaleoni, Stefano: 27
Pantazi, Iurie: 314, 315, 867
Paolicelli, Paola: 45
Papadima, Christina: 854
Papadimos, Georgios: 289, 536
Papaioannou, Ioanna: 327, 380, 381, 382, 390, 436, 437, 606, 854
Papanikolaou, Nikolaos: 420
Papanikolaou, Vasiliki: 327
Papismadov, Benny: 31
Parcelas, Eunice: 894
Pardo Ortega, María Victoria: 387
Pardo Sanchez, Susana: 897
Parejo Morón, Ana Isabel: 720
Parente, Catarina: 316, 317, 492, 843
Parente, Dalila: 789
Parente, Rita: 222, 410
Parente, Sebastián: 633, 634, 804
Park, Joong-Min: 586
Parlapan, Adelina: 69
Parlato, Federica: 369, 680, 683, 685, 696, 924, 927, 976, 978
Parodi, Carolina: 740
Parodi, Javier: 716
Parra Jordán, Juan José: 453
Parra Navarro, Marta: 149, 441
Parra Virto, Alejandro: 427, 791, 845
Parra, Catarina: 728
Parra, Marta: 435, 439, 604

Parreira, Mário: 473
Parreira, Hugo: 588
Parreira, Mário: 213, 219, 274, 682, 686
Parvu, Mirela: 883
Pascual Pérez, Susana Fabiola: 703, 895
Pascucci, Matteo: 707
Paskalis, Georgios Charis: 486, 536, 693, 892
Passera, Sonia: 712
Passerini, Francesca: 45
Passos, Dúlio: 640
Passos, Dúlio Teixeira: 487, 490, 894, 903
Pastor Marín, Sergio: 486
Pastor Marín, Sergio Antonio: 456
Patacho, Marta Ferreira: 635
Patacho, Marta Sá: 365
Patarata, Eunice: 568
Patary, Brikodar: 735
Patrão, Luís: 506
Patrícia, Tereza: 164
Patrício, Catarina: 165, 858
Patrício, Joana: 213, 274, 473
Patrício, Patrícia: 105, 183
Patronillo, Catarina: 321, 589, 951
Paul, George: 735
Paulino, Carolina: 203
Paulino, Madalena: 176, 454, 594
Paulo, Sérgio: 429
Paulos, Ana Rita: 79
Paulos, Rita: 681, 819
Paupério, André: 157, 201, 864, 896
Pavlaki, Maria: 854
Pavleska, Lidija: 939
Pavlou, Konstantinos: 445
Paz Fajardo, Lucía: 87, 273, 360
Paz, Victor: 161
Peagu, Razvan: 345
Peçanha Viana, Alessandra: 957
Pedrazzoli, Roberta: 841, 869
Pedreira, Diana: 431, 785
Pedro, Bárbara: 164, 495, 599
Pedro, Mónica: 494, 502, 944
Pedro, Nelson: 95, 295, 546
Pedro, Paula: 795
Pedro, Whine: 344, 443, 458, 674
Pedromingo Kus, Miguel: 85, 91
Pedroso, Ana: 203, 726
Pedroso, Ana Isabel: 492
Pedroso, Ermelinda: 132, 136, 213, 219, 228, 248, 274, 339, 372, 393, 473, 677, 682, 686, 699, 907, 927, 983
Pego, Petra: 215
Pego, Petra M.: 917
Peixe, Bruno: 368
Peixoto, Maurício: 92, 275, 287, 915
Pelayo Garcia, Maria Gema: 123, 392
Pelikánová, Terezie: 236, 248
Pellicer Espinosa, Isabel: 271
Peña Balbuena, Sonia: 800
Peñalba, Mariana: 716
Peñaloza Martínez, Eduardo Luis: 426, 605, 766, 790, 879
Perdigão, Sofia: 161, 446, 508, 952
Perdigao, Sofia Manuela: 440
Perdomo, María Valentina: 394
Pereira, Maximiliano: 65
Pereira Da Silva, Alda: 288
Pereira Oliveira, Inês: 62
Pereira Rodrigues, Lénia: 448
Pereira, Aida: 490
Pereira, Amália: 569
Pereira, Amélia: 110, 290, 511, 629, 677, 680, 760
Pereira, Ana: 669
Pereira, Ana Francisca: 369, 443
Pereira, Ana Rita: 64, 65, 95
Pereira, Artur: 894
Pereira, Bernardo: 293, 296
Pereira, Carlos: 105
Pereira, Carolina: 657, 934
Pereira, Catarina: 92, 164, 181, 565, 702
Pereira, Catarina Ribeiro: 281, 655
Pereira, Catarina Vilaça: 197, 363, 365, 747
Pereira, Cátia: 199, 326, 330
Pereira, Cátia Marisa Loureiro: 414, 588, 782
Pereira, Cristina: 218
Pereira, Diogo: 672
Pereira, Domingas: 875
Pereira, Flávio: 58, 375, 405, 779, 790, 894
Pereira, Francisca M.: 693
Pereira, Gabriela: 167, 299, 553, 621, 897, 965
Pereira, Gaspar: 252, 499, 669
Pereira, Helder: 65, 121
Pereira, Isaac: 449
Pereira, Isabel Gil: 820
Pereira, Joana: 858
Pereira, João Gonçalves: 222
Pereira, João Pacheco: 210, 564
Pereira, José: 366, 608, 856
Pereira, Laurinda: 326, 434, 603
Pereira, Luís: 189, 540, 572, 776
Pereira, Luísa: 160
Pereira, Márcia: 872
Pereira, Márcia Agostinho: 128
Pereira, Marco: 512
Pereira, Margarida: 681, 819
Pereira, Margarida Sá: 186
Pereira, Maria Maragarida: 917
Pereira, Maria Margarida: 215, 217, 765
Pereira, Marta: 68, 227, 491, 871
Pereira, Marta Matos: 237, 754
Pereira, Nuno: 218, 700, 925

Pereira, Patrícia Gomes: 296
Pereira, Paula: 859
Pereira, Paulo Ricardo: 150
Pereira, Pedro: 363
Pereira, Pedro Manuel Reis: 370
Pereira, Prof Dr Helder: 64
Pereira, Rafaela: 131, 185, 292, 531, 678, 679
Pereira, Ricardo: 213, 219, 274, 400, 473, 557, 682
Pereira, Rita: 19, 512
Pereira, Sara: 59
Pereira, Sílvia Santos: 132
Pereira, Sofia: 103, 590, 664
Pereira, Sónia Campelo: 290, 680
Pereira, Susana: 5
Pereira, Susana Gonçalves: 668
Pereira, Tiago: 480, 497
Pereira, Vítor: 799
Peres, Danay: 671
Peres, Guiomar: 934
Perestrelo, Paula: 665
Pereverzeva, Kristina: 43
Pérez Ardila, María Alejandra: 229, 394, 395
Pérez Arellano, José Luis: 406
Perez Galera, Salvador: 141
Pérez Hernández, Onán: 301
Pérez Linaza, Alba: 895
Perez Mijenes, Danay: 702, 930
Pérez Munoz, Emma: 456, 486
Perez Papadopulos, Amalia Veronica: 63
Pérez Ricarte, Sara: 848
Pérez Sanz, María Teresa: 427
Pérez Tamayo, Isabel: 790
Perez- Vazquez, Gloria Perez: 580
Pérez-Ramada, Dolores: 77, 685
Pérez-Ramírez, Alina: 78, 107
Pérez-Ricarte, Sara: 24, 24
Perez-Vazquez, Gloria: 579
Perez, Andrea: 955
Pérez, Begoña Guerra: 595
Perez, Carlos: 261
Perez, Danay: 645
Pérez, Hernán: 738
Pérez, Lucía: 329
Perez, María Pilar: 552
Perez, Mariona: 439
Perez, Marta: 5
Periago-Peralta, Adela: 420, 421
Perlingeiro, Raissa De Moraes: 504
Pernas Pardavila, Hadrián: 345, 479, 963
Perneta, Filipe: 195, 846
Pessegueiro, Helena: 332, 755
Pessoa, Ana: 454
Pessoa, Diana: 934
Pessoa, Lucília: 480, 497
Petersons, Aivars: 568
Petreska Zovic, Biljana: 939
Petreski, Tadej: 26
Petrikkos, Panagiotis: 190
Petrova, Milana N.: 70
Petrucci, Mario: 712
Petrucci, Tiago: 468
Pettinelli, Maria: 712
Phatel, Hanni: 31
Phyu, Ei Ei: 587
Picado, Bárbara: 835
Piçarra, Bruno: 74, 97
Pidal, Ana: 454, 676
Pienkowska, Joanna: 815
Pierini, Liliana: 716
Piersantelli, Maria Novella: 216
Pierson, Marine: 333
Pietrantonio, Filomena: 707
Piko, Nejc: 2, 26
Pilalas, Dimitrios: 158, 465, 876
Pimenta De Castro, Ana: 531, 679
Pimenta, Diana Alexandra: 783, 784
Pimenta, Fátima: 288, 479, 770, 857, 860, 881
Pimenta, Joana: 702
Pimenta, Joana Liz: 308, 370, 483, 660, 966
Pimentel, Fabiana: 290, 452
Pimentel, Fabiana Costa: 982
Pimentel, Maria Teresa: 498
Pimentel, Teresa: 72, 323, 461, 494, 849
Pina Cabral, João: 188, 208, 267, 353, 634
Pina Cabral, João Eduardo Costa Ferreira: 541
Pina, Rui: 208, 631
Pina, Sérgio: 811
Pinelo, Elisabete: 330, 414, 588, 782
Pinhal, Fernanda: 352, 899
Pinheiro Paiva, Patrícia Daniela: 666
Pinheiro, Alice: 454
Pinheiro, Beatriz: 790, 801
Pinheiro, Dulce Mendonça: 66
Pinheiro, Filipe: 840
Pinheiro, Guiomar: 135
Pinheiro, Hélder: 457
Pinheiro, Hugo: 155, 619
Pinheiro, Inês: 314, 945
Pinheiro, Isabel: 970
Pinheiro, Isabel Maria: 366, 976
Pinheiro, Sara: 795
Pinheiro, Sofia: 502, 911
Pinho Santos, Diana: 280, 281, 283, 949, 977
Pinho, Ana Filipa: 341
Pinho, Filipa: 423, 698, 918
Pinho, Raquel: 407, 468
Pini, Stefanie Francesca: 453
Pinilla Llorente, Blanca: 759, 845, 897

Pinilla, Blanca: 835, 870
Pintassilgo, Inês: 204
Pinto Medeiros, Rita: 260
Pintó Salas, Xavier: 252
Pinto, Alfredo: 350, 351
Pinto, Ana Maria: 775
Pinto, Ana Raquel: 669
Pinto, André: 442, 920
Pinto, André Santos: 519, 816
Pinto, Carla: 617, 618, 864
Pinto, Claudemira Fernanda: 80
Pinto, Cristiana: 349, 750
Pinto, Cristina Almeida: 66
Pinto, Fátima: 278, 505, 656, 657
Pinto, Joel: 99, 242, 272, 313, 375, 779, 790, 842, 894
Pinto, Luísa: 423, 698, 700, 918
Pinto, Maria João: 458
Pinto, Mariana Matos: 288
Pinto, Mário: 526, 814
Pinto, Paula: 60, 62, 200
Pinto, Pedro: 147, 158, 262, 785, 799
Pinto, Sara: 553
Pinto, Sara M.: 74
Pinto, Sara Moreira: 76, 76, 88, 117, 166
Pinto, Teresa: 101, 263, 279, 333, 589, 620, 660, 713, 805, 865, 951
Pinto, Zósima: 499, 635
Pintor-Huertas, Jose María López: 433
Pippo, Antonella: 740
Piqueras Ruiz, Sandra: 259, 427, 457
Pires, Ana Filipa: 549
Pires, Carla Marques: 28, 30
Pires, Catarina: 336, 526, 527, 692, 795, 823
Pires, Joana: 152
Pires, Lígia: 19
Pires, Lindora: 201
Pires, Marco Lopes: 636
Pires, Olga: 93, 191, 315, 407, 418, 515
Pires, Olga Cristina: 348, 893, 964
Pires, Romeu: 131, 297, 548
Pires, Sara: 135
Pires, Sara Xavier: 218
Pires, Sofia Xavier: 225, 931
Pires, Tatiana Costa: 440, 507, 562, 635
Pires, Vanessa: 619
Pirisi, Mario: 50, 311, 317, 336, 361, 448, 839, 841, 869
Pirovano, Alice: 317
Pirtac, Elena: 94, 367, 575
Pisano, Giuseppina: 107, 347, 357
Pissarra, António Pedro: 208
Pissarra, Diana: 200
Pita, Cristina: 468
Pita, Dina: 476, 638, 658, 892
Pita, Dina Rodriguez: 114, 210, 220, 506, 525
Piteira, Ana Rita: 431, 785
Piteira, Maria: 169
Piteira, Maria J.: 429, 598
Piteira, Maria Teresa: 565
Piteira, Teresa: 429
Pitta, Luz: 14
Pitta, Maria Luz: 136
Pivanova, Anastasia: 880
Pizarro, Tomás Camacho: 728
Pizzuto, Andrea: 27, 593
Placidi, Giuseppe: 198
Plácido, Raquel Bastos: 298, 661
Plaz Torres, Maria Corina: 331
Plenc, Mariela: 604
Plenc, Mariela Silvana: 435, 439
Poblet Florentín, Judith: 848
Poças, José: 632
Pocaterra, Daria: 398, 436
Pocinho, Rita: 146, 521
Poço, Jorge: 641
Poggi, Alice: 512
Poletto, Cesare: 27
Polo Sabau, Jorge: 791
Polsinelli, Matteo: 198
Polychronopoulos, Georgios: 158, 876
Pombo, Francisco: 619, 864
Pombo, Francisco Torres: 533
Pomies, Lucia: 65
Pomponio, Giovanni: 830, 830
Pona, Ana Paula: 326, 434, 603
Ponciano, Ana: 57, 152, 616, 899
Ponciano, Ana Inês: 352
Ponte, Alcina: 140, 234, 250, 269, 296, 440, 507, 549, 562, 569, 635, 669, 899, 930
Ponte, Alcina Mota: 799
Ponte, Teresinha: 82, 113, 134, 636
Popova, Anna: 568
Popovici, Mariana: 68, 124, 669
Portas, Pilar: 815
Porteiro, Beatriz: 344, 435, 443, 458, 674
Portincasa, Piero: 45, 326, 377, 749
Porto, Lénea: 534, 980
Portugal, Rita Serejo: 857
Pose Bar, Marta: 151
Pose, Adriana: 716
Poulos, Ioannis: 854
Poursanidis, Paris: 157, 445
Pousinha, Alexandra: 541
Pousinha, Alexandra Prizal: 176
Póvoa, Andreia: 573, 577, 598
Póvoa, Pedro: 203
Prado, Carmen: 953
Prat, Aleix: 604
Prazeres, Jorge: 109

Prescott, David: 91, 167, 224
Prescott, David Ferreira: 93
Presume, João: 124, 128
Prieto-Espinoza, Carolyn Itala: 195
Prieto, Sergio: 833
Principe, Nuno: 203
Proença, José: 170, 173, 214, 659, 900
Proença, Tânia: 181
Protopopov, Mikhail: 919
Provini, Stella: 712
Pruvot, Etienne: 69
Psillakis, Konstantinos: 420
Ptlog, Nadedja: 905
Puceta, Laura: 535, 954
Puche Palao, Gabriel: 271, 286, 410, 417, 456, 624, 762, 838, 841, 855, 960
Puente Fernández, Samuel: 918
Puente, Juan Igor Molina: 85, 91
Puente, Nuria: 267, 268
Puente, Samuel: 707
Pugliese, Stefania: 45, 377, 749
Pulfer, María Dolores: 428
Pulido Adragãos, Francisco: 184
Pulido Valente, Francisca: 71, 155, 258, 462, 463, 468
Puntí, Laura: 856
Pupo, Alexandra: 654
Puppo, Francesco: 890
Putá, Erinda: 839
Puthenkote, Baiju Faizal: 827
Quah, Daniel Song Chiek: 730
Quan, Ruilin: 39
Quaresma, Mariana Cristina: 700, 925
Quaresma, Marta: 294, 348, 454, 676
Quaresma, Tiago: 828
Queirós, João: 884
Queirós, João Pedro Ferreira: 502
Queirós, Rita: 827
Quelhas, Eugénia: 697
Quereda Rodriguez-Navarro, Carmen: 544
Quina, Cátia: 571
Quintão, Susana: 128, 130
Quitério, Adriana: 678
R Santos, Liliana: 299, 928
Rabadão, Tiago: 58, 133, 152, 766
Rabinovich, Anat: 560
Radonic, Radovan: 586
Rafael, Ana: 254, 952
Raftakis, Ioannis: 908
Rahmouni, Safa: 861, 862, 882, 883
Raimundo, Ana Rita: 440
Raimundo, Pedro: 192
Raimundo, Rúben: 118, 222, 234, 410
Raimundo, Ruben Guerreiro: 350
Raimundo, Sara: 197, 405
Ralh, Neeharika: 505
Ramalheira, Carlos: 622, 811
Ramalheira, Carlos Pinhão: 94
Ramalhinho, Vitor: 334
Ramalho, Ana Cochicho: 96
Ramalho, Cristina: 44, 137, 147, 166, 247, 488, 600, 601, 748, 769, 850, 851, 891, 949, 950, 966
Ramalho, Diogo: 121, 226
Ramalho, José: 217, 765
Ramalho, Paulo: 265
Ramalho, Sara: 596, 746
Ramalho, Sara Almeida: 94, 566
Ramírez Navarro, Jesús: 433
Ramírez-Blanco, Yonay: 77, 685
Ramona, Bonometti: 50
Ramos Germán, Francisco Javier: 402
Ramos Merino, Lucía: 499
Ramos Santos, Luis: 309, 736
Ramos-Rincón, José M.: 460
Ramos, Armindo: 184, 492
Ramos, Aura: 562
Ramos, João: 866
Ramos, Jose Manuel: 383
Ramos, Juan José Torres: 43, 102, 709, 848
Ramos, Mariana Moniz: 974, 975
Ramos, Patrícia: 348, 454, 676
Ramos, Paula: 205
Ramos, Paulo: 109
Ramos, Sara Augusta: 973
Ramos, Tania: 267
Rancans, Kristaps: 571
Ranchor, Ridhi: 700, 925
Randjelovic, Jelena: 559
Rangel, Milena: 898
Rapetti, Rachele: 317, 361
Raposo André, Diogo: 50, 104, 359, 585, 736, 744
Rato, Maria: 921
Rawlings, Deborah: 726
Re, Azzurra: 50
Realista Pedrosa, Ana: 364, 523
Rebelo, Ana Teresa Bogalho: 260
Rebelo, Olinda: 855
Rebelo, Sandra Celeste Dias: 325
Rebelo, Sandra Dias: 602
Rebocho, Francisco: 291
Rebocho, Luísa: 169, 170
Rebollo, Álvaro Nava: 848
Redondo Urda, María José: 422, 475
Redondo, María José: 958
Regadas, Maria João: 93, 191, 315, 348, 407, 418, 515, 893, 964
Regamey, Pierre-François: 712
Rego De Figueiredo, Inês: 487
Rego, Almerindo: 145, 419, 419, 787, 788, 859
Rego, Ana Rita Oliveira: 875

Rego, Fábio Salgueiro: 104
Rehm, Sophia: 509
Rei, Andreia: 197
Reigota, Catarina: 566
Reigota, Catarina Peliz: 968
Reigota, Rita: 808
Reis Veloso, Ricardo: 505
Reis, Ana Areia: 549
Reis, Ana Hipólito: 213, 227, 644, 649
Reis, Ana Isabel: 863
Reis, António: 809, 810
Reis, Bruna Albertini: 968
Reis, Diana: 300, 368, 470, 529, 695, 817
Reis, Rúben: 184, 326, 434, 603
Renaudineau, Yves: 316
Renier, Gilles: 739
Rentsch, Katharina: 509
Repolho, Debora: 121
Reppas, Konstantinos: 781
Resende, Janine: 496
Resende, Janine Azevedo: 812
Reshetnikov, Igor: 263
Reth, Peter: 435, 604
Reyes Cadena, Daniela: 618
Reyes-Suárez, Paula: 107, 901, 944, 973
Reyes, Daniela: 596
Rezgui, Amel: 276, 284, 378, 381, 745, 761, 861, 909, 954, 955
Rezi, Elena Cristina: 276, 352
Reznik, Elena Vladimirovna: 771
Rezus, Ciprian: 69, 205
Rezus, Elena: 69, 205
Riba, Janos: 216
Ribeirinho-Soares, Pedro: 92, 565, 702
Ribeirinho, Rita: 280, 639, 904
Ribeiro Almeida, José: 9
Ribeiro Dos Santos, Liliana Filipa: 260
Ribeiro Dos Santos, Pedro: 200
Ribeiro, Ana: 251, 441, 615, 674, 770, 858
Ribeiro, Andreia Machado: 500, 651
Ribeiro, Armindo: 474, 628, 859
Ribeiro, Carla: 471, 787, 807, 964
Ribeiro, Fani: 242, 313, 491, 648, 661, 691, 824, 842
Ribeiro, Heloisa: 5, 108
Ribeiro, Inês: 142
Ribeiro, Joana: 75, 801, 815, 867
Ribeiro, Joana Arana: 314, 315
Ribeiro, João: 452
Ribeiro, João Olivério: 804
Ribeiro, João Olivério Albuquerque: 915
Ribeiro, Juvenalia: 497
Ribeiro, Luis: 485
Ribeiro, Márcia: 221, 369
Ribeiro, Maria Inês: 291, 683
Ribeiro, Maria João: 798
Ribeiro, Pedro: 18, 188, 278, 308, 388, 541, 846, 907
Ribeiro, Pedro Cerdeira: 89
Ribeiro, Renata: 904
Ribeiro, Susana: 676
Ribeiro, Vicência: 639, 795
Ribot-Hernández, Iván: 944
Ricardo Pires, Joana: 168, 855
Ricciulli, Manuela: 498
Riccobono, Eleonora: 512
Ricconi, Francesca: 216
Rico Corral, Miguel Angel: 141
Ridaura Aparisi, Bianca: 402, 404, 477
Riera-Mestre, Antoni: 649
Righi, Ilaria: 86
Rigopoulou, Eirini: 325
Rigopoulou, Eirini I.: 307, 843
Rigueira, Joana: 928
Rinaldi, Luca: 357
Ríos Holgado, Isabel: 379, 750
Ríos Holgado, Isabel M: 642
Rios Lasso, Eduardo: 922
Rios, Elena: 300, 342, 475, 529, 686, 817
Ríos, Gabriel Antonio: 46, 110, 111, 323, 432, 437, 701
Riou, Jérémie: 739
Riqué Dormido, Jesús: 554
Risso, Marina: 4, 716
Rita, Helena: 160, 407, 468, 478, 632
Ritis, Konstantinos: 843
Rito, Miguel: 695
Rivas, Marina Báez: 723
Rizzi, Eleonora: 50
Rizzi, Thales: 453, 504, 753, 863, 898
Rizzi, Thales Oliveira: 900
Robaina-Bordón, Jose María: 685
Robalo Nunes, António: 613
Robalo, Margarida: 89
Robalo, Maria Margarida: 508, 661
Roberto, Fredo Renato: 12, 585
Robiou Vivero, Enrique José Antonio: 836
Robles, Mercedes: 325
Roca, Josep: 455
Rocha, Ana: 573
Rocha, Ana Nunes: 176
Rocha, Ana Silva: 157
Rocha, Bruno: 124
Rocha, Elsa: 58
Rocha, João: 155
Rocha, Luís: 962, 963
Rocha M., Sara: 259
Rocha, Margarida: 59, 495, 553, 897, 965
Rocha, Marta Arriaga: 180, 251, 276
Rocha, Patrícia: 59
Rocha, Paula: 487, 894, 903
Rocha, Raquel: 150, 168, 168

Rocha, Sofia: 175
Rochate, Dina: 118
Roda, Angela: 551
Rodil-Fraile, Raquel: 67, 385
Rodrigo Castroviejo, Nuria: 709
Rodrigues Almeida, Hugo Miguel: 124, 687
Rodrigues Gonçalves, Isabel: 252
Rodrigues Junior, José Anibale: 968
Rodrigues Monteiro, Miguel: 241, 416
Rodrigues, Afonso: 336, 522, 527, 823
Rodrigues, Ana: 75, 470, 562, 669, 902
Rodrigues, Ana Bento: 468, 526, 878
Rodrigues, Ana Catarina: 350
Rodrigues, Ana Cláudia Furão: 148
Rodrigues, Ana Filipa: 521, 531, 701
Rodrigues, Ana Furão: 260, 645
Rodrigues, Ana Isabel: 181, 274, 342, 392, 475, 529, 686, 817, 870
Rodrigues, Ana Rita: 440, 549
Rodrigues, Bruno: 172
Rodrigues, Carla Maria Marques Pires: 55
Rodrigues, Carla Pires: 447, 614
Rodrigues, Carlos: 152, 610, 615, 855
Rodrigues, Carmélia: 147, 158, 262, 625, 689, 696, 799
Rodrigues, Carolina Alves: 202
Rodrigues, Catarina: 68, 124, 130, 517, 645
Rodrigues, Catarina Quina: 55
Rodrigues, Céu: 346, 493, 638
Rodrigues, Cláudia: 303, 399, 578
Rodrigues, Cristina: 255, 797
Rodrigues, Daniela Dantas: 89
Rodrigues, Daniela Luz Silva: 162, 631, 881
Rodrigues, Fátima: 894
Rodrigues, Filipa: 57, 93, 323, 407, 478, 497, 652, 698
Rodrigues, Filipe: 926
Rodrigues, Helena: 566, 760, 968
Rodrigues, Henrique Cabrita: 645
Rodrigues, Joana: 265, 879
Rodrigues, João: 117, 814
Rodrigues, João Oliveira: 526
Rodrigues, Jorge: 497, 539, 683
Rodrigues, Jorge Ricardo: 512, 672
Rodrigues, Josefina: 844
Rodrigues, Larissa: 898
Rodrigues, Lénia: 763
Rodrigues, Lúcia: 935
Rodrigues, Luis Filipe: 497
Rodrigues, Margarida: 175
Rodrigues, Mariela: 278, 505, 656, 657
Rodrigues, Mário: 912, 912
Rodrigues, Marta Gomes: 185
Rodrigues, Miguel: 218
Rodrigues, Pedro: 58
Rodrigues, Raquel: 109
Rodrigues, Ricardo: 537, 620
Rodrigues, Rita: 930
Rodrigues, Rita J.: 269, 296, 899
Rodrigues, Rita Nunes: 631
Rodrigues, Sara Sarmiento: 135
Rodrigues, Sofia: 540
Rodrigues, Susana Vicente: 416, 592
Rodrigues, Tatiana: 595, 959
Rodríguez Alonso, Beatriz: 406, 434
Rodríguez Ávila, Elisa Esther: 798
Rodríguez Fernández-Viagas, Cristina: 554, 703
Rodríguez Ferrero, María Luisa: 793
Rodríguez García, José Manuel: 456
Rodríguez Mayo, María: 499
Rodríguez Pavón, Jesica: 716
Rodríguez Suárez, Sara: 798
Rodríguez-Gaspar, Melchor: 107, 973
Rodríguez, Beatriz: 124, 687
Rodríguez, Carmen: 238
Rodríguez, Jose Claro: 206, 473
Rodríguez, Luis Miguel Palomar: 43, 102, 848, 950
Rodríguez, Sara: 962
Rojano Rivero, Gloria María: 371, 757, 792
Rojas Lorence, Rocío: 379, 642, 750
Roldão, Marisa: 153
Rolla, Inês: 972
Rolo, Rui: 783, 784
Romano, Antonino Davide: 771
Romano, Barbara: 712
Romano, Miguel: 70, 346, 350, 351, 696, 755, 873, 874
Romão, Vera: 773, 932, 935
Romeiro, Silvia Patricia Silva: 723
Romero Acevedo, Lucía: 301
Romero Alonso, Alberto: 139
Romero Bernal, Agueda: 473
Romero Jiménez, Manuel Jesús: 305, 792
Romero-Orcajada, María José: 420, 421
Romero, Daniel Giovanni: 596
Romero, Enrique: 218
Romero, Inês: 731
Romero, Martha: 752
Romero, Selva: 740
Romero, Víctor Madrid: 43, 73, 102, 709, 848, 950
Roncalli, Massimo: 335
Ronchetti, Mario: 707
Roncon-Albuquerque, Roberto Jr: 203
Roque, João: 334
Roque, Maria Filomena: 140, 310, 584
Rora, Mia: 586
Ros-Vilamajó, Rosa: 973
Rosa, Clara: 136, 228, 393, 677, 699, 983
Rosa, João Borges: 295, 546
Rosado E Silva, Raquel: 627
Rosado, Cláudia: 648

Rosado, Margarida: 385
Rosales Salyano, Victor Hugo: 836
Rosario-Mendoza, Héctor: 77, 685
Rosário, Cristina: 28, 74, 76, 88, 117, 166
Rosário, Marisa: 789
Rosete, Marisa: 511, 677, 680
Rosinha, Patrícia: 233, 648
Rosinhas, João: 162
Rossetti, Giulia: 830, 830
Rossetti, Valeria: 86
Rossio, Inês: 96, 667
Rostami, Mohsen: 656
Rota, María José: 937
Roula, Daoud: 245, 772
Roumpou, Afroditi: 327, 380, 381, 382, 390, 436, 437, 606, 854
Rouxinol, Pedro: 407
Roxana, Sararu: 345
Roy, Biswadeep: 304
Royo-Villanova Reparaz, Carlota: 456, 486
Rozi, Foteini: 854
Rua, Fernando: 288
Rua, Inês: 571
Rua, Joana: 127, 131, 297, 349, 548, 728, 750
Rua, João: 278, 808
Ruas, Gonçalo: 976
Rubio-Marin, Patricia: 668, 670
Rubio-Martin, Esther: 579, 580
Rucay, Pierre: 739
Rudoy, Andrey: 100
Rueda Lara, Jonnathan: 618
Rueda, Jonnathan: 596
Rueff Rato, Inês: 496
Rufino, Rodrigo: 15, 38, 145, 162, 312
Rugeles Niño, Jessica: 518, 798
Rugeles, Jessica Paola: 746, 962
Rugina, Sorin: 344
Ruivo, Jorge A.: 970
Ruiz Barranco, Inés: 793
Ruiz Valdepeñas, Benjamín: 716
Ruiz, José Ruipérez: 563, 806
Ruiz, Lucas: 474, 813
Russo, Carlos: 721
Rymberg, Varvara P.: 83
Sá Lopes, Ramiro: 113, 115, 125, 756
Sá, Ana: 72, 323, 461, 494, 498, 849
Sá, Ana João: 789
Sá, Ana Pinheiro: 362, 910, 914
Sá, João: 532, 539
Sá, Juliana: 211, 641, 819, 869
Saavedra Becerril, Daniela: 836
Saavedra, Amanda: 747, 753, 900
Saavedra, Ana: 254
Sabah, Hanachi: 559
Sabino, Vander: 654
Sacchi, Florencia: 65
Sacco, Roberto Maria: 84
Sachla, Zacharo: 289, 486, 693, 892
Sáenz De Tejada López, Marta: 371, 757, 792
Sáez-Martínez, Elvira: 78
Sáez, Rosário: 449
Saez, Rosario Blanco: 292
Safciuc, Sorina-Monica: 403
Sagoschen, Ingo: 42, 561
Sagris, Dimitrios: 446, 843
Sagy, Iftach: 560, 829
Sahebal, Shaira: 340
Sahu, Nitasa: 303
Sahuquillo Serrano, María: 322
Sahuquillo, María: 73, 467, 467
Saidi, Wafa: 761, 765, 769
Saigal, Jennifer: 396
Saijo, Masaji: 745
Sainaghi, Pier Paolo: 448, 841, 869
Sainaghi, Pierpaolo: 839
Sais, Gemma: 439, 604
Saitis, Asterios: 843
Sajid, Sara: 737
Sakkalis, Anastasios: 138, 520
Salavert Lleti, Miguel: 467
Salazar, Tatiana: 58, 59, 454, 676, 932
Salcedo Aguilar, Francisco Javier: 73, 626
Salcedo, Mario: 73, 322, 383, 467, 626, 902
Salero, Teresa: 113, 125, 689, 756, 811
Salgado, Alberto: 30, 614
Salgado, Catarina M.: 202
Salgado, Matilde: 605
Salgado, Vilma: 487, 490, 640, 894, 903
Salgueiro, Elson: 447
Salgueiro, Fábio Rêgo: 540
Saliba, Walid: 22
Salima, Zekri: 559
Salmón González, Zaida: 447, 556, 577
Salomão, Jorge: 58, 923
Saloustros, Emmanouil: 612
Salvá D'Agosto, Pilar: 759
Salvado, Catarina: 114, 210, 220, 476, 506, 525, 638, 658, 668, 892
Salvado, Vera: 662
Salvador, Fernando: 126, 560, 827, 980
Salvador, Pedro: 185, 824
Salvador, Sara: 162
Salvi, Aldo: 216
Salvo, Sofia: 708, 709, 713
Samaniego, Neera Toledo: 54, 759
Samarkos, Michael: 659
Samões, Beatriz: 103, 226, 664, 742
Samouco, Gonçalo: 815
Sampaolesi, Mattia: 216

Sampedro Martinez, Victoria: 430
Sampedro, Manuela Josefa: 435
Sampedro, Victoria: 602, 835
San Martin, Fransico: 628
Sanches, Ana Rita: 153
Sánchez Alvarez, Julio: 428, 429
Sánchez Cámara, Luis: 793
Sánchez Fuentes, Demetrio: 85, 91, 975, 978
Sánchez González, Rebeca: 85, 91
Sánchez Junquera, Paloma: 404, 564
Sánchez Ledesma, María: 434
Sánchez Oliva, M. Purificación: 958
Sánchez Oliva, Purificación: 422, 475, 718
Sánchez Pérez, María José: 301, 301
Sánchez Ruiz Granados, Elena: 757
Sánchez Sánchez, Araceli: 422, 475
Sánchez Sánchez, Cristina: 85, 91
Sánchez Vidal, Efrén: 499
Sánchez-García, M^a Esther: 905
Sánchez-Hernández, Virginia H.: 953
Sánchez-López, Míriam: 194
Sanchez-Martinez, Rosario: 460
Sánchez-Pérez, M.J: 107
Sanchez-Rojas, Maria Carmen Vera: 456, 486
Sánchez-Seco, María Paz: 415
Sánchez-Soblechero, Antonio: 428
Sánchez, Abel: 338
Sanchez, Beatriz Guerrero: 35, 36
Sánchez, Chavely Valdés: 303, 396
Sánchez, Cristina: 856
Sánchez, Demetrio: 415
Sanchez, Joaquina Rodriguez: 728
Sanchez, Luís: 527
Sanchez, Noelia: 3
Sánchez, Rafael: 415
Sánchez, Sonsoles: 415
Sánchez, Verónica: 716
Sandoval, Luis Fernando: 338
Sandra, Braz: 924
Sanlés González, Iria: 447, 556, 577
Sanmartín Pensado, Francisco Javier: 499
Sanroma Mendizábal, Pedro: 453
Santa Cruz, André: 515, 788, 966, 972
Santamaria, Vicente: 962
Santo Manres, Ángela: 456
Santo Manres, Ángela: 486
Santo, Catarina Espírito: 476
Santo, Maria E.: 26, 27
Santos Felipe, Fabiana: 295
Santos Ferreira, Diogo: 66, 67
Santos Martín, Carlos: 800
Santos Pinho, Filipa: 700
Santos Silva, Marília: 255, 613
Santos Silva, Marília Santos: 150
Santos, Afonso: 290, 298, 452
Santos, Alexandra: 764
Santos, Alexandra Vieira Aires: 764
Santos, Ana Catarina: 440, 562
Santos, Ana Filipa: 142, 159, 182
Santos, Ana Lopes: 376
Santos, Ana Rita: 68, 74, 124
Santos, André: 470, 534, 980
Santos, Arsénio: 120, 688
Santos, Bernardo Figueiredo: 929, 933
Santos, Catarina: 729, 730
Santos, Catarina Duarte: 252, 669, 930
Santos, Catarina Reis: 671
Santos, Cátia: 23, 273, 354
Santos, Cátia Ribeiro: 141, 585, 873
Santos, Cláudia Sofia: 799
Santos, Daniela: 493
Santos, Daniela Soares: 120
Santos, Diogo: 832
Santos, Diogo Costa: 309, 425
Santos, Eduardo: 225
Santos, Fábio Videira: 218
Santos, Filipa: 625
Santos, Filipe Cunha: 117
Santos, Flávia: 88, 166, 270, 277, 585, 640, 811
Santos, Francisca: 132, 136, 228, 369, 393, 699, 983
Santos, Francisca Saraiva: 248, 677, 686
Santos, Gabriela: 808
Santos, Helder: 21, 881
Santos, Henrique: 204, 225
Santos, Inês: 52, 327, 364, 611
Santos, Inês Costa: 213, 219, 274, 473
Santos, Inês Fernandes: 543
Santos, Inês Vieira: 105, 183, 564
Santos, Iolanda: 697
Santos, J. Meneses: 640
Santos, Joana: 649
Santos, Joana Dos: 643, 653, 681
Santos, Joana Sofia: 650
Santos, João: 23, 141, 273, 585
Santos, João Meneses: 359, 487, 490, 679, 894, 903
Santos, João Namora: 94, 566
Santos, Josefina: 573
Santos, Lèlita: 95, 292, 295, 507, 546, 566, 760, 804, 880, 886, 968
Santos, Letícia: 596, 746
Santos, Ligia: 376
Santos, Lígia Rodrigues: 128
Santos, Luís Graça: 19
Santos, Maria Beatriz: 146, 419, 459, 481, 520, 611
Santos, Maria Inês: 286, 345, 570, 644, 644
Santos, Mariana: 182
Santos, Mariana Ribeiro: 175
Santos, Mariana Silva: 162, 631, 881

Santos, Marina Raquel: 156
Santos, Mauro: 498, 701
Santos, Miguel González: 250, 440, 507, 562, 569, 635, 930
Santos, Patrícia: 260
Santos, Paula Sousa E: 588
Santos, Pedro: 121
Santos, Raquel: 28, 257, 426, 847
Santos, Raquel Rodrigues: 591
Santos, Rita: 203, 469
Santos, Rui: 293, 353, 368, 513
Santos, Sandra: 199, 326, 846
Santos, Sandra D.: 221, 278
Santos, Sara: 21, 37, 636, 944
Santos, Sofia Marques: 96
Santos, Sónia: 352, 589, 899, 915
Santos, Teresa: 557, 568
Santos, Tiago Sepúlveda: 658
Santos, Vera Costa: 471
Santos, Vitor: 778
Santos M., Rui: 493, 631
Saoud, Imen: 381, 955, 956
Saphina, Nellya: 332
Sapinho, Guilherme: 679, 683, 685, 696
Saraiva, Alcina: 780, 781
Saraiva, André Pinto: 808
Saraiva, Bárbara: 319, 359, 527, 905, 908
Saraiva, Mariana: 8, 14, 14
Sarasin, François: 188
Sarhane Salvi, Yasmina: 903
Sarhane, Yasmina: 433
Sarkar, Niladri: 555, 735
Sarmiento, David: 814
Sarmiento, Helena: 59, 431, 456, 621
Sarmiento, Helena Jacinto: 409
Sarmiento, Inês: 128, 130
Sarmiento, Pedro Morais: 532, 539
Sarmiento, Salvador Morais: 114, 210, 220, 476, 506, 525, 638, 658, 892
Sarmiento, Sara: 767, 974
Sarmiento, Vera P.: 74, 97, 169, 170
Sarsenova, Ainagul: 8
Sartoretti-Schefer, Sabine: 148
Sartori, Filippo: 442
Savopoulos, Christos: 158, 465, 876
Sawai, Yukimitsu: 951
Sayhi, Samah: 887
Sayhi, Sameh: 547, 550, 762
Sayin, Serhat: 737
Sbaihi, Siwar: 537
Scaccabarozzi, Chiara: 211
Scaccianoce, Giuseppe: 749
Schavartz, Michelle: 3
Scheffler, Max: 39
Scheggi, Valentina: 44
Scheip, Ildiko: 883
Scherer, Eduard: 148
Schivavone, Cosima: 53
Schläpfer, Jürg: 69
Schleinitz, Nicolas: 743
Schovanek, Jan: 230
Schramm, Christoph: 325
Schütz, Philipp: 231
Seabra, Daniel: 60, 200
Seara, Vera: 25, 190, 263, 321, 333, 620, 660, 713, 865
Sebaiti, Daniel: 95, 121
Sebaiti, Daniel Neves: 64, 65
Secco, Thaisy: 453, 753, 863, 900
Secco, Thaisy Marques: 504
Seco Vasco, Jose Ramon: 206, 473
Segovia-Alonso, Pablo: 355, 356
Segovia, Vanesa: 205
Segura, Ursula: 105
Segurado, Marta Duarte: 407
Seixal, Miguel Granado: 264
Seixas, Andreia: 553
Seixas, Rui: 379, 474, 628, 710, 859
Selada, Joana: 412, 413, 460
Sellitto, Cristiana: 534
Selva O'Callaghan, Albert: 833
Semedo, Patrícia: 903
Semedo, Patrícia Miguel: 490
Semedo, Pedro: 97
Senan, Sunil: 735
Senturk Oztas, Nihan: 758
Sepúlveda, Carolina: 179, 492, 546, 654
Sequeira, Carolina: 282, 412, 413, 460, 763, 798, 934
Sequeira, Joana: 628
Sequeira, Mafalda: 204
Sequeira, Manuela: 103, 121, 336, 664, 684, 687, 783, 945
Sequeira, Maria Inês: 577, 598
Serafeim, Christos: 854
Serafino, Serena: 84
Sergi, Evaggelia: 138, 201, 520
Serna-Muñoz, María José: 420, 421
Seródio, Joana: 237, 754
Seródio, João: 305, 741
Serodio, João Fernandes: 19
Serpa Pinto, Luísa: 135
Serra, Eduardo: 547
Serra, Isabel: 290
Serra, Sónia: 599, 979, 981
Serradeiro, Elisa: 827
Serraino, Cristina: 792
Serrallonga, Aleix: 435, 439, 604
Serrano García, Isabel: 895
Serrano, Isabel Arvanas: 35, 35, 36
Serras Jorge, Rita: 881
Sersnova, Nadezda: 568

Serviddio, Giovanni: 357
Sérvio, Rita: 91, 167, 224
Sesana, Giovanni: 86
Settimo, Enrica: 45
Sevdali, Eirini: 316
Shadat, Rosie: 724
Shafat, Tali: 1, 89, 557, 847
Shamasna, Motasem: 185
Shanmugam, Harshitha: 326
Sharapov, Olimkhon Nadirkhanovich: 941
Sharma, Abhinav: 49
Sharp, Stephen: 235
Shcheglova, Elena Vital'Evna: 80
Shemenkova, Victoria: 733
Shevchenko, Anastasia: 756
Shiang, Teresa: 471, 787, 807, 807, 964
Shiels, Paul: 17
Shikh Hamdon, Mulham: 98, 505
Shimizu, Taro: 947
Shimony, Avi: 89
Shleyfer, Elena: 560
Shochat, Tzippi: 555
Shonia, Monika: 736
Shuperliski, Kire: 84
Shvarts, Boris: 1, 557, 829, 847
Siafarikas, Christos: 411, 591, 781
Sidahi Serrano, Maryam: 792
Sideras, Lazaros: 286, 289, 486, 536, 693
Sidiropoulos, Georgios: 536, 693
Sidlovszky, Noemi Katalin: 87
Sierra Manzano, Jose María: 718
Sierzputowski, Pawel: 828, 853
Sifi, Karima: 159, 244, 245, 739
Sigon, Giordano: 107
Silva Marques, Joana: 174, 506
Silva, Amilcar: 199, 326
Silva, Ana: 474
Silva, Ana Bento: 228
Silva, Ana Mafalda: 264, 548
Silva, Ana Paula: 292
Silva, Ana Rita: 57
Silva, Anabela: 157, 490
Silva, Andrea: 351, 484
Silva, Andreia: 75, 902
Silva, António: 698, 918
Silva, Artur: 328
Silva, Beatriz Valente: 636
Silva, Bruno: 161, 172
Silva, Carina: 553, 832
Silva, Carina Costa: 221, 369, 516
Silva, Carlos: 558
Silva, Carolina: 135
Silva, Cristina: 224, 456, 476, 621, 865, 866, 965
Silva, Daniela Abreu: 981
Silva, Diana: 393, 983
Silva, Diana Neto: 677
Silva, Dilva: 543, 846, 916
Silva, Diogo J.: 653, 976
Silva, Diogo João: 646, 647, 649
Silva, Duarte: 147, 158, 262, 785, 799
Silva, Eloísa: 471, 787, 807, 964
Silva, Eugénia: 581
Silva, Fátima: 208, 388, 666, 846
Silva, Fernando: 766
Silva, Filipa: 80, 248, 339
Silva, Filipa Sofia: 431, 599, 785
Silva, Filipe Alçada: 645
Silva, Francisco: 30, 214, 228, 543, 581
Silva, Francisco Teixeira: 350, 351
Silva, Fredo Renato: 179
Silva, Glória: 942
Silva, Inês Sf: 658
Silva, Isa: 540, 572
Silva, Isabel: 341, 497
Silva, Isabel Fonseca: 875
Silva, Joana: 174, 871
Silva, João: 211, 641
Silva, João Freitas: 135
Silva, José: 350
Silva, José Brito: 649
Silva, José Manuel: 815
Silva, José Miguel: 234
Silva, José Miguel Lessa: 410
Silva, Juliana: 166, 270, 456, 640
Silva, Luciana: 343
Silva, Luís Duarte: 192
Silva, Luísa Gomes: 362
Silva, Magda Sofia: 326, 434, 603
Silva, Margarida Freitas: 896
Silva, Maria: 607, 813, 819
Silva, Maria Jesus: 409
Silva, Mariana: 571, 609, 688
Silva, Marília: 676
Silva, Marinha: 159
Silva, Marisa Teixeira: 164, 961
Silva, Miguel: 168, 664, 667, 926
Silva, Mónica: 271, 575, 646
Silva, Nilton: 5
Silva, Nuno: 349, 363, 827
Silva, Pedro M.: 26, 27
Silva, Pedro Marques: 29, 29
Silva, Pedro Marques Da: 25
Silva, Rafael: 916
Silva, Raquel: 495, 599
Silva, Renato: 654
Silva, Rita: 208, 478, 920, 960
Silva, Rita Carneiro: 126, 542
Silva, Roberto: 776, 777, 796

Silva, Rogério Corga: 350, 351
Silva, Rosa: 620
Silva, Rosário: 110
Silva, Rui: 70, 558, 873, 874
Silva, Ryan Costa: 878
Silva, Sandra: 241
Silva, Sara Beatriz Santos Da: 243
Silva, Sara Vieira: 875
Silva, Sérgio: 368, 470, 695
Silva, Sónia: 819
Silva, Soraia Proença: 620
Silva, Susana Lopes: 602
Silva, Tiago: 314, 867
Silva, Vítor Macedo: 184, 627
Silveira, Ana: 278, 505, 656, 657
Silveira, Natacha: 796
Silveira, Victor Hugo: 747
Silverio, Rita: 339
Silvestre, Carina Rôlo: 112, 442, 779
Silvestri, Ivan: 211
Silvestri, Nunzia: 143, 391, 534
Simão, Adélia: 351, 484, 697
Simão, Diana: 502
Simão, Giovanna Oncala: 968
Simas, Ana: 278, 505, 656, 657
Simões, André: 222
Simões, Catarina: 727, 727
Simões, Joana: 671
Simões, Maria Inês: 160, 478, 632
Simões, Mariana: 130, 321, 442, 545, 608
Simoës, Otilia: 82
Simões, Rita: 266
Simón, Cintia: 205, 716
Simona, Culacsiz: 780
Simsferidis, Nikolaos: 612
Singh, Pratibha: 283, 513
Singh, Shuchi: 513
Sinha, Smriti: 705
Sintra, Sara: 484
Siopa, Luís: 136, 176, 183, 688
Sipari Merlo, Simona Maria: 27, 593
Skendros, Panagiotis: 843
Skride, Andris: 90
Slouma, Maroua: 470, 547, 550, 833, 834, 861, 862, 882, 883, 884, 885, 887, 888, 967
Slouma, Marwa: 762
Smagulova, Aliya: 54
Smirne, Carlo: 361
Smolenska, Zaneta: 815
Soares, Adriana: 328
Soares, Elsa: 699
Soares, José Ribeirinho: 363, 365
Soares, Maria Manuela: 418, 444, 946
Soares, Mariana: 142, 232, 405, 558, 587
Soares, Neuza: 11
Soares, Patricia: 452, 862
Soares, Pedro Ribeirinho: 181, 197, 747, 921
Soares, Sofia Garcês: 201, 789, 896
Soares, Zara: 294, 676
Sobral, Sofia: 379, 710
Soddu, Daniele: 839, 841, 869
Soeiro, Bárbara: 202, 797, 869
Soeiro, José: 650
Sofogianni, Areti: 158, 465, 876
Sola, Daniele: 448, 869
Solares, Isabel: 751
Solbiati, Luigi: 335
Sóler Gómez, Ángela: 72, 469, 703
Soles, Isabel: 118, 222, 234, 350, 410
Sommer, Johanna: 1
Son, Myeongchul: 745
Sonia, Kammoun: 901
Soong, John: 939
Soria Fernández-Llamazares, Guillermo: 426, 605, 766, 790, 803, 879
Soto Abraham, María Virgilia: 836
Sottomayor, Carlos: 328, 643, 681
Souris, Sotirios: 420
Sousa Carvalho, Margarida: 153
Sousa Costa, José António Santana: 503, 813
Sousa E Costa, José: 220, 474, 550, 628, 710, 859, 982
Sousa Ennis, Giovana Clare: 174, 280, 283
Sousa Guerreiro, António: 522, 526, 527
Sousa Martins, Rute: 259
Sousa Regueiro, Dolores: 499
Sousa Silva, Madalena: 460, 540, 572, 798
Sousa Uva, Maria: 130, 545, 916
Sousa Vale, José: 723
Sousa, Aida Botelho De: 588
Sousa, Ana: 184, 364
Sousa, Ana Antunes Ribeiro: 533
Sousa, Ana C.: 639
Sousa, Ana Célia: 928
Sousa, Ana Chora: 280, 904
Sousa, Bárbara: 68, 156, 174, 871
Sousa, Bruno: 108, 522
Sousa, Círia: 612
Sousa, Cristiana: 440, 952
Sousa, David Lopes: 221, 719, 907
Sousa, Débora: 519
Sousa, Domingos: 115, 181, 274, 300, 342, 368, 392, 470, 475, 529, 686, 695, 817, 870
Sousa, Filipa: 915
Sousa, Inês Egídio: 128, 731
Sousa, Inês Moreira: 5
Sousa, João: 172
Sousa, José: 261, 262, 336, 522, 526, 527, 795, 823
Sousa, Julieta: 248

Sousa, Manuel De: 210, 564
Sousa, Mariana: 472, 910
Sousa, Marlene: 513
Sousa, Marta: 9, 479, 679
Sousa, Nuno: 189
Sousa, Orlando: 179
Sousa, Paulo: 492, 546, 718
Sousa, Pedro Filipe: 966
Sousa, Raquel: 360, 518
Sousa, Ricardo Pinto: 666
Sousa, Sílvia: 202
Sousa, Susana: 778, 789
Sousa, Susana Marques: 25, 190
Souto, Márcia: 49, 197
Sozzi, Fabiola: 712
Spangenberg, Lucia: 97
Spechbach, Herve: 193
Speletas, Matthaios: 316
Spencer, Vanda: 99, 132, 647, 675
Sposito, Paola: 65
Spreafico, Sibilla Maria: 347
Spulveda, Carolina: 12, 585
Sri Kumaran, Shalini: 44
Srivastava, Avinash Chandra: 283
Stampalia, Franco: 738
Stan, Ana Alwina: 53
Stan, Andreea Constanta: 943
Staring, Grace: 551, 755, 816
Stathi, Dimitra: 190
Stavi, Vered: 829
Stavratis, Spiros: 420
Stefanopoulos, Anastasios: 854
Stefanova, Stela: 138, 201, 520
Stefos, Aggelos: 446, 843
Stepanova, Elena Alexandrovna: 771
Stoian, Marilena: 312
Stoica, Andreea Georgiana: 780
Stomeo, Niccolò: 400
Strada, Silvia: 50, 448
Strautmane, Sintija: 90
Strecht, Tânia: 179, 282, 460, 667, 763, 798, 934
Studniarek, Michal: 815
Sturla, Maria: 757
Suardi, Lorenzo Roberto: 44
Suárez Díaz, Silvia: 798
Suarez Herranz, Purificacion: 430
Suárez Pérez, Lucía: 798
Suárez-Díaz, Silvia: 518
Suarez, Carmen: 389
Suarez, Celina: 435, 439, 604
Suarez, Elena: 617
Suárez, Lucía: 746, 962
Suárez, Paula Reyes: 301, 301
Suárez, Silvia: 746, 962
Subra, Jean-François: 739
Subtil, Paulo: 481
Succi, Fabiana Moreira Passos: 968
Sucena, Inês: 630
Sucena, Inês Pereira: 787
Suero Roiz, Ana: 918
Suleac, Maxim: 222, 350
Sumares, Laurinda: 544
Sundalic, Sara: 586
Suzano, Rui: 656
Swarka, Muhareb: 31
Symeonidis, Nikolaos: 190
Tabiasco, Julie: 739
Taborda, Ana Lúcia: 492, 546
Taborda, Filipa: 111, 492, 540, 546, 570, 572
Taborda, Ricardo: 12, 401, 749, 828, 853
Tache, Ana: 465
Tache, Traian: 324, 786
Tadeu, Jose Pedro: 5
Takahashi, Atsushi: 325
Takase, Hiroshi: 947
Tamarit, Marta Del Palacio: 206
Tamburrini, Stefania: 534
Tan, Boo Hui: 720
Tanaka, Atshushi: 325
Tapadinhas, Camila: 203
Targher, Giovanni: 357
Tarsia, Paolo: 86
Tase, Mihal: 232, 941
Tasias Pitarch, María: 467, 467
Tassi, Michele: 84
Taulaigo, Ana: 532, 920
Taulaigo, Anna: 487
Tavares Sousa, Helena: 468
Tavares, Alda: 74, 76, 88, 117, 166, 328, 643, 681
Tavares, Alta: 76
Tavares, Andreia: 108
Tavares, Andreia Filipa: 593, 841
Tavares, Catarina: 426
Tavares, Filipa: 729
Tavares, João: 213, 274, 473, 682, 932, 935
Tavares, João Alexandre: 217, 219, 906
Tavares, Luis: 494
Tavares, Maria João Marelo: 834
Tavares, Miguel: 119
Tavares, Pedro: 549
Tavares, Pedro Neves: 252, 669, 930
Tavares, Sandra: 254, 446, 508, 614
Tavares, Sofia: 953
Taveira, Isabel: 185, 282, 379, 710, 824
Taveira, Mariana: 477, 591
Tay, Joelynn Qiao Bin: 706, 708
Tegos, Thomas: 158, 465
Teigell Garcia, Luis: 766

Teixeira De Sousa, Rita: 642
Teixeira Veríssimo, Manuel: 592
Teixeira, Ana Raquel: 647
Teixeira, Ana Sofia: 719
Teixeira, André: 729, 730, 920
Teixeira, André Filipe De Jesus: 387
Teixeira, Andreia M.: 133, 145, 264, 548
Teixeira, Andreia Vanessa Novais: 288
Teixeira, Carlos Osvaldo: 968
Teixeira, Gabriela: 122
Teixeira, Gilberto: 781
Teixeira, João: 327, 911
Teixeira, Jorge: 217, 347, 906
Teixeira, Júlio: 622
Teixeira, Júlio Lemos: 925, 936
Teixeira, Lídia: 912, 912
Teixeira, Mafalda Ferro: 364, 676
Teixeira, Maria Aparecida Barone: 968
Teixeira, Mariana: 766
Teixeira, Mónica: 935
Teixeira, Natália: 681, 819
Teixeira, Natália Teixeira Nunes: 79
Teixeira, Soraia: 136
Telenti-Asensio, Mauricio: 518
Teles, Carolina: 319, 353, 368
Teles, Luís: 5, 574, 688
Telychko, Maryna: 105, 337, 338, 623
Temido, Helena: 804, 886
Temtem, Ana Margarida: 156
Temtem, Ana Margarida De Abreu: 195, 846
Temtem, Margarida: 66, 736, 797, 798, 928
Teófilo, Eugénio: 565
Teotónio, Cristina: 701
Testa, Elisa: 792
Texeira, Soraia: 186
Tey, Vanessa Hwee Ting: 307
Thabet, Maissa: 381, 384, 745, 861, 954, 955, 956
Than, Htet Phyo: 587
Theaocharidou, Christina Chrysanthi: 286, 486, 536, 892
Thomas, Boban: 21
Thomas, Eugenia: 97
Thomas, Fassier: 210
Tiago, Vasco: 109, 360, 518
Tiberio-Lopez, Gregorio: 67, 385
Tica, Irina: 302
Tieman, Jennifer: 726
Tiersma, Stella: 466
Tigerino, Pablo: 701
Timpone, Sergio: 64
Tinoco, Eduarda M.: 783
Tinoco, Eduarda Milheiro: 471, 807, 964
Tintim, Carolina: 650
Tiraboschi, Silvia: 347
Tirelli, Paolo: 143, 391, 534
Titov, Vladimir Yu.: 83
Tjikongo, Odeth: 523, 524, 529
Tobaldini, Eleonora: 79, 84, 86
Tofani, Lorenzo: 512
Tohme, Aline: 754
Toledano Macías, María: 466, 759, 803, 897
Toledano, María: 835, 870
Toledo, Neera: 870
Tomásia Silva, Teresa: 678
Tomé Martínez De Rituerto, Santiago: 342
Tomé, Elisa: 208, 478
Tomé, Santiago: 340
Tomkinson, Kevin: 724
Tonacci, Alessandro: 890
Tonel, Carla: 500, 651
Toran, Pere: 455
Tordato, Federica Maria Pilar: 398, 436
Toresano López, Daniel: 447, 450, 453
Torgano, Giuseppe: 84
Tornada, Ana: 325, 602
Toro Valiente, Eva: 473
Torre, Edgar: 158, 262, 346, 799
Torre, Marta: 714
Torres, António Simões: 809, 810, 820, 822
Torres, Carmen: 356
Torres, Elisa: 551
Torres, Isabel: 280, 281, 283
Torres, John Molina: 255
Torres, José Pinheiro: 447
Torres, Jose Virgilio: 389
Torres, Raquel: 649
Torres, Veronica: 65, 815
Torres, Yesenia S Maldonado: 3
Torzilli, Guido: 331, 335
Torzillo, Daniela: 211
Tosatto, Valentina: 430, 522, 526, 527, 871
Toscano, Manuel: 492
Toth, Kalman: 216
Tounsi, Haifa: 852
Toyokawa, Tatsuya: 310
Trevisani, Franco: 320
Tribuna, Cindy: 28, 966, 972
Trigo Faria, António: 483, 750
Trigo, Ana Catarina: 55
Trigo, António Figueiredo: 714
Trigo, Catarina: 672
Trindade, Isabel: 403, 464, 777
Trindade, Miguel: 305, 741
Trivelato Felício Cenedesi, Renata: 957
Trofimova, Elizaveta: 733
Trombert, Veronique: 210
Trovão Bastos, Martim: 180, 276
Tsakanikas, Aristeidis: 411, 591
Tsakiri, Dimitra: 854

Tsatsakoulis, Argyrios: 154, 253, 256, 257, 451, 860
Tsifi, Aggeliki: 201
Tsifi, Angeliki: 138, 520
Tsiftsi, Palmyra: 154, 157, 253, 254, 256, 257, 445, 451, 524, 860
Tsilingiris, Dimitrios: 781
Tsilivarakis, Dimitris: 327
Tsiolpidis, Dimitrios: 154, 157, 253, 254, 256, 257, 445, 451, 524, 860
Tsipizidis, Vasilios: 154, 157, 253, 254, 256, 257, 451, 524, 860
Tsoutsouli, Vasiliki: 286, 289, 486, 536, 693, 892
Ttsakoulis, Argyrios: 254
Tsukagoshi, Junji: 940
Tufoni, Manuel: 320
Tuñón, Carlota: 408, 774
Tupin, Estefânia: 122
Turi, Vladiana: 71
Türker, Fatih: 952
Turki, Sami: 901, 969
Turpin, Estefânia: 186, 367, 732
Tyurikova, Lyubov: 775
Tziomalos, Konstantinos: 158
Tzur, Irma: 31
Ubiña Carbonero, Antonio: 17, 233, 375
Uchel, Toribiong: 505
Udrea, Florina Gabriela: 743
Udrea, Gabriela: 922
Ueda, Aki: 19
Ueda, Yasuyuki: 951
Ukar Naberan, Amaia: 582
Ulica, Ernesto: 229
Unal, Serhat: 396, 715
Ungureanu, Viorica: 69
Unnikrishnan, Rahul: 138, 302, 735
Úria, Sara: 942
Uryvaev, Aleksey: 100
Urzal, Joana: 517
Vachier, Jean Luc: 758
Vaio, Teresa: 319, 353, 368
Val Flores, Luís: 682
Valada Marques, Ana: 220, 388, 521, 542, 628
Valadão, Catarina: 132
Valadares, Diana: 977
Valadas, Ana De Matos: 636, 658
Valdez D'Stéfano, Lucia: 738
Valdez, Lucia: 716
Valdez, Pascual: 3, 4, 205, 261, 716, 738, 957
Valdez, Pascual Ruben: 738
Valdivieso, Carmen: 57, 323
Vale Fernandes, Pedro: 744
Vale, Jorge: 802, 803
Vale, José: 172
Valente Da Costa, Sara: 611
Valente, Ana Carmo: 674
Valente, Helena: 676
Valente, Isabel Pulido: 386
Valente, João: 60, 812
Valente, Rita: 122, 186, 367, 732
Valente, Tiago: 154, 472, 648, 661, 691, 790, 801, 824
Valenti, Luigi: 712
Valentim, Marta: 183, 688
Valentim, Marta Mendes: 675, 914, 917
Valenzuela Gonzalez, Antonio: 141
Valério, Bernardino: 203
Valério, Patrícia: 699
Valero, Beatriz: 460
Valiente Millán, María Teresa: 564, 942, 961
Valiuzhenich, Yaraslau: 100
Valle, Luis De Almeida: 708
Vallejo, Maite: 235
Vandernoot, Isabelle: 748
Vanzeller, Manuela: 471, 787, 807, 964
Vanzetti, Cecilia: 261
Varanda, Sara: 142
Varela García, Alba: 918
Varela Ramos, Patrícia: 294, 594
Varela, Ana: 185
Varela, Manuel: 238, 408, 488, 955
Vargas Ruiz, Beatriz: 705
Vargas, Borja: 238, 408, 488, 955
Varudo, Rita: 753, 867
Varvarina, Galina: 775
Vasconcelos, Alexandre: 605, 613, 869, 930
Vasconcelos, Andreína: 610, 615, 780, 781, 855
Vasconcelos, Carlos: 889
Vasconcelos, Gisela: 128, 376
Vasconcelos, Joana: 519
Vasconcelos, Manuela: 512, 539, 672, 683
Vasconcelos, Patrícia: 401, 580
Vasconcelos, Tiago: 407, 468
Vasilvolfa, Aiga: 568
Vasin, Anton: 607
Vasques, Ana Carolina: 934
Vassallo, Gabriele Angelo: 717
Vassalo, Tânia: 109
Vasta, Leonardo: 205
Vaucher, Andrea: 97
Vaz Cunha, Joana: 827
Vaz Marques, Paula: 126, 131, 297, 308, 349, 370, 440, 542, 548, 560, 750, 952
Vaz, Alexandra: 501, 793
Vaz, Ana: 747
Vaz, Bianca: 731, 746
Vaz, Joana: 425
Vaz, Joana Alves: 418, 444, 946
Vaz, José: 198, 249, 249, 452, 805, 862, 875
Vázquez Agra, Néstor: 151, 345, 479, 963
Vázquez Vicente, Rosalía: 456, 486
Vazquez, Dolores: 25, 101, 190, 660, 805

Vázquez, Dolores González: 951
Vázquez, Óscar: 408, 488
Vecchio, Domizia: 841
Vecchio, Vanesa: 205
Vedes, Joana: 905, 908
Veiga E Moura, António: 297, 622
Veiga, Carolina: 221, 832
Veiga, Ricardo: 172
Veiga, Tiago: 214
Velasco, Pablo: 707
Veleba, Jiri: 236, 248
Velebová, Katerina: 236, 248
Velez, Jorge: 144
Velho, Rafael: 347
Veloso, José Carlos: 174
Veloso, Ricardo: 278, 656, 657
Veloso, Tereza: 74, 97, 142, 169, 170
Venade, Gabriela: 868
Venâncio Pereira, Lurdes: 177
Venâncio, Lurdes: 768
Vendemiale, Gianluigi: 771
Vendramini, Natalia: 738
Vendramini, Paula: 716, 738
Venevtseva, Yulia: 41, 196
Ventura, Ana Sofia: 310, 609, 959
Ventura, Magda: 162
Ventura, Pedro: 98, 505
Venugopal, Anand: 219
Vera Cruz, Ana: 215, 217, 681, 765, 819, 917
Vera Delgado, Víctor: 301
Vera-Delgado, Víctor: 901, 973
Verão, Pedro: 57, 323
Verdasca, Irene: 128, 240, 934
Verdasca, Irene Cortes: 81
Verdelho, Miguel: 895
Vergara, Demetrio González: 706
Verma, Amit: 742
Verschelden, Gil: 340
Viana Coelho, Margarida: 115, 342, 371, 392, 475, 686, 870
Viana, Daniela: 131, 297, 349, 548, 612, 750
Viana, Daniela Sousa: 127
Viana, Lorrane: 472, 910
Viana, Margarida: 300, 529, 676, 817
Viana, Raquel: 899
Viana, Sara: 222, 410
Vicente, Ana Cláudia: 379
Vicente, Andreia Póvoa: 314
Vicente, Cláudia: 710
Vicente, Filipa: 744
Vicente, Inês: 460, 798, 934
Vicente, Leopoldina: 103, 170, 173, 211, 214, 242, 245, 335, 641, 659, 665, 782, 794, 900, 920
Vicente, Luís: 678
Vicente, Luis Gonçalves: 90
Vicente, Madalena: 128, 487, 552, 890, 891, 895
Vicente, Maria Inês: 179, 282, 667, 763
Vicente, Patrícia: 240, 354
Vicente, Rodrigo: 109
Victorino, Rui: 165, 369, 679, 680, 683, 685, 696, 924, 927
Victorino, Rui M.: 148
Victorino, Rui M. M.: 129, 357, 359, 487, 490, 640, 645, 894, 903, 936, 976, 978
Vida, Ana Carlota: 504, 655
Vida, Ana Carlota Policarpo Gouveia: 243
Vidal Vázquez, Martín: 479
Vidal Vázquez, Martiño: 345, 963
Vidal, César: 510
Viegas, Ana Filipa: 932, 935
Viegas, Claudia: 708, 709
Viegas, Conceição: 185, 637
Viegas, Hugo: 699
Vieira Alves, Rita: 374, 487, 532, 729, 730, 890
Vieira Brito, Nuno: 334
Vieira E Brito, Nuno: 12, 401, 749, 828, 853
Vieira, Ana Luísa: 788
Vieira, André Mendonça: 667
Vieira, Catarina: 447, 614
Vieira, Catarina Lima: 502
Vieira, César: 177, 530, 538, 574, 633, 634, 804, 818, 821
Vieira, Galini: 978
Vieira, Iolanda: 752
Vieira, Joana Tender: 80
Vieira, Lúcia: 962, 963
Vieira, Manuela: 133
Vieira, Maria João: 8, 14, 273
Vieira, Nuno: 261, 262, 385, 463, 969
Vieira, Nuno Bernardino: 100, 171, 971
Vieira, Pedro: 537, 577, 598
Vieira, Pedro Leite: 10, 11, 175, 671
Vieira, Priscilla: 453
Vieira, Rita: 104, 359, 891
Vieira, Vera Frazão: 899
Vieitez Santiago, Miriam: 404, 450, 453, 564, 582, 942, 961
Viganò, Luca: 335
Vigário, Ana: 925
Vigil, Luis: 238, 408, 488, 955
Vijayakumar, Priya: 735
Vilaça, Helena: 68, 156, 157
Vilaça, Marta: 55, 289, 672
Vilaça, Teresa: 442, 608, 779
Vilão, Filipe: 968
Vilas Boas, Andreia: 971
Vilas-Boas, Andreia: 721
Vilas-Boas, Isabel: 289
Vilas-Boas, João Paulo: 314, 945
Vilas-Boas, Paulo: 913, 929, 933
Vilas-Bôas, Sara: 631
Vilas, Ana Paula: 260, 299, 928

Vilchez, José: 502
Vilela, Andrés: 716
Vilela, Maria: 193, 618, 947
Villa De Brito, José Pedro: 372, 907, 927, 979, 981
Villa, Davide: 79
Villa, Juliana: 229, 394, 395
Villalba García, María Victoria: 270, 430, 845
Villalba, María Victoria: 602, 835, 870
Villanueva Cutillas, Bernat: 252
Villanueva, Rosana: 356
Villarejo, Esther Fraile: 950
Villarejo, Maria Esther Fraile: 73
Viña-Rodríguez, J: 107
Viñas, Montserrat Chimen: 43, 73, 102, 848, 950
Vinatier, Emeline: 739
Vincentelli, Giovanni Maria: 64
Virtuoso, Joao: 468
Visconti, Virginia: 160, 272, 386, 643, 653
Vishnoi, Saumya: 513
Vita, Cristina Limia: 87, 273, 360
Vital, Diana: 204, 337, 338, 623
Vital, João Aragão: 798
Vitorino Costa, Rita: 146
Vitorino, Helena: 96
Vitorino, Marina: 435, 443, 458
Vitorino, Silvia: 121
Viu, Ramón Boixeda: 455
Viveiros, Luísa: 635
Vizcaíno, José Ramón: 573
Vizinho Oliveira, Catarina: 460, 798
Vlad, Cristiana-Elena: 562, 852, 853
Voicu, Cristina: 344
Voicu, Gabriela: 743, 922
Voiculet, Cornelia: 116
Vojtek, Adam: 427
Volkanovska, Ance: 84
Volkova, Natalya: 263, 756
Vollenweider, Peter: 69
Volpi, Marcela: 957
Von Bardeleben, Ralph Stephan: 16
Voulgaridis, Apostolos: 201, 520
Voza, Antonio: 331
Vujaklija Brajkovic, Ana: 586
Vunnam, Rama: 396
Wacker, Julio: 261, 738
Waeber, Gérard: 712
Wah, Daniel Seto Yuan: 714
Wakai, Toshiaki: 745
Wang, Minghong: 970
Watts Soares, Adriana: 160, 266, 386
Watts, Adriana: 272, 653
Wehbé, Amine: 582, 583, 941
Wenzel, Philip: 61
Wong, Marc Hai Liang: 246
X, Lia Ferraro: 855
Xanthopoulou, Anna: 693
Xavier, Sofia: 627
Xu, Juliana: 321
Yahni, Diego: 205
Yakovtsova, Anna A.: 194
Yakushin, Sergey: 43
Yee, Yucai: 714
Yildiz, Canan: 235
Yildiz, Pinar: 715
Yilmaz, Murvet: 741
Yllera Gutiérrez, Carmen: 518, 798
Yllera, Carmen: 746, 962
Yucel Kocak, Sibel: 741
Yuda, Satoshi: 940
Zaccherini, Giacomo: 320
Zaccone, Vincenzo: 216
Zachou, Kalliopi: 307, 316, 325, 843
Zahger, Doron: 89
Zaicenko, Anastasija: 90
Zamudio Moya, Francisco José: 475
Zanquette, Giulia Dal-Cin: 229
Zara, Octavian: 116
Zaragoza, Ángela: 322
Zarakolu, Pinar: 396
Zavagli, Martina: 843
Zdanovskis, Nauris: 178
Zec Baskarad, Marcos: 716
Zecca, Erika: 317, 841, 869
Zekri, Salima: 159, 245, 739
Zekry, Dina: 39, 210
Zelechower, Hugo: 716
Zelinová, Jana: 179, 282, 667, 763, 934
Zhamaliyeva, Lazzat: 8
Zhamankulova, Damira: 8
Zhang, Tian-Tuo: 778
Zhang, Xin: 373
Zhou, Yu-Qi: 778
Ziedina, Ieva: 571
Zinkevich, Oleg: 332
Ziogas, Dimitris: 659
Zlopasa, Ozrenka: 586
Zorila, Eugenia Corina: 377
Zrida, Mohamed Sami: 81, 163, 886
Ztriva, Eleftheria: 158, 465, 876
Zuluaga, Juan David: 229, 394, 395